



Repair and Reconstruction of Medial- and Lateral-sided Knee Injuries

Robert F. LaPrade, MD, PhD
Lars Engebretsen, MD, PhD
Robert G. Marx, MD, MSc, FRCSC

Abstract

Surgical treatment of medial and lateral knee injuries using repair and/or reconstruction techniques is often necessary to restore knee ligament stability and optimize function. Successful execution of these repairs and reconstructions requires a sound understanding of basic anatomy and biomechanics. Against this backdrop, numerous repair and reconstruction techniques have been developed. Although medial knee injuries are often amenable to healing, posterolateral knee injuries often do not heal after a complete tear. Posterolateral corner repair should be attempted only in acute lateral knee injuries and never for midsubstance tears. Postoperative rehabilitation follows a period approach, with an emphasis on early range-of-motion exercises and protection of the surgical repair or reconstruction. By following these approaches to medial and lateral knee repairs and reconstructions, it is possible to restore stability to an injured knee and expedite return to desired levels of activity.

Instr Course Lect 2015;64:531–542.

Treating medial- or lateral-sided knee injuries requires a thorough understanding of knee anatomy and biomechanics to successfully restore native knee kinematics. Injuries to either side of the knee may warrant surgical

treatment, depending on which structures are damaged and the severity of injury. Medial-sided injuries often can be managed nonsurgically. However, primary repair or reconstruction of the medial knee structures should be

attempted in patients with multiligamentous injuries or knee dislocations. Chronic, medial-sided knee injuries with valgus misalignment should be treated with a two-stage approach. A distal femoral osteotomy should be performed first, followed by reconstruction of the medial knee structures.

Lateral-sided knee injuries usually do not heal and require surgical treatment. Primary repair should be attempted for acute repairs except for midsubstance tears. A variety of reconstruction techniques have been developed for posterolateral corner knee injuries. This chapter's authors recommend

Dr. LaPrade or an immediate family member serves as a paid consultant to or is an employee of Arthrex and Smith & Nephew; has received research or institutional support from Arthrex, Smith & Nephew, Ossur, and Limvate; and serves as a board member, owner, officer, or committee member of the American Orthopaedic Society for Sports Medicine; the International Society of Arthroscopy, Knee Surgery and Orthopaedic Sports Medicine; the Arthroscopy Association of North America; and the European Society for Sports Traumatology, Knee Surgery and Arthroscopy. Dr. Engebretsen or an immediate family member has received royalties from Arthrex; is a member of a speakers' bureau or has made paid presentations on behalf of DePuy and Arthrex; serves as a paid consultant to or is an employee of Nycomed, Arthrex, and Smith & Nephew; has stock or stock options held in iBalance; has received research or institutional support from Smith & Nephew; and serves as a board member, owner, officer, or committee member of the European Society for Sports Traumatology, Knee Surgery and Arthroscopy. Dr. Marx or an immediate family member serves as a board member, owner, officer, or committee member of the International Society for Arthroscopy, Knee Surgery and Orthopaedic Sports Medicine.

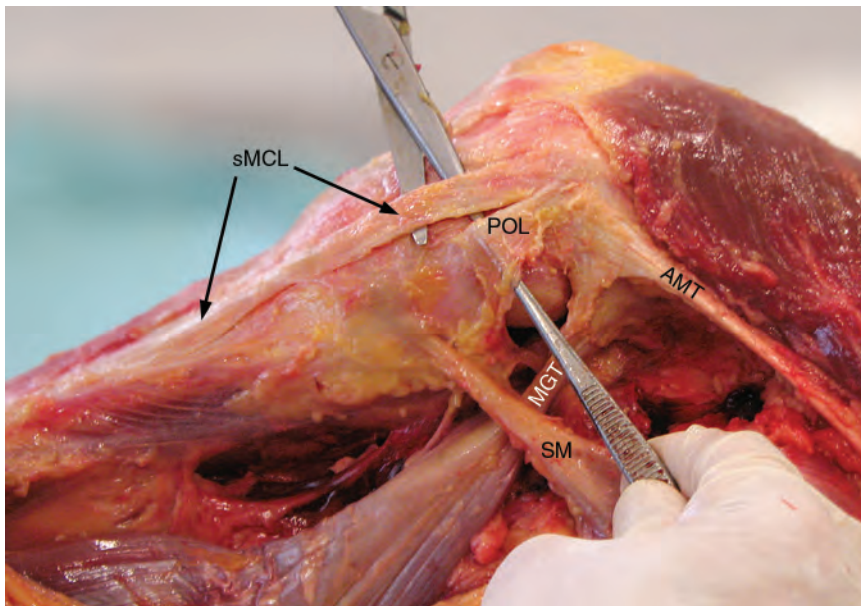


Figure 1 Photograph of the medial aspect of a right knee showing the gross anatomy. AMT = adductor magnus tendon, MGT = medial gastrocnemius tendon, POL = posterior oblique ligament, SM = semimembranosus, sMCL = superficial medial collateral ligament.

anatomic-based reconstructions, which have been validated biomechanically to restore knee function. Rehabilitation should involve early range of motion (ROM), with the goal of full return to activity after the patient has been cleared by the physician.

Medial-sided Knee Injuries Anatomy and Biomechanics

Understanding the anatomy and biomechanics of the medial knee provides an essential foundation for effectively diagnosing and treating medial knee injuries. The primary medial knee stabilizers are the superficial medial collateral ligament (sMCL), the posterior oblique ligament, and the deep medial collateral ligament (dMCL). On the medial aspect of the femur, three bony prominences—the medial epicondyle, the adductor tubercle, and the gastrocnemius tubercle—may be referenced to locate the sMCL, the posterior oblique ligament, and dMCL footprints during

surgical repairs or reconstructions. By understanding the key relationships of ligament and tendinous structures to these bony landmarks, it is possible to perform anatomically accurate medial knee surgical repair and reconstruction techniques.¹

Superficial Medial Collateral Ligament

The sMCL is the largest medial knee structure and consists of a femoral attachment and proximal and distal tibial attachments (**Figure 1**). At its proximal attachment, the sMCL is located 3.2 mm proximal and 4.8 mm posterior to the medial epicondyle.² From its proximal attachment, the sMCL courses distally, attaching first to the proximal tibia 1.2 cm distal to the proximal joint line over the anterior aspect of the semimembranosus tendon. The sMCL continues distally, where it attaches once again to the tibia approximately 6.1 cm distal to the proximal joint line.

Although the proximal tibial attachment has a much lower load to failure (88 N) than the distal attachment (557 N), both attachments provide substantial functional contributions, including resisting valgus gapping, and therefore should be restored during sMCL repair or reconstruction.³ The sMCL is the primary restraint against valgus stress, external rotation at 30° of flexion, and internal rotation (along with the posterior oblique ligament) at all flexion angles.^{4,5}

Posterior Oblique Ligament

The posterior oblique ligament consists of fascial attachments extending from the distal aspect of the semimembranosus tendon, which can be divided into three arms: the superficial, central, and capsular arms.^{2,6,7} Of the three attachments, the central arm is the largest, thickest, and most functionally important.^{2,4} The proximal aspect of the central arm attaches 1.4 mm distal and 2.9 mm anterior to the gastrocnemius tubercle on the medial side of the femur. This relationship is essential for anatomic medial knee reconstructions. Many previous studies have reported that the posterior oblique ligament attachment is closer to the adductor tubercle and other nearby structures.⁷⁻⁹ The distal posterior oblique ligament attachment is adjacent to the semimembranosus tendon and has an additional attachment to the medial meniscus.

Deep Medial Collateral Ligament

The dMCL represents a thickening in the middle-third medial capsular ligament.² The structure is divided into a proximal menisiofemoral division and a distal meniscotibial division, with a firm meniscal attachment in the middle portion (**Figure 2**). The menisiofemoral portion attaches 12.6 mm distal to the

proximal sMCL attachment, whereas the distal meniscotibial portion attaches adjacent to the tibial plateau articular cartilage approximately 3.2 mm distal to the joint line and 9.0 mm proximal to the proximal tibial sMCL attachment. The meniscofemoral portion is consistently longer and thinner than the shorter and thicker meniscotibial division. Wijdicks et al³ reported that the mean load to failure of the dMCL was 101 N. The dMCL functions to resist valgus gapping.

Other Medial Knee Structures

The adductor magnus tendon also attaches along the medial aspect of the knee. The femoral attachment of the adductor magnus tendon is located an average of 3.0 mm posterior and 2.7 mm proximal to the adductor tubercle.² In addition, there is a thick fascial component that fans out posteromedially toward the medial gastrocnemius tendon. The vastus medialis obliquus muscle attaches along both the lateral aspect of the adductor magnus tendon and the thick posteromedial aspect of the tendon insertion.

The medial gastrocnemius tendon attaches 2.6 mm proximal and 3.1 mm posterior to the gastrocnemius tubercle.² It originates from the medial aspect of the medial gastrocnemius tendon and functions to plantarflex the foot. Other medial knee structures include the pes anserine tendon attachments, consisting of the sartorius tendon, the gracilis tendon, and the semitendinosus tendon. The semimembranosus tendon attaches to the tibia through a direct and an anterior arm. The anterior arm attaches deep to the proximal tibial attachment of the sMCL, whereas the direct arm attaches along the posteromedial aspect of the tibia proximal to the tuberculum

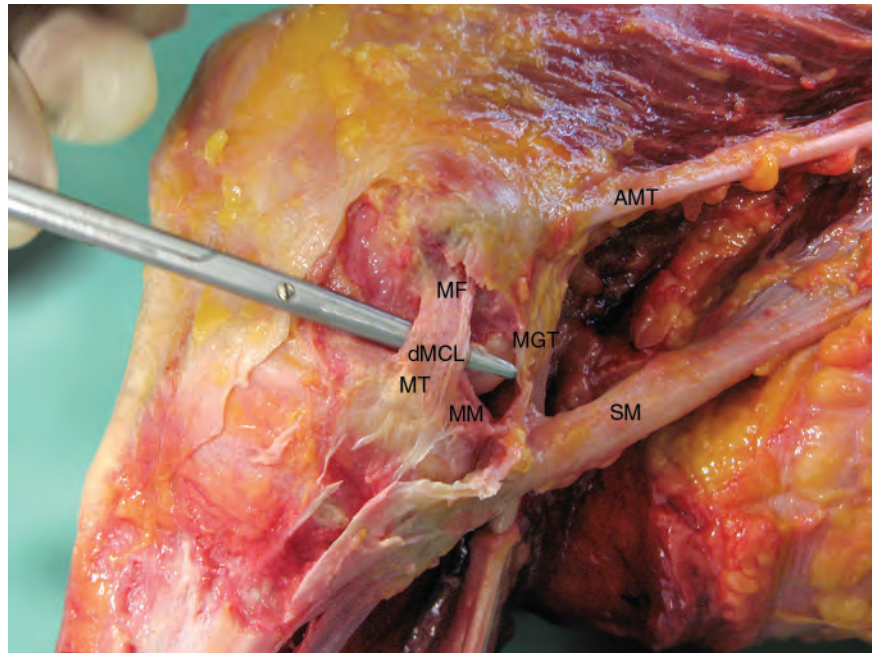


Figure 2 Photograph of the deep medial collateral ligament and the surrounding anatomy. The (dMCL) consists of a proximal meniscofemoral (MF) portion and a distal meniscotibial (MT) portion. AMT = adductor magnus tendon, MGT = medial gastrocnemius tendon, MM = medial meniscus, SM = semimembranosus tendon.

tendinis prominence.² Between these two layers, a semimembranosus bursa is formed.

The saphenous nerve and its infrapatellar and sartorius branches course through the medial aspect of the knee and should be avoided during a medial knee surgical approach.¹⁰⁻¹³ One study reported that the mean distance between the anterior border of the sMCL and the sartorial branch of the saphenous nerve was 4.8 cm and 2 cm distal to the joint line.¹² Moving further distally along the tibia, the distance between the sMCL and the saphenous nerve decreases. Because of the close proximity of the nerve to medial knee structures, grasping the anatomic relationship of the saphenous nerve to key medial knee structures is critical to avoid iatrogenic injury, such as during a medial knee surgical approach and a hamstring tendon harvest.¹⁴

Repair

Primary Repair

Indications for the primary repair of medial knee structures include acute cases of multiligamentous injuries or knee dislocations.¹⁵ Torn structures can be repaired with sutures alone or sutures plus suture anchors. Early, aggressive ROM in a “safe zone,” which is predetermined by the surgeon and the physical therapist, is essential to minimize the risk of arthrofibrosis after surgery.

Augmentation Repair

Augmentation repair for the sMCL is a surgical technique that can be used when tissue quality or surgical indications preclude primary repair.¹ Augmentation repair is performed by releasing the semitendinosus tendon from its proximal musculotendinous attachment with a standard hamstring

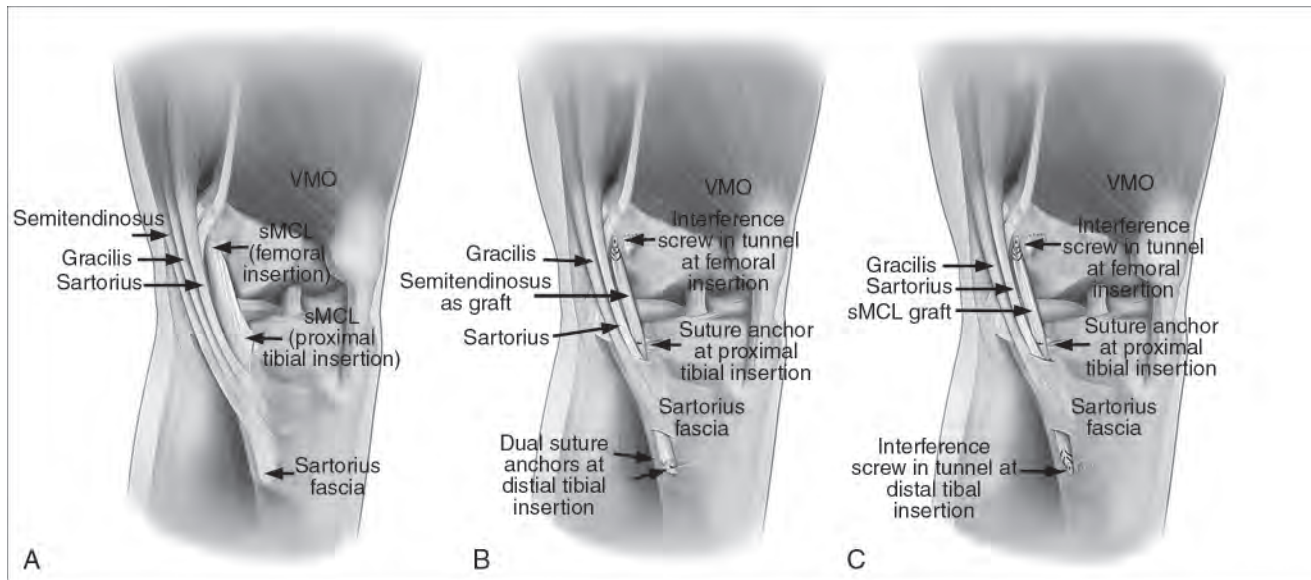


Figure 3 Illustrations demonstrating that the normal superficial medial collateral ligament (sMCL) anatomy (A) and function can be reproduced by using either an augmented repair (B) or reconstruction (C) with a semitendinosus autograft. VMO = vastus medialis obliquus. (Reproduced with permission from Wijdicks CA, Michalski MP, Rasmussen MT, et al: Superficial medial collateral ligament anatomic augmented repair versus anatomic reconstruction: An in vitro biomechanical analysis. *Am J Sports Med* 2013;41[12]:2858-2866.)

harvester (Figure 3). The semitendinosus graft is then reflected and secured at the distal tibial attachment of the sMCL 6 cm from the proximal joint line with two double-loaded suture anchors. The graft is then passed deep to the sartorius fascia. The graft is secured at the femoral sMCL attachment in a closed socket tunnel 3.2 mm proximal and 4.8 mm posterior to the medial epicondyle and fixed with an interference screw. The proximal tibial sMCL attachment is then secured 12 mm distal from the proximal joint line using a double-loaded suture anchor.

Reconstruction

Indications for medial knee reconstruction include acute injuries that fail to improve with a rehabilitation program, valgus gapping in extension, and chronic medial knee instability.¹⁵ Prior to considering surgical reconstruction in chronic medial knee injuries, it is

essential to obtain long-leg radiographs to assess for the presence of a valgus mechanical axis deformity (Figure 4). If a valgus deformity is discovered in the chronic setting, medial knee reconstruction for chronic knee injuries should proceed in a staged fashion, beginning with a distal femoral osteotomy to correct the patient's alignment to neutral. In the acute setting, if alignment is symmetric to the normal side, surgery can be performed in most cases without an osteotomy.

sMCL Reconstruction

Marx and Hetsroni¹⁶ described one reconstruction technique to minimize the risk of surgical overexposure, iatrogenic injury during autograft harvesting, and nonanatomic graft placement. An Achilles tendon allograft is used with the bone plug docked in the anatomic origin of the femur and distally at the insertion of the sMCL just above the

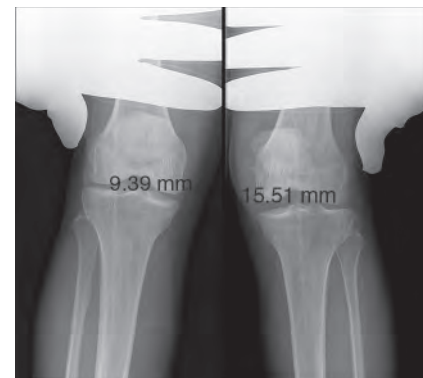


Figure 4 Valgus stress radiographs demonstrating a side-to-side difference of 6.2 mm of medial compartment gapping, which is indicative of a complete superficial medial collateral ligament injury.

pes anserinus tendons with a spiked soft-tissue washer. The outcomes following this technique have demonstrated that recreational athletes are able to return to their preinjury levels of activity.

Another reconstruction technique uses a semitendinosus autograft or allograft and closed socket reconstruction tunnels placed at the anatomic attachment sites at the proximal femoral attachment and the distal tibial attachment¹ (**Figure 5**). A double-loaded suture anchor is used to reproduce the proximal tibial sMCL attachment site.

Anatomic sMCL and Posterior Oblique Ligament Reconstruction

One anatomic-based technique has been developed to reconstruct both the sMCL and the posterior oblique ligament and uses two grafts and four separate tunnels.¹⁷ The sMCL is fixed in a tunnel at the anatomic attachment site of the sMCL on the femur and distally approximately 6 cm from the tibiofemoral joint line. Suture anchors are placed at the site of the proximal tibial attachment of the sMCL, which has been shown to play a smaller but clinically important role in medial knee stability, including valgus motion. The posterior oblique ligament is reconstructed using closed socket tunnels at the native attachment sites. The graft is tensioned and secured in full extension because this is when the posterior oblique ligament is tightest in the intact knee.

Radiographic Identification During Reconstruction

Given the importance of anatomic placement, numerous radiographic methods have been proposed to accurately assess the position of the medial knee tunnel during reconstruction.¹⁸⁻²¹ In cases of a severe obliteration of medial knee sutures or for revision medial knee reconstructions, intraoperative fluoroscopy should be considered for the placement of femoral reconstruction tunnels. Radiographic guidelines

are available for reconstruction of the medial patellofemoral ligament and the sMCL.¹⁸⁻²¹

Rehabilitation

Rehabilitation after medial knee repair and reconstruction must emphasize early ROM to minimize the risk of arthrofibrosis.¹⁵ All ROM exercises for the first 2 weeks should be limited from 0° to 90° of passive or passive-assisted knee flexion. After the first 2 weeks, ROM may progress as tolerated, with the goal of restoring full ROM by 6 weeks. In addition, isolated hamstring exercises should be avoided for the first 4 months postoperatively. Patellar mobilization exercises, straight leg raises in a knee brace, quadriceps sets, hip extension and abduction exercises, and ankle pumps also should be performed. Patients should not bear weight for the first 6 weeks; weight bearing can be increased as tolerated thereafter with an emphasis on restoring normal gait mechanics. At this time, stationary bike exercises and double-leg presses to 70° of knee flexion may be initiated.

At 12 weeks, the patient may discontinue use of a knee brace. At 16 weeks postoperatively, agility drills, including plyometric exercises, are initiated—assuming adequate muscular endurance, muscular strength, ROM, and balance have been achieved. Light straight line jogging may begin after the patient is able to walk 2 to 3 km without a limp or substantial effusion. Full return to activity is dependent on passing a functional test and obtaining physician clearance after subjective and objective assessment of medial knee stability.^{22,23} A side-to-side difference in valgus gapping on stress radiographs of less than 2 mm is considered successful restoration of medial knee stability. In

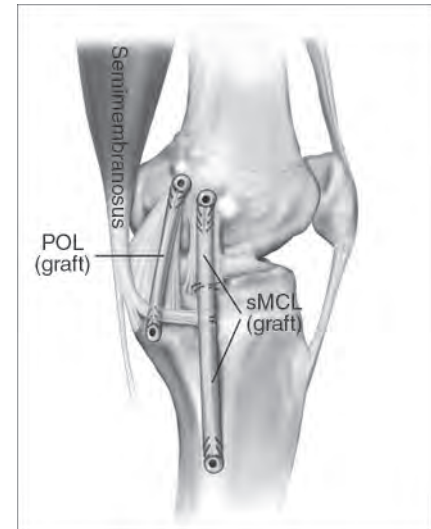


Figure 5 Illustration of an anatomic reconstruction of the superficial medial collateral ligament (sMCL) and the posterior oblique ligament (POL) performed with semitendinosus grafts and four closed socket reconstruction tunnels. (Reproduced with permission from Coobs BR, Wijdicks CA, Armitage BM, et al: An in vitro analysis of an anatomical medial knee reconstruction. *Am J Sports Med* 2010;38[2]:339-347.)

patients with cruciate ligament reconstruction or other concomitant surgical procedures, this rehabilitation regimen may be altered as needed to incorporate additional components.

Lateral-sided Knee Injuries Anatomy and Biomechanics

A thorough understanding of lateral knee anatomy and biomechanics is essential for the accurate diagnosis and the effective treatment of lateral knee injuries. In the past, some authors have characterized the lateral knee as the “dark side” of the knee. However, recent advances in lateral knee anatomy and biomechanics, the development of objective diagnostic methods, and the creation of anatomic repair and reconstruction techniques have led to

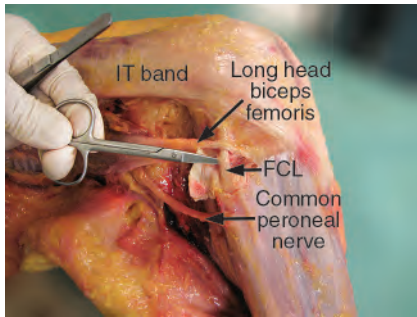


Figure 6 Photograph showing the gross anatomy of the distal attachment of the fibular collateral ligament (FCL) with the biceps bursa reflected in a right knee. IT band = iliotibial band.

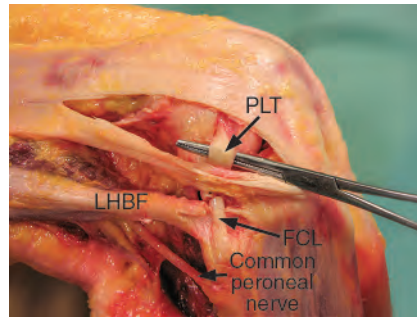


Figure 7 Photograph showing the gross anatomy of the lateral aspect of a right knee, demonstrating the common peroneal nerve, the fibular collateral ligament (FCL), the long head of the biceps femoris (LHBF), and the popliteus tendon (PLT).

improved outcomes after surgery. This section of the chapter highlights the essential anatomy and biomechanics of the primary static stabilizers of the lateral knee, including the fibular collateral ligament (FCL), the popliteus tendon (PLT), and the popliteofibular ligament (PFL), along with other associated structures.

Fibular (Lateral) Collateral Ligament

The FCL originates on the lateral aspect of the femur 1.4 mm proximal and 3.1 mm posterior to the lateral epicondyle.²⁴ This attachment is located approximately 18.5 mm from the PLT attachment, which represents a key anatomic relationship used during surgical repair and reconstruction. The FCL averages 69.6 mm in length and courses distally, deep to the iliotibial band and the indirect arm of the long head of the biceps femoris, before inserting in a small depression located 28.4 mm distal to the tip of the fibular styloid (**Figure 6**). The FCL is the primary varus stabilizer at 0° and 30° of flexion and a secondary restraint against tibial internal and external rotation.²⁵⁻²⁷ Lateral compartment gapping of 2.7 to 4.0 mm

has been reported on stress radiography after sectioning of the FCL and all the posterolateral corner structures, respectively.²⁸

Popliteus Tendon

The PLT emerges from the musculotendinous junction of the popliteus muscle and becomes intra-articular as it courses lateral and anterior to its attachment on the anterior fifth and proximal half of the popliteal sulcus. This attachment is located immediately adjacent to the lateral margin of the lateral femoral condyle articular cartilage (**Figure 7**). Functionally, the PLT has been termed the fifth ligament of the knee because of its contributions to multiplanar stability.²⁹ The PLT is the primary lateral knee restraint against tibial external rotation and provides additional resistance against internal rotation, varus angulation, and anterior translation.

Popliteofibular Ligament

The PFL originates at the popliteal musculotendinous junction and is divided into an anterior and a posterior division.²⁴ The anterior portion

attaches 2.8 mm distal to the tip of the fibular styloid, whereas the posterior division attaches 1.6 mm distal to the fibular styloid. The anterior division attaches along the anterior fibular head downslope, whereas the posterior division attaches on the posterior fibular head downslope. The PFL is a secondary restraint for providing resistance against external rotation at 30° and 60° of flexion and varus stability most prominently at 30° of flexion.^{27,30,31} Although small in size, the PFL is an important contributor to lateral knee stability. McCarthy et al³¹ reported that a PFL reconstruction component was required to adequately reproduce normal posterolateral knee function during reconstruction.

Other Lateral Knee Static and Dynamic Stabilizers

Other lateral knee static and dynamic stabilizers confer additional stability. The iliotibial band is a thick fascial structure that originates at the anterior superior iliac crest, courses distally and superficial to all lateral knee structures, and inserts on the lateral tibia at the Gerdy tubercle. The long head of the biceps femoris attaches in the posterolateral corner of the knee and provides dynamic stability to the knee. It consists of a direct arm that attaches to the posterolateral aspect of the fibular head and an indirect arm that spreads over the distal FCL attachment. The biceps bursa is formed between the direct and indirect arms, which must be incised to access the distal FCL attachment. The lateral head of the gastrocnemius muscle attaches on the lateral femoral head and is an important boundary for retractor placement during open posterolateral knee reconstruction procedures. A small thickening of the

middle-third lateral joint capsule, called the anterolateral ligament, has recently gained increased notoriety, although its functional importance remains controversial.^{32,33} The common peroneal nerve courses through the lateral aspect of the knee, posterior to the long head of the biceps femoris, before wrapping around the fibular neck and bifurcating into the superficial and deep peroneal nerves.

Repair

Primary repair after lateral knee injuries is indicated in very select circumstances. Repair should be considered for avulsed structures after acute injuries presenting within the first 3 weeks.³⁴ After that time, scar tissue deposition, tissue retraction, and degradation of ligament and tendon quality usually preclude primary repair. Because of the high likelihood of suture pullout or repair attenuation, primary repair should never be attempted for a midsubstance FCL or PLT tear. Levy et al³⁵ and Stannard et al³⁶ compared outcomes after posterolateral corner repair versus reconstruction and observed significantly higher failure rates in patients who received a repair versus a reconstruction. In light of these results, it is imperative to be highly selective when considering patients for an isolated primary lateral knee repair.

Bony avulsions of the PLT in the absence of tendon midsubstance tearing or attenuation can be repaired with a popliteus recess procedure.³⁴ In this procedure, a guide pin is used to ream a 5-mm diameter by 10-mm deep closed socket tunnel. The avulsed end of the PLT is whipstitched and pulled into the tunnel using passing sutures and secured over a cortical button on the medial femur. This repair was noted to be successful only if the PLT could be

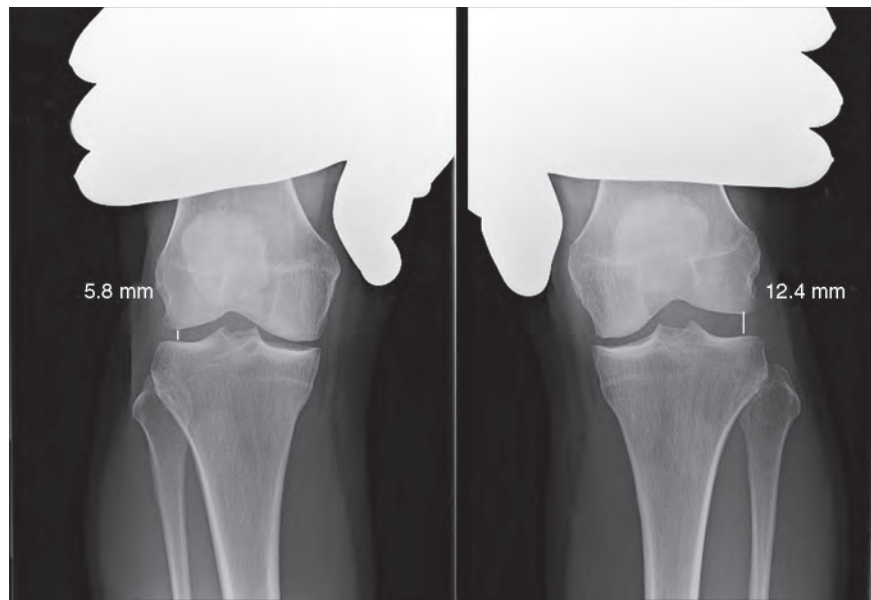


Figure 8 Varus stress radiographs demonstrating a 6.6 mm side-to-side difference in lateral compartment gapping, which is indicative of a complete grade III posterolateral corner injury.

reduced into the tunnel in full extension. Avulsion fractures of the fibular attachment of the biceps femoris can be secured with suture anchors. If the FCL or the PLT is intact, then primary repair of the PFL can be attempted by using suture anchors and suture fixation. A modified approach is used if FCL reconstruction also is required, whereby the distal tail of the FCL graft is folded over the popliteus musculotendinous junction and sutured back onto itself to reproduce the native PFL trajectory. Tears in the popliteomeniscal fascicles or the coronary ligament can be repaired with horizontal mattress sutures. The results of recent anatomic studies have led some authors to advocate repair of the middle-third lateral capsular ligament (the anterolateral ligament) in cases of an avulsion (Segond) fracture.^{32,33}

Reconstruction

Indications for lateral knee reconstruction include all acute grade III

midsubstance FCL and PLT tears and acute and chronic grade III posterolateral corner injuries (FCL, PLT, and PFL). As with medial knee preoperative planning, long-leg radiographs should be obtained in all chronic lateral knee injury patients to assess for the presence of a varus weight-bearing axis. If a varus axis deformity is found in chronic cases of lateral instability, surgical reconstruction should proceed in a staged fashion, beginning with a medial opening wedge high tibial osteotomy followed by ligament reconstruction after 6 months if lateral instability fails to resolve. In one study, 38% of the patients with chronic posterolateral corner knee injuries who underwent a medial opening wedge high tibial osteotomy experienced resolution of instability and did not need subsequent reconstruction.³⁷ In addition, varus stress radiographs should be obtained for surgical planning purposes to assess for the presence of isolated or combined ligament injuries²⁸ (**Figure 8**). Thresholds in the side-to-side

Table 1
Threshold Gapping Values on Varus and
Valgus Stress Radiographs^a

Stress Technique	Gapping Threshold	Associated Injury
Valgus stress radiography ^b	< 3.2 mm	No injury or grade I or II sprain
	3.2 mm to 9.8 mm	Isolated grade III sMCL tear
	> 9.8 mm	Grade III (complete) medial knee injury
Varus stress radiography ^c	< 2.7 mm	No injury or grade I or II sprain
	2.7 mm to 4 mm	Isolated grade III FCL tear
	> 4 mm	Grade III (complete) posterolateral knee injury

FCL = fibular collateral ligament, sMCL = superficial medial collateral ligament.

^a All threshold values represent the side-to-side difference in gapping compared with the contralateral knee.

^b Valgus stress radiographs are captured with the knee in 20° of flexion while a clinician applies a valgus-directed load to the lateral aspect of the knee.

^c Varus stress radiographs are captured with the knee in 20° of flexion while a clinician applies a varus-directed load to the medial aspect of the knee.

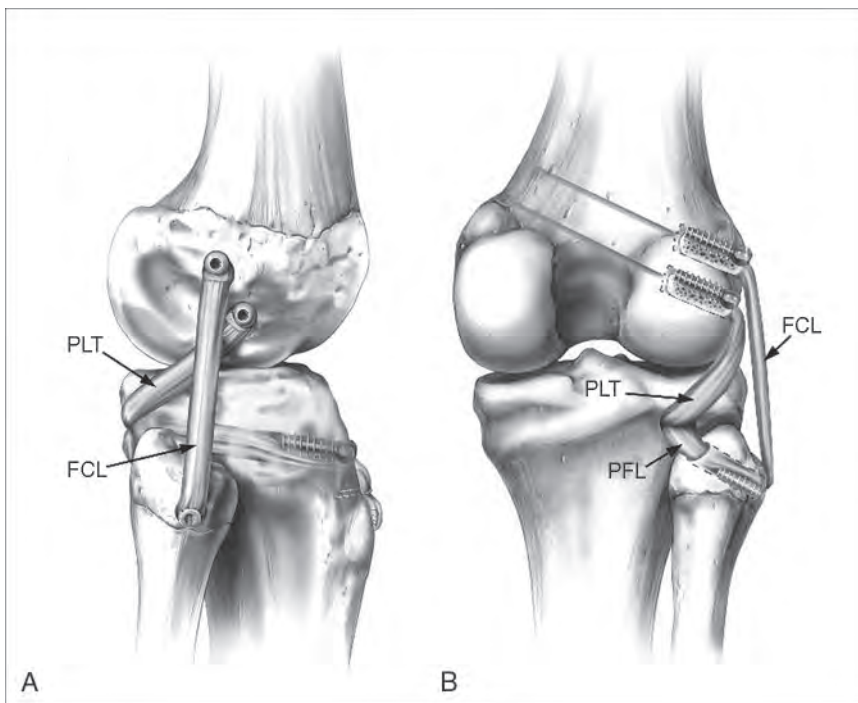


Figure 9 Illustrations demonstrating lateral (A) and posterior (B) views of an anatomic posterolateral corner reconstruction in a right knee. The anatomic posterolateral corner reconstruction is performed using a split Achilles tendon allograft to reproduce the fibular collateral ligament (FCL), the popliteofibular ligament (PFL), and the popliteus tendon (PLT). (Reproduced with permission from LaPrade RF, Johansen S, Wentorf FA, Engebretsen L, Esterberg JL, Tso A: An analysis of an anatomical posterolateral knee reconstruction: An in vitro biomechanical study and development of a surgical technique. *Am J Sports Med* 2004;32[6]:1405-1414.)

difference in lateral compartment gapping are presented in **Table 1**.

Total Posterolateral Corner Reconstruction

Numerous posterolateral corner reconstruction techniques have been described and can be broadly categorized into isometric versus anatomic techniques. Anatomic techniques use two femoral tunnels centered on the FCL and PLT attachments.³⁸⁻⁴² Isometric techniques include biceps femoris tenodesis, arcuate complex advancement, and the single femoral tunnel reconstruction.⁴³⁻⁴⁵ The anatomic reconstruction technique developed by LaPrade et al^{39,46} is illustrated in **Figure 9**.

FCL Reconstruction

In addition to total posterolateral corner reconstruction techniques, isolated reconstruction procedures have been developed for FCL reconstruction. As with posterolateral corner reconstruction, both isometric and anatomic techniques have been described. Isometric techniques include augmentation with the biceps femoris tendon, advancement of the femoral FCL attachment, biceps femoris tendon tenodesis, a doubled-over semitendinosus graft, bone-patellar-bone reconstruction, and a quadriceps tendon-patellar bone autograft reconstruction.⁴⁷⁻⁵³ Anatomic techniques include the open anatomic semitendinosus autograft or allograft (**Figure 10**) and the mini-open, arthroscopically assisted semitendinosus autograft reconstruction.⁵⁴⁻⁵⁶

PLT Reconstruction

Isolated PLT reconstructions have been developed to restore rotary stability to a PLT deficient knee. Surgical

reconstruction techniques include sling reconstruction,⁵⁷ Achilles tendon allograft, iliotibial band augmentation, biceps tendon augmentation, patellar tendon allograft or autograft reconstruction, semitendinosus or tibialis anterior graft reconstruction, and recess procedures.^{30,39,47,58-60} In cases of isolated PLT injury, an anatomic reconstruction technique using a semitendinosus or a tibialis anterior graft has been biomechanically validated to restore objective knee stability²⁹ (Figure 11). This technique also provides the advantage of safe graft harvesting.¹³

Proximal Tibiofibular Joint Reconstruction

The proximal tibiofibular joint may sometimes become subluxated or dislocated and destabilized and thus requires surgical reconstruction. When injured, the fibula is typically anterolaterally subluxated.⁶¹ To restore normal positioning and stability, a lateral hockey stick incision is made, and a peroneal neurolysis is performed.³² The fibular head is manually reduced to its appropriate position. Ligament reconstruction can be performed in chronic cases; alternatively, the joint can be reduced, the capsule can be repaired, and the joint can be held in place with a large-fragment cancellous screw that can be removed at 3 months for acute cases. For reconstruction, a 6-mm tunnel is created in the anterior to posterior direction in the fibula. A 6-mm tibial reconstruction tunnel is then reamed over a guide pin extending from the musculotendinous junction of the popliteus to the flat spot distal and medial to the Gerdy tubercle. With the knee flexed at 70°, a semitendinosus graft is secured in both tunnels using 7-mm bioabsorbable screws while maintaining

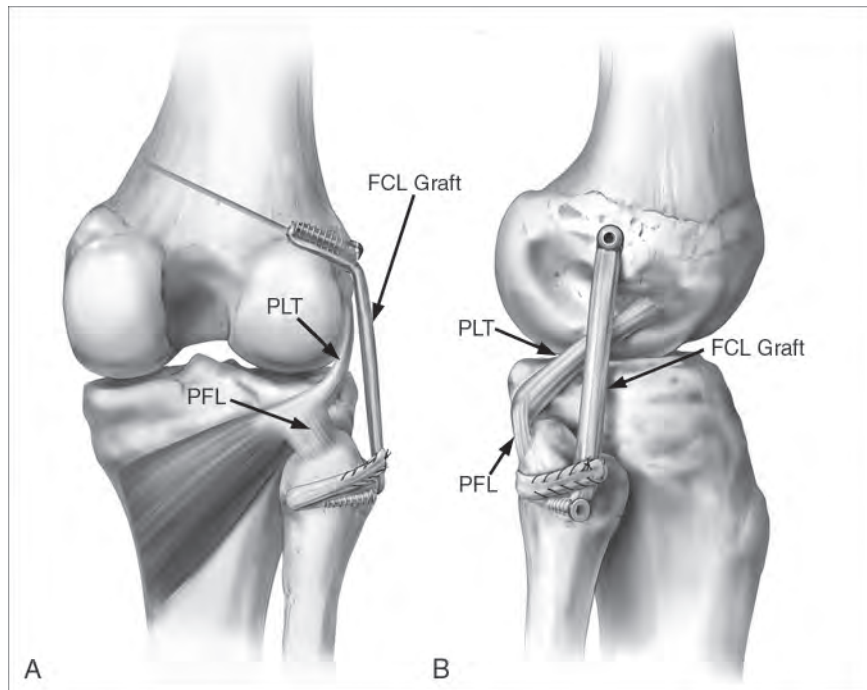


Figure 10 Illustrations demonstrating posterior (A) and lateral (B) views of an anatomic fibular collateral ligament (FCL) reconstruction in a right knee. PFL = popliteofibular ligament, PLT = popliteus tendon. (Reproduced with permission from Coobs BR, LaPrade RF, Griffith CJ, Nelson BJ: Biomechanical analysis of an isolated fibular (lateral) collateral ligament reconstruction using an autogenous semitendinosus graft. *Am J Sports Med* 2007;35[9]:1521-1527.)

adequate tension on the graft and position of the tibiofibular joint.

Rehabilitation

Postoperative restrictions include no weight bearing for the first 6 weeks and restriction from any activity that produces varus or external rotation forces on the knee.⁶² During the first 2 weeks, quadriceps sets and straight leg raises should be performed four times per day in a knee immobilizer. ROM is initiated on postoperative day 1 from 0° to 90° to minimize the risk of arthrofibrosis. After 2 weeks, straight leg raises and quadriceps sets can be completed without the immobilizer brace if no extensor lag is present. ROM is gradually increased after 2 weeks, with the goal of achieving full ROM at 6 weeks.

Controlled weight bearing is initiated on the surgical leg at 6 weeks and increased as tolerated while the patient is progressively weaned off crutches. After ROM reaches 110°, stationary biking is added. At 12 weeks, emphasis is transitioned to building muscular strength through low-impact exercises. The goal is return to full strength by 6 months. At this time, varus stress radiographs are obtained to assess for graft attenuation or failure. Full return to activity is dependent on passing a functional test and obtaining physician clearance after subjective and objective assessment of lateral knee stability.²²

Summary

Most medial-sided knee injuries should initially be treated nonsurgically because

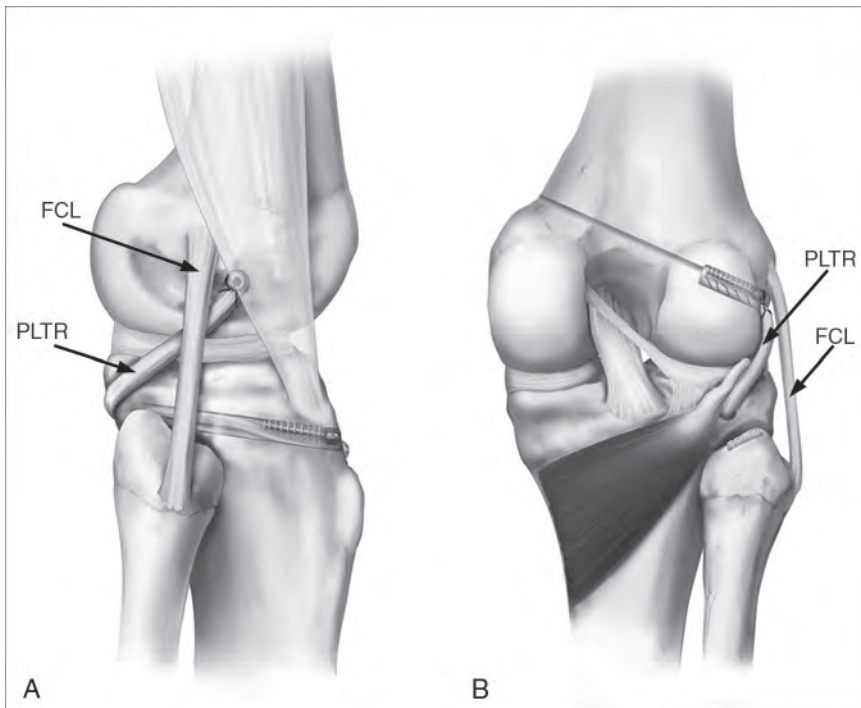


Figure 11 Illustration demonstrating lateral (A) and posterior (B) views of an anatomic popliteus tendon reconstruction (PLTR) in a right knee. FCL = fibular collateral ligament. (Reproduced with permission from LaPrade RF, Wozniczka JK, Stellmaker MP, Wijdicks CA: Analysis of the static function of the popliteus tendon and evaluation of an anatomic reconstruction: The “fifth ligament” of the knee. *Am J Sports Med* 2010;38[3]:543-549.)

many injuries are amenable to healing. In acute multiligamentous injuries or knee dislocations, primary repair may be attempted by suturing torn structures or reattaching torn structures with suture anchors. This may be augmented using hamstring graft to make a more robust repair. In the setting of chronic medial-sided knee injuries, long-leg radiographs should be obtained to assess alignment. Patients with a chronic medial-sided knee injury and a valgus weight-bearing axis should be managed with a staged approach, beginning with a distal femoral osteotomy before augmentation or reconstruction of medial knee structures. Rehabilitation should focus on early ROM in a predetermined safe zone to minimize the risk for the development of arthrofibrosis. Return

to full activity generally occurs after 6 to 9 months.

The ability to evaluate and treat lateral-sided knee injuries is predicated on a comprehensive understanding of lateral knee anatomy and biomechanics. When evaluating a patient with a suspected lateral knee injury, objective diagnosis using varus stress radiography should be emphasized in addition to a comprehensive history and physical examination. Stress radiography offers a reliable means to assess lateral compartment gapping and stability after surgical repair or reconstruction. Contrary to the medial aspect of the knee, lateral-sided knee injuries typically do not heal, which often makes repair or reconstruction necessary. Primary repair should be attempted only in acute

injuries and never for midsubstance tears. Numerous reconstruction techniques using isometric versus anatomic principles have been developed for isolated and combined posterolateral corner knee injuries. This chapter’s authors recommend techniques that use anatomic reconstruction principles and have been biomechanically validated to restore native knee functional properties. Rehabilitation should emphasize early ROM exercises, with a goal of full return to activity when the patient has passed a functional test and has been cleared by his or her physician.

References

1. Wijdicks CA, Michalski MP, Rasmussen MT, et al: Superficial medial collateral ligament anatomic augmented repair versus anatomic reconstruction: An in vitro biomechanical analysis. *Am J Sports Med* 2013;41(12):2858-2866.
2. LaPrade RF, Engebretsen AH, Ly TV, Johansen S, Wentorf FA, Engebretsen L: The anatomy of the medial part of the knee. *J Bone Joint Surg Am* 2007;89(9):2000-2010.
3. Wijdicks CA, Ewart DT, Nuckley DJ, Johansen S, Engebretsen L, LaPrade RF: Structural properties of the primary medial knee ligaments. *Am J Sports Med* 2010;38(8):1638-1646.
4. Griffith CJ, LaPrade RF, Johansen S, Armitage B, Wijdicks C, Engebretsen L: Medial knee injury: Part 1. Static function of the individual components of the main medial knee structures. *Am J Sports Med* 2009;37(9):1762-1770.
5. Wijdicks CA, Griffith CJ, LaPrade RF, et al: Medial knee injury: Part 2. Load sharing between the posterior oblique ligament and superficial medial collateral ligament. *Am J Sports Med* 2009;37(9):1771-1776.
6. Hughston JC: The importance of the posterior oblique ligament in repairs of acute tears of the medial ligaments in knees with and without an associated rupture of the anterior cruciate ligament: Results of

- long-term follow-up. *J Bone Joint Surg Am* 1994;76(9):1328-1344.
7. Hughston JC, Eilers AF: The role of the posterior oblique ligament in repairs of acute medial (collateral) ligament tears of the knee. *J Bone Joint Surg Am* 1973;55(5):923-940.
 8. Fischer RA, Arms SW, Johnson RJ, Pope MH: The functional relationship of the posterior oblique ligament to the medial collateral ligament of the human knee. *Am J Sports Med* 1985;13(6):390-397.
 9. Loredó R, Hodler J, Pedowitz R, Yeh LR, Trudell D, Resnick D: Posteromedial corner of the knee: MR imaging with gross anatomic correlation. *Skeletal Radiol* 1999;28(6):305-311.
 10. Dunaway DJ, Steensen RN, Wiand W, Dopirak RM: The sartorial branch of the saphenous nerve: Its anatomy at the joint line of the knee. *Arthroscopy* 2005;21(5):547-551.
 11. Kerver AL, Leliveld MS, den Hartog D, Verhofstad MH, Kleinrensink GJ: The surgical anatomy of the infrapatellar branch of the saphenous nerve in relation to incisions for anteromedial knee surgery. *J Bone Joint Surg Am* 2013;95(23):2119-2125.
 12. Wijdicks CA, Westerhaus BD, Brand EJ, Johansen S, Engebretsen L, LaPrade RF: Sartorial branch of the saphenous nerve in relation to a medial knee ligament repair or reconstruction. *Knee Surg Sports Traumatol Arthrosc* 2010;18(8):1105-1109.
 13. Worth RM, Kettelkamp DB, Defalque RJ, Duane KU: Saphenous nerve entrapment: A cause of medial knee pain. *Am J Sports Med* 1984;12(1):80-81.
 14. Bertram C, Porsch M, Hackenbroch MH, Terhaag D: Saphenous neuralgia after arthroscopically assisted anterior cruciate ligament reconstruction with a semitendinosus and gracilis tendon graft. *Arthroscopy* 2000;16(7):763-766.
 15. LaPrade RF, Wijdicks CA: The management of injuries to the medial side of the knee. *J Orthop Sports Phys Ther* 2012;42(3):221-233.
 16. Marx RG, Hetsroni I: Surgical technique: Medial collateral ligament reconstruction using Achilles allograft for combined knee ligament injury. *Clin Orthop Relat Res* 2012;470(3):798-805.
 17. Coobs BR, Wijdicks CA, Armitage BM, et al: An in vitro analysis of an anatomical medial knee reconstruction. *Am J Sports Med* 2010;38(2):339-347.
 18. Hartshorn T, Otardifard K, White EA, Hatch GF III: Radiographic landmarks for locating the femoral origin of the superficial medial collateral ligament. *Am J Sports Med* 2013;41(11):2527-2532.
 19. Redfern J, Kamath G, Burks R: Anatomical confirmation of the use of radiographic landmarks in medial patellofemoral ligament reconstruction. *Am J Sports Med* 2010;38(2):293-297.
 20. Schöttle PB, Schmelting A, Rosenstiel N, Weiler A: Radiographic landmarks for femoral tunnel placement in medial patellofemoral ligament reconstruction. *Am J Sports Med* 2007;35(5):801-804.
 21. Wijdicks CA, Griffith CJ, LaPrade RF, et al: Radiographic identification of the primary medial knee structures. *J Bone Joint Surg Am* 2009;91(3):521-529.
 22. Garrison JC, Shanley E, Thigpen C, Geary R, Osler M, Delgiorno J: The reliability of the Vail Sport Test™ as a measure of physical performance following anterior cruciate ligament reconstruction. *Int J Sports Phys Ther* 2012;7(1):20-30.
 23. LaPrade RF, Bernhardtson AS, Griffith CJ, Macalena JA, Wijdicks CA: Correlation of valgus stress radiographs with medial knee ligament injuries: An in vitro biomechanical study. *Am J Sports Med* 2010;38(2):330-338.
 24. LaPrade RF, Ly TV, Wentorf FA, Engebretsen L: The posterolateral attachments of the knee: A qualitative and quantitative morphologic analysis of the fibular collateral ligament, popliteus tendon, popliteofibular ligament, and lateral gastrocnemius tendon. *Am J Sports Med* 2003;31(6):854-860.
 25. Gollehon DL, Torzilli PA, Warren RF: The role of the posterolateral and cruciate ligaments in the stability of the human knee: A biomechanical study. *J Bone Joint Surg Am* 1987;69(2):233-242.
 26. Grood ES, Stowers SF, Noyes FR: Limits of movement in the human knee: Effect of sectioning the posterior cruciate ligament and posterolateral structures. *J Bone Joint Surg Am* 1988;70(1):88-97.
 27. LaPrade RF, Tso A, Wentorf FA: Force measurements on the fibular collateral ligament, popliteofibular ligament, and popliteus tendon to applied loads. *Am J Sports Med* 2004;32(7):1695-1701.
 28. LaPrade RF, Heikes C, Bakker AJ, Jakobsen RB: The reproducibility and repeatability of varus stress radiographs in the assessment of isolated fibular collateral ligament and grade-III posterolateral knee injuries: An in vitro biomechanical study. *J Bone Joint Surg Am* 2008;90(10):2069-2076.
 29. LaPrade RF, Wozniczka JK, Stellmaker MP, Wijdicks CA: Analysis of the static function of the popliteus tendon and evaluation of an anatomic reconstruction: The “fifth ligament” of the knee. *Am J Sports Med* 2010;38(3):543-549.
 30. Maynard MJ, Deng X, Wickiewicz TL, Warren RF: The popliteofibular ligament: Rediscovery of a key element in posterolateral stability. *Am J Sports Med* 1996;24(3):311-316.
 31. McCarthy M, Camarda L, Wijdicks CA, Johansen S, Engebretsen L, LaPrade RF: Anatomic posterolateral knee reconstructions require a popliteofibular ligament reconstruction through a tibial tunnel. *Am J Sports Med* 2010;38(8):1674-1681.
 32. Terry GC, LaPrade RF: The posterolateral aspect of the knee: Anatomy and surgical approach. *Am J Sports Med* 1996;24(6):732-739.
 33. Claes S, Vereecke E, Maes M, Victor J, Verdonk P, Bellemans J: Anatomy of the anterolateral ligament of the knee. *J Anat* 2013;223(4):321-328.
 34. Geeslin AG, LaPrade RF: Outcomes of treatment of acute grade-III isolated and combined posterolateral knee injuries: A prospective case series and surgical technique. *J Bone Joint Surg Am* 2011;93(18):1672-1683.
 35. Levy BA, Dajani KA, Morgan JA, Shah JP, Dahm DL, Stuart MJ: Repair versus reconstruction

- of the fibular collateral ligament and posterolateral corner in the multiligament-injured knee. *Am J Sports Med* 2010;38(4):804-809.
36. Stannard JP, Brown SL, Farris RC, McGwin G Jr, Volgas DA: The posterolateral corner of the knee: Repair versus reconstruction. *Am J Sports Med* 2005;33(6):881-888.
 37. LaPrade RF, Engebretsen L, Johansen S, Wentorf FA, Kurtenbach C: The effect of a proximal tibial medial opening wedge osteotomy on posterolateral knee instability: A biomechanical study. *Am J Sports Med* 2008;36(5):956-960.
 38. Bicos J, Arciero RA: Novel approach for reconstruction of the posterolateral corner using a free tendon graft technique. *Sports Med Arthrosc* 2006;14(1):28-36.
 39. LaPrade RF, Johansen S, Wentorf FA, Engebretsen L, Esterberg JL, Tso A: An analysis of an anatomical posterolateral knee reconstruction: An in vitro biomechanical study and development of a surgical technique. *Am J Sports Med* 2004;32(6):1405-1414.
 40. Noyes FR, Barber-Westin SD: Surgical reconstruction of severe chronic posterolateral complex injuries of the knee using allograft tissues. *Am J Sports Med* 1995;23(1):2-12.
 41. Schechinger SJ, Levy BA, Dajani KA, Shah JP, Herrera DA, Marx RG: Achilles tendon allograft reconstruction of the fibular collateral ligament and posterolateral corner. *Arthroscopy* 2009;25(3):232-242.
 42. Sekiya JK, Kurtz CA: Posterolateral corner reconstruction of the knee: Surgical technique utilizing a bifid Achilles tendon allograft and a double femoral tunnel. *Arthroscopy* 2005;21(11):1400.
 43. Wascher DC, Grauer JD, Markoff KL: Biceps tendon tenodesis for posterolateral instability of the knee: An in vitro study. *Am J Sports Med* 1993;21(3):400-406.
 44. Hughston JC, Jacobson KE: Chronic posterolateral rotatory instability of the knee. *J Bone Joint Surg Am* 1985;67(3):351-359.
 45. Larson RV, Sidles JA, Beals CT: Isometry of lateral collateral and popliteofibular ligaments and a technique for reconstruction, in *University of Washington Research Report*. Seattle, WA, University of Washington, 1996, pp 42-44.
 46. LaPrade RF, Johansen S, Engebretsen L: Outcomes of an anatomic posterolateral knee reconstruction: Surgical technique. *J Bone Joint Surg Am* 2011;93(suppl 1):S10-S20.
 47. Veltri DM, Warren RF: Operative treatment of posterolateral instability of the knee. *Clin Sports Med* 1994;13(3):615-627.
 48. Noyes FR, Barber-Westin SD: Surgical restoration to treat chronic deficiency of the posterolateral complex and cruciate ligaments of the knee joint. *Am J Sports Med* 1996;24(4):415-426.
 49. Fanelli GC, Feldmann D: Management of combined anterior cruciate ligament/posterior cruciate ligament/posterolateral complex injuries of the knee. *Oper Tech Sports Med* 1999;7:143-149.
 50. Buzzi R, Aglietti P, Vena LM, Giron F: Lateral collateral ligament reconstruction using a semitendinosus graft. *Knee Surg Sports Traumatol Arthrosc* 2004;12(1):36-42.
 51. Latimer HA, Tibone JE, ElAttrache NS, McMahon PJ: Reconstruction of the lateral collateral ligament of the knee with patellar tendon allograft: Report of a new technique in combined ligament injuries. *Am J Sports Med* 1998;26(5):656-662.
 52. Noyes FR, Barber-Westin SD: Posterolateral knee reconstruction with an anatomical bone-patellar tendon-bone reconstruction of the fibular collateral ligament. *Am J Sports Med* 2007;35(2):259-273.
 53. Chen CH, Chen WJ, Shih CH: Lateral collateral ligament reconstruction using quadriceps tendon-patellar bone autograft with bioscrew fixation. *Arthroscopy* 2001;17(5):551-554.
 54. Coobs BR, LaPrade RF, Griffith CJ, Nelson BJ: Biomechanical analysis of an isolated fibular (lateral) collateral ligament reconstruction using an autogenous semitendinosus graft. *Am J Sports Med* 2007;35(9):1521-1527.
 55. LaPrade RF, Spiridonov SI, Coobs BR, Ruckert PR, Griffith CJ: Fibular collateral ligament anatomical reconstructions: A prospective outcomes study. *Am J Sports Med* 2010;38(10):2005-2011.
 56. Liu P, Wang J, Zhao F, Xu Y, Ao Y: Anatomic, arthroscopically assisted, mini-open fibular collateral ligament reconstruction: An in vitro biomechanical study. *Am J Sports Med* 2014;42(2):373-381.
 57. Feng H, Hong L, Geng XS, Zhang H, Wang XS, Zhang J: Posterolateral sling reconstruction of the popliteus tendon: An all-arthroscopic technique. *Arthroscopy* 2009;25(7):800-805.
 58. Clancy W, Chapman M: Repair and reconstruction of the posterior cruciate ligament. *Operative Orthopaedics* 1988;3:1651-1665.
 59. Clancy WG Jr, Sutherland TB: Combined posterior cruciate ligament injuries. *Clin Sports Med* 1994;13(3):629-647.
 60. Müller W: *The Knee: Form, Function, and Ligament Reconstruction*. Berlin, Germany, Springer-Verlag, 1983, pp 246-248.
 61. Horst PK, LaPrade RF: Anatomic reconstruction of chronic symptomatic anterolateral proximal tibiofibular joint instability. *Knee Surg Sports Traumatol Arthrosc* 2010;18(11):1452-1455.
 62. Lunden JB, Bzdusek PJ, Monson JK, Malcomson KW, LaPrade RF: Current concepts in the recognition and treatment of posterolateral corner injuries of the knee. *J Orthop Sports Phys Ther* 2010;40(8):502-516.

Video Reference

LaPrade RD, Moulton SG: Video. *Posterolateral Corner Reconstruction*. Vail, CO, 2014.