

Efficacy of autologous platelet rich fibrin in bone augmentation and bone regeneration at extraction socket

Bernard Blinsein¹, Stasys Bojarskas²

SUMMARY

Objective. The purpose of the present study is to provide the efficacy of autologous platelet rich fibrin in bone augmentation and bone regeneration procedures in regard of soft and hard tissue healing in oral surgery treatment.

Material and methods. An electronic search on PubMed database was performed regarding the placement of autologous platelet rich fibrin at tooth extraction sockets, bone and soft tissue augmentation procedures associated with implant placement and infrabony defects. The search was constrained to English language articles published during last five years and includes only clinical trials.

Results. In total, 25 articles were included in this literature review. The studies were divided into five main groups, depending on the application: 1) utilization of autologous platelet rich fibrin at 3rd molar extraction sockets preservation, 2) any extraction socket preservation, 3) bone augmentation/sinus lift procedures with implant placement, 4) augmentation of peri-implant tissues, and 5) treatment of infrabony defects.

Conclusions. The application of autologous platelet rich fibrin (PRF) show benefits in promoting soft tissue healing and bone regeneration in different surgical procedures. Furthermore, it is an autologous biomaterial which has low cost and does not need administration of any additives. Nevertheless, further studies with a bigger sample size and longer follow up duration are necessary to facilitate more substantial evidence of the efficacy of PRF in promotion of soft and hard tissue healing.

Key words: platelet rich fibrin, bone regeneration, soft tissue healing, bone augmentation.

INTRODUCTION

Nowadays, the effectiveness in medicine and dental surgical procedures include application of bioactive materials to promote soft and hard tissue healing. Platelet rich fibrin was first introduced in 2001 by Dr. Joseph Choukroun *et al.* (1, 2) in France. Choukroun used autologous whole blood to establish a platelet rich fibrin clot with the help of a centrifuge (2). Various surgical applications resulting in inadequate discomfort of the patient, for example pain and swelling after 3rd molar extractions, but with the application of PRF the healing process might be accelerated. Autologous platelet rich

fibrin is a second generation immune and platelet concentrate frequently used in hard and soft tissue healing, which had been used for bone augmentation, angiogenesis, wound healing and periodontal healing (2). PRF is a bioactive material and does not require any addition and avert of any kind of material in contrast to platelet rich plasma (PRP), which needs biochemical modification (1, 3, 6).

The autologous biomaterial has a tetramolecular structure and is composed of a fibrin matrix trapping platelets, leukocytes, cytokines and circulating stem cells (4). Growth factors including platelet derived growth factor (PDGF- $\beta\beta$), transforming growth factor (TGF- β 1), vascular endothelial growth factor (VEGF), insulin-like growth factor, leukocytic cells and their cytokines (interleukin 1 β , IL-6, IL-4) and tumor necrosis factor α are enmeshed within the fibrin matrix (2).

PRP, which was first described by Marx *et al.* in 1998 requires for its preparation the above mentioned biochemical modification, bovine thrombin

¹Faculty of Odontology, Medical Academy, Lithuanian University of Health Sciences, Kaunas, Lithuania

²Department of Oral and Maxillofacial surgery Faculty of Odontology, Medical Academy, Lithuanian University of Health Sciences, Kaunas, Lithuania

Address correspondence to Stasys Bojarskas, Department of Oral and Maxillofacial Surgery, Medical Academy, Lithuanian University of Health Sciences, Eivenių str. 2, 50009, Kaunas, Lithuania.
E-mail address: litmaxfac@yahoo.com

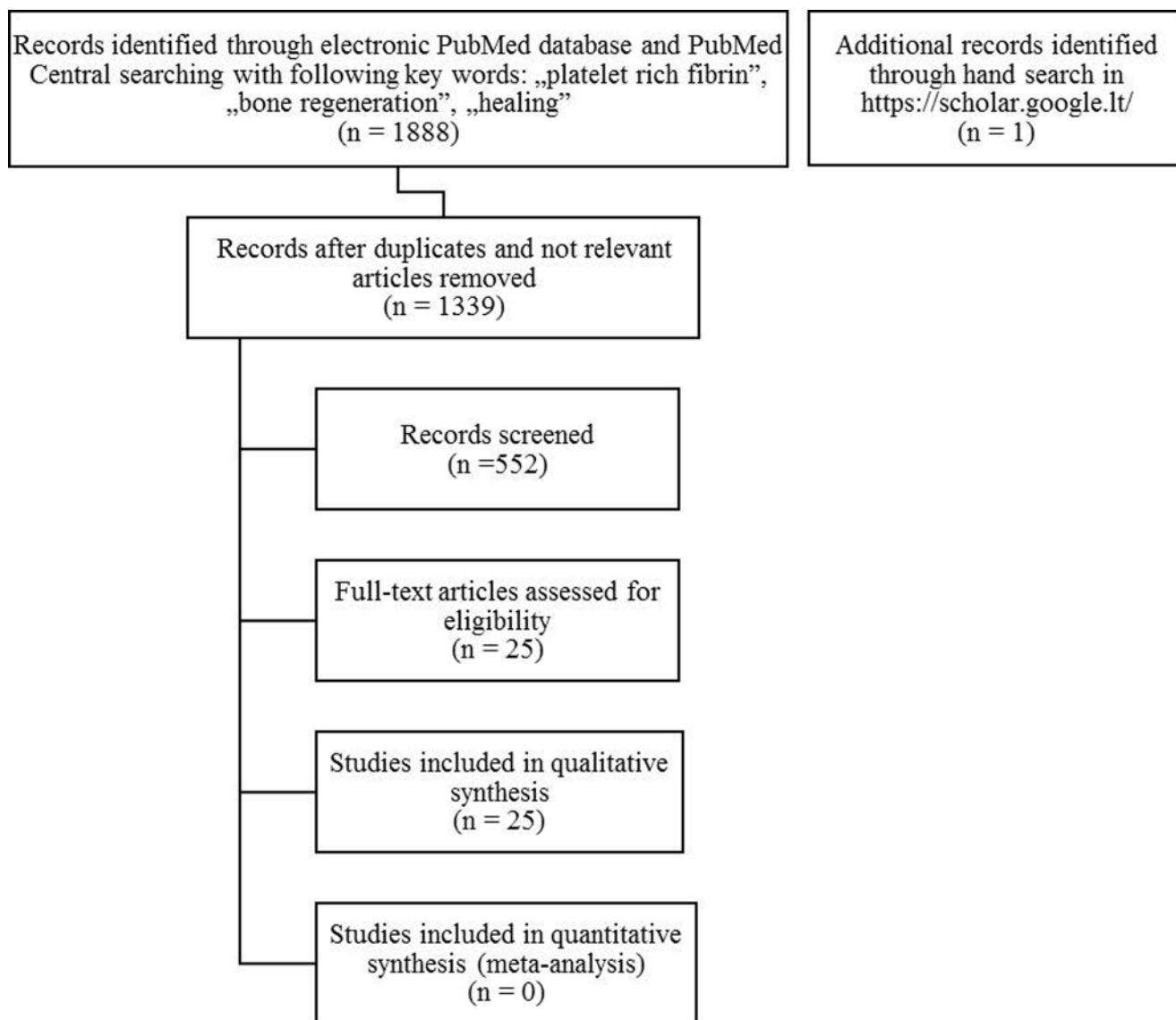


Fig. Diagram of the literature search strategy

or anticoagulant which can originate antibodies to factors 5, 9 and thrombin, resulting in risk of life threatening coagulopathies (1, 3, 6). PRF can be used in multiple procedures as Charrier J. P. *et al.* state "Beneficial effects of PRF have been studied in various procedures, such as facial plastic surgery, sinus-lift procedure as a sole osteoconductive filling material, and multiple gingival recessions cases treated with coronally advanced flap." (as cited in Ajwani H, 2014, p. 33) (7). Furthermore PRF can be administered in socket preservation after extraction of teeth, infrabony defects, implant placement for adequate osseous regeneration and soft tissue healing. Several studies exhibit superior wound healing of oral mucosa and alveolar bone after extraction of third molars, bone augmentation, various procedures of implant placement and treatment of infrabony defects. The autologous fibrin-matrix conduces as a resorbable membrane and was primarily used in im-

plantology, but at the present day, PRF is utilized in many disciplines of dentistry (8). PRF offers distinct advantages, containing promoting wound healing, bone growth and maturation, graft stabilization, wound sealing and hemostasis (9).

MATERIALS AND METHODS

Search strategy

An electronic search was performed in the database of MEDLINE/PubMed and PubMed Central using the following search terms – ("platelet rich fibrin" or "platelet rich fibrin" and "bone regeneration" or "platelet rich fibrin" and "healing" or "platelet rich fibrin" and "augmentation"). The inclusion criteria were constrained to English language articles published during last five years and included only clinical trials. An additional hand search on <https://scholar.google.lt/> was performed

and an article from The Saudi Journal of Dental Research was retrieved and selected for full-text screening. The search provided 1888 articles. After filtering according to the inclusion criteria, the quest delivered 552 articles, of which the abstracts were screened for meeting the inclusion criteria. In total, 25 articles were selected for full-text review according to the inclusion criteria. All 25 clinical trials were included in the literature review which accomplished the inclusion criteria (Figure). The first retrieval was conducted in PubMed electronic data base in 2016. The last electronic search was performed in January the 5th, 2017.

Selection criteria

Clinical studies assessing the effect of platelet rich fibrin in treatment of extraction socket preservation, bone augmentation procedures with implant placement and infrabony defects were included in the review. There were no constraints regarding the number of patients treated and the protocol of PRF preparation. Articles were selected according to the following inclusion criteria:

- English language articles
- Published during last five years
- Human studies
- Clinical trials, parallel and split- mouth study design
- Comparative studies between PRF used alone or together with
- xenograft and other biomaterials
- Availability of at least one experimental and/ or control group
- Clinical studies evaluating the application of PRF in third molar extraction socket, socket preservation after teeth extractions, sinus augmentation procedures, peri-implant tissue augmentation, infrabony defects
- Preoperative/ postoperative measurements and follow- up

Articles were selected according to the consequent exclusion criteria:

- Articles older than five years
- Case series
- Literature reviews
- Animal studies
- Clinical trials of intrabony defects with furcation involvement
- Clinical trials of PRF application in gingival recession

Risk of bias in individual studies

The risk of bias was performed at the outcome level with the Cochrane Collaboration's tool, but no

study was excluded for its risks of bias. Five quality criteria were assessed: 1. Random sequence generation, 2. Allocation concealment, 3. Blinding of participants and personnel, 4. Incomplete outcome data, and 5. Selective reporting. Each of the study was classified in three different categories: Low risk, moderate and high risk. Low risk was assessed, if all criteria were positive or one variable unclear or absent, moderate if two variables were unclear and/ or absent and high risk if more than two variables were absent.

RESULTS

Platelet rich fibrin application in third molar extraction socket: soft tissue and/or bone healing

Three studies were included in this literature review assessing the efficacy of platelet rich fibrin in 3rd molar extraction sockets preventing local osteitis (10, 11, 25). In one clinical trial patients underwent bilateral extraction of mandibular third molars with one socket receiving platelet rich fibrin and the other socket leaving empty as control side (10). In the other study 200 patients underwent bilateral third molar extractions. 100 patients received PRF into their extraction sockets, the other 100 patients did not and served as a control group (11). In all clinical trials the occurrence of localized osteitis was statistically significantly less in test groups than in control groups. In the study from Hoaglin *et al.* (11) the PRF group had an incidence of localized osteitis (LO) in two extraction sites out of 200 in contrast to the control group where 19 extraction sites out of 200 developed LO. The patients who obtained PRF into their extraction socket had statistically significantly less occurrence of localized osteitis with a very low P value =0.0001 (11). Furthermore, they calculated the postoperative appointments and minutes to treat LO for the patients who acquired LO. The patient who did not receive PRF had average postoperative appointments of 3.8 times and 395 minutes to manage their LO. In contrast the PRF group had an average of 2.0 times postoperative appointments and average of 32 minutes treatment time. In the split-mouth study of Eshghpour *et al.* (10) the frequency of localized osteitis in PRF sites was significantly lower than non-PRF extraction sites. The risk development of LO in control sockets was 0.44 (P<0.05). In all other studies of that subsection, post-operative radiologic and clinical assessments showed better results in soft tissue healing, trabecular bone formation and bone density in PRF-groups than in control groups (1, 6, 12, 13). In the study from Singh *et al.* (12) there was a statistical differ-

ence between the PRF-group and the control group in soft tissue healing after the 3rd day $P=0.022$ and at the 7th day $P=0.015$. In one study from Yelamali *et al.* (20) PRF application was compared to platelet rich plasma (PRP). The mean values for soft tissue healing collected one week post-operatively, were significantly higher in the PRF group compared to the PRP group. Likewise, the mean values of bone density which were collected at the end of the fourth months post-operatively, were significantly higher for the PRF group as compared to the PRP group ($P=0.000$). The data for soft tissue healing were examined at the end of first week post-operative, utilizing healing index of Laundry *et al.* and the data for bone regeneration were evidenced by digital orthopantomogram after four months postoperative. The images were compared between left and right extraction side of the same patient on the program Adobe Photoshop CS.

Platelet rich fibrin application: post-operative pain and facial swelling after 3rd molar extraction

Two studies reported a statistically significant difference in pain reduction in PRF-groups compared to control groups (2, 13). The study from Kumar *et al.* (13) showed pain value by visual analog scale of $P=0.017$ and swelling $P=0.022$ which were lesser in the PRF-group than in the control group. In the study from Ozgul *et al.* (4) there was no statistically significant differences regarding pain among the groups, but regarding swelling, the control group exhibited more swelling on 3rd day post-operatively ($P<0.05$).

Efficacy of platelet rich fibrin in preservation of extraction sockets: soft tissue and/or bone healing

PRF used alone

The study from Anwandter *et al.* (14) used PRF alone with no comparative treatment option. Clinical data of the buccal and oral bone resorption were added up and the mean horizontal bone loss was 1.56 ± 0.07 mm. A total horizontal resorption of 1.53mm was reported at the alveolar crest, 1.64 mm, 1.5mm resorption at 2mm and 4mm apical to crest, respectively. Radiographic data reported during the fourth months after tooth extraction statistically significant reduction in socket depth ranged from 4.5 ± 3.0 mm ($P=0.0001$).

PRF versus non-PRF

The study from Temmerman *et al.* (21) reported a statistically significant difference in the reduction of total width of the alveolar ridge between the test and the control group. Likewise, the radiographic

evaluation reported a significant difference in the socket fill between test and the control group ($P<0.005$). Marenzi *et al.* (5) reported mean value post-extraction pain for the test group 3.2 ± 0.3 and for the control group 4.1 ± 0.6 ($P=0.0001$). Modified Healing Index after seven days showed; test group: 4.8 ± 0.6 and control: 5.1 ± 0.9 which had a statistical significant difference at day three and seven between both groups.

PRF versus β -TCP-CI

Das *et al.* (15) compared PRF to beta-tri-calcium phosphate (β -TCP-CI) with collagen in socket preservation (15). Intergroup comparison of clinical parameters between group I (PRF) and group II (β -TCP-CI) reported a decrease in mid-buccal crestal height in group I (PRF) and buccolingual/palatal width of both groups. Furthermore, there was an increase for all other parameters in group I (PRF) as well as in group II (β -TCP-CI). If compared to measurements at baseline. The reduction for all clinical parameters in group II (β -TCP-CI) was higher if compared to PRF group with a statistical significant difference ($P<0.05$). Histological analysis of the PRF-group bone sections stained with hematoxylin and eosin (H and E) showed well-formed mature bone and as well cancellous bone. Besides, they reported that bony trabeculae were well formed with proper medullary spaces which were filled with fatty tissue. As well, there were no signs of inflammation.

Efficacy of platelet rich fibrin in sinus augmentation procedures

All studies used PRF in combination with xenograft (mostly from Bio-Oss®) and compared it to xenograft used alone in sinus augmentation procedure. One study had an exception, which compared the PRF membrane with a collagen membrane (from Bio-Gide®) to cover lateral osteotomy site in maxillary sinus augmentation (22). There was no statistical significant difference between the test and the control groups in all studies. The study from Gassling *et al.* (22) reported that the bone quality and mean vital bone formation was almost equal in test and control group after five months. The study from Tatullo *et al.* (23) reported in the histological analysis that after 106 days the PRF group produced vascularized tissue which achieved primary stability of implants. The study from Zhang *et al.* (24) reported that the percentage of new bone formation in the PRF group was 1.4 times higher than that of the control group. However, the percentage of residual bone substitute in the control group was 1.5 times higher than that of the test group.

Efficacy of platelet rich fibrin in augmentation procedures of soft/hard tissues associated with implants

Two studies compared the influence of augmenting soft tissue with PRF application versus non-PRF on crestal bone and soft tissue around implants (17, 18). The study from Boora *et al.* (18) reported that in the third months all implants were osseointegrated and lesser changes in mean marginal bone were observed in the PRF group compared to the non-PRF group. There was no statistical significant difference regarding probing depth or bleeding on probing between both groups.

The retrospective, observational study from Marelli *et al.* (19) reported complete coverage of all dental implants with newly formed soft tissue which varied from one millimeter till three. Likewise, cortical bone adaptation after 30 months post-operative ranged from 0.4 mm till 1.7 mm. Hehn *et al.* (17) reported that a soft tissue augmentation with PRF leads to a significant tissue loss. In the test group, the crestal tissue thickness reduced from 2.20 ± 0.48 mm when compared to control group which showed higher stability with 2.64 ± 0.48 mm.

Efficacy of platelet rich fibrin in treatment of infrabony periodontal defects

Two randomized controlled trials evaluated the efficacy of PRF together with an open flap debridement versus an open flap debridement alone in treatment of infrabony defects (3, 7). In both split-mouth trials, there was a statistical significant difference in the radiographic defect fill between both groups, with better results for the PRF group. Ajwani *et al.* (7) reported statistical significant changes in mean defect fill (cemento-enamel junction to the base of the defect (BOD) and alveolar crest to BOD) with $P=0.003$. Furthermore, the study from Joseph *et al.* (3) reported statistical significant improvements in the PRF group compared to the control group in probing depth, clinical attachment level and radiographic infrabony depth of defect ($P<0.001$). There was no statistical significant difference between the PRF and the control groups in the randomized controlled trials, which one of them compared effectiveness of PRF and freeze-dried- bone allograft (9) and the other study PRF with autogenous bone graft (8) in treatment of infrabony defects. Besides, intragroup comparison showed in both groups statistical significant improvements in pocket depth reduction and clinical attachments level.

RISK OF BIAS ACROSS STUDIES

Randomization was reversed by all included studies except seven studies, which did not mention

or utilize random sequence generation (2, 11, 12, 14, 16, 19, 20). Most of the included studies did not report or utilize allocation concealment except five trials (3, 9, 10, 21, 17). Blinding of participants and personnel was ensured in six studies (3, 4, 7, 9, 10, 21) while in the rest of the studies it was either not mentioned or absent. Blinding of outcome assessment was reported in twelve studies (1, 3, 4, 6-8, 10, 13, 16, 22, 24) and in the rest of the studies it was not mentioned or absent. Incomplete data was present in only two studies (10, 14). Overall, seven studies revealed low risk of bias (3, 4, 7, 9, 10, 17, 21), seven studies had moderate risk of bias (1, 6, 8, 13, 22, 23, 27) and the rest had high risk of bias (2, 5, 11, 12, 14, 15, 18*20, 24).

DISCUSSION

Platelet rich fibrin can be utilized in 3rd molar extraction sockets to preserve alveolar ridge and promotes healing of soft tissue of the oral mucosa. Most studies which evaluated the efficacy of PRF in application of 3rd molar extraction sockets revealed a better healing outcome in PRF groups which were filled as a sole grafting material into the extraction socket. Girish Rao *et al.* state that the PRF group has a definite improvement in the regeneration of bone after third extraction socket as compared to the control group. Though, there was no statistically significant difference between both groups in the mean pixels during the study from Rao *et al.* (1). The study from Hoaglin *et al.* (11) and Eshghpour *et al.* (10) reported that the occurrence of LO was statistical significant less in PRF-groups than in control groups. The other studies of that subsection reported better results in soft tissue healing, trabecular bone formation and bone density in PRF-groups when compared to control groups (1, 6, 12, 13, 20). Two studies showed statistically significant higher values for the PRF- group of soft tissue healing after one week postoperative and bone density after three and four months, respectively (12). PRF has significantly superior results in promoting soft tissue healing and as well quicker bone regeneration after 3rd molar extraction, when it is compared with PRP. One main reason could be the simpler preparation protocol of PRF compared to PRP and capability of PRF to release certain growth factors in a "controlled way" (as cited in Yelamali T, 2014, p. 410) However, the overall period of the study from Yelamali *et al.* was only four months and osseous regeneration was only measured indirectly over computer aided software (Adobe Photoshop CS) (20). Three studies evaluated the efficacy of PRF in pain reduction of

mandibular 3rd molar extraction sockets (2, 4, 13). Two of these studies revealed a statistically significant reduction of pain after one day postoperative in PRF sites compared to control sites (2, 13). There was no statistically significant difference between in postoperative swelling among all techniques utilized (2). The other study from Ozgul *et al.* (4) reported no statistical significant difference among test and control groups regarding postoperative pain. Limitations in the study from Ozgul *et al.*; patients underwent bilaterally extractions at the same appointment, thus the results of pain might have been influenced by the control side. Likewise, a three-dimensional scanner would have given superior and more accurate results in the measurements of the facial swelling (4). Furthermore, the study from Uyanic *et al.* (2) reported reduced number of analgesics taken, when piezosurgery was utilized additionally with PRF.

Four studies evaluated the efficacy of PRF at different extraction sockets to preserve alveolar bone, socket fill and establish adequate healing process (5, 14, 15, 21). In the study from Temmerman *et al.* (21), they reported a statistically significant difference in reduction of the total width of alveolar ridge and socket fill between the test and the control group ($P < 0.005$). In the study from Das *et al.* (15), when PRF was compared to beta-tricalcium phosphate to preserve extraction sockets, both materials showed similar results at clinical and radiographic outcome measurements. Furthermore, the study from Marenzi *et al.* (5) reported statistically significant reduction of pain and higher values for healing index in the PRF-group when compared with the control group. However, Marenzi *et al.* claim that their study does not show the real benefit and strength of PRF because it is more helpful in complex cases when there are intrabony defects and bone regeneration is hard to achieve (5). L-PRF has a positive outcome in diminishing dimensional changes if compared to the natural healing process, because of its growth factors and angiogenic properties (14). Every clinical trial has its limitations and the main drawback is that the anatomy of the extraction socket may vary in width and height, densities of osseous plates, presence of fenestrations and dehiscence, periodontal biotype and the location of the socket (mandible or maxilla). Because of all those varieties it is difficult to measure the benefit of the graft material in the limitation of resorption of the bone (14, 15). Some studies have the lack of histological confirmation of bone preservation, thus low number of participants (5, 14, 15, 21).

PRF in combination with xenograft was com-

pared to xenograft alone utilized in sinus augmentations in three studies (16, 23, 24). The other study from Gassling *et al.* (22) compared PRF membrane with collagen membrane (Bio-Gide®) in coverage of lateral window osteotomy in sinus augmentation procedure. All the studies associated with sinus augmentation showed no statistically significant difference between test and control groups in clinical, radiographic (new bone formation), histological, and histomorphometric outcome measurements. The study from Zhang *et al.* (24) showed that PRF in combination with Bio-Oss has no significant effect on new bone formation, as well as the graft volume after six months postoperative. Overall the study from Zhang *et al.* revealed neither benefits nor drawbacks when PRF is combined with Bio-Oss (24). Besides, the study from Tatullo *et al.* (23) revealed in their histological analysis after 106 days in the PRF group a formation of lamellar bone tissue with an interposed stroma which was highly vascularized. That means primary stability of endosseous implants can be achieved earlier but Tatullo *et al.* (23) claims that the functional loading can still not be assessed after 106 days postoperative.

Three studies evaluated the efficacy of platelet rich fibrin in augmentation procedures of soft tissue associated with implants (17-19). In all studies all implants remained osseointegrated after three months postoperative (Boora *et al.*, Marelli *et al.*) (18, 19) and six months postoperative (Hehn *et al.*) (17). One single case of implant failure occurred because of bacterial peri-implantitis due to not adequate oral hygiene of the patient (19). Hehn *et al.* (17) reported better results of the control group compared to the PRF-group in soft tissue loss and higher values in crestal mucosa. Hehn *et al.* (17) suggest that soft tissue augmentation with PRF utilizing a split-thickness flap technique is not advised to alter thin gingiva types. Additionally, Hehn *et al.* (17) claim that a tissue flap requires a sufficient nutrition of blood with 0.8-1.2 mm of full thickness mucoperiosteal flap. And in split-thickness flaps in combination with PRF the nutrition of the flap is poor, resulting in lesser formation of soft tissue thickness (17). In the study from Boora *et al.* (18), the surgeons performed operations with a full mucoperiosteal flap and overall, mean marginal bone changes after three months were lesser in the PRF group compared to the control group (measured with intraoral periapical radiographs). The administration of PRF during implant placement has a positive, stimulating effect on bone formation in cases for single staged implant with immediate provisionalization in maxillary anterior zone (18).

Two studies compared the efficacy of PRF together with an open flap debridement to an open flap debridement alone in treatment of infrabony defects (3, 7). Both studies showed statistical significant decrease in post-operative pain, probing depth, gain in clinical attachment level and radiographic bone fill when intergroup and intragroup comparison was analyzed, all in favor for the PRF-groups (3, 7). Overall, PRF in combination with open flap debridement results in a significant enhancement in radiographic and clinical values after nine months postoperative (7). Furthermore, Joseph *et al.* point out that the patients could not be blinded to the procedures they underwent, so a Hawthorne effect could have occurred, biased the results of their study (3). The other two studies compared either PRF with autogenous bone graft (8) or PRF with DFDBA (9) in treatment of infrabony defects. Both studies reported statistically significant decrease in probing depth, gain in clinical and relative attachment level when intragroup comparison was analyzed, but however, no statistical significant difference was observed between PRF groups and other graft material which augmented the defects. Furthermore, in the study from Mathur *et al.* (8) defect fill and defect resolution of treated infrabony defects was not statistically significant different between the PRF group and the autogenous bone graft group ($P>0.05$). Overall, PRF-groups showed more superior outcome results when compared with non-PRF groups and similar outcome results between groups when DFDA or autogenous bone graft was utilized.

CONCLUSION

1. Most of the included studies showed superior outcome results in PRF-groups over non-PRF groups at extraction sockets, peri-implant augmentations and infrabony defects treatment.
2. According to some literature it is not recommended to utilize PRF in combination with a split-thickness flap in soft tissue augmentation associated with implants, rather with a full mucoperiosteal flap.
3. PRF can be administered in different applications in oral surgery and can promote adequate soft tissue healing and bone regeneration.
4. PRF is an autologous biomaterial which has low cost and does not need administration of any additives.
5. Further studies with a larger sample size and longer follow up duration are necessary to facilitate more substantial evidence of the efficacy of PRF in promotion of soft and hard tissue healing.
6. Additional studies are necessary to assemble synergistic effect of PRF adjunct with different grafts.

STATEMENT OF CONFLICTS OF INTEREST

The authors state no conflict of interest.

REFERENCES

1. Girish Rao S, Bhat P, Nagesh KS, Rao GH, Mirle B, Kharbhari L, et al. Bone regeneration in extraction sockets with autologous platelet rich fibrin gel. *J Maxillofac Oral Surg* 2013;12:11-6.
2. Uyanik LO, Bilginaylar K, Etikan İ. Effects of platelet-rich fibrin and piezosurgery on impacted mandibular third molar surgery outcomes. *Head Face Med* 2015;11:25.
3. Rosamma Joseph V, Raghunath A, Sharma N. Clinical effectiveness of autologous platelet rich fibrin in the management of infrabony periodontal defects. *Singapore Dent J* 2012;33:5-12.
4. Ozgul O, Senses F, Er N, Tekin U, Tuz HH, Alkan A, et al. Efficacy of platelet rich fibrin in the reduction of the pain and swelling after impacted third molar surgery: randomized multicenter split-mouth clinical trial. *Head Face Med* 2015;11:37.
5. Marenzi G, Ricciatiello F, Tia M, di Lauro A, Sammartino G. Influence of leukocyte- and platelet-rich fibrin (l-prf) in the healing of simple postextraction sockets: a split-mouth study. *Biomed Res Int* 2015;2015:369273.
6. Baslarli O, Tumer C, Ugur O, Vatankulu B. Evaluation of osteoblastic activity in extraction sockets treated with platelet-rich fibrin. *Med Oral Patol Oral Cir Bucal* 2015;20:e111-6.
7. Ajwani H, Shetty S, Gopalakrishnan D, Kathariya R, Kulloli A, Dolas RS, Pradeep AR. Comparative evaluation of platelet-rich fibrin biomaterial and open flap debridement in the treatment of two and three wall intrabony defects. *J Int Oral Health* 2015;7:32-7.
8. Mathur A, Bains VK, Gupta V, Jhingran R, Singh GP. Evaluation of intrabony defects treated with platelet-rich fibrin or autogenous bone graft: A comparative analysis. *Eur J Dent* 2015;9:100-8.
9. Shah M, Patel J, Dave D, Shah S. Comparative evaluation of platelet-rich fibrin with demineralized freeze-dried bone allograft in periodontal infrabony defects: A randomized controlled clinical study. *J Indian Soc Periodontol* 2015;19:56-60.
10. Eshghpour M, Dastmalchi P, Nekooei AH, Nejat A. Effect of platelet-rich fibrin on frequency of alveolar osteitis following mandibular third molar surgery: a double-blinded randomized clinical trial. *J Oral Maxillofac Surg* 2014;72:1463-7.
11. Hoaglin DR, Lines GK. Prevention of localized osteitis

- in mandibular third-molar sites using platelet-rich fibrin. *Int J Dent* 2013;2013:875380.
12. Singh A, Kohli M, Gupta N. Platelet rich fibrin: a novel approach for osseous regeneration. *J Maxillofac Oral Surg* 2012;11:430-4.
 13. Kumar N, Prasad K, Ramanujam L, K R, Dexith J, Chauhan A. Evaluation of treatment outcome after impacted mandibular third molar surgery with the use of autologous platelet-rich fibrin: a randomized controlled clinical study. *J Oral Maxillofac Surg* 2015;73:1042-9.
 14. Anwandter A, Bohmann S, Nally M, Castro AB, Quirynen M, Pinto N. Dimensional changes of the post extraction alveolar ridge, preserved with Leukocyte- and Platelet Rich Fibrin: A clinical pilot study. *J Dent* 2016;52:23-9.
 15. Das S, Jhingran R, Bains VK, Madan R, Srivastava R, Rizvi I. Socket preservation by beta-tri-calcium phosphate with collagen compared to platelet-rich fibrin: A clinico-radiographic study. *Eur J Dent* 2016;10:264-76.
 16. Bolukbasi N, Ersanlı S, Keklikoglu N, Basegmez C, Ozdemir T. Sinus augmentation with platelet-rich fibrin in combination with bovine bone graft versus bovine bone graft in combination with collagen membrane. *J Oral Implantol* 2015;41:586-95.
 17. Hehn J, Schwenk T, Striegel M, Schlee M. The effect of PRF (platelet-rich fibrin) inserted with a split-flap technique on soft tissue thickening and initial marginal bone loss around implants: results of a randomized, controlled clinical trial. *Int J Implant Dent* 2016;2:13.
 18. Boora P, Rathee M, Bhorla M. Effect of platelet rich fibrin (PRF) on peri-implant soft tissue and crestal bone in one-stage implant placement: A Randomized Controlled Trial. *J Clin Diagn Res* 2015;9:ZC18-21.
 19. Marrelli M, Tatullo M. Influence of PRF in the healing of bone and gingival tissues. Clinical and histological evaluations. *Eur Rev Med Pharmacol Sci* 2013;17:1958-62.
 20. Yelamali T, Saikrishna D. Role of platelet rich fibrin and platelet rich plasma in wound healing of extracted third molar sockets: a comparative study. *J Maxillofac Oral Surg* 2015;14:410-6.
 21. Temmerman A, Vandessel J, Castro A, Jacobs R, Teughels W, Pinto N, Quirynen M. The use of leucocyte and platelet-rich fibrin in socket management and ridge preservation: a split-mouth, randomized, controlled clinical trial. *J Clin Periodontol* 2016;43:990-9.
 22. Gassling V, Purcz N, Braesen JH, Will M, Gierloff M, Behrens E, et al. Comparison of two different absorbable membranes for the coverage of lateral osteotomy sites in maxillary sinus augmentation: a preliminary study. *J Craniomaxillofac Surg* 2013;41:76-82.
 23. Tatullo M, Marrelli M, Cassetta M, Pacifici A, Stefanelli LV, Scacco S, et al. Platelet Rich Fibrin (P.R.F.) in reconstructive surgery of atrophied maxillary bones: clinical and histological evaluations. *Int J Med Sci* 2012;9:872-80.
 24. Zhang Y, Tangl S, Huber CD, Lin Y, Qiu L, Rausch-Fan X. Effects of Choukroun's platelet-rich fibrin on bone regeneration in combination with deproteinized bovine bone mineral in maxillary sinus augmentation: a histological and histomorphometric study. *J Craniomaxillofac Surg* 2012;40:321-8.
 25. Al-Hamed FS, Abdel-MonemTawlik M, Abdelfadil E. Clinical effect of platelet rich fibrin (PRF) following surgical extraction of lower third molar. *Saudi J Dent Res* 2017;8:19-25.

Received: 17 04 2017
Accepted for publishing: 25 12 2018