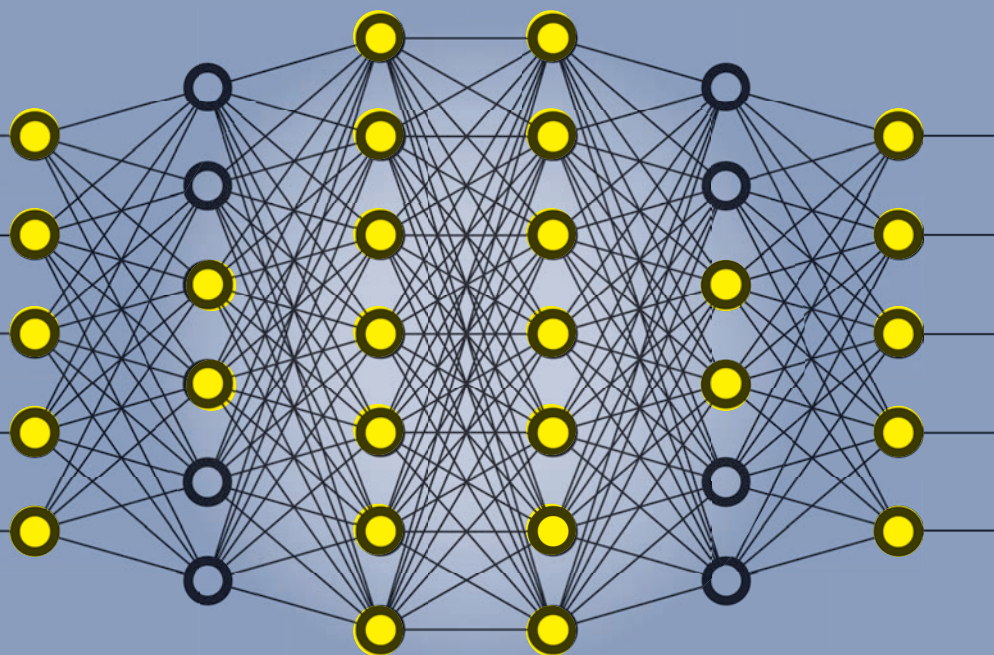


# RETINA SPECIALIST

NOVEMBER 2017

North of the Border: 10 Lessons  
From the Neovascular AMD Trials Page 9

Page 36 Five From ASRS 2017: Syringes, Sirolimus  
And Endophthalmitis Prophylaxis



## THE PROMISE OF **DEEP LEARNING** IN RETINA

**PAGE 21**

The 'Switch' and  
Macular Atrophy in AMD

**PAGE 24**

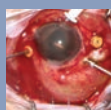
Choroid in AMD:  
A Critical Point of Failure?

**PAGE 28**

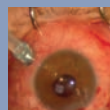
Genetics, Vitamins  
And Astronaut Eyes

**PAGE 32**

### **ONLINE VIDEOS:**




**Surgical Pearl: Draining  
Choroidal Detachments – page 16**



**Beyond Retina: Managing Aphakia  
Without Capsular Support – page 17**



# Teaming up for Better Surgical Outcomes



Visit us at booth #1535  
during AAO, New Orleans!

OCULUS Surgical has acquired Insight Instruments to create an unparalleled portfolio of retinal wide-angle viewing equipment.

Whether with the superb BIOM® Optic Set or the exclusive SUPER VIEW® HTC Contact Lens, OCULUS Surgical is here to bring you the best there is for improved surgical outcomes.

Please note: The availability of the products and features may differ in your country. Specifications and design are subject to change. Please contact your local distributor for details.



11 Campus Blvd., Suite 100  
Newtown Square, PA 19073  
Telephone (610) 492-1000  
Fax (610) 492-1039

Editorial inquiries (610) 492-1000  
Advertising inquiries (610) 492-1011  
E-mail [retinaspecialist@jobson.com](mailto:retinaspecialist@jobson.com)

#### EDITORIAL STAFF

##### EDITOR-IN-CHIEF

Walter Bethke  
[wbethke@jobson.com](mailto:wbethke@jobson.com)

##### CHIEF MEDICAL EDITOR

Charles C. Wykoff, MD, PhD  
[ccwmd@houstonretina.com](mailto:ccwmd@houstonretina.com)

##### EDITOR

Richard Mark Kirkner  
[rkirkner@jobson.com](mailto:rkirkner@jobson.com)

##### ART DIRECTOR

Jared Araujo  
[jaraujo@jhihealth.com](mailto:jaraujo@jhihealth.com)

##### SENIOR GRAPHIC DESIGNER

Matt Egger  
[megger@jhihealth.com](mailto:megger@jhihealth.com)

##### AD PRODUCTION MANAGER

Scott Tobin  
[stobin@jhihealth.com](mailto:stobin@jhihealth.com)

#### EDITORIAL BOARD

Ashkan M. Abbey, MD, Dallas  
David Brown, MD, Houston  
Kevin Corcoran, COE, CPC, San Bernardino, Calif.  
Emmett T. Cunningham, MD, PhD, San Francisco  
Lisa Olmos de Koo, MD, MBA, Los Angeles  
Paul Hahn, MD, PhD, Teaneck, N.J.  
Kirk A. Mack, COMT, COE, CPC, CPMA, Galveston, Texas  
Efreim D. Mandelcorn, MD, FRCSC, Toronto  
Jonathan L. Prenner, MD, Edison, N.J.  
Carl D. Regillo, MD, FACS, Philadelphia  
Philip J. Rosenfeld, MD, PhD, Miami

#### EDITORIAL CONTRIBUTORS

Clarissa S.M. Cheng, FRCOphth, Manchester, UK  
Michael N. Cohen, MD, Boston  
Felipe Dhawahir-Scala, FRCS (Ed), FRCOphth, LMS, Manchester, UK  
Shu Feng, MD, Seattle  
Omar Abu Al Ghanam, MBBSC, Manchester, UK  
Philip J. Luthert, BSc, MB, BS, London  
Stephan Michels, MD, MBA, Zurich, Switzerland  
William C. Ou, Dallas  
Steven S. Saraf, MD, Seattle  
Chirag P. Shah, MD, MPH, Boston  
Scott M. Smith, PhD, Houston  
Peng Yan, MD, Toronto  
Joel Yap, MBChB, Toronto  
Moussa A. Zouache, PhD, London  
Sara R. Zwart, PhD, Houston



Jobson Medical Information LLC



# Deep Learning, MD

Geoffrey Hinton, the father of deep learning, was recently quoted in *The New Yorker* as saying, "They should stop training radiologists now."<sup>1</sup> The days of the clinician simply serving as pattern-recognition specialist are numbered. Turns out, machines are really good at pattern recognition—better than you and I.

In these pages we provide a crash course on deep learning with additional background on page 21 thanks to William Ou. The general concept of machine learning is that one teaches a machine to detect patterns in data through application of rules, accomplished by providing explicit definitions of features to consider in drawing a conclusion. Such technology has been used for decades in the interpretation of electrocardiograms,<sup>2</sup> producing the printout at the top that most of us rely on to determine if there's reason for concern.

Deep learning represents a subset of machine learning in which no external rules are provided. The algorithm programs itself by learning from a large collection of examples that illustrate a defined finding. The algorithm learns the most predictive findings directly from the images themselves. Such deep-learning systems are already commercially employed for radiologic applications.

They are coming to retina. Google sponsored and published a deep-learning algorithm for detection of "referable" diabetic retinopathy and "referable" diabetic macular edema based on training from a dataset of over 250,000 retinal images.

## Quotable

*"Deep learning represents a subset of machine learning in which no external rules are provided. The algorithm programs itself by learning from a large collection of examples that illustrate a defined finding."*

Notably, just two of the 15 authors are MDs.<sup>3</sup>

Fascinatingly, despite our ability to create and implement deep-learning algorithms, we have limited insight into the specific features employed to arrive at a given conclusion. How these algorithms "see and think" are a black box and a field of intensive investigation.

"We are doctors," you say, "not computer scientists or mathematicians!" Get ready.

## REFERENCES

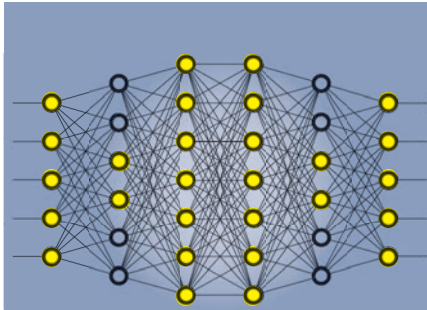
1. Mukherjee S. AI versus MD: What happens when diagnosis is automated. *New Yorker*. April 3, 2017.
2. Willems JL, Abruë-Lima C, Arnaud P, et al. The diagnostic performance of computer programs for the interpretation of electrocardiograms. *N Engl J Med*. 1991;325:1767-1773.
3. Gulshan V, Peng L, Coram M, et al. Development and validation of a deep learning algorithm for detection of diabetic retinopathy in retinal fundus photographs. *JAMA*. 2016;316:2402-2410.

A PUBLICATION BY RETINA

# RETINA SPECIALIST

NOVEMBER 2017

## FEATURES



21

### The Promise of **Deep Learning** in Retina

Artificial intelligence is poised to take diagnostic imaging to the next level.

By William C. Ou and  
Charles C. Wykoff, MD, PhD

24

### The 'Switch' and Macular Atrophy in nAMD

New insights into how frequent, long-term anti-VEGF injections impact RPE.

By Stephan Michels, MD, MBA and Justis P. Ehlers MD

28

### The Choroid in AMD: A Critical Point of Failure?

A look at what's improving our understanding of choroidal failure.

By Moussa Z. Zouche, PhD,  
and Philip J. Luthert, BSc, MB, BS

32

### Genetics, Vitamins And Astronaut Eyes

How space is providing new insights into ophthalmic pathophysiology.

By Scott M. Smith, PhD,  
and Sara R. Zwart, PhD

## DEPARTMENTS

### 3 Editor's Page

Deep Learning, MD  
By Charles C. Wykoff, MD, PhD

### 7 News

As FDA Issues HORV Warning, Histology  
Gains Clarification; Gene Therapy on Track

### 9 North of the Border

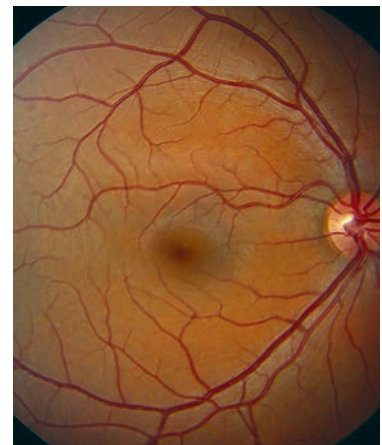Top 10 Lessons from nAMD Trials

Edited by Efreem D. Mandelcorn, MD

### 12 Retina Rounds

Getting Too Close to the Sun

Edited by Lisa Olmos de Koo, MD, MBA



### 16 Surgical Pearl Video

Draining Choroidal Detachments

Online Video By Paul Hahn, MD, PhD

### 39 Innovation Insight

The Hypersonic Principle

By Richard Mark Kirkner

### 40 Clinical Trial Closeup

A Drop for DME and AMD

Edited by Emmett T. Cunningham Jr., MD, PhD

ALSO INSIDE:

17

### Beyond the Retina: Managing Aphakia Without Capsular Support



A close look at  
retropupillary implantation  
of the iris-claw IOL.

By Clarissa S.M. Cheng, FRCOphth,  
Omar Abu Al Ghanam, MBBS, Felipe  
Dhawahir-Scala, FRCS (Ed), FRCOphth, LMS

36

### Report from ASRS 2017: Syringes, Sirolimus and Endophthalmitis Prophylaxis

Plus four-year results of gene therapy  
and insights into when to perform  
ERM removal.

By Ashkan M. Abbey, MD



# STRENGTH IN EVIDENCE

The efficacy and safety of LUCENTIS were rigorously studied in 10 clinical trials<sup>1\*</sup>

  
**LUCENTIS**<sup>®</sup>  
RANIBIZUMAB INJECTION

Approved for wet AMD, DR, DME, mCNV,  
and macular edema following RVO.

## INDICATIONS

LUCENTIS<sup>®</sup> (ranibizumab injection) is indicated for the treatment of patients with:

- Neovascular (wet) age-related macular degeneration (wAMD)
- Macular edema following retinal vein occlusion (RVO)
- Diabetic macular edema (DME)
- Diabetic retinopathy (DR)
- Myopic choroidal neovascularization (mCNV)

## IMPORTANT SAFETY INFORMATION CONTRAINDICATIONS

- LUCENTIS is contraindicated in patients with ocular or periocular infections or known hypersensitivity to ranibizumab or any of the excipients in LUCENTIS. Hypersensitivity reactions may manifest as severe intraocular inflammation

## WARNINGS AND PRECAUTIONS

- Intravitreal injections, including those with LUCENTIS, have been associated with endophthalmitis, retinal detachment, and iatrogenic traumatic cataract. Proper aseptic injection technique should always be utilized when administering LUCENTIS. Patients should be monitored following the injection to permit early treatment, should an infection occur
- Increases in intraocular pressure (IOP) have been noted both pre-injection and post-injection (at 60 minutes) with LUCENTIS. Monitor intraocular pressure prior to and following intravitreal injection with LUCENTIS and manage appropriately
- Although there was a low rate of arterial thromboembolic events (ATEs) observed in the LUCENTIS clinical trials, there is a potential risk of ATEs following intravitreal use of VEGF inhibitors. ATEs are defined as nonfatal stroke, nonfatal myocardial infarction, or vascular death (including deaths of unknown cause)
- Fatal events occurred more frequently in patients with DME and DR at baseline treated monthly with LUCENTIS compared with control. Although the rate of fatal events was low and included causes of death typical of patients with advanced diabetic complications, a potential relationship between these events and intravitreal use of VEGF inhibitors cannot be excluded

## ADVERSE EVENTS

- Serious adverse events related to the injection procedure that occurred in <0.1% of intravitreal injections included endophthalmitis, rhegmatogenous retinal detachment, and iatrogenic traumatic cataract
- In the LUCENTIS Phase III clinical trials, the most common ocular side effects included conjunctival hemorrhage, eye pain, vitreous floaters, and increased intraocular pressure. The most common non-ocular side effects included nasopharyngitis, anemia, nausea, and cough

## Please see Brief Summary of LUCENTIS full Prescribing Information on next page.

\* The following randomized, double-masked clinical trials were conducted for the 5 LUCENTIS indications: **wAMD**: MARINA—Phase III, multicenter, 2-year, sham injection-controlled study; primary end point at 1 year. ANCHOR—Phase III, multicenter, 2-year, active treatment-controlled study; primary end point at 1 year. PIER—Phase IIIb, 2-year, sham injection-controlled study; primary end point at 1 year. HARBOR—Phase III, multicenter, 2-year, active treatment-controlled dose-response study; primary end point at 1 year. **DR and DME**: RISE and RIDE—Methodologically identical, Phase III, multicenter, 3-year, sham injection-controlled studies; primary end point at 2 years. Protocol S—Phase III, multicenter, 2-year, active-controlled study; key clinical outcomes at 2 years. **mCNV**: RADIANCE—Phase III, multicenter, 1-year, active-controlled study; key clinical outcomes at month 3. **RVO**: BRAVO—Phase III, multicenter, 1-year, sham injection-controlled study; primary end point at 6 months. CRUISE—Phase III, multicenter, 1-year, sham injection-controlled study; primary end point at 6 months.<sup>2-11</sup>

**REFERENCES:** **1.** LUCENTIS [package insert]. South San Francisco, CA: Genentech, Inc; 2017. **2.** Rosenfeld PJ, et al; MARINA Study Group. *N Engl J Med.* 2006;355:1419-1431. **3.** Brown DM, et al; ANCHOR Study Group. *Ophthalmology.* 2009;116:57-65. **4.** Regillo CD, et al; PIER Study Group. *Am J Ophthalmol.* 2008;145:239-248. **5.** Busbee BG, et al; HARBOR Study Group. *Ophthalmology.* 2013;120:1046-1056. **6.** Campochiaro PA, et al; BRAVO Investigators. *Ophthalmology.* 2010;117:1102-1112. **7.** Brown DM, et al; CRUISE Investigators. *Ophthalmology.* 2010;117:1124-1133. **8.** Brown DM, et al; RISE and RIDE Research Group. *Ophthalmology.* 2013;120:2013-2022. **9.** Data on file. Genentech, Inc. South San Francisco, CA. **10.** Nguyen QD, et al; RISE and RIDE Research Group. *Ophthalmology.* 2012;119:789-801. **11.** Gross JG, et al; Writing Committee for the Diabetic Retinopathy Clinical Research Network. *JAMA.* 2015;314:2137-2146.

**Genentech**  
A Member of the Roche Group

© 2017 Genentech USA, Inc. 1 DNA Way, South San Francisco, CA 94080-4990 All rights reserved. LUC/033117/0027(1) 09/17



# **LUCENTIS®** **RANIBIZUMAB INJECTION**

**Brief summary—please see the LUCENTIS® package insert for full prescribing information.**

## 1 INDICATIONS AND USAGE

LUCENTIS is indicated for the treatment of patients with:

- 1.1 Neovascular (Wet) Age-Related Macular Degeneration (AMD)
- 1.2 Macular Edema Following Retinal Vein Occlusion (RVO)
- 1.3 Diabetic Macular Edema (DME)
- 1.4 Diabetic Retinopathy (DR)
- 1.5 Myopic Choroidal Neovascularization (mCNV)

## 4 CONTRAINDICATIONS

### 4.1 Ocular or Periorcular Infections

LUCENTIS is contraindicated in patients with ocular or periorcular infections.

### 4.2 Hypersensitivity

LUCENTIS is contraindicated in patients with known hypersensitivity to ranibizumab or any of the excipients in LUCENTIS. Hypersensitivity reactions may manifest as severe intraocular inflammation.

## 5 WARNINGS AND PRECAUTIONS

### 5.1 Endophthalmitis and Retinal Detachments

Intravitreal injections, including those with LUCENTIS, have been associated with endophthalmitis and retinal detachments. Proper aseptic injection technique should always be used when administering LUCENTIS. In addition, patients should be monitored following the injection to permit early treatment should an infection occur [see Dosage and Administration (2.7, 2.8) in the full prescribing information and Patient Counseling Information (17)].

### 5.2 Increases in Intraocular Pressure

Increases in intraocular pressure have been noted both pre-injection and post-injection (at 60 minutes) while being treated with LUCENTIS. Monitor intraocular pressure prior to and following intravitreal injection with LUCENTIS and manage appropriately [see Dosage and Administration (2.8) in the full prescribing information].

### 5.3 Thromboembolic Events

Although there was a low rate of arterial thromboembolic events (ATEs) observed in the LUCENTIS clinical trials, there is a potential risk of ATEs following intravitreal use of VEGF inhibitors. ATEs are defined as nonfatal stroke, nonfatal myocardial infarction, or vascular death (including deaths of unknown cause).

### Neovascular (Wet) Age-Related Macular Degeneration

The ATE rate in the three controlled neovascular AMD studies (AMD-1, AMD-2, AMD-3) during the first year was 1.9% (17 of 874) in the combined group of patients treated with 0.3 mg or 0.5 mg LUCENTIS compared with 1.1% (5 of 441) in patients from the control arms [see Clinical Studies (14.1) in the full prescribing information]. In the second year of Studies AMD-1 and AMD-2, the ATE rate was 2.6% (19 of 721) in the combined group of LUCENTIS-treated patients compared with 2.9% (10 of 344) in patients from the control arms. In Study AMD-4, the ATE rates observed in the 0.5 mg arms during the first and second year were similar to rates observed in Studies AMD-1, AMD-2, and AMD-3.

In a pooled analysis of 2-year controlled studies (AMD-1, AMD-2, and a study of LUCENTIS used adjunctively with verteporfin photodynamic therapy), the stroke rate (including both ischemic and hemorrhagic stroke) was 2.7% (13 of 484) in patients treated with 0.5 mg LUCENTIS compared to 1.1% (5 of 435) in patients in the control arms (odds ratio 2.2 [95% confidence interval (0.8-7.1)]).

### Macular Edema Following Retinal Vein Occlusion

The ATE rate in the two controlled RVO studies during the first 6 months was 0.8% in both the LUCENTIS and control arms of the studies (4 of 525 in the combined group of patients treated with 0.3 mg or 0.5 mg LUCENTIS and 2 of 260 in the control arms) [see Clinical Studies (14.2) in the full prescribing information]. The stroke rate was 0.2% (1 of 525) in the combined group of LUCENTIS-treated patients compared to 0.4% (1 of 260) in the control arms.

### Diabetic Macular Edema and Diabetic Retinopathy

Safety data are derived from studies D-1 and D-2. All enrolled patients had DME and DR at baseline [see Clinical Studies (14.3, 14.4) in the full prescribing information].

In a pooled analysis of Studies D-1 and D-2 [see Clinical Studies (14.3) in the full prescribing information], the ATE rate at 2 years was 7.2% (18 of 250) with 0.5 mg LUCENTIS, 5.6% (14 of 250) with 0.3 mg LUCENTIS, and 5.2% (13 of 250) with control. The stroke rate at 2 years was 3.2% (8 of 250) with 0.5 mg LUCENTIS, 1.2% (3 of 250) with 0.3 mg LUCENTIS, and 1.6% (4 of 250) with control. At 3 years, the ATE rate was 10.4% (26 of 249) with 0.5 mg LUCENTIS and 10.8% (27 of 250) with 0.3 mg LUCENTIS; the stroke rate was 4.8% (12 of 249) with 0.5 mg LUCENTIS and 2.0% (5 of 250) with 0.3 mg LUCENTIS.

### 5.4 Fatal Events in Patients with DME and DR at Baseline

Diabetic Macular Edema and Diabetic Retinopathy  
Safety data are derived from studies D-1 and D-2. All enrolled patients had DME and DR at baseline [see Clinical Studies (14.3, 14.4) in the full prescribing information].

A pooled analysis of Studies D-1 and D-2 [see Clinical Studies (14.3) in the full prescribing information], showed that fatalities in the first 2 years occurred in 4.4% (11 of 250) of patients treated with 0.5 mg LUCENTIS, in 2.8% (7 of 250) of patients treated with 0.3 mg LUCENTIS, and in 1.2% (3 of 250) of control patients. Over 3 years, fatalities occurred in 6.4% (16 of 249) of patients treated with 0.5 mg LUCENTIS and in 4.4% (11 of 250) of patients treated with 0.3 mg LUCENTIS. Although the rate of fatal events was low and included causes of death typical of patients with advanced diabetic complications, a potential relationship between these events and intravitreal use of VEGF inhibitors cannot be excluded.

## 6 ADVERSE REACTIONS

The following adverse reactions are discussed in greater detail in other sections of the label:

- Endophthalmitis and Retinal Detachments [see Warnings and Precautions (5.1)]
- Increases in Intraocular Pressure [see Warnings and Precautions (5.2)]
- Thromboembolic Events [see Warnings and Precautions (5.3)]
- Fatal Events in patients with DME and DR at baseline [see Warnings and Precautions (5.4)]

### 6.1 Injection Procedure

Serious adverse reactions related to the injection procedure have occurred in < 0.1% of intravitreal injections, including endophthalmitis [see Warnings and Precautions (5.1)], rhegmatogenous retinal detachment, and iatrogenic traumatic cataract.

## 6.2 Clinical Studies Experience

Because clinical trials are conducted under widely varying conditions, adverse reaction rates observed in one clinical trial of a drug cannot be directly compared with rates in the clinical trials of the same or another drug and may not reflect the rates observed in practice.

The data below reflect exposure to 0.5 mg LUCENTIS in 440 patients with neovascular AMD in Studies AMD-1, AMD-2, and AMD-3; in 259 patients with macular edema following RVO. The data also reflect exposure to 0.3 mg LUCENTIS in 250 patients with DME and DR at baseline [see Clinical Studies (14) in the full prescribing information].

Safety data observed in Study AMD-4, D-3, and in 224 patients with mCNV were consistent with these results. On average, the rates and types of adverse reactions in patients were not significantly affected by dosing regimen.

### Ocular Reactions

Table 1 shows frequently reported ocular adverse reactions in LUCENTIS-treated patients compared with the control group.

**Table 1 Ocular Reactions in the DME and DR, AMD, and RVO Studies**

Adverse Reaction	DME and DR 2-year		AMD 2-year		AMD 1-year		RVO 6-month	
	LUCENTIS 0.3 mg n=250	Control n=250	LUCENTIS 0.5 mg n=379	Control n=379	LUCENTIS 0.5 mg n=440	Control n=441	LUCENTIS 0.5 mg n=259	Control n=260
Conjunctival hemorrhage	47%	32%	74%	60%	64%	50%	48%	37%
Eye pain	17%	13%	35%	30%	26%	20%	17%	12%
Vitreous floaters	10%	4%	27%	8%	19%	5%	7%	2%
Intraocular pressure increased	18%	7%	24%	7%	17%	5%	7%	2%
Vitreous detachment	11%	15%	21%	19%	15%	15%	4%	2%
Intraocular inflammation	4%	3%	18%	8%	13%	7%	1%	3%
Cataract	28%	32%	17%	14%	11%	9%	2%	2%
Foreign body sensation in eyes	10%	5%	16%	14%	13%	10%	7%	5%
Eye irritation	8%	5%	15%	15%	13%	12%	7%	6%
Lacrimation increased	5%	4%	14%	12%	8%	8%	2%	3%
Blepharitis	3%	2%	12%	8%	8%	5%	0%	1%
Dry eye	5%	3%	12%	7%	7%	7%	3%	3%
Visual disturbance or vision blurred	8%	4%	18%	15%	13%	10%	5%	3%
Eye pruritus	4%	4%	12%	11%	9%	7%	1%	2%
Ocular hyperemia	9%	9%	11%	8%	7%	4%	5%	3%
Retinal disorder	2%	2%	10%	7%	8%	4%	2%	1%
Maculopathy	5%	7%	9%	9%	6%	6%	11%	7%
Retinal degeneration	1%	0%	8%	6%	5%	3%	1%	0%
Ocular discomfort	2%	1%	7%	4%	5%	2%	2%	2%
Conjunctival hyperemia	1%	2%	7%	6%	5%	4%	0%	0%
Posterior capsule opacification	4%	3%	7%	4%	2%	2%	0%	1%
Injection site hemorrhage	1%	0%	5%	2%	3%	1%	0%	0%

### Non-Ocular Reactions

Non-ocular adverse reactions with an incidence of  $\geq 5\%$  in patients receiving LUCENTIS for DR, DME, AMD, and/or RVO and which occurred at  $\geq 1\%$  higher frequency in patients treated with LUCENTIS compared to control are shown in Table 2. Though less common, wound healing complications were also observed in some studies.

**Table 2 Non-Ocular Reactions in the DME and DR, AMD, and RVO Studies**

Adverse Reaction	DME and DR 2-year		AMD 2-year		AMD 1-year		RVO 6-month	
	LUCENTIS 0.3 mg n=250	Control n=250	LUCENTIS 0.5 mg n=379	Control n=379	LUCENTIS 0.5 mg n=440	Control n=441	LUCENTIS 0.5 mg n=259	Control n=260
Nasopharyngitis	12%	6%	16%	13%	8%	9%	5%	4%
Anemia	11%	10%	8%	7%	4%	3%	1%	1%
Nausea	10%	9%	9%	6%	5%	5%	1%	2%
Cough	9%	4%	9%	8%	5%	4%	1%	2%
Constipation	8%	4%	5%	7%	3%	4%	0%	1%
Seasonal allergy	8%	4%	4%	4%	2%	2%	0%	2%
Hypercholesterolemia	7%	5%	5%	5%	3%	2%	1%	1%
Influenza	7%	3%	7%	5%	3%	2%	3%	2%
Renal failure	7%	6%	1%	1%	0%	0%	0%	0%
Upper respiratory tract infection	7%	7%	9%	8%	5%	5%	2%	2%
Gastroesophageal reflux disease	6%	4%	4%	6%	3%	4%	1%	0%
Headache	6%	8%	12%	9%	6%	5%	3%	3%
Edema peripheral	6%	4%	3%	5%	2%	3%	0%	1%
Renal failure chronic	6%	2%	0%	1%	0%	0%	0%	0%
Neuropathy peripheral	5%	3%	1%	1%	1%	0%	0%	0%
Sinusitis	5%	8%	8%	7%	5%	5%	3%	2%
Bronchitis	4%	4%	11%	9%	6%	5%	0%	2%
Atrial fibrillation	3%	3%	5%	4%	2%	2%	1%	0%
Arthralgia	3%	3%	11%	9%	5%	5%	2%	1%
Chronic obstructive pulmonary disease	1%	1%	6%	3%	3%	1%	0%	0%
Wound healing complications	1%	0%	1%	1%	1%	0%	0%	0%

## 6.3 Immunogenicity

As with all therapeutic proteins, there is the potential for an immune response in patients treated with LUCENTIS. The immunogenicity data reflect the percentage of patients whose test results were considered positive for antibodies to LUCENTIS in immunoassays and are highly dependent on the sensitivity and specificity of the assays.

The pre-treatment incidence of immunoreactivity to LUCENTIS was 0%-5% across treatment groups. After monthly dosing with LUCENTIS for 6 to 24 months, antibodies to LUCENTIS were detected in approximately 1%-9% of patients.

The clinical significance of immunoreactivity to LUCENTIS is unclear at this time. Among neovascular AMD patients with the highest levels of immunoreactivity, some were noted to have iritis or vitritis. Intraocular inflammation was not observed in patients with DME and DR at baseline, or RVO patients with the highest levels of immunoreactivity.

## 6.4 Postmarketing Experience

The following adverse reaction has been identified during post-approval use of LUCENTIS. Because this reaction was reported voluntarily from a population of uncertain size, it is not always possible to reliably estimate the frequency or establish a causal relationship to drug exposure.

- Ocular: Tear of retinal pigment epithelium among patients with neovascular AMD

## 7 DRUG INTERACTIONS

Drug interaction studies have not been conducted with LUCENTIS.

LUCENTIS intravitreal injection has been used adjunctively with verteporfin photodynamic therapy (PDT). Twelve (12) of 105 (11%) patients with neovascular AMD developed serious intraocular inflammation; in 10 of the 12 patients, this occurred when LUCENTIS was administered 7 days ( $\pm 2$  days) after verteporfin PDT.

## 8 USE IN SPECIFIC POPULATIONS

### 8.1 Pregnancy

#### Risk Summary

There are no adequate and well-controlled studies of LUCENTIS administration in pregnant women.

Administration of ranibizumab to pregnant monkeys throughout the period of organogenesis resulted in a low incidence of skeletal abnormalities at intravitreal doses 13-times the predicted human exposure (based on maximal serum trough levels [C<sub>trough</sub>]) after a single eye treatment at the recommended clinical dose. No skeletal abnormalities were observed at serum trough levels equivalent to the predicted human exposure after a single eye treatment at the recommended clinical dose [see Animal Data].

Animal reproduction studies are not always predictive of human response, and it is not known whether ranibizumab can cause fetal harm when administered to a pregnant woman. Based on the anti-VEGF mechanism of action for ranibizumab [see Clinical Pharmacology (12.1) in the full prescribing information], treatment with LUCENTIS may pose a risk to human embryofetal development.

LUCENTIS should be given to a pregnant woman only if clearly needed.

### Data

#### Animal Data

An embryo-fetal developmental toxicity study was performed on pregnant cynomolgus monkeys. Pregnant animals received intravitreal injections of ranibizumab every 14 days starting on Day 20 of gestation, until Day 62 at doses of 0, 0.125, and 1 mg/eye. Skeletal abnormalities including incomplete and/or irregular ossification of bones in the skull, vertebral column, and hindlimbs and shortened supernumerary ribs were seen at a low incidence in fetuses from animals treated with 1 mg/eye of ranibizumab. The 1 mg/eye dose resulted in trough serum ranibizumab levels up to 13 times higher than predicted C<sub>trough</sub> levels with single eye treatment in humans. No skeletal abnormalities were seen at the lower dose of 0.125 mg/eye, a dose which resulted in trough exposures equivalent to single eye treatment in humans. No effect on the weight or structure of the placenta, maternal toxicity, or embryotoxicity was observed.

### 8.2 Lactation

#### Risk Summary

There are no data available on the presence of ranibizumab in human milk, the effects of ranibizumab on the breastfed infant or the effects of ranibizumab on milk production/excretion.

Because many drugs are excreted in human milk, and because the potential for absorption and harm to infant growth and development exists, caution should be exercised when LUCENTIS is administered to a nursing woman.

The developmental and health benefits of breastfeeding should be considered along with the mother's clinical need for LUCENTIS and any potential adverse effects on the breastfed child from ranibizumab.

### 8.3 Females and Males of Reproductive Potential

#### Infertility

No studies on the effects of ranibizumab on fertility have been conducted, and it is not known whether ranibizumab can affect reproduction capacity. Based on the anti-VEGF mechanism of action for ranibizumab, treatment with LUCENTIS may pose a risk to reproductive capacity.

### 8.4 Pediatric Use

The safety and effectiveness of LUCENTIS in pediatric patients have not been established.

### 8.5 Geriatric Use

In the clinical studies, approximately 76% (2449 of 3227) of patients randomized to treatment with LUCENTIS were  $\geq 65$  years of age and approximately 51% (1644 of 3227) were  $\geq 75$  years of age [see Clinical Studies (14) in the full prescribing information]. No notable differences in efficacy or safety were seen with increasing age in these studies. Age did not have a significant effect on systemic exposure.

## 10 OVERDOSAGE

More concentrated doses as high as 2 mg ranibizumab in 0.05 mL have been administered to patients. No additional unexpected adverse reactions were seen.

## 17 PATIENT COUNSELING INFORMATION

Advise patients that in the days following LUCENTIS administration, patients are at risk of developing endophthalmitis. If the eye becomes red, sensitive to light, painful, or develops a change in vision, advise the patient to seek immediate care from an ophthalmologist [see Warnings and Precautions (5.1)].

## LUCENTIS® [ranibizumab injection]

Manufactured by:  
**Genentech, Inc.**  
A Member of the Roche Group  
1 DNA Way  
South San Francisco, CA  
94080-4990

Initial US Approval: June 2006  
Revision Date: LUC/021815/005(02) 2017  
LUCENTIS® is a registered trademark of Genentech, Inc.  
©2017 Genentech, Inc.

## IN BRIEF

The first patient in the clinical investigation of the **VisionCare Inc.** Implantable Miniature Telescope has successfully received the implant in a procedure that swapped out a previously implanted intraocular lens. The Food and Drug Administration approved the company's investigational device exemption for clinical study in January 2017.

**Topcon Medical Systems'** Pascal Synthesis TwinStar laser received FDA approval for single-spot photocoagulation in the posterior segment as well as pattern-scanning photocoagulation in the non-macular retina. The laser incorporates yellow 577 nm and red 638 nm wavelengths in a single system.

Erin Lavik, ScD, of the University of Maryland, Baltimore County, won the \$90,000 **National Eye Institute** 3-D Retina Organoid Challenge that seeks to design human retina from stem cells. Dr. Lavik's team proposed building a retina by screen printing adult neural progenitor-derived retinal neurons in layers that mimic the structure of the human retina.

**ThromboGenics NV** has successfully introduced a new "Already-Diluted" formulation of Jetrea (ocriplasmin). The new formulation is designed to eliminate the preparatory dilution steps before injection. At the point of administration into the eye, the strength, potency, composition and pharmaceutical form of the already-diluted formulation remain identical to the currently available formulation after dilution.

## As FDA Issues HORV Warning, Histology Gains Clarification

**A**s the Food and Drug Administration was ordering a new label warning about the risk of hemorrhagic occlusive retinal vasculitis, more commonly known as HORV, with the use of vancomycin injection during cataract surgery, the thinking behind the pathophysiology of HORV was undergoing a revision.

At the annual meeting of the Retina Society last month, Bozho Todorich, MD, PhD, of Camp Hill, Pa., reported the first histologic findings of a patient with this condition who developed a blind, painful eye following intracameral vancomycin during cataract surgery. The research concluded the disease is not a form of leukocytoclastic retinal vasculitis as had been thought, but rather a primary non-granulomatous choroiditis with secondary retinal vasculopathy but without retinal vasculitis.

"The clinico-pathologic analysis of this eye demonstrated diffuse hemorrhagic necrosis of the neurosensory retina with intraluminal vascular thrombosis, diffuse choroidal infiltration of inflammatory cells and iris and ciliary body infarction," Dr. Todorich tells *Retina Specialist*. "The immunophenotyping of the choroidal infiltrate demonstrated predominance of CD8+ and CD4+ T cells, lesser abundance of B cells, and scattered plasma cells, mast cells and eosinophils. The choroid also exhibited an unusual glomeruloid proliferation of endothelial cells."

The choroiditis is predominantly T-cell driven and more consistent

with a type IV rather than type III drug hypersensitivity, Dr. Todorich says. "Thus, a more precise pathologic label for this condition is hemorrhagic occlusive choroidal and retinal vasculopathy (HOCRVP)."

The clinical signs and symptoms include delayed onset of up to three weeks of sudden painless decreased vision, intraocular inflammation, intraretinal hemorrhage, retinal vasculitis, vascular occlusion and retinal ischemia. Bilateral vancomycin administration is "a likely consequence of HORV," the FDA statement read.

Cataract surgeons commonly use a compounded form of triamcinolone, moxifloxacin and vancomycin (TMV) as prophylaxis against endophthalmitis. Because of the risk of HORV, the FDA recommends against use of intraocular vancomycin, either alone or in a compounded drug, during cataract surgery.

The FDA's action is based on an adverse event report it received in August concerning a patient who was diagnosed postoperatively with bilateral HORV after receiving TMV in each eye at the conclusion of cataract operations done two weeks apart. The TMV formulation was compounded by Imprimis Pharmaceuticals Inc., Ledgewood, N.J.

Giving the FDA action context, Andre J. Witkin, MD, of Tufts Medical Center, Boston, who reported the first case of HORV in 2015,<sup>1</sup> says, "This may mean that physicians could be held accountable for adverse reactions to vancomycin that occur as

a result of intracameral vancomycin use during cataract surgery.”

The supplemental new drug application the FDA approved in September adds the following in the warnings section of vancomycin injection:

*Hemorrhagic occlusive retinal vasculitis, including permanent loss of vision, occurred in patients receiving intracameral or intravitreal administration of vancomycin during or after cataract surgery.*

*The safety and efficacy of vancomycin administered by the intracameral or the intravitreal route have not been established by adequate and well-controlled trials. Vancomycin is not indicated for prophylaxis of endophthalmitis.*

## REFERENCE

1. Witkin AJ, Shah AR, Engstrom RE, et al. Postoperative hemorrhagic occlusive retinal vasculitis: Expanding the clinical spectrum and possible association with vancomycin. *Ophthalmology*. 2015; 122:1438-1451.

# Gene Therapy On Track For January FDA Approval

**W**ith the recent unanimous endorsement from a Food and Drug Administration advisory committee, Spark Therapeutics is on track to receive approval early next year for its Luxturna gene therapy for biallelic *RPE65* mutation-associated retinal dystrophy such as Leber congenital amaurosis (LCA) and retinitis pigmentosa (RP).


The endorsement of Luxturna (voretigene neparvovec) came from the FDA's Cellular, Tissue and Gene Therapies Advisory Committee. The FDA set a date in January to consider the recommendation and act on Spark's application. While the advisory committee vote is non-binding, it is an indication that the full FDA panel will favorably view the application. Luxturna had already received orphan drug, breakthrough therapy and rare pediatric disease designations from FDA.

The advisory committee's recommendation is based on Luxturna's clinical development program, which includes the first completed randomized, controlled Phase III gene therapy clinical trial for a genetic disease. In the original Phase III intervention group, participants age

4 to 44 years on average maintained the functional vision and visual function improvements for 30 days after Luxturna administration through their last annual follow-up visit.

The FDA review noted that patients who had treatment with Luxturna had improvements in visual performance for at least two years. "Overall, the available clinical efficacy data support a consistent, clinically meaningful and durable treatment effect of voretigene neparvovec in patients with vision loss due to biallelic *RPE65* mutation," the briefing document stated.

The advisory committee did have one cautionary note: Luxturna improved sight using the light levels measured for the primary endpoint, but fell far short of curing retinal dystrophy triggered by genetic *RPE65* mutations. Results also varied based on the number of viable retinal cells a recipient has left upon receiving treatment, the review document noted.

Other diagnoses of *RPE65*-related retinal disease include severe early childhood onset retinal dystrophy, tapetal retinal dystrophy-LCA type or delayed retinal maturation. 

# RETINA SPECIALIST

## BUSINESS OFFICES

11 CAMPUS BOULEVARD, SUITE 100  
NEWTOWN SQUARE, PA 19073  
SUBSCRIPTION INQUIRIES (877) 529-1746  
(USA ONLY); OUTSIDE USA, CALL (847) 763-9630

## BUSINESS STAFF

PUBLISHER

**JAMES HENNE**

(610) 492-1017 JHENNE@JOBSON.COM

REGIONAL SALES MANAGER

**MICHELE BARRETT**

(610) 492-1014 MBARRETT@JOBSON.COM

REGIONAL SALES MANAGER

**MICHAEL HOSTER**

(610) 492-1028 MHOSTER@JOBSON.COM

## CLASSIFIED ADVERTISING

(888)-498-1460

VICE PRESIDENT OF OPERATIONS

**CASEY FOSTER**

(610) 492-1007 CFOSTER@JOBSON.COM

PRODUCTION MANAGER

**SCOTT TOBIN**

(610) 492-1011 STOBIN@JOBSON.COM

## SUBSCRIPTIONS

US ONE YEAR: \$63.00

CANADIAN ONE YEAR: \$99.00

FOREIGN ONE YEAR: \$158.00

SUBSCRIPTIONS E-MAIL:

RETINASPECIALIST@CAMBEYWEST.COM

## CIRCULATION

RETINA SPECIALIST

PO BOX 397

CONGERS, NY 10920-0397

CIRCULATION CUSTOMER SERVICE

PHONE: (877) 529-1746 (U.S.)

OR(845) 267-3065 (OUTSIDE U.S.)

SENIOR CIRCULATION MANAGER

**HAMILTON MAHER**

(212) 219-7870 hmaher@jhihealth.com

CEO, INFORMATION GROUP SERVICES

**MARC FERRARA**

SENIOR VICE PRESIDENT, OPERATIONS

**JEFF LEVITZ**

VICE PRESIDENT, HUMAN RESOURCES

**TAMMY GARCIA**

VICE PRESIDENT, CREATIVE SERVICES & PRODUCTION

**MONICA TETTAMANZI**

SENIOR CORPORATE PRODUCTION DIRECTOR

**JOHN ANTHONY CAGGIANO**

VICE PRESIDENT, CIRCULATION

**EMELDA BAREA**



440 Ninth Avenue, 14th Floor  
New York, N.Y. 10001





# Top 10 Lessons from the nAMD Trials

*Key takeaways that inform how we approach treatment.*

**By Joel Yap, MBChB, and Peng Yan, MD**

**W**e all know that age-related macular degeneration is the leading cause of blindness and visual disability in patients age 60 years and older in North America, and that neovascular AMD (nAMD) accounts for most AMD-related severe vision loss. In our practice in Toronto, patients with nAMD initially receive three monthly anti-VEGF injections followed by a treat-and-extend regimen. We base this management strategy on these 10 lessons we've learned from selected landmark nAMD trials.

## **Lesson 1: Better than Photocoagulation**

Laser photocoagulation was previously used to treat nAMD, but is no longer indicated for subfoveal disease. The Macular Photocoagulation Study showed, however, that it can be a treatment option for extrafoveal nAMD. After 18 months of follow-up, 60 percent of untreated eyes vs. 25 percent of treated eyes experienced severe visual loss, defined as a loss of more than 6 lines on an Early Treatment of Diabetic Retinopathy Study chart.<sup>1</sup> However, 59 percent of patients in the treatment group demonstrated recurrent neovascularization in the form of either neovascularization contiguous with the treatment scar or independent neovascular membranes.<sup>2</sup>

## **Lesson 2: Variable Results With Photodynamic Therapy**

Photodynamic therapy (PDT) for nAMD is effective in preventing visual loss from nAMD, though there is doubt about the size of the

effect. The TAP trial studied the effect of PDT on subfoveal, "classic" choroidal neovascular membranes (CNVM) on fluorescein angiography, while the VIP trial did a similar study on CNVM caused by pathological myopia.<sup>3,4</sup> Participants received, on average, five treatments over two years, and patients who received PDT treatment had a 0.77 relative risk of losing 3 or more lines of visual acuity at 24 months.<sup>5</sup> Alarming, severe acute visual loss occurred in about 2 percent of patients within seven days of treatment.

## **Lesson 3: Visual Acuity Improvement is Measurable**

The advent of anti-VEGF treatment revolutionized our approach to nAMD and resulted in a paradigm shift in the way patients with nAMD are managed. The ANCHOR trial compared monthly ranibizumab (Lucentis, Roche/Genentech) therapy with PDT treatment for "predominantly classic" nAMD lesions, and the MARINA trial compared monthly ranibizumab therapy with sham injections for "minimally classic" or "occult" nAMD lesions.<sup>6,7</sup> These trials showed that monthly ranibizumab injections for two years not only prevent visual loss, but also improved vision.

In the ANCHOR trial, visual acuity improved by 15 letters or more in 40.3 percent of the 0.5-mg ranibizumab injection group, compared with 5.6 percent in the PDT group after one year. Similarly, visual acuity improved by 15 or more letters in 33.8 percent of the 0.5-mg ranibizumab injection group, compared

with 5 percent of the sham injection group in the MARINA trial. These efficacy outcomes were achieved with a very low rate of serious ocular adverse events, including infectious endophthalmitis.<sup>8</sup>

Similarly, the VIEW1 and VIEW2 studies compared monthly and bimonthly intravitreal aflibercept (Eylea, Regeneron) injections with monthly ranibizumab injections. The studies concluded that intravitreal aflibercept given monthly or bimonthly, after three initial monthly injections, produced similar efficacy and safety outcomes to monthly ranibizumab.<sup>24,25</sup>

The VIEW trials demonstrated that aflibercept is an effective treatment for nAMD, with the bimonthly injection regimen offering the potential to reduce the treatment burden of monthly injections.

## **Lesson 4: Monthly Treatment Truly Works**

Pivotal clinical trials reported that ranibizumab, bevacizumab (Avastin, Roche/Genentech) and aflibercept treatment achieved the best visual acuity outcomes with three initial consecutive monthly injections followed by continued monthly injections.<sup>9</sup> For example, the PIER study evaluated the efficacy of three monthly injections followed by quarterly injections in patients with nAMD. Although mean visual acuity improved from baseline in the first three months with ranibizumab treatment, VA then declined an average of 2.2 letters over the two-year trial period,<sup>10</sup> suggesting that quarterly treatment is, on average, infe-

rior to monthly treatment and that more frequent monitoring is needed.

### **Lesson 5: Individualize Treatment Plans**

Patients with nAMD respond variably to the available anti-VEGF agents and treatment regimens, so individualizing treatment regimens is possible. The PRONTO study assessed three consecutive monthly injections followed by optical coherence tomography-guided variable dosing. Visual acuity improved 15 or more letters in 35 percent of patients and an average of 5.6 injections were administered over 12 months.<sup>11</sup>

While PRONTO demonstrated similar visual outcomes to the MARINA and ANCHOR trials but with fewer intravitreal injections, substantial trial design differences limit comparisons. The SUSTAIN trial had a protocol very similar to the PRONTO study, with monthly visits following three initial monthly injections. Patients again achieved maximal visual acuity gain, on average, after the first three monthly injections. VA decreased slightly under a PRN regimen during the next two to three months, but was then sustained throughout the rest of the treatment period.<sup>12</sup>

### **Lesson 6: Prompt Initiation Of Therapy Preserves Vision**

Treatment of nAMD should be initiated promptly because a longer delay from symptom onset was a significant predictor of poorer treatment outcome when controlling for age, sex and baseline visual acuity. Patients with a delay in treatment of 21 weeks or more had an odds ratio of 2.62 for worse vision after treatment, compared to patients with a delay of seven weeks or less.<sup>13</sup>

In another retrospective review of 1,099 patients who began anti-VEGF therapy for nAMD, a two-week-earlier injection was associated with a 5-letter gain in mean VA at three months after initial presentation.<sup>14</sup> Moreover, the preliminary results of the LUMINOUS study showed that patients with a better presenting visual acuity had a better one-year visual outcome.<sup>15</sup>

### **Lesson 7: Treat-and-Extend Is An Effective Protocol**

Treat-and-extend (TREX) regimens offer similar anatomical and functional outcomes and can greatly reduce treatment burden. The TREX-AMD study group compared a TREX management strategy with monthly ranibizumab injections. The TREX patients were treated monthly for at least three doses, until resolution of clinical and OCT evidence of exudative disease activity. Thereafter, the interval between visits was individualized.

At one year, the visual acuity gain was similar in the two groups and the mean number of injections was 13 in the monthly group and 10.1 in the TREX cohort. The mean maximum extension interval after the first three monthly injections was 8.4 weeks.<sup>16</sup> The LUCAS study, which compared bevacizumab and ranibizumab injections in a treat-and-extend protocol, also showed that visual acuity results at one year were comparable to other clinical trials with monthly treatment. In this study, once patients achieved disease stability, the treatment interval was extended by two weeks at a time up to a maximum of 12 weeks. Disease recurrence meant shortening the treatment interval by two weeks at a time.<sup>17</sup>

Interim results of the

CANTREAT study in Canada also suggested that fewer injections and visits using a treat-and-extend strategy rather than monthly dosing can achieve comparable vision improvement in a real-world setting.<sup>18</sup>

### **Lesson 8: Ranibizumab vs. Bevacizumab, Monthly vs. PRN**

Intravitreal bevacizumab, ranibizumab and aflibercept can be used to treat nAMD. The CATT and IVAN studies were non-inferiority trials, which assigned patients to receive intravitreal injections of ranibizumab or bevacizumab on either a monthly schedule or as needed (PRN) with monthly evaluation. The CATT study showed that monthly bevacizumab was equivalent to monthly ranibizumab, with 8 and 8.5 letters gained, respectively.

Bevacizumab administered PRN was equivalent to ranibizumab PRN, with 5.9 and 6.8 letters gained, respectively. Ranibizumab as needed was equivalent to monthly ranibizumab, although the comparison between bevacizumab as needed and monthly bevacizumab was inconclusive.<sup>19</sup>

Likewise, the IVAN study found that ranibizumab and bevacizumab have similar efficacy. However, these investigators found that reduction in the frequency of retreatment resulted in a small loss of efficacy, irrespective of the drug.<sup>20</sup> The CATT study also found that the proportion of patients with serious systemic adverse events, primarily hospitalizations, was higher with bevacizumab than with ranibizumab treatment.

### **Lesson 9: GA and Monthly vs. PRN Treatments**

Geographic atrophy (GA) has been shown to be more common with



monthly treatment than with PRN regimens in retrospective analyses of the CATT and IVAN studies. Approximately 20 percent of patients in the CATT trial developed GA within two years of treatment. Independent baseline risk factors included poor vision, retinal angiomatous proliferation, foveal intraretinal fluid and monthly dosing.<sup>21</sup> In the IVAN trial, the percentage of participants with new GA was no different between drug groups, but it was significantly lower in the arms that received PRN injections.<sup>20</sup>

However, this is a subject of ongoing debate, as this association has not been replicated in other trials. Further studies, such as RIVAL, which will assess the development of GA with either ranibizumab or aflibercept treatment, will enhance our understanding of this problem.

## Lesson 10: What the Long-term Data Tell Us

In long-term follow-up studies, nAMD patients remain at risk for substantial visual decline. SEVEN-UP is a follow-up study that reviewed 65 patients who received ranibizumab treatment from the MARINA and ANCHOR studies over a mean of 7.4 years. Of the study eyes, 37 percent had 20/70 vision or better and 37 percent had 20/200 vision or worse, which was a substantial decline compared to the initial two-year MARINA and ANCHOR study results.<sup>22</sup>

Although vision gain was largely sustained in the VIEW1 Extension Study, which followed 323 patients from the original VIEW1 study over four years, on average vision loss of 3 letters occurred at four years.<sup>26</sup> Active disease was still present in 68 percent of study eyes and 46 percent

were receiving ongoing anti-VEGF treatments.

Likewise, the five-year results of the CATT study found that the vision gains made in the first two years were not maintained at five years. However, 50 percent of eyes had VA of 20/40 or better, confirming anti-VEGF therapy as a major long-term therapeutic advance for nAMD.<sup>23</sup>

Although anti-VEGF therapy is not a cure for patients with nAMD, it has set a high standard for their care. Many treatment regimens exist, and the ideal regimen should be patient-specific. We hope that these 10 lessons shed light on our decision to adopt a treat-and-extend strategy, and that the final results of future landmark studies, such as the CANTREAT, LUMINOUS and RIVAL trials, will continue to guide our clinical practice. **RS**

*Dr. Mandelcorn is an assistant professor of ophthalmology at the University of Toronto. Dr. Yap is a vitreoretinal fellow and Dr. Yan a vitreoretinal surgeon at the University of Toronto.*

## REFERENCES

1. No authors listed. Argon laser photocoagulation for senile macular degeneration. Results of a randomized clinical trial. *Arch Ophthalmol.* 1982;100:912-918.
2. No authors listed. Recurrent choroidal neovascularization after argon laser photocoagulation for neovascular maculopathy. Macular Photocoagulation Study Group. *Arch Ophthalmol.* 1986;104:503-512.
3. No authors listed. Photodynamic therapy of subfoveal choroidal neovascularization in age-related macular degeneration with verteporfin: one-year results of 2 randomized clinical trials—TAP report. Treatment of age-related macular degeneration with photodynamic therapy (TAP) Study Group. *Arch Ophthalmol.* 1999;117:1329-1345.
4. Verteporfin in Photodynamic Therapy Study Group. Photodynamic therapy of subfoveal choroidal neovascularization in pathologic myopia with verteporfin. 1-year results of a randomized clinical trial—VIP report no. 1. *Ophthalmology.* 2001;108:841-852.
5. Wormald R, Evans J, Smeeth L, Henshaw K. Photodynamic therapy for neovascular age-related macular degeneration. *Cochrane Database Syst Rev.* 2007;CD002030.
6. Brown DM, Kaiser PK, Michels M, et al. Ranibizumab versus

- verteporfin for neovascular age-related macular degeneration. *N Engl J Med.* 2006;355:1432-1444.
7. Rosenfeld PJ, Brown DM, Heier JS, et al. Ranibizumab for neovascular age-related macular degeneration. *N Engl J Med.* 2006;355:1419-1431.
8. Fintak DR, Shah GK, Blinder KJ, et al. Incidence of endophthalmitis related to intravitreal injection of bevacizumab and ranibizumab. *Retina.* 2008;28:1395-9.
9. Mitchell P, Korobelnik JF, Lanzetta P, et al. Ranibizumab (Lucentis) in neovascular age-related macular degeneration: evidence from clinical trials. *Br J Ophthalmol.* 2010;94:2-13.
10. Regillo CD, Brown DM, Abraham P, et al. Randomized, double-masked, sham-controlled trial of ranibizumab for neovascular age-related macular degeneration: PIER Study year 1. *Am J Ophthalmol.* 2008;145:239-248.
11. Fung AE, Lalwani GA, Rosenfeld PJ, et al. An optical coherence tomography-guided, variable dosing regimen with intravitreal ranibizumab (Lucentis) for neovascular age-related macular degeneration. *Am J Ophthalmol.* 2007;143:566-583.
12. Holz FG, Amoaku W, Donate J, et al. Safety and efficacy of a flexible dosing regimen of ranibizumab in neovascular age-related macular degeneration: the SUSTAIN study. *Ophthalmology.* 2011;118:663-671.
13. Lim JH, Wickremasinghe SS, Xie J, et al. Delay to treatment and visual outcomes in patients treated with anti-vascular endothelial growth factor for age-related macular degeneration. *Am J Ophthalmol.* 2012;153:678-686, 86 e1-2.
14. Rasmussen A, Brandt S, Fuchs J, et al. Visual outcomes in relation to time to treatment in neovascular age-related macular degeneration. *Acta Ophthalmol.* 2015;93:616-620.
15. Brand C. One-year outcomes with ranibizumab in treatment naive patients with neovascular age-related macular degeneration. An interim analysis from the LUMINOUS study. Presented at: ARVO; May 1-5, 2016; Seattle, Washington.
16. Wykoff CC, Croft DE, Brown DM, et al. Prospective trial of treat-and-extend versus monthly dosing for neovascular age-related macular degeneration: TREX-AMD 1-year results. *Ophthalmology.* 2015;122:2514-2522.
17. Berg K, Pedersen TR, Sandvik L, Bragadottir R. Comparison of ranibizumab and bevacizumab for neovascular age-related macular degeneration according to LUCAS treat-and-extend protocol. *Ophthalmology.* 2015;122:146-152.
18. Kertes P. Canadian treat and extend analysis trial with ranibizumab in patients with neovascular AMD: Interim analysis of the CANTREAT study. Presented at: EURETINA; September 7-10, 2017; Barcelona, Spain.
19. Group CR, Martin DF, Maguire MG, et al. Ranibizumab and bevacizumab for neovascular age-related macular degeneration. *N Engl J Med.* 2011;364:1897-1908.
20. Chakravarthy U, Harding SP, Rogers CA, et al. Alternative treatments to inhibit VEGF in age-related choroidal neovascularisation: 2-year findings of the IVAN randomised controlled trial. *Lancet.* 2013;382:1258-1267.
21. Grunwald JE, Daniel E, Huang J, et al. Risk of geographic atrophy in the comparison of age-related macular degeneration treatments trials. *Ophthalmology.* 2014;121:150-161.
22. Comparison of Age-Related Macular Degeneration Treatments Trials (CATT) Research Group, Maguire MG, Martin DF, Ying GS, et al. Five-year outcomes with anti-vascular endothelial growth factor treatment of neovascular age-related macular degeneration: The Comparison of Age-Related Macular Degeneration Treatments Trials. *Ophthalmology.* 2016;123:1751-1761.
23. Rofagha S, Bhisitkul RB, Boyer DS, Sadda SR, Zhang K; SEVEN-UP Study Group. Seven-year outcomes in ranibizumab-treated patients in ANCHOR, MARINA, and HORIZON: a multicenter cohort study (SEVEN-UP). *Ophthalmology.* 2013;120:2292-2299.



# Getting Too Close to the Sun

*This patient learned firsthand about the dangers of viewing the solar eclipse.*

**By Shu Feng, MD, and Steven S. Saraf, MD**

**A** 19-year-old male college student with no medical history presented for evaluation of a “blind spot” in the right eye of two weeks duration following the August 21, 2017, solar eclipse. The patient reported that he intermittently looked at the eclipse without eye protection for a total of 2.5 minutes, taking breaks to look away every 10 to 15 seconds.

He noticed the scotoma just nasal to fixation in the right eye starting about one hour after the eclipse. He noted no progressive enlargement of the scotoma or new scotomas in the subsequent days and found that the “blind spot” had grown less noticeable over time. His ocular history was unremarkable.

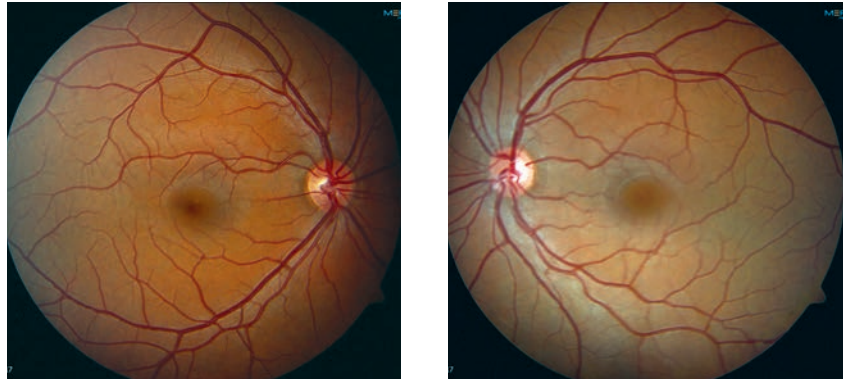
## Examination Findings

Best-corrected visual acuity was 20/20 in both eyes and intraocular pressures were normal. No afferent pupillary defect was detected. Visual fields were full upon confrontation bilaterally. However, on Amsler grid testing he localized a small area of metamorphopsia just nasal to fixation in the right eye.

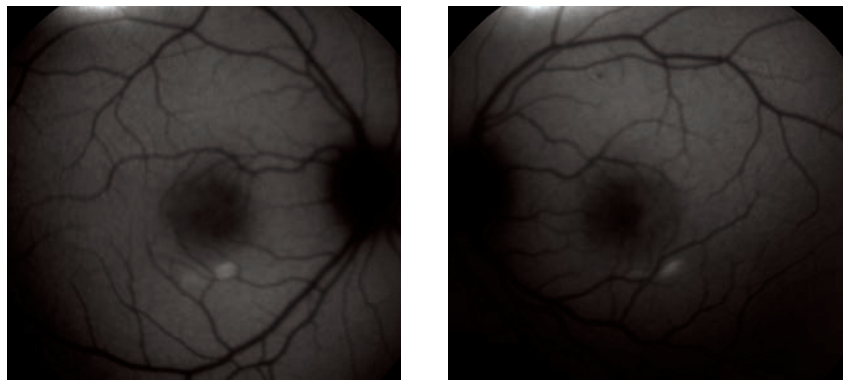
The anterior segment exam was normal in both eyes. Fundus examination was unremarkable in both eyes with no corresponding macular findings in the right eye to explain his symptoms (*Figure 1*).

## Workup

Fundus autofluorescence (FAF) was normal in both eyes (*Figure 2*). Spectral-domain optical coherence tomography (SD-OCT) of the right eye showed normal foveal contour with a focal area of subfoveal ellipsoid



**Figure 1.** Color fundus photography was normal in both eyes.



**Figure 2.** Fundus autofluorescence was normal in both eyes, although in some cases of solar retinopathy FAF can show hypoautofluorescent fovea with a faint irregular ring of hyperautofluorescence.

zone loss measuring approximately 150  $\mu\text{m}$  (*Figure 3A*). SD-OCT of the left eye was normal (*Figure 3B*). The RPE was intact in both eyes.

Swept-source OCT *en-face* images of the outer retinal layers showed disruption of the fovea and an outer perifoveolar ring of disruption in the right eye (*Figure 3C*), and less-prominent disruption of the perifoveolar macula in the left eye (*Figure 3D*).

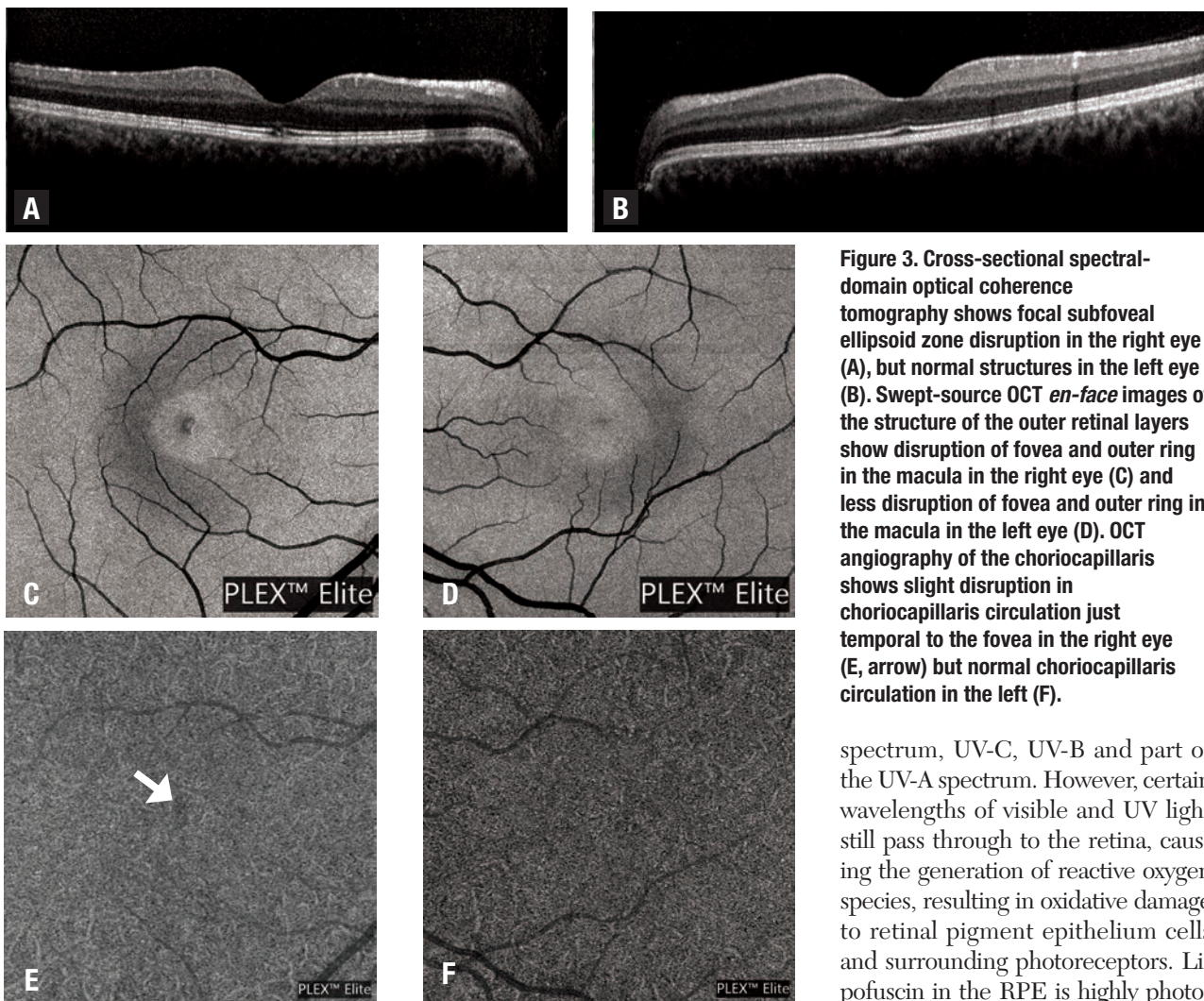
SS-OCT angiography of the right eye showed focal irregularity of the choriocapillaris circulation corresponding with the areas of overlying outer retinal loss (*Figure 3E*). SS-

OCT-A of the left eye showed normal choriocapillaris circulation that appeared asymmetric compared to the affected right eye (*Figure 3F*).

## Diagnosis and Management

Based on this patient’s history of viewing the eclipse without eye protection and the focal subfoveal ellipsoid zone loss, our diagnosis was solar retinopathy. No evidence-based therapy is available for treatment of solar retinopathy, but we advised the patient to start on AREDS2 vitamins and arranged for follow-up in one month.





**Figure 3.** Cross-sectional spectral-domain optical coherence tomography shows focal subfoveal ellipsoid zone disruption in the right eye (A), but normal structures in the left eye (B). Swept-source OCT *en-face* images of the structure of the outer retinal layers show disruption of fovea and outer ring in the macula in the right eye (C) and less disruption of fovea and outer ring in the macula in the left eye (D). OCT angiography of the choriocapillaris shows slight disruption in choriocapillaris circulation just temporal to the fovea in the right eye (E, arrow) but normal choriocapillaris circulation in the left (F).

## Discussion

Solar retinopathy is retinal insult caused by photo-oxidative damage from unprotected exposure to the sun. It can also occur in the context of prolonged exposure to an operating microscope, arc welding or lasers. It occurs more commonly in younger patients who have a clear crystalline lens that allows higher transmission of UV-B light,<sup>1</sup> and more commonly in men than woman.

Symptoms typically include blurred vision with a central or paracentral

scotoma, sometimes with chromatopsia, metamorphopsia, photophobia and headache. Typically both eyes are affected, but the condition can be asymmetric. Visual acuity at presentation typically ranges from 20/20 to 20/60, but has been reported to be as poor as 20/200.<sup>2</sup> As little as one-minute fixation on the sun can cause solar retinopathy, though increased intensity and duration of exposure can lead to more severe pathology.<sup>3</sup>

The cornea, anterior chamber, and adult lens absorb light in the visible

spectrum, UV-C, UV-B and part of the UV-A spectrum. However, certain wavelengths of visible and UV light still pass through to the retina, causing the generation of reactive oxygen species, resulting in oxidative damage to retinal pigment epithelium cells and surrounding photoreceptors. Lipofuscin in the RPE is highly photo-reactive, and shorter wavelength light causes induction of reactive oxygen species in lipofuscin that in turn causes subsequent damage to the RPE.<sup>3</sup> With injury to the supportive RPE layer, photoreceptor segments may also undergo secondary damage.

Fundus examination may appear normal; however, classically described changes include a yellowish-white foveal spot with surrounding dark granular pigmentation occurring one to three days post-injury.<sup>3</sup> This can evolve into a well-circumscribed red spot after 10 to 14 days. Transient

macular edema can also occur. In the chronic phase, the macular lesion may take on a yellowish color with irregular borders of RPE mottling.<sup>4</sup>

The most sensitive diagnostic imaging technique is OCT, which typically exhibits reduced reflectivity from the RPE with disruption of the inner and outer photoreceptor segments.<sup>3,4</sup> OCT structural changes are not consistent among cases, but acute changes predominantly include disruption of the RPE and outer photoreceptor segments.<sup>2</sup> Acute changes may resolve, but patients with chronic vision loss often have OCT findings of inner and outer photoreceptor segment damage, demonstrating permanent disruption of photoreceptors.<sup>2</sup>

FAF can show a hypoautofluorescent fovea with a faint irregular ring of hyperautofluorescence.<sup>5</sup> Hypoautofluorescence is due to a deficiency of lipofuscin from loss of RPE and photoreceptors. Fluorescein angiography may show punctate window defects or parafoveal leaks correlating with damage to the RPE and photoreceptors, but is frequently within normal limits.<sup>4,6</sup> OCT angiography can detect subtle microvascular abnormalities and provide extensive detail of retinal vasculature. There is no published work regarding OCT-A in patients with solar retinopathy, but it may be helpful in future studies of this disease.<sup>3</sup>

Decreased visual acuity in solar retinopathy is often self-resolving, and prognosis is correlated with initial visual acuity and photoreceptor damage on OCT.<sup>3,7</sup> A study from Nepal found that more than 80 percent of 319 patients with solar retinopathy had final visual acuity of 20/40 or better.<sup>8</sup> In a case series of 36 patients with solar retinopathy from a 1995


solar eclipse in Pakistan, 72 percent of patients had full recovery of vision and another 19 percent had partial recovery, with maximum recovery occurring between two weeks and six months.<sup>9</sup>

Another case series showed most patients recovered vision within two to four weeks, and pre-exposure acuity of 20/50 or better had earlier and more favorable visual recovery.<sup>10</sup> However, there are patients from all of these studies that experienced persistent central or paracentral scotomas,<sup>8-10</sup> and patients experienced no further improvement in visual acuity after six to 18 months.<sup>9,10</sup>

No evidence-based treatment of solar retinopathy is available. Steroids have been proposed as treatment for acute solar retinopathy because of their anti-inflammatory effects and for treatment of associated macular edema. However, the macular edema associated with solar retinopathy has been shown to improve on its own and prognosis is variable with steroid administration. The use of steroids also places the patient at risk for other complications, such as cataract formation, intraocular pressure elevation or central serous chorioretinopathy.<sup>3</sup>

Because the mechanism of damage in solar retinopathy is thought to be free radicals, antioxidants have also been proposed to protect against UV damage from solar retinopathy. In the Age Related Eye Disease Study, antioxidant vitamins were shown to reduce the risk of progression of age-related macular degeneration,<sup>11</sup> but there is no certainty regarding whether administration of antioxidants after UV exposure could aid visual recovery in cases of solar retinopathy.

Because no proven therapies for

solar retinopathy exist, the retina specialist has a responsibility to participate in preventative care and patient education. Community outreach at times of significant events such as a solar eclipse is important in educating patients regarding safe viewing practices. 

## References

1. Mainster MA, Turner PL. Ultraviolet-B phototoxicity and hypothetical photomelanomagenesis: Intraocular and crystalline lens photoprotection. *Am J Ophthalmol*. 2010;149:543-549.
2. Chen KC, Jung JJ, Aizman A. High definition spectral domain optical coherence tomography findings in three patients with solar retinopathy and review of the literature. *Open Ophthalmol J*. 2012;6:29. <https://www.ncbi.nlm.nih.gov/offcampus.lib.washington.edu/pmc/articles/PMC3394112/>. Accessed September 28, 2017.
3. Begaj T, Schaal S. Sunlight and ultraviolet radiation-pertinent retinal implications and current management. *Surv Ophthalmol*. 2017 September 18. Epub ahead of print.
4. Jain A, Desai RU, Charalel RA, Quiram P, Yannuzzi L, Sarraf D. Solar retinopathy: Comparison of optical coherence tomography (OCT) and fluorescein angiography (FA). *Retina*. 2009;29:1340-1345.
5. Brùè C, Mariotti C, Franco ED, Fisher Y, Guidotti JM, Giovannini A. Solar retinopathy: A multimodal analysis. *Case Rep Ophthalmol Med*. 2013;2013:906920 Epub 2013 February 12.
6. Dhir SP, Gupta A, Jain IS. Eclipse retinopathy. *Br J Ophthalmol*. 1981;65:42-45.
7. Klemencic S, McMahon J, Upadhyay S, Messner L. Spectral domain optical coherence tomography as a predictor of visual function in chronic solar maculopathy. *Optom Vis Sci*. 2011;88:1014-1019.
8. Rai N, Thuladar L, Brandt F, Arden GB, Berminger TA. Solar retinopathy. A study from Nepal and from Germany. *Doc Ophthalmol*. 1998;95:99-108.
9. Awan AA, Khan T, Mohammad S, Arif AS. Eclipse retinopathy: Follow up of 36 cases after April 1995 solar eclipse in Pakistan. *J Ayub Med Coll Abbottabad*. 2002;14:8-10.
10. MacFaul PA. Visual prognosis after solar retinopathy. *Br J Ophthalmol*. 1969;53:534-541.
11. Lutein + zeaxanthin and omega-3 fatty acids for age-related macular degeneration: The Age-Related Eye Disease Study 2 (AREDS2) randomized clinical trial. *JAMA*. 2013;309:2005-2015.

**UW Medicine**  
**EYE INSTITUTE**


*Dr. Olmos de Koo is an associate professor of ophthalmology and director of the retina fellowship program at the University of Washington in Seattle, where Dr. Feng is a second-year ophthalmology resident and Dr. Saraf is a retina fellow.*



A PUBLICATION BY **REVIEW**  
of Ophthalmology

# RETINA SPECIALIST

Retina Specialist focuses on the latest advances in the diagnosis, medical management and surgical treatment of diseases of the retina, along with practical, real-world advice from leading clinicians and other experts on managing the successful retina practice.



The new addition to the *Review* family serves the entire Retina Specialist marketplace.

Look for your issues in 2017:

» **MARCH**

» **JUNE**

» **SEPTEMBER**

» **NOVEMBER**

For inquiries contact

**RETINASPECIALIST@JOBSON.COM**

**Advertising opportunities**

**JIM HENNE • PUBLISHER • 610-492-1017 • JHENNE@JOBSON.COM**

**MICHELE BARRETT • 215-519-1414 • MBARRETT@JOBSON.COM**

**MICHAEL HOSTER • 610-492-1028 • MHOSTER@JOBSON.COM**

[www.retina-specialist.com](http://www.retina-specialist.com)



# Draining Choroidal Detachments

*A look at cut-down and cannula-based approaches to achieve external drainage of hemorrhage. With Michael N. Cohen, MD, and Chirag P. Shah, MD, MPH*

**H**emorrhagic choroidal detachment is a rare and sight-threatening complication. Vitreoretinal specialists should feel comfortable managing this complex situation with external drainage.

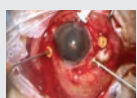
## Timing and Planning

Delaying surgery up to two weeks can allow liquefaction of a clot to improve surgical clearance. With “kissing” choroidals or uncontrolled intraocular pressure, one may wish to intervene sooner. Preoperative B-scan ultrasonography may help identify liquefaction and localize the largest choroidals as optimal quadrants for drainage (*Figure A*).

## Anterior Chamber Infusion

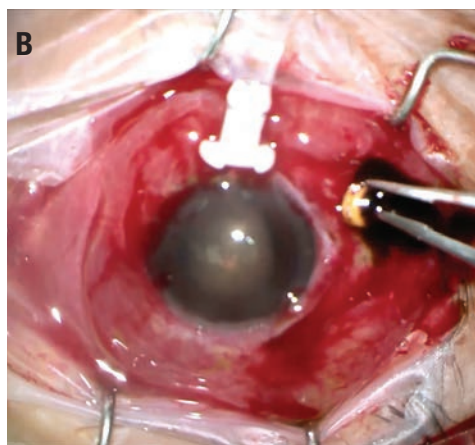
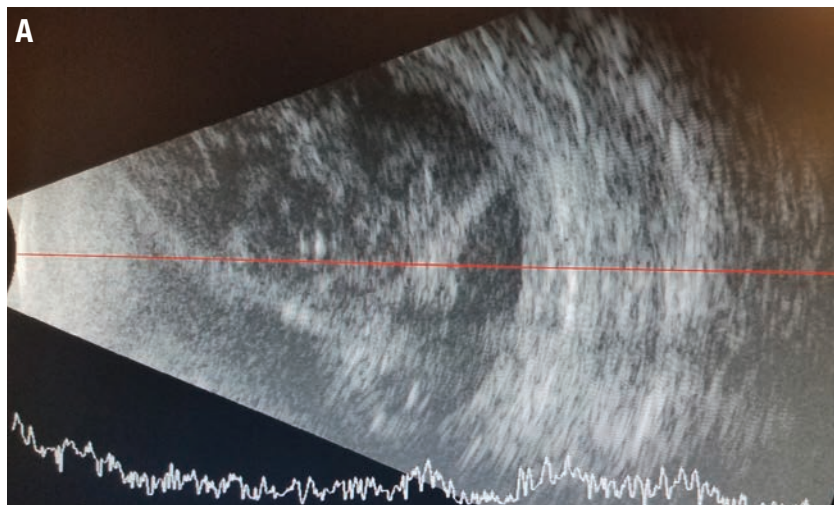
Successful drainage requires IOP control. The view posteriorly is often compromised, and an anterior chamber maintainer, or a vitrectomy cannula attached to an infusion line as an elegant and readily available alternative, should be placed to avoid misplacement of the posterior trocar, which can pierce the retina or infuse into the choroidal space. Deepening a shallow anterior chamber with viscoelastic is helpful to facilitate safe anterior chamber insertion. Transient IOP elevation (for example, to 60 mmHg) facilitates drainage of hemorrhage.

### View the Video



Drs. Cohen and Shah demonstrate the cut-down and cannula-based techniques for draining hemorrhagic choroidal detachments.

Available at: [http://bit.ly/RS\\_VideoPearl\\_004](http://bit.ly/RS_VideoPearl_004).



**Figure. B-scan demonstrates large, partially liquefied hemorrhagic choroidal detachment (A). Choroidal drainage utilizes a 23-gauge cannula and anterior chamber maintainer (B).**

## Scleral Cut-Down Vs. Trocar Insertion

The video demonstrates how surgeons can employ various techniques to facilitate drainage. Scleral cut-down involves a targeted conjunctival peritomy to expose bare sclera over the previously identified drainage quadrants. After achieving episcleral hemostasis with cautery, use a crescent blade to create a radial cut-down near the equator or a circumferential cut-down 4 mm posterior to the lim-

bus. The latter approach may provide better exposure and can be converted into a full-thickness sclerotomy if a concomitant vitrectomy is planned.

When the suprachoroidal space is accessed, a gush of dark red liquefied heme will typically appear. Detachment of the choroid protects against full-thickness penetration into the vitreous cavity. Consider inserting a cyclodialysis spatula into the suprachoroidal space to keep the cut-down open for egress of the hemorrhage and to clear clots that obstruct flow. Focal pressure applied to the anterior lip of the wound and/or ocular massage can help maximize drainage.

As an alternative to a cut-down, one can insert a 23- or 25-gauge cannula. An angled-20° approach has been  
*(Continued on page 27)*



Series: Beyond the Retina

# MANAGING APHAKIA Without Capsular Support

*Retropupillary implantation of the iris-claw IOL  
is one tool in the cataract surgeon's kit.*

By Clarissa S.M. Cheng, FRCOphth, Omar Abu Al Ghanam, MBBSc, and  
Felipe Dhawahir-Scala, FRCS (Ed), FRCOphth, LMS

The management of aphakia without capsular support is a subject of frequent debate. While authors have described many techniques, they've reached no consensus on the ideal method. For our cataract-surgery colleagues, the challenge of implanting an intraocular lens in an eye without capsular support lies in finding a technique that is not only easy and quick to perform, but has long-term stability and low complication rates.

Common intraocular lens designs include open-loop anterior chamber IOLs (AC-IOL), iris clipped, sutured IOLs and scleral-haptic fixated IOLs. Clipping of lenses on the iris using an iris-claw IOL is a well-established technique in the treatment of aphakia without capsular support. Jan Worst, MD, first described this technique in 1972, initially implanting the lens into the anterior chamber clipped to the anterior surface of the iris.<sup>1</sup> This technique proved to be safe and effective, and provided predictable clinical re-

sults without direct angle compromise.<sup>2-4</sup> It was also faster to perform compared to iris-sutured or scleral haptic-fixated IOL.

The main concern of implanting the iris-claw IOL in the anterior chamber is endothelial cell loss; studies have reported rates as high as 10.5 to 13.4 percent at three to four years post-implantation of anterior Artisan IOLs (Ophtec),<sup>4-6</sup> particularly in the presence of narrow anterior chambers.<sup>7,8</sup> These lenses have since been implanted retropupillary, clipped to the posterior surface of the iris, a technique that has been shown to have lower risk of endothelial cell loss while providing good and predictable clinical outcomes.<sup>9-11</sup>

Here, the last in the series "Beyond the Retina," we describe our surgical technique for retropupillary implantation of the iris-claw IOL and discuss

the efficacy and safety of the IOL.

## Surgery Planning and Technique

The ideal candidate for an

## ABOUT THE AUTHORS



Dr. Cheng is a clinical vitreoretinal fellow at Manchester Royal Eye Hospital.



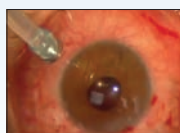
Dr. Abu Al Ghanam is an ophthalmology resident at Manchester Royal Eye Hospital.



Dr. Dhawahir-Scala is a consultant ophthalmic and vitreoretinal surgeon and director of the acute ophthalmic service at Manchester Royal Eye Hospital.

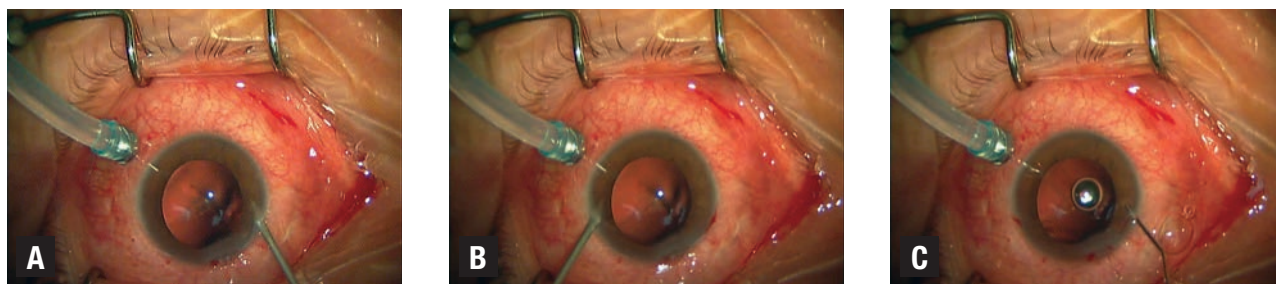**DISCLOSURES:** The authors have no financial disclosures to report.

## View the Video



The authors demonstrate the various steps of implanting the Artisan intraocular

lens in this instructional video. Available at: [http://bit.ly/RS\\_Aphakia\\_005](http://bit.ly/RS_Aphakia_005).



**Figure 1.** This is a patient who underwent insertion of a retropupillary Artisan IOL combined with 27-gauge removal of silicone oil in the left eye. Posterior infusion is used for maintenance of intraocular pressure. The first step involves creating a nontunneled paracentesis at the limbus at 10 o'clock (A). Posterior infusion is kept for maintenance of intraocular pressure. This specific patient had a pre-existing inferior peripheral iridectomy. Then, create a second paracentesis at the limbus at 2 o'clock (B). Inject acetylcholine chloride 1% (Miochol) to achieve miosis of the pupil (C).

Artisan IOL would be a patient with adequate iris stroma, pupil size of  $\leq 5$  mm and central pupil position. Small iris defects that do not preclude stable IOL implantation and corectopia where the optic can cover the pupil are not excluded. Although sufficient iris tissue is required for support, the surgeon may employ suture pupilloplasty if needed to reform the pupil, and the IOL may be placed in any axis desired.<sup>1</sup> Contraindications to implanting an iris-claw IOL would include uveitis and large iris defects.

The Artisan Aphakia IOL is a single-piece biconvex polymethyl methacrylate IOL that is 8.5 mm in length and 1.04 mm in height with a 5.4 mm optical zone width. The manufacturer's recommended A constant for implantation above the iris is 115 for ultrasound biometry or 115.7 for optical biometry. For retropupillary implantation, we use an A constant of 116.8 for ultrasound biometry or

116.9 for optical biometry

### Preferred Surgical Technique

The following describes the surgeon's preferred surgical technique:

- Introduce the anterior chamber maintainer through an inferotemporal limbal corneal incision to maintain intraocular pressure
- Create two nontunneled paracentesis incisions at the 2 and 10 o'clock positions (*Figures 1A and B*) and inject acetylcholine chloride 1% (Miochol) to achieve miosis (*Figure 1C*).
- Inject a cohesive ophthalmic viscosurgical device (OVD) (*Figure 2A*) into the anterior chamber and create a superior 5.5-mm limbal corneal incision at 12 o'clock (*Figure 2B*) or in the desired axis. Perform a superior iridotomy.
- Flip the Artisan iris-claw IOL upside-down outside of the eye and introduce it into the anterior chamber through the superior corneal wound using the DO2-70/72/74 Artisan Implantation Forceps (Ophtec) (*Figure 3A*).
- Once in the eye, center the Artisan IOL over the pupil and rotate it until the haptic slots are in the desired position. This is usually the mid-peripheral iris at

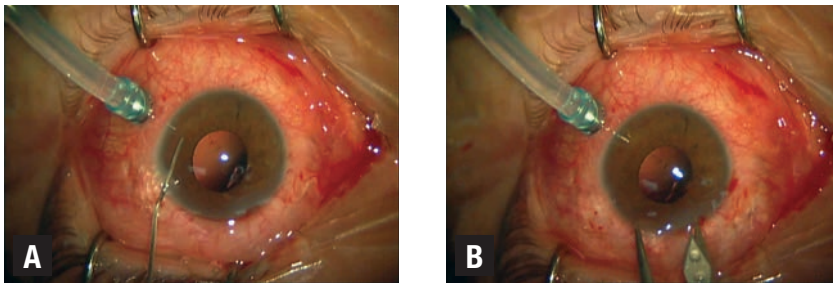
3 o'clock and 9 o'clock, but it can be adjusted to avoid areas of iris thinning (*Figure 3B*).

- Once the Artisan IOL is in the desired position, gently slide it behind the iris one haptic at a time. To facilitate enclavation, tilt the IOL so the haptic on the side of the nondominant hand is pressed upward against the iris, creating an imprint against the iris and thus facilitating location of the haptic slot.
- Using the nondominant hand, insert a iris hook through the paracentesis on the same side and push sufficient mid-peripheral iris tissue into the slot of the haptic (*Figure 4A*, page 20). Swap hands and repeat this step on the other side (*Figure 4B*). Take care not to distort the iris while sliding the second haptic posteriorly to avoid disenclavation of the first haptic, to promote central positioning of the optic and maintain a round pupil.
- Close the corneal incisions with interrupted 10-0 vicryl sutures (*Figure 5*, page 20). Flush the OVD in the anterior chamber with balanced salt solution and hydrate the paracentesis wounds to ensure a watertight seal. Should a simultaneous vitrecto-

### Take-home Point

This article reports on the authors' experience with retropupillary iris-fixed intraocular lenses. They describe it as an effective and safe technique with a relatively short learning curve and ease of implantation. It is a viable treatment option for patients with aphakia without capsular support.





**Figure 2.** Inject a cohesive ophthalmic viscosurgical device to deepen the anterior chamber and protect the corneal endothelium during Artisan IOL insertion (A). Create a superior corneal incision with a keratome, using calipers to measure 5.5 mm (B).

my be required, our preference is a 27-gauge vitrectomy for its superior wound closure and lower conjunctival scarring. For infection prophylaxis in the absence of contraindications, intracameral cefuroxime 1 mg in 0.1 ml can be injected at the end of surgery together with a subconjunctival injection of dexamethasone (4 mg/ml of 0.4 ml) and the patient is prescribed topical chloramphenicol 0.5% QID for two weeks, topical prednisolone 1% Q2H for two weeks then QID for four weeks, and topical bromfenac BID for six weeks.

### Options for IOL Fixation

With the advances in surgical devices, IOL models and suture materials, surgeons are now presented multiple options to tackle aphakia without adequate capsule support. Implantation of an AC-IOL is a quick and easy option; however, its use in younger patients is less preferred due to the considerable risks of angle damage and endothelial cell loss compared to iris- or scleral-haptic-fixed IOLs.<sup>12</sup>

Scleral-haptic fixation of IOLs can be performed with or without sutures and is most commonly approached *ab externo* through the ciliary sulcus or pars plana using the corneal limbus as an external landmark.<sup>13,14</sup> This requires IOLs with suture eyelets to allow stable anchoring of sutures to

the IOL. These include the Akreos Adapt (Bausch + Lomb), CZ 70 BD (Alcon) and enVista MX60 (B+L) IOLs. Preferred sutures are polypropylene or Gore-tex. Scleral-haptic fixation is accomplished by threading sutures through the haptic eyelets and then insertion of the IOL into the posterior chamber.

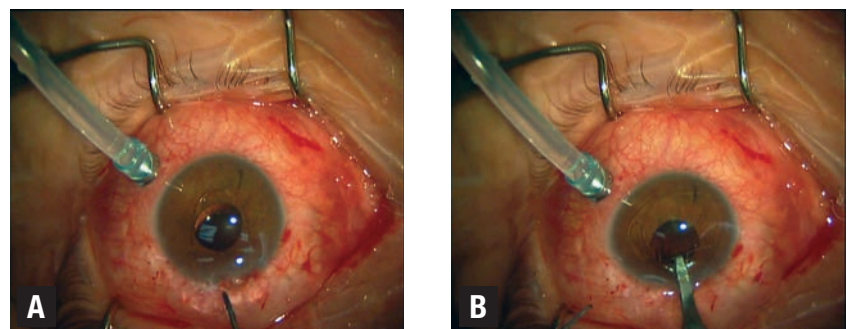
The sutures are then externalized through the sclera 2 to 3 mm from the limbus using a 27-gauge needle to dock the needle, or using intraocular forceps to grasp the suture through the pars plana cannula. Timothy Olsen, MD, and Jonathan Pribila, MD, at Emory Eye Center in Atlanta described a novel technique of passing sutures *ab interno* using intraocular endoscopy to locate the ciliary sulcus under direct visualization.<sup>15</sup>

Fixation of sutureless scleral haptics involves externalizing IOL haptics for fixation within the sclera. Sutureless scleral-haptic fixation is compatible with multiple three-piece IOLs; it does not require specialized haptics-containing suture eyelets.

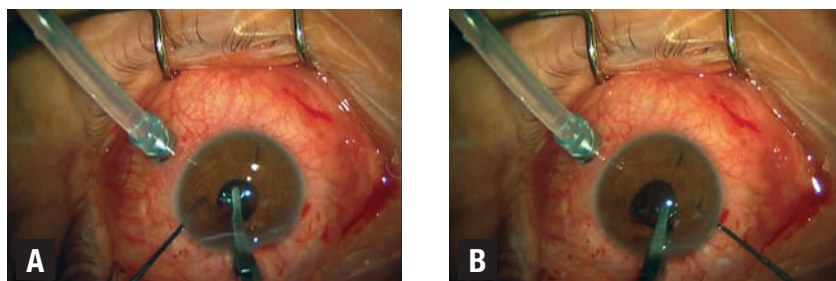
Once the IOL is inserted into the posterior chamber, haptic retrieval is done using 27-gauge needle to dock the needle in a “handshake” technique and the externalized haptics can be tucked under scleral flaps or scleral tunnels.<sup>16–18</sup> Authors have also described modified techniques employing the use of fibrin glue or thermal cautery to create a flanged haptic.<sup>16,19,20</sup>

The options for iris fixation of IOLs include sutured or clipped. Suturing of the IOL onto the iris involves the use of a three-piece posterior chamber lens that can be injected through a 3- to 3.5-mm corneal incision; a Siesper sliding knot with 10-0 polypropylene secures the haptics to the peripheral iris. Compared to scleral fixation of IOLs, iris suturing has the advantage of no externalized sutures, hence reduced risk of endophthalmitis, and it preserves the conjunctiva, which is of importance in glaucoma patients.

(Continued on page 20)



**Figure 3.** After flipping the Artisan intraocular lens outside the eye, insert it into the anterior chamber centered over the pupil (A), and rotate it so that the haptics are at 3 and 9 o'clock (B). The D02-70/72/74 Artisan Implantation Forceps hold the IOL stable. This patient did not have a superior iridectomy as he had a pre-existing inferior iridectomy.

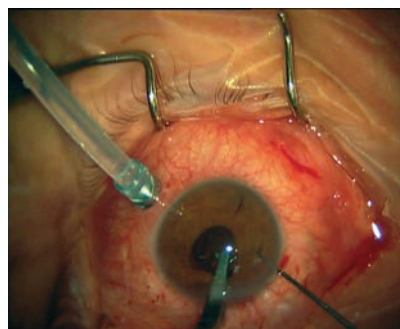


**Figure 4.** Once the desired position is achieved, gently slide one haptic behind the iris and tilt it upwards against the iris, creating an imprint on the iris to facilitate the location of the haptic slot. Insert the iris hook through the paracentesis on the same side and use it to push sufficient mid-peripheral iris tissue into the slot of the haptic (A). Repeat the previous steps with the other haptic (B).

### Safer and Faster


In our opinion, once one acquires sufficient experience, either anterior or posterior chamber iris-claw IOL implantation is safer and faster compared to the other techniques. The disadvantages of the iris-claw IOL technique are, when compared to iris-sutured techniques, induced astigmatism secondary to the larger corneal incision wound of 5.5 mm, and, when compared to scleral fixated or sutured IOL techniques, its contraindication in uveitis patients. Reported complications include disenclavation of the haptics from the iris, cystoid macular edema, glaucoma, hyphema and iritis.<sup>9,21</sup>

A study of 320 eyes with retropupillary iris-fixated Artisan IOL evaluated its long-term stability and reported



**Figure 5.** Close the main corneal wound with interrupted 10-0 vicryl sutures after removal of OVD.

over an average of 5.3 years three (0.9 percent) cases of disenclavation with one complete posterior dislocation, one (0.3 percent) retinal detachment and three (0.9 percent) cases of CME.<sup>9</sup> The investigators reported no cases of iritis or postoperative elevated intraocular pressure and no statistically significant change in endothelial cell density at the study end.

Another study of 137 eyes reported higher rates of complications with a mean follow-up of five months. These researchers found CME occurring in 12 eyes (8.7 percent), endophthalmitis in one (0.7 percent), hyphema in three (2.1 percent), chronic uveitis requiring IOL removal in one (0.7 percent) and disenclavation in 12 (8.7 percent).<sup>21</sup> However, such rates are still comparatively lower than with the transscleral-sutured IOL, in which CME has been reported to occur in 5.8 percent to 33 percent of cases,<sup>22,23</sup> retinal detachment in 6.3 percent to 8.2 percent, IOL dislocation in 6.3 percent and suture breakage in up to 27.9 percent of cases.<sup>24,25</sup> 

### REFERENCES

1. Worst JGF, Massaro RG, Ludwig HHH. The introduction of an artificial lens into the eye using Binkhorst's technique. *Ophthalmologica*. 1972;164:387-391.
2. Sawada T, Kimura W, Kimura T, et al. Long-term follow-up of primary anterior chamber intraocular lens implantation. *J Cataract Refract Surg*. 1998;24:1515-1520.
3. Chen Y, Liu Q, Xue C, Huang Z, Chen Y. Three-year follow-up of secondary anterior iris fixation of an aphakic intraocular lens to

- correct aphakia. *J Cataract Refract Surg*. 2012;38:1595-1601.
4. Güell JL, Velasco F, Maleceza F, Vázquez M, Gris O, Manero F. Secondary Artisan-Versise aphakic lens implantation. *J Cataract Refract Surg*. 2005;31:2266-2271.
5. Menezo JL, Cisneros AL, Rodríguez-Salvador V. Endothelial study of iris-claw phakic lens: four year follow-up. *J Cataract Refract Surg*. 1998;24:1039-1049.
6. Koss MJ, Kohnen T. Intraocular architecture of secondary implanted anterior chamber iris-claw lenses in aphakic eyes evaluated with anterior segment optical coherence tomography. *Br J Ophthalmol*. 2009;93:1301-1306.
7. Saxena R, Boekhoorn SS, Mulder PG, Noordzij B, van Rij G, Luyten GP. Long-term follow-up of endothelial cell change after Artisan phakic intraocular lens implantation. *Ophthalmology*. 2008;115:608-613.
8. Shajari M, Scheffel M, Koss MJ, Kohnen T. Dependency of endothelial cell loss on anterior chamber depth within first 4 years after implantation of iris-supported phakic intraocular lenses to treat high myopia. *J Cataract Refract Surg*. 2016;42:1562-1569.
9. Forlini M, Soliman W, Bratu A, Rossini P, Cavallini GM, Fortini C. Long-term follow-up of retropupillary iris-claw intraocular lens implantation: a retrospective analysis. *BMC Ophthalmol*. 2015;15:143.
10. Gicquel J-J, Guigou S, Bejjani RA, Briat B, Ellices P, Dighiero P. Ultrasound biomicroscopy study of the Versise aphakic intraocular lens combined with penetrating keratoplasty in pseudophakic bullous keratopathy. *J Cataract Refract Surg*. 2007;33:455-464.
11. Gonnermann J, Amiri S, Klamann M, et al. Endothelial cell loss after retropupillary iris-claw intraocular lens implantation. *Klin Monatsbl Augenheilkd*. 2014;231:784-787.
12. Moschos MM, Nitoda E. The correction of aphakia using anterior chamber intraocular lens in vivo. 2016;30:733-738.
13. Nakashizuka H, Shimada H, Iwasaki Y, Matsumoto Y, Sato Y. Pars plana suture fixation for intraocular lenses dislocated into the vitreous cavity using a closed-eye cow-hitch technique. *J Cataract Refract Surg*. 2004;30:302-306.
14. Teichmann KD. Pars plana fixation of posterior chamber intraocular lenses. *Ophthalmic Surg*. 1994;25:549-553.
15. Olsen TW, Priblitz JT. Pars plana vitrectomy with endoscope-guided sutured posterior chamber intraocular lens implantation in children and adults. *Am J Ophthalmol*. 2011;151:287-296.
16. Agarwal A, Kumar DA, Jacob S, Baid C, Agarwal A, Srinivasan S. Fibrin glue-assisted sutureless posterior chamber intraocular lens implantation in eyes with deficient posterior capsules. *J Cataract Refract Surg*. 2008;34:1433-1438.
17. Rodríguez-Agíretxe I, Acera-Osa A, Ubeda-Erviti M. Needle-guided intrascleral fixation of posterior chamber intraocular lens for aphakia correction. *J Cataract Refract Surg*. 2009;35:2051-2053.
18. Gabor SG, Pavlidis MM. Sutureless intrascleral posterior chamber intraocular lens fixation. *J Cataract Refract Surg*. 2007;33:1851-1854.
19. Prakash G, Agarwal A, Jacob S, Kumar DA, Chaudhary P, Agarwal A. Femtosecond-assisted Descemet stripping automated endothelial keratoplasty with fibrin glue-assisted sutureless posterior chamber lens implantation. *Cornea*. 2010;29:1315-1319.
20. Cervantes LJ. Combined double-needle flanged-haptic intrascleral fixation of an intraocular lens and Descemet-stripping endothelial keratoplasty. *J Cataract Refract Surg*. 2017;43:593-596.
21. Gonnermann J, Klamann MKJ, Maier A-K, et al. Visual outcome and complications after posterior iris-claw aphakic intraocular lens implantation. *J Cataract Refract Surg*. 2012;38:2139-2143.
22. Mittelviehhaus H. A modified technique of transscleral suture fixation of posterior chamber lenses. *Ophthalmic Surg Lasers Imaging Retina*. 1992;23:496-498.
23. Uthoff D, Teichmann KD. Secondary implantation of scleral-fixated intraocular lenses. *J Cataract Refract Surg*. 1998;24:945-950.
24. Vote BJ, Tranos P, Bunce C, Charteris DG, Da Cruz L. Long-term outcome of combined pars plana vitrectomy and scleral fixated sutured posterior chamber intraocular lens implantation. *Am J Ophthalmol*. 2006;141:308-312.
25. Bading G, Hillenkamp J, Sachs HG, Gabel V-P, Framme C. Long-term safety and functional outcome of combined pars plana vitrectomy and scleral-fixated sutured posterior chamber lens implantation. *Am J Ophthalmol*. 2007;144:371-377.



# THE PROMISE OF DEEP LEARNING IN RETINA

*How artificial intelligence is poised to take diagnostic imaging to the next level.*

By William C. Ou and Charles C. Wykoff, MD, PhD

The potential utility of artificial intelligence (AI) in medicine has long been recognized, with an early example being automated interpretation of electrocardiograms.<sup>1</sup> As clinicians rely more on medical imaging, the workload for radiologists has increased, and it is no surprise that various commercial systems have been developed for computer-aided diagnosis (CAD) in areas including mammography, detection of lung nodules on chest computed tomography (CT) and detection of colon polyps on CT colonography.<sup>2</sup>

With the rise of digital fundus photography and optical coherence tomography, retina care has also become increasingly reliant on the diagnostic value of medical imaging. For many clinicians, OCT has become the default diagnostic imaging test for most retinal diseases, while reading-center grading of color fundus photographs remains the preferred method for monitoring disease activity in large clinical trials. CAD has been investigated for a number of retinal diseases including age-related macular degeneration, diabetic retinopathy (DR) and pathologic myopia,<sup>3,4</sup> but no commercial retinal CAD systems are yet available for routine clinical use.

Because of both an aging population and the global diabetes mellitus epidemic, the prevalence of both AMD<sup>5</sup> and DR<sup>6</sup> are set to increase

in the coming decades, as will the workload of retina specialists. Beyond the ophthalmologist's clinic, interest is mounting in photographic screening programs for DR in primary care settings. Universal adoption of such programs in the United States would necessitate interpretation of an estimated 32 million images annually.<sup>7</sup> Improvements in CAD via deep learning may provide a way to approach these new challenges.

## Deep Learning in Retinal Image Analysis

Much of the existing literature on deep learning in computer diagnosis of retinal disease has focused on DR detection in fundus photography. Many authors have applied deep learning to issues that include segmentation, quality assessment or

feature detection, while others have attempted to train AI to detect and classify disease (*Table, page 23*).<sup>8</sup>

Michael Abràmoff, MD, PhD, and colleagues at the University of Iowa demonstrated in 2016 that the addition of deep-learning methods to

### ABOUT THE AUTHORS



Mr. Ou is a medical student at the University of Texas Southwestern Medical School, Dallas.



Dr. Wykoff, chief medical editor of *Retina Specialist*, is director of research at Retina Consultants of Houston and deputy chair of ophthalmology for the Blanton Eye Institute, Houston Methodist Hospital.

DISCLOSURES: Mr. Ou and Dr. Wykoff have no relevant financial disclosures.

an existing DR detection algorithm resulted in greatly improved performance for detection of referable DR.<sup>9</sup> Shortly thereafter, investigators from Google published a report describing results achieved with a deep-learning algorithm trained by using over 100,000 images to identify referable DR.<sup>10</sup> The algorithm was validated using two independent datasets (EyePACS-1,  $n=9,963$ ; and Messidor-2,  $n=1,748$ ), and the majority opinion of a panel of ophthalmologists as a reference standard. Impressively, at an operating point selected for sensitivity, sensitivity was 97.5 percent and 96.1 percent and specificity was 93.4 percent and 93.9 percent for EYEPAACS-1 and Messidor-2, respectively. This year, Rishab Gargeya, a Davidson Fellows Scholar, joined Theodore Leng, MD, MS, at Byers Eye Institute, Stanford University, to demonstrate that automated detection of DR using deep learning can be extended to include detection of mild DR, in addition to referable DR.<sup>11</sup>

Given promising results in color fundus photography, extension of deep learning techniques to OCT analysis may be a reasonable next step. Some efforts have been undertaken to this end, with applications to both segmentation and disease diagnosis.<sup>12-15</sup> For example, Cecelia Lee, MD, MS, and colleagues at the Uni-

### Take-home Point

Artificial intelligence (AI) has made significant inroads in medicine, particularly with the advent of deep learning. In retina, this has led to advances in automated analysis of digital fundus photography and optical coherence tomography. This article explores the state of deep learning in the diagnosis of retinal disease, some of the challenges facing broader adoption of AI in the field and the possibilities and consequences of deep learning in retina care.

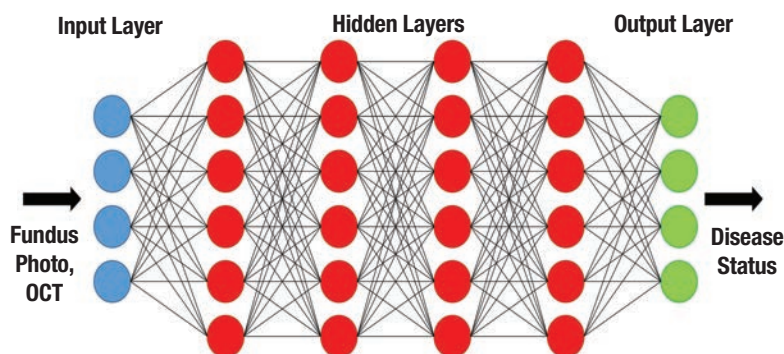


Figure. Simplified schematic of a deep neural network.

### Man vs. Machine: Closing the Gap

The field of artificial intelligence (AI) was born in the summer of 1956 at Dartmouth College, based on the idea that machines could be made to simulate human intelligence. Substantial progress in the field over the decades has naturally given rise to a key question: Is it possible to develop AI that can equal or surpass the capabilities of humans?

For the ancient Chinese game of Go, this ideal was, for many years, considered out of reach. Despite its simple rules, many have described Go as the most complex classical strategy game in history. Indeed, even following the successes of AI in chess, including the famous 1997 defeat of Grandmaster Garry Kasparov by IBM's Deep Blue, Go engines struggled to defeat even moderately skilled players, let alone professionals.<sup>17</sup>

However, this changed in unprecedented fashion in 2016, when Google DeepMind's AlphaGo<sup>18</sup> defeated Lee Sedol, among the world's best Go players, in a highly publicized five-game series. One of the key factors in this groundbreaking achievement was the utilization of a technique known as deep learning.<sup>19</sup>

versity of Washington, Seattle, have demonstrated that deep learning can effectively distinguish between normal OCT images and those from patients with AMD, achieving peak sensitivity and specificity of 93 percent and 94 percent, respectively, when probabilities from images taken of the same patient were averaged.

Notably, images and clinical data and notes the study authors used to determine AMD status were automatically extracted from an electronic medical record (EMR) database, demonstrating another key contributor to the growth of deep learning: the ever-increasing availability of datasets that are sufficiently large enough to train neural networks.

### A Glimpse Ahead

Although considerable work re-

mains to be done with respect to further validating, optimizing and generalizing these algorithms, the overall trend of the data available thus far seems promising. Although still somewhat premature, it is interesting to consider the possibilities and consequences that widespread deployment of deep-learning algorithms in retina care could bring.

In the clinic, assisted or automated interpretation of images could improve the efficiency of image reading and allow physicians more direct face-time with patients. Beyond the clinic, the low cost and high processing capacity of these systems may open doors in areas such as telemedicine, disease screening or monitoring, and even research. In the latter case, for example, deep-learning algorithms could improve objectivity and repro-



ducibility in both prospective and retrospective studies by serving as a universal standard for image grading in situations where centralized reading-center grading is not feasible or accessible.

Yet, deep learning in medicine is not without its own unique challenges. For example, the scale and complexity of deep-learning algorithms makes them a “black box,” while physicians interpret images based on sets of defined features and their relationship with disease, neither physicians nor programmers can know exactly how the algorithms reach their final conclusions. Although this would hardly be the first instance of the medical community adopting a tool whose mechanism is poorly understood, some degree of apprehension toward the potential integration of deep learning is likely inevitable, given its computerized nature.

At the same time, developers of these algorithms are not completely blind to the inner workings of the “black box.” Some groups have generated heat maps that highlight the regions on each image that were the most influential on the decision of the algorithm, providing a much-needed link between man and machine.<sup>11,15</sup> Another potential confounding issue is that of automation bias: a tendency for individuals to agree with the computer’s decision, for better or for worse. It would not be unreasonable to suspect that this effect would be-

come more pronounced as automation reaches parity with (or perhaps even superiority over) humans, but it is clear that additional research on this phenomenon is needed.<sup>16</sup>

Ultimately, although there are still many challenges ahead, AI looks like it is here to stay. The big question now emerging is that of how the health-care system as a whole is going to adapt to the ever-increasing incorporation of this technology. If the transition to EMR is any indication, it could very well become the case that AI integration will eventually transform from a luxury into a necessity. Public trust in the healthcare system is likely to be a crucial factor in this process, and accordingly, physicians and other healthcare providers should prepare to confidently take the lead in facilitating these changes.


## REFERENCES

1. Willems JL, Abreu-Lima C, Arnaud P, et al. The diagnostic performance of computer programs for the interpretation of electrocardiograms. *N Engl J Med.* 1991;325:1767-1773.
2. van Ginneken B, Schaefer-Prokop CM, Prokop M. Computer-aided diagnosis: How to move from the laboratory to the clinic. *Radiology.* 2011;261:719-732.
3. Mookiah MRK, Acharya UR, Chua CK, Lim CM, Ng EYK, Laude A. Computer-aided diagnosis of diabetic retinopathy: A review. *Comput Biol Med.* 2013;43:2136-2155.
4. Zhang Z, Srivastava R, Liu H, et al. A survey on computer aided diagnosis for ocular diseases. *BMC Med Inform Decis Mak.* 2014;14:80.
5. Wong WL, Su X, Li X, et al. Global prevalence of age-related macular degeneration and disease burden projection for 2020 and 2040: A systematic review and meta-analysis. *Lancet Glob Health.* 2014;2:e106-116.
6. Saaddine JB, Honeycutt AA, Narayan KMV, Zhang X, Klein R, Boyle JP. Projection of diabetic retinopathy and other major eye diseases among people with diabetes mellitus: United States, 2005-2050. *Arch Ophthalmol.* 2008;126:1740-1747.
7. Abràmoff MD, Niemeijer M, Russell SR. Automated detection of diabetic retinopathy: Barriers to translation into clinical practice. *Expert Rev Med Devices.* 2010;7:287-296.
8. Lijtens G, Kooi T, Bejnordi BE, et al. A Survey on Deep Learning in Medical Image Analysis. *Med Image Anal.* 2017;42:60-88.

## What is Deep Learning?

Deep learning employs architectures known as artificial neural networks (ANNs), which are systems of interconnected units (“neurons”) modeled after the neuronal connections in the human nervous system. ANNs are organized into layers that feed information into each other (Figure, page 22). Units in each layer receive inputs from the preceding layer, and their outputs become the inputs for units in the following layer.

By adjusting the strengths (weights) of these connections based on existing data, the ANN can be “trained” to perform at a specific task, such as image recognition. Deep neural networks (hence “deep” learning) contain multiple intermediate (hidden) layers between the basic input and output layers, with additional layers facilitating hierarchical feature abstraction—for example, progressing from pixels to lines to shapes and so on.

Historically, training deep neural networks was considered to be impractical, but advances in methodology and hardware have spurred a re-emergence of interest in these techniques and brought about exciting advances in many disciplines. 

9. Abràmoff MD, Lou Y, Erginay A, et al. Improved automated detection of diabetic retinopathy on a publicly available dataset through integration of deep learning. *Invest Ophthalmol Vis Sci.* 2016;57:5200-5206.
10. Gulshan V, Peng L, Coram M, et al. Development and validation of a deep learning algorithm for detection of diabetic retinopathy in retinal fundus photographs. *JAMA.* 2016;316:2402-2410.
11. Gargeya R, Leng T. Automated identification of diabetic retinopathy using deep learning. *Ophthalmology.* 2017;124:962-969.
12. Fang L, Cunefare D, Wang C, Guymer RH, Li S, Farsiu S. Automatic segmentation of nine retinal layer boundaries in OCT images of non-exudative AMD patients using deep learning and graph search. *Biomed Opt Express.* 2017;8:2732-2744.
13. Lee CS, Tyring AJ, Deryuter NP, Wu Y, Rokem A, Lee AY. Deep-learning based, automated segmentation of macular edema in optical coherence tomography. *Biomed Opt Express.* 2017;8:3440-3448.
14. El Tanboly A, Ismail M, Shalaby A, et al. A computer-aided diagnostic system for detecting diabetic retinopathy in optical coherence tomography images. *Med Phys.* 2017;44:914-923.
15. Lee CS, Baughman DM, Lee AY. Deep learning is effective for classifying normal versus age-related macular degeneration OCT images. *Ophthalmol Retina.* 2017;1:322-327.
16. Goddard K, Roudsari A, Wyatt JC. Automation bias: A systematic review of frequency, effect mediators, and mitigators. *J Am Med Inform Assoc.* 2012;19:121-127.
17. Müller M. Computer Go. *Artif Intell.* 2002;134:145-179.
18. Silver D, Huang A, Maddison CJ, et al. Mastering the game of Go with deep neural networks and tree search. *Nature.* 2016;529:484-489.
19. LeCun Y, Bengio Y, Hinton G. Deep learning. *Nature.* 2015;521:436-444.

**Table. Examples of Deep Learning for Detection Of Diabetic Retinopathy in Color Fundus Photographs**

	DR Severity Detected	Validation Dataset	Reported Sensitivity	Reported Specificity
Abràmoff, et al. <sup>12</sup>	Referable DR*	Messidor-2 (n=1,748)	96.8%	87.0%
Gulshan, et al. <sup>13</sup>	Referable DR*	EyePACS-1 (n=9,963)	97.5	93.4
		Messidor-2 (n=1,748)	96.1%	93.4%
Gargeya and Leng <sup>14</sup>	Any DR	Messidor-2 (n=1,748)	93%	87%

\*Referable DR = moderate or worse nonproliferative DR, or presence of macular edema

# THE ‘SWITCH’ AND MACULAR ATROPHY IN nAMD

*New insights into how frequent, long-term anti-VEGF injections and a change in medication impact RPE loss.*

By Stephan Michels, MD, MBA

**W**e have learned over the past decade that the risk of under-treatment of active neovascular age-related macular degeneration appears to be greater than the risk of over-treatment. Specifically, while multiple datasets have indicated that insufficient treatment of neovascular AMD leads to vision loss, the risk of anti-VEGF injections contributing to progressive loss of the retinal pigment epithelium (RPE) remains unclear.

Despite adequate wet AMD treatment that aims to achieve the clinical goals of maintaining a dry macula and avoiding recurrences, a significant proportion of patients note a slow, steady, and continuous decline in their visual function over time.

Not infrequently we find situations documenting a progressive loss of RPE that can clearly explain a patient's difficulty reading (*Figure 1*). The situation becomes even more challenging if the patient requires frequent anti-VEGF treatments.

## Anti-VEGF and RPE: No Consensus

Currently, no consensus exists on the potential effect of anti-VEGF therapy on the health of the RPE.

Animal studies have indicated that anti-VEGF agents have a relevant effect on the choriocapillaris and its anatomic structure (e.g., loss of fenestration), and that drugs with higher affinity for vascular endothelial growth factor induce more such changes.<sup>1</sup> Furthermore, if VEGF is neutralized experimentally, the RPE shows vacuoles and separation from the photoreceptor outer segments.<sup>2</sup> These changes appear to be transient in cases where VEGF suppression is stopped.

Several clinical studies have found an effect of anti-VEGF inhibitors on the human choroid in different diseases, and it appears that a switch from ranibizumab (Lucentis, Roche/Genentech) to aflibercept (Eylea, Regeneron/Bayer) induces even further

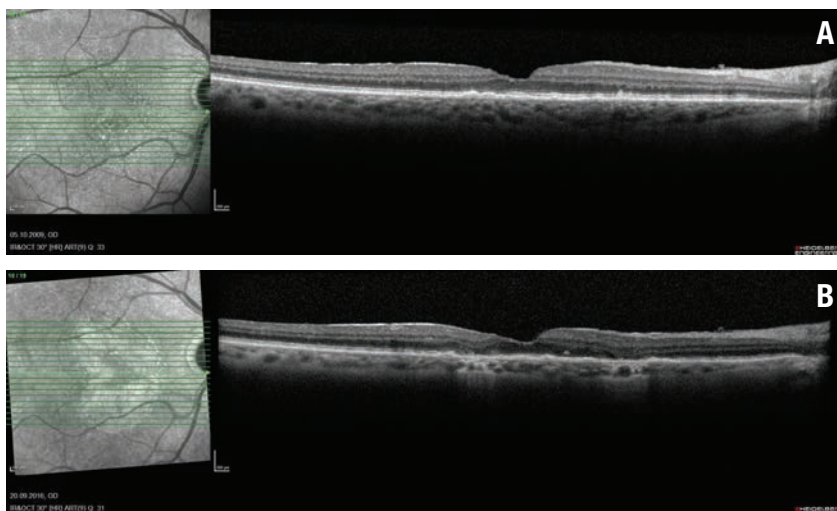
reduction in choroidal thickness.<sup>3-5</sup> However, it remains unclear if these changes are clinically relevant to the RPE and if a more profound reduction in choroidal thickness is related to acceleration in RPE loss. The CATT and IVAN studies indicated that patients continuously treated with either ranibizumab or bevac-

## ABOUT THE AUTHOR



Dr. Michels is vice chair and head of medical retina at the City Hospital Triemli in Zurich, Switzerland, and professor at the University of Zurich.

**DISCLOSURES:** The research foundation at the City Hospital Triemli, Zurich, obtains reimbursement for Dr. Michels' advisory/consultancy/presentation work from Novartis, Bayer, Roche and Allergan.



**Figure 1 .Optical coherence tomography B-scan through the fovea prior to any treatment shows no evidence of retinal pigment epithelium loss (A). The infrared images indicate one small area of RPE loss. OCT B-scan six years later (after 41 intravitreal ranibizumab injections) shows extended areas of hypertransmission with evidence of overlying photoreceptor loss indicating macular atrophy (B). The infrared image outlines the ring-shaped extent of the RPE loss around the fovea.**

zumab (Avastin, Roche/Genentech) have a higher rate of new RPE loss.<sup>6</sup> Unfortunately, so far in the VIEW studies, no rates of new RPE loss have been published on aflibercept. Besides the discussions regarding the most appropriate technology for evaluating the RPE, it remains questionable if these results are applicable in the clinic, where most physicians individualize treatment approaches instead of using fixed, frequent dosing.

We also started to realize that different types of RPE loss in neovascular AMD exist: loss directly associated with the neovascular lesion (Figure 2); and local RPE loss independent of choroidal neovascularization (Figure 1).

In the first case, differentiating the cause of the RPE loss is almost impossible. It may be due to the neovascular disease itself, VEGF inhibition or “successful” CNV regression. But consider the most worrisome situation for many of us: an AMD patient who

requires retreatment at least every six weeks (close to continuous treatment) is switched to aflibercept with the aim of a longer treatment interval.

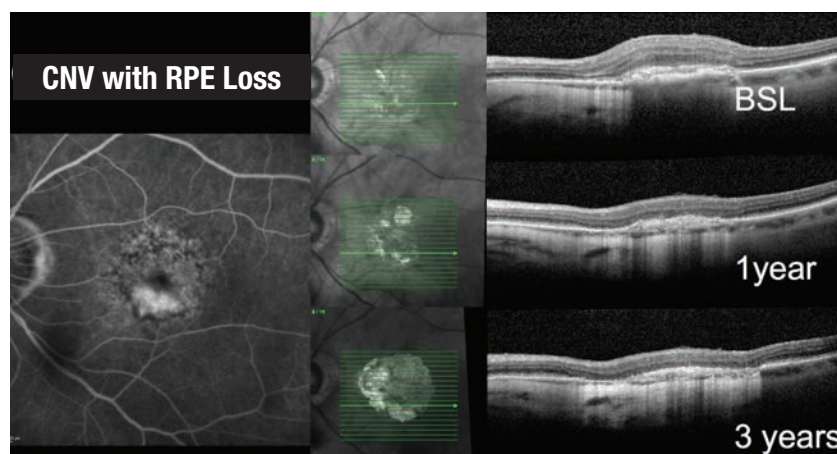
### Our Retrospective Analysis

We performed our own retrospective analysis of such a neovascular

### Take-home Point

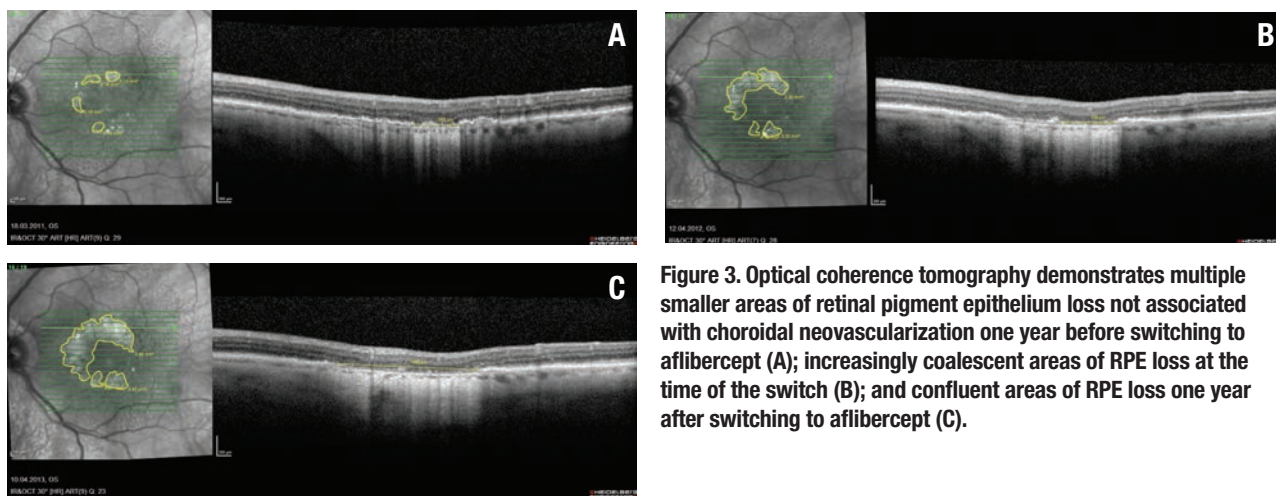
For patients with neovascular age-related macular degeneration that require frequent reinjections, under-treatment with anti-VEGF agents poses the highest risk for vision loss. No consensus exists on the potential effect of anti-VEGF drugs on the retinal pigment epithelium, although animal studies have indicated they affect the choriocapillaris and its anatomic structures, and that drugs with a higher affinity for VEGF induce more such changes. This article reports on a retrospective analysis that indicates frequent and long-term anti-VEGF injections with ranibizumab or a switch to aflibercept in this patient population do not accelerate the rate of RPE loss, and confirms previous reports that a switch to aflibercept may lead to a modest but significant reduction in central retinal thickness and have some effect on pigment epithelial detachments, but causes no improvement in vision.

AMD patient population ( $n=96$ ), requiring retreatment at least every six weeks with ranibizumab or bevacizumab. Similar to other reports, we found that the subsequent switch to aflibercept leads to a modest but significant reduction in central retinal thickness, some effect on pigment



**Figure 2. This composite demonstrates progressive retinal pigment epithelium loss in the area of choroidal neovascularization in an eye with neovascular age-related macular degeneration undergoing a treat-and-extend regimen with aflibercept over three years.**





**Figure 3. Optical coherence tomography demonstrates multiple smaller areas of retinal pigment epithelium loss not associated with choroidal neovascularization one year before switching to aflibercept (A); increasingly coalescent areas of RPE loss at the time of the switch (B); and confluent areas of RPE loss one year after switching to aflibercept (C).**

epithelial detachments (PEDs) and an increase in the treatment interval (5.6 to 6.9 weeks), but no improvement in vision.<sup>7</sup> This raises the question if we are providing any benefit to the patient by using a drug with experimentally more effect on the choroid but with limited data on the rate of new RPE loss, location of RPE loss and association with lesion type or specific characteristics such as choroidal thickness or intraretinal fluid.<sup>8</sup>

This worry was exacerbated in our patient population ( $n=84$ ) showing an accelerated reduction in choroidal thickness by optical coherence tomography following the switch to aflibercept.<sup>5</sup> We were fortunate to have a full spectral-domain OCT

dataset (Heidelberg Spectralis) on all 96 patients, allowing us to evaluate for OCT-defined RPE loss. We defined RPE loss/macular RPE atrophy—with no consensus on OCT-defined RPE loss at hand—as an area with hypertransmission and overlying photoreceptor band loss of at least 300  $\mu\text{m}$  in diameter.

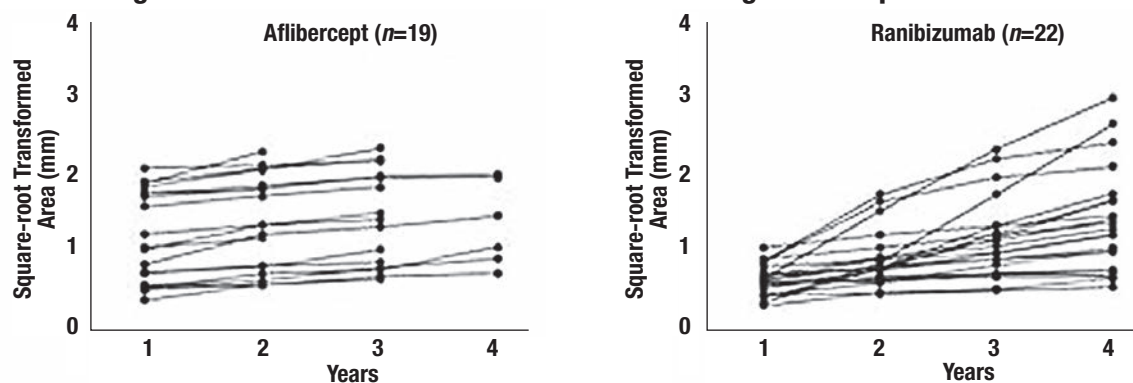
In addition we evaluated only for non-CNV-associated RPE loss to avoid the confounding aspects described previously, and used OCT to outline the RPE at different key time points (*Figure 3*). The example we present here may suggest an accelerated RPE loss with the switch in therapy to aflibercept.

To avoid the confounding factor

that large areas of RPE loss grow faster than small areas, we followed the suggestion of Philip Rosenfeld, MD, and co-authors to use a square-root transformation to compensate for this effect.<sup>9</sup> In our population of frequently treated patients (median of 20 intravitreal injections over 24 months prior to switch), we found 17 of 96 eyes with evidence of RPE loss of at least 300  $\mu\text{m}$  in diameter one year prior to switch.

Based on the previous choroidal thickness analysis and selected cases (*Figure 3*), we expected an accelerated RPE loss with the switch to the VEGF inhibitor with higher affinity for VEGF. However, our study findings did not confirm our hypothesis.

**Figure 4. Course of RPE Loss for Patients Receiving Aflibercept and Ranibizumab<sup>10</sup>**



The area of RPE loss not associated with the CNV grew at a constant rate in the year before and the year after the switch.<sup>10</sup> No acceleration on the progression of RPE loss could be detected up to three years after the switch. A potential explanation may be a minimal reduction in the number of median injections from 20 over the 24 months prior to the switch to 17 in the 24 months afterward.

Outlining the area of RPE loss after square-root transformation of up to four years on aflibercept treatment and a comparable group on ranibizumab shows quite constant growth rates on the area of RPE loss (*Figure 4*). We actually found strong indicators for the linearity of the progression of RPE loss in both patient groups (mean R<sup>2</sup> of 0.959).

Of course, we selected this patient population for non-CNV-related RPE loss, not for overall RPE loss. However, the patients did receive an adequate number of anti-VEGF injections associated with substantial VEGF suppression. So, it is reassuring that this presumably at-risk population did not show an accelerated RPE loss after the switch and over long-term follow-up.

On the other hand, this population may actually not be the one at risk for accelerated RPE loss, since the high need for anti-VEGF inhibition could indicate that the RPE produces adequate amounts of VEGF to protect the eye from the potentially adverse effects of VEGF suppression.

We also need to realize that these patients—unlike those receiving monthly treatment in the continuous treatment arms in CATT and IVAN—did not have constant VEGF suppression but were on a treat-and-extend strategy where complete and constant VEGF suppression is unlikely. Unfortunately, were not able to evaluate

the rate of RPE loss prior to the appearance of neovascular AMD. That might be a most interesting study: monitoring fellow eyes with non-neovascular AMD that eventually develop neovascular AMD and require anti-VEGF treatment.

Our findings may help in decision-making regarding individual treatment strategies for patients with neovascular AMD that require frequent reinjections in order to maintain a dry retina. It appears that in this patient population, frequent and long-term anti-VEGF injections with ranibizumab or a switch to aflibercept do not accelerate the persistent rate of RPE loss most likely due to the underlying disease. Therefore, the highest risk for vision loss in this specific population remains under-treatment with anti-VEGF therapies. <sup>RS</sup>

## REFERENCES

1. Julien S, Biesemeier A, Taubitz T, Schraermeyer U. Different effects of intravitreally injected ranibizumab and aflibercept on retinal and choroidal tissues of monkey eyes. *Br J Ophthalmol*. 2014;98:813-25.
2. Ford KM, Saint-Geniez M, Walshe T, et al. Expression and role of VEGF in the adult retinal pigment epithelium. *Invest Ophthalmol Vis Sci*. 2011 9;52:9478-9487.
3. Yiu G, Manjunath V, Chiu SJ, et al. Effect of anti-vascular endothelial growth factor therapy on choroidal thickness in diabetic macular edema. *Am J Ophthalmol*. 2014;158:745-751.
4. Kim JH, Lee TG, Chang YS, et al. Short-term choroidal thickness changes in patients treated with either ranibizumab or aflibercept: a comparative study. *Br J Ophthalmol*. 2016;100:1634-1639.
5. Mazaraki K, Fassnacht-Riederle H, Blum R, et al. Change in choroidal thickness after intravitreal aflibercept in pretreated and treatment-naïve eyes for neovascular age-related macular degeneration. *Br J Ophthalmol*. 2015;99:1341-1344.
6. Chakravarthy U, Harding SP, Rogers CA et al. Alternative treatments to inhibit VEGF in age-related choroidal neovascularisation: 2-year findings of the IVAN randomised controlled trial. *Lancet*. 2013;382:1258-1267.
7. Pfau M, Fassnacht-Riederle HM, Freiberg FJ, et al. Switching therapy from ranibizumab and/or bevacizumab to aflibercept in neovascular age-related macular degeneration (AMD): One-year results. *Klin Monbl Augenheilkd*. 2016 ;233:945-590.
8. Kuroda Y, Yamashiro K, Ooto S, et al. Macular atrophy and macular morphology in aflibercept-treated neovascular age-related macular degeneration. *Retina*. 2017 Jul 4. Epub ahead of print.
9. Feuer WJ, Yehoshua Z, Gregori G, et al. Square root transformation of geographic atrophy area measurements to eliminate dependence of growth rates on baseline lesion measurements: a reanalysis of age-related eye disease study report no. 26. *JAMA Ophthalmol*. 2013;131:110-111.
10. Wons J, Wirth MA, Graf N, et al. Comparison of progression rate of retinal pigment epithelium loss in patients with neovascular age-related macular degeneration treated with ranibizumab and aflibercept. *J Ophthalmol*. 2017 Feb 20. Epub ahead of print.

## Draining Choroidal Detachments

(Continued from page 16)

found beneficial to position in the suprachoroidal space.<sup>1</sup> If using a valved cannula, cut the valve off with the vitrector or use forceps to maintain patency.

## Avoid Vitrectomy If Possible, Remember Goals of Surgery

The goals of hemorrhagic choroidal drainage are to eliminate appositional or large, nonappositional choroidals, normalize IOP and eliminate posterior pressure on the lens-iris diaphragm. This can be obtained without complete choroidal drainage. Unless the pathology requires, avoid a concurrent vitrectomy. If a vitrectomy is performed, perfluorocarbon liquid may help displace remaining hemorrhage anteriorly.<sup>2</sup>

Other refinements to these techniques have been developed to manage this often complex scenario. As always, multiple approaches in your armamentarium increase your likelihood of success. <sup>RS</sup>

*Dr. Hahn is an associate at New Jersey Retina in Teaneck. Dr. Cohen is a second-year vitreoretinal surgery fellow at Ophthalmic Consultants of Boston and Tufts Medical Center in Boston. Dr. Shah is co-director of the vitreoretinal fellowship program at Ophthalmic Consultants of Boston and Tufts Medical Center, and a vitreoretinal specialist at Ophthalmic Consultants of Boston.*

## REFERENCES

1. Rezende FA, Kickingier MC, Li G, et al. Transconjunctival drainage of serous and hemorrhagic choroidal detachment. *Retina*. 2012;32:242-249.
2. Desai UR, Peyman GA, Chen CJ, et al. Use of perfluoroperhydrophenanthrene in the management of suprachoroidal hemorrhages. *Ophthalmology*. 1992;99:1542-1547.

# THE CHOROID IN AMD: A Critical Point of Failure?

*Advancements in imaging and new computational models are improving our understanding of choroidal failure.*

By **Moussa A. Zouache, PhD, and Philip J. Luthert, BSc, MB, BS**

**D**espite being a critical part of the metabolite delivery system to the outer retina, the choroid remains poorly understood. Perhaps because clinical research inevitably focuses largely on the more readily observable retina, many of the changes reported in the choroid in age-related macular degeneration are often overlooked or misunderstood. Advances in imaging technology and newly developed mathematical models have the potential to greatly advance our understanding of this most significant tissue and the role that it plays in the onset and progression of AMD. This is of critical importance for the design and implementation of better therapeutic strategies and monitoring tools for this disease.

## Structure of the Choroid

The choroid is the sole supplier of oxygen and nutrients to the outer one-third of the retina, and it is the primary clearance route for retinal metabolism byproducts. Given the high metabolic rate of the photoreceptors—one of the highest of any cell of the human body—it is not surprising that the choroid should be, per-unit mass, one of the most vascularized tissues of the human body. The choroid is supplied by 10 to 20 short posterior ciliary arteries and two long posterior ciliary arteries, which cross the sclera near the optic nerve and radiate toward the periphery of the eye.

Typically, four vortex veins drain each quadrant of the choroid and ciliary body and empty into the ophthalmic veins. The choroidal vasculature forms a segmented vascular tree, whereby branches of the choroidal arteries supply ever-smaller sectors of

tissue and ultimately join the choroidal vascular bed, the choriocapillaris. Similarly, venules drain distinct sectors of the choriocapillaris and merge into larger veins.

This branching pattern gives a seemingly layered organization to the choroid in the posterior pole. The largest choroidal arteries and veins form the outermost vascular layer (Haller's layer) and intermediate arterioles and venules make up the layer internal to Haller's. The choriocapillaris and Bruch's membrane, respectively, form the innermost layers of the tissue (*Figure 1*).<sup>1,2</sup>

The exchange between the retina and the choroid occurs mostly at the choriocapillaris, which, unlike most capillary beds, has evolved a planar vascular geometry.<sup>3</sup> It forms a continuous and extensively anastomosing meshwork of capillaries supported by a rigid framework of intercapillary connective tissue that extends from

the optic nerve margins to the ora serrata.

Capillaries are characteristically large in diameter; avascular septae or pillars separate them. Perhaps one of the most distinguishing features of choriocapillaris vessels is their fenestration; pores line their inner endo-

## ABOUT THE AUTHORS



Prof. Luthert is professor of pathology at the Institute of Ophthalmology, University College London.



Dr. Zouache is a post-doctoral fellow at the Institute of Ophthalmology, University College London. His research combines physics, biology and engineering principles to further the understanding of the interface between choroid and retina.

**DISCLOSURES:** The authors have no relevant disclosures.



thelium. The choriocapillaris attaches internally to Bruch's membrane, which forms a complex five-layered structure between the choroid and the retinal pigment epithelium.<sup>1</sup>

Many aspects of the choroidal vasculature change with location in the eye. The vascular density of the choriocapillaris, which is the local volume fraction of tissue occupied by capillaries as opposed to septae, and the number of arterioles and veins inserting into the choriocapillaris are maximal at the macula. Bruch's membrane is thicker in the submacular choroid as compared to the periphery of the eye.<sup>4,5</sup> Enhanced-depth optical coherence tomography has shown that the choroid is at its thinnest at the fovea.<sup>6</sup> Diurnal variations in choroidal thickness by up to 70  $\mu\text{m}$  have been reported;<sup>7</sup> however, the mechanisms involved in this regulation are yet to be identified.

Dramatic changes in the structure of the choroid have been reported with normal aging. Between the ages of 6 and 100, the choriocapillaris vascular density and choroidal thickness decrease on average by 45 percent and 57 percent, respectively. Bruch's membrane undergoes the largest changes, with an increase of 135 percent in thickness on average.<sup>8</sup>

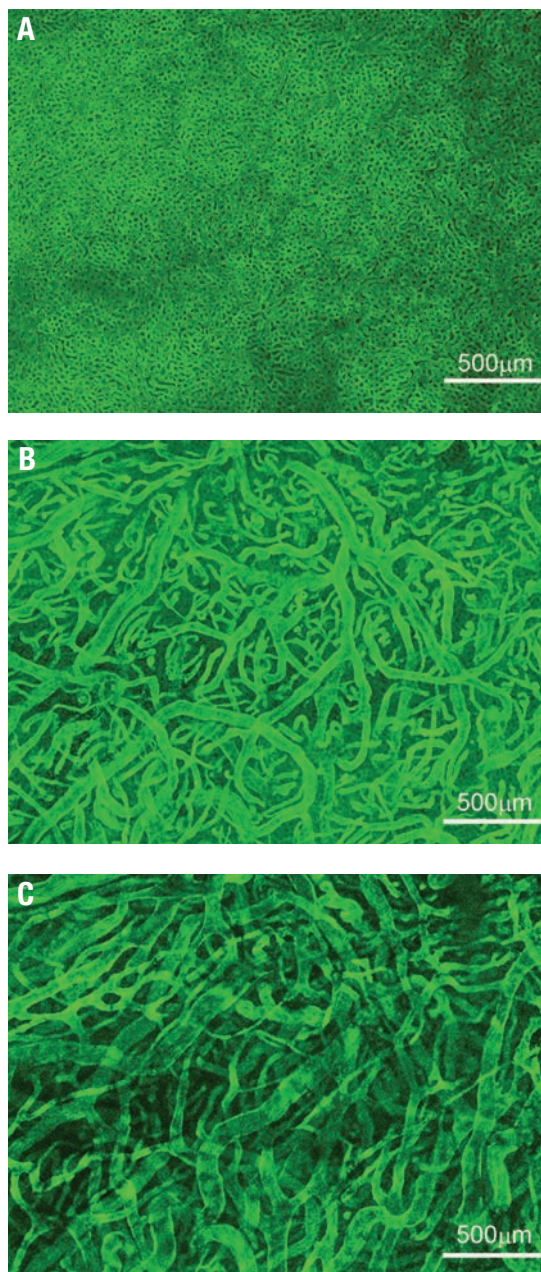
### Unique Functional Features

The choroid has evolved into a structure capable of supporting a variety of transport processes with great efficiency (*Figure 2*). The delivery of oxygen to the photoreceptors relies on a steep gradient of concentration that drives oxygen from the choriocapillaris across the outer retina. This gradient requires a high blood flow in the choroid.<sup>9,10</sup> It is one of the largest in the human body with a per-unit mass flow three to four times greater than that in the kidney and about 10 times that of the brain.

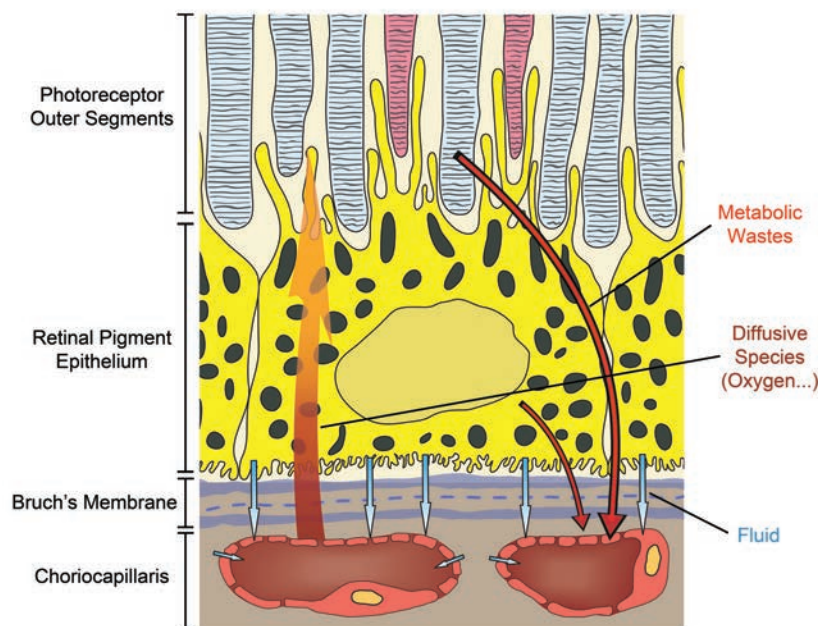
Because choriocapillaris vessels are fenestrated, they are highly permeable to many low-molecular weight substances such as glucose.<sup>11</sup> This helps maintain a high concentration at the interface between the choroid and the retina and facilitates transport to and across the RPE. The choriocapillaris also participates in maintaining an adequate oncotic pressure in the extravascular choroidal tissue, which is key to ensuring proper fluid movement and drainage. In addition to sustaining the outer retina, some have suggested that the high choroidal blood flow plays a key role in the thermoregulation of the back of the eye,<sup>12</sup> thus protecting the retina from damage in

### Take-home Point

Advances in imaging are shedding more light on the critical role choroidal failure plays in the pathogenesis of age-related macular degeneration. This article describes what has been learned about choroidal anatomy in recent years, its function in delivering oxygen to photoreceptors, and what changes the choroid undergoes in the progression of AMD. The authors also discuss how computational models are advancing the understanding of disease progression and how they may influence AMD management in the future.



**Figure 1.** The innermost vascular layer of the choroidal vasculature, here visualized in the submacular area, is the choriocapillaris (A), a densely organized capillary bed. Deeper inside the choroid, Sattler's layer (B) is composed of arterioles and venules supplying the choriocapillaris. The outermost choroidal vascular layer, Haller's layer (C), is made up of large arteries and veins. These images were obtained by immunostaining a portion of tissue dissected from a human eye and imaging them using confocal microscopy.



**Figure 2.** This schematic illustrates the variety of transport processes crucial to vision that the choroid sustains. These processes include the supply of passive compounds, such as oxygen, to the photoreceptors, the maintenance of fluid movement in the back of the eye and the clearance of various retinal metabolic wastes.

extreme temperatures.

A unique and striking functional feature of the choroid is that the blood flow in the choriocapillaris is decomposed into a tessellation of functional lobules, which fill independently from each other. This segmentation, which is observable during dye angiography of the choroid (*Figure 3*), has recently been shown to be a natural consequence of the continuity of the choriocapillaris and the way in which arterioles and venules insert into the plane of the capillaries.<sup>3</sup>

### Choroidal Changes in AMD

AMD is a complex disease with genetic<sup>22</sup> and aging components. Evidence suggests that it involves a breakdown of mass exchange processes within and between the choroid and retina. We do not understand how this breakdown initiates or evolves as AMD progresses; however, exploring changes in the retina and

choroid in both health and disease is key to identifying the factors involved.

Many structural changes have been reported in the choroid in both early and late-stage AMD. Interestingly, the nature of these changes varies with AMD pathology. In maculae presenting basal laminar deposits, geographic atrophy and disciform scarring, the vascular density of the choriocapillaris is significantly smaller than in normal maculae. Thickening of Bruch's membrane is associated with normal aging and contributes to a decline in the ability of small molecules to diffuse across the membrane.<sup>14</sup>

In eyes with GA, complete atrophy of the RPE is associated with a significant loss of choriocapillaris density. Remaining capillaries are largely non-fenestrated and are extremely constricted, which suggests that choriocapillaris function is dramatically impaired. In eyes with choroidal neovascularisation, a reduced choriocap-

illaris density is observed near the CNVs in the absence of RPE atrophy.<sup>15</sup> Of potential significance, given the genetic risk associated with dysregulation of the alternative complement pathways, is the localization of complement components in the inner choroid, including in the region of the choriocapillaris.<sup>16</sup>

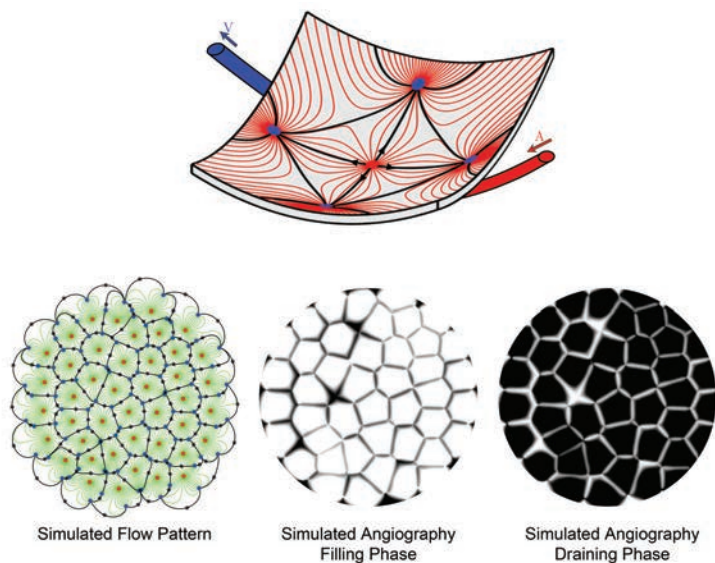
Few functional changes have been reported in the choroid in AMD, and they are often difficult to reconcile with structural changes. Early AMD is associated with a prolonged choroidal filling phase during angiography, which may result from a reduced choroidal perfusion or changes in the diffusional properties of Bruch's membrane that the presence of diffuse deposits may cause.<sup>17</sup> The distribution of reticular pseudodrusen has been found to relate to watershed zones of the choroidal vasculature,<sup>18</sup> which would indicate a possible link between their formation and choroidal perfusion.

### Computational Models: Insight Into Structure and Function

An important challenge in AMD research is to understand how structural and functional changes affect the physiology of the choroid and its ability to sustain the outer retina. Numerous aspects to consider in both the choroid and retina and the difficulty of accessing the back of the eye make conventional methods insufficient or difficult to implement.

Computational methods are particularly well suited to investigate complex systems and have the potential to radically improve our understanding of the dynamics of the choroid in health and disease. Basic physical principles and eighteenth century mathematics have helped show that blood flow in the choriocapillaris is significantly heterogeneous and de-





**Figure 3. Computational models may be used to simulate the blood flow and dye angiography in the choriocapillaris. In this computationally simulated blood flow pattern, blood travels along the lines connecting arterioles (red dots) to venules (blue dots). Because of the geometry of the choriocapillaris, the blood flow is segmented into a tessellation of functional lobules, which are observable during the filling and draining phases of angiograms. The boundaries between lobules correspond to regions where the travel time of the dye is comparatively longer.**

composes into non-communicating functional vascular segments that correspond to functional lobules. The boundaries between functional lobules consist of regions, where the transport of passive compounds is dominantly diffusive and, therefore, comparatively slower (*Figure 3*).

Regions of comparatively lower perfusion are omnipresent over the choriocapillaris and their number is maximal in the submacular area, which could indicate a higher susceptibility to changes in this region. Evidence has shown that the shape of functional lobules is a key determinant in the exchange of diffusive species between the choroid and the outer retina and that it decreases approximately linearly with the choriocapillaris vascular fraction.<sup>3</sup>

Variations in the vascular density of the choriocapillaris and the relative distribution of arterioles and venules

inserting into the choriocapillaris may allow for a local tuning of the perfusion pressure and mass extraction.<sup>3,19</sup>

Only a few mathematical models have explored the effect of pathologies associated with AMD theoretically. A mathematical investigation of CNV dynamics has suggested that a reduction in choriocapillaris blood flow may be sufficient to reduce CNVs and associated retinal edema.<sup>20</sup> Variations in the distance between the photoreceptors and the choriocapillaris have been shown to have a dramatic effect on oxygen tension at the photoreceptor inner segments.<sup>21</sup>

A mathematical model of the RPE/Bruch's membrane/choriocapillaris complex has revealed that, rather than being driven by growth factors or holes in Bruch's membrane, the initiation and progression of CNVs are dominantly driven by defects in RPE adhesion to Bruch's membrane.<sup>22</sup>

## Challenges and Future Directions

A major challenge of AMD research is to identify the chain of biological events that lead to the onset and progression of the disease. This is essential not only for the early diagnosis and monitoring of AMD, but also to determine when, where and how to intervene. Genetic variations in several RPE genes are strongly associated with AMD,<sup>13</sup> which indicates that the RPE plays a key role in the onset of the disease. Based on histological observations, some authors have suggested that choroidal failure is in fact the main trigger of AMD.<sup>23</sup>

In animal models, failure of the choroid leads to retinal degeneration. However, evidence also suggest that retinal degeneration results in choriocapillaris loss. Many studies have shown that biological markers of AMD are present in the retina and the choroid,<sup>16,24</sup> which suggest functional impairments in both tissues. This evidence indicates that the retina and the choroid should ideally be considered together to identify the key events in the onset and progression of AMD. These investigations also demonstrate that a better understanding of the complexity of the interactions between the two tissues is crucial.

While we have focused on AMD, it is worth noting that choroidal changes have a role in other conditions, such as diabetes and hypertension. It will be important to understand the similarities and differences between these conditions and, in the case of diabetic eye disease, to what extent choroidal pathology is a significant determinant of changes in the neural retina. As with the retinal circulation, the choroidal circulation is one of the few microvascular beds that can be

*(Continued on page 41)*



# GENETICS, VITAMINS AND ASTRONAUT EYES

*How space research is providing new insights into ophthalmic pathophysiology with implications for terrestrial and aerospace medicine.*

By Scott M. Smith, PhD, and Sara R. Zwart, PhD

Ophthalmic changes that some International Space Station astronauts have experienced include choroidal folds, optic disc edema, cotton-wool spots, globe flattening and changes in refraction. These changes occurred during and after their four-to-six-month space missions. While the search for a cause and treatment has mostly focused on intracranial pressure, nutritionists have proposed a multifaceted hypothesis that starts with the genetics of one-carbon metabolism, and could end up affecting our understanding of polycystic ovary syndrome (PCOS) as well as endothelial disorders of the eye. The nutrition connection may offer a simple countermeasure.

Initially dubbed the vision impairment/intracranial pressure (VIIP) syndrome, the symptoms and signs were thought to be related to increased intracranial pressure resulting from spaceflight-associated factors: fluid shifts; elevated ambient carbon dioxide concentrations; resistive exercise and/or dietary sodium. Elevated intracranial pressure could impinge on the optic nerve and eye.

Since reports of the original seven cases of VIIP in 2011, much has been done and even more has been written in an attempt to characterize this syndrome, find a ground-based analog in which to study it, and/or propose preventative measures and treatments.<sup>1-9</sup> However, not all astronauts are affected, and the number of cases has varied from mission to mission and year to year, leading to a debate over the actual incidence of ocular issues in ISS astronauts.

A recent consensus has coalesced around the idea that all ISS inhabitants have some degree of optic disc edema during and/or after flight, and that this edema reaches clinical significance in about 15 to 20 percent of them. We reported that 13 percent of astronauts had cotton-wool spots, 60 percent had a change in visual acuity of at least 0.5 D in one eye, 13 percent had choroidal folds and 65 percent had globe flattening.<sup>10</sup> Nonetheless, many astronauts do not develop any of these findings.

## One-Carbon Metabolism

As part of a study examining nutritional status, we were analyzing a broad range of nutritional and biochemical analytes from astronauts before, during and after flight. We had analytes for five of the seven VIIP cases, and found that astronauts who had ophthalmic changes also had high-

er concentrations of homocysteine than those who did not. At that point when we were analyzing our data, we classified VIIP cases dichotomously; either they had any of the previously mentioned ophthalmic changes after flight or they had none. Affected astronauts also had higher concentra-

## ABOUT THE AUTHORS



Dr. Smith is manager for the National Aeronautics and Space Administration Nutritional Biochemistry Laboratory, Human Health and Performance Directorate, Lyndon B. Johnson Space Center, Houston.



Dr. Zwart is deputy manager for the NASA Nutritional Biochemistry Laboratory and is with the University of Texas Medical Branch, Galveston.

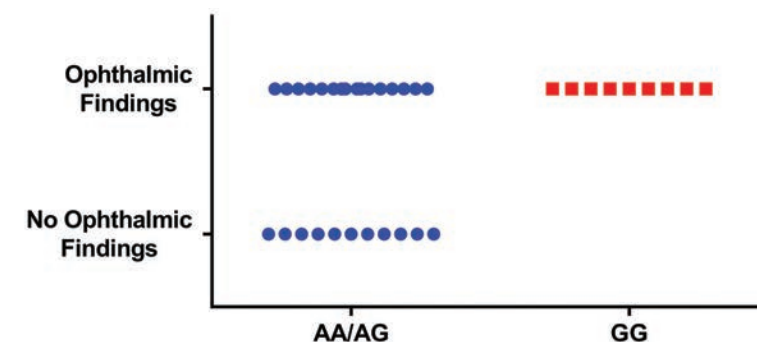
Disclosures: Drs. Smith and Zwart have no relevant disclosures.

tions of three other metabolites: cystathionine; 2-methylcitric acid; and methylmalonic acid.

What's more, these four metabolites were at higher concentrations in affected astronauts *before* flight. These astronauts also had significantly lower serum folate concentrations during flight.<sup>11</sup>

We hypothesized that genetics might be responsible for the differences in circulating metabolites of one-carbon metabolism between affected and unaffected astronauts. One-carbon metabolism is replete with common gene variants that influence the activity of enzymes in the pathway. Some of these gene variants are associated with subtle elevations in homocysteine and other metabolites and reductions in serum folate, all of which we had observed in affected astronauts.

In 49 astronauts who participated in a small study of five single-nucleotide polymorphisms (SNPs), one being the gene for the enzyme methionine synthase reductase (*MTRR*, *rs1801394*) A66G SNP, all who had the GG gene variant (rather than the AG or AA variant) of this SNP had ophthalmic findings (Figure 1). However, not everyone with ophthalmic issues had this variant of the gene. Statistical modeling of the data demonstrated that specific gene variants were significant predictors of the incidence of ophthalmic changes in astronauts,<sup>10</sup> and including B-vitamin status at landing in the model significantly improved it.



**Figure 1. Ophthalmic results (number of astronauts having ophthalmic findings or not) in astronauts having different single-nucleotide polymorphisms (SNPs) in their gene for the enzyme methionine synthase reductase. Astronauts having the AA or AG variants of the SNP were combined for comparison with astronauts having the GG variant.**

cantly improved it. Regarding specific gene variants, the GG form of the *MTRR* A66G SNP was associated with choroidal folds and cotton-wool spots, while the CC variant of *C1420T* SNP of the gene for the enzyme serine hydroxymethyltransferase-1 (*SHMT-1*, *rs1979227*) was associated with all but one case of optic disc edema.<sup>10</sup>

Our extended biochemical, endocrine and metabolomic analyses also identified associations of ophthalmic issues with androgens and carbohydrate (glucose-mannose) metabolism markers.<sup>10</sup> For example, individuals with a greater testosterone response (area under the curve for testosterone concentration) during spaceflight had a greater dioptric change. Those with higher preflight concentrations of dehydroepiandrosterone-sulfate (DHEA-S, a testosterone precursor) had a higher prevalence of cotton-wool spots and a greater dioptric

change after flight.

Thus, we have established an association of one-carbon pathway genetics and B-vitamin status with the development of ophthalmic pathology in some astronauts.<sup>10</sup> However, we cannot explain the etiology of every case of ophthalmic pathology, in part because we evaluated such a small number of SNPs; only five. To remedy that, we have initiated an experiment to evaluate a much broader set (>500) of SNPs associated with one-carbon metabolism in astronauts.

### The Hypothesis

We developed an end-to-end hypothesis to describe how one-carbon pathway genetics and B-vitamin status might be related to ophthalmic changes in some astronauts.<sup>12</sup> We proposed a multiple-hit hypothesis linking endothelial dysfunction, leaky blood vessels and subclinical edema.

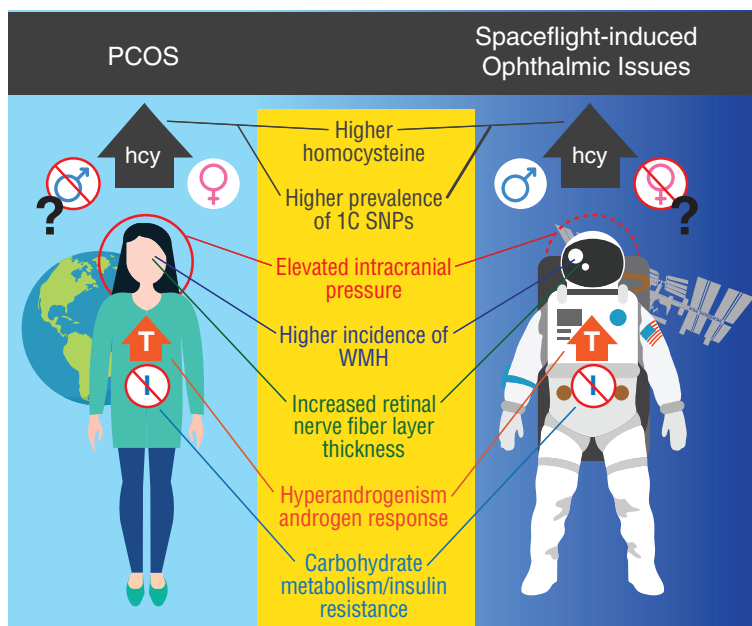
### Take-home Point

The genetics of one-carbon metabolism and B-vitamin status have been associated with the development of ophthalmic changes in astronauts after missions on the International Space Station. This article describes a hypothesis that explains how genetics and physiological and biochemical insults to vascular endothelial function result in impaired nitric oxide synthesis and oxidative stress, and lead to endothelial dysfunction and a buildup of pressure around the optic nerve and the posterior globe. Furthermore, individual structural variations of the area surrounding the optic canal could exacerbate the effects of increased pressure. An additional hypothesis holds that the genetics, biochemistry and cardiovascular (and potentially ocular) physiology are similar between affected astronauts and women with polycystic ovary syndrome. The implications of this research for both space and terrestrial medicine are profound.

Several insults lead to vascular endothelial dysfunction by way of impaired nitric oxide synthesis and oxidative stress. Genetic along with biochemical, environmental and physiological factors in some combination cause impaired endothelial nitric oxide synthesis and oxidative stress. These lead to endothelial dysfunction, leaky blood vessels and subsequent subclinical edema. Localized edema in the cerebral venous sinuses impinges upon arachnoid villi, reducing the normal efflux of cerebrospinal fluid (CSF) from the villi into the venous circulation. Pressure from the slowed CSF efflux to the venous sinuses builds up in the subarachnoid space of the optic nerve

and exerts itself on the optic nerve and the posterior globe.<sup>12</sup> Individual structural variations of the area surrounding the optic canal could exacerbate this increased pressure.<sup>12</sup> The subarachnoid space of the optic nerve is narrowest around the optic canal.

Genetics can affect individual nutrient requirements, and subsequently peripheral and cerebral vitamin status. The function of the blood-brain barrier (BBB) can further affect this. The BBB concentrates certain vitamins, including folate, in the brain using active transport mechanisms. Anything that affects BBB permeability can thus affect cerebral vitamin status. Radiation, a key concern for space travelers, can also affect BBB function. Radiation and B-vitamin de-



**Figure 2.** This graphic compares findings in polycystic ovary syndrome (PCOS) and spaceflight-induced ophthalmic issues. Only women are thought to have PCOS, but so far only men have had spaceflight-induced ophthalmic issues. Commonalities in the two conditions include elevated serum homocysteine concentrations, greater prevalence of risk alleles in the one-carbon metabolic pathway, higher incidence of white-matter hyperintensities, increased retinal nerve fiber layer thickness, elevated testosterone levels (in PCOS) or response of testosterone to spaceflight, altered carbohydrate metabolism, insulin resistance and possibly elevated intracranial pressure.

iciencies are also associated with an increased incidence of factors such as white matter hyperintensities, which are currently being studied in astronauts.

B-vitamin insufficiency is associated with increased serum homocysteine and depleted reserves of endothelial antioxidants. Oxidative stress, in combination with other physiological (e.g., fluid shifts, altered testosterone or carbohydrate metabolism) or environmental (e.g., radiation, ambient CO<sub>2</sub>) influences, contributes to endothelial dysfunction.

Fluid shifts, radiation, CO<sub>2</sub> and oxidative stress may lead to endothelial dysfunction and contribute to astronauts' ophthalmic pathology. Yet, not all astronauts develop ophthal-

mic pathology. Thus, we maintain that genetic effects on one-carbon pathway function remain an indispensable factor in this pathology, given that all astronauts are exposed to microgravity-induced fluid shifts, radiation and cabin CO<sub>2</sub> concentrations higher than those on Earth.

However, testing this hypothesis is challenging given the inherent difficulties of obtaining these data during spaceflight and the lack of ground-based environments that simulate spaceflight. Some have reported small ophthalmic changes during bed rest, a common analog for effects of

spaceflight on bone and muscle, but nothing to the extent observed in astronauts.<sup>4,13</sup>

### Astronauts and Ovaries

One of the more intriguing observations related to the phenomenon of ocular changes in spaceflight is that many documented or purported characteristics of astronauts with ophthalmic changes are shared by women with polycystic ovary syndrome (PCOS) (Figure 2). Curiously, all of the frank cases of spaceflight-related ophthalmic pathology to date have been in men, and debate surrounds whether the condition affects only men or if we simply haven't flown enough women. While having ovaries is a requirement for being diagnosed



with PCOS, having polycystic ovaries is not. Some have advocated that men can have this same syndrome, with only the metabolic and endocrine characteristics.<sup>14</sup> Cardiovascular pathology in PCOS patients is well documented, but less well understood.<sup>15</sup>

We are currently evaluating one-carbon genetics/biochemistry and ophthalmic exams in women with PCOS and/or idiopathic intracranial hypertension (IIH), patients with IIH (but not PCOS) and matched controls. Our hypothesis is that the similarities between women with PCOS and astronauts with ophthalmic issues are real, and that women with PCOS may provide a ground analog population to study these genetic/ocular relationships and hopefully lead to countermeasures.

Ultimately, proving this hypothesis could yield substantial benefits for both aerospace and terrestrial medicine. Specifically, the study will shed light on the understanding of the nature and genetics of PCOS. Understanding these processes more thoroughly provides the opportunity to find new treatments, or make current treatments more effective.

For one intriguing anecdote, when we published our genetics paper in 2016, a fellow NASA employee emailed, stating, “Six years ago I was diagnosed with papilledema that has caused my right pupil to dilate differently from my left. No cause was ever found. Something is putting pressure on my optic nerve ... but what? At some point in all of this, I was diagnosed with a B12 deficiency. And I am one of those 10 to 20 percent of women with PCOS.”


## The Countermeasure

Preventing or treating ophthalmic issues during spaceflight is critical before we embark on exploration-class

missions far from Earth. The most obvious and lowest-risk countermeasure, according to our data and subsequent hypothesis, is a biologically active B-vitamin supplement.

Pharmacologic agents plausibly might have their specific effects on points in this hypothesis, but might also miss others with unknown consequences. B-vitamin supplementation has been shown to enhance nitric oxide synthesis, mitigate endothelial dysfunction, improve blood-brain barrier function and reduce hypertension, among other things—all with very low risk.

But we have yet to prove our hypothesis, so perhaps it is imprudent to prescribe vitamins at this point. We feel that evidence must be established. Nonetheless, we have documented an association between one-carbon genetics, B-vitamin status and astronauts who develop ophthalmic issues. We recently also documented that individuals with one-carbon genetics similar to that of astronauts who develop ophthalmic issues have altered responses to CO<sub>2</sub> exposure,<sup>16</sup> so this line of thinking may not be a fluke. One could argue that our hypothesis is wrong, and that an entirely different set of arrows could link one-carbon genetics and B-vitamin status to these ophthalmic issues. That is the point of research.

Biomedical research is a slow process, but we expect that developing our hypothesis, whether it proves true or not, has produced ideas that will contribute to solving problems in several areas of medicine. 

**Acknowledgments:** *The authors would like to acknowledge the One-Carbon Investigator Team: Drs. Jesse F. Gregory, Steven H. Zeisel and Patrick J. Stover for their work in B vitamins and one-carbon metabolism;*

*Drs. Thomas Mader and C. Robert Gibson for their experience in evaluating astronaut eyes; and Drs. Alice Y. Chang and John J. Chen for leading the efforts to accomplish our study of one-carbon genetics, biochemistry and ocular exams in women with polycystic ovary syndrome. Acknowledgment also goes to the astronauts who have participated from the outset and Jane Krauhs for editorial assistance. The Human Health Countermeasures Element of NASA's Human Research Program and the Nutritional Biochemistry Laboratory Team have also supported the research.*

## REFERENCES

1. Lee AG, Tarver WJ, Mader TH, Gibson CR, Hart SF, Otto CA. Neuro-ophthalmology of space flight. *J. Neuroophthalmol.* 2016;36:85-91.
2. Mader TH, Gibson CR, Pass AF, et al. Optic disc edema in an astronaut after repeat long-duration space flight. *J. Neuroophthalmol.* 2013;33:249-255.
3. Marshall-Bowman K, Barratt MR, Gibson CR. Ophthalmic changes and increased intracranial pressure associated with long duration spaceflight: an emerging understanding. *Acta Astronaut.* 2013;87:77-87.
4. Taibbi G, Cromwell RL, Kapoor KG, Godley BF, Vizzeri G. The effect of microgravity on ocular structures and visual function: a review. *Surv. Ophthalmol.* 2013;58:155-163.
5. Marshall-Goebel K, Mulder E, Bershad E, et al. Intracranial and intraocular pressure during various degrees of head-down tilt. *Aerosp Med Hum Perform.* 2017;88:10-16.
6. Mader TH, Gibson CR, Pass AF, et al. Optic disc edema, globe flattening, choroidal folds, and hyperopic shifts observed in astronauts after long-duration space flight. *Ophthalmology.* 2011;118:2058-2069.
7. Lawley JS, Petersen LG, Howden EJ, et al. Effect of gravity and microgravity on intracranial pressure. *J Physiol.* 2017;595:2115-2127.
8. Mader TH, Gibson CR, Otto CA, et al. Persistent asymmetric optic disc swelling after long-duration space flight: Implications for pathogenesis. *J. Neuroophthalmol.* 2017;37:133-139.
9. Mader TH, Gibson CR, Lee AG, Patel NB, Hart SF, Pettit DR. Unilateral loss of spontaneous venous pulsations in an astronaut. *J. Neuroophthalmol.* 2015;35:226-227.
10. Zwart SR, Gregory JF, Zeisel SH, et al. Genotype, B-vitamin status, and androgens affect spaceflight-induced ophthalmic changes. *FASEB J.* 2016;30:141-148.
11. Zwart SR, Gibson CR, Mader TH, et al. Vision changes after spaceflight are related to alterations in folate- and vitamin B-12-dependent one-carbon metabolism. *J. Nutr.* 2012;142:427-431.
12. Zwart SR, Gibson CR, Gregory JF, et al. Astronaut ophthalmic syndrome. *FASEB J.* 2017;31:3746-3756.
13. Taibbi G, Cromwell RL, Zanello SB, et al. Ocular outcomes comparison between 14- and 70-day head-down-tilt bed rest. *Invest Ophthalmol Vis. Sci.* 2016;57:495-501.
14. Kurzrock R, Cohen PR. Polycystic ovary syndrome in men: Stein-Leventhal syndrome revisited. *Med Hypotheses.* 2007;68:480-483.
15. Yanes Cardozo LL, Romero DG, Reckelhoff JF. Cardiometabolic features of polycystic ovary syndrome: role of androgens. *Physiology.* 2017;32:357-366.
16. Laurie SS, Vizzeri G, Taibbi G, et al. Effects of short-term mild hypercapnia during head-down tilt on intracranial pressure and ocular structures in healthy human subjects. *Physiol Rep.* 2017;5:e13302.

# FIVE FROM ASRS 2017: SYRINGES, SIROLIMUS AND ENDOPHTHALMITIS PROPHYLAXIS

*Plus four-year results of gene therapy  
and insights into when to perform ERM removal.*

**By Ashkan M. Abbey, MD**

**T**he annual meeting of the American Society of Retina Specialists brings together leading retina specialists from around the world to share the most cutting-edge clinical research. ASRS 2017 in Boston showcased the latest in diagnostics, treatment and management strategies for retinal disease. The meeting once again demonstrated how rapidly the field of retina is advancing.

Here, we present summaries of five of the most intriguing presentations. They include long-term results of gene therapy for inherited retinal disease, assessing syringes used for bevacizumab injections for silicone oil droplets, the use of intravitreal sirolimus for recalcitrant neovascular age-related macular degeneration, an intravitreal injection protocol to reduce the risk of endophthalmitis and evaluating early vitrectomy for epiretinal membranes.

## **Four-Year Results: Gene Therapy for IRD**

The treatment of inherited retinal diseases has perplexed the retina community for decades. Fortunately, there appears to be significant promise with the use of viral vectors for gene therapy in these patients. In this study, voretigene neparvovec

(VN, Luxturna, Spark Therapeutics), an adeno-associated viral type 2 vector that drives expression of hRPE 65, was administered to eyes of patients with RPE65-mediated inherited retinal disease. An initial Phase I study evaluated single-dose subretinal administration of VN in the eye with worse vision.

This follow-up study presented four-year results after subretinal administration of VN 0.3 ml in the second, previously uninjected eye of 11 patients.<sup>1</sup> Subjects were then tested for ability to navigate in varying light levels through multi-luminance mobility testing (MLMT) and full-field, light-sensitivity threshold testing (FST).

Four-year data for eight of the 11 patients was presented. After treatment, MLMT improved rapidly and was sustained at four years. FST also demonstrated a rapid im-

provement after treatment. Compared with baseline, there was a hundredfold improvement of FST at 30 days, which was sustained over four years. There were no serious adverse events associated with VN, nor were there any reported immune responses.

The sustained improvement in visual function after treatment with this viral vector marks a significant step toward effectively treating RPE65-mediated inherited retinal disease. Subretinal gene therapy

## **ABOUT THE AUTHOR**



Dr. Abbey is a surgical and medical retina specialist at Texas Retina Associates, Dallas, and clinical assistant professor of ophthalmology at the University of Texas Southwestern Medical Center.

**DISCLOSURE:** Dr. Abbey is a consultant for Allergan.

using viral vectors continues to show promise for a number of inherited retinal diseases for which we do not have any efficacious treatment.

*The study author disclosed being an investigator for and grant recipient of Spark Therapeutics.*

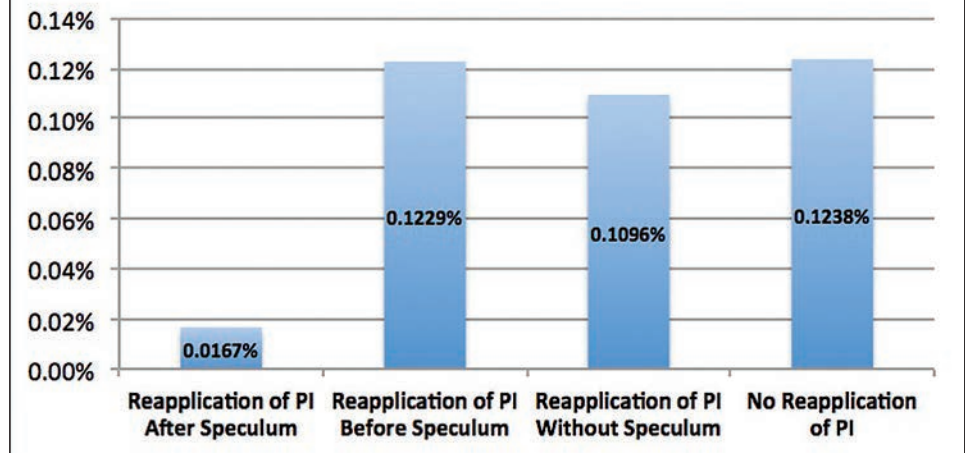
### Silicone Oil Droplets More Common With BD Insulin Syringes

In 2016, the ASRS received an unusually high number of adverse event reports regarding symptomatic silicone oil droplets in the vitreous cavity after bevacizumab injections. This study attempted to determine if the commonly used Becton Dickinson (BD) insulin syringes were more likely to result in oil droplets being injected into the vitreous.<sup>2</sup> This study evaluated four different types of syringes: BD insulin syringes; BD tuberculin syringes; Henke Sass Wolf (HSW) insulin syringes; and HSW silicone-free syringes.

Twenty of each type of syringe were loaded with 0.06 mL of fluorescein and incubated at 40° C for two to four weeks. Subsequently, the syringe fluid was ejected onto slides and examined microscopically.

Silicone oil droplets were identified in five (25 percent) of the BD insulin syringes. No oil droplets were found in any of the other syringes. The oil droplets also occurred when the plunger was maximally depressed with the fixed-needle design. The study also found that syringes that lack dead space are more susceptible to silicone oil droplets being injected into the vitreous.

**Figure. Incidence of Post-Injection Endophthalmitis By Aseptic Protocol Involving 5% Povidone-Iodine (PI)**



This important study identifies a higher risk of silicone oil droplets with injections using BD insulin syringes, particularly with a lack of dead space in the syringe. Retina specialists should carefully consider the type of syringe that their compounding pharmacy is using in order to avoid this potential complication.

*The study author had no relevant disclosures.*

### Aseptic Protocol to Reduce Endophthalmitis Risk After IVT

The application of povidone-iodine is known to be the most critical measure that can be taken to prevent endophthalmitis after intravitreal injection (IVT). This study identified one key step that significantly

reduced the risk of endophthalmitis in patients receiving injections: applying PI after placement of the lid speculum.<sup>3</sup>

This retrospective study of 37,646 intravitreal injections used a multivariate analysis to identify risk factors for development of endophthalmitis occurring after injection. Before all injections, a technician applied 5% PI to the eyelids and conjunctiva. Among 27 different retina specialists, four distinct aseptic protocols emerged with regard to reapplication of PI: physicians who did not reapply PI; reapplication of PI without the use of a lid speculum; reapplication of PI before speculum placement; and reapplication of PI after speculum placement.

Thirty-three cases of endophthal-

### Take-home Point

This article explores five noteworthy presentations from the American Society of Retina Specialists 37th annual meeting: a readout of four-year results of gene therapy for RPE65-mediated inherited retinal disease; a study of different syringes and their proclivity for leaving residual oil droplets; a comparison of sirolimus and anti-VEGF therapy vs. anti-VEGF monotherapy; how an aseptic protocol may reduce endophthalmitis risk after intravitreal therapy; and a study of epiretinal membrane removal before vision declines below 20/40.



mitis were identified for an overall incidence of 0.088 percent (*Figure, page 37*). The first three groups had very similar incidences of endophthalmitis (0.124 percent, 0.110 percent and 0.122 percent, respectively). However, the fourth group, which reapplied PI after insertion of the lid speculum, was associated with a significant reduction in the incidence of endophthalmitis (0.017 percent,  $p=0.004$ ).

This study suggests that contact from the eyelid to the injection site after final application of PI may significantly increase the risk of post-injection endophthalmitis. The application of PI after insertion of a lid speculum appears to provide a substantial safety benefit for intravitreal injections.

*The study authors had no relevant disclosures.*

### Sirolimus with Aflibercept Vs. Aflibercept Monotherapy

Intravitreal injection of sirolimus (Santen) in conjunction with aflibercept (Eylea, Regeneron) leads to better anatomical outcomes on optical coherence tomography in patients with chronic exudative AMD compared to aflibercept monotherapy. Sirolimus inhibits the mammalian target of rapamycin (mTOR), which has been shown to be involved in inflammation, angiogenesis, fibrosis and hyperpermeability. In a previous study, the authors compared sirolimus monotherapy to standard anti-VEGF treatment for chronic neovascular AMD and found a significant decrease in central subfield thickness in the sirolimus group compared to an increase in the standard anti-VEGF group.

In this study, the authors aimed to determine if combination treatment with sirolimus and aflibercept

would be beneficial for chronic exudative AMD.<sup>4</sup> They performed a prospective, randomized study of patients with persistent intraretinal or subretinal fluid despite appropriate treatment with anti-VEGF agents for exudative AMD. Group 1 (10 patients) received intravitreal injections of sirolimus (440 µg) at baseline, and week four, 12, 20 and 28, and aflibercept at weeks one, eight and 16. Future aflibercept injections were based on the persistence of fluid. Group 2 (10 patients) received aflibercept at baseline, weeks eight, 16, 24 and 32.

After nine months, group 1 demonstrated a better anatomical response, but no statistically significant difference in visual acuity changes was noted between the two groups. The presence of baseline chronic fluid may have precluded more robust gains in visual acuity in group 1 despite the better anatomical outcomes.

This study suggests that intravitreal injection of sirolimus may be an effective adjuvant therapy for recalcitrant neovascular AMD. Larger studies with earlier use of sirolimus will be useful to determine if this combination therapy could result in better long-term visual outcomes and reduced injection burden compared to anti-VEGF monotherapy.


*The lead author disclosed being a consultant to Santen. Four co-authors had no relationships to disclose.*

### When Should ERMs Be Removed?

Modern small-gauge surgical techniques are more likely to preserve vision when epiretinal membrane (ERM) removal is performed sooner rather than after a significant decline in vision below 20/40. The

authors performed a retrospective chart review of 119 pseudophakic eyes that underwent vitrectomy and ERM/internal limiting membrane peeling for idiopathic ERM.<sup>5</sup> Twenty-four of 27 (89 percent) eyes with preoperative vision  $\geq 20/40$  attained final postoperative vision of  $\geq 20/40$ , while only 52 of 88 (59 percent) eyes with preoperative vision  $\leq 20/50$  attained  $\geq 20/40$  vision at final postoperative vision.

Vitreoretinal surgeons often use the arbitrary vision threshold of 20/40 when deciding to operate on an ERM. This study indicates that the removal of an ERM prior to a significant decline in vision below 20/40 may increase the likelihood of achieving final postoperative vision of  $\geq 20/40$ . These findings may motivate surgeons to operate sooner on symptomatic patients with epiretinal membranes. Larger studies are needed to validate this intriguing finding.

*The lead author had no relationships to disclose. A co-author disclosed relationships with Covalent Medical, Dutch Ophthalmic Research Center (DORC) and Vestrum Health.* 

### REFERENCES

- Maguire AM. Year 4 results for a Phase I trial of voretigene neparvovec in biallelic RPE65-mediated inherited retinal disease. Paper presented at: 35th annual meeting of the American Society of Retina Specialists; August 15, 2017; Boston, MA.
- Emerson GE. Silicone oil droplets are more common in fluid from BD insulin syringes as compared to other syringes. Paper presented at: 35th annual meeting of the American Society of Retina Specialists; August 14, 2017; Boston, MA.
- Levinson JD. An aseptic protocol to reduce the risk of endophthalmitis following intravitreal injection. Paper presented at: 35th annual meeting of the American Society of Retina Specialists; August 13, 2017; Boston, MA.
- Maturi RK, Chhablani J, Harless A, Japeen A, Bracha P. Sirolimus in conjunction with aflibercept vs. aflibercept monotherapy for the treatment of chronic exudative AMD. Paper presented at: 35th annual meeting of the American Society of Retina Specialists; August 14, 2017; Boston, MA.
- Par G, Pollack JS. Should epiretinal membranes be removed before vision drops below 20/40? Paper presented at: 35th annual meeting of the American Society of Retina Specialists; August 12, 2017; Boston, MA.



# The Hypersonic Principle

*A closer look at “the first major vitreous removal innovation in 40 years.”*

**W**ith the launch of its Stellaris Elite system for retina surgery with the Vitesse vitrectomy system, Bausch + Lomb claims it to be the “first and only hypersonic, 100-percent open-port vitrectomy system,” and the “first major vitreous removal innovation in 40 years.”

What is hypersonic vitrectomy and how does it differ from the existing platforms out there? Paulo Stanga, MD, who worked with B+L in developing the Vitesse system, offers some answers to that question. Dr. Stanga is a professor of at the University of Manchester in the United Kingdom, a vitreoretinal surgeon for the Manchester Royal Eye Hospital and director of the Manchester Vision and Regeneration Lab.

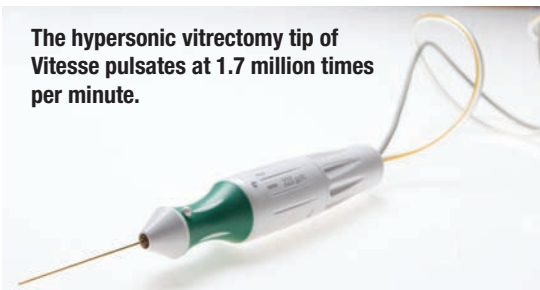
He notes that existing vitrectors use guillotine-based cutters, and are either mechanically, electrically or air driven. They work by first aspirating vitreous fibers and then cutting them once they are in the vitrector needle. “Therefore, the vitreous fibers are cut only after they have been pulled from the posterior cavity into the inside of the needle port and traction has been exerted on the retina,” Dr. Stanga says.

Smaller-gauge needles mean reductions in flow volumes. Some systems compensate by increasing cut rates, which causes flow volume to drop further. “However, there are limitations: speed of the cutter blade, duty cycle and turbulence within the probe,” Dr. Stanga says.

## Vitreous Liquefaction

The hypersonic system liquefies

**The hypersonic vitrectomy tip of Vitesse pulsates at 1.7 million times per minute.**



the vitreous and the cutting process takes place before vitreous fibers enter the port. “In addition, it achieves a much higher cut rate than guillotine-based cutters without compromising on duty cycle or flow,” he says.

He explains that the hypersonic vitrector tip pulsates at 1.7 million times a minute, driving fluid through the port at its end. “An ‘active zone’ develops only in front of the port: within this zone, a sheer cross-flow of fluid and vitreous develops and that breaks up the collagen fibers in the vitreous into very small pieces, effectively liquefying it,” Dr. Stanga says.

## Guillotine vs. Hypersonic

Dr. Stanga has done comparative studies of the guillotine-based and hypersonic vitrectors in water and vitreous. “Guillotine vitrector performance is dependent on cut rate, vacuum and gauge, both in water and vitreous,” he says. “However, performance of the hypersonic vitrector is dependent only on vacuum and flow for both fluids and ultrasonic power for vitreous flow, therefore allowing for the use of smaller gauges and port sizes, as well as providing less variation in flow and consequently more stable infusion pressures.”

The hypersonic vitrector is capable of operating with port openings as

small as 200 to 250  $\mu\text{m}$  compared to 500 to 600  $\mu\text{m}$  with guillotine vitrectors. “Because force is the product of vacuum and area, the hypersonic vitrector exerts less traction,” he says.

The device can also work at a lower vacuum level than guillotine vitrectors because of the small and fixed open port and the fact that it is drawing in liquefied vitreous. “Lower vacuum also means less traction,” he says. “A permanently open port with no resulting variations in flow leads to reduced intraocular turbulence. All of this, could make the removal of vitreous safer, especially when working close to the retina.”

## How a Case Proceeds

For the surgeon, a case using a hypersonic vitrector begins like one with a guillotine vitrector, but the system settings are different. “A stroke amplitude is selected instead of a cut rate, and the aspiration vacuum setting may be much lower,” Dr. Stanga says. He adds that the hypersonic technology allows for the removal of vitreous, dense hemorrhage, soft lens material and silicone oil as well as the execution of a retinectomy using the same probe. “This is quite unique,” says Dr. Stanga.

A first-in-human study of hypersonic vitrectomy suggests it is a promising alternative to guillotine platforms, and operating times appear to be similar or shorter with the hypersonic instrument. “The hypersonic vitrector was effective in vitreous removal in all cases, although larger-scale studies are required to confirm our initial findings,” Dr. Stanga says. 📧



# A Drop for DME and AMD

*Are clinical investigators close to finding the Holy Grail for retinal disease?*

**By Richard Mark Kirkner**

**R**esearchers have pursued topical treatments for retinal disease like the Holy Grail, only to find the quest as daunting as King Arthur's mythical adventures. But in ophthalmology, its seekers have become emboldened with the release last month of Phase I/II data of a topical candidate SciFluor Life Sciences has in development.

SciFluor unveiled the positive top-line results of SF0166 for the topical treatment of diabetic macular edema. In 40 patients with DME who were randomized to one of two dose strengths (2.5% and 5%), the safety endpoint was achieved with no drug-related serious adverse events. Ocular adverse events were recorded in the treated eyes of six patients; all were mild, and only one was considered possibly drug-related. The patients self-administered the agent as an eye drop twice a day for 28 days.

More importantly, SF0166 demonstrated biological activity in both dosage groups, with 53 percent of patients demonstrating a reduction in retinal thickness and improvements in visual acuity. Durability of RT response after the 28-day course of therapy was observed during the month of follow-up without treatment.

SF0166 is a selective small-molecule inhibitor of integrins. Here Peter Kaiser, MD, provides insight into how SF0166 works and explores the potential for topical treatment for DME and age-related macular degeneration. Dr. Kaiser holds the Chaney Family Endowed Chair in Ophthalmology Research and is a

staff physician of the vitreoretinal faculty at the Cleveland Clinic Cole Eye Institute.

## The mechanism of action in his own words

SF0166 blocks integrins, primarily integrin  $\alpha\beta3$ , which is found in both DME and AMD. As the name of the company would suggest, the key feature of this formulation is that the drug is fluorinated. Fluorination of the drug improves the lipophilicity, slows metabolism and improves interactions with ligands. Preclinical studies have shown sustained levels in the retina after topical administration for up to eight hours.

## Q What are the physiological challenges of getting active agents from the sclera to the retina?

**A** The biggest issue is the cornea. Basically, the agent needs to have a special electrical charge for these molecules to cross through the eye. The eye is designed not to allow things to penetrate it. The past paradigm for topical agents was to put the active ingredients into an artificial-tear drop, but that didn't add anything to the charge of the drop to make it pass through the eye's defenses.

Newer topical therapies are working on better ways to overcome these defenses to reach the posterior segment. For example, Ohr Pharmaceuticals is in Phase III with a topical therapy for AMD, and Kala Pharmaceuticals has completed a preclinical study of its lead compound KPI-285 for wet AMD. This really brings a new era in topical treatment.

## Quotable

**"SF0166 demonstrated biological activity in both dosage groups, with 53 percent of patients demonstrating a reduction in retinal thickness and improvements in visual acuity."**

## Q What else is happening in this space to generate interest in the potential for integrin antagonism for retinal disease?

**A** Allegro Ophthalmics has in development Luminate that also acts to inhibit integrins and disrupt the production of vascular endothelial growth factor. Two different Phase II studies showed Luminate to be non-inferior to monthly bevacizumab (Avastin, Roche/Genentech). Phase III studies will be starting shortly. Thrombogenics is also starting studies with its integrin inhibitor.

## Q What's appeal of topical treatment for DME?

**A** Retina specialists are getting "injected out." A therapy that offers similar efficacy and better safety in the form of a drop is a welcome




addition. Moreover, a prescription eye drop comes out of a different bucket of health-care spending and it moves it away from the doctor having to administer and store the medication; the doctor writes a prescription, and the patient goes to the pharmacy to get it.

### Q How will drops for retinal disease overcome compliance issues characteristic of glaucoma therapy?

A The reason glaucoma compliance is poor is because glaucoma patients have no idea they're losing vision. They have to remember every day to take a drop that may sting or burn and they don't see any benefit. There's no change in vision.

In DME and AMD, we know that patients come in for up to monthly injections because they know if they miss the treatments, they'll start to lose vision. That's why the compliance rate for an eye drop in retinal disease is going to be vastly different from glaucoma—because if patients stop taking it, they're going to notice a decrease in vision.

### Q What's the next step in the development of SF0166?

A Results of the DME trial will be presented at the American Academy of Ophthalmology meeting, and the results for the AMD trial will be completed shortly thereafter. The anticipation is that full analysis of the DME results combined with the hopefully positive AMD results will help determine which dosing groups will proceed into the Phase IIb trials. 


## The Choroid in AMD

(Continued from page 31)

optically imaged and has the potential to provide insights into systemic vascular disorders on an individual patient basis.

While still a developing technology, OCT angiography has the potential to radically improve our understanding of retinal and choroidal structures and function, and how they change with age and in AMD.<sup>25</sup> When combined with other conventional imaging techniques, OCT-A may provide a window into the relationship between choroidal and retinal changes in AMD. Advances in OCT-A or possibly other imaging technology are likely to make it possible to establish absolute rates of flow in the choriocapillaris and larger choroidal vessels which will be even more powerful.

Computational methods and systems approaches offer powerful platforms to develop an integrated understanding of the retina and choroid and allow researchers to investigate the interactions between the two tissues. At a time when mining the vast amount of everyday, clinical data has become a challenge, computational models offer an ideal framework in which various clinical observations may be brought together to simulate retinal and choroidal function.

The assessment of the choriocapillaris function may, for instance, be improved by combining angiography of the choroid with novel mathematical frameworks.<sup>3</sup> Cross-disciplinary collaborations may be challenging, but they are key to tackling this complex and multifactorial disease. 

## REFERENCES

1. J. Hogan M, A. Alvarado J, Esperson Weddell J. *Histology of the Human Eye: An Atlas and Textbook*. W. B. Saunders Company; 1971:320.
2. Hayreh SS. Physiological anatomy of the choroidal vascular bed. *Int Ophthalmol*. 1983;6:85-93.

3. Zouache MA, Eames I, Kletner CA, Luthert PJ. Form, shape and function: segmented blood flow in the choriocapillaris. *Sci Rep*. 2016;6:35754.
4. Spraul CW, Lang GE, Grossniklaus HE. Morphometric analysis of the choroid, Bruch's membrane, and retinal pigment epithelium in eyes with age-related macular degeneration. *Invest Ophthalmol Vis Sci*. 1996;37:2724-2735.
5. Spraul CW, Lang GE, Grossniklaus HE, Lang GK. Histologic and morphometric analysis of the choroid, Bruch's membrane, and retinal pigment epithelium in postmortem eyes with age-related macular degeneration and histologic examination of surgically excised choroidal neovascular membranes. *Surv Ophthalmol*. 1999;44 Suppl 1:S10-32.
6. Margolis R, Spaide RF. A pilot study of enhanced depth imaging optical coherence tomography of the choroid in normal eyes. *Am J Ophthalmol*. 2009;147:811-815.
7. Usui S, Ikuno Y, Akiba M, et al. Circadian changes in subfoveal choroidal thickness and the relationship with circulatory factors in healthy subjects. *Invest Ophthalmol Vis Sci*. 2012;53:2300-2307.
8. Ramrattan RS, van der Schaft TL, Mooy CM, de Bruijn WC, Mulder PG, de Jong PT. Morphometric analysis of Bruch's membrane, the choriocapillaris, and the choroid in aging. *Invest Ophthalmol Vis Sci*. 1994;35:2857-2864.
9. Linsenmeier RA, Braun RD. Oxygen distribution and consumption in the cat retina during normoxia and hypoxemia. *J Gen Physiol*. 1992;99:177-197.
10. Linsenmeier RA, Goldstick TK, Blum RS, Enroth-Cugell C. Estimation of retinal oxygen transients from measurements made in the vitreous humor. *Exp Eye Res*. 1981;32:369-379.
11. Bill A, Törnquist P, Alm A. Permeability of the intracocular blood vessels. *Trans Ophthalmol Soc U K*. 1980;100:332-336.
12. Bill A. Intraocular pressure and blood flow through the uvea. *Arch Ophthalmol*. 1962;67:336-348.
13. Black JRM, Clark SJ. Age-related macular degeneration: genome-wide association studies to translation. *Genet Med*. 2016;18:283-289.
14. Hillenkamp J, Hussain AA, Jackson TL, Cunningham JR, Marshall J. The influence of path length and matrix components on aging characteristics of transport between the choroid and the outer retina. *Invest Ophthalmol Vis Sci*. 2004;45:1493-1498.
15. Bhutto I, A. Luty G. Understanding age-related macular degeneration (AMD): Relationships between the photoreceptor/retinal pigment epithelium/Bruch's membrane/choriocapillaris complex. *Mol Aspects Med*. 2012;33:295-317.
16. Johnson PT, Betts KE, Radeke MJ, Hageman GS, Anderson DH, Johnson LV. Individuals homozygous for the age-related macular degeneration risk-conferring variant of complement factor H have elevated levels of CRP in the choroid. *Proc Natl Acad Sci U S A*. 2006;103:17456-17461.
17. Pauleikhoff D, Spital G, Radermacher M, Brumm GA, Lommatzsch A, Bird AC. A fluorescein and indocyanine green angiographic study of choriocapillaris in age-related macular disease. *Arch Ophthalmol*. 1999;117:1353-1358.
18. Alten F, Clemens CR, Heiduschka P, Eter N. Localized reticular pseudodrusen and their topographic relation to choroidal watershed zones and changes in choroidal volumes. *Invest Ophthalmol Vis Sci*. 2013;54:3250-3257.
19. Zouache MA, Eames I, Luthert PJ. Blood flow in the choriocapillaris. *J Fluid Mech*. 2015;774:37-66.
20. Flower RW, Kerczek C von, Zhu L, Ernest A, Eggleton C, Topoleski LD. Theoretical investigation of the role of choriocapillaris blood flow in treatment of subfoveal choroidal neovascularization associated with age-related macular degeneration. *Am J Ophthalmol*. 2001;132:85-93.
21. Linsenmeier RA, Padnick-Silver L. Metabolic dependence of photoreceptors on the choroid in the normal and detached retina. *Invest Ophthalmol Vis Sci*. 2000;41:3117-3123.
22. Shirinifard A, Glazier JA, Swat M, et al. Adhesion failures determine the pattern of choroidal neovascularization in the eye: a computer simulation study. *PLoS Comput Biol*. 2012;8:e1002440.
23. Mullins RF, Khanna A, Schoo DP, et al. Is age-related macular degeneration a microvascular disease? *Adv Exp Med Biol*. 2014;801:283-289.
24. Hageman G. An integrated hypothesis that considers drusen as biomarkers of immune-mediated processes at the RPE-Bruch's membrane interface in aging and age-related macular degeneration. *Prog Retin Eye Res*. 2001;20:705-732.
25. Kashani AH, Chen C-L, Gahm JK, et al. Optical coherence tomography angiography: A comprehensive review of current methods and clinical applications. *Prog Retin Eye Res*. 2017.

**1 INDICATIONS AND USAGE**

EYLEA is a vascular endothelial growth factor (VEGF) inhibitor indicated for the treatment of: **Neovascular (Wet) Age-Related Macular Degeneration (AMD); Macular Edema Following Retinal Vein Occlusion (RVO); Diabetic Macular Edema (DME); Diabetic Retinopathy (DR) in Patients with DME**

**4 CONTRAINDICATIONS**

**4.1 Ocular or Periocular Infections**

EYLEA is contraindicated in patients with ocular or periocular infections.

**4.2 Active Intraocular Inflammation**

EYLEA is contraindicated in patients with active intraocular inflammation.

**4.3 Hypersensitivity**

EYLEA is contraindicated in patients with known hypersensitivity to aflibercept or any of the excipients in EYLEA. Hypersensitivity reactions may manifest as rash, pruritus, urticaria, severe anaphylactic/anaphylactoid reactions, or severe intraocular inflammation.

**5 WARNINGS AND PRECAUTIONS**

**5.1 Endophthalmitis and Retinal Detachments.** Intravitreal injections, including those with EYLEA, have been associated with endophthalmitis and retinal detachments [see *Adverse Reactions (6.1)*]. Proper aseptic injection technique must always be used when administering EYLEA. Patients should be instructed to report any symptoms suggestive of endophthalmitis or retinal detachment without delay and should be managed appropriately [see *Dosage and Administration (2.7)* and *Patient Counseling Information (17)*].

**5.2 Increase in Intraocular Pressure.** Acute increases in intraocular pressure have been seen within 60 minutes of intravitreal injection, including with EYLEA [see *Adverse Reactions (6.1)*]. Sustained increases in intraocular pressure have also been reported after repeated intravitreal dosing with vascular endothelial growth factor (VEGF) inhibitors. Intraocular pressure and the perfusion of the optic nerve head should be monitored and managed appropriately [see *Dosage and Administration (2.7)*].

**5.3 Thromboembolic Events.** There is a potential risk of arterial thromboembolic events (ATEs) following intravitreal use of VEGF inhibitors, including EYLEA. ATEs are defined as nonfatal stroke, nonfatal myocardial infarction, or vascular death (including deaths of unknown cause). The incidence of reported thromboembolic events in wet AMD studies during the first year was 1.8% (32 out of 1824) in the combined group of patients treated with EYLEA. The incidence in the DME studies from baseline to week 52 was 3.3% (19 out of 578) in the combined group of patients treated with EYLEA compared with 2.8% (8 out of 287) in the control group; from baseline to week 100, the incidence was 6.4% (37 out of 578) in the combined group of patients treated with EYLEA compared with 4.2% (12 out of 287) in the control group. There were no reported thromboembolic events in the patients treated with EYLEA in the first six months of the RVO studies.

**6 ADVERSE REACTIONS**

The following potentially serious adverse reactions are described elsewhere in the labeling:

- Hypersensitivity [see *Contraindications (4.3)*]
- Endophthalmitis and retinal detachments [see *Warnings and Precautions (5.1)*]
- Increase in intraocular pressure [see *Warnings and Precautions (5.2)*]
- Thromboembolic events [see *Warnings and Precautions (5.3)*]

**6.1 Clinical Trials Experience.** Because clinical trials are conducted under widely varying conditions, adverse reaction rates observed in the clinical trials of a drug cannot be directly compared to rates in other clinical trials of the same or another drug and may not reflect the rates observed in practice.

A total of 2711 patients treated with EYLEA constituted the safety population in seven phase 3 studies. Among those, 2110 patients were treated with the recommended dose of 2 mg. Serious adverse reactions related to the injection procedure have occurred in <0.1% of intravitreal injections with EYLEA including endophthalmitis and retinal detachment. The most common adverse reactions (≥5%) reported in patients receiving EYLEA were conjunctival hemorrhage, eye pain, cataract, vitreous floaters, intraocular pressure increased, and vitreous detachment.

**Neovascular (Wet) Age-Related Macular Degeneration (AMD).** The data described below reflect exposure to EYLEA in 1824 patients with wet AMD, including 1223 patients treated with the 2-mg dose, in 2 double-masked, active-controlled clinical studies (VIEW1 and VIEW2) for 12 months.

**Table 1: Most Common Adverse Reactions (≥1%) in Wet AMD Studies**

Adverse Reactions	EYLEA (N=1824)	Active Control (ranibizumab) (N=595)
Conjunctival hemorrhage	25%	28%
Eye pain	9%	9%
Cataract	7%	7%
Vitreous detachment	6%	6%
Vitreous floaters	6%	7%
Intraocular pressure increased	5%	7%
Ocular hyperemia	4%	8%
Corneal epithelium defect	4%	5%
Detachment of the retinal pigment epithelium	3%	3%
Injection site pain	3%	3%
Foreign body sensation in eyes	3%	4%
Lacrimation increased	3%	1%
Vision blurred	2%	2%
Intraocular inflammation	2%	3%
Retinal pigment epithelium tear	2%	1%
Injection site hemorrhage	1%	2%
Eyelid edema	1%	2%
Corneal edema	1%	1%

Less common serious adverse reactions reported in <1% of the patients treated with EYLEA were hypersensitivity, retinal detachment, retinal tear, and endophthalmitis.

**Macular Edema Following Retinal Vein Occlusion (RVO).** The data described below reflect 6 months exposure to EYLEA with a monthly 2 mg dose in 218 patients following CRVO in 2 clinical studies (COPERNICUS and GALILEO) and 91 patients following BRVO in one clinical study (VIBRANT).

**Table 2: Most Common Adverse Reactions (≥1%) in RVO Studies**

Adverse Reactions	CRVO		BRVO	
	EYLEA (N=218)	Control (N=142)	EYLEA (N=91)	Control (N=92)
Eye pain	13%	5%	4%	5%
Conjunctival hemorrhage	12%	11%	20%	4%
Intraocular pressure increased	8%	6%	2%	0%
Corneal epithelium defect	5%	4%	2%	0%
Vitreous floaters	5%	1%	1%	0%
Ocular hyperemia	5%	3%	2%	2%
Foreign body sensation in eyes	3%	5%	3%	0%
Vitreous detachment	3%	4%	2%	0%
Lacrimation increased	3%	4%	3%	0%
Injection site pain	3%	1%	1%	0%
Vision blurred	1%	<1%	1%	1%
Intraocular inflammation	1%	1%	0%	0%
Cataract	<1%	1%	5%	0%
Eyelid edema	<1%	1%	1%	0%

Less common adverse reactions reported in <1% of the patients treated with EYLEA in the CRVO studies were corneal edema, retinal tear, hypersensitivity, and endophthalmitis.

**Diabetic Macular Edema (DME).** The data described below reflect exposure to EYLEA in 578 patients with DME treated with the 2-mg dose in 2 double-masked, controlled clinical studies (VIVID and VISTA) from baseline to week 52 and from baseline to week 100.

**Table 3: Most Common Adverse Reactions (≥1%) in DME Studies**

Adverse Reactions	Baseline to Week 52		Baseline to Week 100	
	EYLEA (N=578)	Control (N=287)	EYLEA (N=578)	Control (N=287)
Conjunctival hemorrhage	28%	17%	31%	21%
Eye pain	9%	6%	11%	9%
Cataract	8%	9%	19%	17%
Vitreous floaters	6%	3%	8%	6%
Corneal epithelium defect	5%	3%	7%	5%
Intraocular pressure increased	5%	3%	9%	5%
Ocular hyperemia	5%	6%	5%	6%
Vitreous detachment	3%	3%	8%	6%
Foreign body sensation in eyes	3%	3%	3%	3%
Lacrimation increased	3%	2%	4%	2%
Vision blurred	2%	2%	3%	4%
Intraocular inflammation	2%	<1%	3%	1%
Injection site pain	2%	<1%	2%	<1%
Eyelid edema	<1%	1%	2%	1%

Less common adverse reactions reported in <1% of the patients treated with EYLEA were hypersensitivity, retinal detachment, retinal tear, corneal edema, and injection site hemorrhage.

**6.2 Immunogenicity.** As with all therapeutic proteins, there is a potential for an immune response in patients treated with EYLEA. The immunogenicity of EYLEA was evaluated in serum samples. The immunogenicity data reflect the percentage of patients whose test results were considered positive for antibodies to EYLEA in immunoassays. The detection of an immune response is highly dependent on the sensitivity and specificity of the assays used, sample handling, timing of sample collection, concomitant medications, and underlying disease. For these reasons, comparison of the incidence of antibodies to EYLEA with the incidence of antibodies to other products may be misleading.

In the wet AMD, RVO, and DME studies, the pre-treatment incidence of immunoreactivity to EYLEA was approximately 1% to 3% across treatment groups. After dosing with EYLEA for 24-100 weeks, antibodies to EYLEA were detected in a similar percentage range of patients. There were no differences in efficacy or safety between patients with or without immunoreactivity.

**8 USE IN SPECIFIC POPULATIONS**

**8.1 Pregnancy**

**Risk Summary**

Adequate and well-controlled studies with EYLEA have not been conducted in pregnant women. Aflibercept produced adverse embryofetal effects in rabbits, including external, visceral, and skeletal malformations. A fetal No Observed Adverse Effect Level (NOAEL) was not identified. At the lowest dose shown to produce adverse embryofetal effects, systemic exposures (based on AUC for free aflibercept) were approximately 6 times higher than AUC values observed in humans after a single intravitreal treatment at the recommended clinical dose [see *Animal Data*].

Animal reproduction studies are not always predictive of human response, and it is not known whether EYLEA can cause fetal harm when administered to a pregnant woman. Based on the anti-VEGF mechanism of action for aflibercept [see *Clinical Pharmacology (12.1)*], treatment with EYLEA may pose a risk to human embryofetal development. EYLEA should be used during pregnancy only if the potential benefit justifies the potential risk to the fetus.

All pregnancies have a background risk of birth defect, loss, or other adverse outcomes. The background risk of major birth defects and miscarriage for the indicated population is unknown. In the U.S. general population, the estimated background risk of major birth defects and miscarriage in clinically recognized pregnancies is 2-4% and 15-20%, respectively.

**Data**

**Animal Data**

In two embryofetal development studies, aflibercept produced adverse embryofetal effects when administered every three days during organogenesis to pregnant rabbits at intravenous doses ≥3 mg per kg, or every six days during organogenesis at subcutaneous doses ≥0.1 mg per kg.

Adverse embryofetal effects included increased incidences of postimplantation loss and fetal malformations, including anasarca, umbilical hernia, diaphragmatic hernia, gastroschisis, cleft palate, ectrodactyly, intestinal atresia, spina bifida, encephalomeningocele, heart and major vessel defects, and skeletal malformations (fused vertebrae, sternbrae, and ribs; supernumerary vertebral arches and ribs; and incomplete ossification). The maternal No Observed Adverse Effect Level (NOAEL) in these studies was 3 mg per kg. Aflibercept produced fetal malformations at all doses assessed in rabbits and the fetal NOAEL was not identified. At the lowest dose shown to produce adverse embryofetal effects in rabbits (0.1 mg per kg), systemic exposure (AUC) of free aflibercept was approximately 6 times higher than systemic exposure (AUC) observed in humans after a single intravitreal dose of 2 mg.

**8.2 Lactation**

**Risk Summary**

There is no information regarding the presence of aflibercept in human milk, the effects of the drug on the breastfed infant, or the effects of the drug on milk production/excretion. Because many drugs are excreted in human milk, and because the potential for absorption and harm to infant growth and development exists, EYLEA is not recommended during breastfeeding.

The developmental and health benefits of breastfeeding should be considered along with the mother's clinical need for EYLEA and any potential adverse effects on the breastfed child from EYLEA.

**8.3 Females and Males of Reproductive Potential**

**Contraception**

Females of reproductive potential are advised to use effective contraception prior to the initial dose, during treatment, and for at least 3 months after the last intravitreal injection of EYLEA.

**Infertility**

There are no data regarding the effects of EYLEA on human fertility. Aflibercept adversely affected female and male reproductive systems in cynomolgus monkeys when administered by intravenous injection at a dose approximately 1500 times higher than the systemic level observed humans with an intravitreal dose of 2 mg. A No Observed Adverse Effect Level (NOAEL) was not identified. These findings were reversible within 20 weeks after cessation of treatment [see *Nonclinical Toxicology (13.1)*].

**8.4 Pediatric Use.** The safety and effectiveness of EYLEA in pediatric patients have not been established.

**8.5 Geriatric Use.** In the clinical studies, approximately 76% (2049/2701) of patients randomized to treatment with EYLEA were ≥65 years of age and approximately 46% (1250/2701) were ≥75 years of age. No significant differences in efficacy or safety were seen with increasing age in these studies.

**17 PATIENT COUNSELING INFORMATION**

In the days following EYLEA administration, patients are at risk of developing endophthalmitis or retinal detachment. If the eye becomes red, sensitive to light, painful, or develops a change in vision, advise patients to seek immediate care from an ophthalmologist [see *Warnings and Precautions (5.1)*].

Patients may experience temporary visual disturbances after an intravitreal injection with EYLEA and the associated eye examinations [see *Adverse Reactions (6)*]. Advise patients not to drive or use machinery until visual function has recovered sufficiently.

Manufactured by:  
**Regeneron Pharmaceuticals, Inc.**  
777 Old Saw Mill River Road  
Tarrytown, NY 10591

Issue Date: June 2017  
Initial U.S. Approval: 2011

Based on the May 2017 EYLEA® (aflibercept) Injection full Prescribing Information.

EYLEA is a registered trademark of Regeneron Pharmaceuticals, Inc.  
© 2017, Regeneron Pharmaceuticals, Inc. All rights reserved.

**REGENERON**

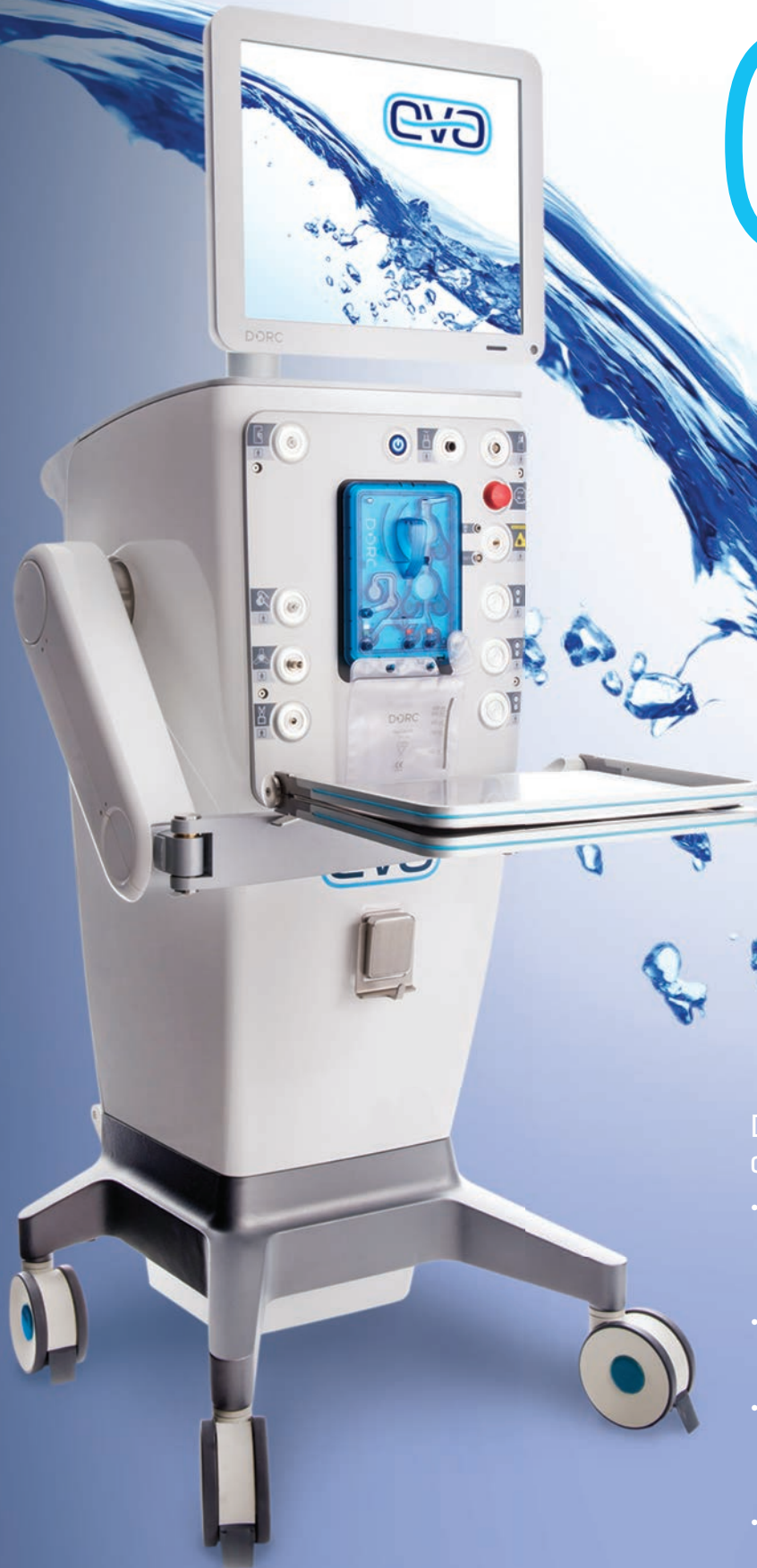

inspired by you created by DORC



[www.dorc.eu](http://www.dorc.eu)

Visit us at AAO Booth #501  
Nov 11 – Nov 14



DORC's history in innovation is changing the surgical landscape.

- **TDC: two-dimensional cutter**
  - Up to 16,000 cpm\*
  - Port open design enhances surgeon efficiency & predictability
- **Dual capabilities**
  - Phaco – MICS 1.8 capable
  - Vitrectomy – 20g, 23g, 25g & 27g options
- **VTi fluidics**
  - Linear Displacement Pump provides surgeons with enhanced stability & control
  - Vacuum or Flow options on the fly
- **LED illumination**
  - 10,000 hours of consistent light output



D.O.R.C. International



Dutch Ophthalmic Research Center

\* The TDC vitrectome cuts at 8,000 cpm and is designed to cut on the return of each stroke, doubling the cut rate.





# POWER TO PREVAIL

As demonstrated in phase 3 clinical trials evaluating BCVA,\* as measured by ETDRS letters, in patients with Wet AMD, Macular Edema following RVO, DME, and by ETDRS-DRSS<sup>†</sup> in DR in Patients with DME,<sup>1</sup> as well as your clinical experience

Start with EYLEA for proven efficacy outcomes<sup>1</sup>

AMD = Age-related Macular Degeneration; DME = Diabetic Macular Edema; DR = Diabetic Retinopathy.

## INDICATIONS AND IMPORTANT SAFETY INFORMATION

### INDICATIONS

- EYLEA<sup>®</sup> (aflibercept) Injection is indicated for the treatment of patients with Neovascular (Wet) Age-related Macular Degeneration (AMD), Macular Edema following Retinal Vein Occlusion (RVO), Diabetic Macular Edema (DME), and Diabetic Retinopathy (DR) in Patients with DME.

### CONTRAINDICATIONS

- EYLEA<sup>®</sup> (aflibercept) Injection is contraindicated in patients with ocular or periocular infections, active intraocular inflammation, or known hypersensitivity to aflibercept or to any of the excipients in EYLEA.

### WARNINGS AND PRECAUTIONS

- Intravitreal injections, including those with EYLEA, have been associated with endophthalmitis and retinal detachments. Proper aseptic injection technique must always be used when administering EYLEA. Patients should be instructed to report any symptoms suggestive of endophthalmitis or retinal detachment without delay and should be managed appropriately. Intraocular inflammation has been reported with the use of EYLEA.
- Acute increases in intraocular pressure have been seen within 60 minutes of intravitreal injection, including with EYLEA. Sustained increases in intraocular pressure have also been reported after repeated intravitreal dosing with VEGF inhibitors. Intraocular pressure and the perfusion of the optic nerve head should be monitored and managed appropriately.
- There is a potential risk of arterial thromboembolic events (ATEs) following intravitreal use of VEGF inhibitors, including EYLEA. ATEs are defined as nonfatal stroke, nonfatal myocardial infarction, or vascular death (including deaths of unknown cause). The incidence of reported thromboembolic events in wet AMD studies during the first year was 1.8% (32 out of 1824) in the combined group of patients treated with EYLEA. The incidence in the DME studies from baseline to week 52 was 3.3% (19 out of 578) in the combined group of patients treated with EYLEA compared with 2.8% (8 out of 287) in the control group; from baseline to week 100, the incidence was 6.4% (37 out of 578) in the combined group of patients treated with EYLEA compared with 4.2% (12 out of 287) in the control group. There were no reported thromboembolic events in the patients treated with EYLEA in the first six months of the RVO studies.

### ADVERSE REACTIONS

- Serious adverse reactions related to the injection procedure have occurred in <0.1% of intravitreal injections with EYLEA including endophthalmitis and retinal detachment.
- The most common adverse reactions (≥5%) reported in patients receiving EYLEA were conjunctival hemorrhage, eye pain, cataract, vitreous floaters, intraocular pressure increased, and vitreous detachment.

**Please see adjacent Brief Summary.**

\*Best-corrected visual acuity.

<sup>†</sup>Early Treatment Diabetic Retinopathy Study—Diabetic Retinopathy Severity Scale: an established grading scale for measuring the severity of DR.

**Reference: 1.** EYLEA<sup>®</sup> (aflibercept) Injection full U.S. Prescribing Information. Regeneron Pharmaceuticals, Inc. May 2017.

EYLEA is a registered trademark of Regeneron Pharmaceuticals, Inc.

**REGENERON**