

# New American Academy of Neurology Disease-Modifying Treatment Guidelines: Impact on Clinical Practice

Key concepts and checklists provide a framework for optimal decision making with patients.

By Kedar R. Mahajan, MD, PhD and Alexander Rae-Grant, MD, FRCP(C), FAAN



New therapies and updated multiple sclerosis (MS) treatment guidelines have created opportunities to improve care. The 2017 American Academy of Neurology (AAN) evidence-based practice guidelines

provide a systematic review on the use of disease-modifying therapies (DMTs) for adults with MS. The guideline panel developed 30 recommendations pertaining to starting, switching, and stopping DMTs. This review provides an overview of these topics and elaborates on key points with cross-references to the section and recommendation number within the AAN guideline given in **green**.<sup>1</sup>

Starting DMTs requires confirming the diagnosis, selecting the appropriate treatment for the appropriate patient, pretesting, evaluating efficacy, and monitoring safety. MS is a highly variable and individual condition requiring long-term therapy. This requires an engaged and informed patient and a clinician who respects patient autonomy and factors. We explore key concepts to provide neurologists the framework for optimal decisions and provide 2 case examples. We also provide checklists for clinicians to ensure important topics are addressed.

## Highlights of the New American Academy of Neurology Disease-Modifying Treatment Guideline

The 2017 AAN DMT guidelines<sup>1</sup> allow for reassessing treatment, particularly as the expectation for decreasing relapses and MRI lesions grows with more efficacious therapies. These topics are covered, referencing specific AAN recommendations, and expanded to provide practical guidance.

Treatment for MS first requires an appropriate diagnosis.

Nonspecific white matter lesions can be interpreted as possible demyelinating disease. Patients may read online that their symptoms of fatigue, numbness, and brain fog are seen with MS. Unfortunately, patients are often misdiagnosed with MS as a result of nonspecific MRI lesions and symptoms.

Initiating a DMT after verifying the diagnosis should be patient-centric with clarification of the role of DMTs in reducing relapses and new MRI lesions [**Starting Recommendation 9**], potentially slowing progression of disability, and reviewing potential adverse effects with particular DMTs. Readiness to initiate treatment and identify any barriers is necessary.

There are no current high-quality studies comparing initiation treatment with a high-efficacy strategy versus initiating with stepped care to guide decision making. Often, the decision of which DMT to start is affected by managed care and out-of-pocket costs and appeals or applying for financial assistance can help select the desired therapy.

Patients with a single episode of clinical demyelination and 2 or more MRI lesions consistent with demyelination should be offered DMT. Treatment does not depend on a formal diagnosis of MS, and earlier treatment is preferable to a wait-and-see approach. Patients with relapsing-remitting MS should be offered DMTs in a conversation that respects their individual decision making [**Starting Recommendation 7**]. When patients decide to defer starting DMT, careful clinical and MRI monitoring is important to assess for new disease activity that might affect their decision [**Starting Recommendation 8**].

A treatment algorithm (Figure) should be individualized for each patient with core features of 1) an indication for treatment, 2) evaluating safety prior to initiating and during treatment, 3) review-

ing adverse effects and compliance, and 4) addressing symptoms, wellness, and ancillary needs. Checklist 1 provides a list of issues to address in follow-up visits.

### Avoiding Misdiagnosis

Using neuropathologic confirmation, estimates of MS misdiagnosis range from 5% to 10%.<sup>2</sup> A recent study across 4 major academic MS centers identified 110 misdiagnoses of MS, some with a duration greater than 20 years, with 70% exposed to immunomodulating therapies.<sup>3</sup> Common MS mimics were migraine, fibromyalgia, nonspecific symptoms with an abnormal MRI, psychogenic disorder, and neuromyelitis optica spectrum disorder. Contributors to misdiagnosis included inappropriate use of diagnostic criteria with an absence of a typical demyelinating attack, MRI findings of dissemination in space (DIS) criteria but with nonspecific symptoms, lack of objective examination or imaging findings, misclassification of juxtacortical or periventricular lesions to meet DIS, and

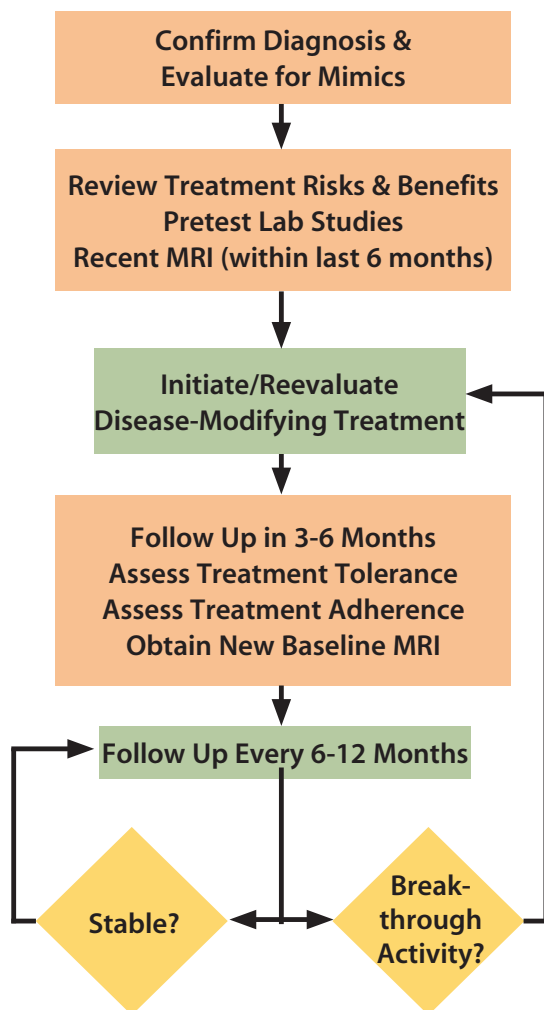


Figure. Overview of treatment strategy for patients with multiple sclerosis.

### Checklist 1. Topics to Address During Semiannual/Annual Follow-Up Visits

- Review history for relapses and evaluate changes in clinical examination
- Review/order monitoring laboratory studies and MRI
- Ancillary care:
  - Physical, occupational, and speech therapy
  - Psychology, psychiatry, and neuropsychiatric testing
  - Financial counseling
  - Social work
  - Prescriptions for assistive devices for ambulation and accommodations for accessibility at home
  - Paperwork for employment
  - Handicap placards
- Wellness
  - Diet including vitamin D
  - Exercise and stretching
  - Lifestyle behaviors
  - Comorbidities
- Symptomatic management
  - Dysesthesias
  - Pain
  - Spasticity
  - Bladder impairment
  - Fatigue

determining dissemination in time when variability was due to MRI slice orientation.<sup>3</sup> Misdiagnosis may exist for an indefinite period, preclude appropriate treatment, and add unnecessary risks and expenses. It is useful to consider a second opinion in atypical or equivocal cases.

### Starting Disease-Modifying Treatment

#### Patient-Centered Approach

As newly diagnosed patients can be overwhelmed and have difficulty recalling information [Starting Recommendation 1], discussing the concepts in Checklist 2 during a follow-up visit [Starting Recommendation 4] and addressing depression and anxiety [Starting Recommendation 5] may be helpful. If a decision is made to defer DMT initiation, a surveillance brain MRI is more effective than waiting for a relapse because new and enlarging T2 lesions can occur on average 5 to 10 times per each new relapse.<sup>4</sup>

Grouping DMTs into categories by efficacy or route of administration may simplify the approach (Table). Emphasizing the role of DMTs in preventing inflammatory lesions but not treating preexisting injury is important [Starting Recommendation 3].

Aversion to injections, difficulty swallowing pills, and difficulty remembering to take medication can influence the preferred route of administration. Flu-like symptoms or fatigue with interferons, injection site reactions and hair loss with teriflunomide, and flushing/diarrhea with dimethyl fumarate may decrease patients' adherence to a medication regimen [Starting: Recommendations 2 and 6]. Comorbidities and medications should be reviewed for any interactions with DMTs [Starting: Recommendation 5] (eg, hypertension or  $\beta$ -blocker use with fingolimod).

Patients should be informed of a risk of rebound activity with discontinuation of fingolimod<sup>5</sup> and natalizumab<sup>6</sup> and the need to repeat the first dose observation if fingolimod is stopped for 14 days. Although uncommon, the risk of malignancies and opportunistic infections should be mentioned [Switching: Recommendation 7].<sup>7</sup> In patients with MS, progressive multifocal leukoencephalopathy (PML) unconfounded with prior DMT exposure has been reported with dimethyl fumarate and fingolimod<sup>8</sup> and in 4 carryover cases with ocrelizumab.

Comprehensive care also entails ancillary care, wellness, symptomatic management (Checklist 2), pregnancy counseling in women of childbearing age and men considering teriflunomide, and addressing any financial barriers to care.

### Initiation Paradigms

Few head-to-head clinical trials are available, and cross-trial comparisons are challenging because of differences in design

#### Checklist 2. Topics to Address When Initiating Disease-Modifying Therapy

- Assess patient's readiness to initiate
- Review role in reduced risk for relapses and consequent disability rather than symptomatic improvement or repair of prior injury/deficits
- Review adverse effects and issues with tolerability
- Review uncommon but potential risk of permanent harm/death with certain therapies
- Evaluate concomitant medications
- Address factors influencing compliance, importance of adherence, and risks associated with poor compliance
- Counsel on risks of DMTs during pregnancy
- Review the need for ongoing office visits to evaluate for adherence, safety, and efficacy of DMTs, surveillance MRIs for efficacy, as well as progressive multifocal leukoencephalopathy (PML), and monitoring for laboratory abnormalities.
- Order and review pretesting laboratory studies, ECG, and optical coherence tomography (OCT).

and populations. Whether to initiate highly efficacious therapy first or escalate following breakthrough activity that occurred when a patient was taking low or moderate efficacy DMTs is a hot debate (see Ongoing Research). Individuals with multiple new or enlarging T2 or gadolinium-enhancing lesions should be considered as having high disease activity and offered moderate to highly efficacious therapies (Clinical Case 1, Table ) [Starting: Recommendation 14]. Individuals with spinal cord lesions have a greater risk of future cord lesions,<sup>9</sup> and greater risk of disability,<sup>10</sup> prompting consideration of more effective DMT. On an individual level, the trajectory of clinical disability, frequency of clinical relapses, and evolution of MRI lesion burden can be helpful in deciding the risks and benefits of initiating a low, moderate, or highly efficacious DMT.

### Switching DMTs

Regardless of the DMT, surveillance for clinical relapses, ongoing disease activity with MRI (minimum of annual brain imaging), compliance (tolerability and adherence) [Switching: Recommendation 3], and adverse events (symptoms or laboratory abnormalities) [Switching: Recommendations 4-7] is recommended. As DMTs may take time to become clinically effective, obtaining a new baseline MRI 3 to 6 months after initiating a DMT (with a repeat MRI in 6-12 months) will allow for a fair assessment of its efficacy [Switching: Recommendation 1]. Patients should report new or worsening symptoms [Starting: Recommendation 3] persisting longer than 24 hours. Although DMTs do not completely prevent relapses or new MRI activity, switching to highly efficacious therapies should be considered if there is breakthrough activity when a patient is taking lower-efficacy medications [Switching: Recommendation 2].

Risks associated with DMTs are not static and can change over time. Seroconversion to John Cunningham virus (JCV) positivity or rising JCV titers should prompt consideration for switching from natalizumab given the increased risk for PML [Starting: Recommendation 16]. Persistent natalizumab neutralizing antibodies may decrease efficacy and are associated with allergic reactions [Switching: Recommendation 8]. Following discontinuation of natalizumab [Switching: Recommendation 9], initiation of an alternative DMT (eg, fingolimod or antiCD20 therapy) within 3 months may reduce risk for recurrence. As DMTs may cause lymphopenia, absolute lymphocyte counts should ideally recover to greater than 500 cells per mL prior to switching to an alternative DMT. Adverse effects potentially associated with a DMT, such as malignancy or opportunistic infections, should raise consideration for switching DMTs [Switching: Recommendation 7].

### Clinically Isolated Syndrome

DMTs can be considered if there is more than 1 brain lesion typical of MS and a single clinical demyelinating event typical of MS<sup>1</sup> to reduce risk of relapses.<sup>11</sup> Serial imaging at least annually for the first 5 years may be useful to identify new lesions that would support the diagnosis of MS.

**TABLE. DISEASE-MODIFYING THERAPIES**

EFFICACY	ROUTE	MECHANISM OF ACTION	ADVERSE EFFECTS	PRETESTING	MONITORING
Low					
Interferon- $\beta$	SC/IM	Immunomodulation: Th1 to Th2 shift, inhibits lymphocyte proliferation and alters cytokine production	Injection site reactions, flu-like symptoms, headache, lymphopenia, hepatotoxicity, depression, spasticity	HCG, CBC, LFTs	Every 6 months: CBC, LFTs Every 12 months: TSH
Glatiramer acetate	SC	Immunomodulation: competitively binds to APCs instead of myelin antigen	Immediate postinjection reaction, lipoatrophy, uncommon idiosyncratic reaction	—	—
Teriflunomide	PO	Cell depletion: inhibits DHODH, de novo pyrimidine synthesis, and T- and B-cell proliferation	Diarrhea, nausea, alopecia, bone marrow suppression, hepatotoxicity, peripheral neuropathy, teratogenicity	HCG, CBC, LFTs, PPD/IGRA	Every month: LFTs Every 6 months: CBC
Medium					
Dimethyl fumarate	PO	Immunomodulation: activates Nrf2 and inhibits NF $\kappa$ B	Dyspepsia, nausea, vomiting, abdominal cramps, diarrhea, flushing, PML	CBC, LFTs, HCG	Every 6 months: CBC, LFTs
Fingolimod	PO	Impairs lymphocyte trafficking out of lymph nodes by modulating sphingosine 1-phosphate	Headache, hypertension, transaminitis, lymphopenia, HSV, macular edema, bradycardia, PML, dermatologic cancers	EKG, OCT, VZV, CBC, LFTs, HCG	In 3 months: repeat OCT, ECG, CBC, LFTs Every 6 months: LFTs, CBC
High					
Natalizumab	IV	Impairs lymphocyte trafficking hmAb targeting $\alpha$ 4-integrin preventing mononuclear cell entry into CNS ( $\alpha$ 4 $\beta$ 1)	Infusion reactions, hepatotoxicity, PML, HSV encephalitis, headache	JCV, CBC, LFTs, HCG	Every 3 months: JCV Every 6 months: LFTs, MRI After first 6 months: natalizumab neutralizing antibodies
Alemtuzumab	IV	Cell depletion hmAb targets CD52 on T/B cells, monocytes, and eosinophils	Secondary autoimmunity (eg thyroid, ITP, glomerular nephropathy), infusion reactions, malignancy, infections, pneumonitis	CBC, Cr, LFTs, TSH, VZV, HIV, hepatitis, HCG, UA, skin examination, GYN, PPD/IGRA	<b>For 48 months:</b> Every month: CBC, BUN/Cr, UA Every 3 months: TSH, skin exam, GYN Every 6 months: MRI
Ocrelizumab	IV	Cell depletion rhAb targets CD20 on pre and mature B cells	Infusion reactions, reactivation of hepatitis B, possible malignancy	CBC, LFTs, HCG, PPD/IGRA <sup>a</sup> , remote hepatitis panel <sup>b</sup> , VZV <sup>a</sup>	Every 6 months: MRI

<sup>a</sup>: Pretesting for tuberculosis and VZV suggested to avoid risk of reactivation of latent infection.

<sup>b</sup>: Hepatitis B surface antigen, total core antibody, and qualitative surface antibody; hepatitis C antibody.

Abbreviations: APCs, antigen presenting cells; BUN, blood urea nitrogen; CBC, complete blood count with differential; Cr, creatinine; DHODH, dihydroorotate dehydrogenase; ECG, electrocardiogram; GI, gastrointestinal; GYN, gynecological screening for human papilloma virus and cervical dysplasia, human chorionic gonadotropin; hmAb, human monoclonal antibody; HSV, herpes simplex virus; IM, intramuscular; ITP, idiopathic thrombocytopenic purpura; IV, intravenous; JCV, John Cunningham virus titers with STRATIFY reflex; LFT, liver function panel; Nrf2, nuclear factor E2-related factor-2; OCT, optical coherence tomography; PML, progressive multifocal leukoencephalopathy; PO, oral; PPD, purified protein derivative tuberculosis test; rhAb, recombinant humanized monoclonal antibody; SC, subcutaneous; TSH, thyroid-stimulating hormone; UA, urinalysis; VZV, varicella-zoster virus immunoglobulin.



## ▶▶▶ Clinical Case 1: A Patient With Relapsing Multiple Sclerosis

A right-handed woman, age 32, presents to the emergency department with paresthesias in her right foot that began 2 days earlier and progressed to heaviness in the right lower extremity while climbing stairs and some difficulty with her handwriting within the last day. Her neurologic examination is notable for mild right hemiparesis, hypoesthesia in the right upper and lower extremities, brisk reflexes on the right, and an unequivocal plantar response on the right. She is admitted for further evaluation.

Her brain MRI, with and without contrast, shows a moderate T2-hyperintense lesion burden with multiple ovoid and periventricular lesions and 1 gadolinium-enhancing right juxtacortical lesion. Her cervical and thoracic spinal cord MRI reveals a right dorsolateral C4 lesion with gadolinium enhancement and a normal thoracic cord.

She is diagnosed with MS and given methylprednisolone 1 g daily for 3 days resulting in some improvement in her right hemiparesis but still has paresthesias in her right lower extremity. She is discharged with outpatient therapy and gabapentin.

Two weeks later, she reports improvement in her right hemiparesis and paresthesias. Given a moderate lesion burden and 2 enhancing lesions on her MRIs, a moderate or highly effective therapy is advisable. She is not currently planning pregnancy. After discussing options, she favors fingolimod. She asks about wellness and reports occasional spasms when going to bed. She is recommended to follow the Mediterranean diet, stretching daily particularly at bedtime, and aerobic exercise for 150 minutes a week. She is ordered pretesting (Table 1).

A week later, her test results are unremarkable except for a 25-hydroxy vitamin D level of 17.2 ng/mL. She is called and agrees to proceed with fingolimod and vitamin D supplementation (50,000 IU weekly for 12 weeks followed by 4,000 IU daily).

On follow-up 3 months later, a repeat MRI brain to establish a new baseline has unchanged findings from her initial MRI. Symptomatically she is doing well without any paresthesias or spasms while on gabapentin. You set up follow-up visits at 6-month intervals for the immediate future and appropriate monitoring lab orders, including an annual vitamin D level.

### Treatment in Progressive Disease

Clinical relapses and ongoing MRI activity (new/enlarging T2 or gadolinium-enhancing lesions) even in patients with progressive disease suggest a benefit from continuing or initiating a DMT (Clinical Case 2). Ocrelizumab is approved for primary progressive MS, particularly if the patient exhibits evidence of ongoing MRI activity or relapses [Starting: Recommendation 17]. The risk of pneumonia and urinary tract infections should be considered particularly in higher-risk individuals with greater disability. Given the potential

for certain cancers, routine surveillance for cancer based on a patient's age and risk factors should be planned.

### Monitoring

#### Medication Adherence

Assessing adherence to medications during follow-up visits is necessary to reduce risk of relapses and for safety [Starting: Recommendation 10]. Injection site discomfort, flu-like symptoms with interferons, greater disability, and lower treatment satisfaction/quality-of-life scores are associated with decreased compliance.<sup>12</sup> Switching therapies despite stable disease activity may be necessary if physical disability (eg, hand dexterity for injection administration) or cognitive impairment (eg, remembering doses) are barriers. Poor compliance with fingolimod is particularly problematic as the first dose observation period needs to be repeated if discontinued for greater than 2 weeks due to upregulation of cardiac sphingosine 1-phosphate receptors and risk of bradycardia.

#### Safety

It is feasible to find a DMT with an appropriate risk/benefit profile for both the patient and clinician given the multitude of available options. DMTs are generally safe when care is taken to evaluate pretesting and continued monitoring (Table). Of the FDA-approved medications, Risk Evaluation and Mitigation Strategy (REMS) programs are available for alemtuzumab, fingolimod, and natalizumab (Tysabri Outreach: Unified Commitment to Health; TOUCH) and require clinical and laboratory assessments to ensure safety. Reproductive plans should be addressed in women of childbearing age and men considering teriflunomide.

#### Financial Barriers

Financial considerations should not preclude patients from receiving a DMT [Starting: Recommendation 15]. There is considerable variability in the DMT approval process between insurance carriers, and they may require failure of one or more low- to moderate-efficacy DMTs prior to approving a high-efficacy medication. Appeals outlining the rationale for initiating a highly efficacious therapy in a patient with active disease or greater risk of disability from brainstem<sup>13</sup> or spinal cord lesions,<sup>14</sup> noting requisite pretesting, and documentation of the diagnosis and office visit note are necessary. Templates of appeals are available through the National MS Society. Additionally, financial assistance programs are available through the drug manufacturer for individuals who qualify based on their income.

#### Pregnancy Counseling

Women of childbearing age should be counseled on potential risks associated with DMTs (See also *Reproductive Issues for Patients With Multiple Sclerosis*, p. 63) and should plan to discontinue DMT prior to pregnancy unless the risk of relapse

is expected to exceed potential harm. Cyclophosphamide can also affect male fertility. Teriflunomide should be avoided in women of childbearing potential and in any couple planning pregnancy. As the drug can be detected up to 2 years following discontinuation, there is a risk of teratogenic-

## ▶▶▶ Clinical Case 2: A Patient With Progressive Multiple Sclerosis

A man with a diagnosis of MS for 21 years, age 67, presents for a follow-up visit. He has occasional falls, left lower extremity weakness, moderate fatigue, urinary urgency, forgetfulness, and difficulty multitasking. He is still working full-time in sales but experiences considerable fatigue in the afternoon. He denies any relapses throughout his course but reports his balance and ambulation have worsened considerably in the last year. His MRIs have shown moderate brain T2 lesion burden and mild brain atrophy, and he has never had spinal cord imaging. He was initially treated with interferon- $\beta$  for 2 years, switched to glatiramer acetate for 3 years due to breakthrough activity, and has been off therapy since then due to loss of his medical insurance. Despite having insurance for the last 5 years, he had not been seen in follow-up.

His left foot drop and moderate spasticity in his left lower extremity and sensory loss are worse compared to 5 years ago, and he has a new finding of mild right hip flexor weakness and an extensor plantar response on the right. A repeat brain MRI is ordered, he is started on baclofen 5 mg daily with a plan to uptitrate to 10 mg twice daily over 2 weeks, and he is referred for outpatient rehabilitation.

He returns 1 month later with a slight improvement in his ambulation but still endorses motor fatigability after walking more than 50 meters. His brain MRI shows 2 new small periventricular lesions compared to his prior MRI results 5 years ago. His clinical course appears consistent with primary progressive MS, and there is interval MRI activity suggesting ongoing inflammation. After discussing options, he favors starting ocrelizumab, and pretesting is ordered (Table). MRIs of the cervical and thoracic cord are ordered to establish a baseline.

A week later, his laboratory studies are notable for negative varicella-zoster virus (VZV) IgG titers, and he schedules varicella vaccination prior to his first cycle. His MRIs a month later show patchy cervical lesions C3-C5 and one right lateral T4 lesion, all without gadolinium enhancement. He returns for a follow-up appointment in 6 months and reports tolerating ocrelizumab without any adverse effects. He denies any recent falls, has been discharged from outpatient rehabilitation, and has started exercising more routinely. For symptomatic management, oxybutynin 5 mg daily is started for his urinary urgency after he is cautioned of potential anticholinergic side effects. Dalfampridine is considered, and a basic metabolic panel is ordered for a therapeutic trial.

ity from both sperm and maternal exposure. Accelerated elimination chelation therapy for women and men planning pregnancy with cholestyramine or activated charcoal is recommended until serum levels are  $<0.02$  mcg/mL [Starting: Recommendation 12].<sup>9</sup>

### Discontinuing DMTs

Some patients will choose to stop DMTs; in these cases, careful MRI and clinical follow-up is important [Stopping: Recommendation 1]. Patients with secondary progressive MS, who do not have ongoing clinical relapses or MRI activity, and are not ambulatory for  $>2$  years, can also consider discontinuation [Stopping: Recommendation 2]. Individuals with CIS on DMT may also consider discontinuing if stable clinically and radiographically [Stopping: Recommendation 3].

The efficacy of DMTs is in part *what does not happen*, such as avoidance of relapses or new lesion formation, making decisions about discontinuation difficult. Surveillance MRIs can be useful to determine whether the clinical stability was attributable to the DMT or the natural clinical course. However, as cortical lesions are unapparent on conventional imaging and asymptomatic spinal cord lesions not routinely imaged can be missed, determining ongoing activity off DMT can be challenging.

### Ongoing Research

The DELIVER-MS<sup>a</sup> and TREAT-MS<sup>b</sup> clinical trials are studies designed to determine whether initiation of highly effective monoclonal therapies (alemtuzumab, natalizumab, rituximab, or ocrelizumab) compared to low- to medium-efficacy medications will affect outcome measures over 3 to 4 years: MRI atrophy, new/enlarging T2-weighted hyperintense lesions, T1-weighted hypointense lesions, clinical disability measures, quality of life, disability progression, number of relapses, and optical coherence tomography retinal nerve fiber layer thickness.

To address whether it is safe to discontinue DMTs in patients with low risk of relapses (ie, age 55 and over with stable imaging and absence of a relapse in the last 5 years), the DISCOMS<sup>c</sup> trial is randomizing 300 patients 1:1 for either remaining on their current DMT or discontinuing). Outcome measures include new MRI activity when assessed every 6 months for 2 years, quality of life, and disability.

Novel biomarkers of disease activity, such as serum neurofilament light chain,<sup>15</sup> may improve detection of ongoing activity that may be 1) unapparent on conventional imaging (eg, cortical lesions), 2) occurring in a region not being routinely imaged (eg, thoracic cord), and 3) offer an alternative to MRIs to save costs or in individuals where MRI is not possible.

(Continued on page 38)

a DELIVER MS (NCT03535298), Determining the effectiveness of early intensive versus escalation approaches for the treatment of relapsing-remitting MS.

b TREAT MS (NCT 03500328), Traditional versus early aggressive therapy for MS.

c DISCOMS (NCT03073603), Discontinuation of disease-modifying therapies in MS.

(Continued from page 27)

## Conclusions

Care of patients with MS requires a systematic and individually tailored approach. Ensuring the appropriate diagnosis and promptly initiating therapy are important initial steps. Continued laboratory and MRI surveillance, reviewing pregnancy planning, reassessing treatment efficacy, ensuring compliance, symptomatic management, lifestyle modifications, reviewing quality of life, and arranging for ancillary care needs are required for comprehensive care. The overarching goals of these interventions are to limit/prevent further disability and optimize quality of life. ■

1. Rae-Grant A, Day GS, Marrie RA, et al. Practice guideline recommendations summary: disease-modifying therapies for adults with multiple sclerosis: report of the Guideline Development, Dissemination, and Implementation Subcommittee of the American Academy of Neurology. *Neurology*. 2018;90(17):777-788.
2. Engell T. A clinico-pathoanatomical study of multiple sclerosis diagnosis. *Acta Neurol Scand*. 1988;78(1):39-44.
3. Solomon AJ, Bourdette DN, Cross AH, et al. The contemporary spectrum of multiple sclerosis misdiagnosis: a multi-center study. *Neurology*. 2016;87(13):1393-1399.
4. Sormani MP, Bruzzi P. MRI lesions as a surrogate for relapses in multiple sclerosis: a meta-analysis of randomised trials. *Lancet Neurol*. 2013;12(7):669-676.
5. Frau J, Sormani MP, Signori A, et al. Clinical activity after fingolimod cessation: disease reactivation or rebound? [Published online June 1, 2018.] *Eur J Neurol*.
6. Sorensen PS, Koch-Henriksen N, Petersen T, et al. Recurrence or rebound of clinical relapses after discontinuation of natalizumab therapy in highly active MS patients. *J Neurol*. 2014;261(6):1170-1177.
7. Hauser SL, Bar-Or A, Comi G, et al. Ocrelizumab versus interferon beta-1a in relapsing multiple sclerosis. *N Engl J Med*. 2017;376(3):221-234.
8. Ho PR, Koendgen H, Campbell N, et al. Risk of natalizumab-associated progressive multifocal leukoencephalopathy in patients with multiple sclerosis: a retrospective analysis of data from four clinical studies. *Lancet Neurol*. 2017;16(11):925-933.
9. Hua LH, Donlon SL, Sobhanian MJ, et al. Thoracic spinal cord lesions are influenced by the degree of cervical spine involvement in multiple sclerosis. *Spinal Cord*. 2015;53(7):520-525.
10. Valsasina P, Aboulwafa M, Preziosa P, et al. Cervical cord T1-weighted hypointense lesions at MR imaging in multiple sclerosis: relationship to cord atrophy and disability [published online April 17, 2018]. *Radiology*.
11. Comi G, De Stefano N, Freedman MS, et al. Comparison of two dosing frequencies of subcutaneous interferon beta-1a in patients with a first clinical demyelinating event suggestive of multiple sclerosis (REFLEX): a phase 3 randomised controlled trial. *Lancet Neurol*. 2012;11(1):33-41.
12. Saiz A, Mora S, Blanco J, et al. Therapeutic compliance of first line disease-modifying therapies in patients with multiple sclerosis: COMPLIANCE Study. *Neurologia*. 2015;30(4):214-222.
13. Habek M. Evaluation of brainstem involvement in multiple sclerosis. *Exp Rev Neurother*. 2013;13(3):299-311.
14. Tiftikcioglu BI, Ilgezdi I, Zorlu Y, et al. Long-term disability and progression in spinal onset multiple sclerosis. *Acta Neurol Belg*. 2018;118(2):217-225.
15. Siller N, Kuhle J, Muthuraman M, et al. Serum neurofilament light chain is a biomarker of acute and chronic neuronal

### Kedar R. Mahajan, MD, PhD

Mellen Center for Multiple Sclerosis Treatment and Research  
Cleveland Clinic  
Cleveland, OH

### Alexander Rae-Grant, MD, FRCP(C), FAAN

Mellen Center for Multiple Sclerosis Treatment and Research  
Cleveland Clinic  
Cleveland, OH

### Disclosures

*No targeted funding related to this article was received. K.R.M. is funded by National Multiple Sclerosis Society Clinician Scientist Development Award FAN-1507-05606. K.R.M. has received personal fees from Sanofi Genzyme. A.R.-G. receives royalties from 2 textbooks (1 on neurology and 1 on MS) and organizes and receives honoraria for grand rounds and neurology review courses.*