

Septoplasty and Turbinoplasty

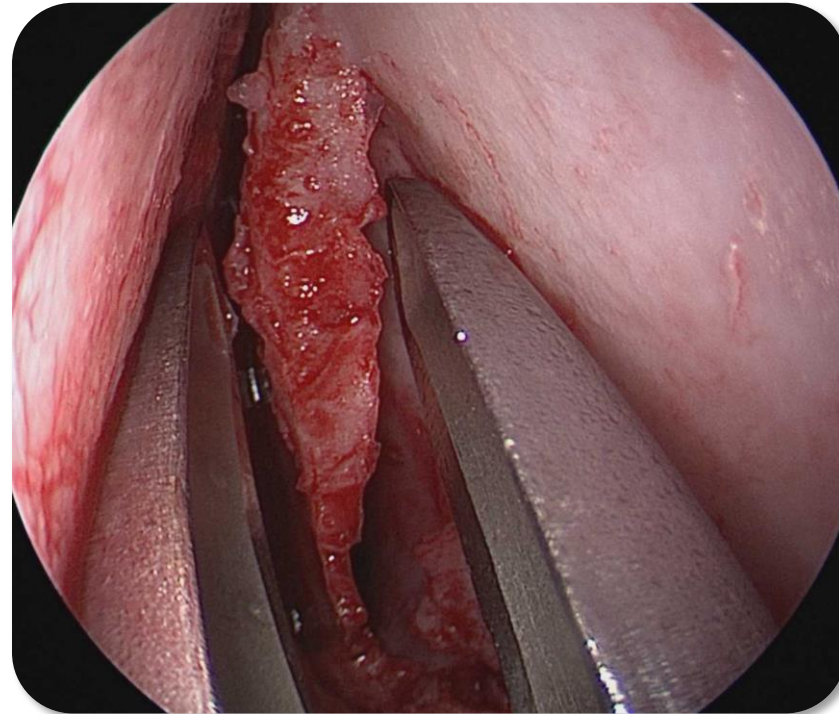
Indications - Technique - Follow up - Pitfalls

H.R. Briner

ORL-Zentrum

Klinik Hirslanden

Zürich



Septoplasty and Turbinoplasty

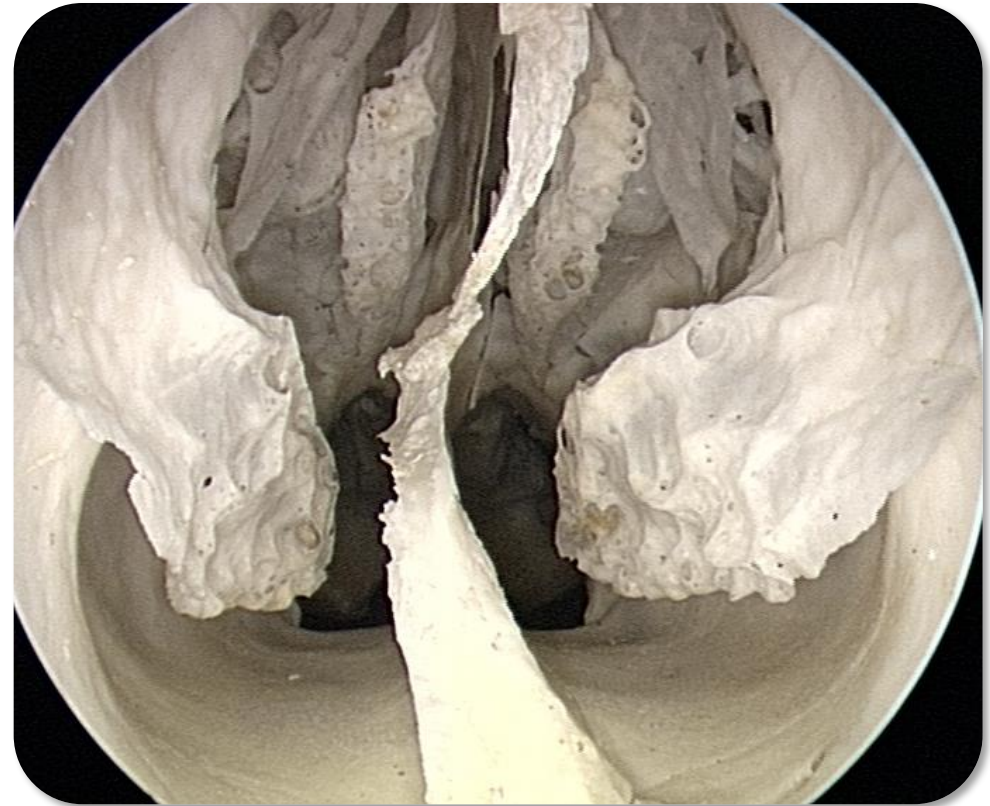
➤ Septoplasty

- *Indications*
- *Technique*
- *Follow up*
- *Complications, Tips and Tricks*

➤ Turbinoplasty

- *Basics, Indications*
- *Technique*
- *Follow up*
- *Complications, Tips and Tricks*

➤ Discussion

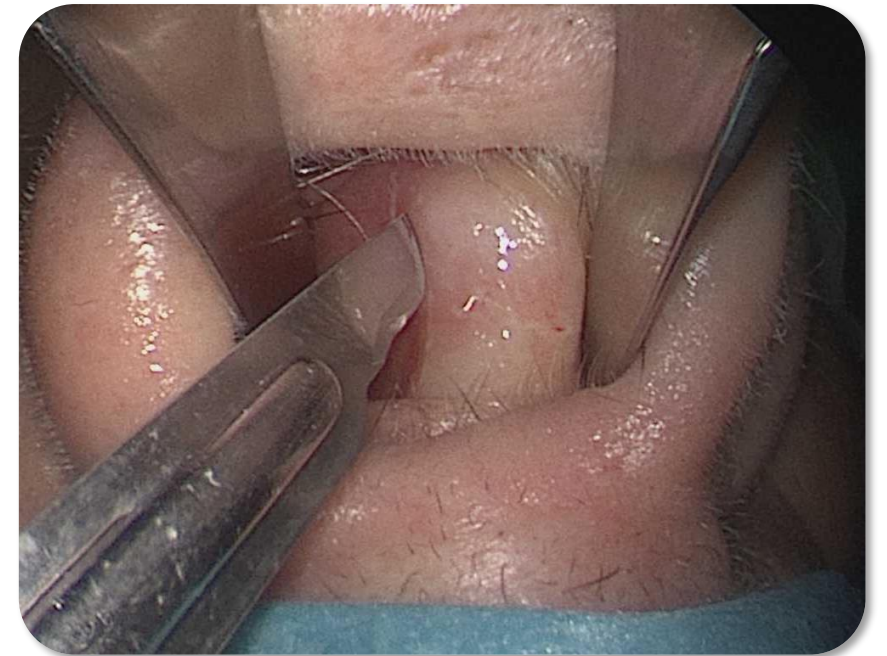


Septoplasty

Basics

Septoplasty

- One of the most common rhinosurgical procedures
- **Basic procedure** in rhinosurgery
- Degree of technical difficulty ranges from easy to extremely difficult

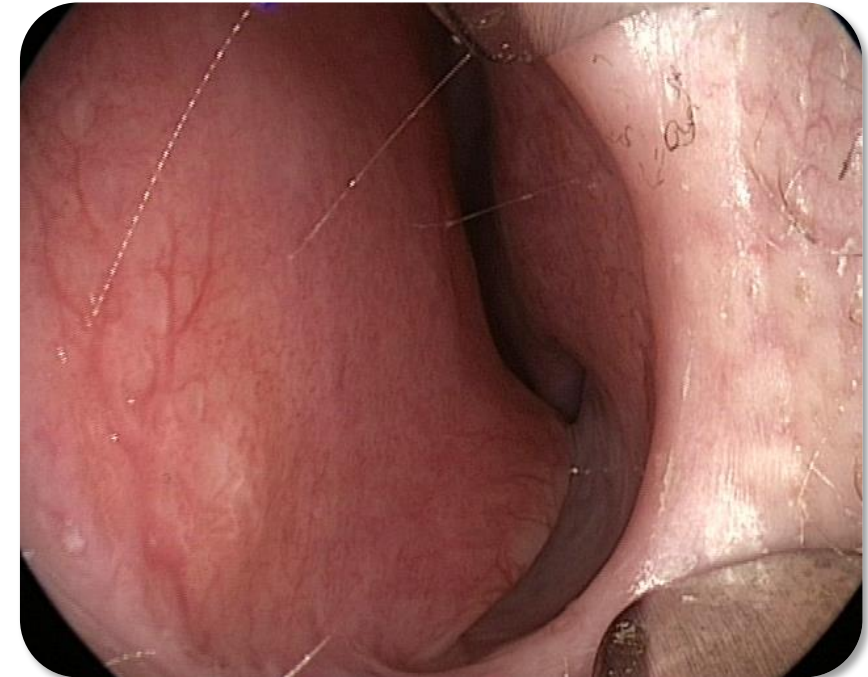


Septoplasty

Indications

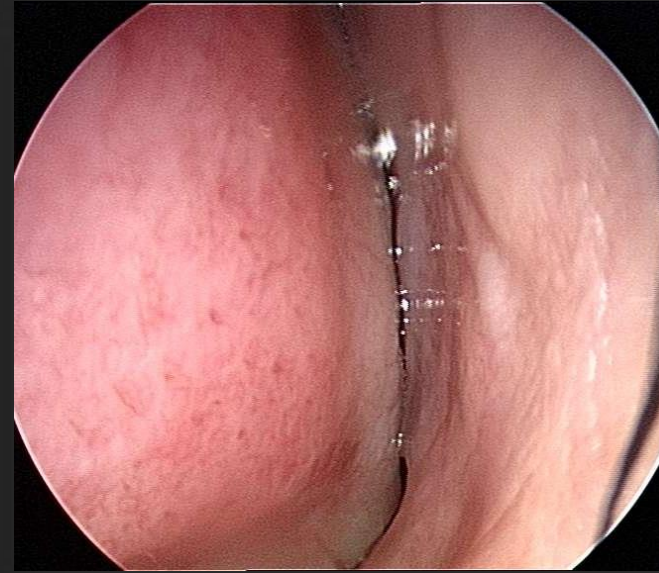
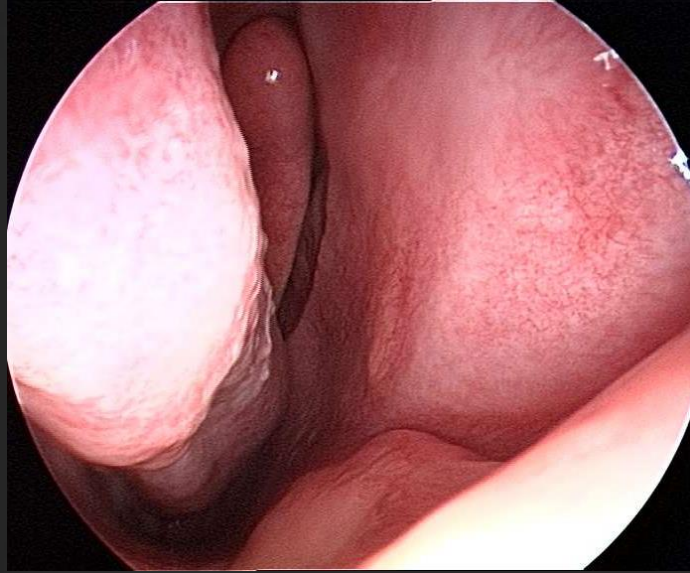
Indications for septoplasty

- **Symptomatic deviation of nasal septum**
 - *Breathing difficulties*
- Part of the surgical procedure in correction of the external nose («septorhinoplasty»)
 - *Crooked nose*
- May be part of the approach to the paranasal sinuses and the anterior skull base
- Others (*trauma, epistaxis, tumor surgery, ..*)

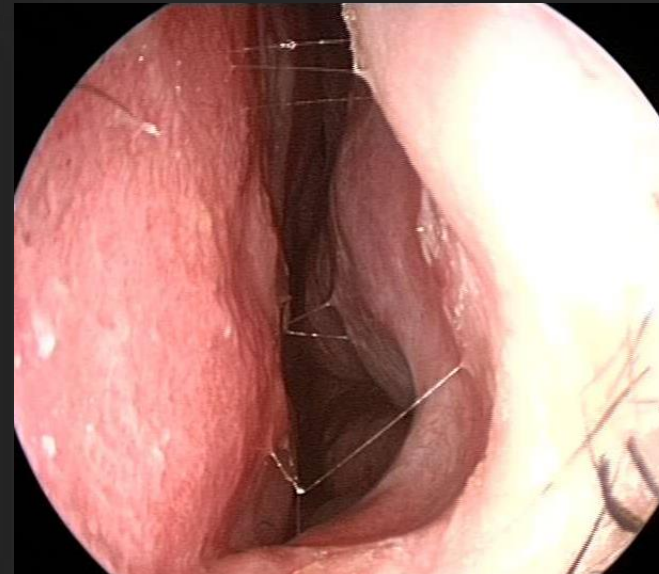
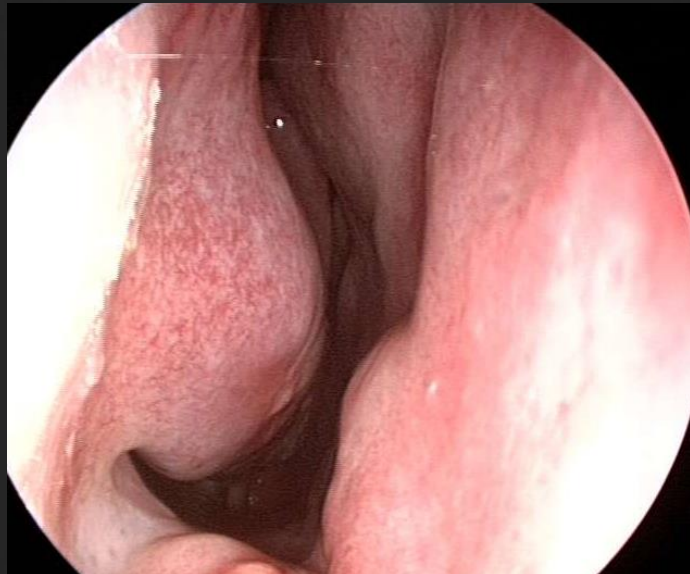


Symptomatic deviation of the nasal septum

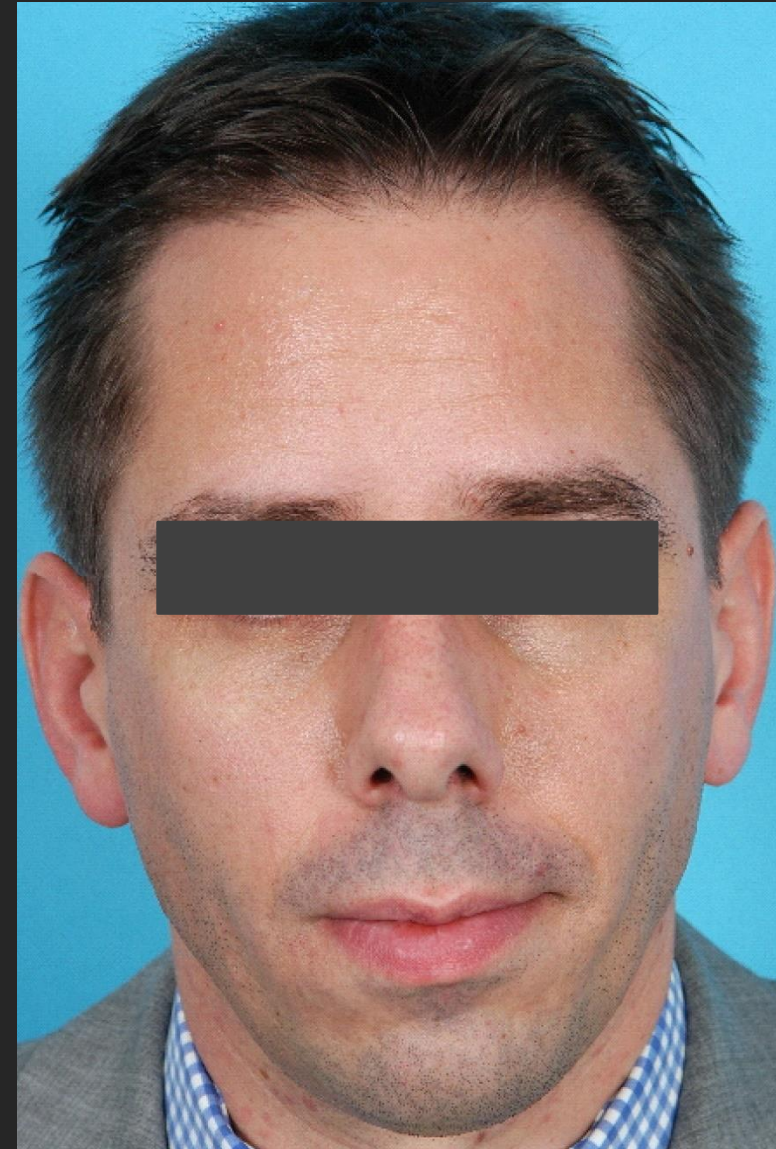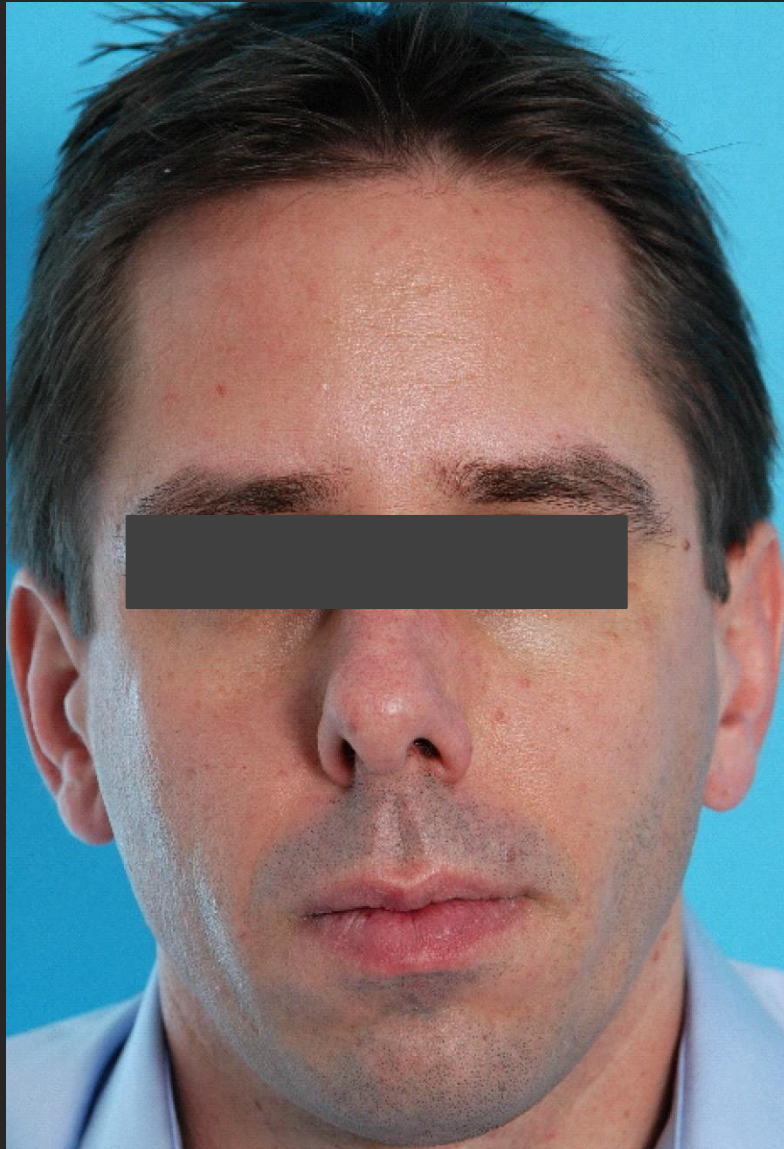preoperative



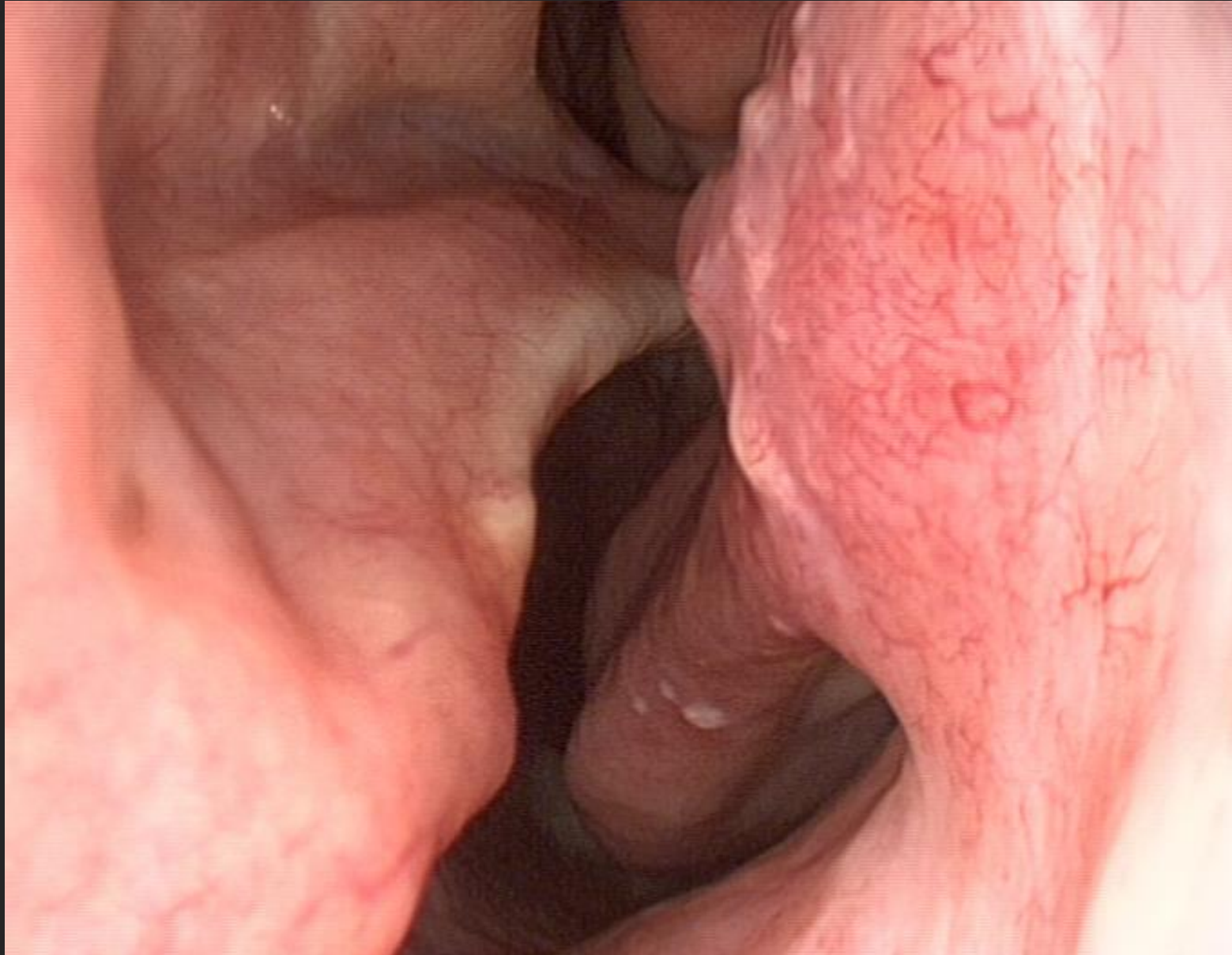
postoperative



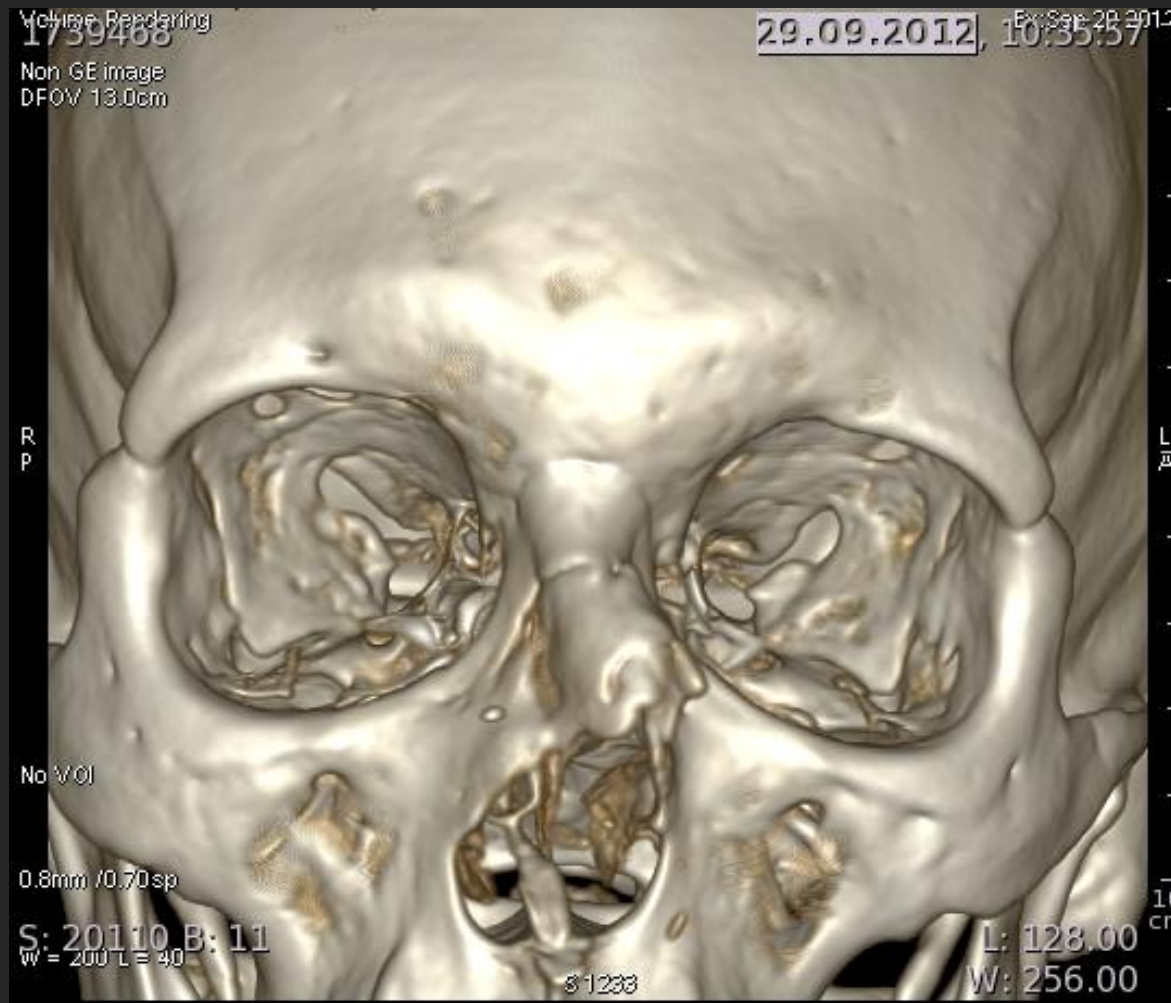
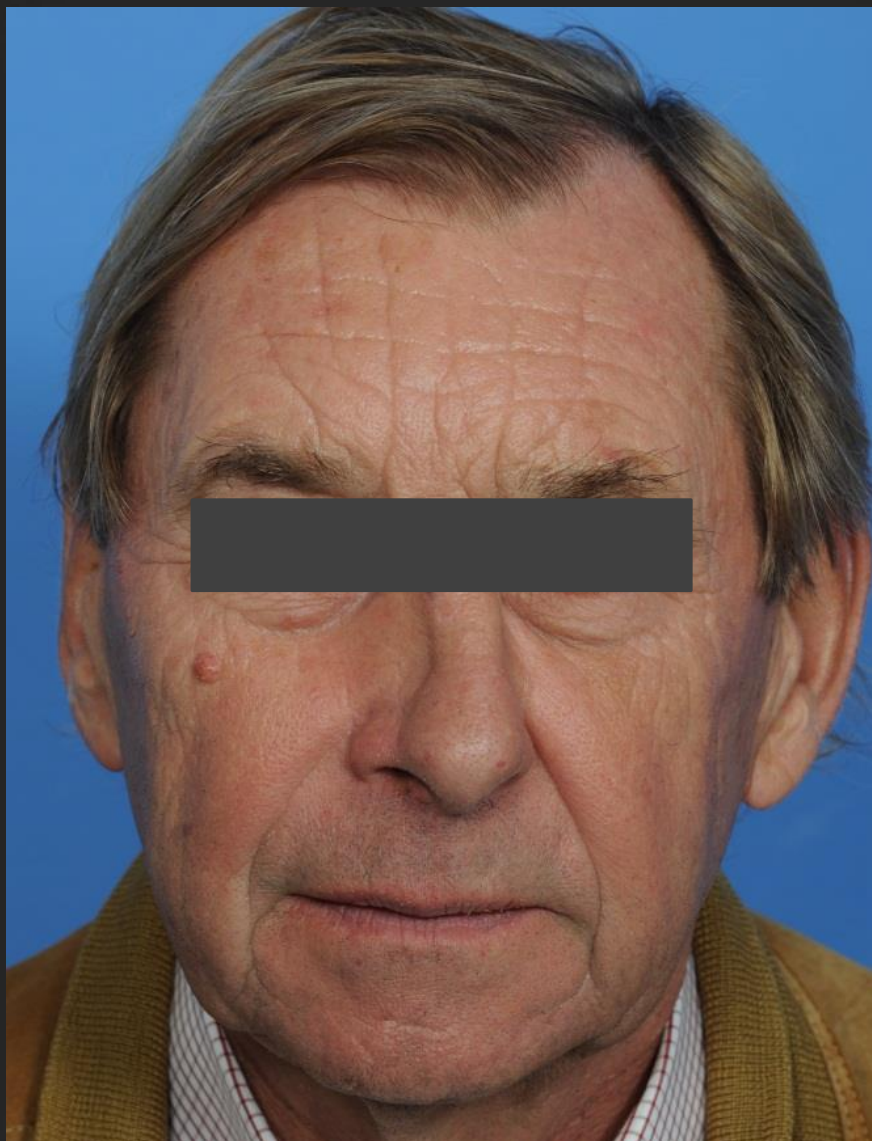Congenital deviated nose



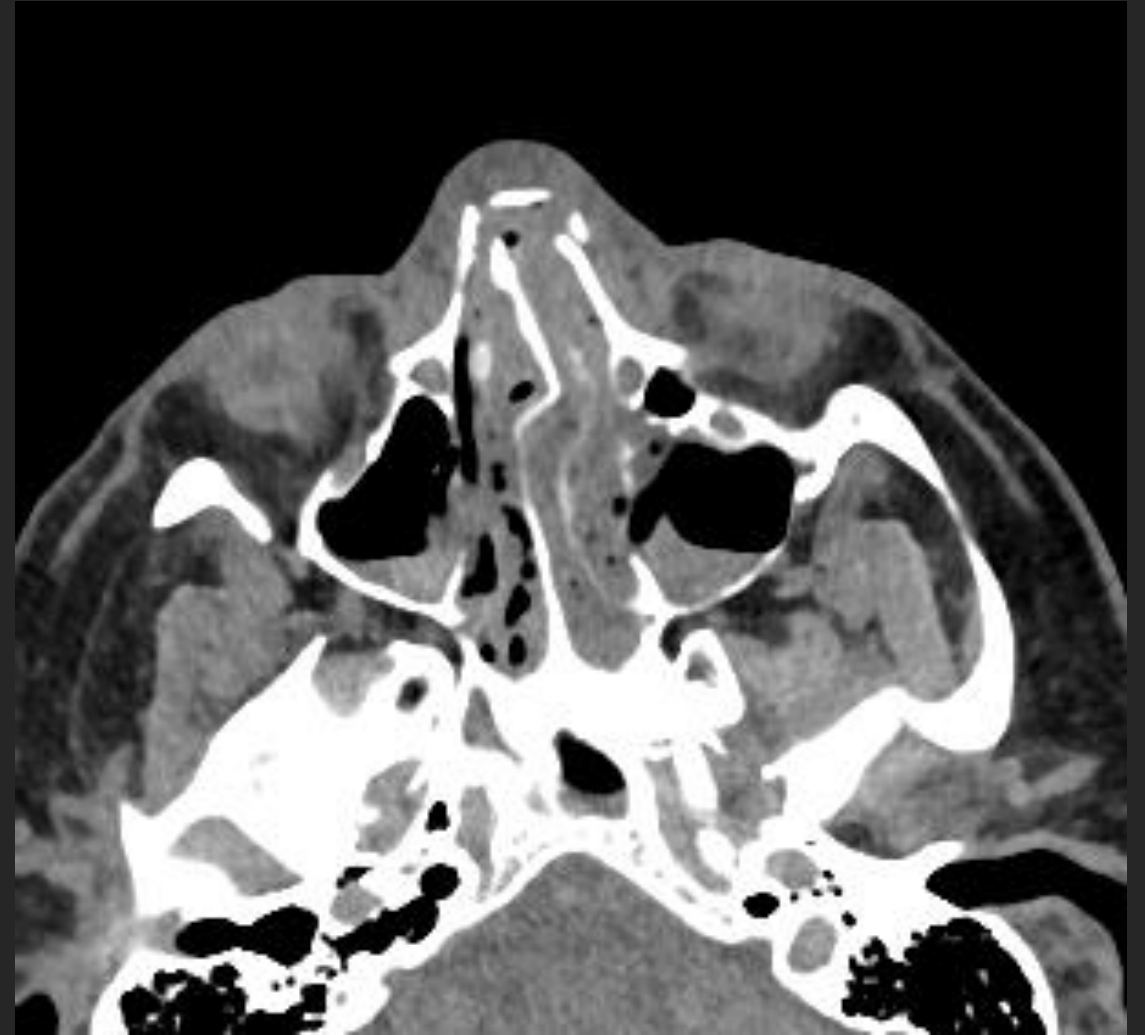
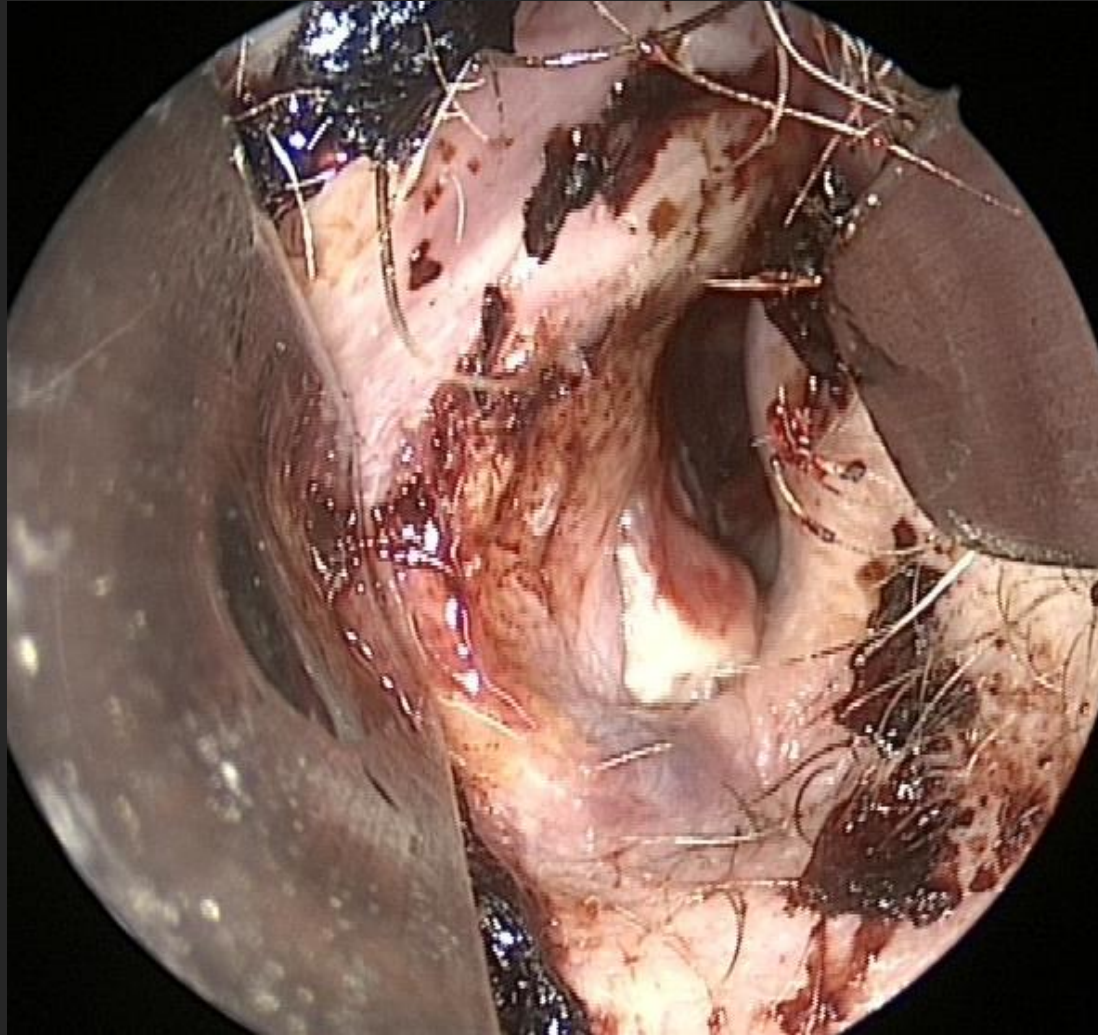
Septal spur blocking access to sphenoidotomy



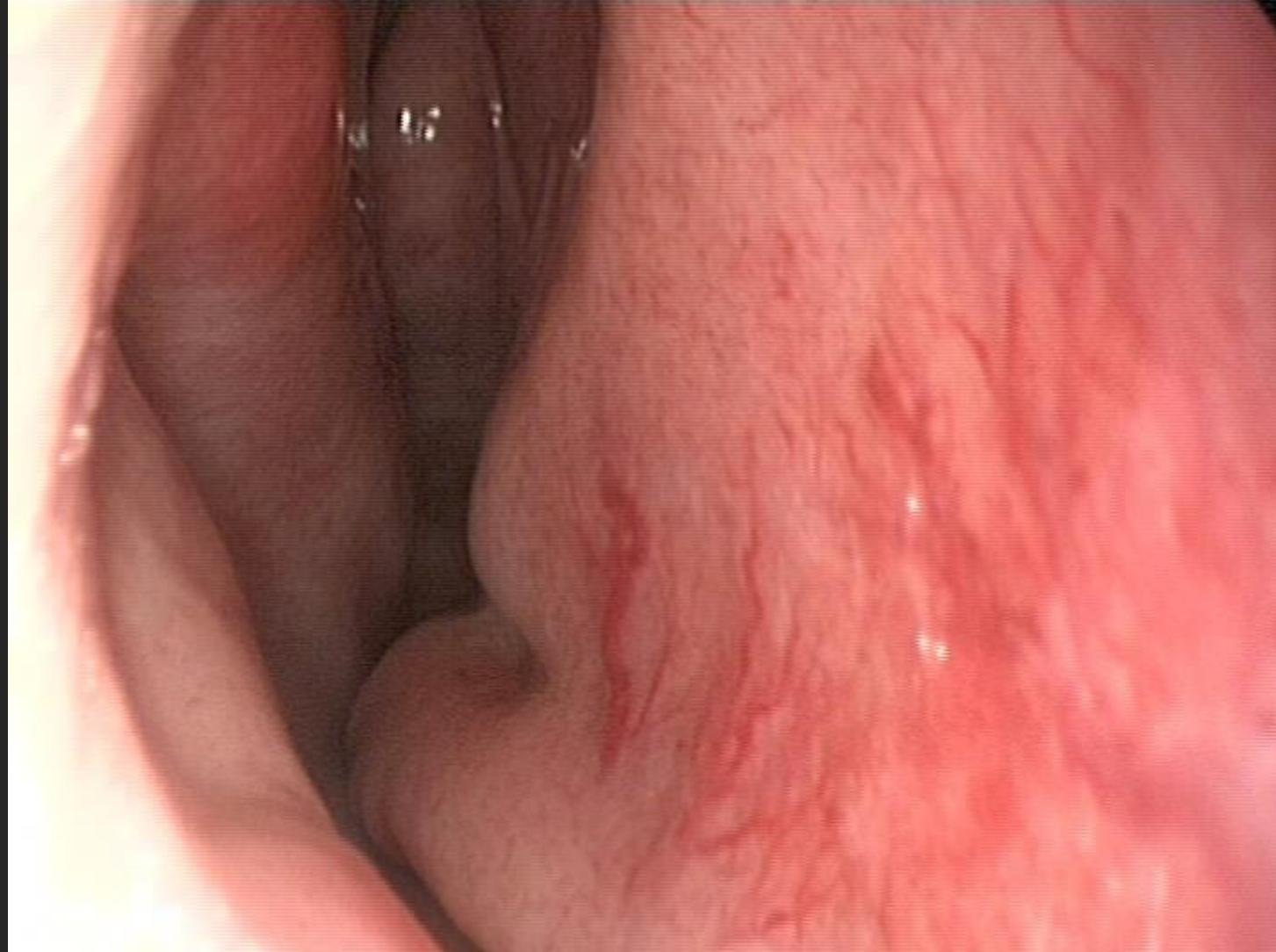Posttraumatic crooked nose



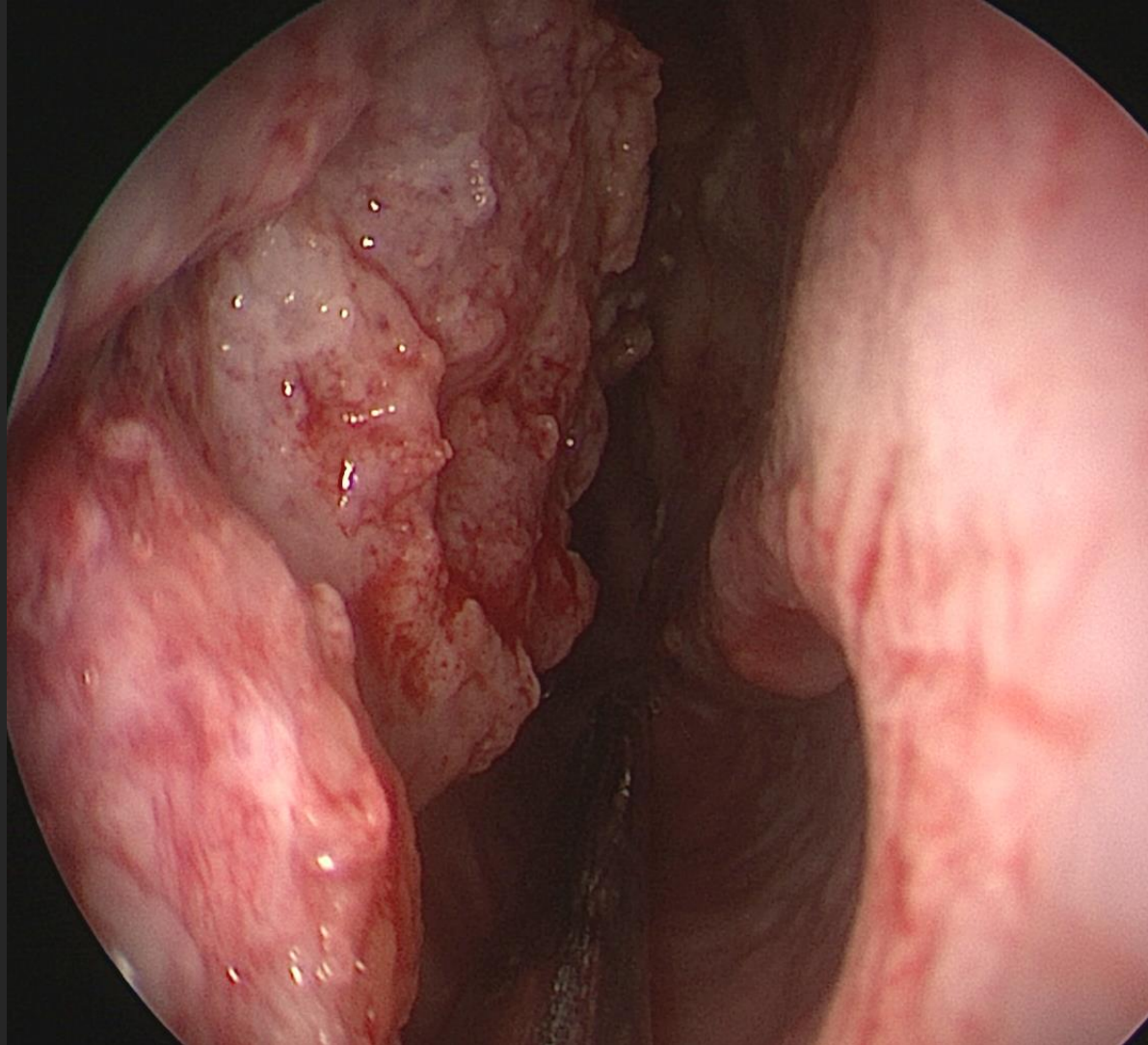
Fracture of the nasal septum



Recurrent epistaxis at site of septal deviation
(if conservative therapy is insufficient)



Tumors involving the nasal septum

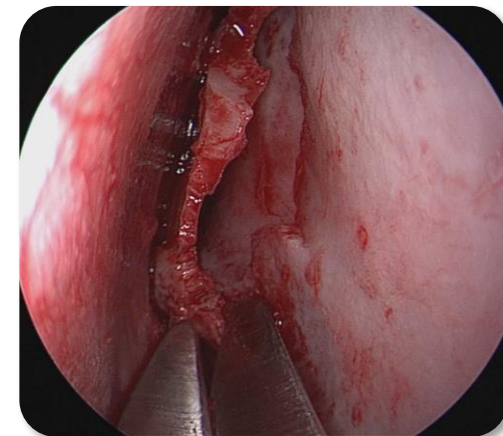
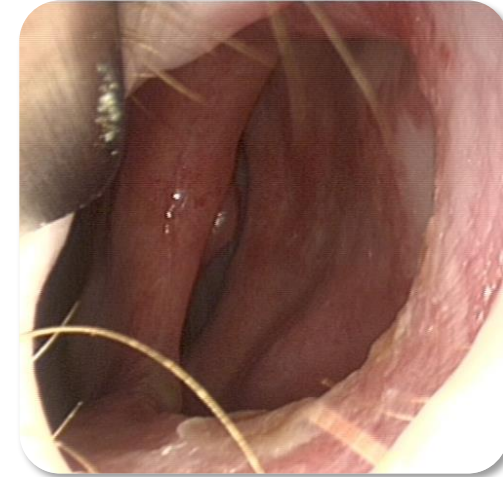

Septoplasty

Technique

History

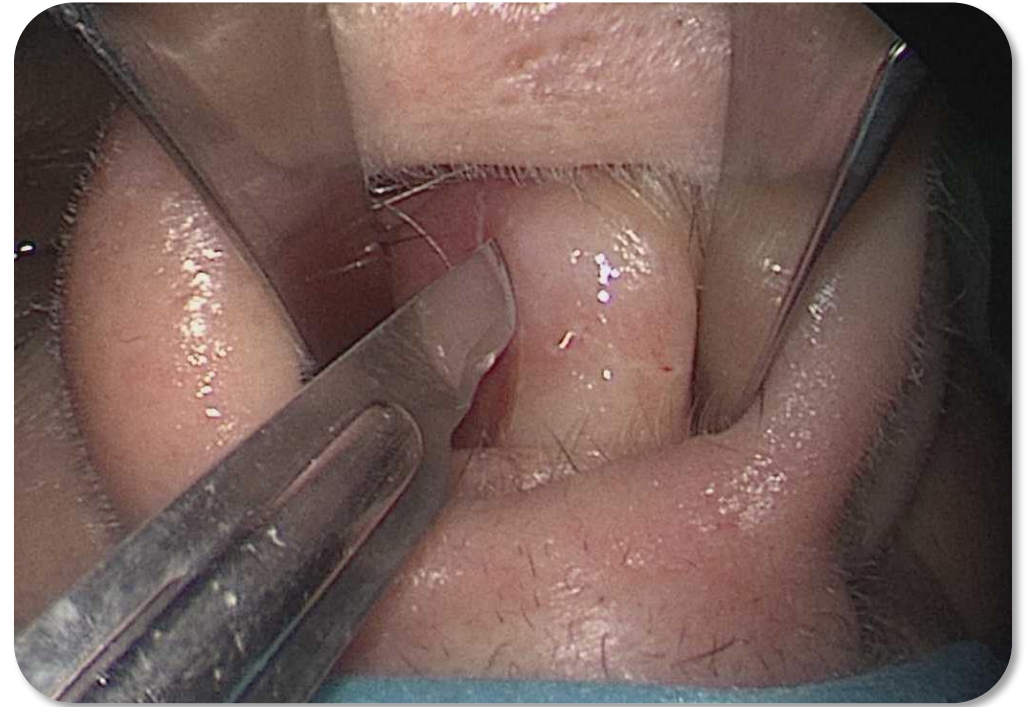
- **Resection of the nasal septum**
 - *Resection of the whole deviated nasal septum*
- **Submucous resection**
 - *Resection of the deviated nasal cartilage or bone (Kilian, Freer)*
- **Septoplasty**
 - *Correction of the deviated nasal septum **restoring cartilage and bone** (Metzenbaum, Cottle, Fomon)*



Septoplasty

Technique

- Anesthesia
- Incision
- Dissection of the septum
- Correction of the deviation
- Refixation of the septum
- How to deal with mucosal tears
- Closure of incision, splints or sutures, packing
- Endoscopic septoplasty
- Extracorporeal septoplasty

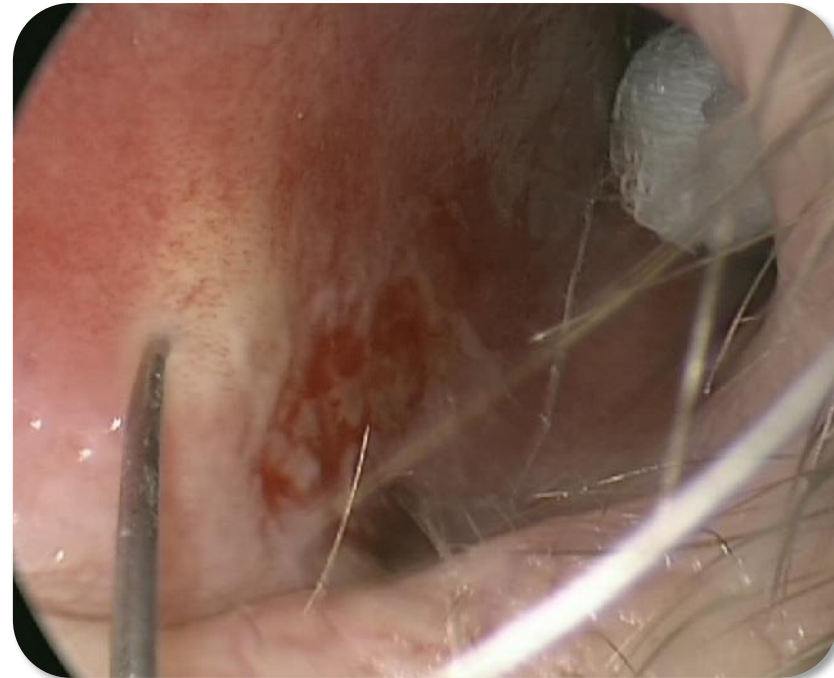

Septoplasty

Technique

Anesthesia

- Local anesthesia
 - possible
- General anesthesia
 - Orotracheal intubation

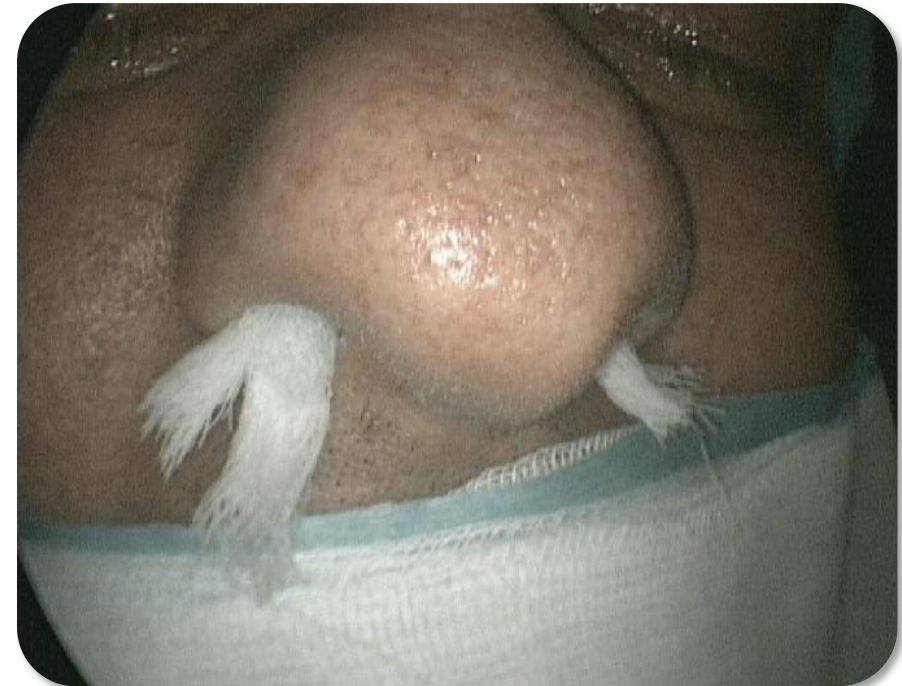

Septoplasty

Technique

Decongesting nasal mucosa

- Preparing surgical field by placing gauze or cotton swabs soaked with local anesthetic and vasoconstricting solution
 - *e.g. tetracaine 1% with epinephrine 1:100'000*

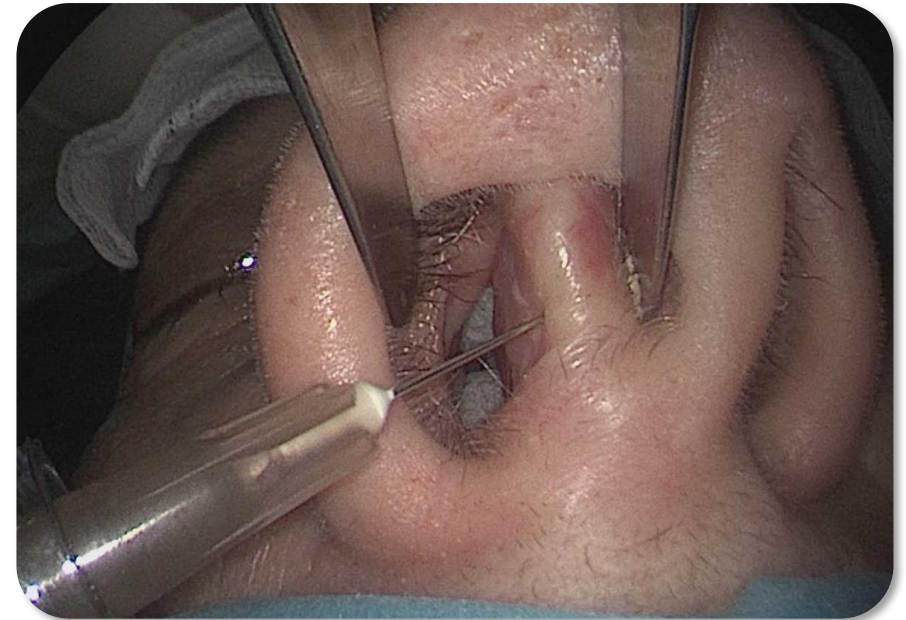


Septoplasty

Technique

Local anesthesia

- Infiltration of local anesthesia with vasoconstricting agent at site of planned incision for hemitransfixion
 - *e.g. lidocaine 1% with epinephrine 1:100'000*

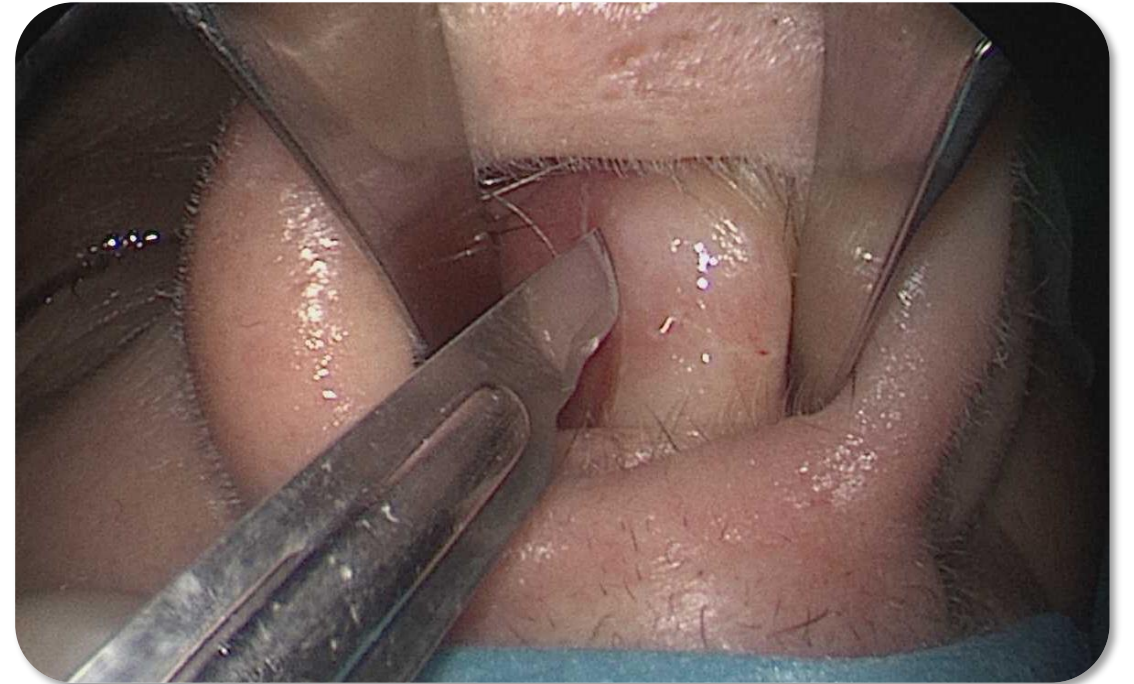


Septoplasty

Technique

Incision

- Hemitransfixion incision
 - 1-3 mm dorsal of the anterior edge of the cartilaginous septum
 - Right side (or left)
 - Blade 15

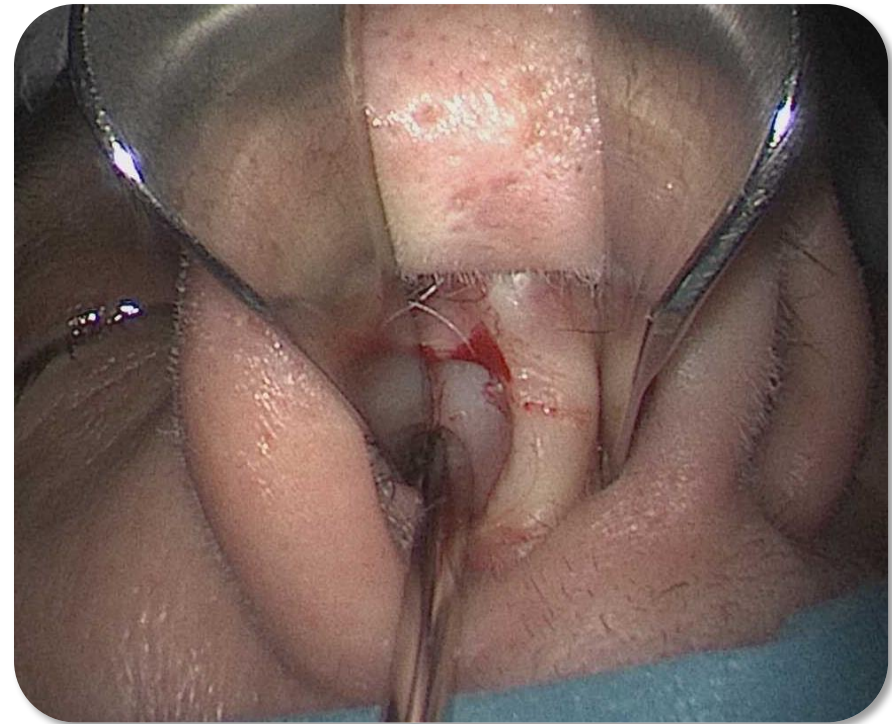


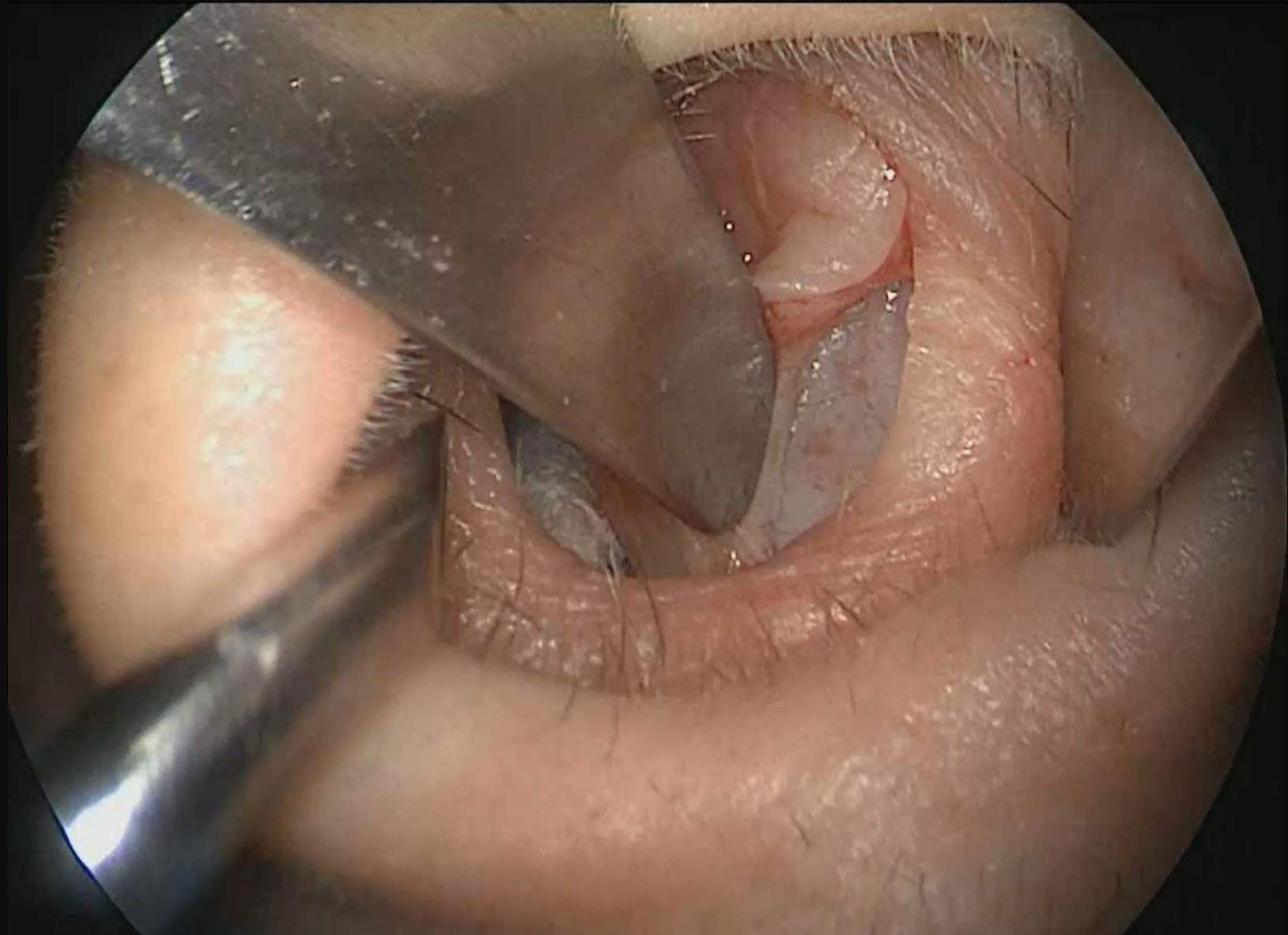
Septoplasty

Technique

Incision

- Exposure of septal cartilage
 - Cave: Right anatomical layer (subperichondral)
 - Scalpel
 - Scissors
 - Raspatory
 - Suction raspatory



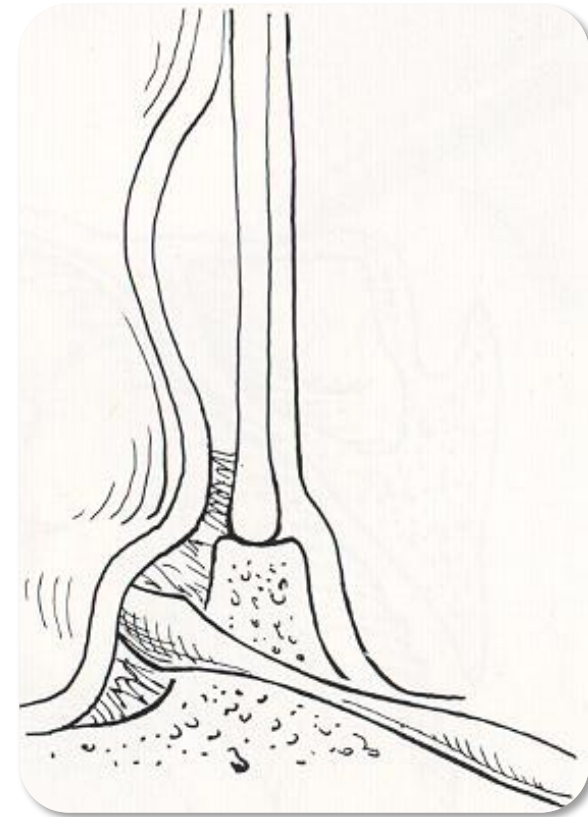


Septoplasty

Technique

Exposure of the septal cartilage and bone

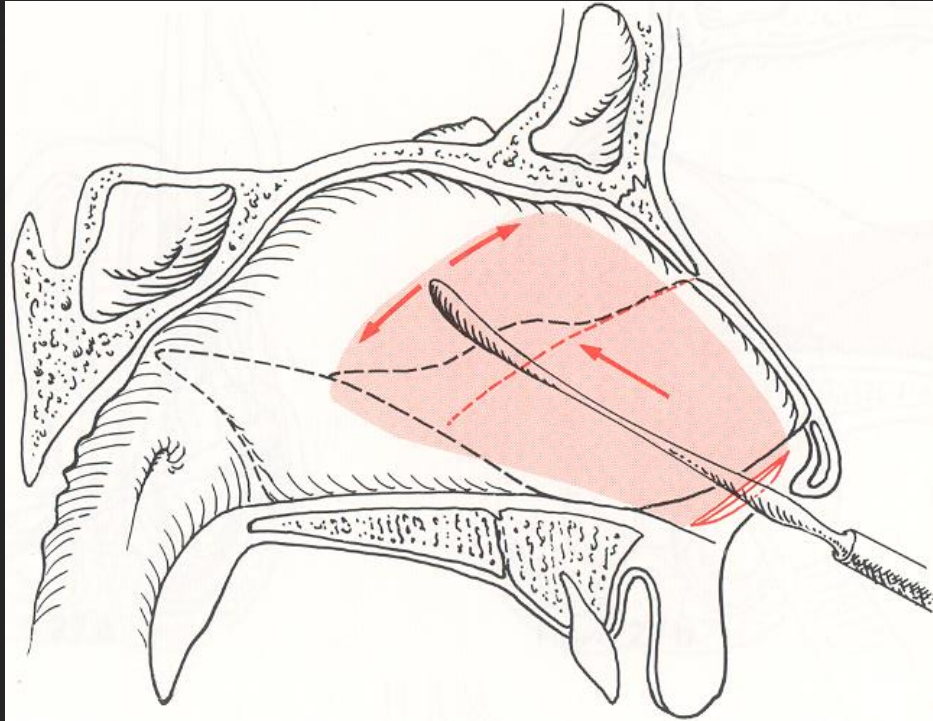
- Dissection of the cartilage and bone on the side of the hemitransfixion
 - „Upper“ and „lower“ tunnel
 - Instruments: Raspatory, suction raspatory, scissors, scalpel



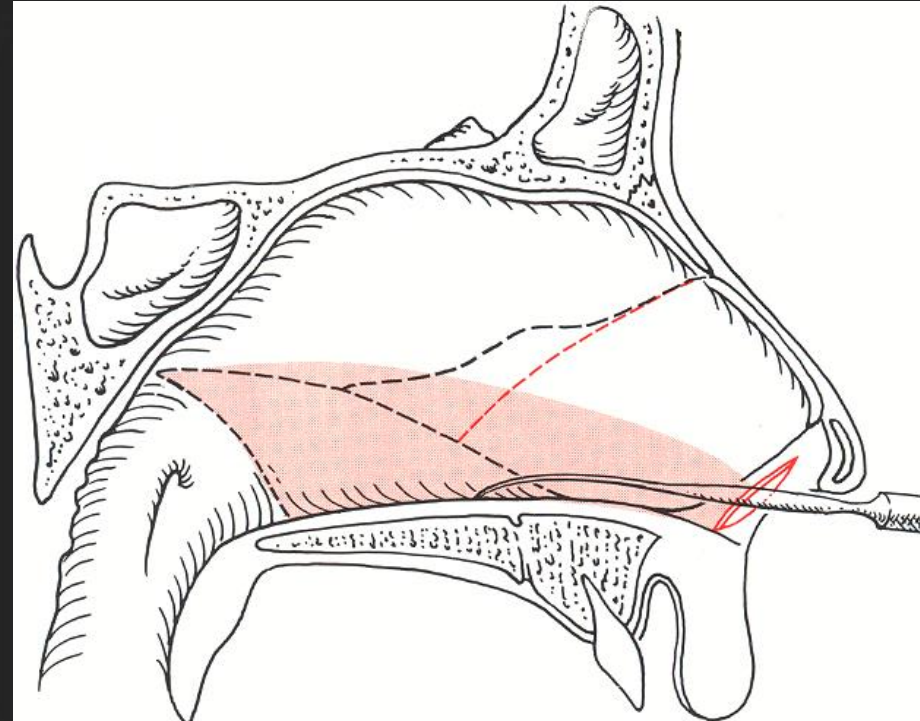
From: "Head and Neck Surgery", H.H. Naumann et al., Thieme

Dissection of the cartilaginous and bony septum

„Upper“ tunnel



„Lower“ tunnel

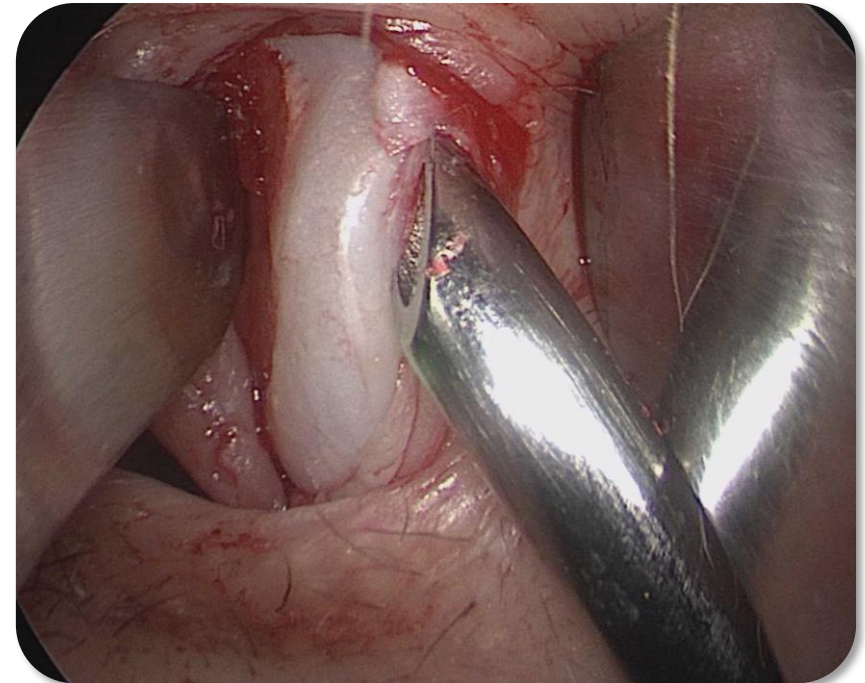


Septoplasty

Technique

Dissection of the septum

- Exposure of the anterior border of the septal cartilage
 - Cutting through the tough fibrous tissue (scalpel)
- Dissection of the cartilage and bone of the other side
 - Gives better exposure for correction
 - Not always necessary

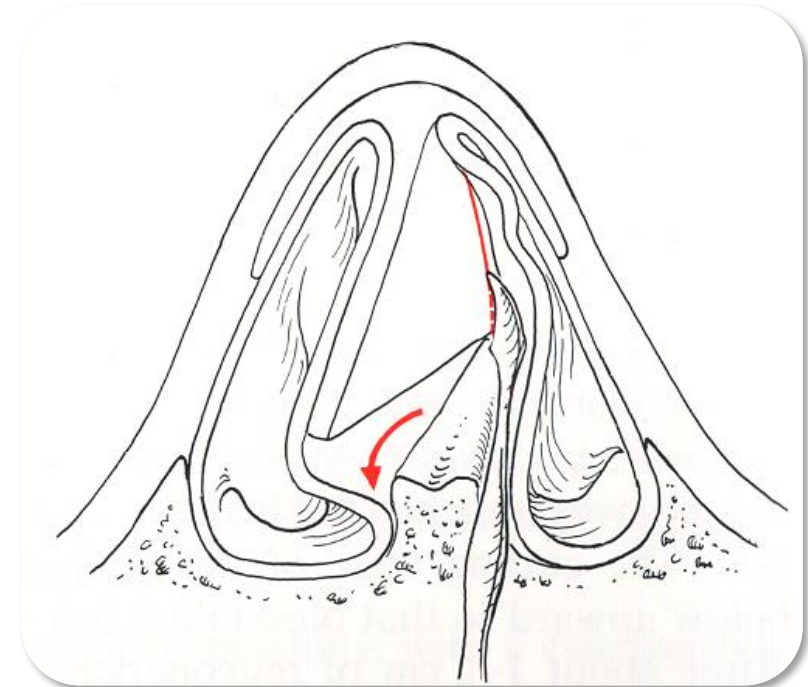


Septoplasty

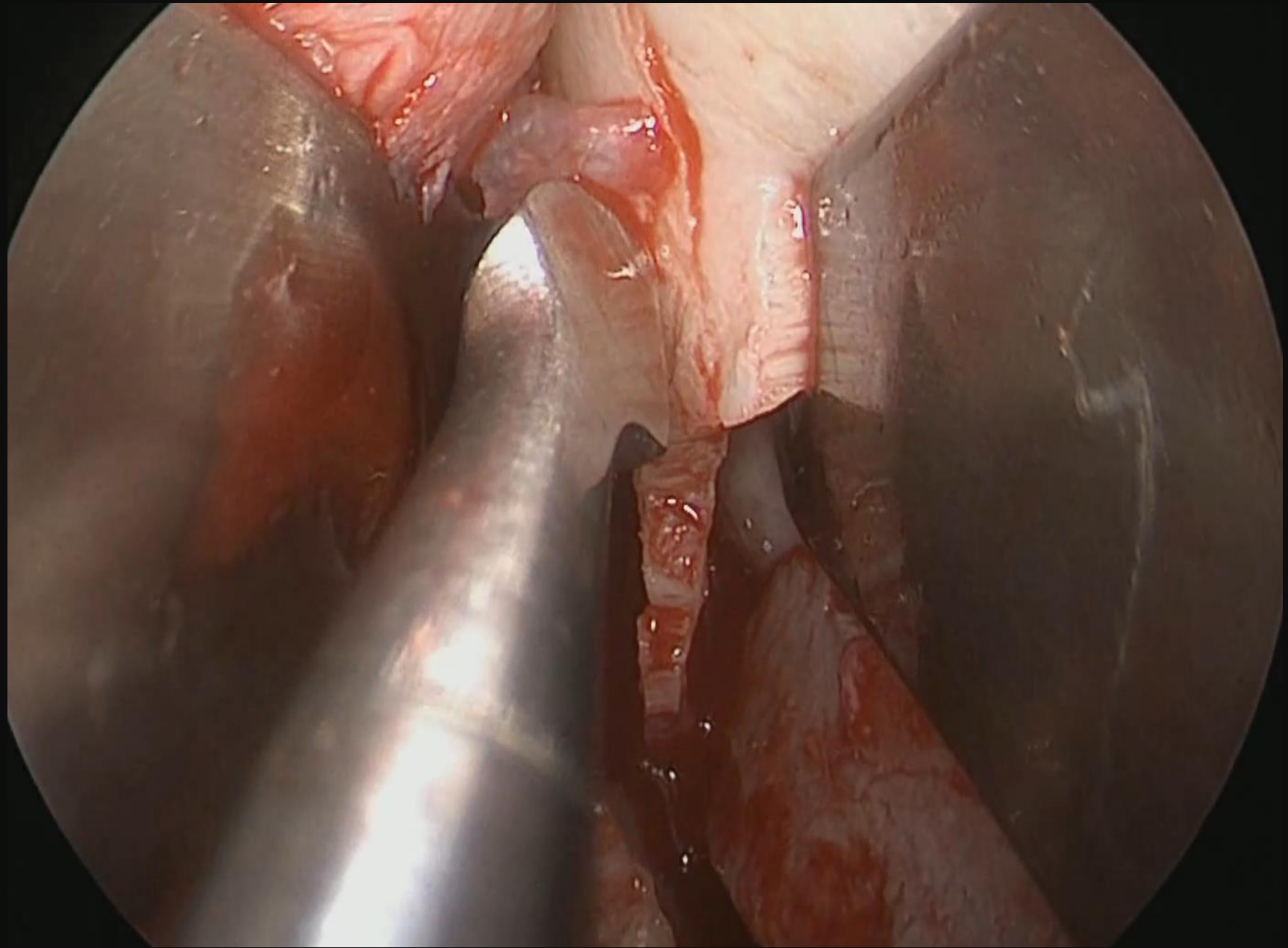
Technique

Dissection of the septum

- Mobilisation of the cartilaginous septum for better exposure and ability of correction
 - Release of the quadrangular cartilage from the basal bony ridge
 - Posterior chondrotomy
 - «Pendelseptum»



From: "Head and Neck Surgery", H.H. Naumann et al., Thieme



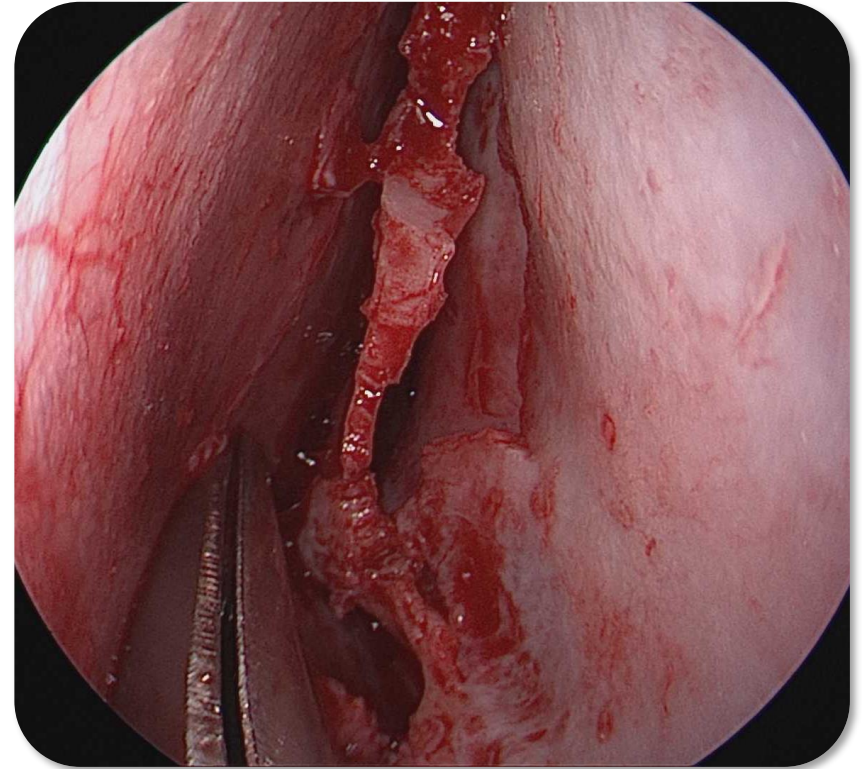
Septoplasty

Technique

Correction of the deviated septum

➤ Possibilities for correction

- Mobilisation
- Resection
- Splinting
- Scoring
- Rekonstruktion, if too complex also extracorporal („Austauschplastik“)

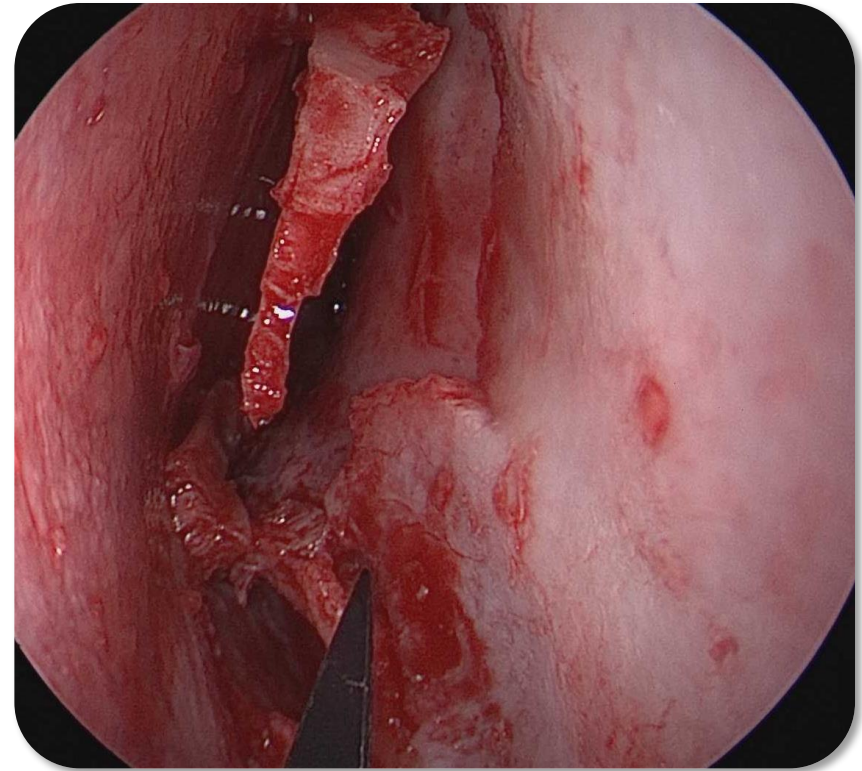


Septoplasty

Technique

Correction of the deviated septum

- Correction by mobilisation
 - Mobilisation of deviated areas of the septum and reposition at the correct plane

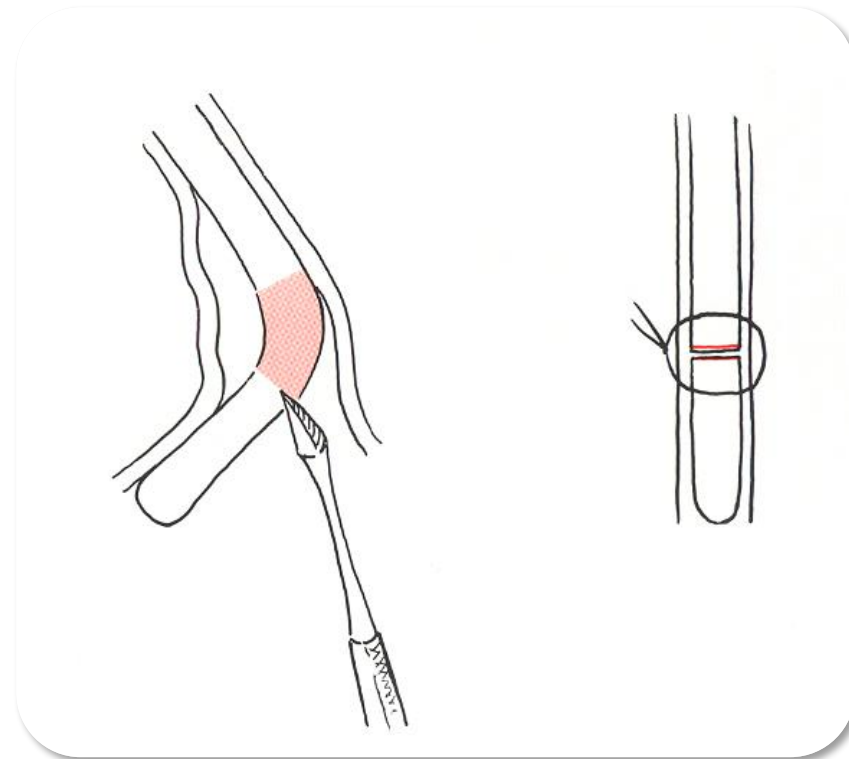


Septoplasty

Technique

Correction of the deviated septum

- Correction by resection
 - Resection of deviated parts of the septum



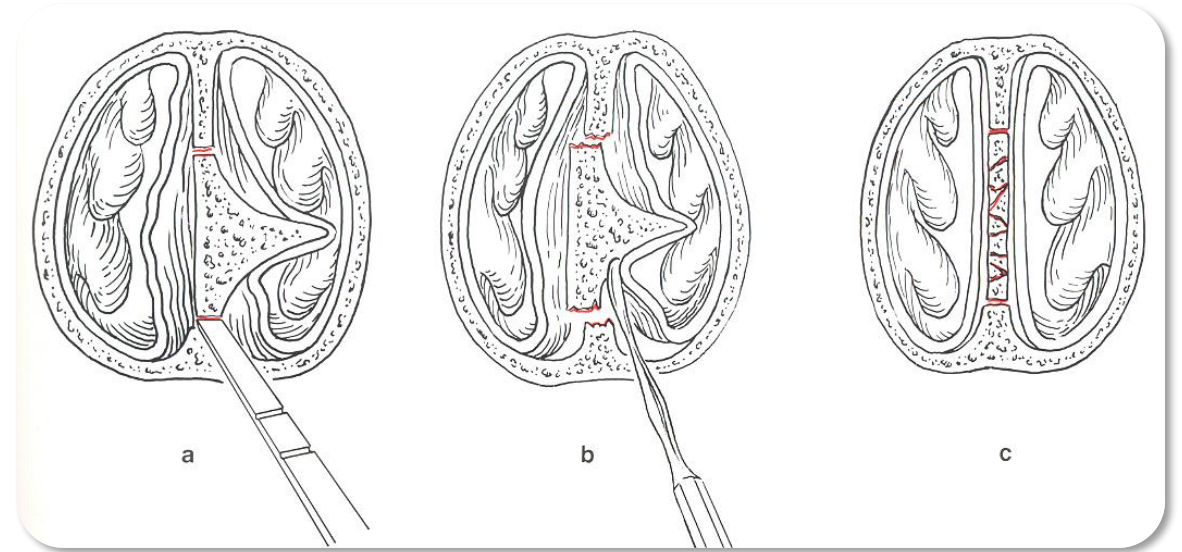
From: "Head and Neck Surgery", H.H. Naumann et al., Thieme

Septoplasty

Technique

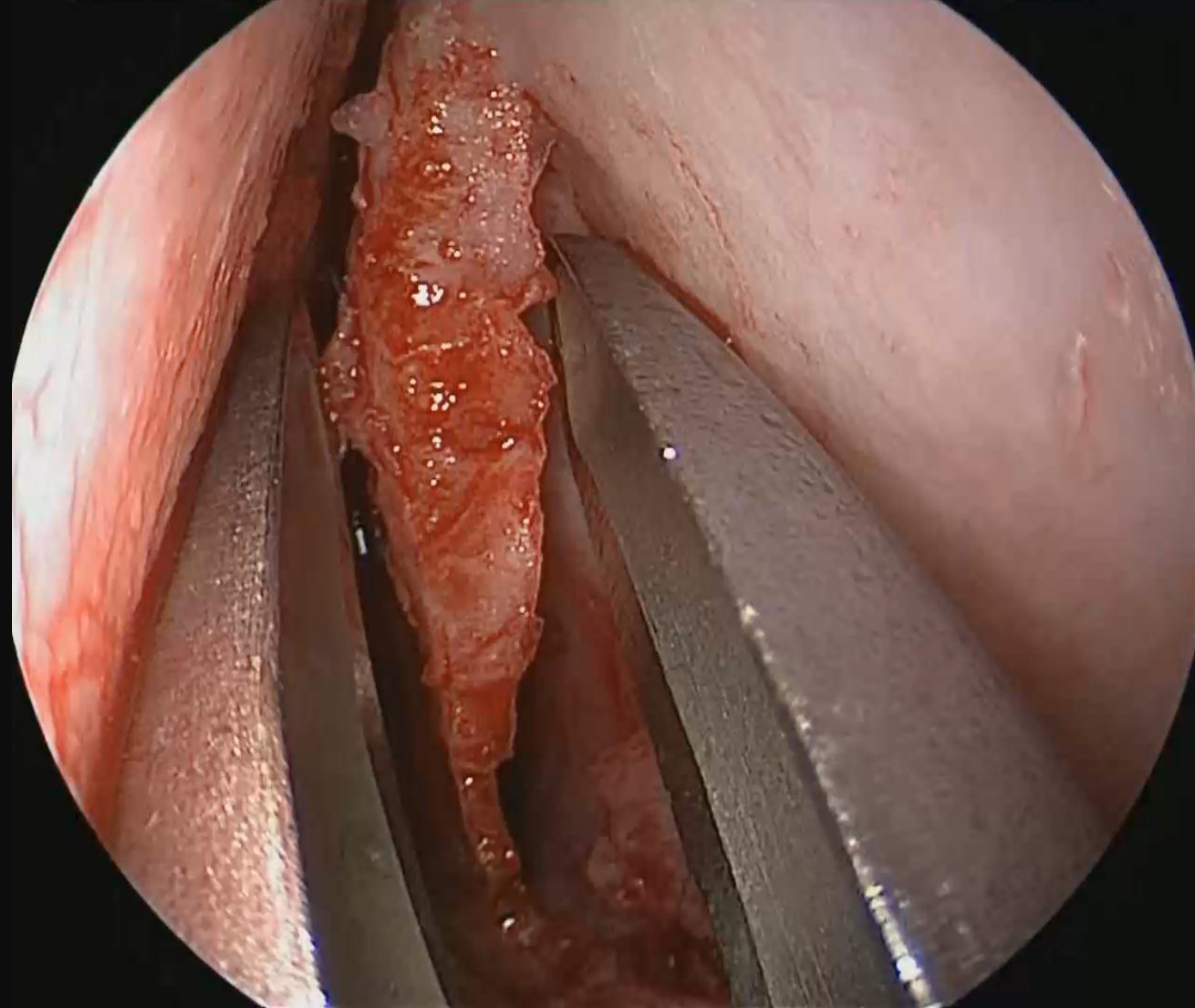
Correction of the deviated septum

- Correction by resection
 - Replantation of straight septal fragments if possible

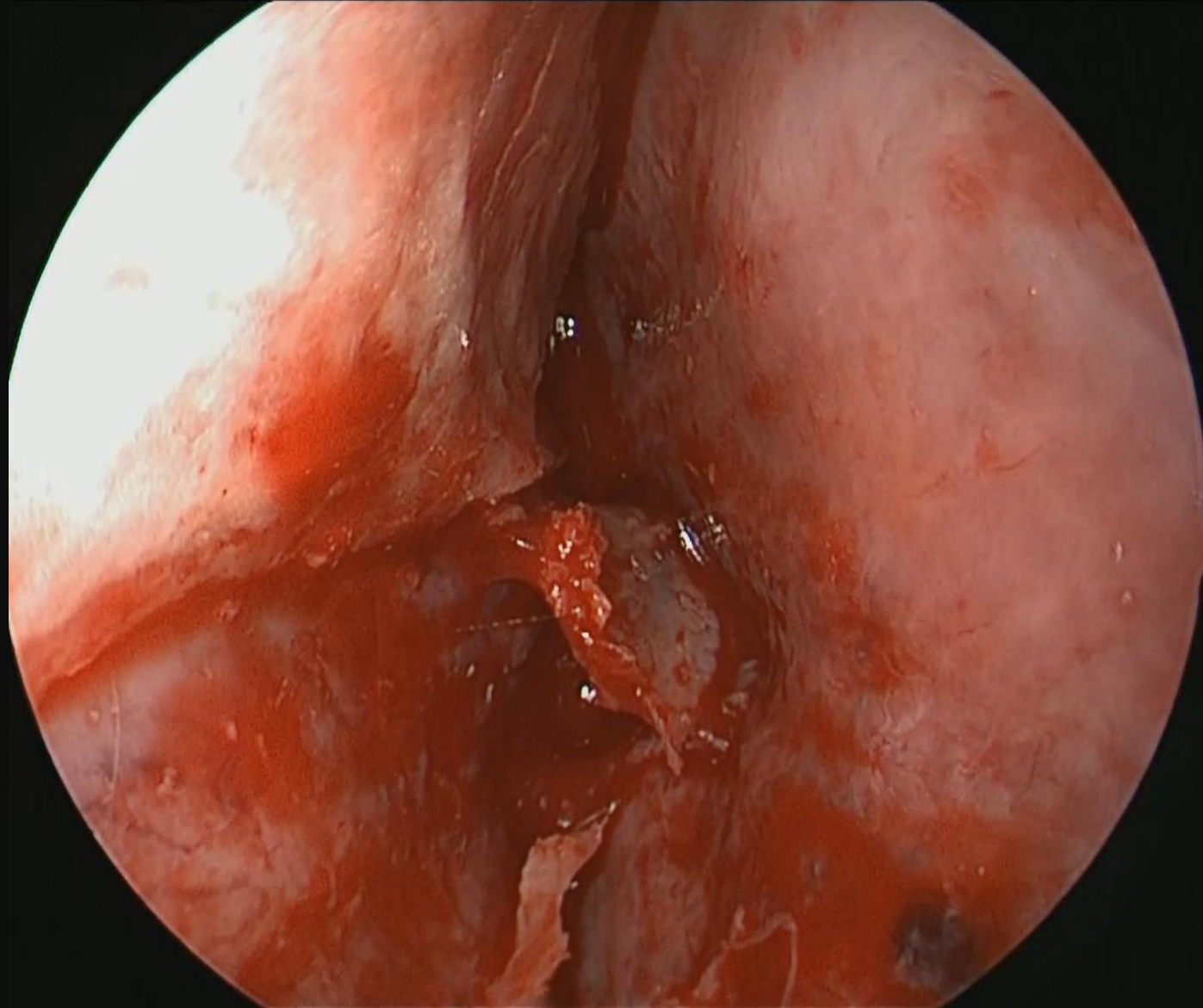


From: "Head and Neck Surgery", H.H. Naumann et al., Thieme

Excision of a convex deviation

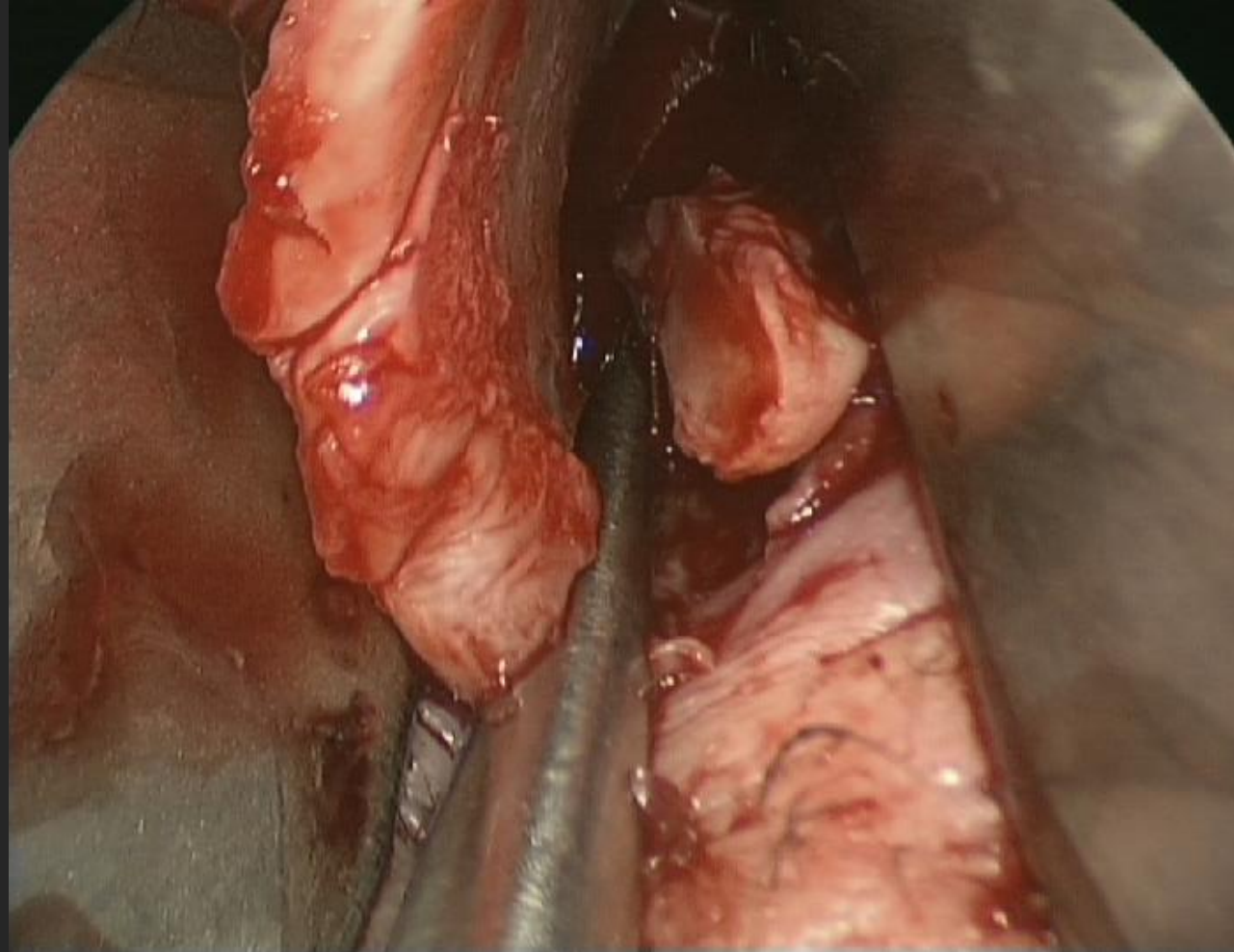


Excision of a septal spur



Correction by resection

Correction of a convex deviation by basal resection of the «too long» cartilage

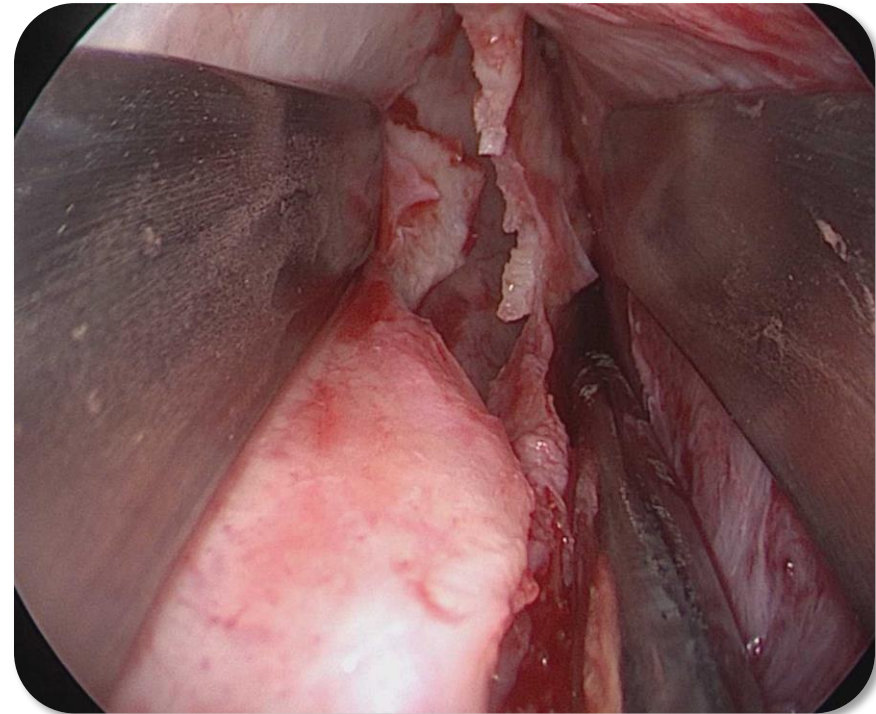


Septoplasty

Technique

Correction of the deviated septum

- Correction by splinting
 - Suturing a straight bony part of the lamina perpendicularis on the deviated cartilaginous septum
 - Also possible: PDS-sheet, *titan-device?*
 - Technically difficult



Septoplasty

Technique

Correction of the deviated septum

- Correction by scoring
 - Cartilage bends if scored on one side
 - Bending effect difficult to predict



Abb. 1
Histologisches Bild eines geritzten Ohrknorpels aus der Originalarbeit von Stenström 1963.

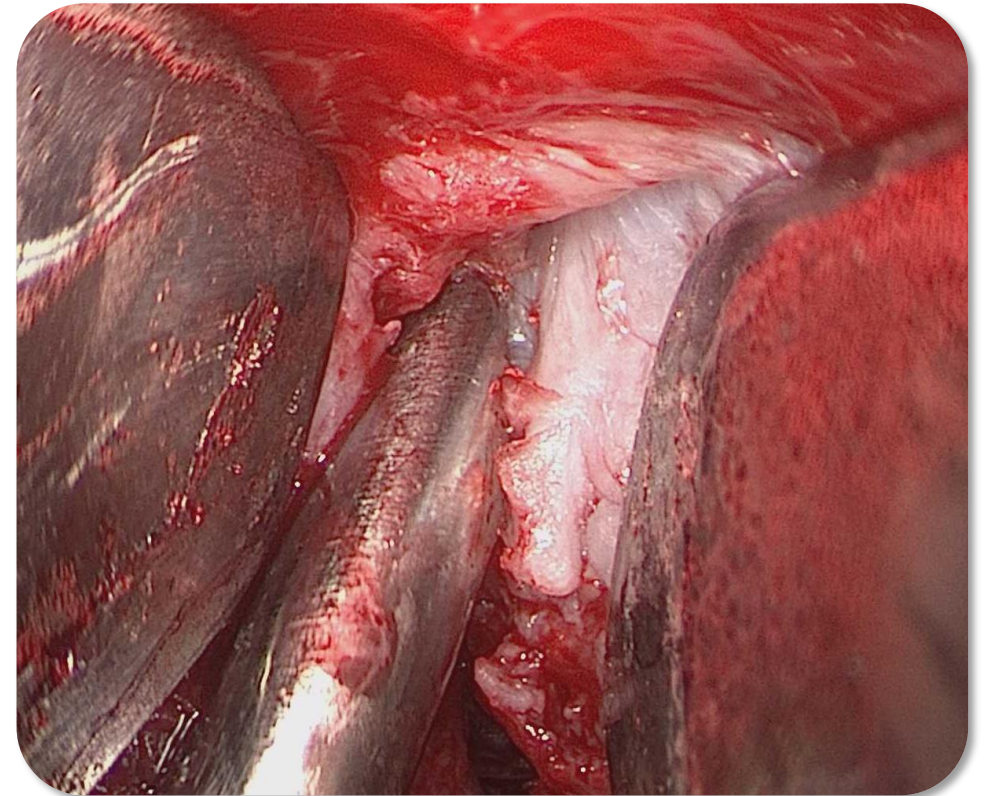
From: "Otoplastik", Schlegel C, Briner HR, Endo:Press; Tuttlingen

Septoplasty

Technique

Correction of the «difficult» deviated septum

- Extracorporal correction
«Septumaustauschplastik»
 - Taking the septum out of the nose, straighten it by remodeling and splinting and replanting it
 - Usually by an open approach
 - Difficult technique

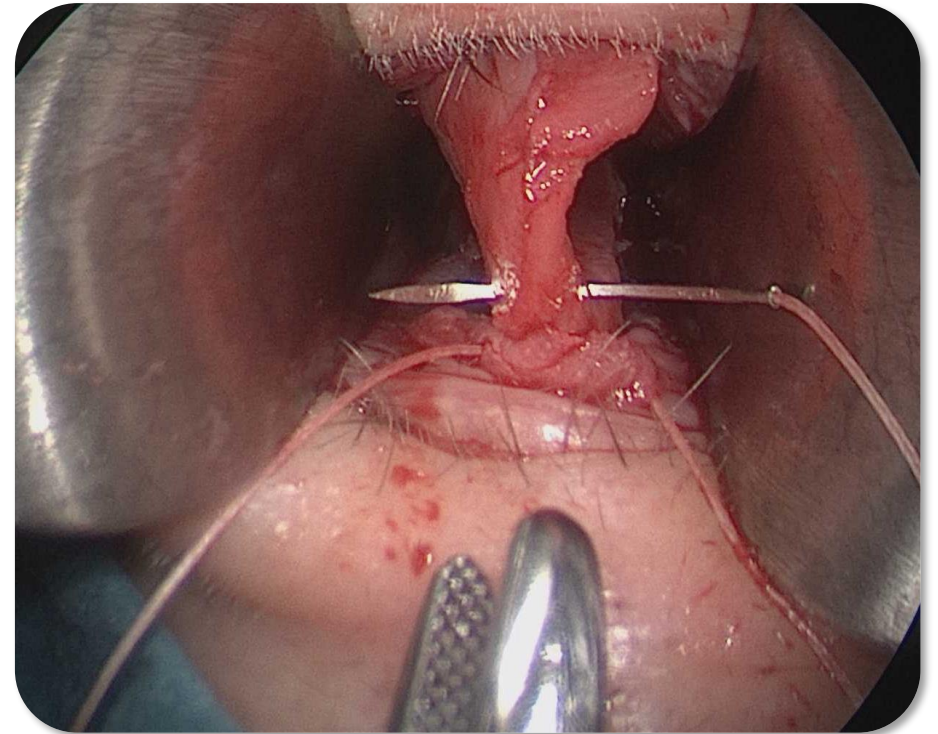


Septoplasty

Technique

Refixation of the septum

- Fixation of the anterior inferior border of the septum at the anterior nasal spine
 - «8» suture
 - Resorbable or non resorbable material
 - Prevents dorsal displacement of cartilaginous septum

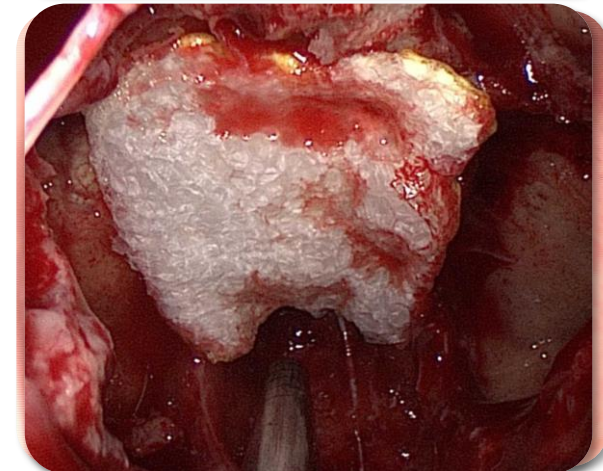
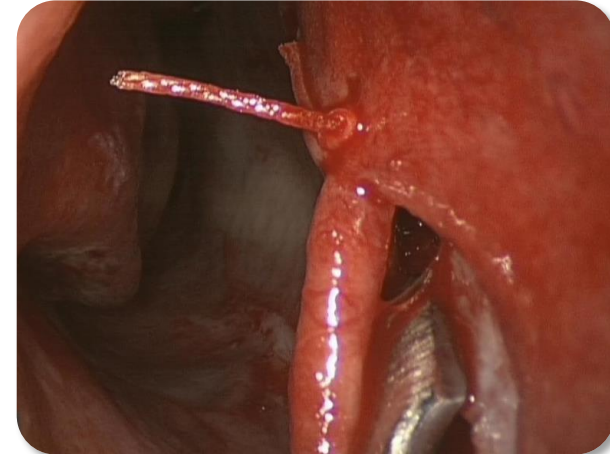


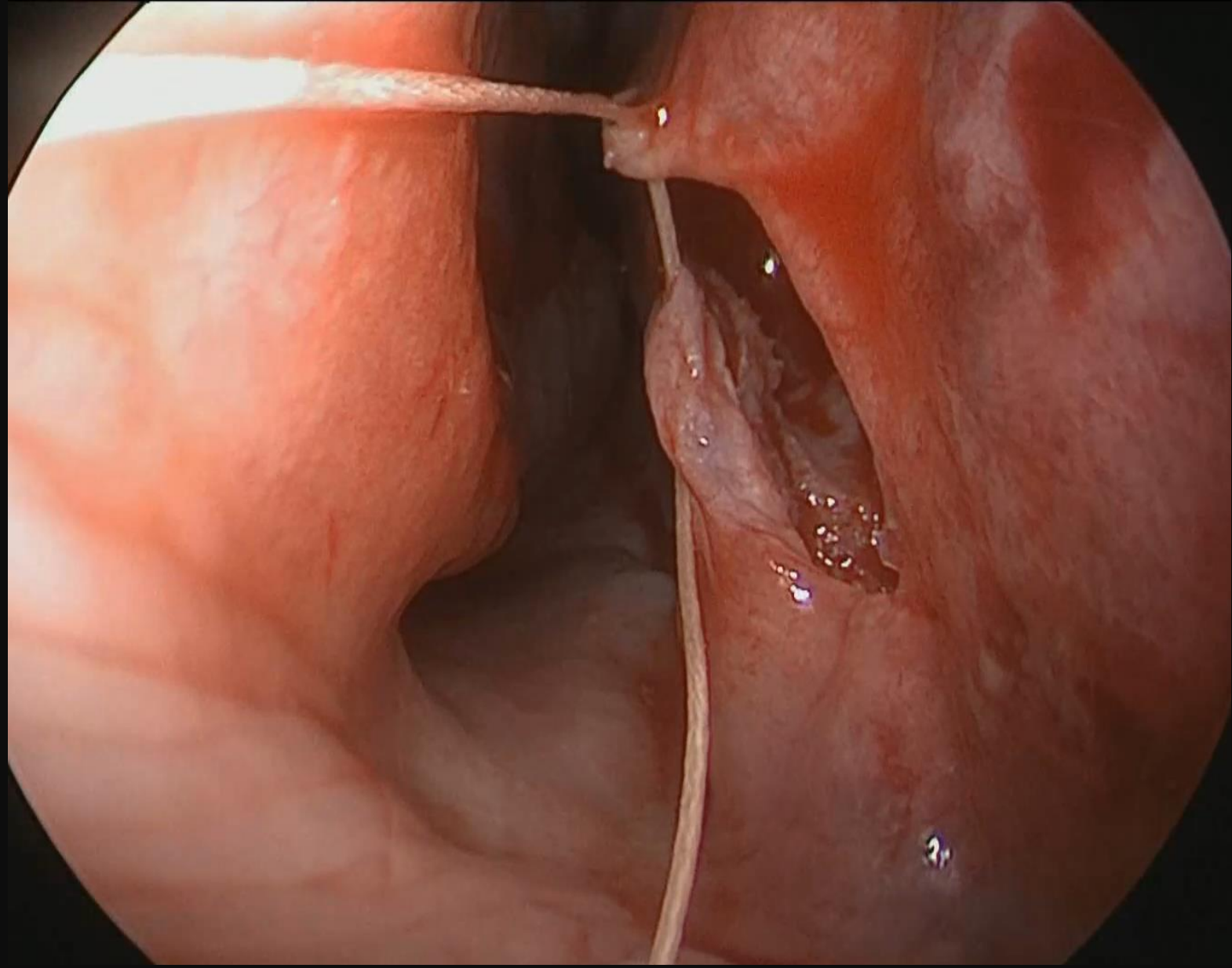
Septoplasty

Technique

What to do with mucosal tears

- Small tears
 - No need to repair
- **Suture of mucosal tears**
 - Large tears
 - Corresponding mucosal tears of both side without cartilage in between
- **Fascia, Tachosil®**
 - Placing under mucoperichondrium, «inner splinting of the tear»



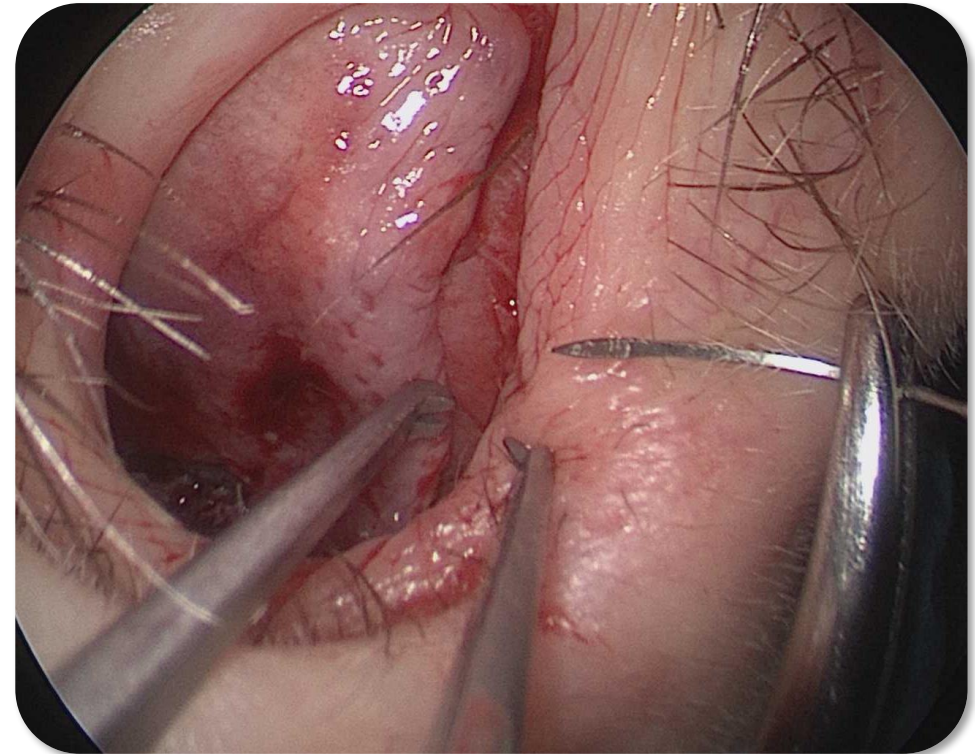


Septoplasty

Technique

Closure of incision

- Suturing of hemitransfixation incision
 - Resorbable suture material

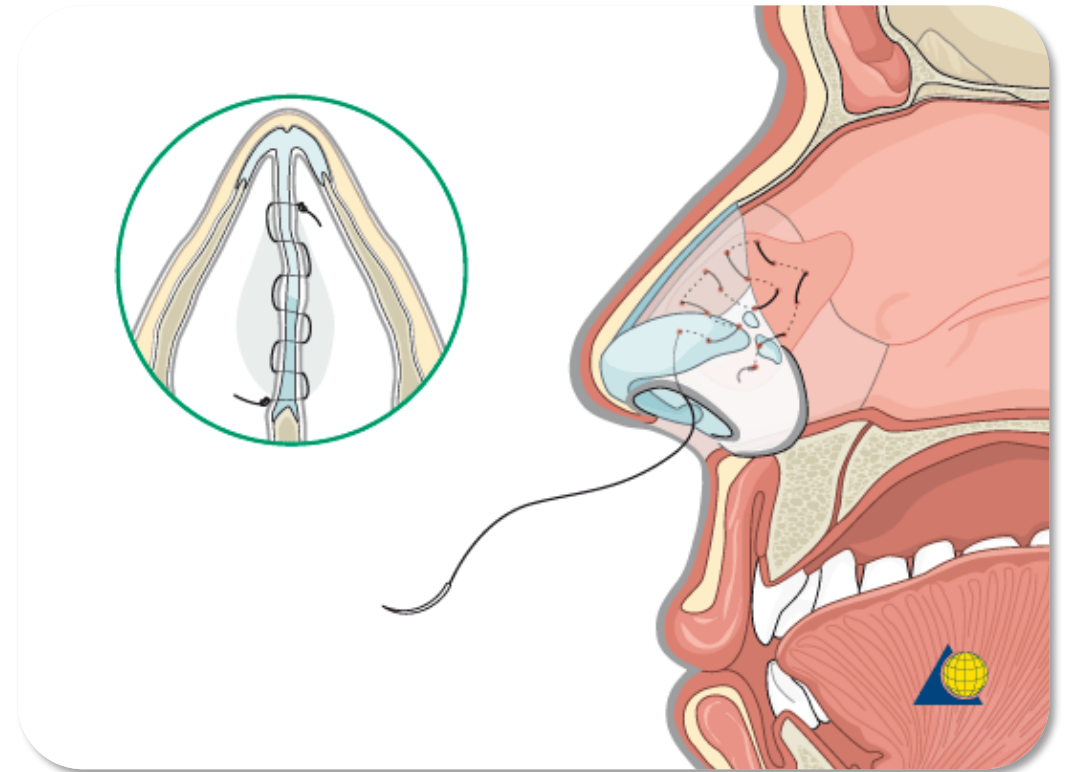


Septoplasty

Technique

Prophylaxis of septal hematoma

- Silicon sheets
- Sutures
 - «Quilting suture»
 - Resorbable
 - Probably less pain.. *



Picture source:Internet

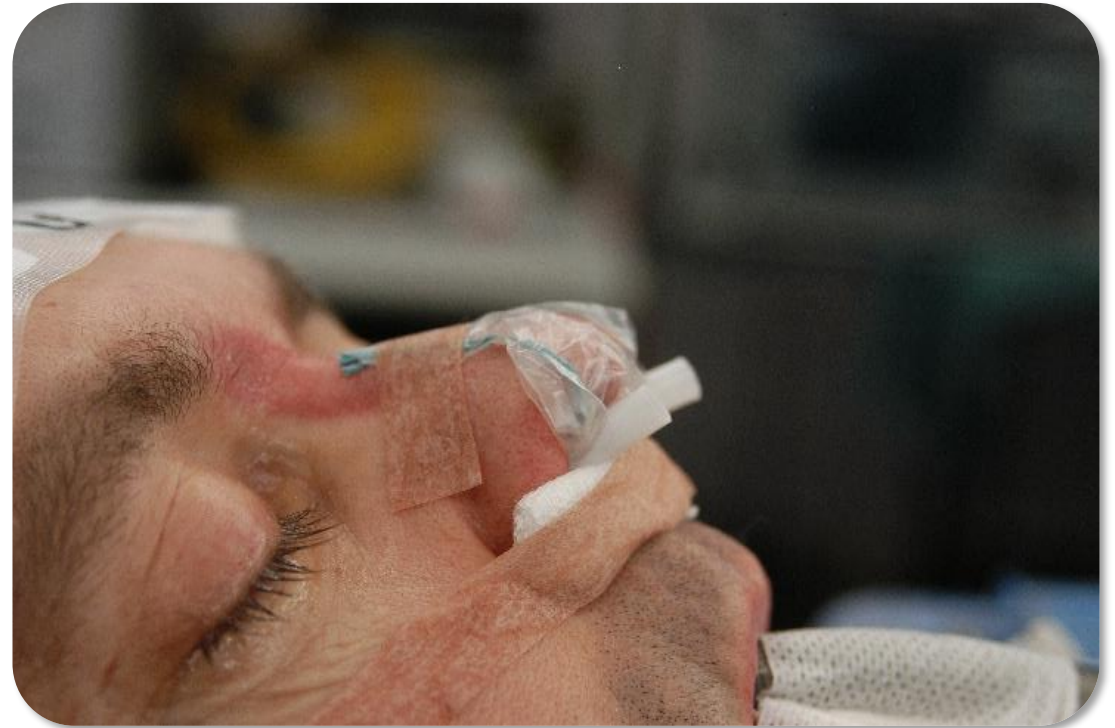*Quin et al. Postoperative Management in the Prevention of Complications after Septoplasty: A Systematic Review. Laryngoscope 2013

Septoplasty

Technique

Prophylaxis of septal hematoma

- Packing (Merocel[®], Netcel[®], etc.), e.g. for 24 hours
- Tubes for breathing («Breathing straws»*)



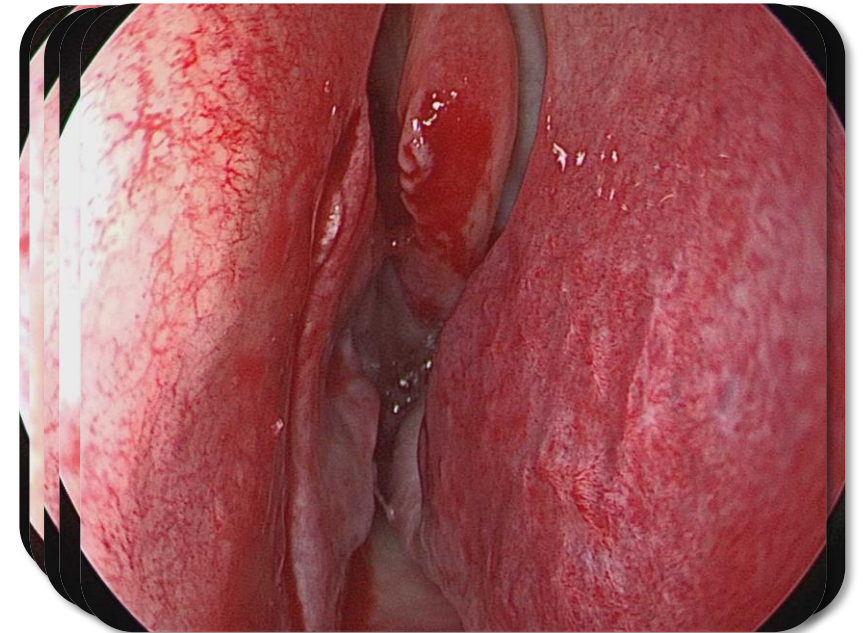
*Dhanasekar G, Simmen D, Briner HR. Breathing straws. *J Laryngol Otol* 2010 Jan; 124(1): 73-74.

Septoplasty

Technique

Endoscopic septoplasty

- Localised septal deviation
 - Septal spur, «cranial» deviation of area III
 - «Straight forward» technique
 - Incision at site of deviation
 - Mobilisation and excision of deviated septum
 - Usually no need for suturing or packing
- Endoscopic technique can be used also for «conventional» septoplasty

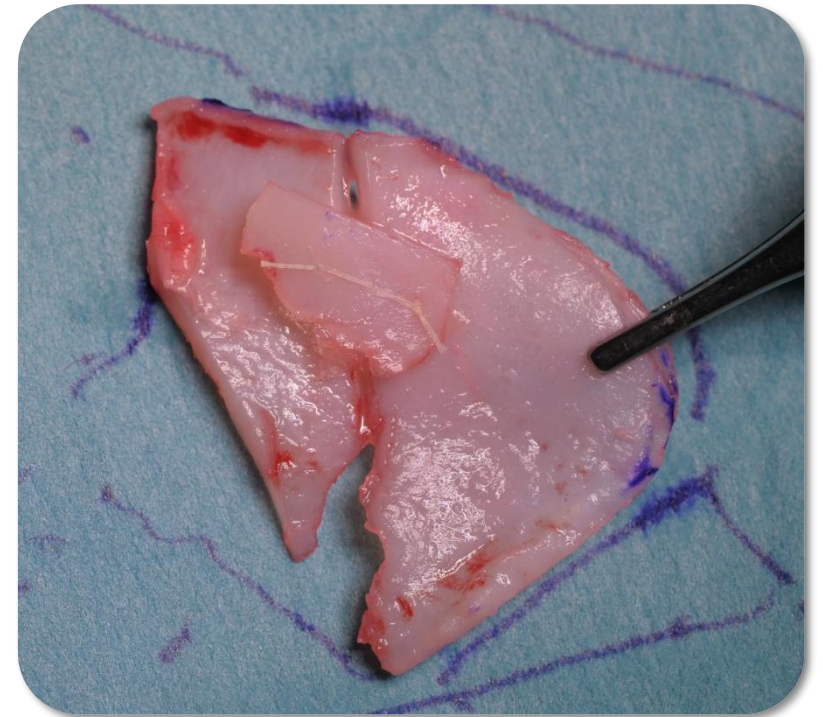


Septoplasty

Technique

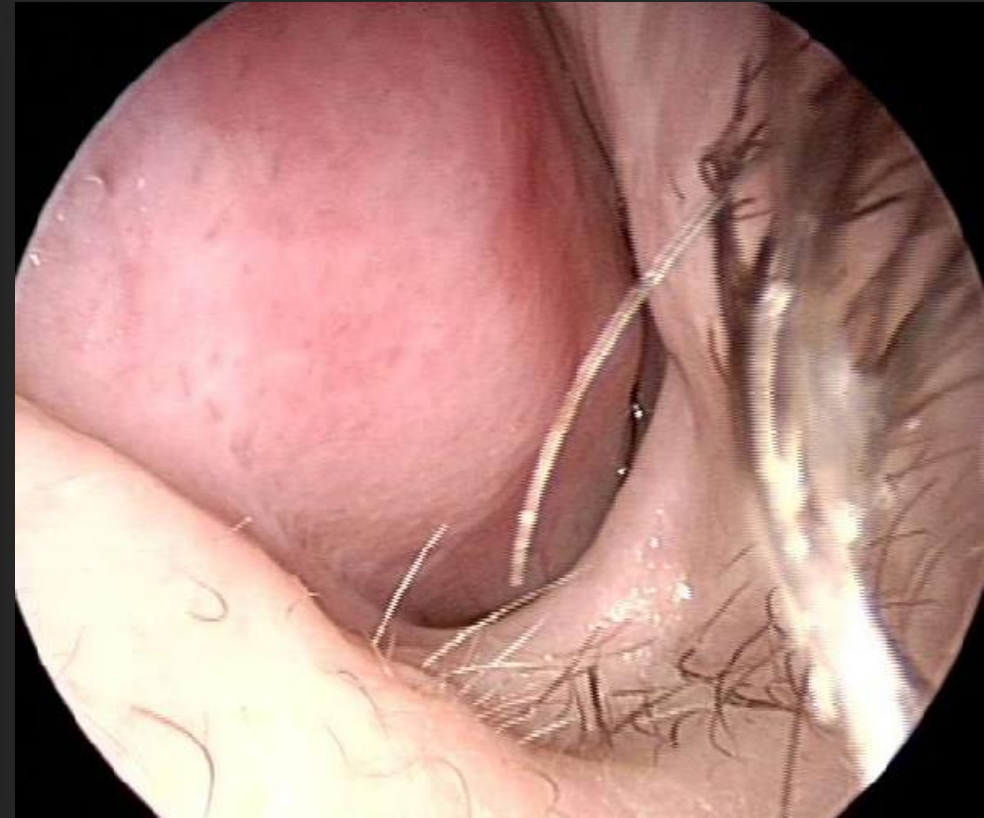
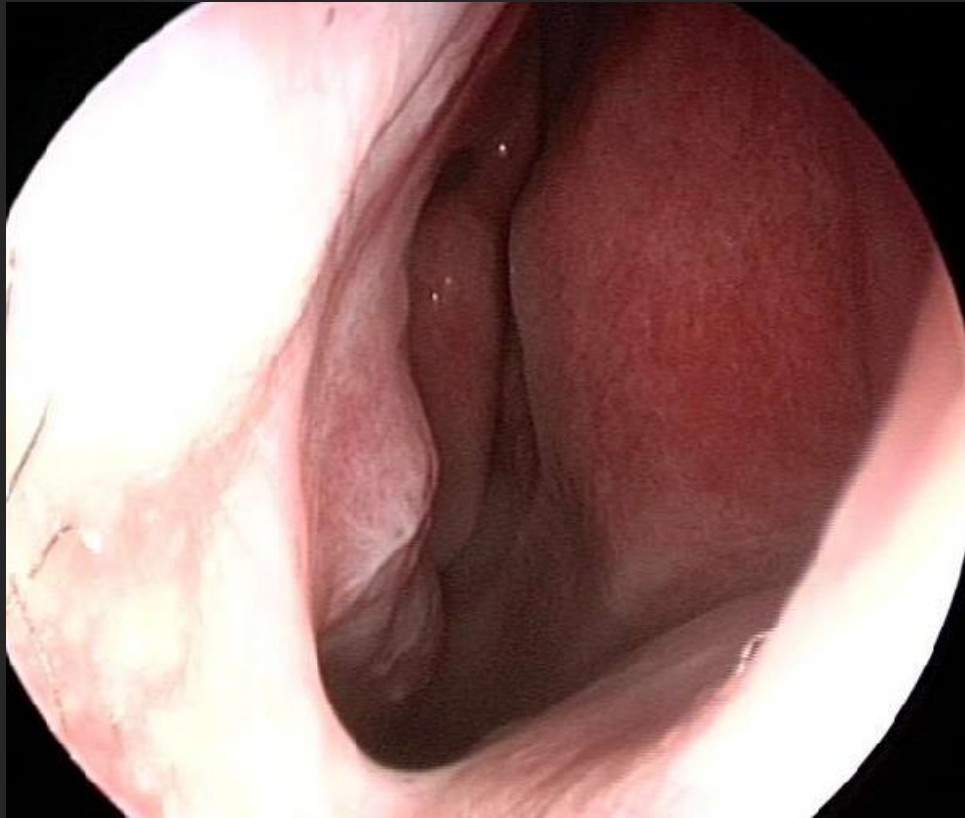
Correction of complex septal deviations

- Extracorporal septoplasty
«Septumaustauschplastik»
 - taking the septum out of the nose, straighten it by remodeling and splinting and replanting it
 - Usually by an open approach
 - Difficult technique
 - Good anatomical results



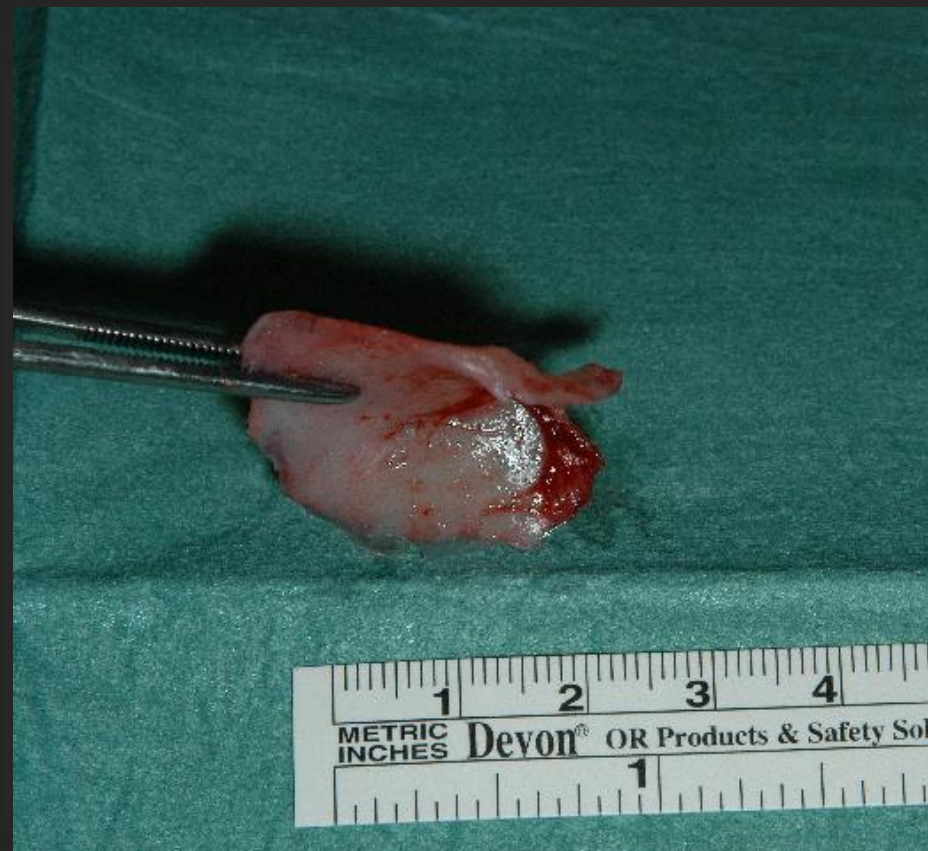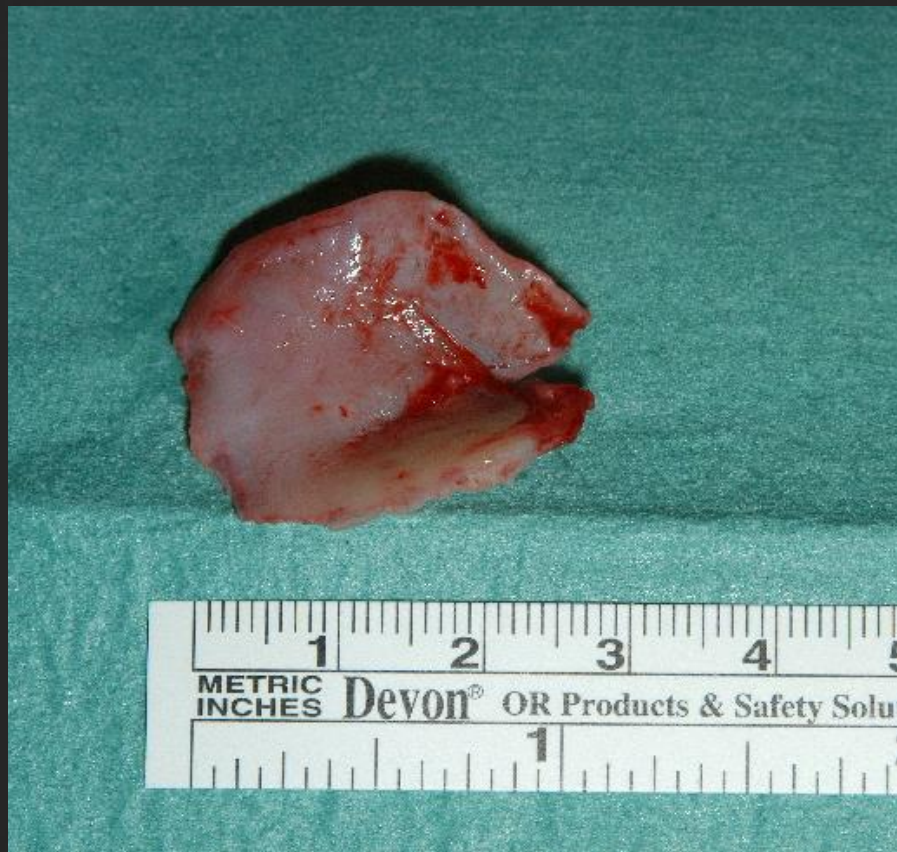„Extracorporal septoplasty“

Pronounced posttraumatic septal deviation to the left side



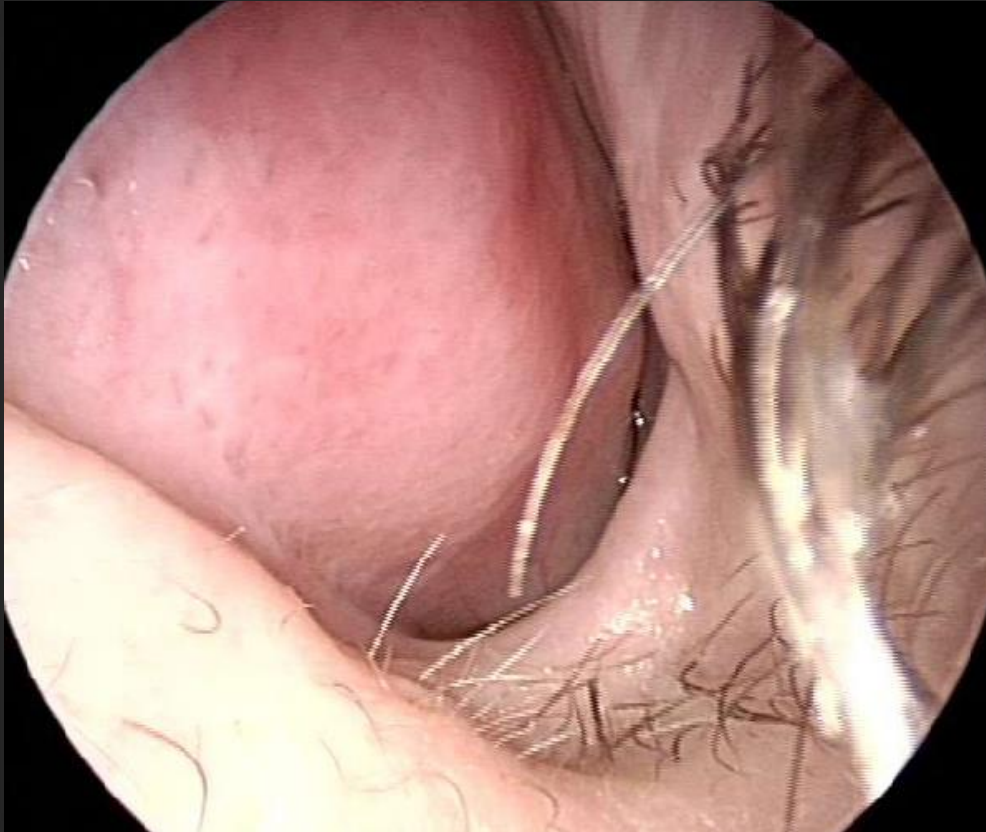
„Extracorporal septoplasty“

Deviated nasal septum

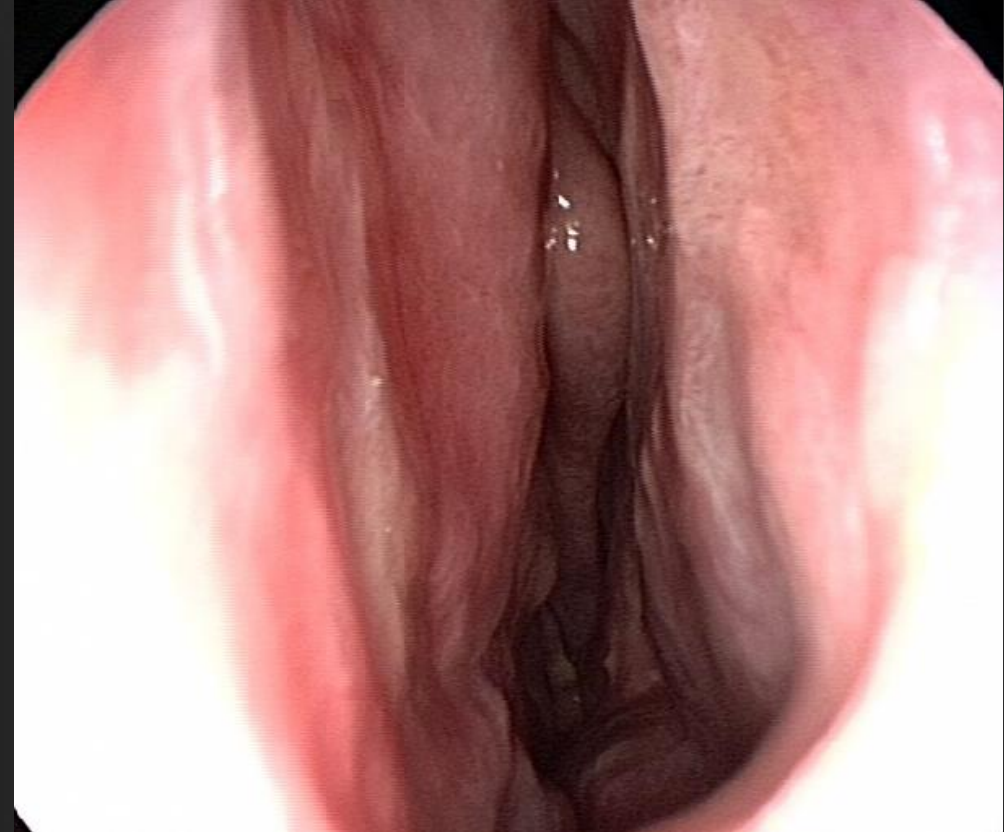

„Extracorporal septoplasty“

Left nose before



Left nose after correction

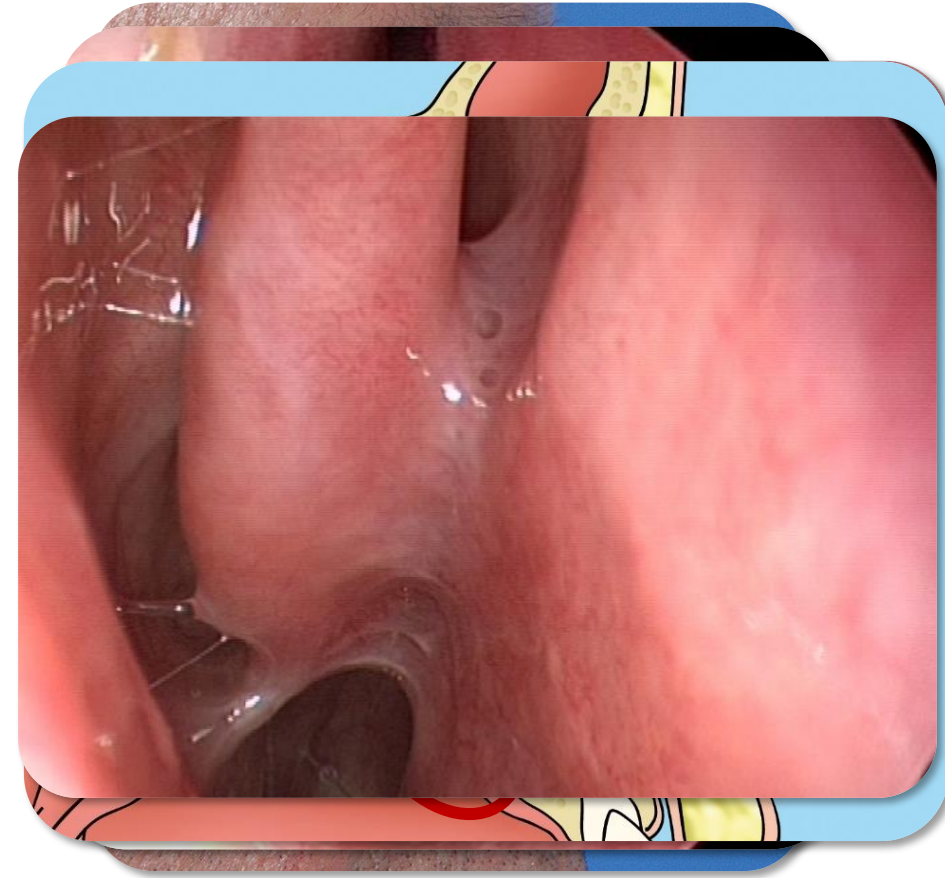


Septoplasty

Complications

Complications

- Bleeding, septal hematoma (~1%)
- Wound infection (0.4-12%*)
- Septal perforation (1,6-6,7%*)
- Changement of the external nose (0.4-3,4%*)
- Recurrence of the septal deviation (~7%)
- Hyposthesia of the incisival nerve
- Others (synechiae, anosmia, csf leak,)



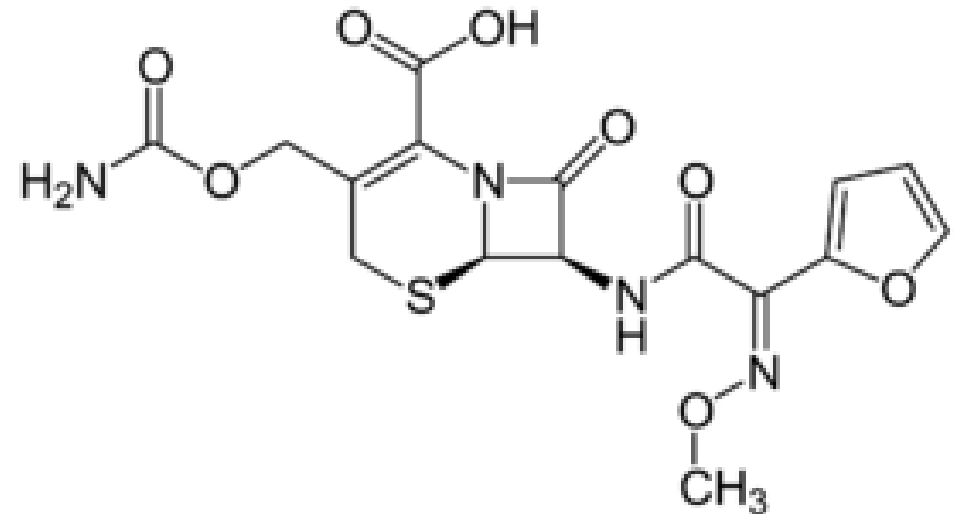
*Ketcham AS et. al. *Complications and management of septoplasty. Otolaryngol Clin North Am* 2010

Septoplasty

Tips and Tricks

„Tips and Tricks“

- Antibiotic prophylaxis not necessary in routine septoplasty *
- Antibiotics to be considered in complex cases (revision surgery, extracorporeal septoplasty, immune deficiency, ..)



Cefuroxim

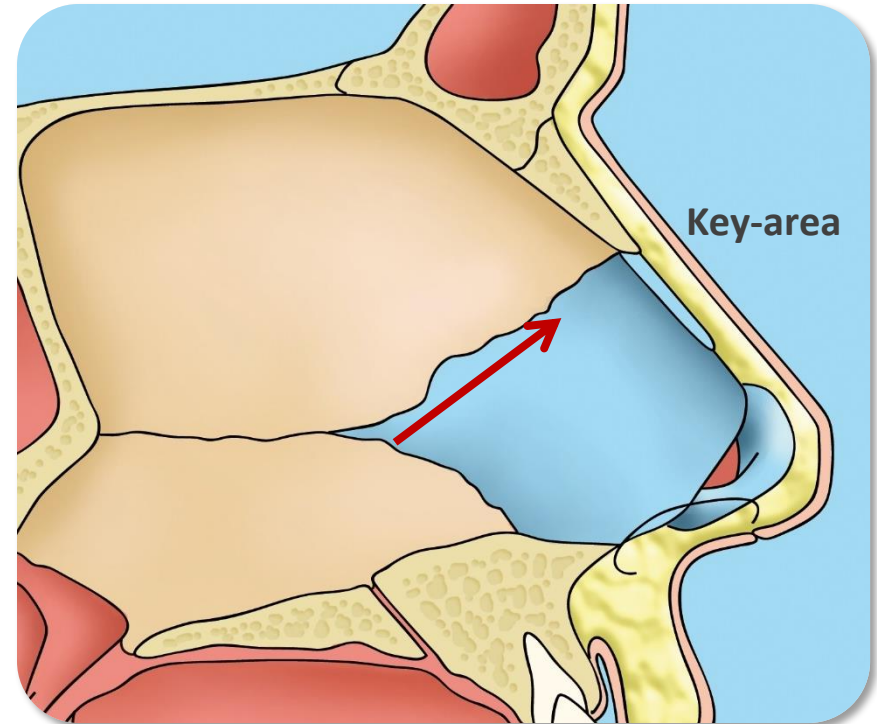
*Ricci G et. al. Antibiotics in septoplasty: evidence or habit? Am J Rhinol Allergology 2012

Septoplasty

Tips and Tricks

„Tips and Tricks“

- Posterior chondrotomy not too cranial, otherwise there is a risk of instability of cartilaginous nasal dorsum (saddle nose deformity)
- Leave at least 10-12 mm

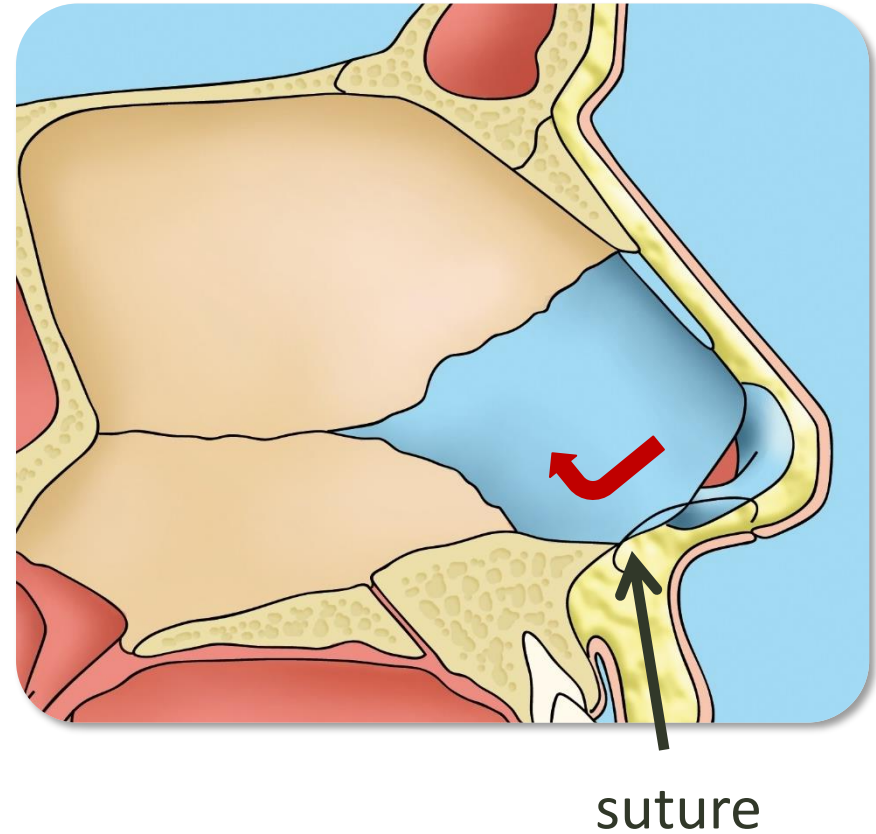


Septoplasty

Tips and Tricks

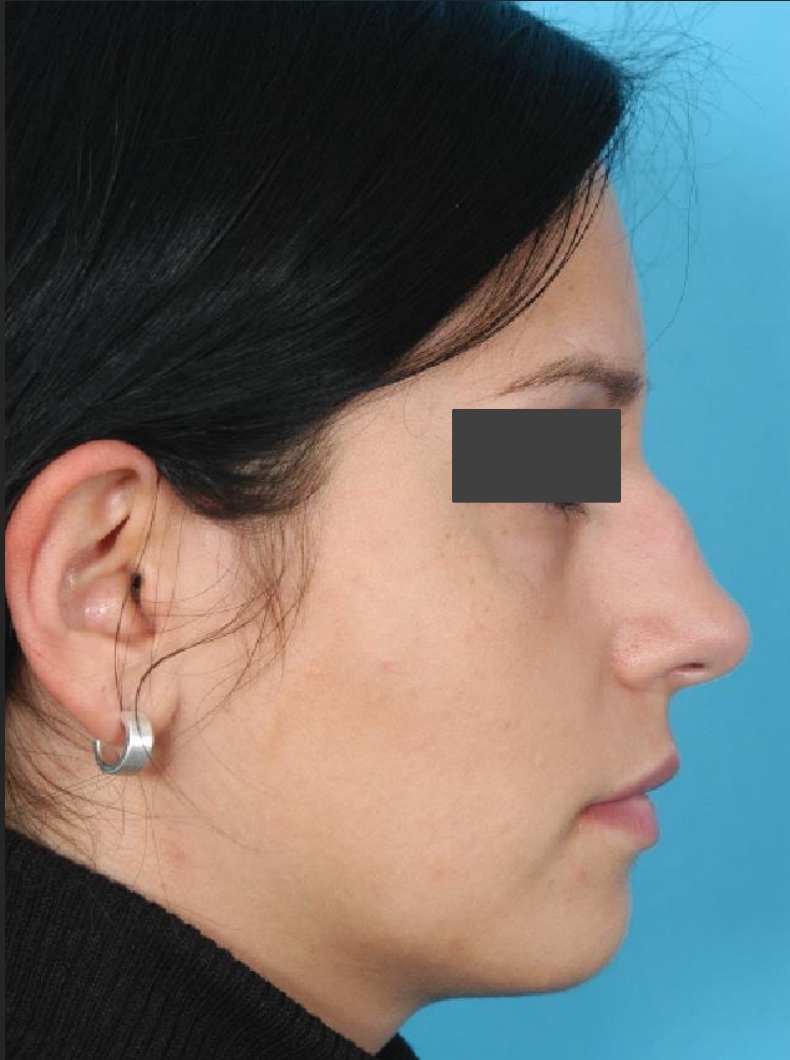„Tips and Tricks“

- If there is any instability of the cartilaginous septum (dorsal displacement), fix it at the anterior nasal spine

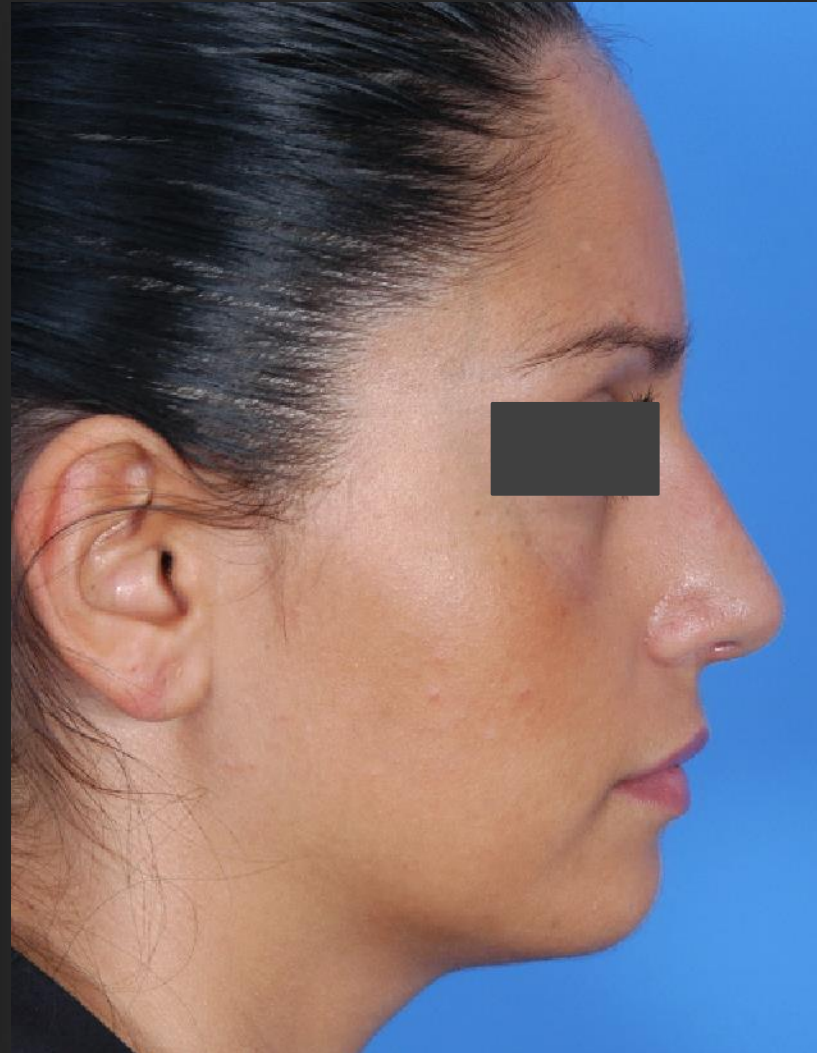

Cartilaginous saddle deformity after septoplasty

Status after septoplasty



After correction (augmentation rhinoplasty)

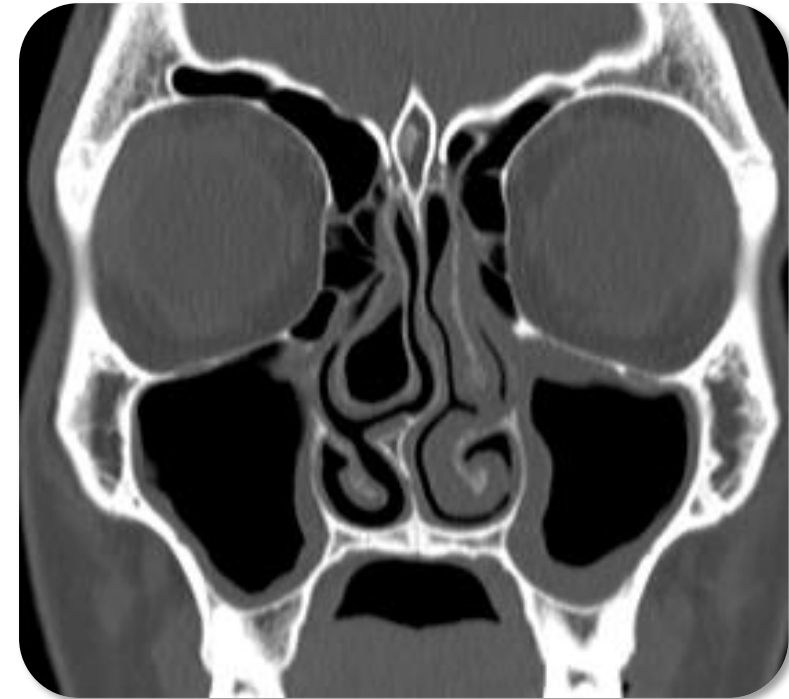


Turbinoplasty

Basics

Basics

- Reduction surgery of the turbinates - «turbinoplasty»:
 - **Goal: Enlargement of the nasal airways by volume reduction of the turbinates**
 - Most often reduction surgery of the inferior turbinates
 - Occasionally reduction of the middle turbinate (Concha bullosa)

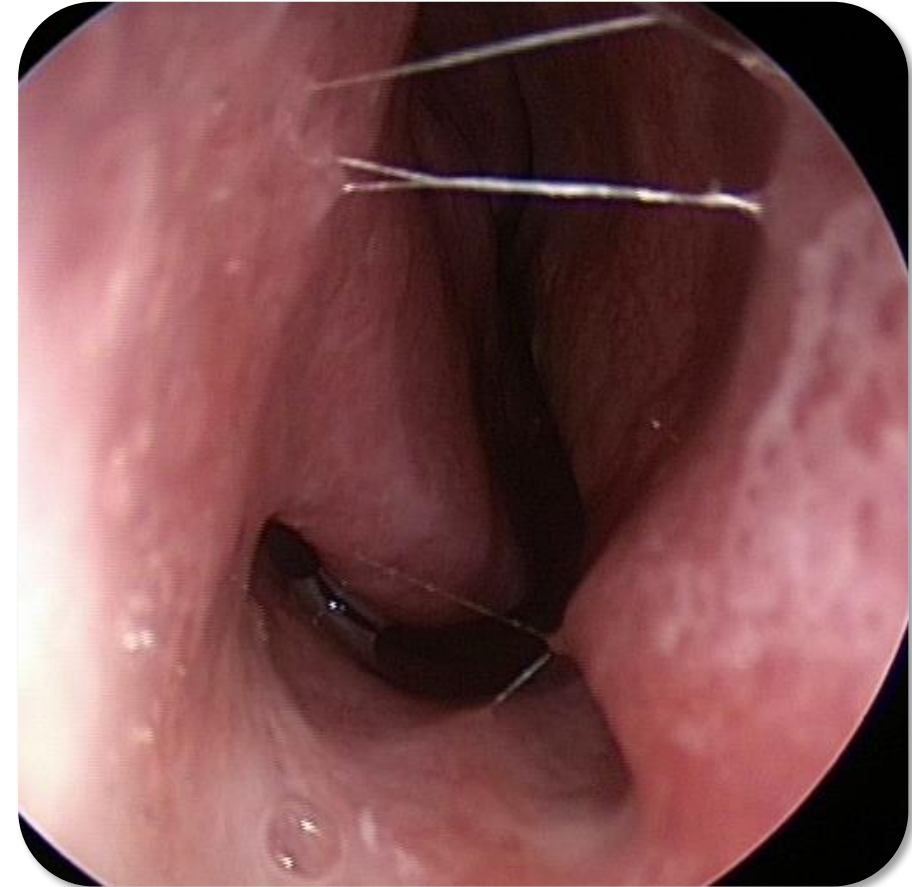

Turbinoplasty

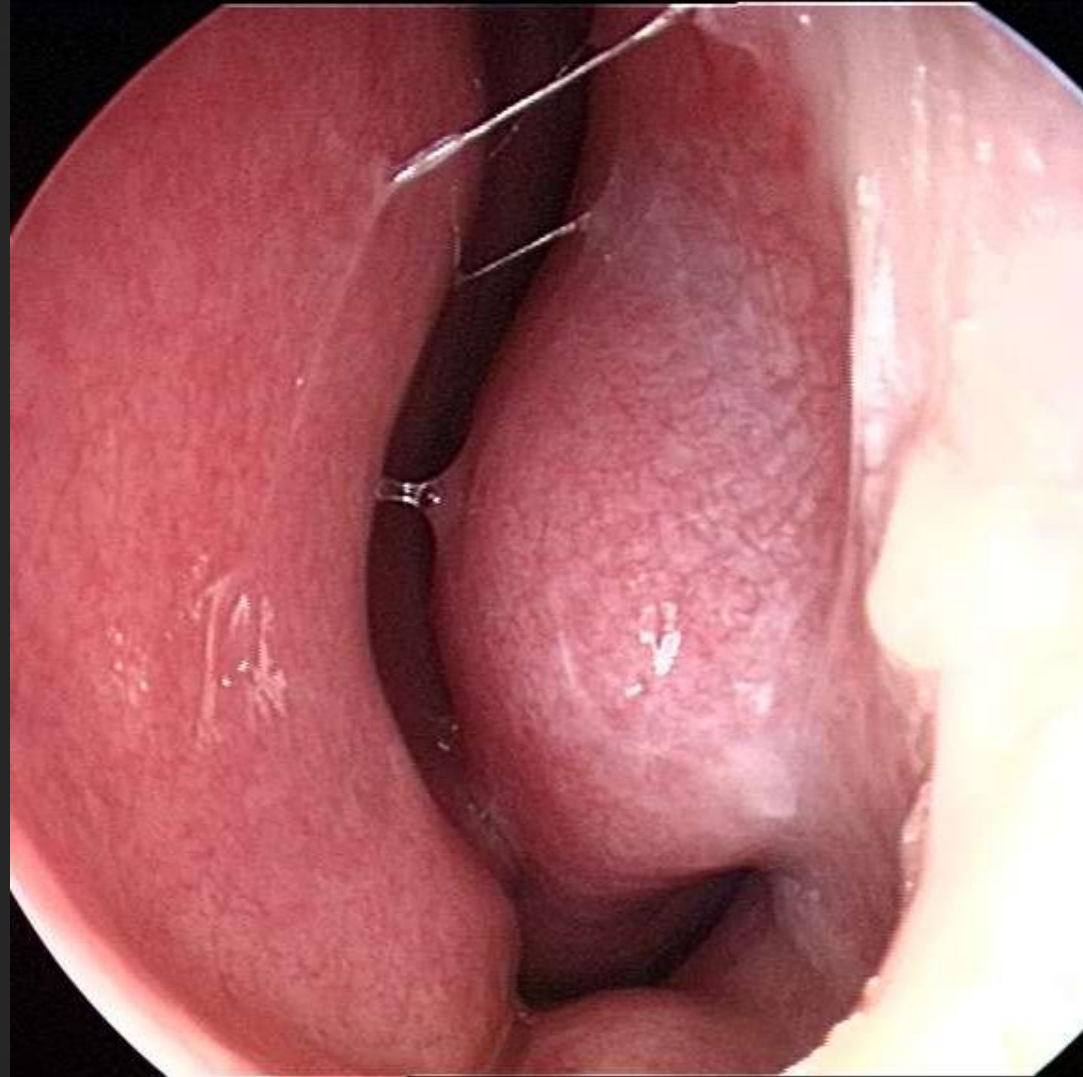
Indications

Indications

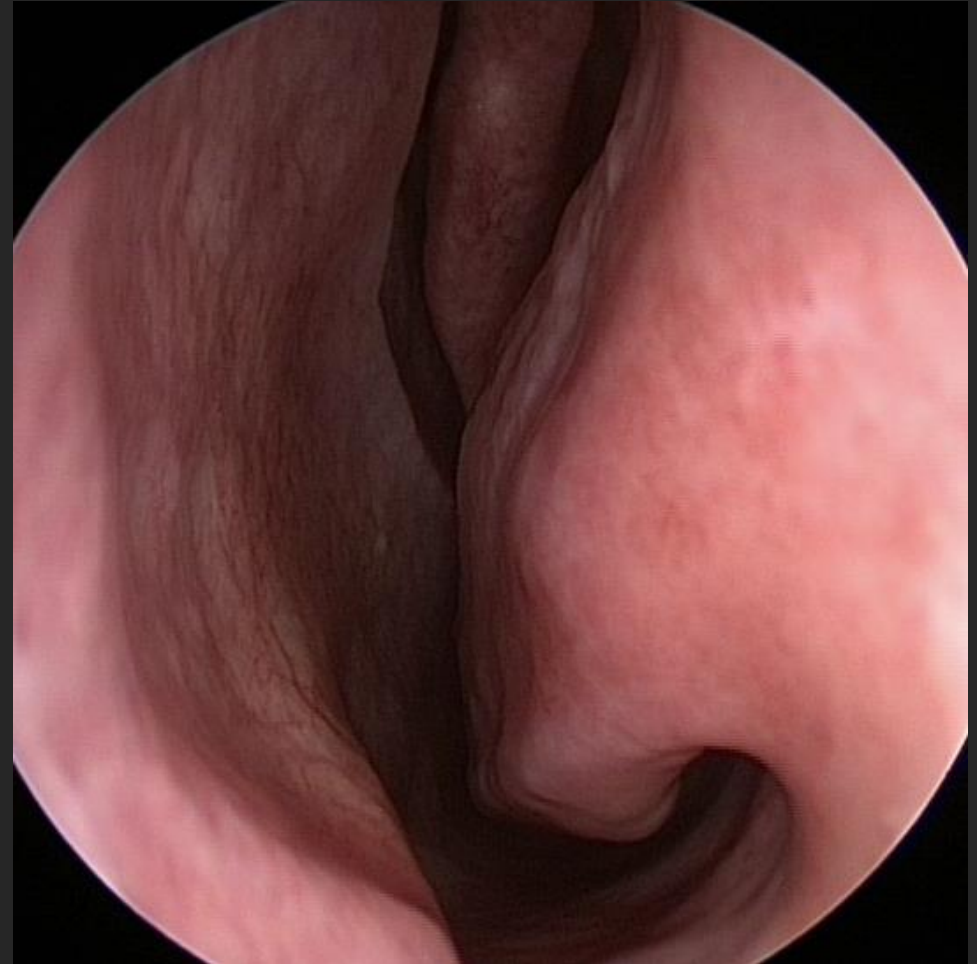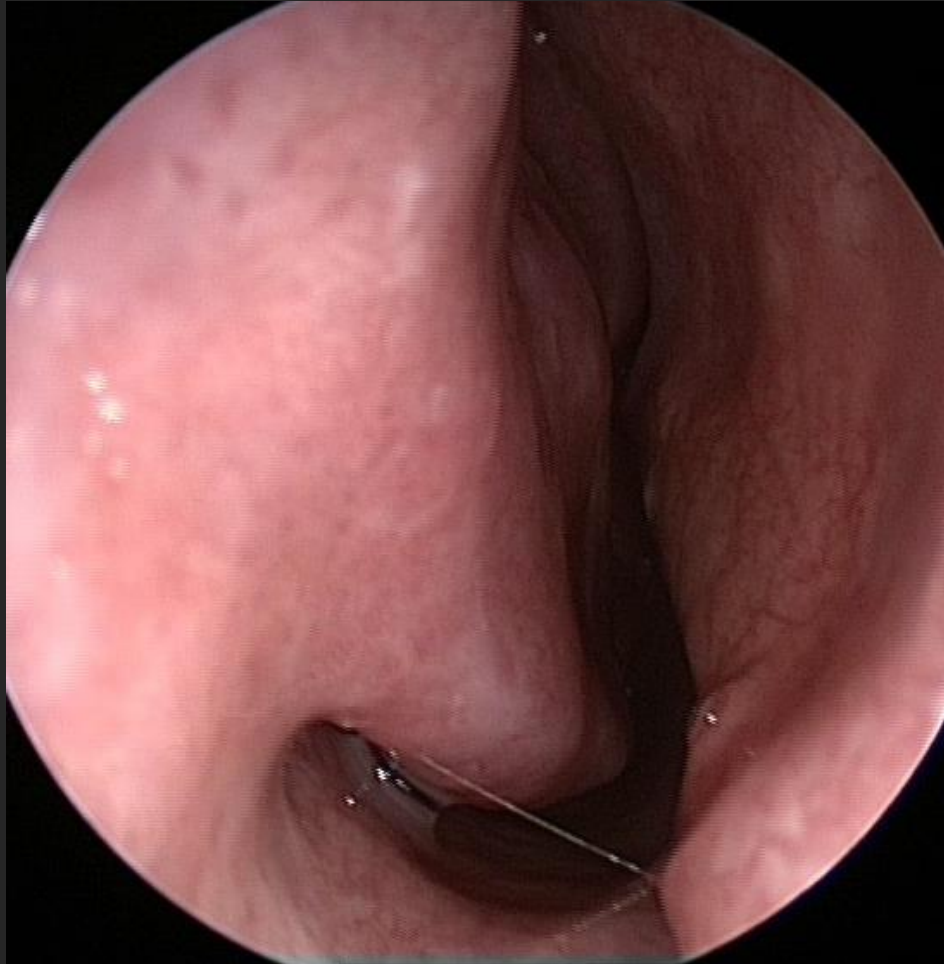
- **Impaired nasal breathing**, not sufficiently responding to medical treatment
- Chronic allergic rhinitis
- Chronic unspecific rhinitis
- Others??



Chronic allergic rhinitis



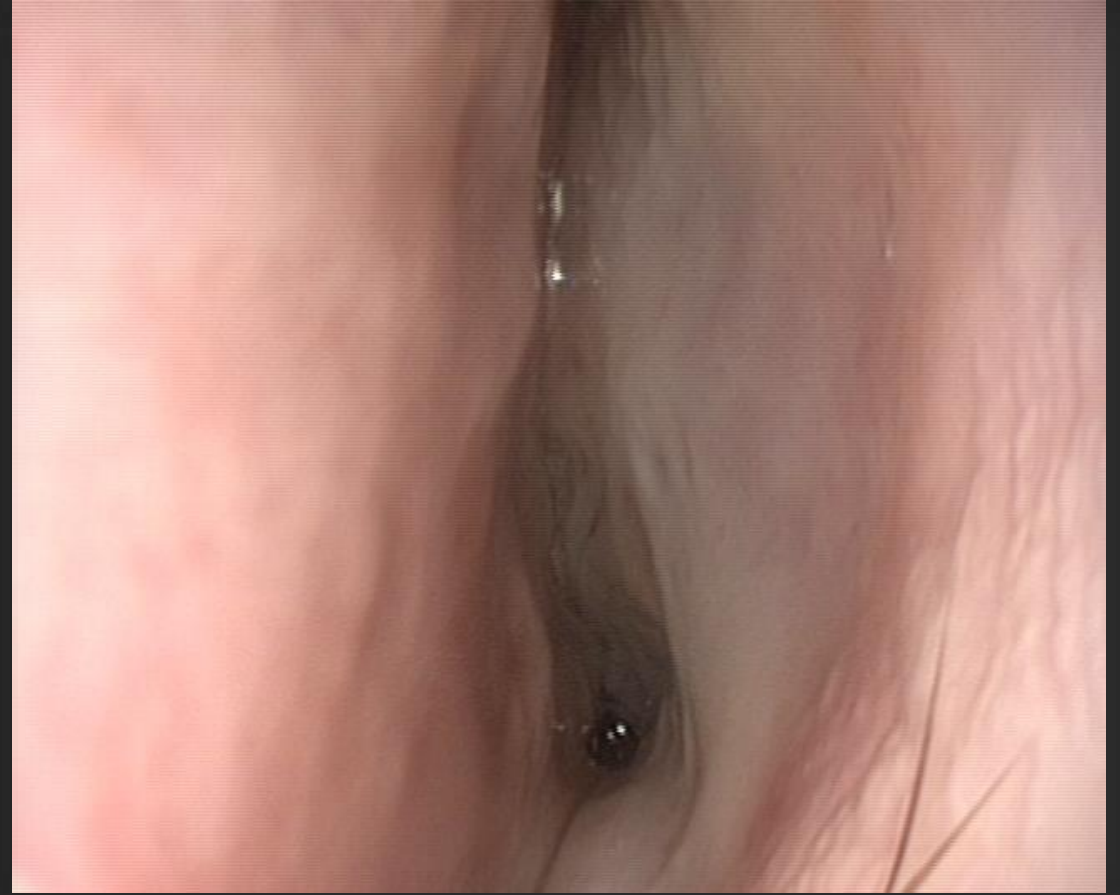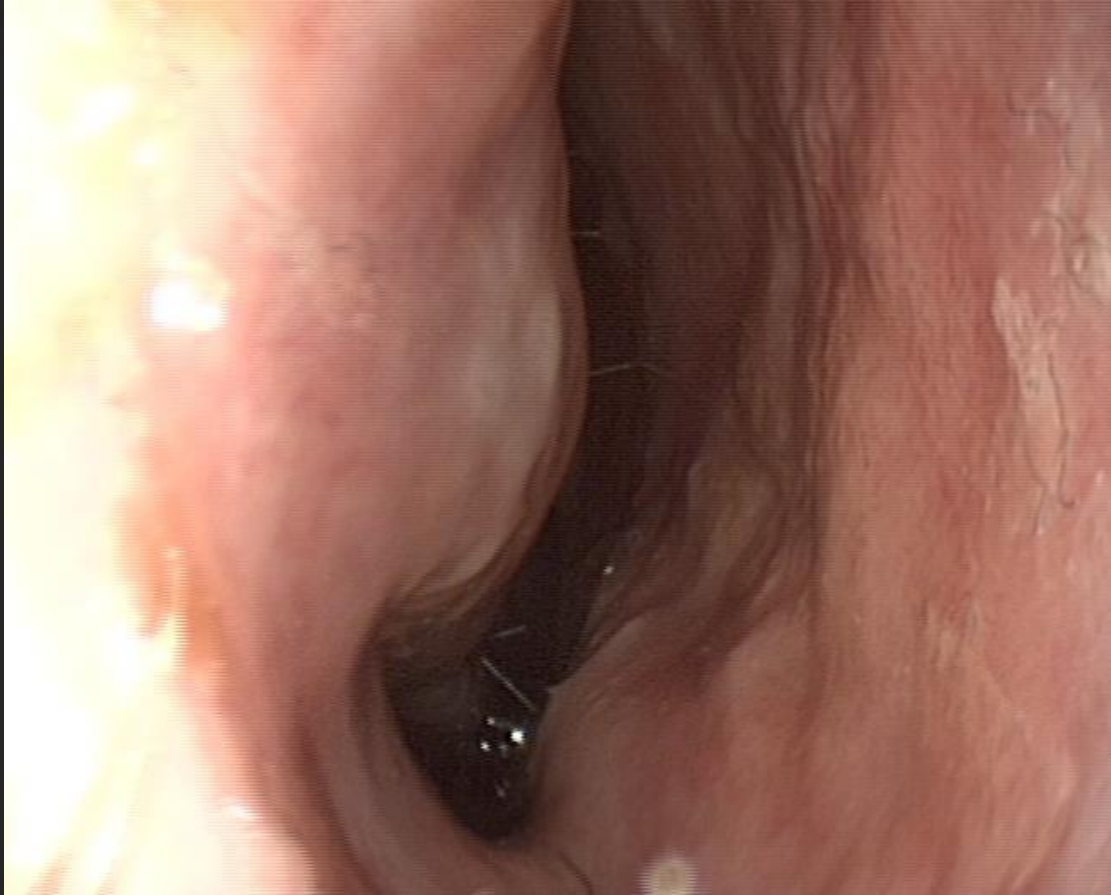Chronic unspecific rhinitis



After decongestion

Chronic unspecific rhinitis

Systemic disease?

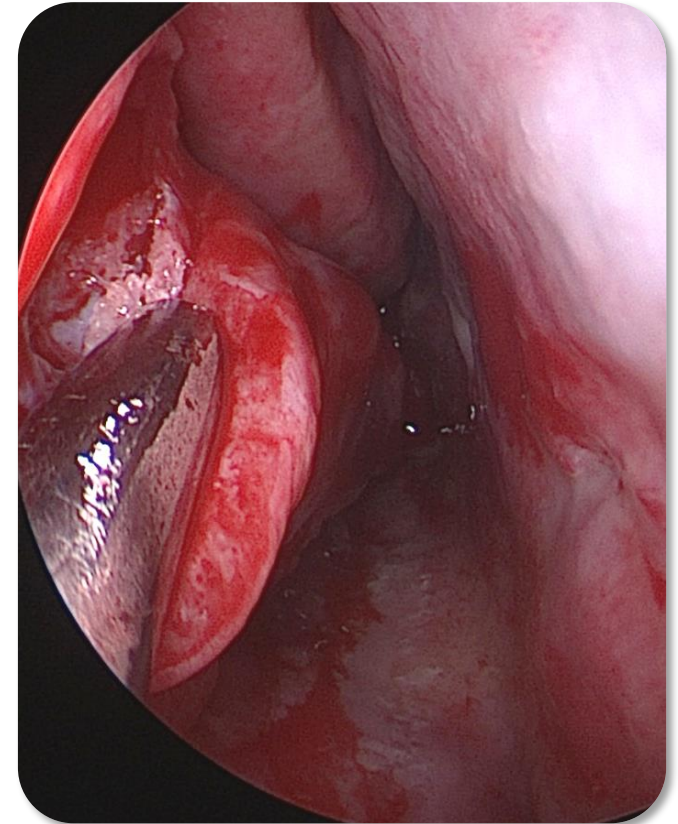


Turbinoplasty

Technique

Technique

- Volume reduction of the inferior turbinate:
 - Location:
 - anterior third
 - full length of the turbinate
 - Resection of
 - mucosa (submucous tissue)
 - bone
 - mucosa and bone
- Lateralisation of inferior turbinate

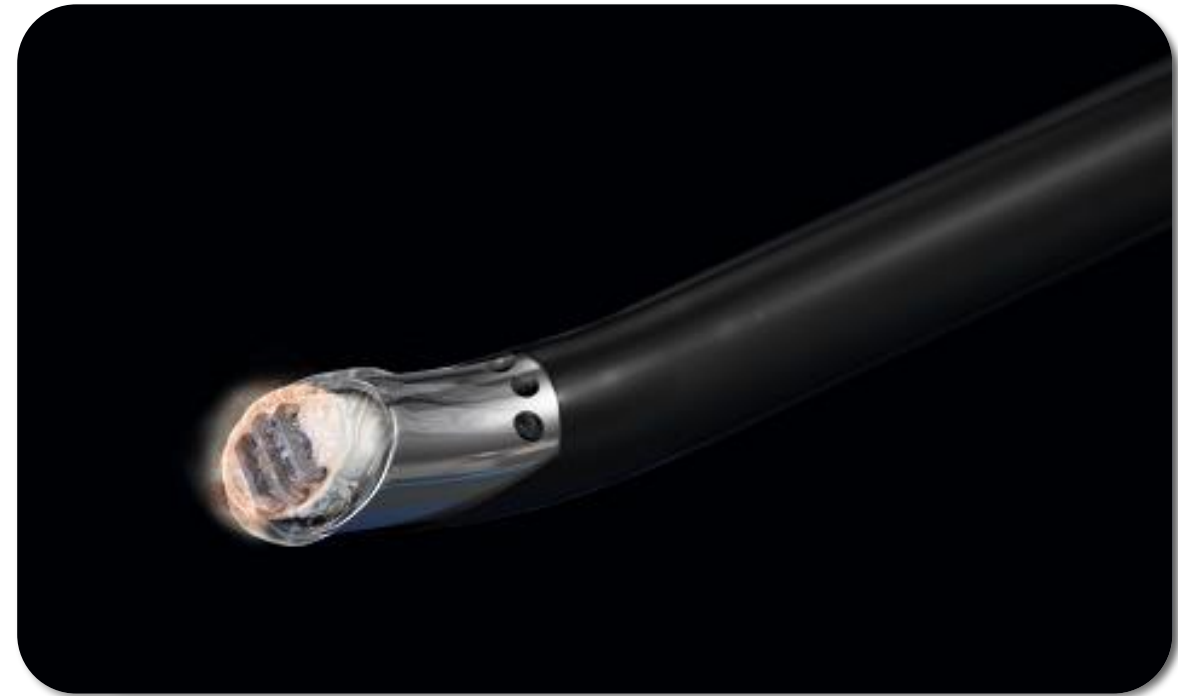

Turbinoplasty

Technique

Technique

- Surgical instruments:
 - Cold steel (Scalpel, scissors, ..)
 - Powered instruments (shaver..)
 - High frequency coagulation/ablation
 - Laser
 - Coblation[®], others

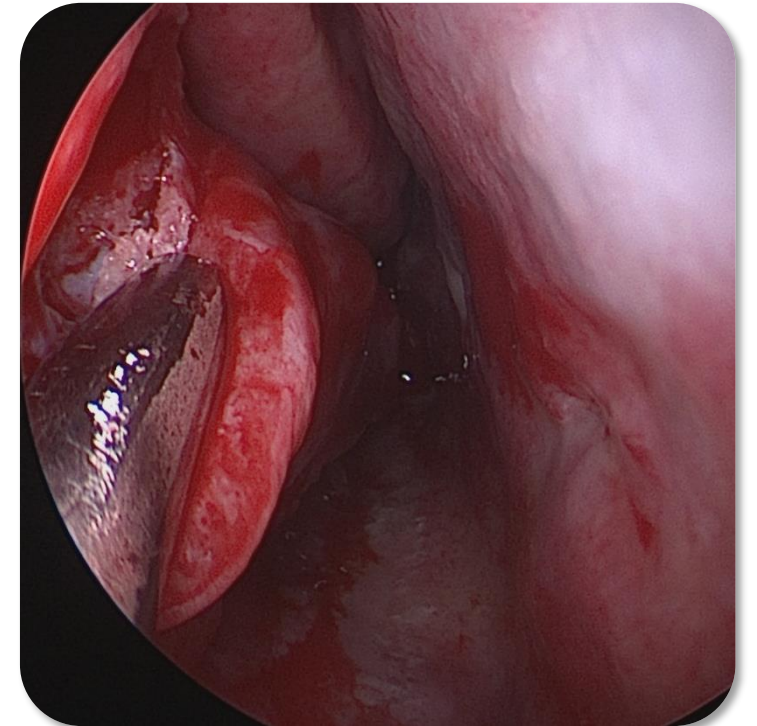


Turbinoplasty

Technique

Technique – results

- Rate of «improvement»
 - Cryotherapy 38%
 - Submucosal resection cold steel 52%
 - Electrocautery 67%
 - Partial turbinectomy 71%
 - Laser 74%
 - Total turbinectomy 79%
 - Radiofrequency ablation 85%
 - Submucosal resection microdebrider 91%



Turbinoplasty Technique

Technique - results

Table 3. Subjective Data *

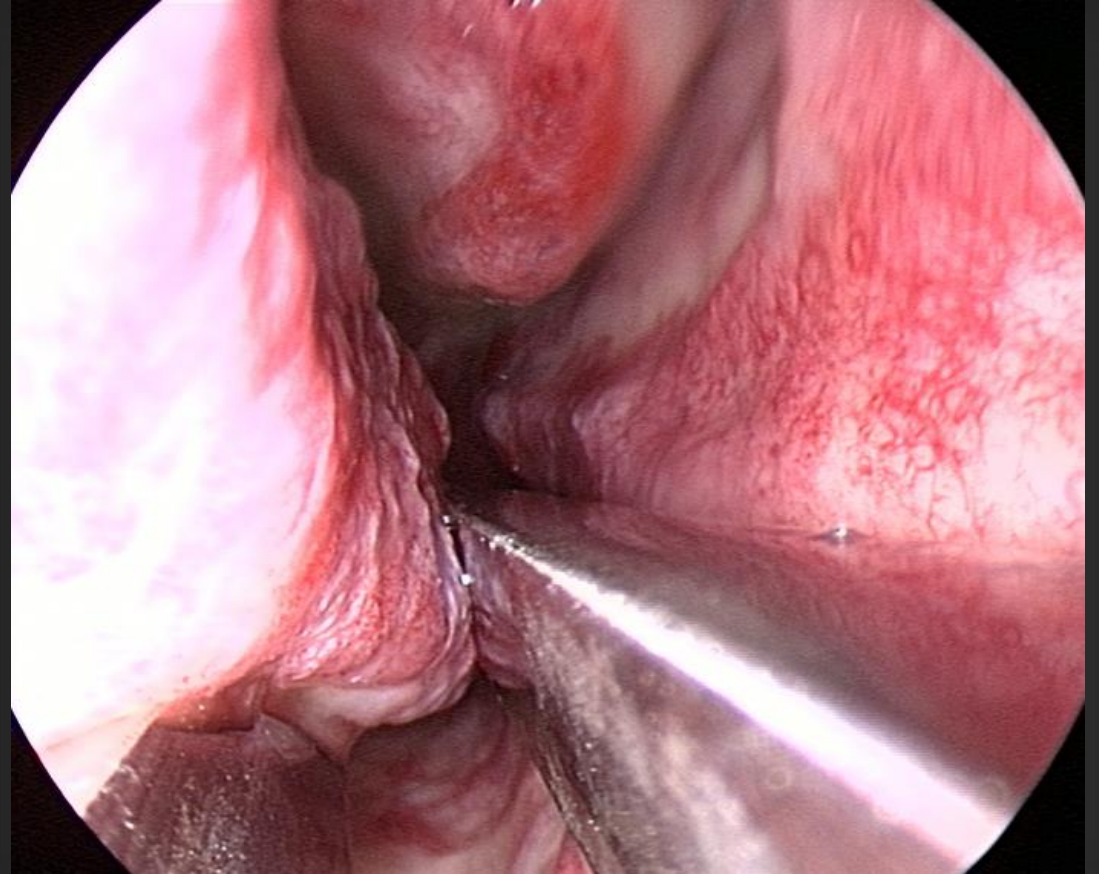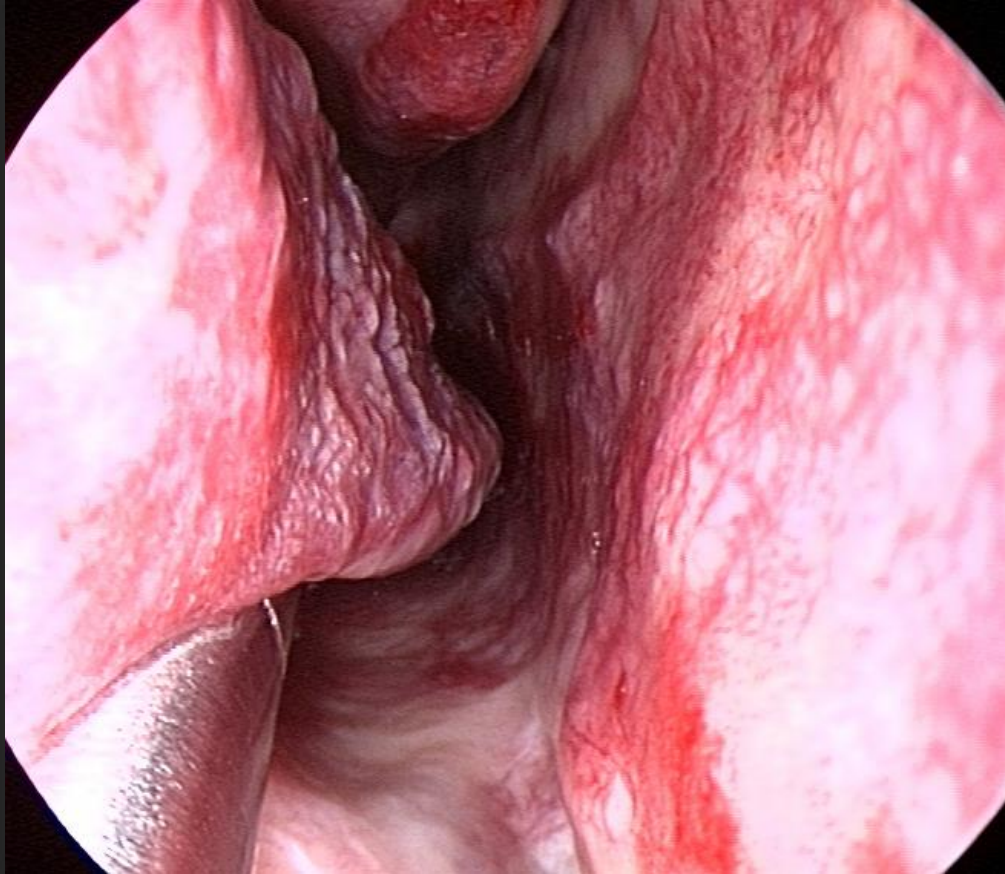Subjective	Average Proportion of Patients with Improvement (%)	Average Proportion of Patients with Improvement in VAS Score (%)
Total turbinectomy	79	39.1
Partial turbinectomy	71.3	48.5
SMR manual	52	n/a
SMR microdebrider	91.2	65.1
Electrocautery	67.3	54.1
Laser	74.2	44.6
Cryotherapy	38.2	69
Radiofrequency ablation	85.5	48.9
Turbinate outfracture	n/a	n/a

better:
40-90%

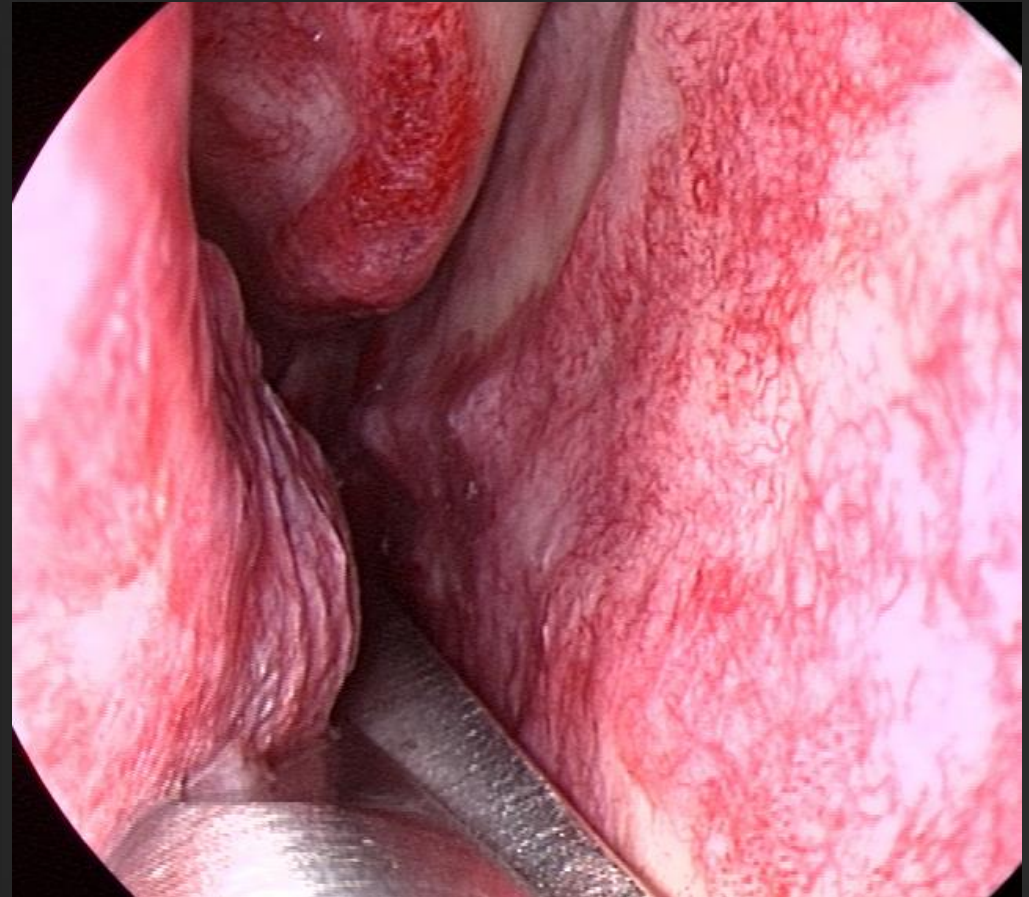
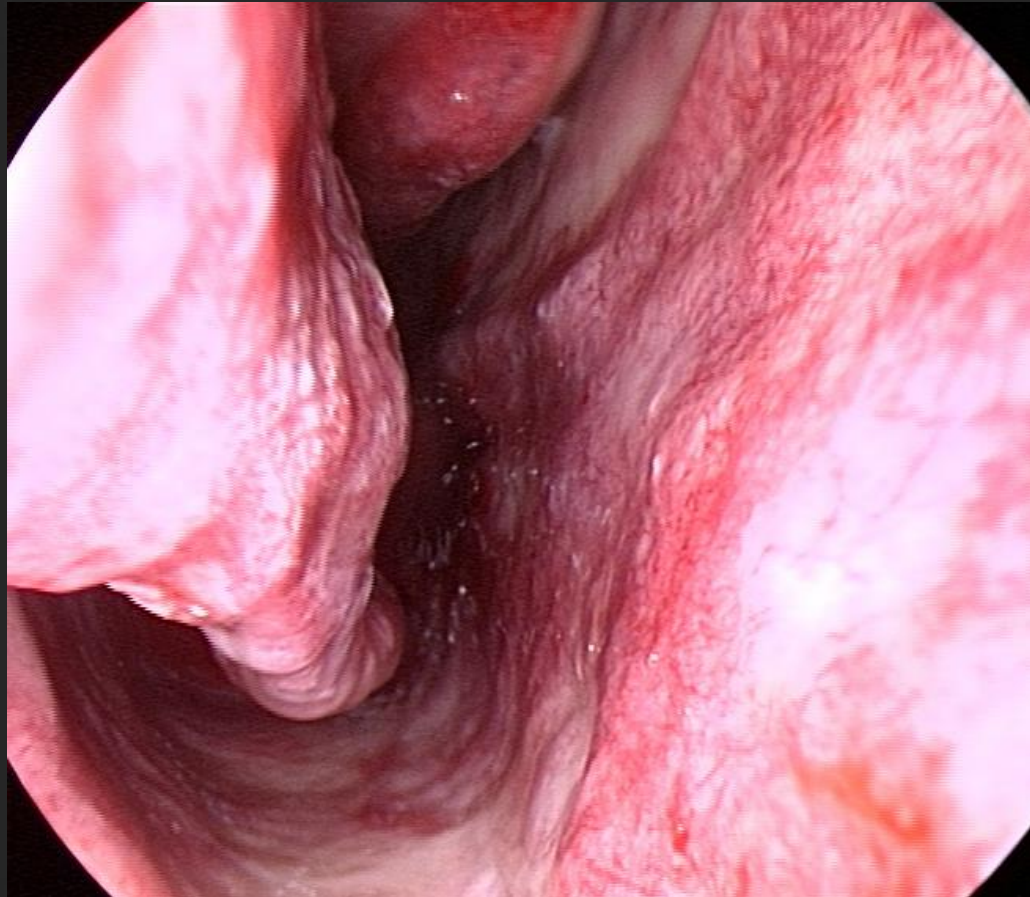
VAS, visual analogue scale; SMR, submucous resection; n/a, not available.

*Sinno S et al. Inferior Turbinate Hypertrophy in Rhinoplasty: Systematic Review of Surgical Techniques. *Plast Reconstr. Surg.* 2016

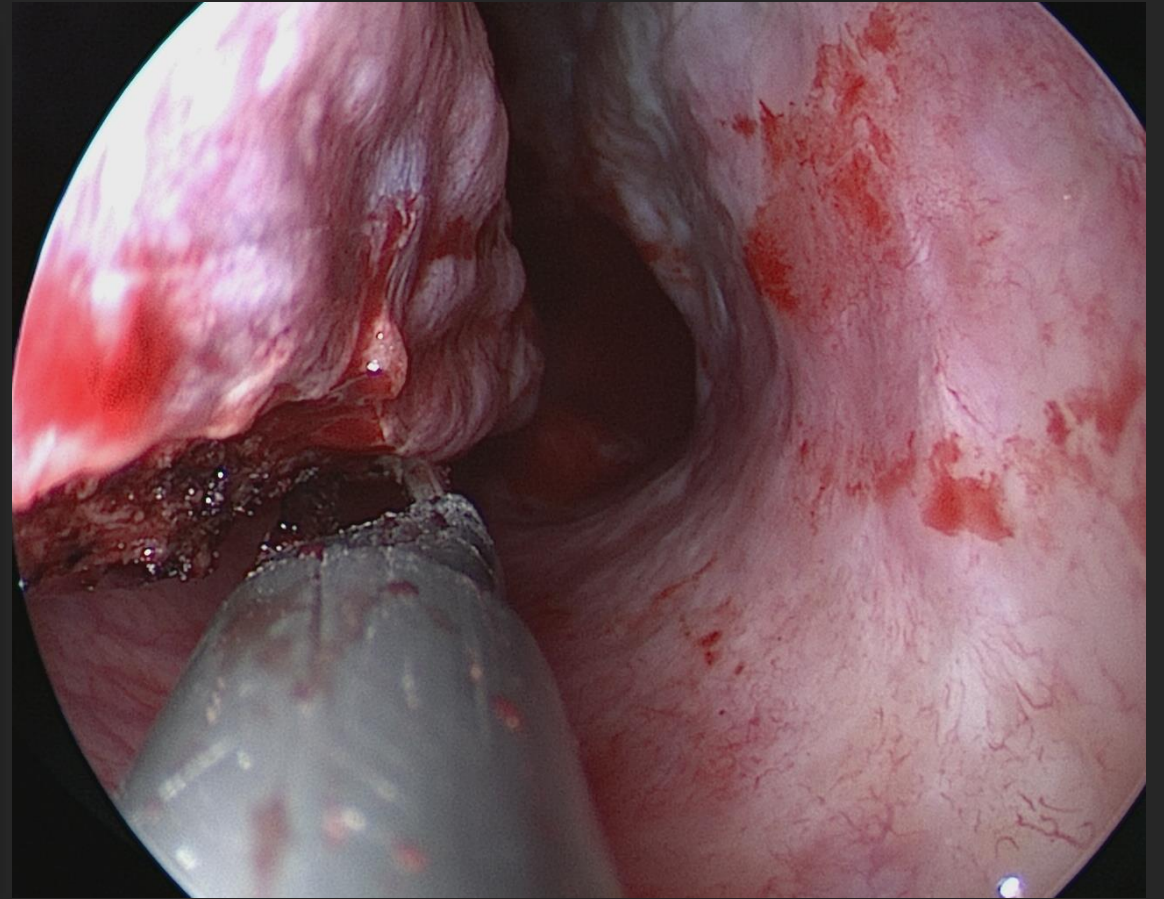
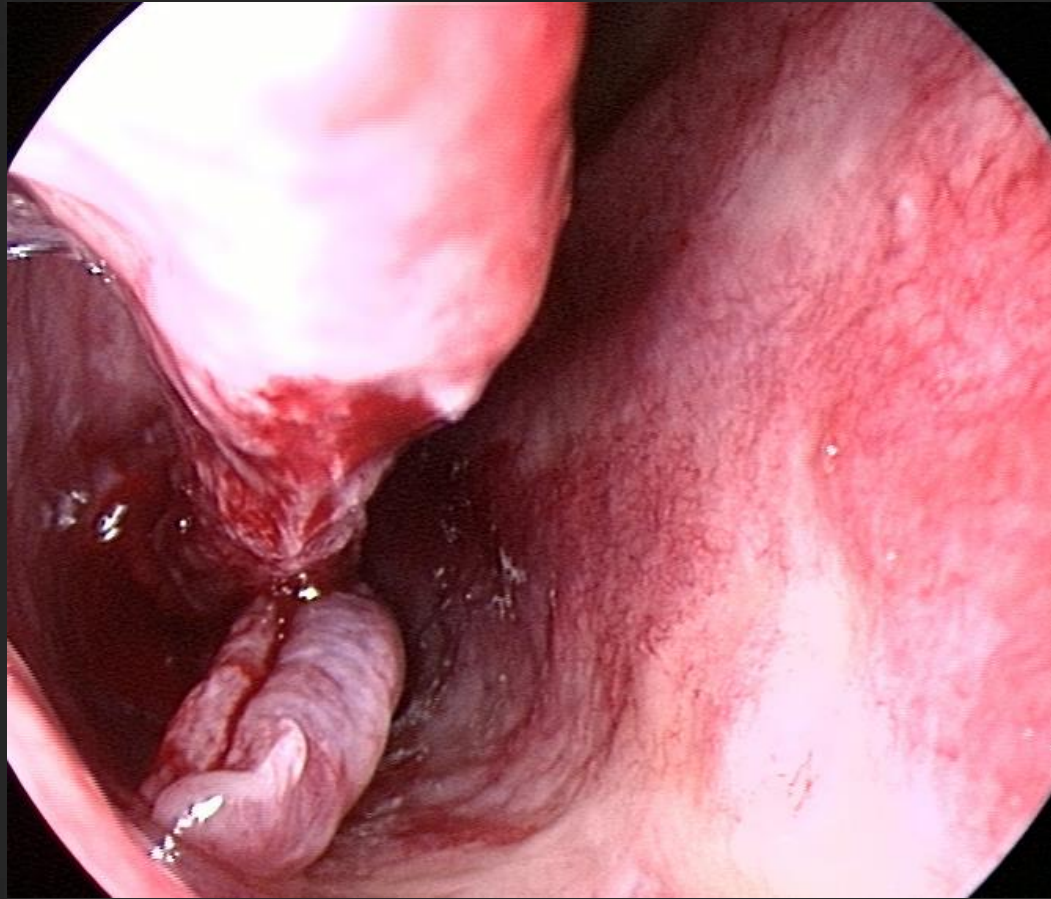
“Cold steel” - partial resection of inferior turbinate (conchotomy)



“Cold steel” - partial resection of inferior turbinate (conchotomy)



“Cold steel” - partial resection of inferior turbinate (conchotomy)

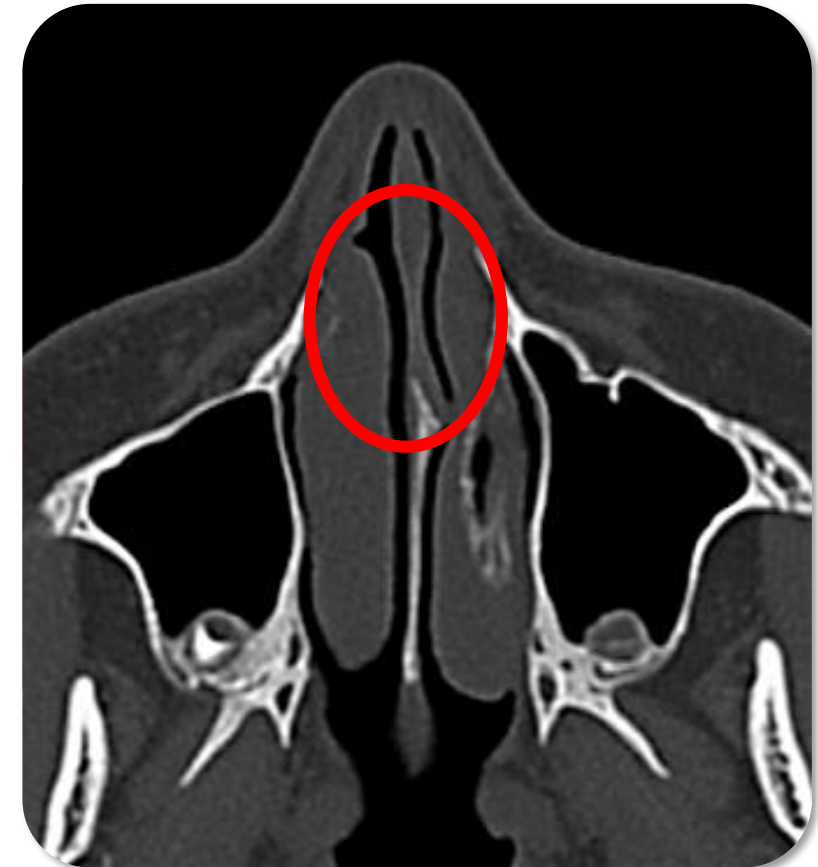


Turbinoplasty

Technique

Pyriform turbinoplasty

- Volume reduction by submucous resection of anterior insertion of inferior turbinate bone
- Most narrow part of the nasal airway
- Area of pyriform aperture
⇒ «pyriform turbinoplasty»

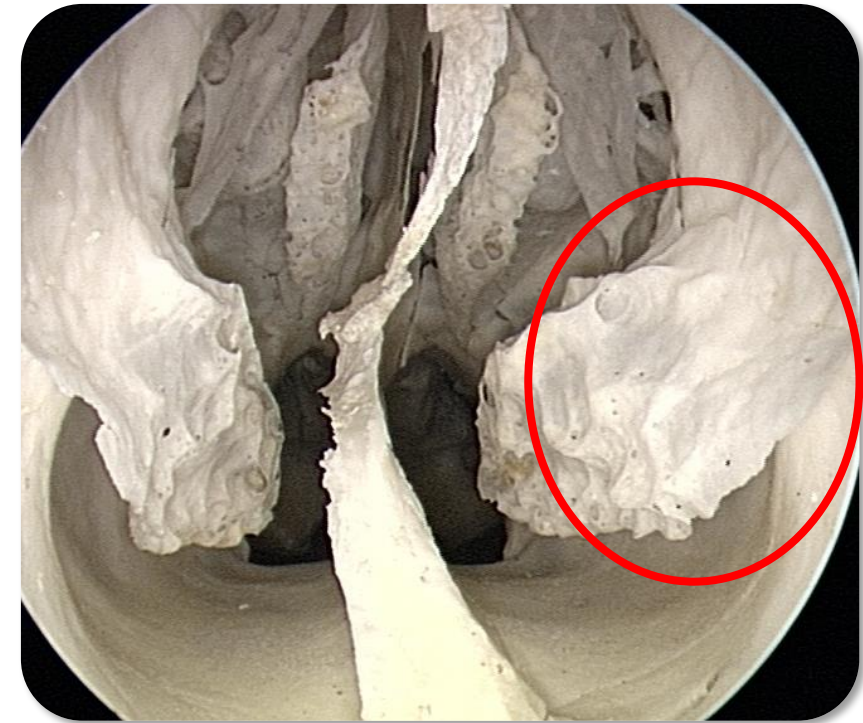


Turbinoplasty

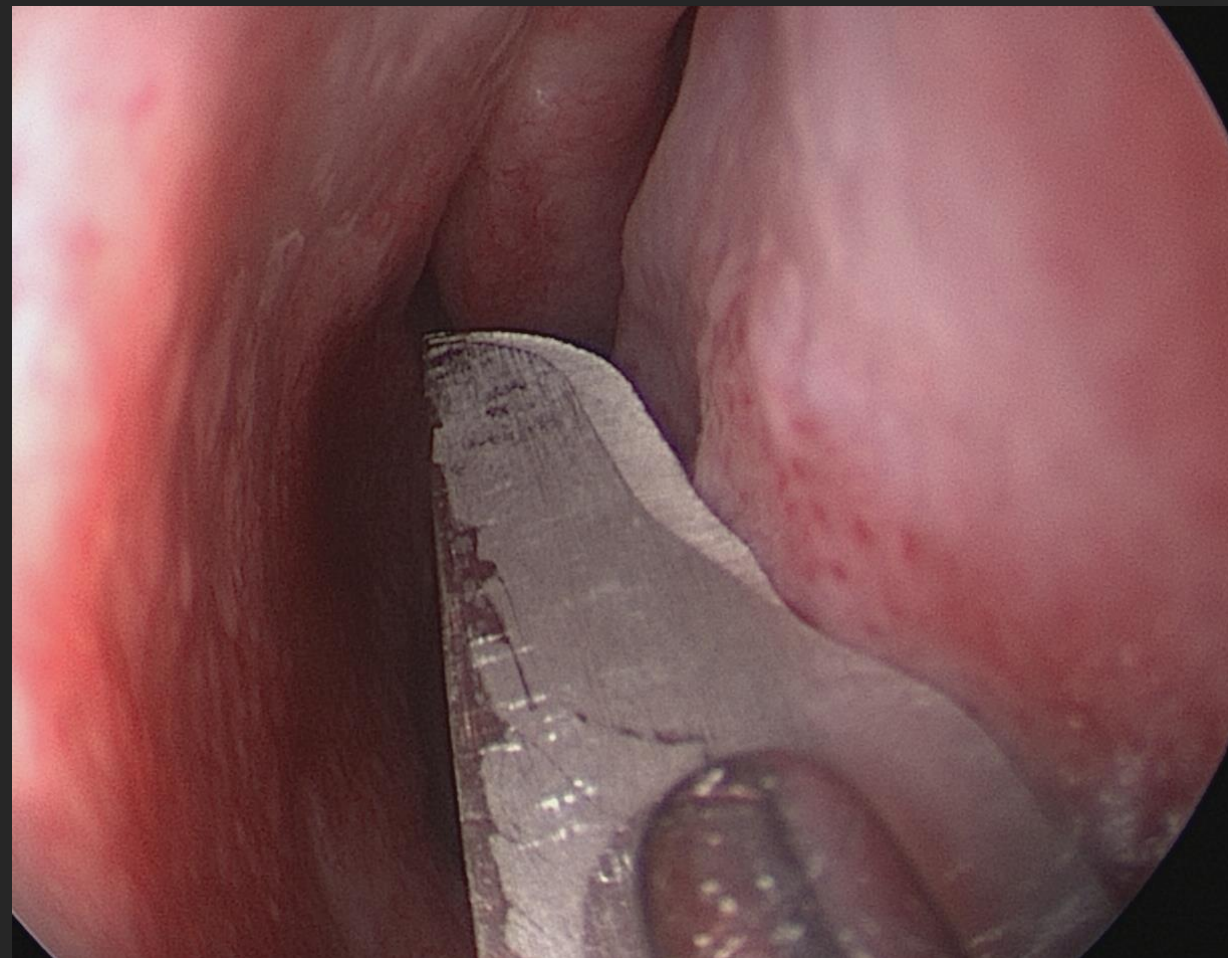
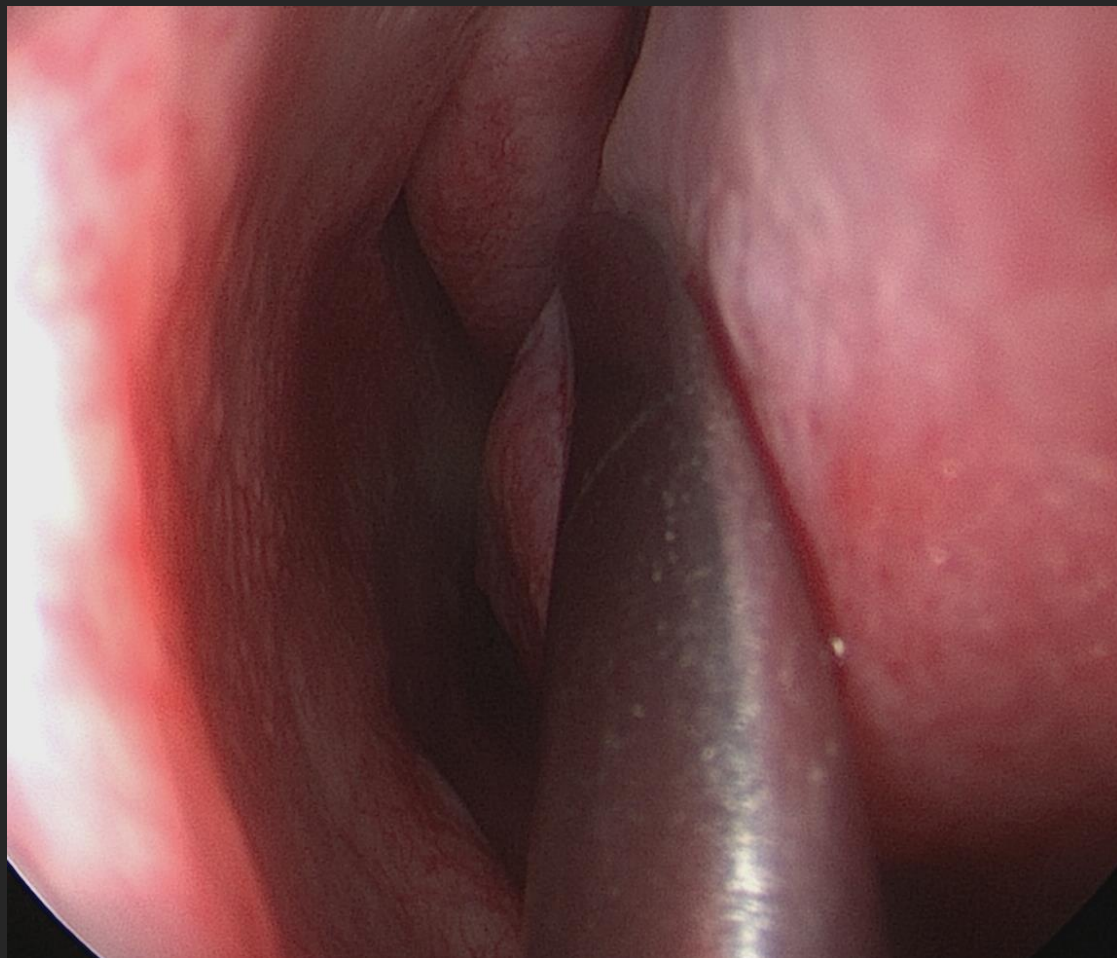
Technique

Pyriform turbinoplasty

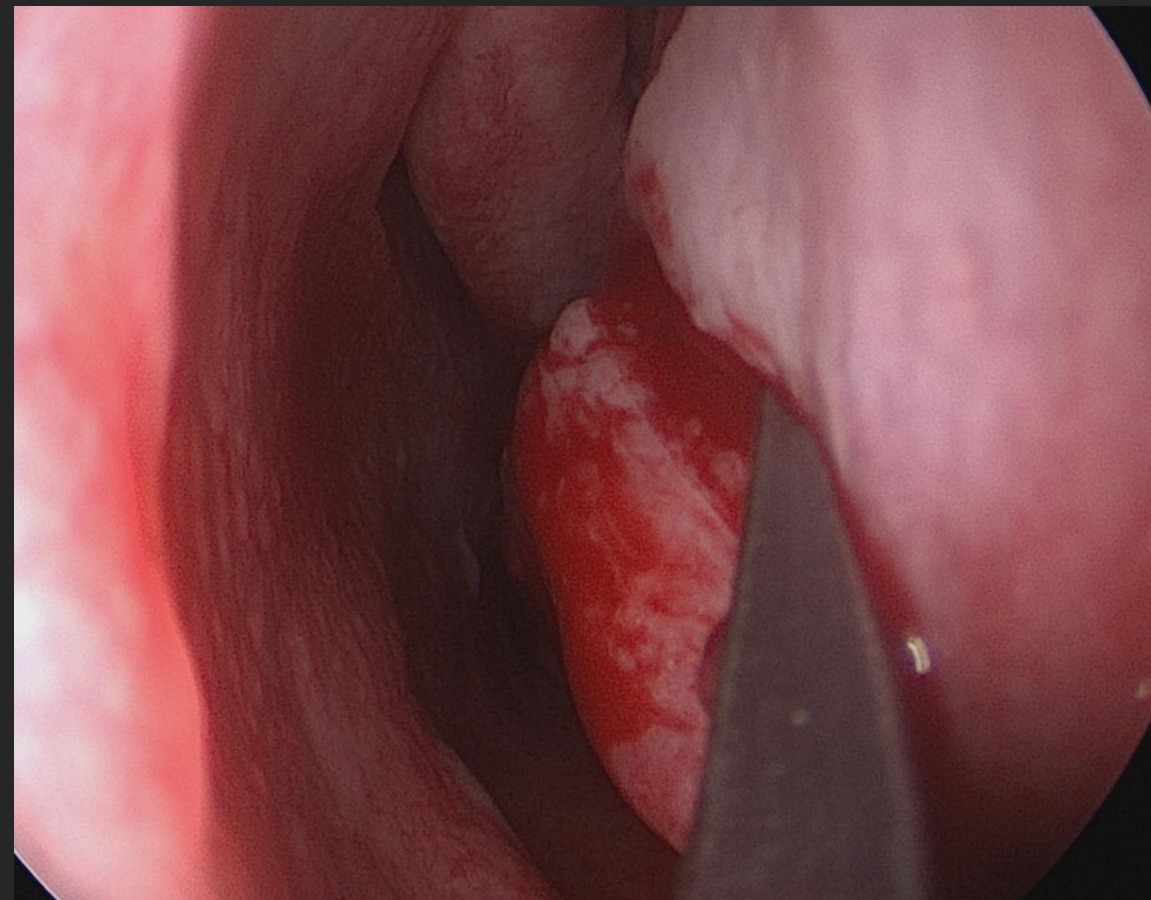
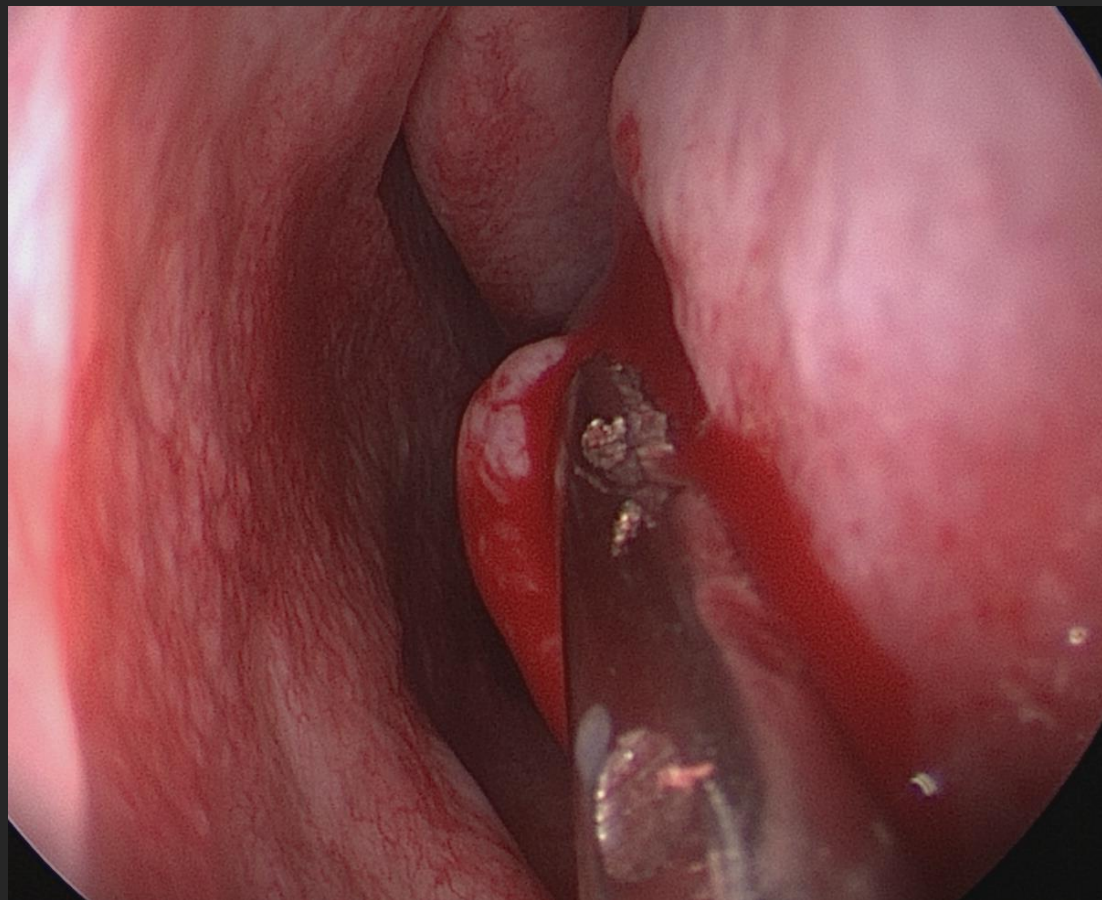
- Volume reduction of inferior turbinate:
 - Location:
 - anterior third
 - full length of the turbinate
 - Resection of
 - mucosa (submucous tissue)
 - bone
 - mucosa and bone



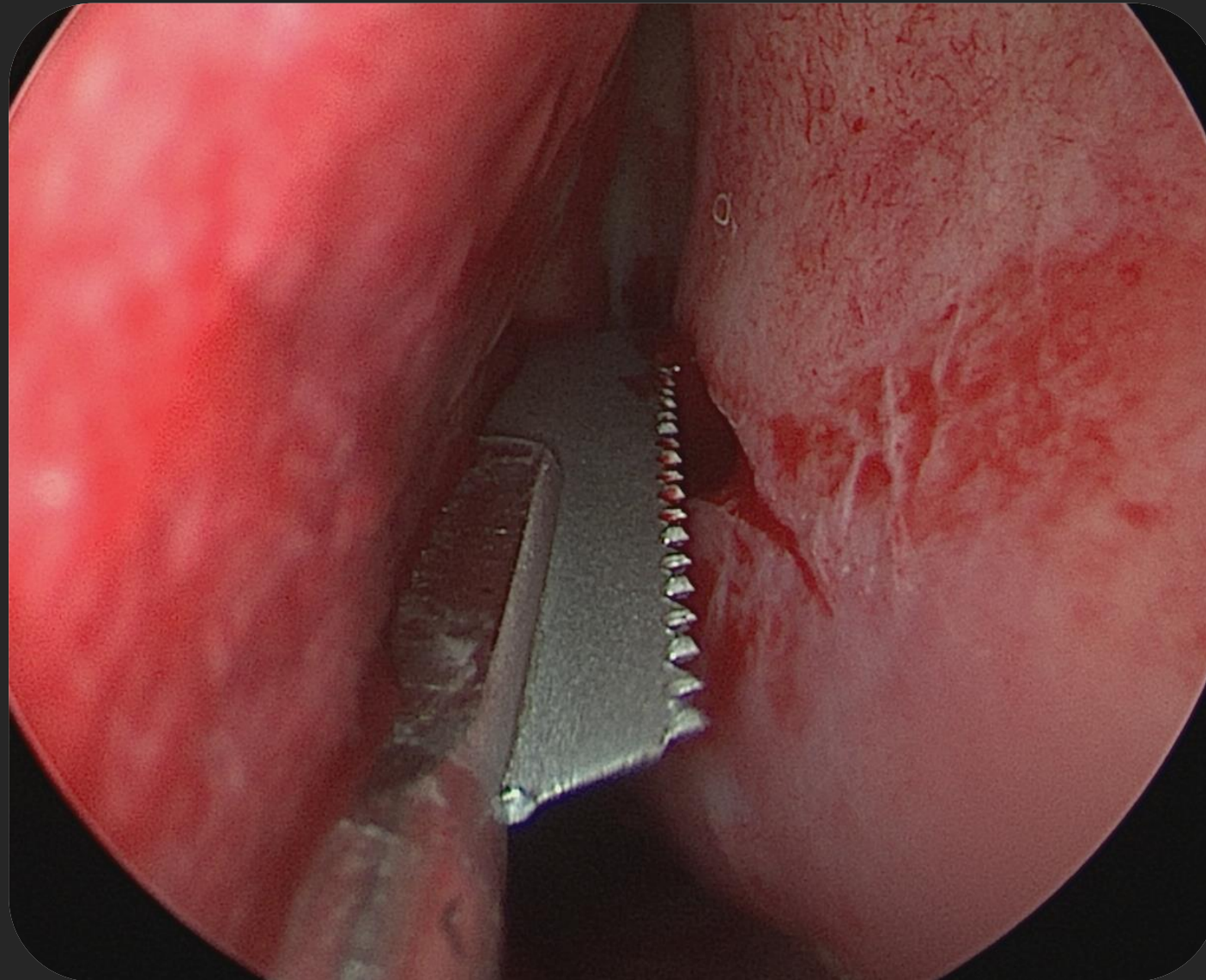
Pyriform turbinoplasty



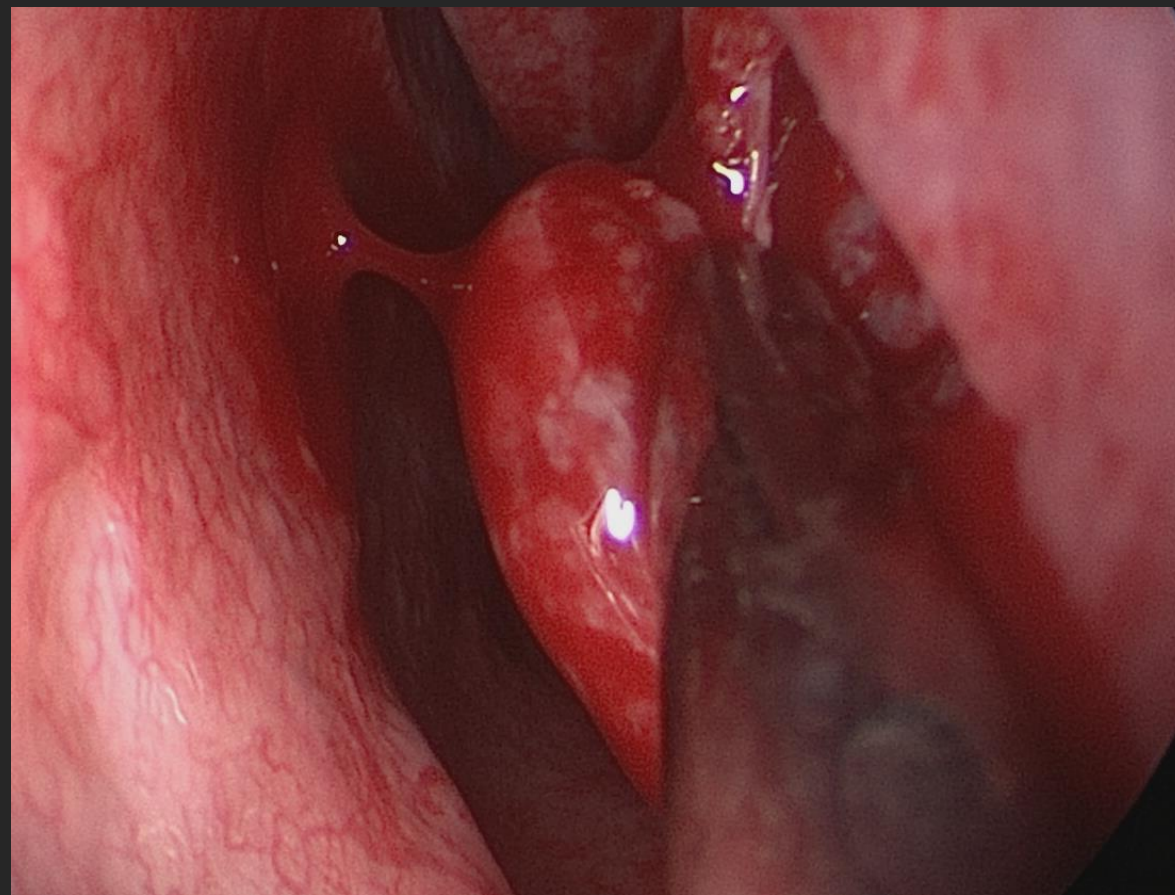
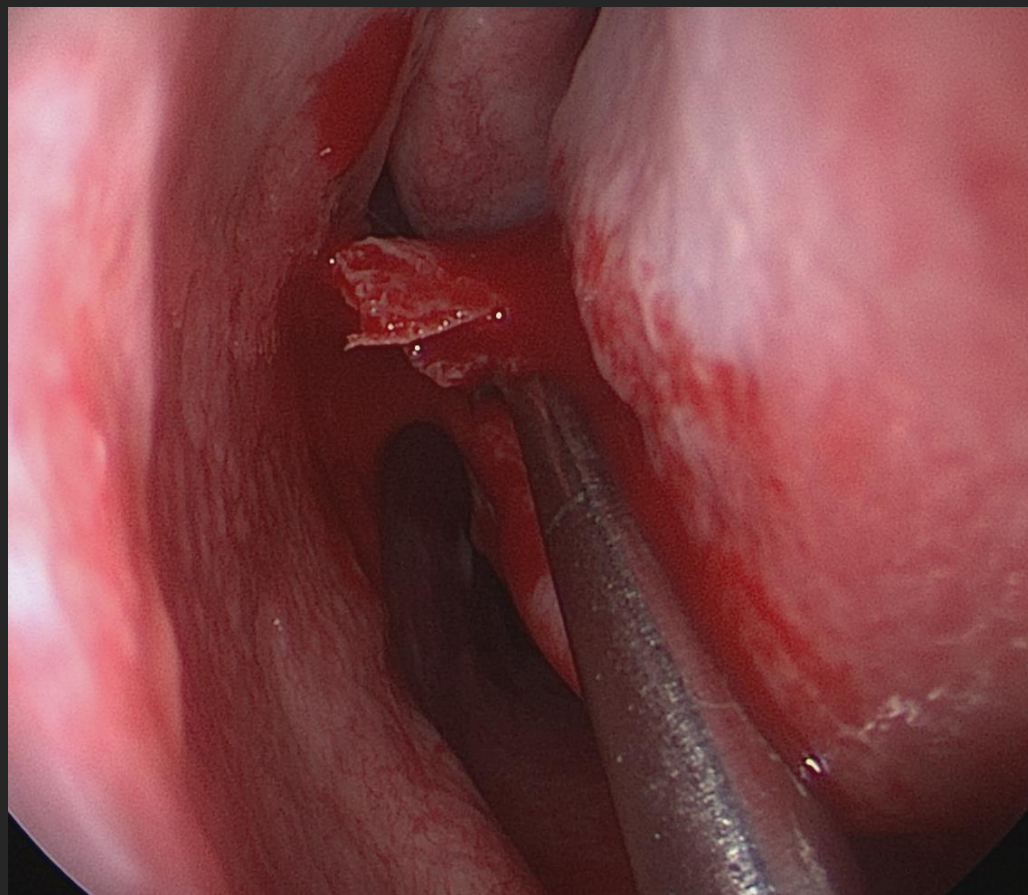
Pyriform turbinoplasty



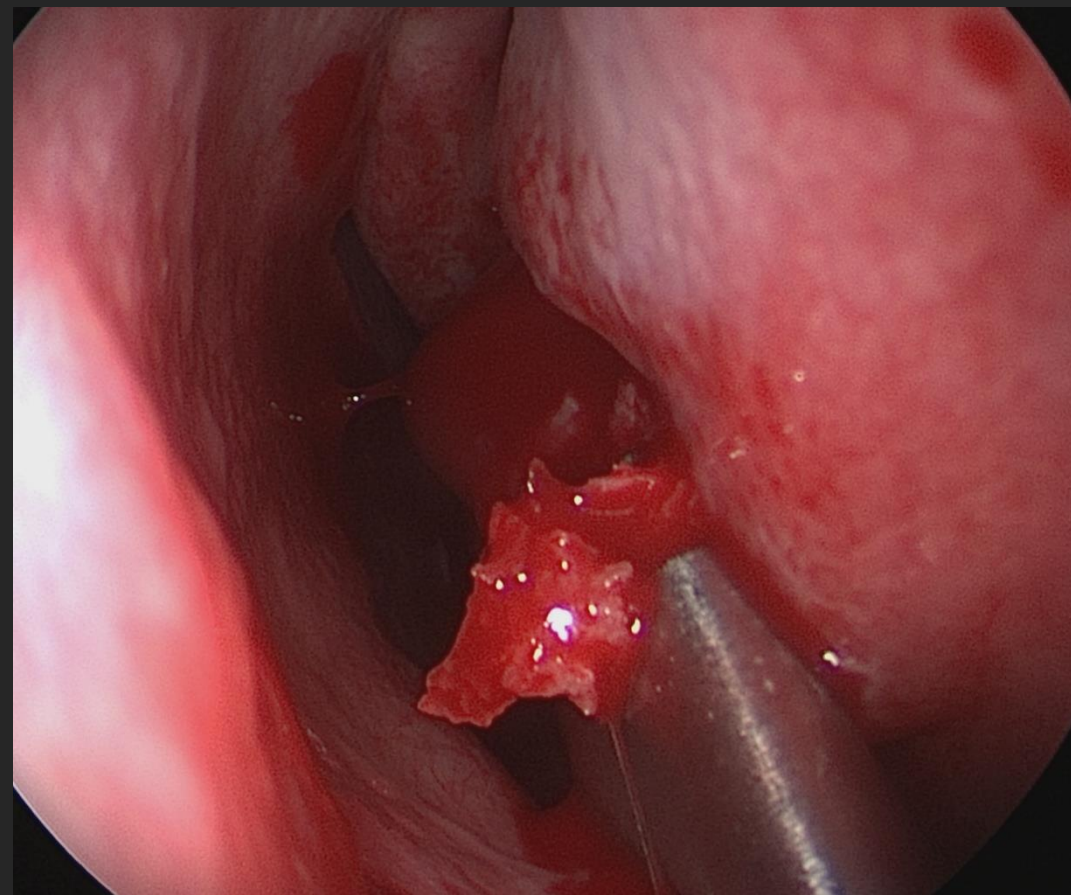
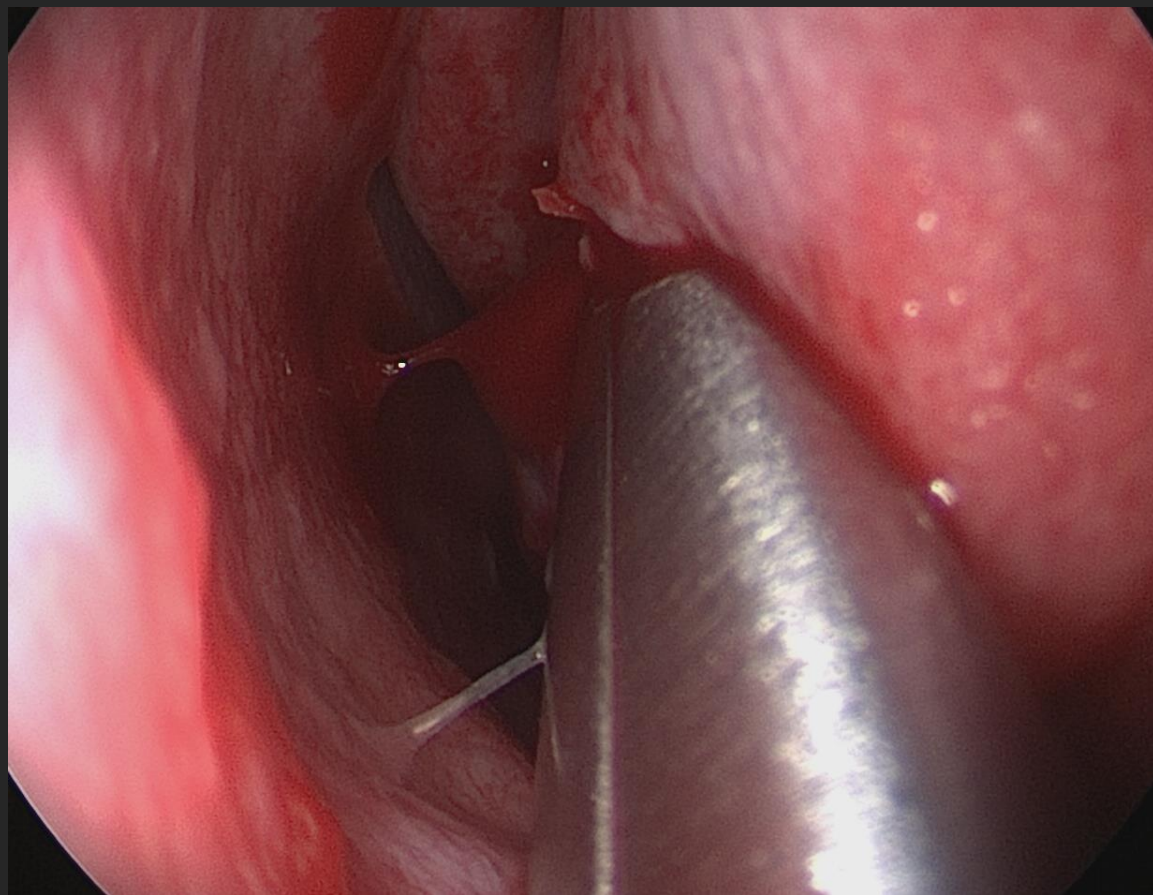
Pyriform turbinoplasty



Pyriform turbinoplasty

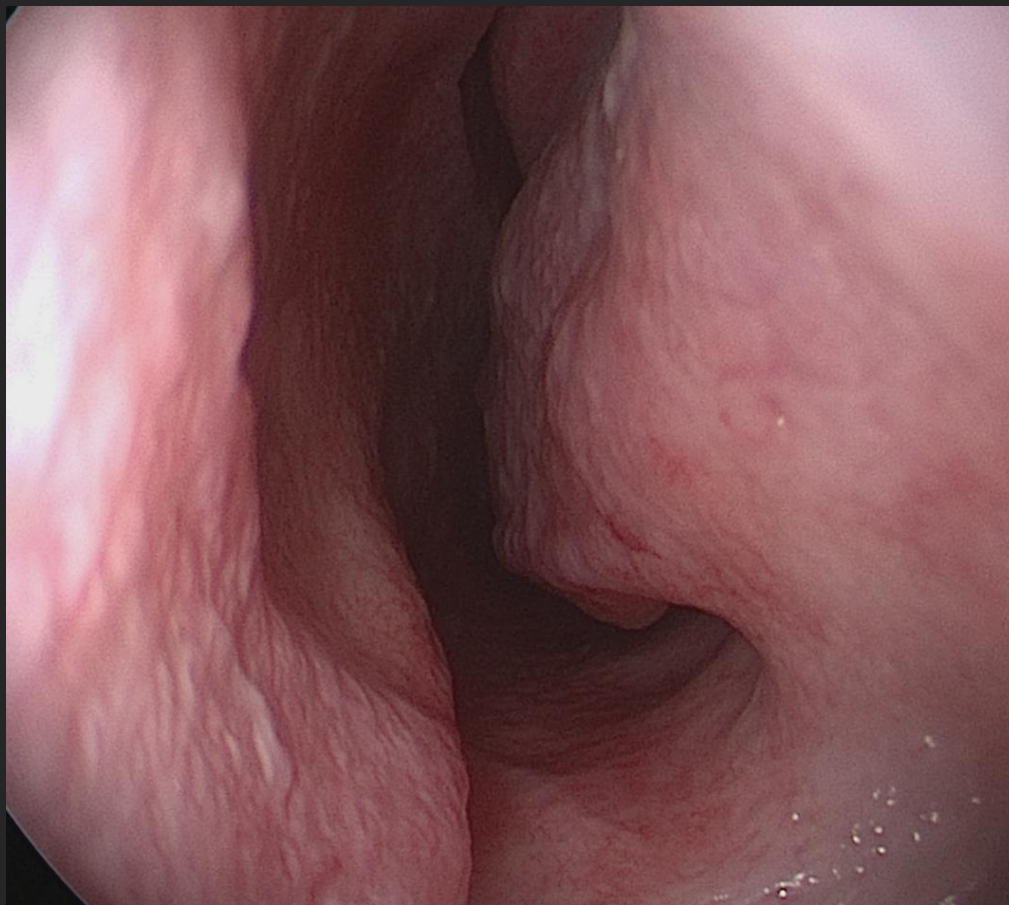


Pyriform turbinoplasty

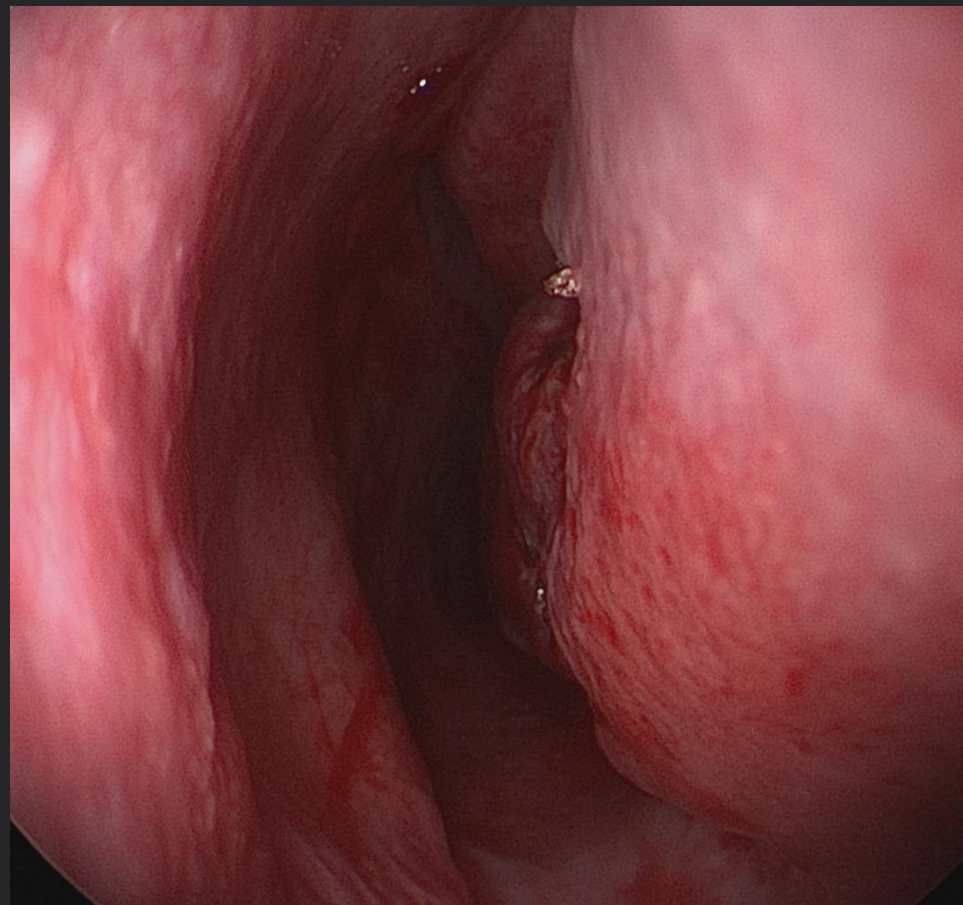


Pyriform turbinoplasty

before



after

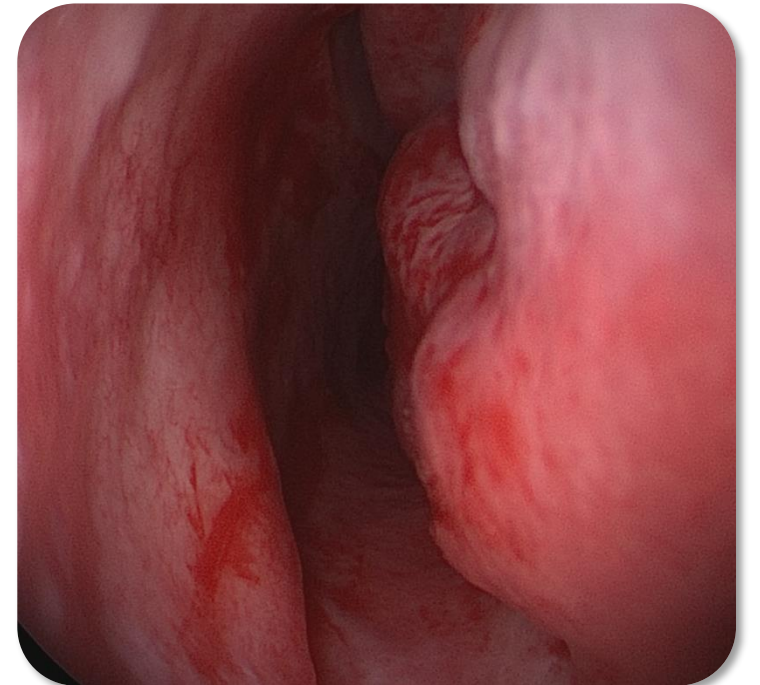


Turbinoplasty

Technique

Pyriform turbinoplasty

- Advantages
 - Preservation of mucosa, fast healing
 - Promotes permanent lateralisation of inferior turbinate
(«lateral nasal wall lateralisation»)
 - Enables a more physiological airflow compared to conventional conchotomy
 - Is part of the anterior approach to the natural maxillary sinus ostium

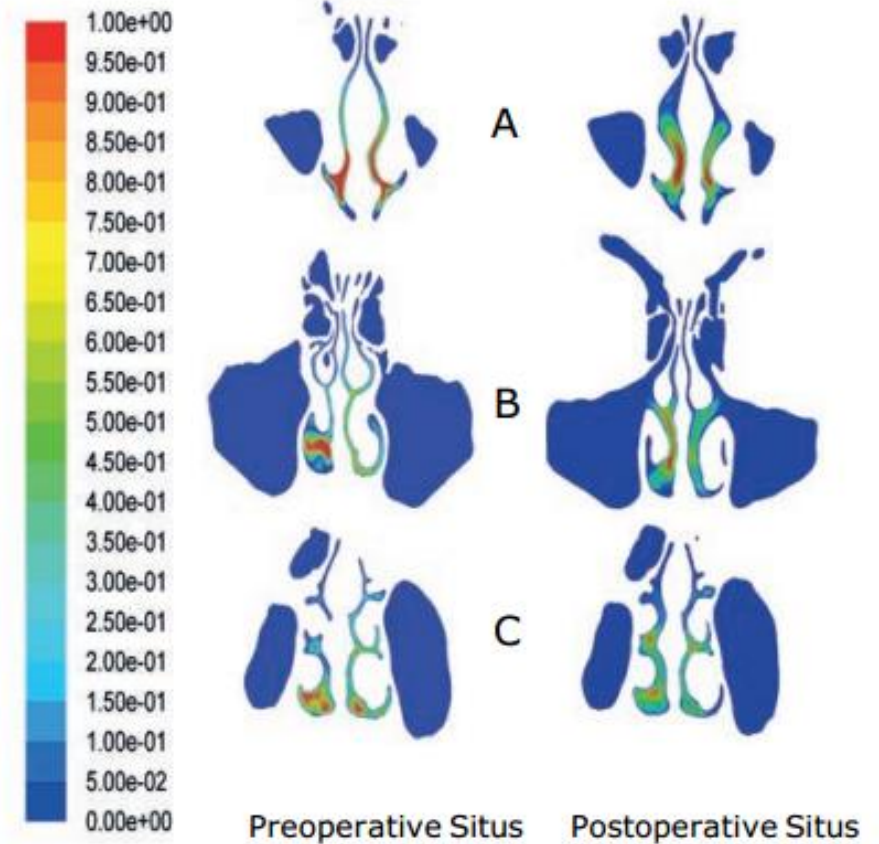


Turbinoplasty Technique

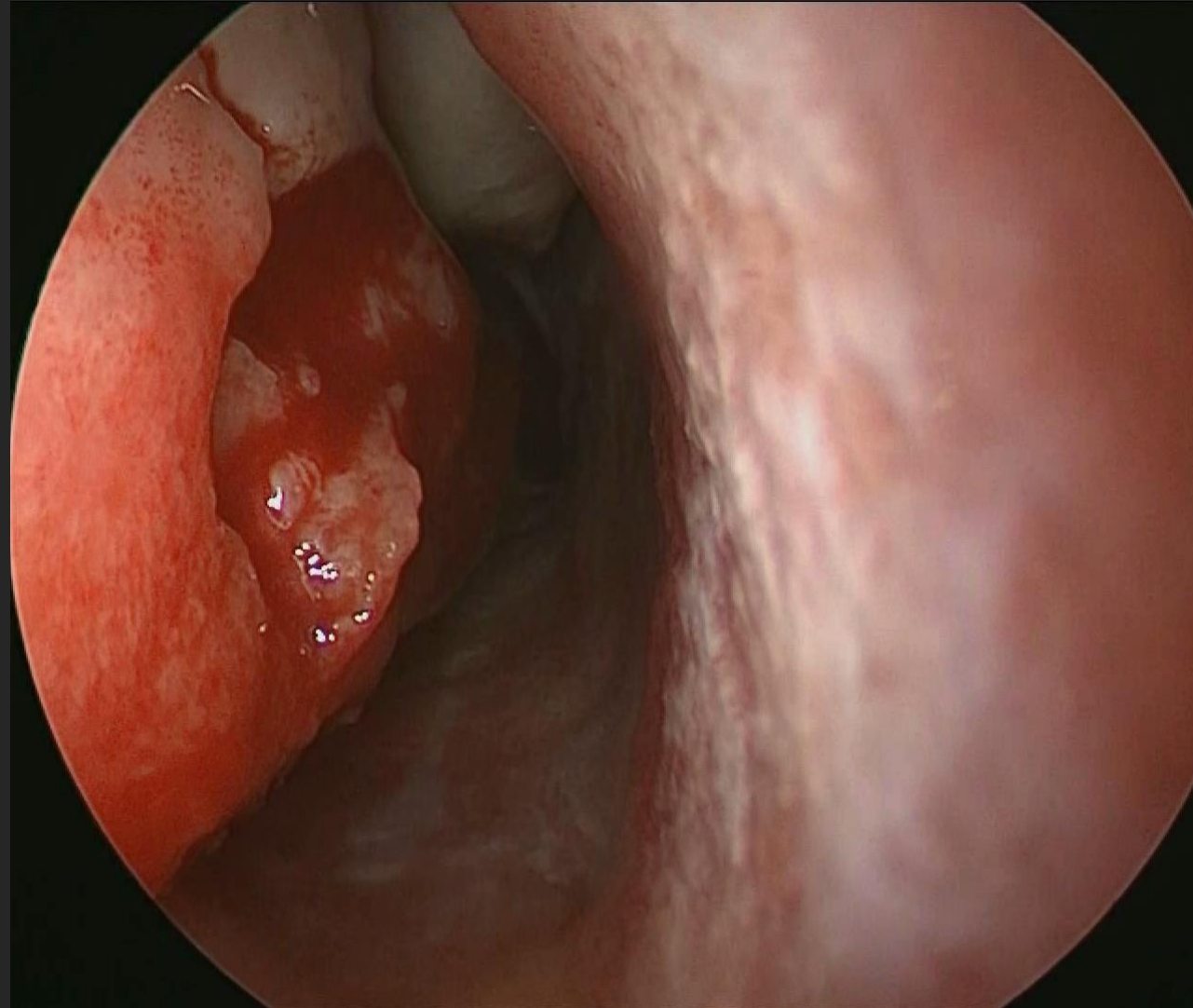
The effect of “Pyriform Turbinoplasty” on nasal airflow using a virtual model

*Daniel Simmen, Fabian Sommer, Hans Rudolf Briner, Nick Jones,
Ralf Kröger, Thomas Karl Hoffmann, Jörg Lindemann*

Rhinology 53: 242-248, 2015



Pyriform turbinoplasty

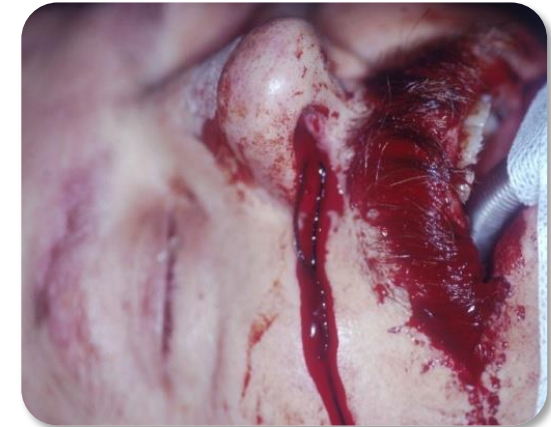

Turbinoplasty

Complications

Complications depending on technique

➤ Rate of complications	crusting	bleeding
➤ Cryotherapy	0%	3%
➤ Submucosal resection cold steel	12%	10%
➤ Electrocautery	23%	3%
➤ Partial turbinectomy	20%	8%
➤ Laser	2%	5%
➤ Total turbinectomy	21%	7%
➤ Radiofrequency ablation	2%	7%
➤ Submucosal resection microdebrider	?%	10%



*Sinno S et al. Inferior Turbinate Hypertrophy in Rhinoplasty: Systematic Review of Surgical Techniques. *Plast Reconstr. Surg.* 2016

Turbinoplasty

Complications

Technique - complications

Table 4. Complications* 0-25% 0-10%

Complication	Crusting	Bleeding	Atrophy	Rhinorrhea	Postnasal Drip	Infection	Synechiae
Total turbinectomy	21	7	n/a	1.3	19	n/a	6.25
Partial turbinectomy	20	8	n/a	11	7	6	3
SMR manual	12.3	10	n/a	n/a	2.9	4	n/a
SMR microdebrider	n/a	9.7	n/a	0	10	n/a	6.7
Electrocautery	23.3	3.3	n/a	n/a	33.9	4	n/a
Laser	1.5	5	n/a	n/a	11.4	n/a	4.4
Cryotherapy	0	2.6	0	n/a	13.8	0	n/a
Radiofrequency ablation	2.3	7.2	1.1	n/a	3.3	n/a	n/a
Turbinate outfracture	0	0	n/a	n/a	n/a	n/a	0

SMR, submucous resection; n/a, not available.

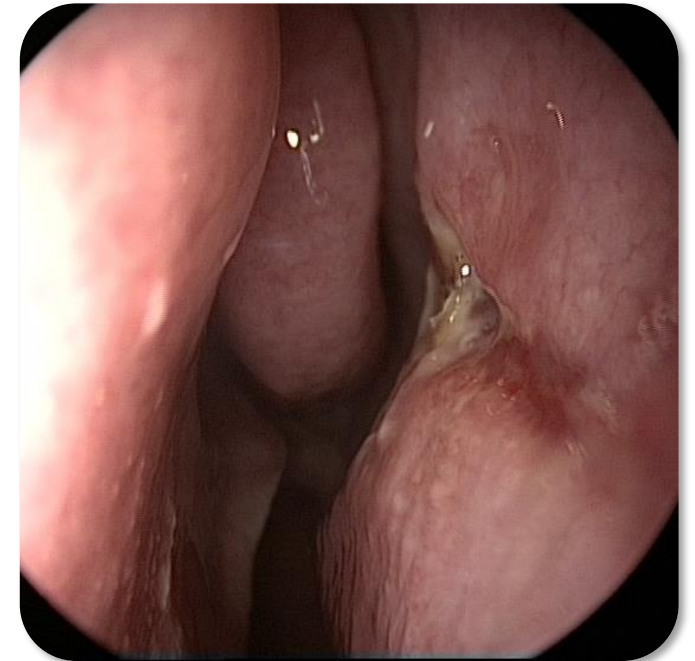*Sinno S et al. Inferior Turbinate Hypertrophy in Rhinoplasty: Systematic Review of Surgical Techniques. *Plast Reconstr. Surg.* 2016

Turbinoplasty

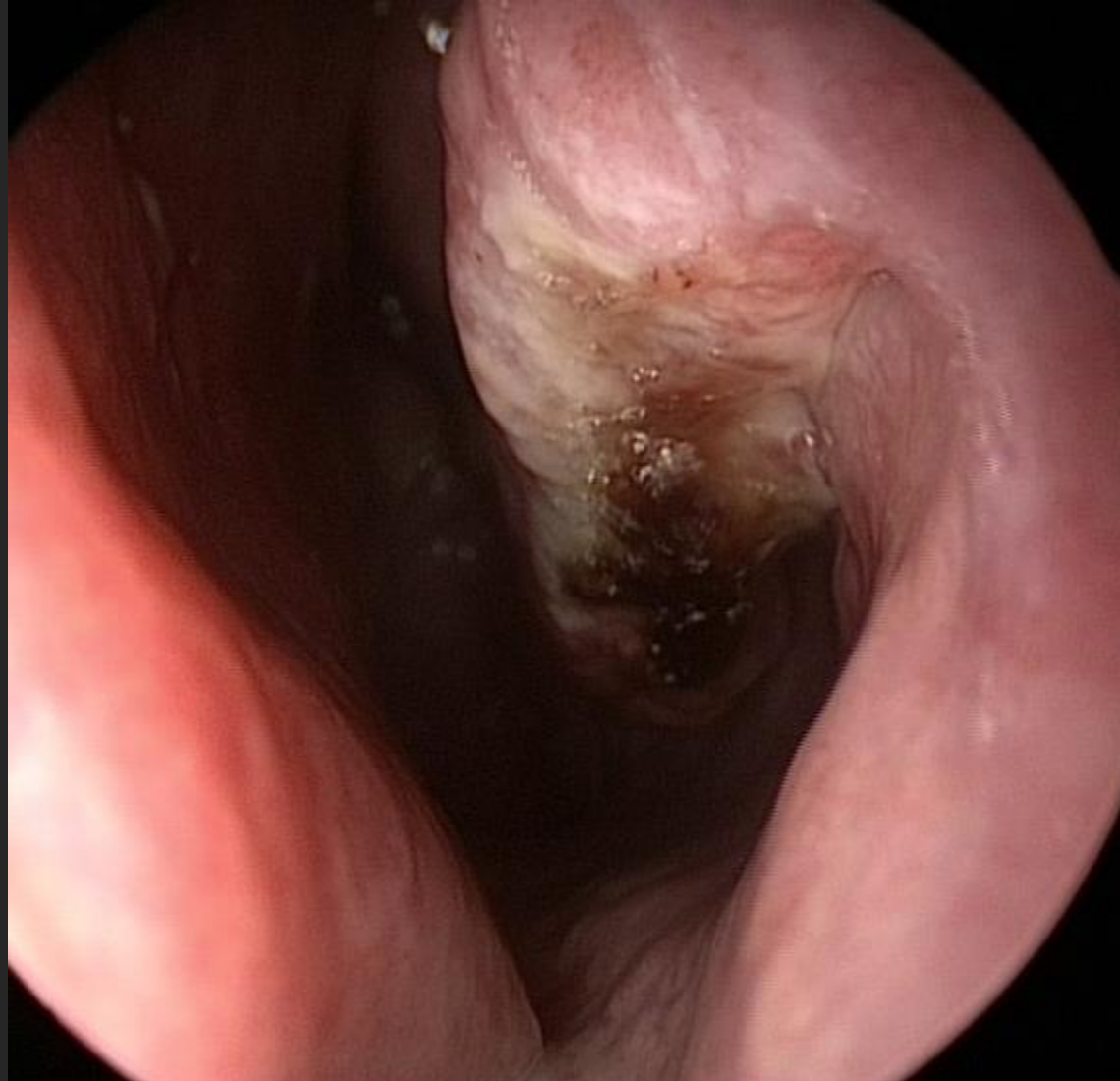Follow up

Postoperative Treatment

- Crusting
 - Treatment with nasal douching (*NaCl-Solution*) and ointment
 - Endoscopic cleaning *e.g. postop. day 7, 14*
- Bleeding
 - No excessive exercise for 7-14 days
- Pain
 - Pain medication rarely necessary

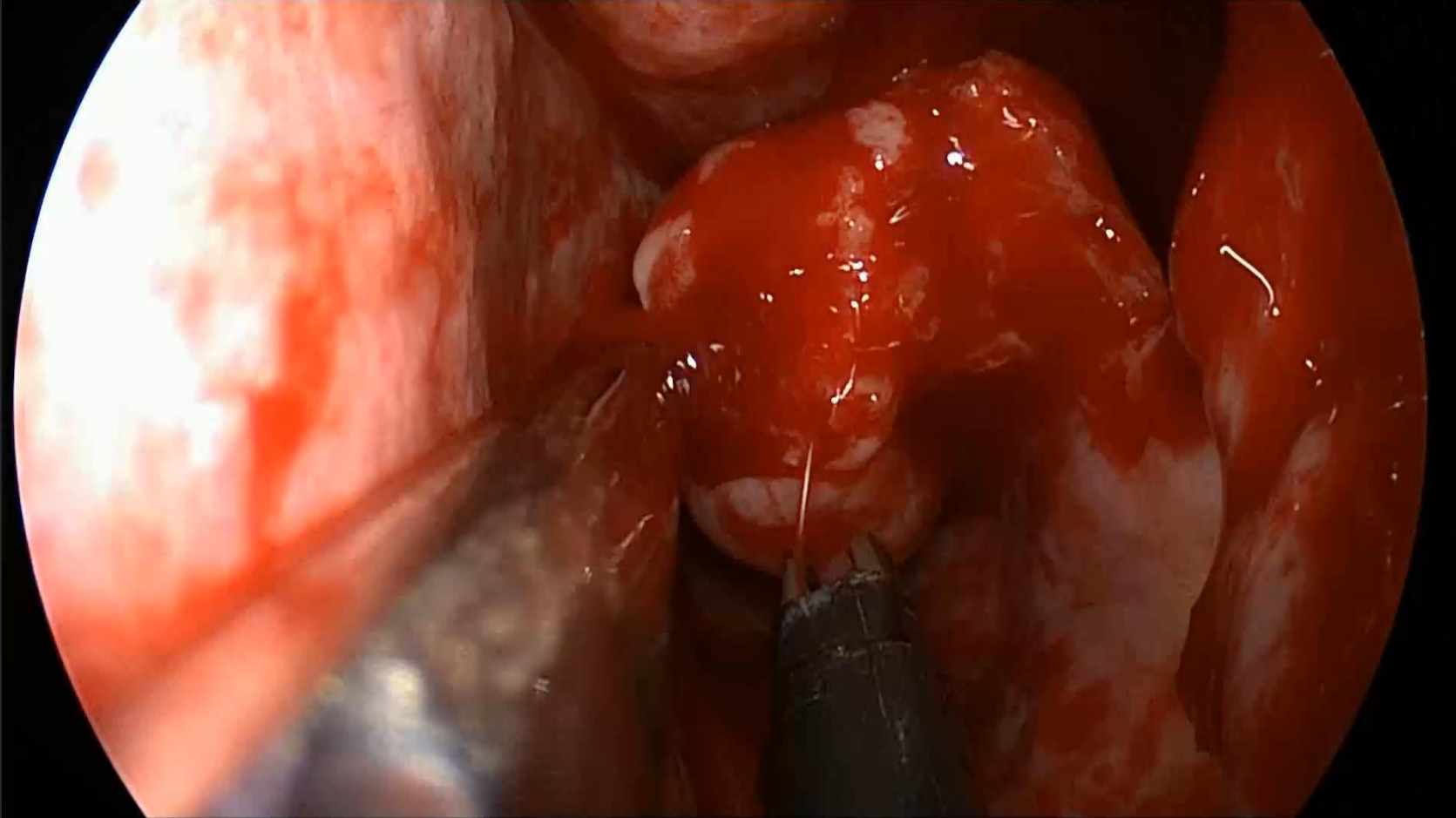


Postoperative crusting



Tips and Tricks

A. sphenopalatina – inferior conchal branch

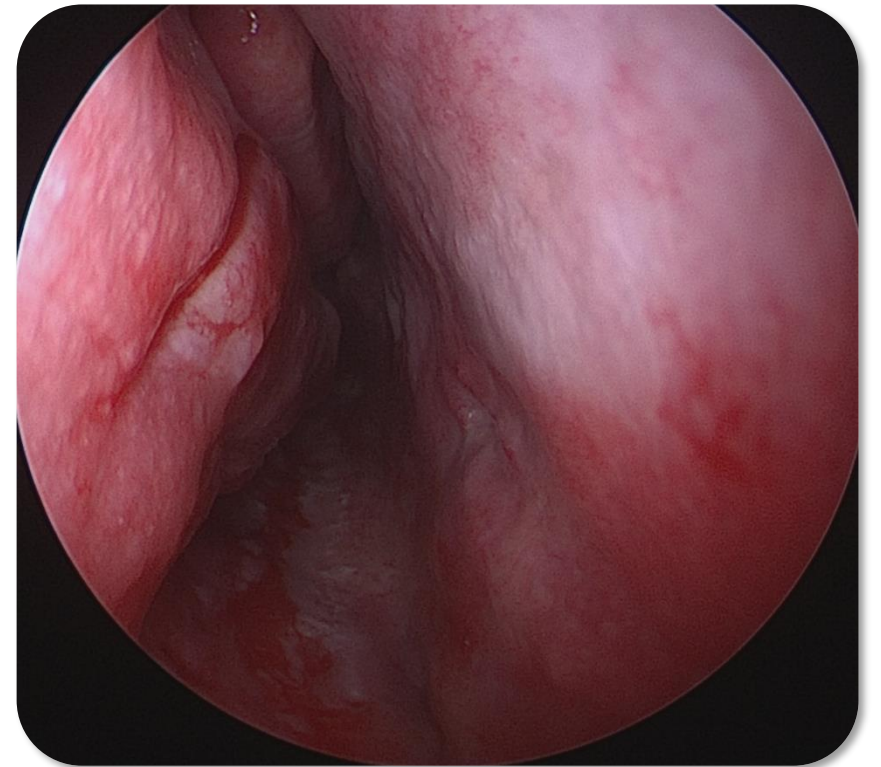


Turbinoplasty

Tips and Tricks

Cave

- Cave: «**ablative surgery**»
 - Does not normalize underlying mucosal disease
 - «Normal breathing» not guaranteed
 - Risk of inducing «Empty Nose Syndrome»




Turbinoplasty

Tips and Tricks

Cave

- Empty nose syndrome:
 - Rare
 - Correlates with amount of tissue resection*
 - Occurs with all types of turbinate surgery
 - **Correlation with psychiatric comorbidities****



Beat Rosenberg – Abstract portrait

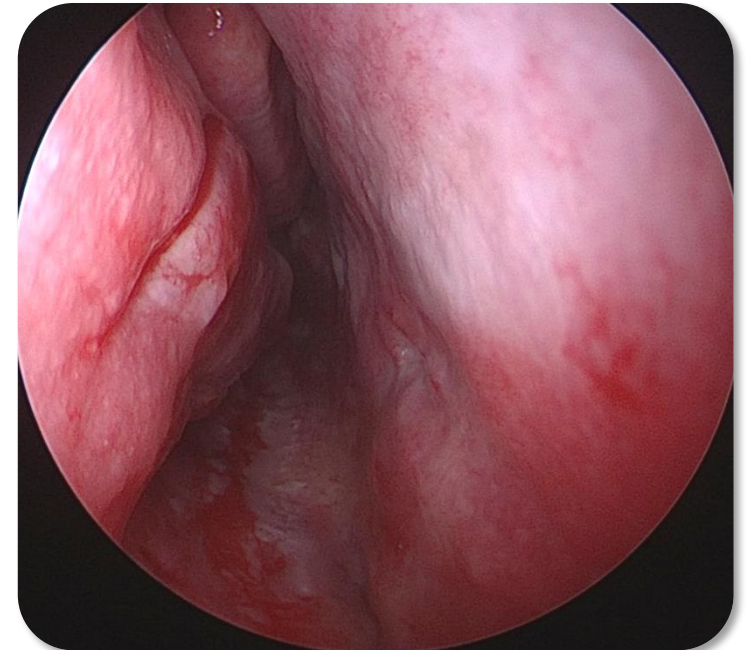
*Hong HR et al. Correlation between remnant inferior turbinate volume and symptom severity of empty nose syndrome. *Laryngoscope* 2016

** Lee TJ et al. Evaluation of depression and anxiety in empty nose syndrome after surgical treatment. *Laryngoscope* 2016

Turbinoplasty

Take home

- Indications: **Impaired nasal breathing**, not sufficiently responding to medical treatment
- Multiple technical methods available
- Does not correct underlying mucosal disease
- Does not guarantee «normal nasal breathing»
- Risiko of «Empty Nose Syndrome»
- **Conservative, mucosal sparing volume reduction**



Septoplasty and Turbinoplasty

Indications - Technique - Follow up - Pitfalls

H.R. Briner

ORL-Zentrum

Klinik Hirslanden

Zürich

