

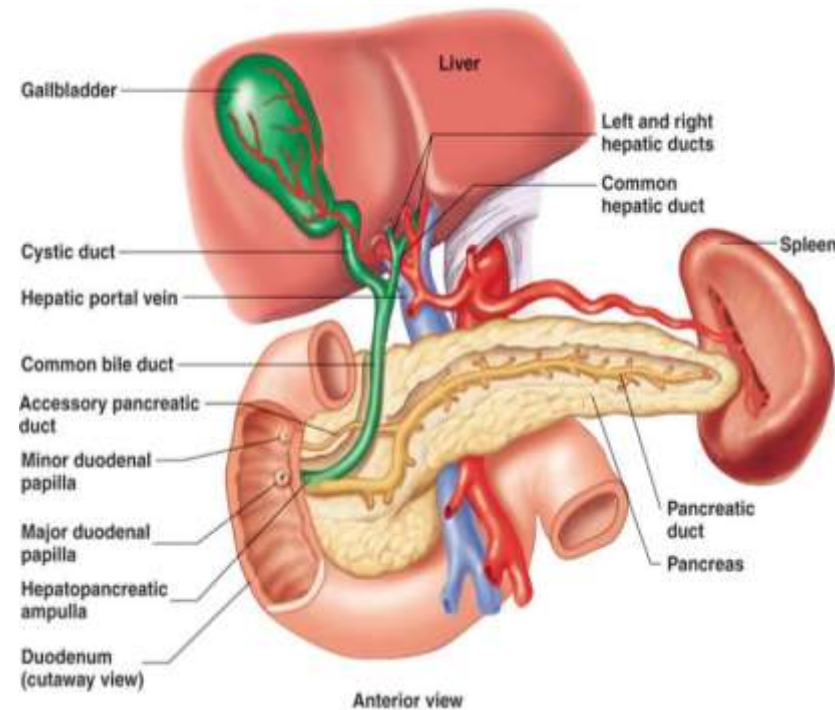
# Signs and Symptoms of Hepatobiliary Tract and Exocrine Pancreas Disorders

LECTURE IN INTERNAL MEDICINE PROPAEDEUTICS

M. Yabluchansky, L. Bogun, L.Martymianova, O. Bychkova, N. Lysenko, N. Makienko  
V.N. Karazin National University Medical School' Internal Medicine Dept.

# Plan of the lecture

- Definition of Hepatobiliary Tract and Exocrine Pancreas
- Spectrum of Hepatobiliary Tract and Pancreas Disorders
- Hepatobiliary Tract
  - Reminder (how does Hepatobiliary Tract work)
  - History-taking
  - Patient's examination (clinical, instrumental, laboratory)
  - syndromes
- Exocrine pancreas
  - Reminder (how does exocrine pancreas work)
  - History-taking
  - Patient's examination (clinical, laboratory, instrumental)
  - syndromes
- Glossary of terms referred to endocrine diseases and metabolic disorders



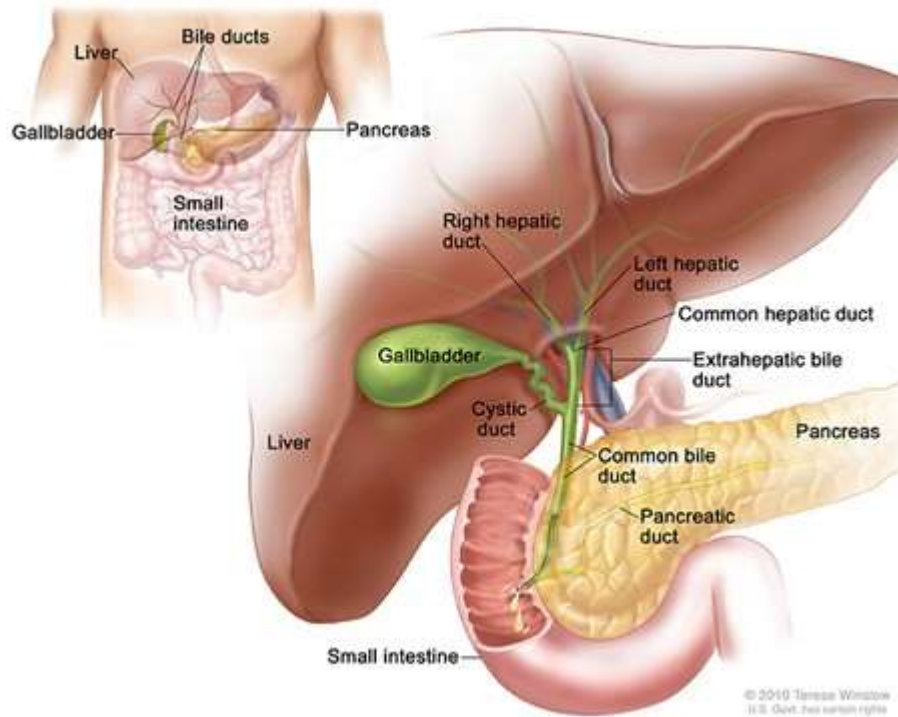
# Definition of Hepatobiliary Tract and Exocrine Pancreas

- The hepatobiliary tract and exocrine pancreas is essential for digestion and includes: the liver, the pancreas, bile ducts and the gallbladder
  - The liver is one of the largest organs in the human body and has many functions including: processing food and changing it into energy; breaking down toxic substances in the body and their excretion; storing iron reserves, as well as vitamins and minerals; creating bile, which aids in digestion, glucose homeostasis, plasma protein synthesis, lipid and lipoprotein synthesis
  - The pancreas is an organ behind the stomach and in front of the spine, the primary exocrine function of the pancreas is to produce fluids to help break down food
  - After being produced by the liver, bile is secreted into the bile ducts and stored in the gallbladder; bile aids in the digestion of fats

# Spectrum of Hepatobiliary Tract and Pancreas Disorders

- Liver
  - Liver Tumors  
(hepatocellular carcinoma, metastatic colorectal cancer, neuroendocrine cancer, other metastatic tumor)
  - Benign Liver Lesions  
(hepatic cyst, hemangioma, adenoma, focal nodular hyperplasia)
  - Hepatitis
  - Fatty liver
  - Liver Cirrhosis
- Pancreas
  - Pancreatic Cancer
  - Acute and Chronic Pancreatitis
  - Pseudocyst
  - Cystic Neoplasms
- Bile Ducts and Gallbladder
  - Gallstones
  - Stricture
  - Leaks (of bile, caused from trauma and surgery)
  - Gallbladder Cancer
  - Bile Duct Cancer  
(cholangiocarcinoma)
  - Cholangitis
  - Cholecystitis

# Hepatobiliary Tract: Reminder

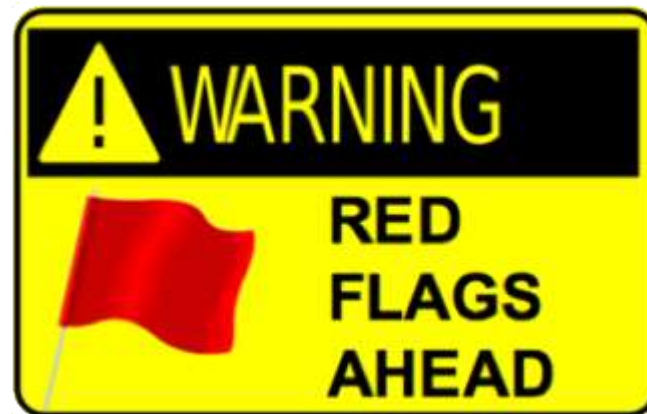

[How does Hepatobiliary Tract work](#)

# Hepatobiliary Tract: History-taking

Chief complaints' /signs “red flags”

- Pain
- Weight lost
- Fever
- Jaundice
- Acute diarrhea
- Persistent constipation
- Coagulopathy
- Bleeding
- Vomiting blood
- Hepatic encephalopathy
- Severe tenderness of the belly



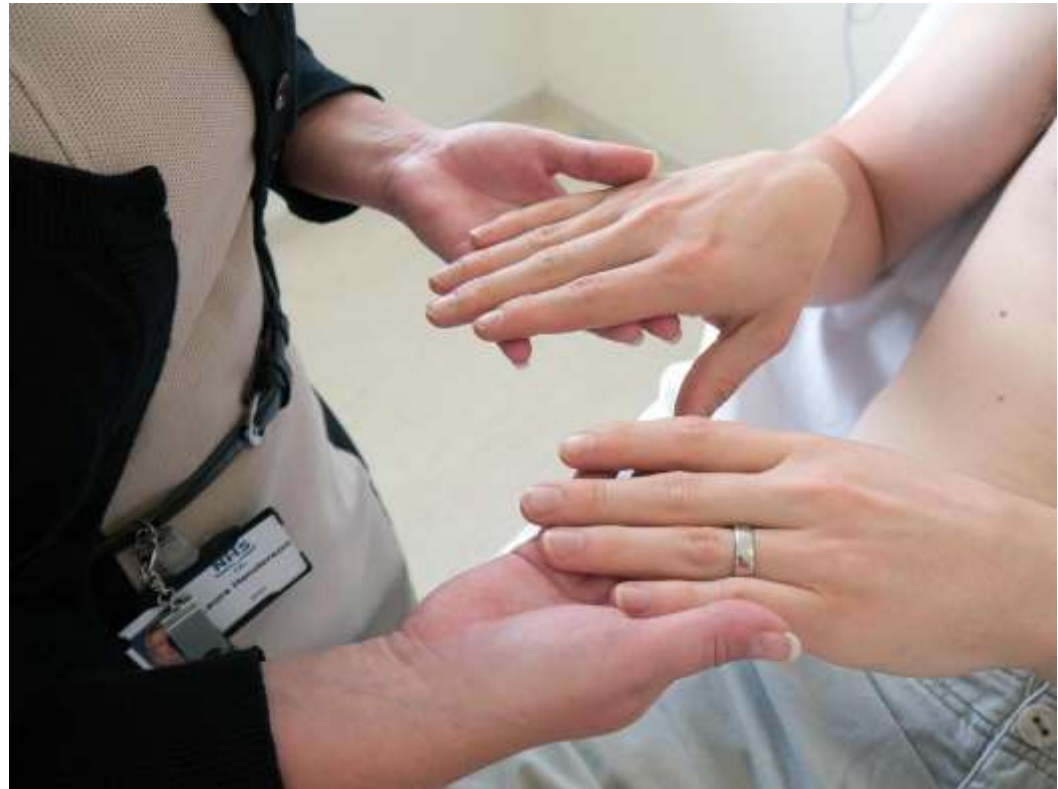# Hepatobiliary Tract: History-taking

## Example of specific questions in chief complaint

- Character
- Location
- Severity
- Timing
- Duration
- Radiation
- Provocation
- Relieving conditions
- When did it first start?
- How often does it occur?
- Is appetite good or has it changed?
- What brought it on?
- Were there associated symptoms
- Is it becoming more frequent with time?
- Are the symptoms lasting longer?
- How the symptoms relate to food intake?

# Hepatobiliary Tract: Clinical examination of the patient

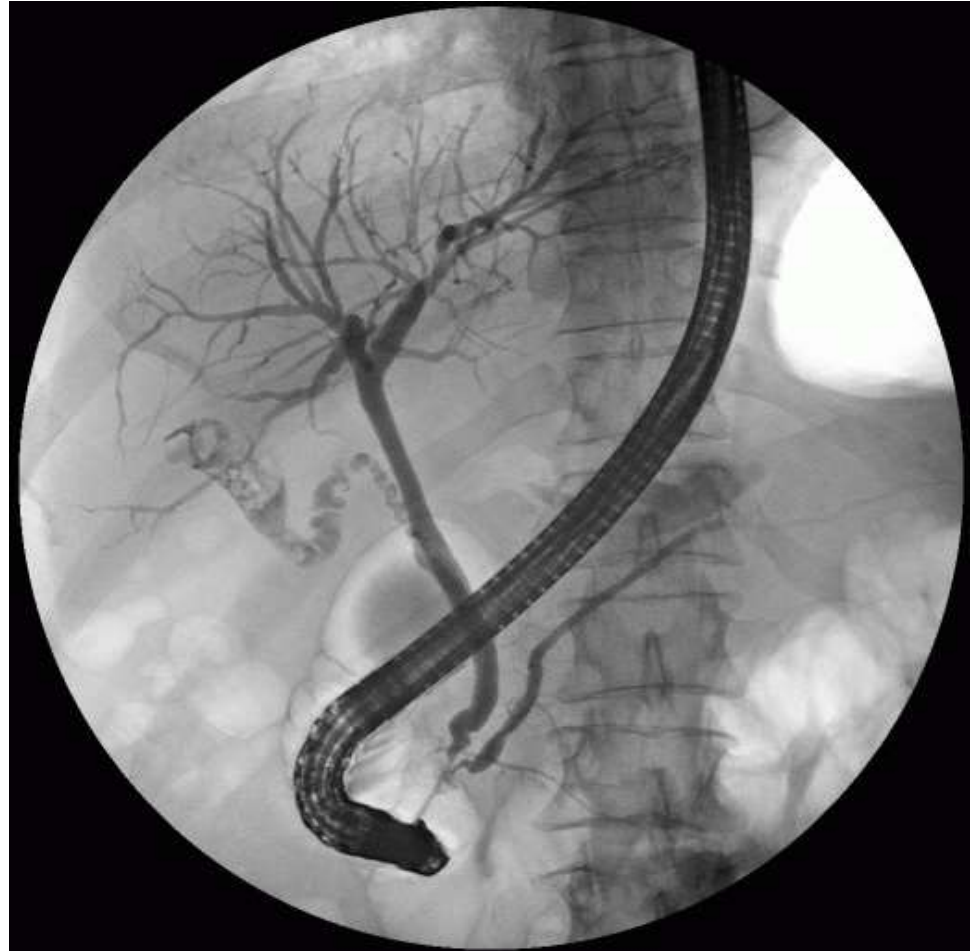- General inspection from the end of the bed
- General examination of:
  - Hands/pulse
  - Face
  - Lymph nodes
- Examination of the abdomen
  - Inspection
  - Palpation
  - Percussion
  - Auscultation





# Hepatobiliary Tract: Instrumental examination of the patient

- Flat-plate film of the abdomen
- Computed tomography
- Magnetic resonance imaging
- Abdominal ultrasonography
- Color Doppler
- Endoscopic ultrasonography
- Endoscopic retrograde cholangiopancreatography (ERCP)
- Biopsy



# Hepatobiliary Tract: Laboratory examination of the patient

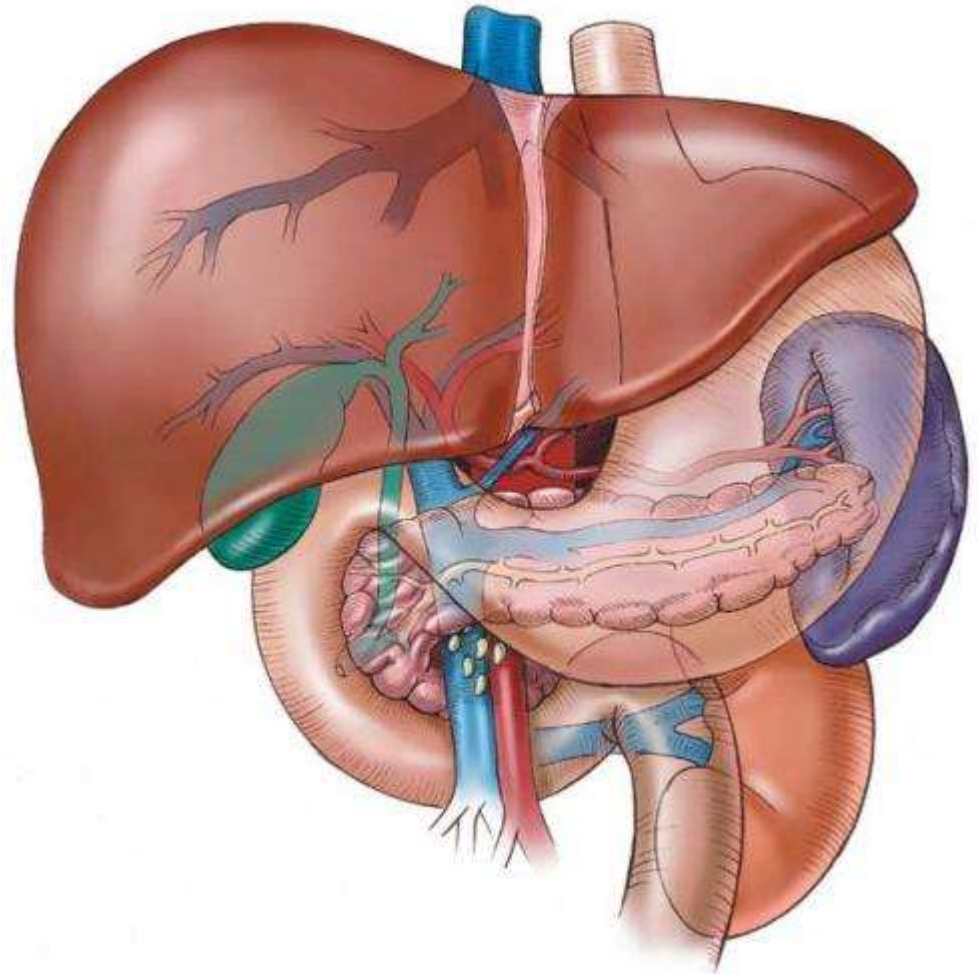
- Blood count
- Blood sugar tests
- Blood Coagulation
- Electrolytes
- Bilirubin blood test
- Plasma proteins
- Blood ammonia
- Alkaline phosphatase
- Gamma glutamyl transferase
- Enzyme & protein blood tests
- Lipid blood tests
- C-reactive protein
- Fecal occult blood test
- Serology (viral hepatitis)



Photo courtesy of Cepheid

# Hepatobiliary Tract: syndromes

- Gallbladder motility disorder
- Jaundice
- The syndromes of liver size changes
- Portal hypertension
- Hepatocellular Dysfunction
- Cholestatic syndrome



# Gallbladder motility disorder: Definition

- Gallbladder motility disorder is defined as biliary pain in the absence of gallstones, sludge, microlithiasis, or microcrystal disease
- The diagnosis is considered in patients with typical biliary-type pain who have had other causes for the pain excluded
- The prevalence of functional gallbladder disorder among patients with biliary-type pain and a normal transabdominal gallbladder ultrasound is up to 8 percent in men and 21 percent in women

# Gallbladder motility disorder: Cause and mechanisms

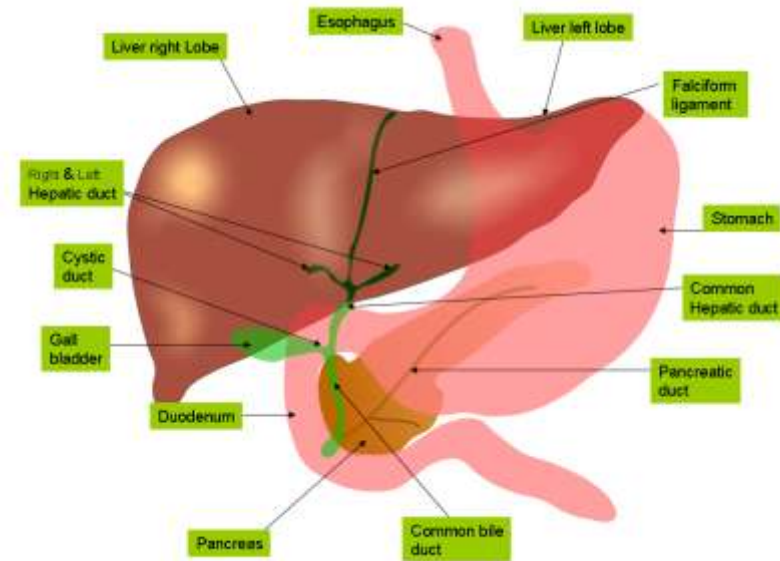
- The cause is unclear, but it is generally regarded as a motility disorder of the gallbladder
- It may result from an initial metabolic disorder (i.e., bile supersaturated with cholesterol) or a primary motility disorder in the absence, at least initially, of any abnormalities of bile composition
- It has been noted that patients with functional gallbladder disorder may have abnormal gastric emptying and colonic transit, suggesting a possible generalized gastrointestinal motility disorder
- The hypothesis that disorder is related to abnormal gallbladder motility is the basis for measuring the gallbladder ejection fraction as part of the evaluation

# Gallbladder motility disorder: Clinical signs

- Patients present with biliary-type pain, also known as biliary colic
- The liver and pancreas blood tests are normal, no gallstones or gallbladder sludge are seen on imaging, and upper endoscopic examinations are normal
- Despite the name, biliary colic is usually constant and not colicky
- The classic description is of an intense discomfort located in the right upper quadrant or epigastrium that may radiate to the back (particularly the right shoulder blade)
- The pain is often associated with diaphoresis, nausea, and vomiting
- The pain plateaus in less than an hour, ranging from moderate to excruciating in severity
- Once it has plateaued, the pain typically lasts at least 30 minutes and then slowly subsides over several hours, with the entire attack usually lasting less than six hours
- While the pain often develops one to two hours after ingestion of a fatty meal, an association with meals is not universal, and in a significant proportion of patients the pain is nocturnal, with a peak occurrence around midnight
- While nonspecific dyspeptic symptoms, such as indigestion, abdominal bloating, and belching, may coexist in patients with biliary colic, they are not usually relieved by cholecystectomy

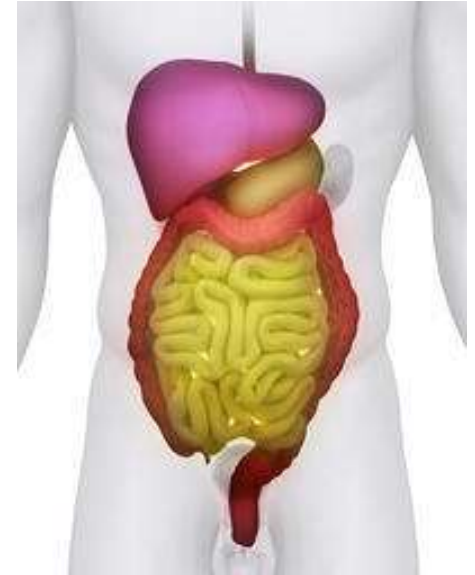
# Gallbladder motility disorder: Laboratory, imaging, and endoscopic studies

- ❖ Patients with functional gallbladder disorder have normal blood tests, including aminotransferases, bilirubin, alkaline phosphatase/gamma-glutamyltranspeptidase, amylase, and lipase
- In addition, abdominal imaging is normal, with no evidence of gallstones, gallbladder sludge, or cholesterol polyps
- Finally, patients have normal upper endoscopic examinations



# Gallbladder motility disorder: The Rome III criteria for biliary-type pain

- Pain is located in the epigastrium and/or right upper quadrant
- Pain is recurrent, but occurs at variable intervals (not daily)
- Pain lasts at least 30 minutes
- Pain builds up to a steady level
- Pain is severe enough to interrupt daily activities or lead to an emergency department visit
- Pain is not relieved by bowel movements, postural changes, or antacids

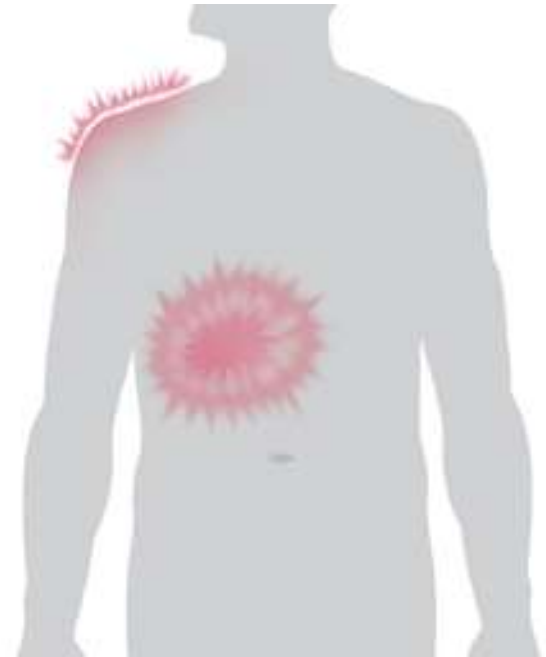




# Gallbladder motility disorder: The Rome III criteria for biliary-type pain

## Supportive criteria

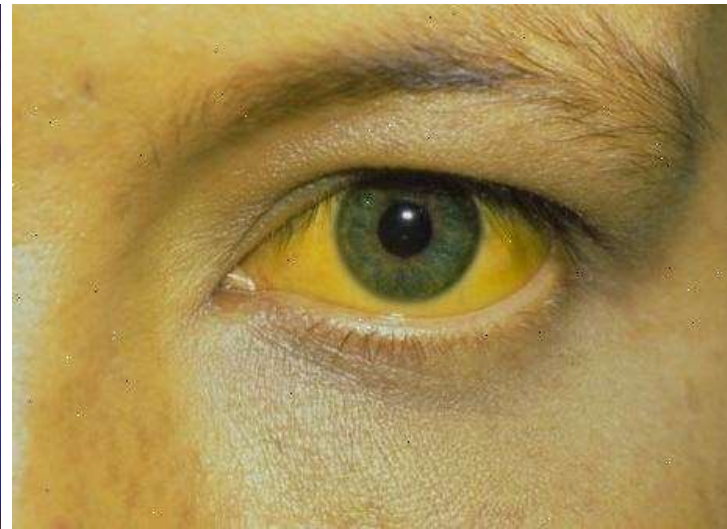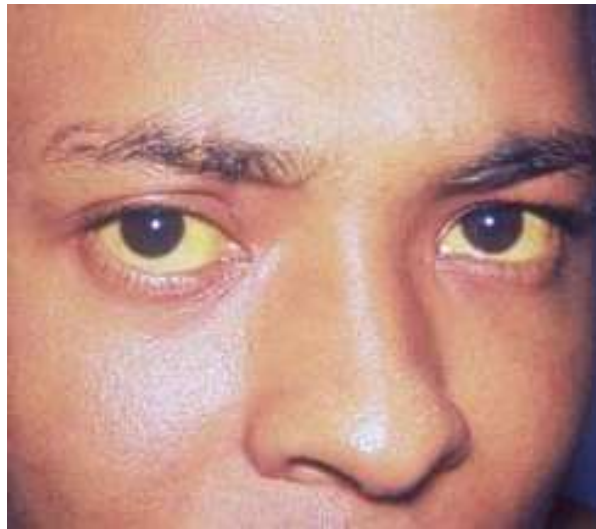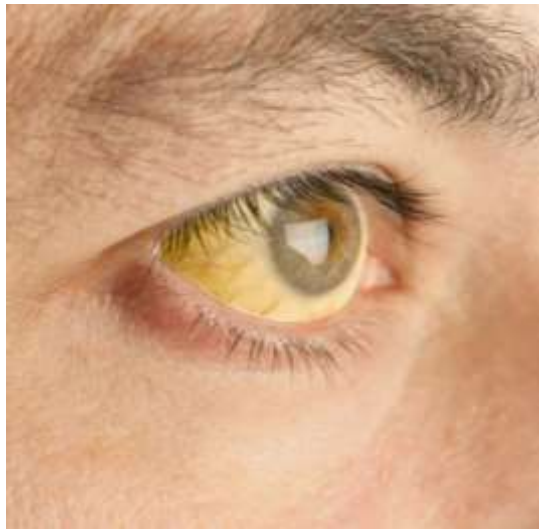- Pain is associated with nausea and vomiting
- Pain radiates to the back and/or right infrascapular region
- Pain awakens the patient from sleep in the middle of the night



# Jaundice: Definition

- Jaundice (icterus) is a yellowish pigmentation of the skin, the conjunctival membranes over the sclerae (whites of the eyes), and other mucous membranes caused by high blood bilirubin levels
- This hyperbilirubinemia subsequently causes increased levels of bilirubin in the extracellular fluid
- Concentration of bilirubin in blood plasma is normally below 1.2 mg/dL (<25 $\mu$ mol/L)
- A concentration higher than approx. 3 mg/dL (>50 $\mu$ mol/L) leads to jaundice


# Jaundice



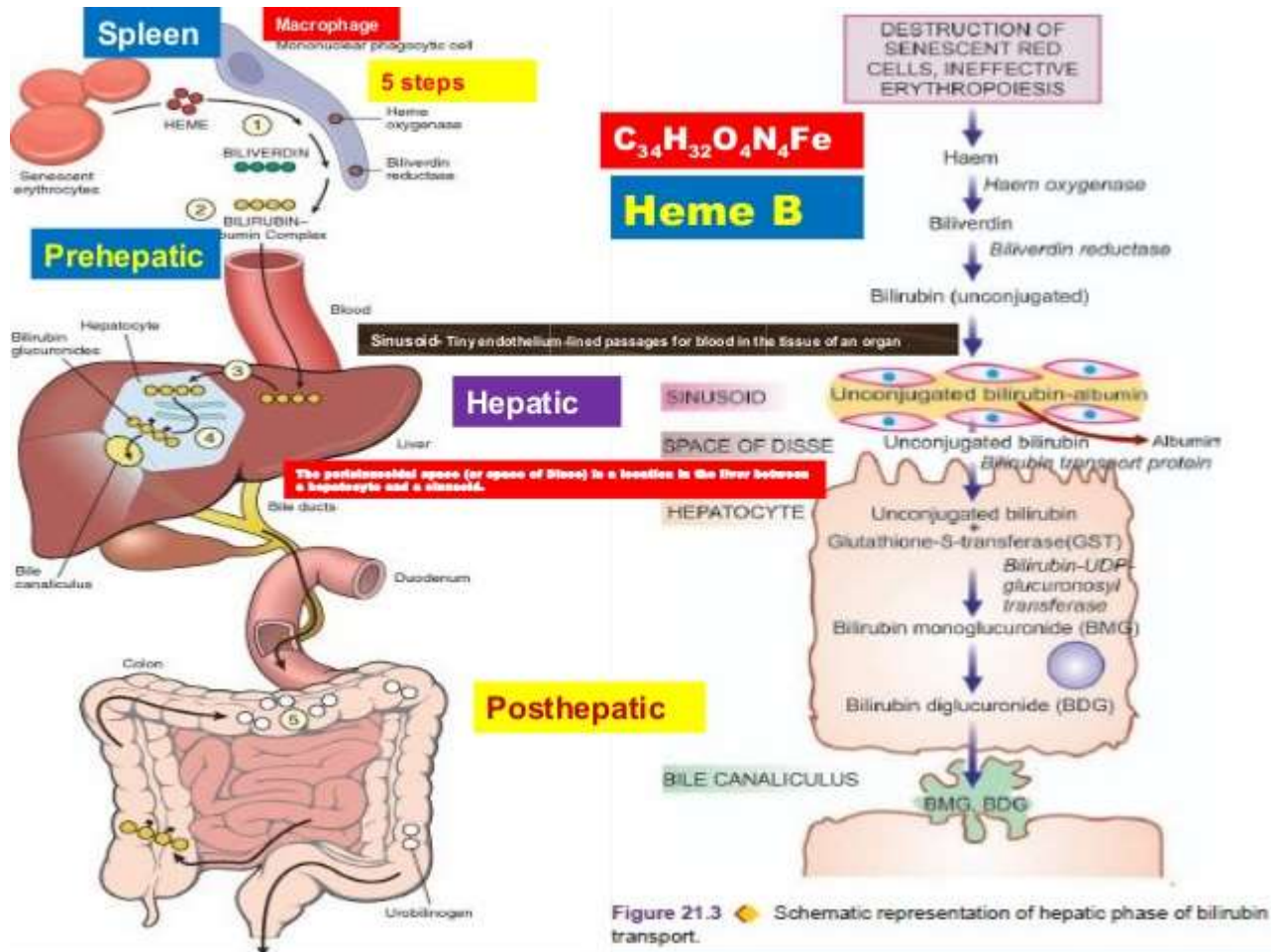
- 
- A concentration higher than approx. 3 mg/dL ( $>50\mu\text{mol/L}$ ) leads to jaundice

# Jaundice: Types

- Pre-hepatic jaundice
- Intra-hepatic jaundice
- Post-hepatic jaundice
- Neonatal jaundice



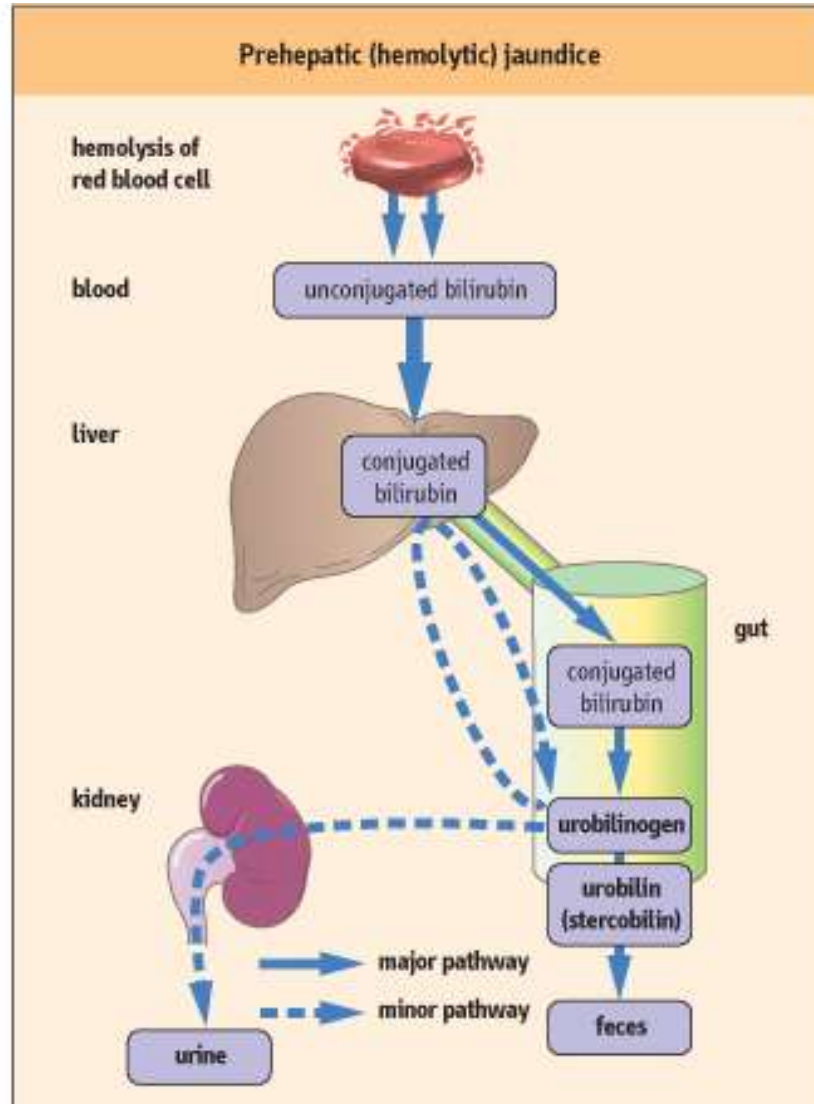
# Jaundice



# Jaundice: Pre-hepatic jaundice

- Pre-hepatic jaundice is caused by anything which causes an increased rate of hemolysis (breakdown of red blood cells): severe malaria, sickle cell anemia, spherocytosis, thalassemia, pyruvate kinase deficiency, glucose 6-phosphate dehydrogenase deficiency, diseases of the kidney, defects in bilirubin metabolism etc.
- The increased breakdown of red blood cells leads to an increase in the amount of unconjugated bilirubin present in the blood and deposition of this unconjugated bilirubin into various tissues can lead to a jaundiced appearance
- In jaundice secondary to hemolysis, the increased production of bilirubin leads to the increased production of urine-urobilinogen
- Bilirubin is not usually found in the urine because unconjugated bilirubin is not water-soluble, so, the combination of increased urine-urobilinogen with no bilirubin (since, unconjugated) in urine is suggestive of hemolytic jaundice

# Jaundice

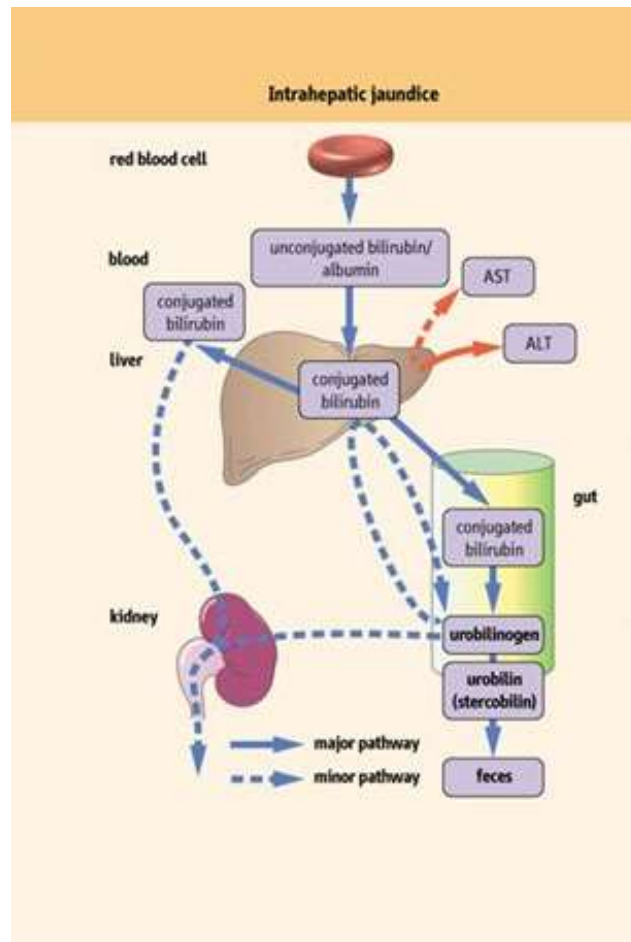


# Jaundice: Intra-hepatic jaundice

- Intra-hepatic jaundice can be caused by acute or chronic hepatitis, hepatotoxicity, cirrhosis, drug-induced hepatitis and alcoholic liver disease
- Cell necrosis reduces the liver's ability to metabolize and excrete bilirubin leading to a buildup of unconjugated bilirubin in the blood
- Other causes include primary biliary cirrhosis leading to an increase in plasma conjugated bilirubin because there is impairment of excretion of conjugated bilirubin into the bile
- The blood contains an abnormally raised amount of conjugated bilirubin and bile salts which are excreted in the urine
- The unconjugated bilirubin still enters the liver cells and becomes conjugated in the usual way
- This conjugated bilirubin is then returned to the blood, probably by rupture of the congested bile canaliculi and direct emptying of the bile into the lymph leaving the liver
- Thus, most of the bilirubin in the plasma becomes the conjugated type rather than the unconjugated type, and this conjugated bilirubin which did not go to intestine to become urobilinogen gives the urine the dark color



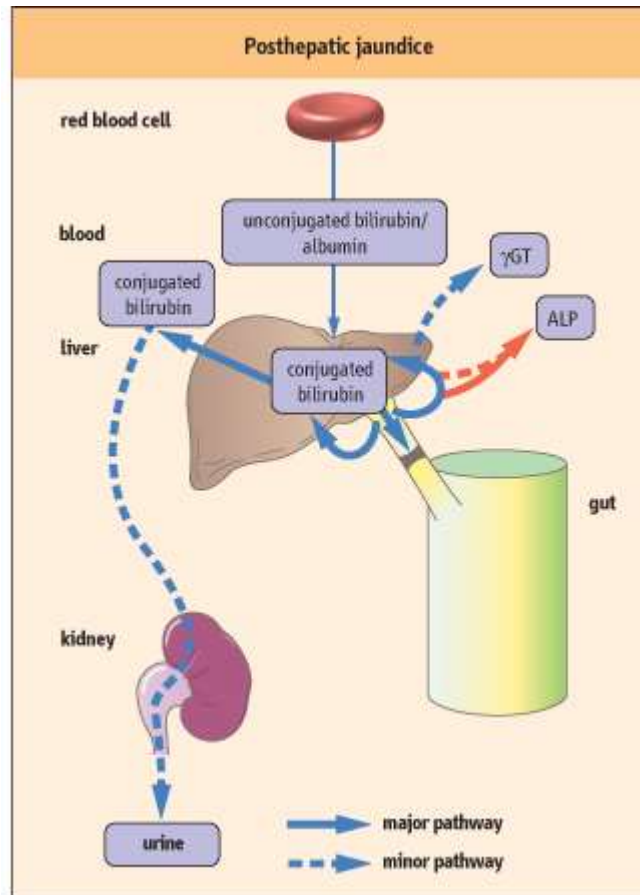
# Jaundice



# Jaundice: Post-hepatic jaundice

- Post-hepatic (obstructive) jaundice, is caused by an interruption to the drainage of bile containing conjugated bilirubin in the biliary system
- The most common causes are gallstones in the common bile duct, and pancreatic cancer in the head of the pancreas
- Also, a group of parasites known as "liver flukes" can live in the common bile duct, causing obstructive jaundice
- Other causes include strictures of the common bile duct, biliary atresia, cholangiocarcinoma, pancreatitis, cholestasis of pregnancy, and pancreatic pseudocysts
- In complete obstruction of the bile duct, no urobilinogen is found in the urine, since bilirubin has no access to the intestine and it is in the intestine that bilirubin gets converted to urobilinogen to be later released into the general circulation
- Presence of bilirubin (conjugated) in the urine without urine-urobilinogen suggests obstructive jaundice, either intra-hepatic or post-hepatic
- The presence of pale stools and dark urine suggests an obstructive or post-hepatic cause as normal feces get their color from bile pigments
- Patients also can present with elevated serum cholesterol, and often complain of severe itching or "pruritus" because of the deposition of bile salt

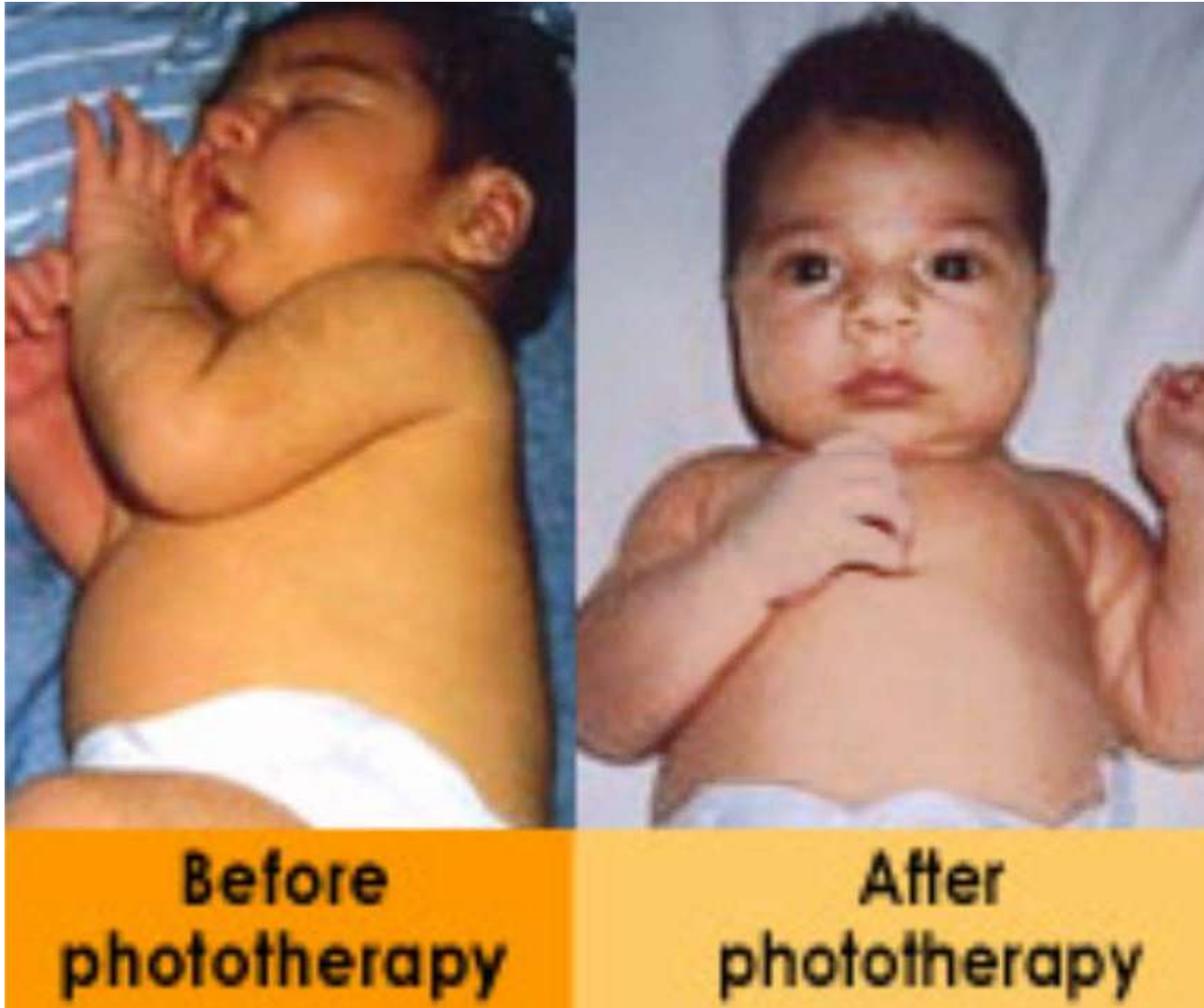# Jaundice



# Jaundice: Neonatal jaundice

- Neonatal jaundice is usually harmless and is often seen in infants around the second day after birth, lasting until day 8 in normal births, or to around day 14 in premature births
- Typical causes for neonatal jaundice include normal physiologic jaundice, jaundice due to formula supplementation and hemolytic disorders that include hereditary spherocytosis, glucose-6-phosphate dehydrogenase deficiency, pyruvate kinase deficiency, ABO/Rh blood type autoantibodies, or infantile pyknocytosis
- Serum bilirubin normally drops to a low level without any intervention required
- In cases where bilirubin rises higher, a brain-damaging condition known as kernicterus can occur, leading to significant disability
- A Bili light is often the tool used for early treatment, which often consists of exposing the baby to intensive phototherapy

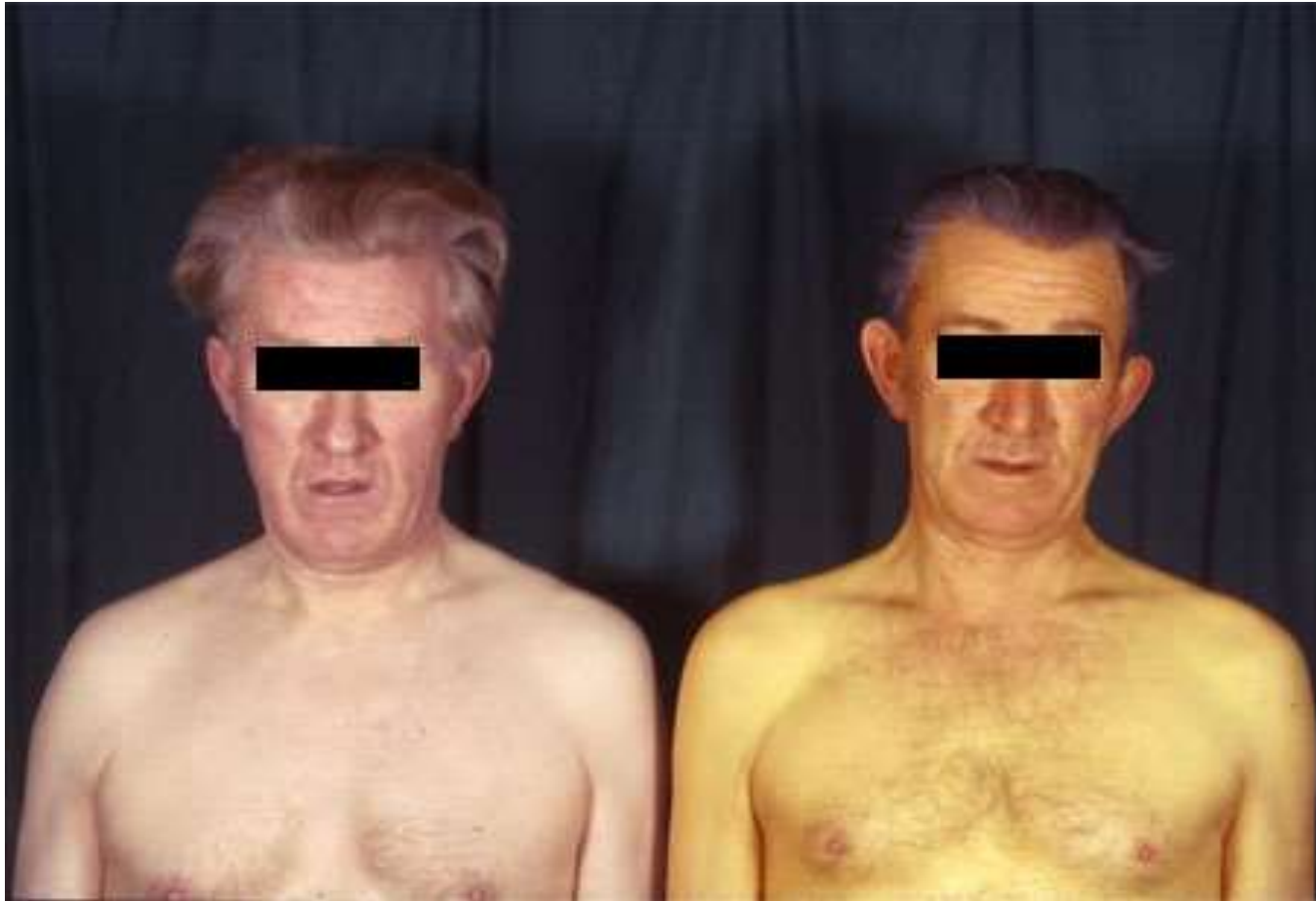# Jaundice



# Jaundice: Symptoms

- The main symptom of jaundice is a yellowish discoloration of the white area of the eye and the skin
- The conjunctiva of the eye are one of the first tissues to change color as bilirubin levels rise in jaundice
- Urine is dark in colour
- Stools (faeces or poo) can be pale in colour

# Jaundice



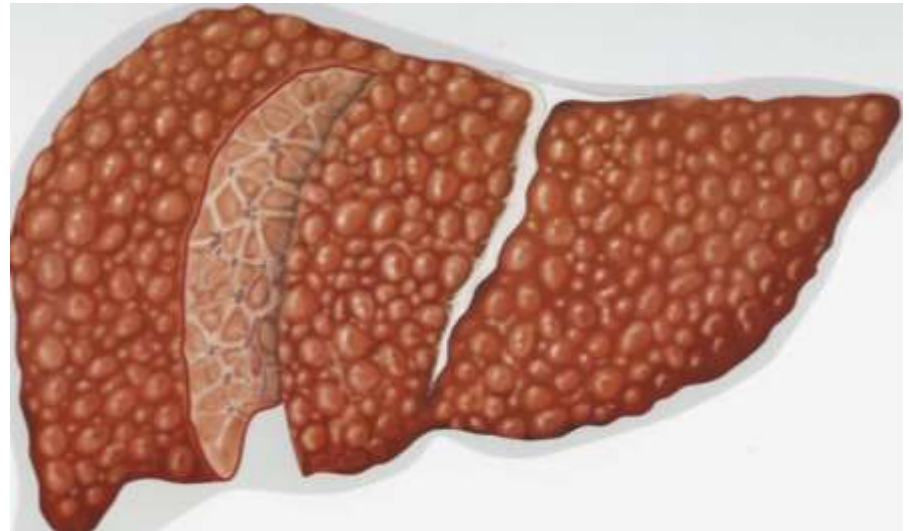# Jaundice: Diagnostic tests

Function test	Jaundice		
	Pre-hepatic	Hepatic	Post-hepatic
Total bilirubin	Normal / Increased	Increased	
Conjugated bilirubin	Normal	Increased	Increased
Unconjugated bilirubin	Normal / Increased	Increased	Normal
Urobilinogen	Normal / Increased	Decreased	Decreased / Negative
Urine Color	Normal	Dark (urobilinogen + conjugated bilirubin)	Dark (conjugated bilirubin)
Stool color	Normal	Normal/Pale	Pale
Alkaline phosphatase levels	Normal	Increased	
Alanine transferase and aspartate transferase levels		Increased	
Conjugated Bilirubin in Urine	Not Present	Present	
Splenomegaly	Present	Present	Absent



# The syndromes of liver size changes

- Enlarged Liver (Hepatomegaly)
- Small for size syndrome



Bridging Fibrosis

# Enlarged Liver: Causes

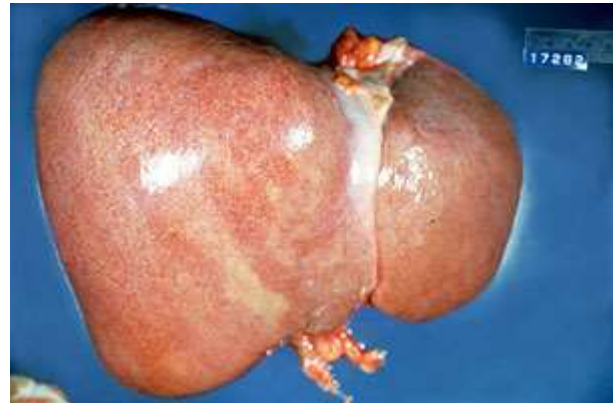- Alcoholic liver disease
- Congestive heart failure
- Cirrhosis
- Hepatitis
- Liver cancer
- Hyperlipidemias
- Chronic leukocytic leukemia
- Hepatic vein thrombosis (Budd-Chiari syndrome)
- Metabolic syndrome X
- Pericarditis
- Adult-Onset Still's disease
- Hypolipoproteinemia

# Enlarged Liver: Symptoms

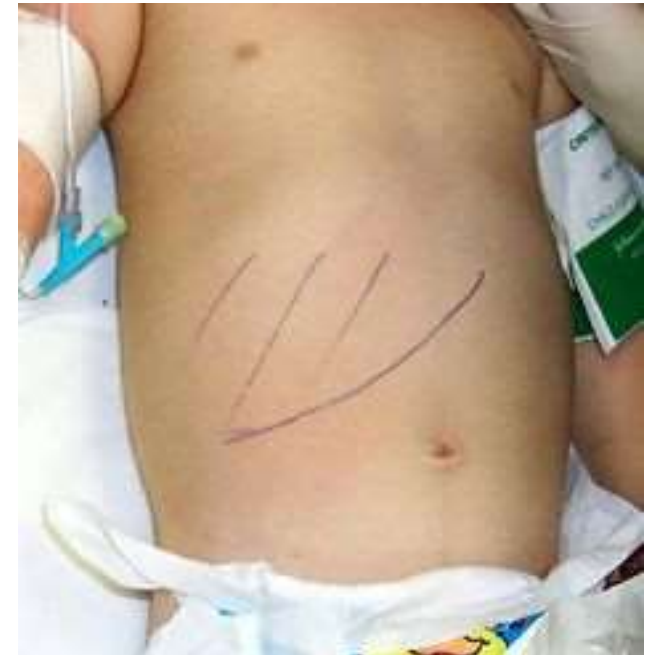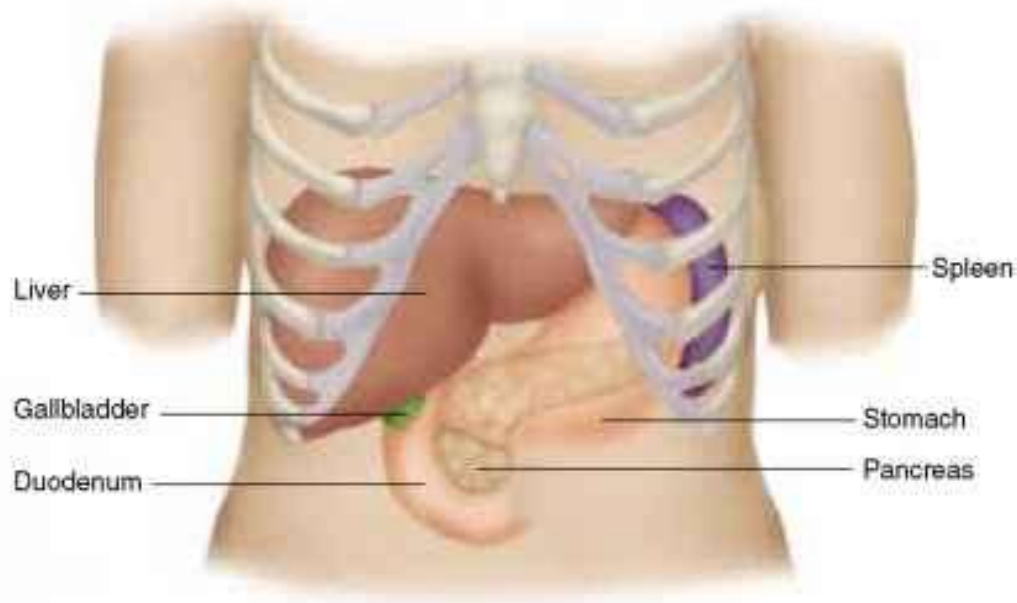
- A feeling of fullness
- Discomfort in the belly
- Depending on the cause of enlarged liver, patient may notice symptoms like:
  - Jaundice
  - Fatigue and weakness
  - Nausea
  - Weight loss

# Enlarged Liver: Diagnosis

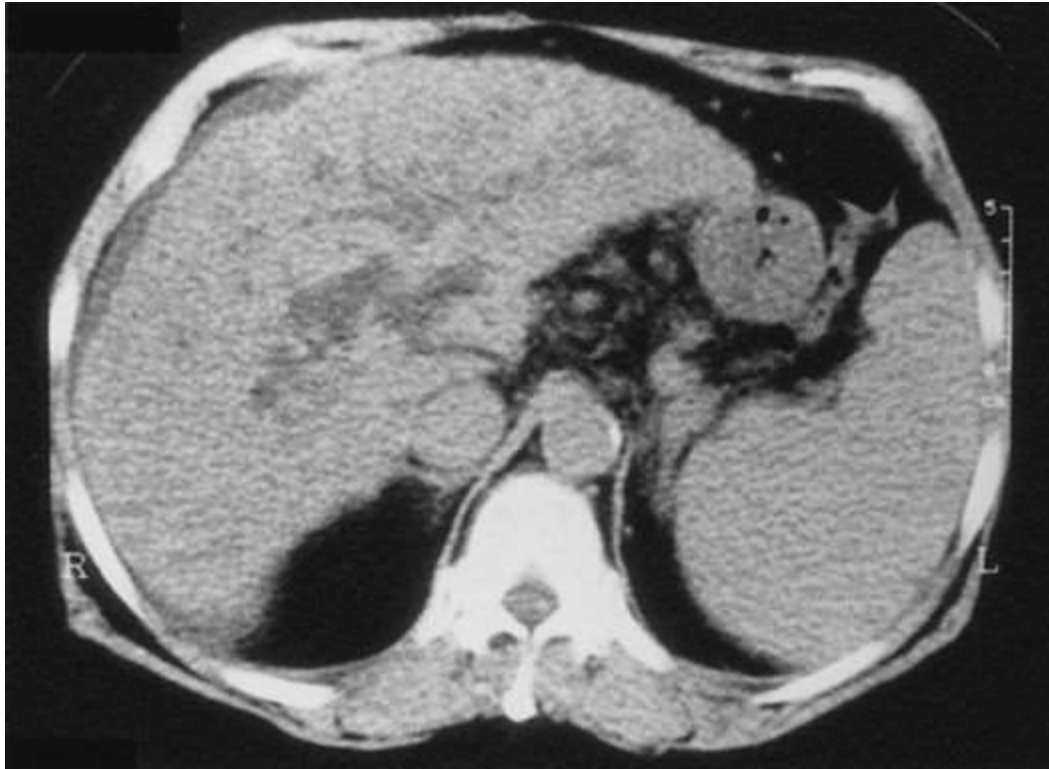
- Physical examination
- CT scan
- MRI
- Ultrasound



# Enlarged Liver: Physical examination

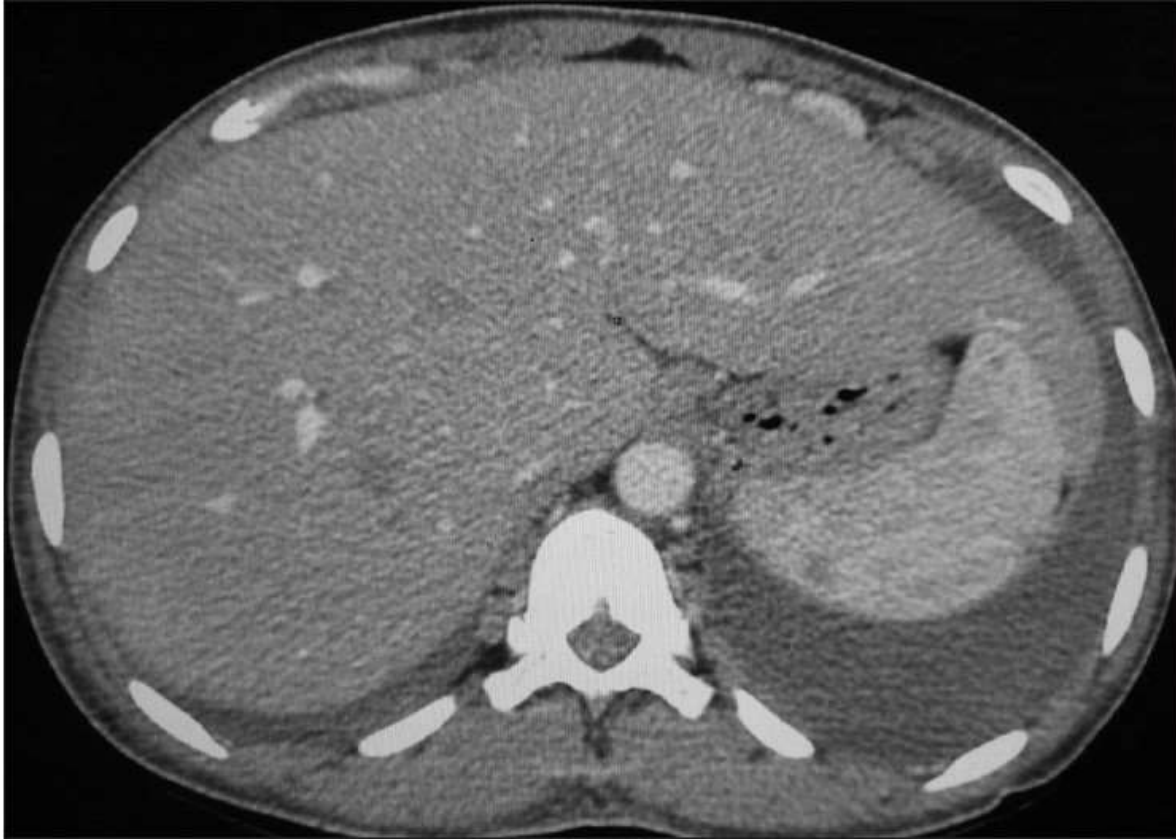

# Enlarged Liver: CT scan



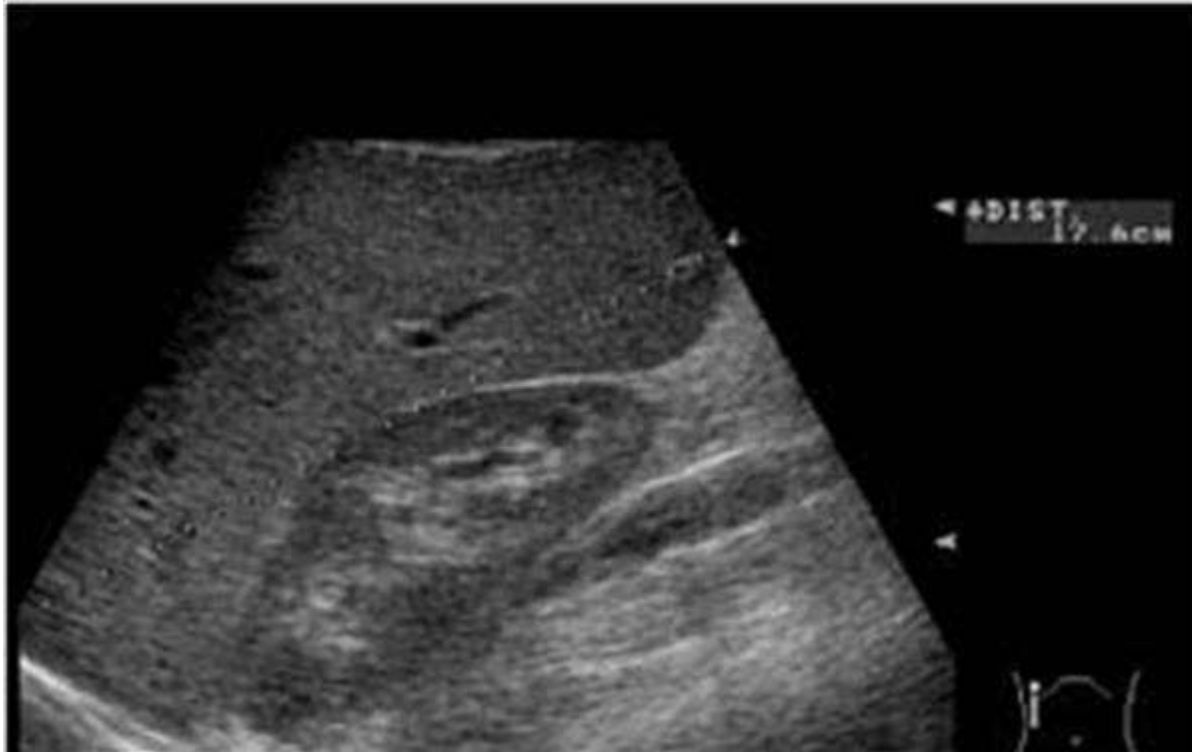
Native CT scan shows a slightly lobulated liver contour with ascites and dilated bile ducts and an enlarged spleen

# Enlarged Liver: MRI



Hepatomegaly and multiple hypoechoic areas in spleen suggesting splenic involvement

# Enlarged Liver: Ultrasound



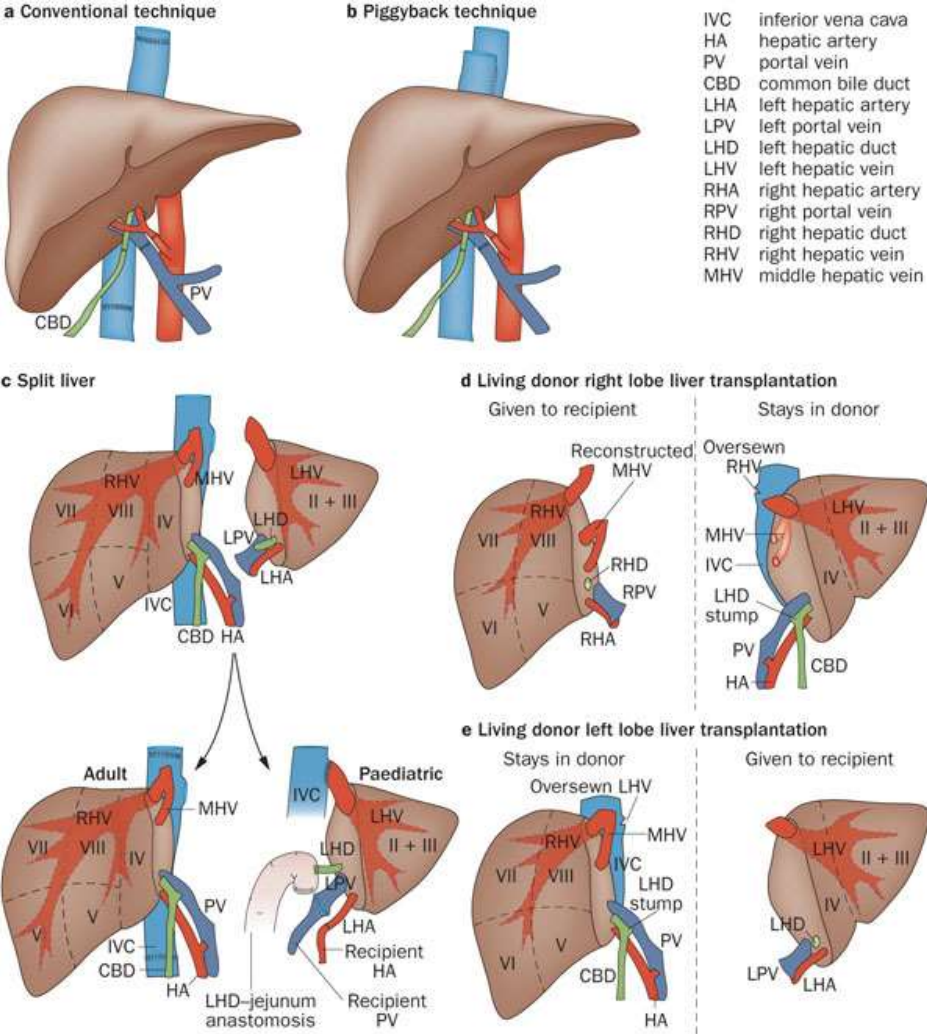
Hodgkin disease with splenomegaly hepatomegaly  
and enlarged mesenteric lymph nodes



## Small for size syndrome: Causes

- Small for size syndrome - is a condition which causes considerable confusion partly because the term has been extended beyond its original meaning
  - It was initially used to describe the situation in liver transplantation where a patient develops liver dysfunction and ascites because the donated organ is too small for the recipient
  - It is now used variably to describe any circumstance where there is post operative liver failure or dysfunction in a patient who has had liver resection or partial or small graft liver transplantation

# Small for size syndrome: Liver transplantation



# Small for size syndrome: Mechanisms

- Small-for-size syndrome can occur in the special situation of partial liver graft transplantation, especially in adult living donor liver transplantation, with resultant size mismatching between graft size and recipient hepato-portal circulation
- Once the partial liver volume graft is subjected to excessive portal inflow, portal hyperperfusion results in the development of the small-for-size syndrome

# Small for size syndrome: Symptoms

- Excessive ascites
- Hyperbilirubinemia
- Coagulopathy
- Encephalopathy
- Renal dysfunction

*Transplant recipients develop symptoms related to the above abnormalities after transplantation and post-transplant prognosis is reported to be less than ideal*

# Portal hypertension: Definition

- Portal hypertension is abnormally high blood pressure in the portal vein system, which is composed of the portal vein, and its branches and tributaries
- Portal hypertension is defined as elevation of hepatic venous pressure gradient to  $>5\text{mmHg}$

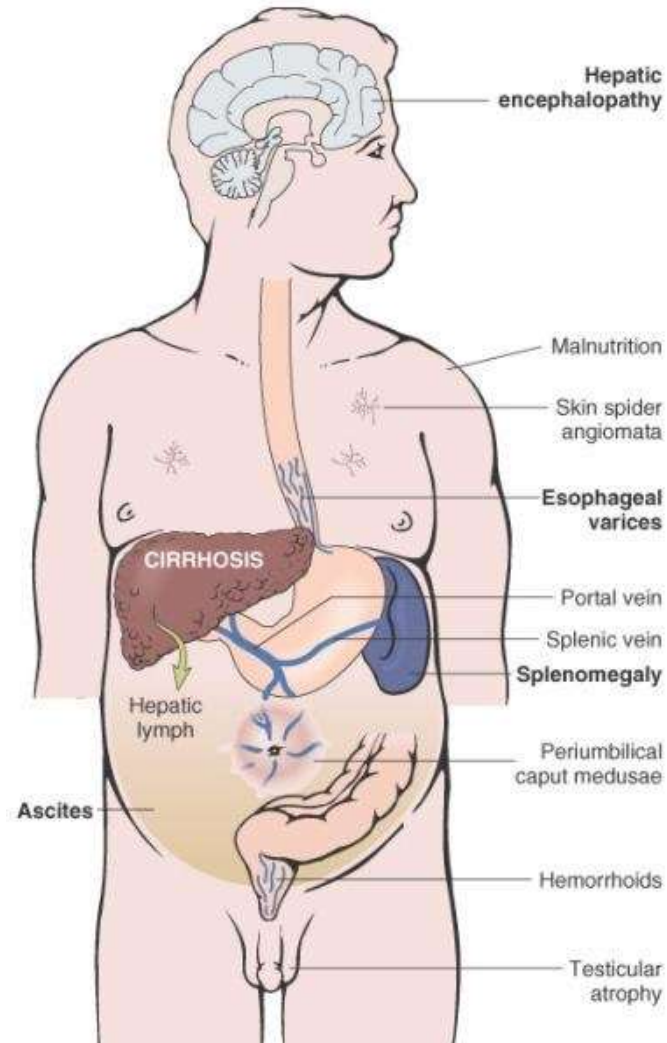
# Portal hypertension: Causes

- Prehepatic: portal vein thrombosis or congenital atresia
- Intrahepatic: liver cirrhosis, hepatic fibrosis, noncirrhotic causes (schistosomiasis, massive fatty change and diffuse granulomatous diseases)
- Posthepatic: hepatic vein thrombosis, inferior vena cava thrombosis, inferior vena cava congenital malformation, constrictive\_pericarditis

# Portal hypertension: Symptoms

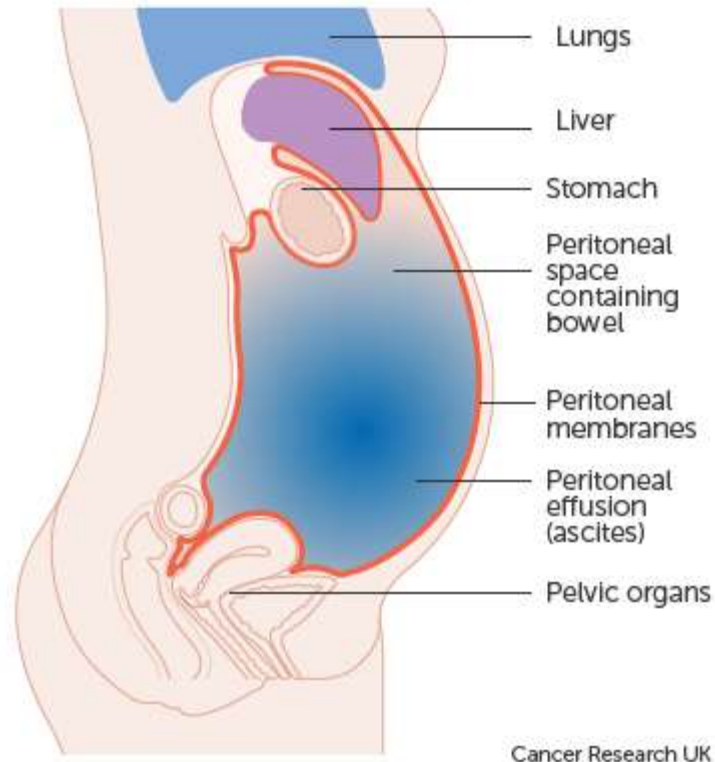
- Weakness, tiredness, and malaise
- Anorexia, weight loss (common with acute and chronic liver disease)
- Ascites
- Hepatic encephalopathy
- Increased risk of spontaneous bacterial peritonitis
- Increased risk of hepatorenal syndrome
- Splenomegaly with a consequent accumulation of red blood cells, white blood cells, and platelets, together leading to mild pancytopenia
- Development of varices at portacaval anastomoses: esophageal varices, gastric varices, ano-rectal varices, caput medusae
- Esophageal and gastric varices pose an ongoing risk of life-threatening bleeding, with bloody vomiting or melena

# Portal hypertension: Symptoms

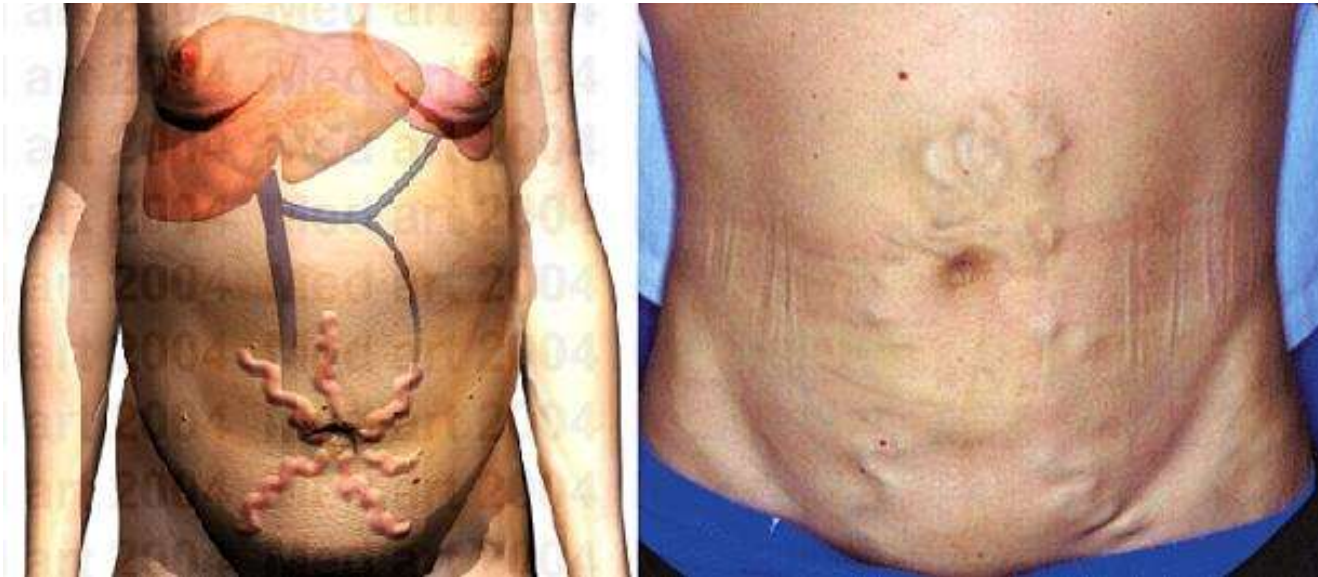



# Portal hypertension: Ascites



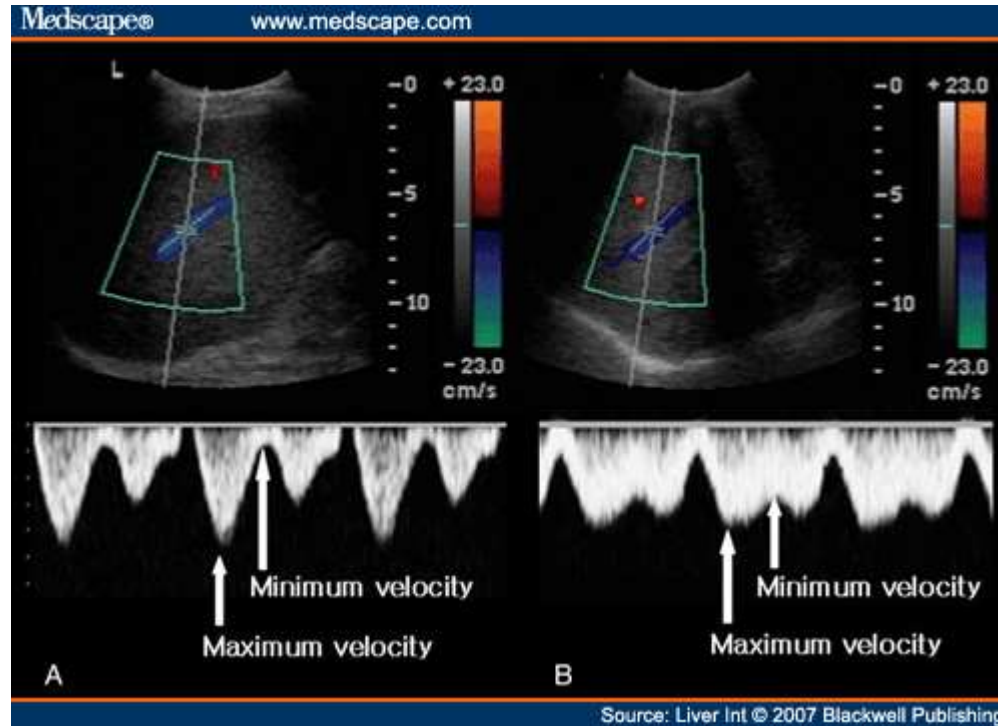
# Portal hypertension: Caput medusae



# Portal hypertension: Diagnosis

- Clinical symptoms
- HVPG (hepatic venous pressure gradient) measurement as the gold standard for assessing the severity of portal hypertension
- HVPG replaced the old one - contrast angiography
- Portal hypertension is defined as HVPG greater than or equal to 5mm Hg and is considered to be clinically significant when HVPG exceeds 10 to 12 mm Hg
- Imaging tests, such as duplex Doppler ultrasonography , magnetic resonance imaging (MRI), or computed tomography (CT)
- Liver biopsy and histologic examination
- Hemodynamic measurement of the hepatic venous pressure gradient (HVPG): A criterion standard for assessment of portal hypertension
- Upper GI endoscopy (or, esophagogastroduodenoscopy [EGD]): A criterion standard for assessment of portal hypertension

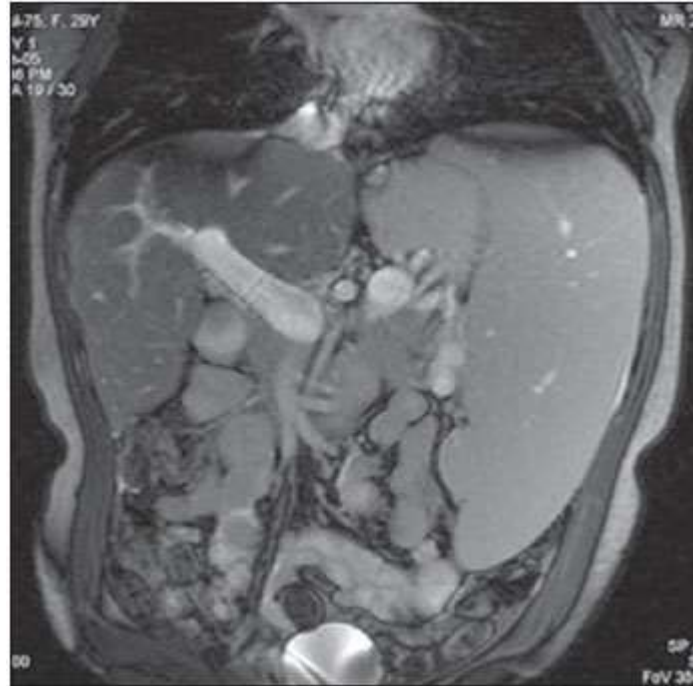# Portal hypertension: Hepatic venous pressure gradient



Measurement of damping index (DI) of hepatic vein waveform. DI is calculated by the minimum velocity/maximum velocity of the downward hepatic vein wave.

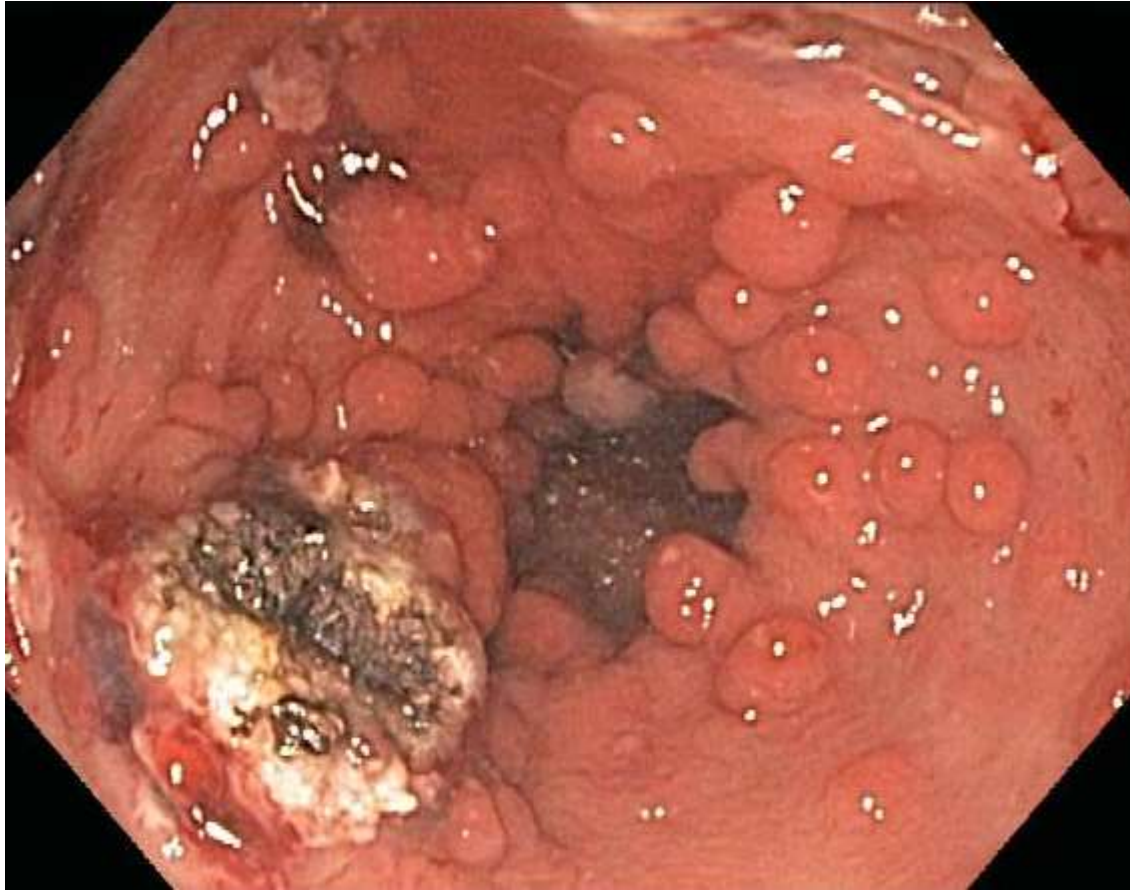
(A) A patient with liver cirrhosis showed 0.26 of DI with 7 mmHg of hepatic venous pressure gradient (HVPg). (B) Another patient with liver cirrhosis showed 0.72 of DI with 15 mmHg of HVPg.

# Portal hypertension: MRI



Coronal section plane of the abdomen acquired with the true fast imaging (TRUFI) sequence, used to define the middle segment of the portal vein.

# Portal hypertension: Esophagogastroduodenoscopy

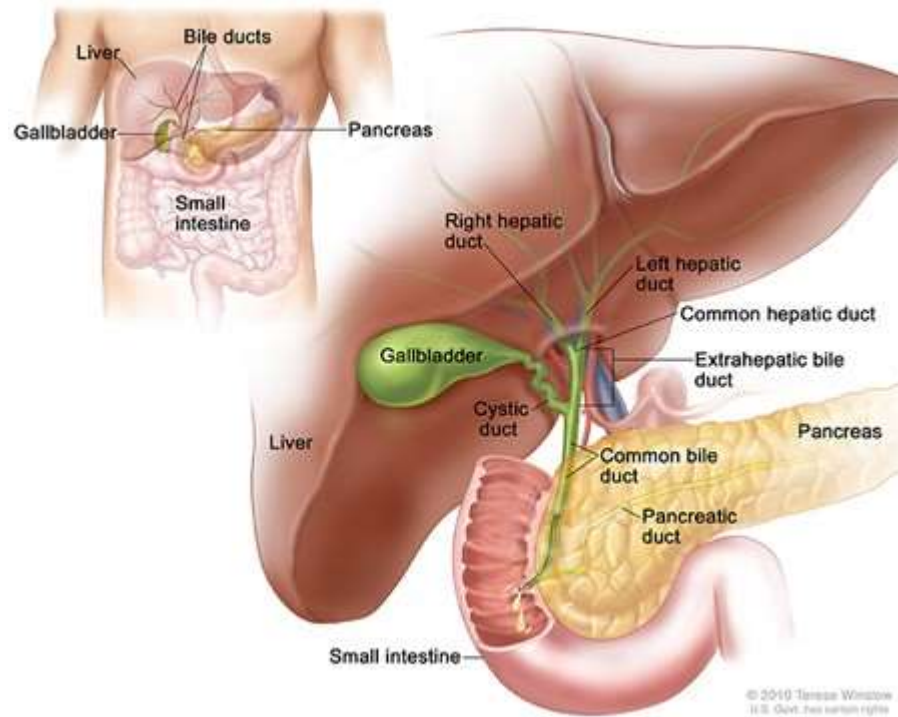


Endoscopic view of multiple, large portal hypertensive polyps in the antrum.

# Portal hypertension: Laboratory testing

- Complete blood count
- Liver function tests (e.g., aspartate aminotransferase [AST], alanine aminotransferase [ALT], bilirubin, alkaline phosphatase [ALP])
- Coagulation studies (prothrombin time [PT], partial thromboplastin time [PTT], international normalized ratio [INR])
- Blood urea nitrogen, creatinine, and electrolytes
- Arterial blood gas (ABG) and pH measurements
- Hepatic and viral hepatitis serologies, particularly hepatitis B and C serologies
- Albumin levels: Hypoalbuminemia is common (impaired hepatic synthetic function)
- Antinuclear antibody, antimitochondrial antibody, antismooth muscle antibody
- Iron indices
- Alpha1-antitrypsin deficiency
- Ceruloplasmin, 24-hour urinary copper

# Exocrine pancreas: Reminder

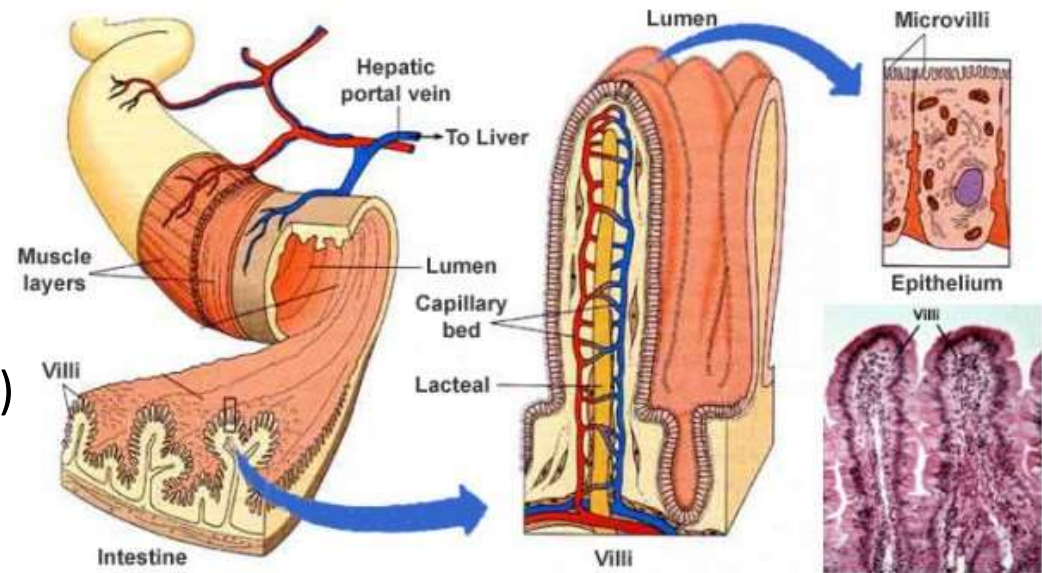


[How do Exocrine Pancreas works](#)



# Exocrine pancreas: History-taking

- Upper abdominal pain
- Nausea and vomiting
- Malabsorption
- Diabetes
- Losing weight without trying
- Oily, smelly stools (steatorrhea)
- Tenderness when touching the abdomen
- Miscellaneous



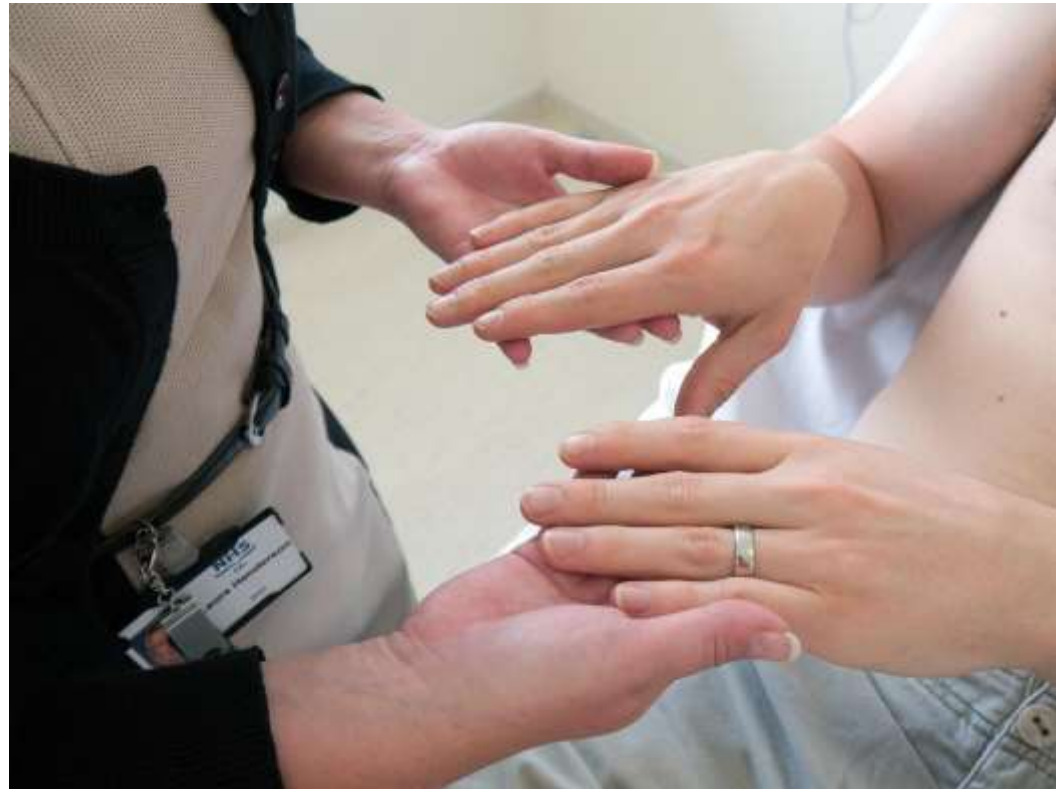# Exocrine pancreas: History-taking

## Example of specific questions in chief complaint

- Character
- Location
- Severity
- Timing
- Duration
- Radiation
- Provocation
- Relieving conditions
- When did it first start?
- How often does it occur?
- Is appetite good or has it changed?
- What brought it on?
- Were there associated symptoms
- Is it becoming more frequent with time?
- Are the symptoms lasting longer?
- How **are** the symptoms related to food intake?

# Exocrine pancreas: Clinical examination of the patient

- General inspection from the end of the bed
- General examination of:
  - Hands/pulse
  - Face
  - Lymph nodes
- Examination of the abdomen
  - Inspection
  - Palpation
  - Percussion
  - Auscultation



# Exocrine pancreas: Instrumental examination of the patient

- Flat-plate film of the abdomen
- Computed tomography
- Magnetic resonance imaging
- Abdominal ultrasonography
- Color Doppler
- Endoscopic ultrasonography
- Endoscopic retrograde cholangiopancreatography (ERCP)



# Exocrine pancreas: Laboratory examination of the patient

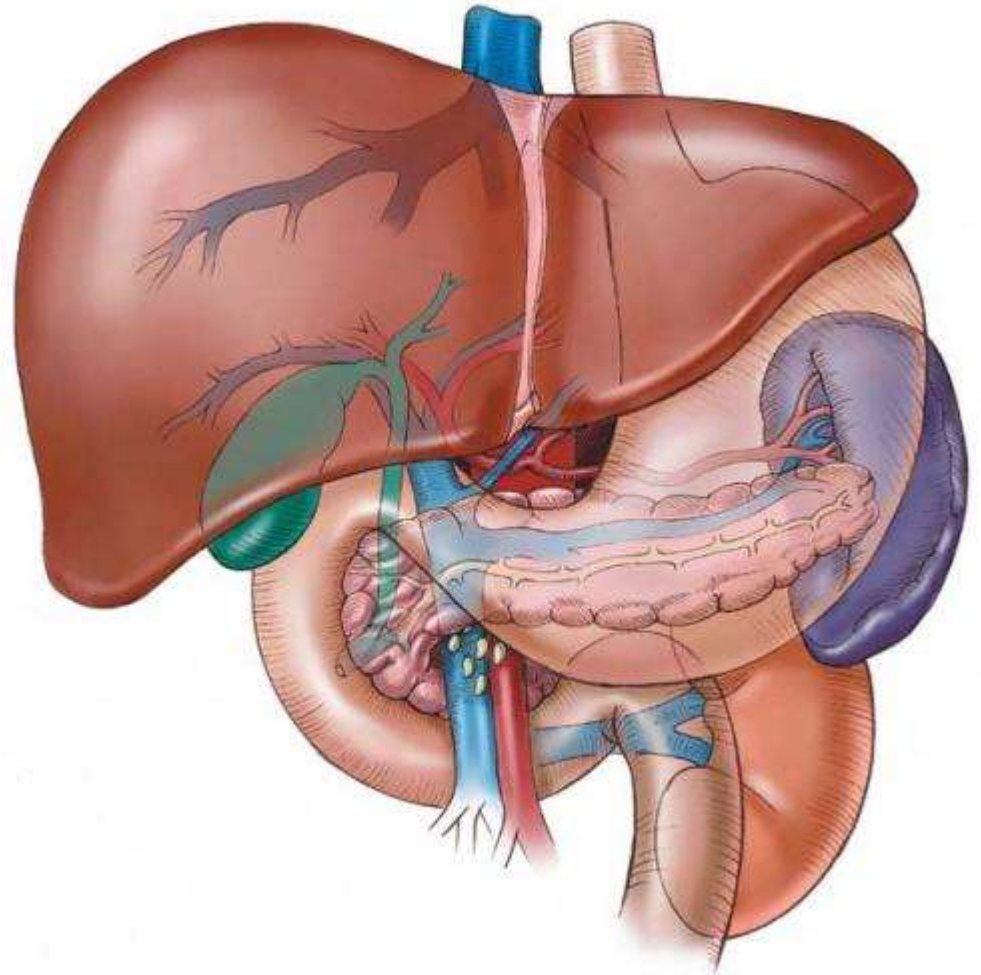
- Blood count
- Blood sugar tests
- Blood Coagulation
- Electrolytes
- Bilirubin blood test
- Plasma proteins
- Blood ammonia
- Alkaline phosphatase
- Gamma glutamyl transferase
- Enzyme & protein blood tests
- Lipid blood tests
- C-reactive protein
- Fecal occult blood test



Photo courtesy of Cepheid

# Exocrine pancreas: Syndromes

- Exocrine Pancreatic Insufficiency
  - Diarrhea
  - Steatorrhea
  - Abdominal pain
  - Symptoms of vitamin deficiencies



# Exocrine Pancreatic Insufficiency: Definition

- Exocrine pancreatic insufficiency (EPI) is the inability to properly digest food due to a lack of digestive enzymes made by the pancreas
- EPI is caused by a progressive loss of the pancreatic cells that make digestive enzymes

# Exocrine Pancreatic Insufficiency: Causes

- Pancreatic
  - Chronic pancreatitis
  - Cystic fibrosis
  - Obstructions of the pancreatic duct (e.g., from pancreatic cancer or ampullary tumors)
  - Shwachman-Diamond syndrome (EPI, bone marrow dysfunction, leukemia predisposition, and skeletal abnormalities)
- Nonpancreatic
  - Celiac disease
  - Crohn disease
  - Autoimmune pancreatitis
  - Zollinger-Ellison syndrome
  - GI and pancreatic surgical procedures



# Exocrine Pancreatic Insufficiency: Pathophysiology

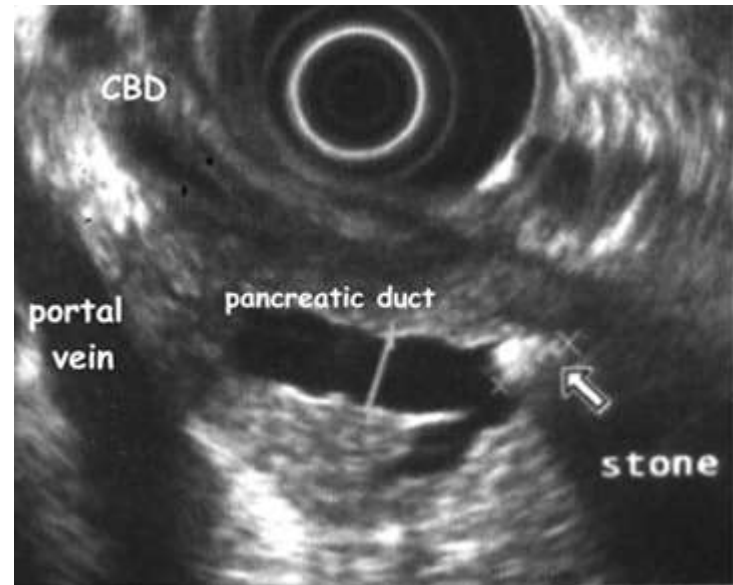
- EPI is characterized by a deficiency of exocrine pancreatic enzymes, which results in inability to digest food properly (i.e., maldigestion)
- Because pancreatic lipase accounts for up to 90% of fat digestion, maldigestion of fat is more profound in EPI than maldigestion of proteins and carbohydrates is
- Because the exocrine pancreas retains a large reserve capacity for enzyme secretion, fat digestion is not clearly impaired until lipase output decreases to below 10% of the normal level
- Fat malabsorption precedes malabsorption of other macronutrients
- Bile salt precipitation and subsequent adsorption to undigested food reduces the bile salt pool, and this reduction further impairs fat digestion
- Undigested fat, rather than being absorbed, is excreted in the feces, leading to steatorrhea
- Another factor that contributes to pancreatic steatorrhea is the presence of neurohormonal disturbances, which result in gall bladder hypomotility and accelerated gastric and intestinal transit
- Malabsorption of fat-soluble vitamins A, D, E, and K may accompany EPI

# Exocrine Pancreatic Insufficiency: Symptoms

- Steatorrhea
- Weight loss
- Diarrhea
- Pale, bulky, malodorous stools often float on top of the toilet water with oily droplets and are difficult to flush
- Fatigue
- Flatulence and abdominal distention
- Edema (result from hypoalbuminemia)
- Anemia (can be either microcytic (related to iron deficiency) or macrocytic (related to vitamin B-12 deficiency))
- Bleeding disorders (a consequence of vitamin K malabsorption and subsequent hypoprothrombinemia)
- Ecchymosis
- Metabolic bone disease (vitamin D deficiency )
- Neurologic manifestations (result from electrolyte disturbances): generalized motor weakness, peripheral neuropathy, loss of a sense of vibration and position, night blindness, seizures

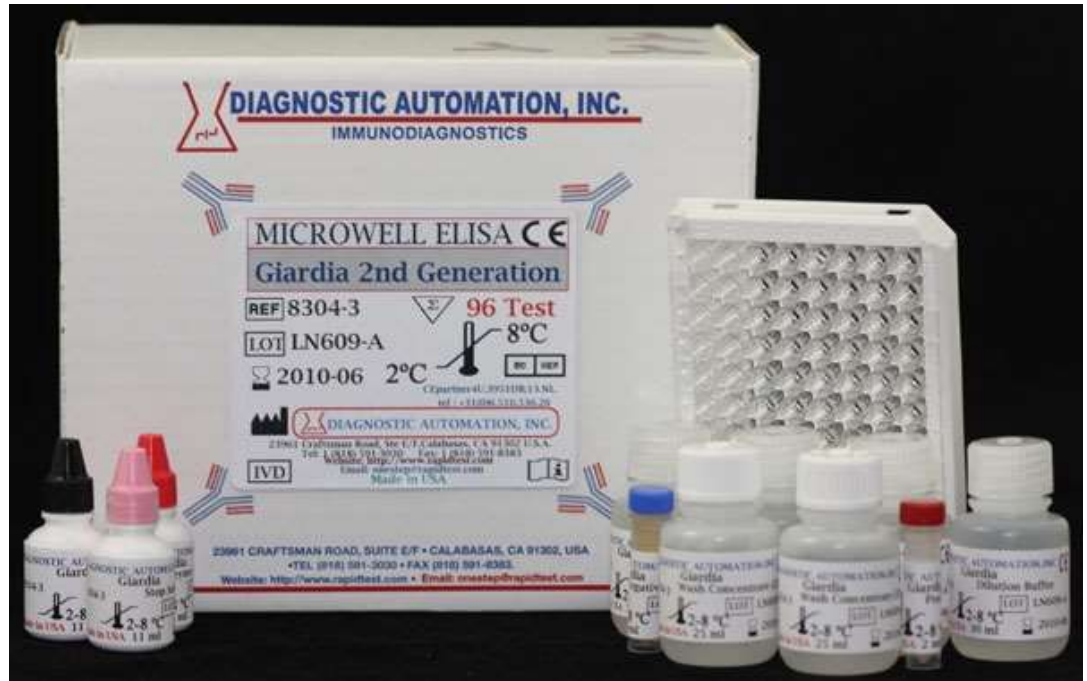# Exocrine Pancreatic Insufficiency: Diagnosis

- Blood tests
- 3-day fecal test
- Fecal elastase-1
- CT scan
- MRI
- Endoscopic ultrasound



# Exocrine Pancreatic Insufficiency: 3-day fecal test

- The normal range for fecal fat testing is 7 grams over a 24-hour period
- Normal results for a 72-hour test would be 21 grams

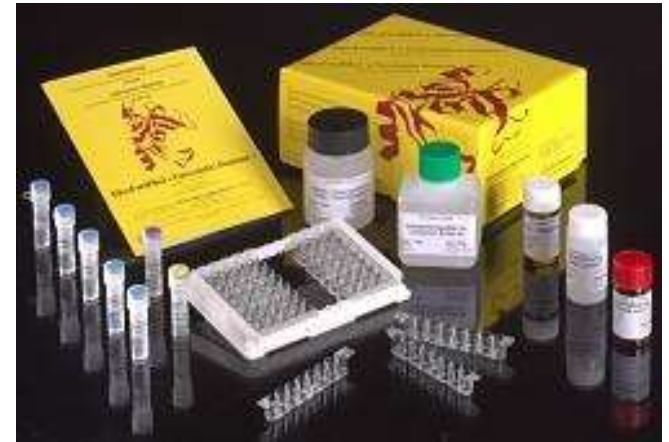

Fecal Stool Test Kits

# Exocrine Pancreatic Insufficiency: Fecal elastase-1

Reference concentration to interpret Pancreatic Elastase results for adults and children after the first month of life:

- Values  $> 200 \mu\text{g}$  elastase/g stool indicate normal exocrine pancreatic function
- Values of  $100\text{-}200 \mu\text{g}$  elastase/g stool suggest mild to moderate pancreatic insufficiency
- Values  $< 100 \mu\text{g}$  elastase/g stool indicate exocrine pancreatic insufficiency



Extraction Buffer for Fecal  
Elastase 1™ Kit

# Glossary of hepatobiliary tract and exocrine pancreas pathology' terms 1

**Abdomen** - area between the chest and the hips that contains the stomach, small intestine, large intestine, liver, gallbladder, pancreas, and spleen.

**Absorption** - the way nutrients from food move from the small intestine into the cells in the body.

**Accessory digestive organs** - organs that help with digestion but are not part of the digestive tract. These organs include the tongue, pancreas, liver, gallbladder, and glands in the mouth that make saliva.

**Acute** - used to describe a symptom or condition which has a sudden onset as opposed to being chronic.

**Anemia** - blood disorder caused by a deficiency of red blood cells or hemoglobin (the oxygen-carrying protein in red blood cells).

**Angiography** - X-ray that uses injected dye (contrast material) to detect bleeding in the gastrointestinal tract.

**Ascites** - fluid build-up in the abdominal cavity which is usually caused by severe liver diseases, such as cirrhosis.

**Atresia** - lack of a normal opening from the esophagus, biliary system, intestines, or the anus.

**Autoimmune hepatitis** - liver disease caused when the body's immune system destroys liver cells for no known reason.

**Bile** - fluid made by the liver and stored in the gallbladder. Bile helps break down fats and gets rid of wastes in the body.

**Bile acids** - acids made by the liver that work with bile to break down fats.

**Bile ducts** - tubes that carry bile from the liver to the gallbladder for storage and to the small intestine for use in digestion.

# Glossary of hepatobiliary tract and exocrine pancreas pathology' terms 2

**Biliary atresia** - condition present from birth in which the bile ducts inside or outside the liver do not have normal openings. Bile becomes trapped in the liver, causing jaundice and cirrhosis. Without surgery, the condition may cause death.

**Biliary stricture** - narrowing of the biliary tract from scar tissue. The scar tissue may result from injury, disease, pancreatitis, infection, or gallstones.

**Biliary tract (also called biliary system or biliary tree)** - gallbladder and the bile ducts.

**Bilirubin** - a yellow-green color substance found in bile formed when hemoglobin breaks down. Bilirubin gives bile its color. Bilirubin is normally passed in stool. Too much bilirubin causes jaundice.

**Bloating** - fullness or swelling in the abdomen that often occurs after meals.

**Budd-Chiari syndrome** - rare liver disease in which the veins that drain blood from the liver are blocked or narrowed.

**Calculi** - stones or solid lumps such as gallstones.

**Catheter** - thin, flexible tube that carries fluids into or out of the body.

**Cholangiography** - a procedure in which dye (contrast) is deposited and the bile duct structures can be viewed by X-ray.

**Cholangitis** - irritated or infected bile ducts.

**Cholecystectomy** - operation to remove the gallbladder.

**Cholecystitis** - irritated, inflamed gallbladder.

**Cholecystography (also called oral cholecystography or gallbladder series)** - a series of X-rays are taken of the gallbladder after a special contrast dye is swallowed, making it possible to detect gallstones, cholecystitis, and other abnormalities.

# Glossary of hepatobiliary tract and exocrine pancreas pathology' terms 3

**Choledocholithiasis** - gallstones in the bile ducts.

**Cholelithiasis** - gallstones in the gallbladder.

**Cholestasis** - blocked bile ducts often caused by gallstones.

**Cholesterol** - a substance normally made by the body, but also found in foods from animal sources, like beef, eggs, and butter. Too much cholesterol in the body can lead to narrowing and blockage of the arteries, especially those that supply blood to the heart and keep it healthy. High cholesterol can also cause the formation of gallstones. Ideally, blood cholesterol levels should be less than 200mg/dL.

**Chronic** - referring to a disease or disorder that usually develops slowly and lasts for a long period of time.

**Cirrhosis** - a chronic problem that makes it hard for the liver to remove toxins (poisonous substances) from the body. Alcohol, medications, and other substances may build up in the bloodstream and cause problems. Cirrhosis is a result of scarring and damage from other diseases, such as biliary atresia and alcoholism.

**Common bile duct** - tube that carries bile from the liver to the small intestine.

**Common bile duct obstruction** - blockage of the common bile duct, often caused by gallstones.

**Computed tomography scan (CT or CAT scan)** - a diagnostic imaging procedure using a combination of X-rays and computer technology to produce cross-sectional images (often called slices), both horizontally and vertically, of the body. A CT scan shows detailed images of any part of the body, including the bones, muscles, fat, and organs. CT scans are more detailed than general X-rays.

**Cystic duct** - tube that carries bile from the gallbladder into the common bile duct and the small intestine.

**Cystic duct obstruction** - blockage of the cystic duct, often caused by gallstones.

**Digestive tract** - the organs that are involved in digestion, including the mouth, salivary glands, esophagus, stomach, pancreas, liver, gallbladder, small intestine, and large intestine.



# Glossary of hepatobiliary tract and exocrine pancreas pathology' terms 4

**Distention** - bloating or swelling; usually referring to the abdomen.

**Duodenum** - the first section of the small intestine.

**Endoscope** - small, flexible tube with a light and a lens on the end used to look into the esophagus, stomach, duodenum, colon, or rectum. It can also be used to take tissue from the body for testing or to take color photographs of the inside of the body. Colonoscopes and sigmoidoscopes are types of endoscopes.

**Endoscopic retrograde cholangiopancreatography (ERCP)** - a procedure that allows the doctor to diagnose and treat problems in the liver, gallbladder, bile ducts, and pancreas. The procedure combines X-ray and the use of an endoscope--a long, flexible, lighted tube. The scope is guided through the patient's mouth and throat, then through the esophagus, stomach, and duodenum. The doctor can examine the inside of these organs and detect any abnormalities. A tube is then passed through the scope, and a dye is injected which will allow the internal organs to appear on an X-ray.

**Endoscopic sphincterotomy** - operation to cut the muscle between the common bile duct and the pancreatic duct. Also called endoscopic papillotomy.

**Endoscopy** - procedure that uses an endoscope to diagnose or treat a condition.

**Enteral nutrition (also called tube feeding)** - a way to provide food through a tube placed in the nose, the stomach, or the small intestine. A tube in the nose is called a nasogastric or nasoantral tube. A tube that goes through the skin into the stomach is called a gastrostomy or percutaneous endoscopic gastrostomy (PEG). A tube into the small intestine is called a jejunostomy or percutaneous endoscopic jejunostomy (PEJ) tube.

**Esophageal varices** - stretched veins in the esophagus that occur when the liver is not working properly.

# Glossary of hepatobiliary tract and exocrine pancreas pathology' terms 5

**Esophagogastroduodenoscopy (also called EGD or upper endoscopy)** - a procedure that allows the doctor to examine the inside of the esophagus, stomach, and duodenum. A thin, flexible, lighted tube, called an endoscope, is guided into the mouth and throat, then into the esophagus, stomach, and duodenum. The endoscope allows the doctor to view the inside of this area of the body, as well as to insert instruments through a scope for the removal of a sample of tissue for biopsy (if necessary).

**Esophagus** - organ that connects the mouth to the stomach.

**Excrete** - to get rid of waste from the body.

**Extrahepatic biliary tree** - bile ducts located outside the liver.

**Fatty liver (also called steatosis)** - buildup of fat in liver cells.

**Fecal fat test** - test to measure the body's ability to break down and absorb fat.

**Fibrosis** - the growth of scar tissue due to infection, inflammation, injury, or even healing.

**Gallbladder** - organ that stores the bile made in the liver and sends bile into the small intestine to help digest fat.

**Gallstones** - solid masses or stones made of cholesterol or bilirubin that form in the gallbladder or bile ducts.

**Gastrectomy** - operation in which part (subtotal or partial) or all (total) of the stomach is removed.

**Gastritis** - inflammation of the stomach lining.

**Gastroenteritis** - infection or irritation of the stomach and intestines, which may be caused by bacteria or parasites from spoiled food or unclean water, or eating food that irritates the stomach lining.

**Gastroenterologist** - doctor who specializes in digestive diseases.

**Glucagon** - a hormone produced by the pancreas.

# Glossary of hepatobiliary tract and exocrine pancreas pathology' terms 6

**Glycogen** - converted glucose for storage. Glycogen plays a role in controlling blood sugar levels.

**Glucose** - a simple sugar, which is the body's main source of energy.

**Hepatic** - related to the liver.

**Hepatitis** - inflammation of the liver that sometimes causes permanent damage; caused by viruses, drugs, alcohol, or parasites. Hepatitis has the following forms:

**Hepatitis A** - a form of infectious hepatitis caused by the hepatitis A virus. The virus may be spread by fecal-oral contact, fecal-infected food or water, and may also be spread by a blood-borne infection (which is rare).

**Hepatitis B** - a form of infectious hepatitis caused by the hepatitis B virus. Transmission of the hepatitis B virus occurs through blood and body fluid exposure such as blood, semen, vaginal secretions, or saliva.

**Hepatitis C** - a form of infectious hepatitis caused by the hepatitis C virus. Transmission of the hepatitis C virus occurs primarily from contact with infected blood, but can also occur from sexual contact or from an infected mother to her baby.

**Hepatitis D** - a form of infectious hepatitis caused by the hepatitis D (Delta) virus. This form of hepatitis can only occur in the presence of hepatitis B. Transmission of hepatitis D occurs the same way as hepatitis B.

**Hepatitis E** - a form of infectious hepatitis caused by the hepatitis E virus. This form of hepatitis is similar to hepatitis A. Transmission occurs through fecal-oral contamination. Hepatitis E is most common in poorly developed countries and is rarely seen in the US.

**Hepatitis G** - the newest form of infectious hepatitis. Transmission is believed to occur through blood and is seen in IV drug users, individuals with clotting disorders, such as hemophilia, and individuals who require hemodialysis for renal failure.

**Hepatobiliary scintigraphy** - an imaging technique of the liver, bile ducts, gallbladder, and upper part of the small intestine.

# Glossary of hepatobiliary tract and exocrine pancreas pathology' terms 7

**Hepatologist** - doctor who specializes in liver diseases.

**Hepatology** - field of medicine concerned with the functions and disorders of the liver.

**Hormones** - chemical substances created by the body that control numerous body functions.

**Ileal** - related to the ileum, the lowest end of the small intestine.

**Ileum** - lower end of the small intestine.

**Insulin** - a hormone produced by the pancreas. Insulin affects the amount of glucose absorbed by the liver.

**Jaundice** - yellowing of the skin and eyes that is caused by too much bilirubin in the blood.

**Jejunum** - middle section of the small intestine between the duodenum and ileum.

**Laparoscopy** - use of a viewing tube with a lens or camera (and a light on the end), which is inserted through a small incision in the abdomen to examine the contents of the abdomen and remove tissue samples.

**Laparotomy** - a surgical incision into a cavity in the abdomen, usually performed using general or regional anesthesia.

**Large intestine** - part of the intestine that goes from the cecum to the rectum.

**Liver** - largest organ in the body, which carries out many important functions, such as making bile, changing food into energy, and cleaning alcohol and poisons from the blood.

**Liver biopsy** - a procedure in which tissue samples from the liver are removed (with a needle or during surgery) from the body for examination under a microscope.

**Liver enzyme tests (also called liver function tests)** - blood tests to screen for liver and biliary system abnormalities.

# Glossary of hepatobiliary tract and exocrine pancreas pathology' terms 8

**Lower GI (gastrointestinal) series (also called barium enema)** - a procedure that examines the rectum, the large intestine, and the lower part of the small intestine. A fluid called barium (a metallic, chemical, chalky, liquid used to coat the inside of organs so that they will show up on an X-ray) is given into the rectum as an enema. An X-ray of the abdomen shows strictures (narrowed areas), obstructions (blockages), and other problems.

**Magnetic resonance imaging (MRI)** - a diagnostic procedure that uses a combination of large magnets, radiofrequencies, and a computer to produce detailed images of organs and structures within the body.

**Nausea** - a feeling or sensation leading to the urge to vomit.

**Obstruction** - blockage in the GI tract that prevents the flow of liquids or solids.

**Pancreas** - gland that makes enzymes for digestion and the hormone insulin.

**Pancreatitis** - inflammation of the pancreas.

**Percutaneous transhepatic cholangiography (PTC)** - a needle is introduced through the skin and into the liver where the dye (contrast) is deposited so the bile duct structures can be viewed by X-ray.

**Perineum** - area between the anus and the sex organs.

**Peritoneum** - lining of the abdominal cavity.

**Peritonitis** - infection of the peritoneum.

**Portal hypertension** - high blood pressure in the portal vein that carries blood from the intestine into the liver.

**Portal vein** - large vein that carries blood from the intestines and spleen to the liver.

**Portosystemic shunt** - operation to create an opening between the portal vein and other veins around the liver.

**Postcholecystectomy syndrome (also called biliary dyskinesia)** - condition that occurs after gallbladder removal in which the muscle between the gallbladder and the small intestine does not work properly, causing pain, nausea, and indigestion.

# Glossary of hepatobiliary tract and exocrine pancreas pathology' terms 9

**Primary sclerosing cholangitis** - irritation, scarring, and narrowing of the bile ducts inside and outside the liver.

**Proton pump inhibitors** - medications that stop the stomach's acid pump.

**Pyloric sphincter** - muscle between the stomach and the small intestine.

**Pyloric stenosis** - narrowing of the opening between the stomach and the small intestine.

**Pylorus** - opening from the stomach into the top of the small intestine (duodenum).

**Rectum** - lower end of the large intestine, leading to the anus.

**Rupture** - break or tear in any organ or soft tissue.

**Sclerotherapy** - method of stopping upper GI bleeding. A needle is inserted through an endoscope to bring hardening agents to the place that is bleeding.

**Small intestine** - the section of the digestive tract between the stomach and the large intestine. Most of digestion occurs here as nutrients are absorbed from food.

**Sphincter** - ring-like band of muscle that opens and closes a passageway in the body.

**Sphincter of Oddi** - muscle between the common bile duct and pancreatic ducts.

**Spleen** - organ that filters blood and makes white blood cells.

**Stricture (also called stenosis)** - abnormal narrowing of a body opening.

**Tumor** - an abnormal lump or mass of tissue. Tumors can be benign (noncancerous) or malignant (cancerous).

**Ultrasound (also called sonography)** - a diagnostic imaging technique, which uses high-frequency sound waves and a computer to create images of blood vessels, tissues, and organs. Ultrasounds are used to view internal organs of the abdomen such as the liver, spleen, and kidneys and to assess blood flow through various vessels.

**Upper GI endoscopy** - looking into the esophagus, stomach, and duodenum with an endoscope.

# Glossary of hepatobiliary tract and exocrine pancreas pathology' terms 10

**Upper GI (gastrointestinal) series (also called barium swallow)** - a diagnostic test that examines the organs of the upper part of the digestive system: the esophagus, stomach, and duodenum (the first section of the small intestine). A fluid called barium (a metallic, chemical, chalky, liquid used to coat the inside of organs so that they will show up on an X-ray) is swallowed. X-rays are then taken to evaluate the digestive organs.

**Varices** - stretched, dilated veins such as those that form in the esophagus from cirrhosis.

**X-ray** - a diagnostic test which uses invisible electromagnetic energy beams to produce images of internal tissues, bones, and organs onto film.