Brain, Behavior, and Immunity 23 (2009) 85–91

Contents lists available at ScienceDirect

Brain, Behavior, and Immunity

journal homepage: www.elsevier.com/locate/ybrbi

Spinal cord histopathological alterations in a patient with longstanding complex regional pain syndrome

Luis Del Valle [a], Robert J. Schwartzman [b], Guillermo Alexander [b,*]

[a] Department of Neuroscience, Neuropathology Core and Center for Neurovirology, Temple University School of Medicine, 1900 North 12th Street, Philadelphia, PA 19122, USA
[b] Department of Neurology, Drexel University College of Medicine, 245 North 15th Street, Mail Stop 423, Philadelphia, PA 19102, USA

ARTICLE INFO

Article history:
Received 1 April 2008
Received in revised form 5 August 2008
Accepted 12 August 2008
Available online 26 August 2008

Keywords:
Complex regional pain syndrome
CRPS
Histopathology
Chronic pain
Spinal cord
Microglia
Astrocytes
Neuronal loss

ABSTRACT

Complex regional pain syndrome (CRPS) is a chronic pain condition that usually arises from an injury or as a complication from a surgical procedure. CRPS can result from multiple mechanisms including active processes involving both the peripheral and the central nervous system and sickness like responses involving interactions between the immune and nervous systems. In animal models both peripheral and central sensitization as well as loss of inhibition has been implicated in neuropathic pain states. Glial cells, in particular microglia and astrocytes, are the immunocompetent cells in the central nervous system and are activated following tissue injury or inflammation. In animal studies, activated glia have been shown to be both necessary and sufficient for enhanced nociception. Using immunohistochemical techniques, this study evaluated the degree of astrocytic and microglial activation as well as neuronal loss in autopsy tissue from the cervical, thoracic and lumbar spinal cord of a patient afflicted with CRPS as compared to four control individuals. The major findings of this study are that in long standing CRPS there was significant posterior horn cell loss and activation of both microglia and astrocytes most prominently at the level of the original injury but extending throughout the entire length of the spinal cord. Our hope is that the data obtained from this and other studies of autopsy material may aid in elucidating the mechanisms involved in the pathophysiology of CRPS, which may lead to the refinement of current therapies as well as novel treatments.

© 2008 Elsevier Inc. All rights reserved.

1. Introduction

Complex regional pain syndrome (CRPS) is a chronic pain condition that usually arises from an injury or as a complication from a surgical procedure. The signs and symptoms of CRPS cluster into four distinct subgroups; abnormalities in pain processing, skin color and temperature changes, edema, vasomotor and sudomotor abnormalities and motor dysfunction and trophic changes (Harden et al., 2007). Continuous pain is the most devastating of these symptoms. The pain of CRPS is intense, out of proportion to the severity of the injury, worsens over time and can spread beyond the injured area (Maleki et al., 2000).

Studies in both animals and humans have shown that the types of chronic pain observed in CRPS patients can result from multiple mechanisms. These mechanisms include changes in the peripheral nervous system (PNS) (Matzner and Devor, 1994; Waxman et al., 1999, 2000; Ishikawa et al., 1999) and active processes involving both the PNS and the central nervous system (CNS) (Siviloti and Woolf, 1994; Woolf and Salter, 2000; Moore et al., 2002; Janig and Baron, 2003). In addition, a number of studies have demonstrated that chronic pain states can also result from interactions between the immune and nervous systems (Calder et al., 1998; Marchand et al., 2005; Watkins and Maier, 2005; Alexander et al., 2007). Glial cells, in particular microglia and astrocytes, are the immunocompetent cells in the central nervous system (CNS) and are activated following tissue injury or inflammation (Tsuda et al., 2005; Watkins et al., 2001). Once activated, glia secretes a number of substances known to excite pain transmission in neurons (Kreutzberg, 1996; Watkins et al., 2001). In animal studies, activated glial cells have been shown to be both necessary and sufficient for enhanced nociception (Watkins and Maier, 2003). In the present study we utilized immunohistochemical methods to evaluate the degree of microglia and astrocytic activation as well as neuronal loss in autopsy tissue from the cervical, thoracic and lumbar spinal cord of a patient with longstanding refractory CRPS.

2. Materials and methods

2.1. CRPS patient

The CRPS patient was a 55-year-old Caucasian female who suffered CRPS for seven years. She was originally injured in June of 1998 during vigorous exercise in which she damaged her left

* Corresponding author. Fax: +1 215 762 3161.
E-mail address: guillermo.alexander@drexelmed.edu (G. Alexander).

0889-1591/$ - see front matter © 2008 Elsevier Inc. All rights reserved.
doi:10.1016/j.bbi.2008.08.004

gastrocnemius muscle. She immediately noticed bruising and swelling at the site of injury and by August of 1998 she suffered sharp shooting pains, a deep ache and sensitivity to touch in her entire left leg. In December of 1999, the patient noted numbness of the fingers of her right hand, and aching in the dorsal radial sensory distribution of the right forearm. She had concomitant pain in the left buttock, hip and lateral side of the left leg that radiated to the great toe as well as hyperhidrosis of the left leg and both feet. Her pain was continuous, was exacerbated by walking and weight bearing, and slightly relieved by recumbency and pain medications. The patient reported hot and cold sensations in these distributions that were accompanied by hyperhidrosis. She was severely restricted in both her social and recreational activities and was recumbent for most of the day. Sleep was severely affected both in the ability to fall asleep and to remain asleep. At this time, she demonstrated all factors necessary for the diagnosis of CRPS (Harden et al., 2007) in the left lower extremity that included; swelling, hyperhidrosis, color and temperature change, weakness and dystrophic changes of her skin and nails. Her pain was spontaneous at the level of 8/10 on a Likert numeric rating scale (NRS) (0 being no pain and 10 being the worst pain imaginable). She suffered severe dynamic and static allodynia of the left leg at a 6–8/10 level on a Likert NRS.

During this period the patient had tried high doses of oxycontin, neurontin, topamax, hydrocodone, diazepam, multiple antidepressants and non-steroidal anti-inflammatory agents without success. The patient underwent eight paravertebral sympathetic blocks on the left side and eight Bier blocks in her left foot which gave her 2–3 weeks of partial relief early in the course of the illness but were ineffective with time. In June of 2000, the patient had a dorsal column stimulator placed in the midline at T10. In the areas of stimulator coverage her global pain scale was 2/10 on a Likert NRS. By August, her Likert NRS was 5/10 in both legs. Multiple voltage and stimulator pulse width adjustments were made with her neuromodulation system from March 7, 2001 to November 11, 2002 without success. In September of 2002, she started cognitive behavioral therapy, which was ineffective. The patient also unsuccessfully tried biofeedback, transcutaneous electrical nerve stimulator (TENS) and psychological interventions.

In January of 2004, the patient fell and injured her low back, which exacerbated her pain in the legs and cervical areas to a Likert NRS of 9/10. In May of 2004 she underwent radio frequency neurolysis of L4–L5 which relieved her electric-like, sharp pain in the legs but she still suffered deep aching pain and tightness in these distributions. Zanaflex 4 mg every 6 h, was added to oxycodone 5/325 1–2 tablets every 4–8 h and Valium 5 mg every 4–8 h with minimal relief. In June of 2004 she noted burning pain of her entire right upper extremity. In July of 2004, she underwent superior cervical ganglion blocks on the right with the co-administration of an anticonvulsant, narcotic and muscle relaxant with minimal relief. Her NRS pain level in the right arm was 8/10 for dynamic and static mechanoallodynia and she was hyperalgesic to pinprick. She also had associated hyperhidrosis of the right arm, temperature change (coldness) and weakness of the hand. Morphine at 30 mg tid with morphine sulfate immediate release (MSIR) 30 mg for breakthrough pain was of little benefit. In September 2004, a dorsal column stimulator was placed in the cervical spine and by October she had 1/10 pain in the right arm and was able to decrease the MSIR to 4 mg/day. Through the winter of 2004, the patient gradually lost the effectiveness of both of her stimulation systems, due to difficulties in adequate coverage of the affected areas. Through the summer of 2005 the pain in both upper extremities and the left lower extremity had returned to 7/10 on a Likert NRS. She underwent two more stimulation implantations for both the upper and lower extremities without significant pain relief. The patient died of cardiopulmonary arrest in September of 2005. The autopsy was performed and the tissues collected less than 24 h after death.

Table 1
Neurons (pan-axonal neurofilaments SMI-311)

	Control #1				Control #2			
	Anterior horn		Posterior horn		Anterior horn		Posterior horn	
	Left	Right	Left	Right	Left	Right	Left	Right
Cervical (C5–C7)	68	72	40	39	61	70	41	40
Thoracic (T9–T11)					57	58	35	29
Lumbar (L3–L5)	63	73	41	42	59	68	39	37
	Control #3							
	Anterior horn		Posterior horn					
	Left	Right	Left	Right				
Cervical (C5–C7)	58	57	38	37				
Thoracic (T9–T11)								
Lumbar (L3–L5)	55	54	36	35				
	Control #4				CRPS case			
	Anterior horn		Posterior horn		Anterior horn		Posterior horn	
	Left	Right	Left	Right	Left	Right	Left	Right
C5–C6	65	62	38	39	52	48	14	22
C6–C7	63	66	34	34	45	41	16	19
T9–T10	59	54	31	29	38	32	12	17
T10–T11	53	61	32	28	33	30	15	16
L3–L4	61	68	37	41	49	51	13	20
L4–L5	58	71	36	40	46	49	11	21

Neuronal cell count performed on 5 μm thick sections from cervical, thoracic and lumbar spinal cord. Immunolabeling was done with antibodies against neurofilaments (Sternberger Monoclonals Inc., Clone SMI-311, 1:1000 dilution). Cell counts were performed by counting the total number of positive cells on the anterior and posterior horns of the left and right sides per cellular marker at 200× magnification.

Table 2
Activated microglial cells (CD-68)

	Control #1				Control #2			
	Anterior horn		Posterior horn		Anterior horn		Posterior horn	
	Left	Right	Left	Right	Left	Right	Left	Right
Cervical (C5–C7)	0	1	0	0	0	0	0	0
Thoracic (T9–T11)					0	1	0	0
Lumbar (L3–L5)	0	1	1	0	0	0	1	0
	Control #3							
	Anterior horn		Posterior horn					
	Left	Right	Left	Right				
Cervical (C5–C7)	1	0	0	0				
Thoracic (T9–T11)								
Lumbar (L3–L5)	0	0	0	0				
	Control #4				CRPS case			
	Anterior horn		Posterior horn		Anterior horn		Posterior horn	
	Left	Right	Left	Right	Left	Right	Left	Right
C5–C6	0	0	1	0	0	0	7	5
C6–C7	1	0	0	0	1	0	13	8
T9–T10	1	0	0	1	0	1	22	12
T10–T11	0	0	0	0	1	2	28	17
L3–L4	0	0	0	1	3	1	33	19
L4–L5	0	0	1	0	2	0	42	23

Activated microglia cell count performed on 5 μm thick sections from cervical, thoracic and lumbar spinal cord. Immunolabeling was done with antibodies against human CD-68 (Clone PG-M1, DAKO, 1:100 dilution). Cell counts were performed by counting the total number of positive cells on the anterior and posterior horns of the left and right sides per cellular marker at 200× magnification.

Table 3
Reactive astrocytes (glial fibrillary acidic protein—GFAP)

	Control #1				Control #2			
	Anterior horn		Posterior horn		Anterior horn		Posterior horn	
	Left	Right	Left	Right	Left	Right	Left	Right
Cervical (C5–C7)	11	15	12	11	9	10	7	13
Thoracic (T9–T11)					11	17	19	11
Lumbar (L3–L5)	14	16	15	13	10	11	12	11
	Control #3							
	Anterior horn		Posterior horn					
	Left	Right	Left	Right				
Cervical (C5–C7)	8	10	8	11				
Thoracic (T9–T11)								
Lumbar (L3–L5)	10	9	11	10				
	Control #4				CRPS case			
	Anterior horn		Posterior horn		Anterior horn		Posterior horn	
	Left	Right	Left	Right	Left	Right	Left	Right
C5–C6	9	13	10	14	25	23	39	42
C6–C7	11	13	7	15	29	27	45	38
T9–T10	10	14	12	8	28	31	68	71
T10–T11	17	15	13	16	27	30	74	70
L3–L4	12	12	14	18	38	35	78	79
L4–L5	17	13	16	17	45	52	85	81

Reactive astrocyte cell count performed on 5 μm thick sections from cervical, thoracic and lumbar spinal cord. Immunolabeling was done with antibodies against glial fibrillary acidic protein (GFAP, DAKO, Clone 62F, 1:100 dilution). Cell counts were performed by counting the total number of positive cells on the anterior and posterior horns of the left and right sides per cellular marker at 200× magnification.

2.2. Control patients

Control spinal cord autopsy material was obtained from four individuals. Control #1 was a 61-year-old Caucasian male that died from cardiac arrest. The autopsy was performed and the tissues collected 4.5 h after death. Control #2 was a 51-year-old Caucasian female that died of coronary artery disease. The autopsy was performed and the tissues collected 7 h after death. Control #3 was a 70-year-old Caucasian female that died of a ruptured aortic aneurism. The autopsy was performed and the tissues collected 8 h after death. Control #4 was a 31-year-old African American female that died of complications from heart transplant surgery while under

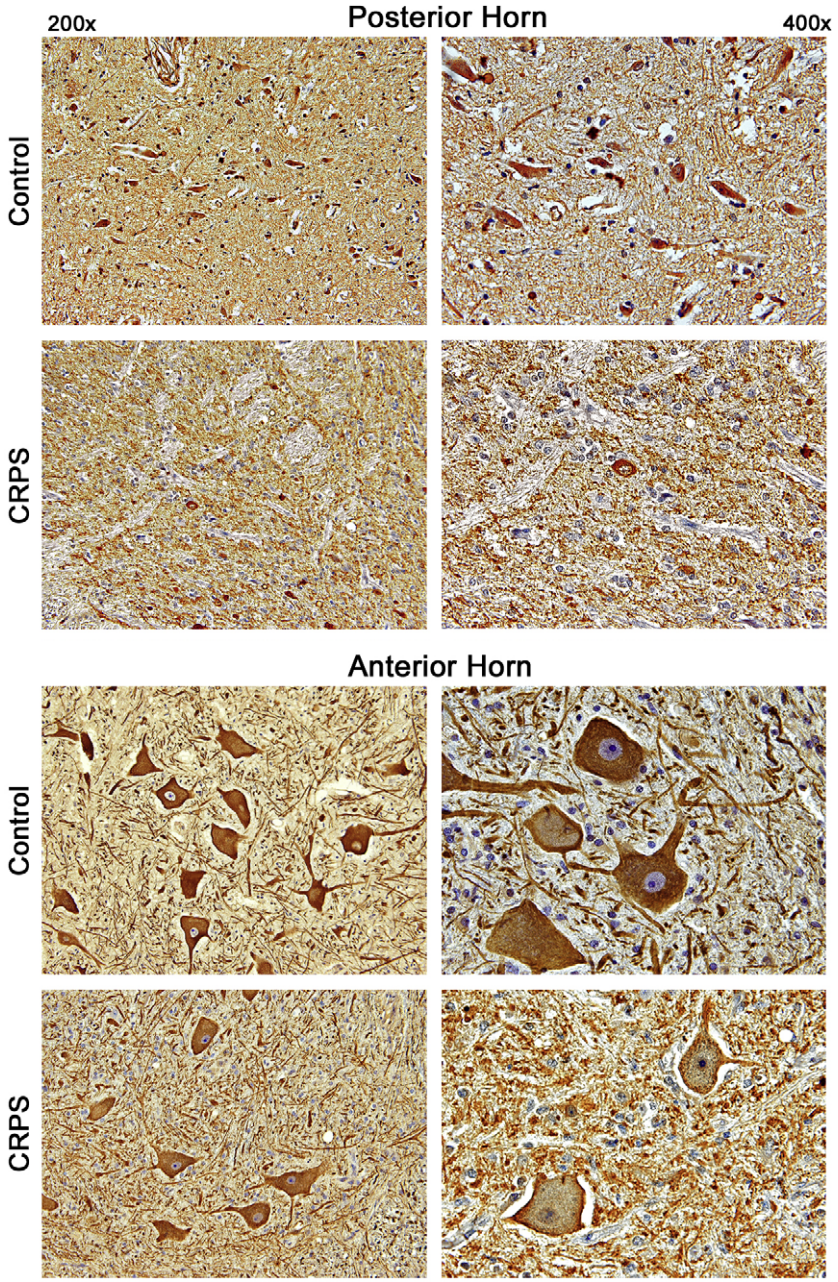

Fig. 1. Neurofilament (NF) positive cell loss in a case of CRPS. Immunohistochemistry for Neurofilaments (pan-neuronal SMI-311) demonstrates a significant lower number of neurons in the posterior horn of the CRPS case in comparison to the normal control case, especially at the lumbar levels. Although there seems to be a smaller number of motor neurons in the anterior horn, this change is much less pronounced (left panels original magnification 200×, right panels 400×).

standard chronic immunosuppressive therapy. The autopsy was performed and the tissues collected 17 h after death.

2.3. Histology and Immunohistochemistry

After extraction at autopsy, the spinal cords were fixed in 10% buffered formalin and embedded in paraffin. Sections of 5 μm in thickness from the cervical, thoracic and lumbar segments were cut and placed on electromagnetically charged glass slides. Hematoxylin and Eosin staining was performed for routine histological evaluation. Immunohistochemistry for specific cellular markers was performed using the avidin–biotin–peroxidase methodology, according to the manufacturer's instructions (Vectastain Elite Kit, Vector Laboratories, Burlingame, CA). Our modified protocol includes deparaffination in xylene, rehydration through descending grades of ethanol up to water, non-enzymatic antigen retrieval with 0.01 M sodium citrate buffer pH 6.0 for 30 min at 97 °C in a vacuum oven, and quenching of endogenous peroxidase with 3% H_2O_2 in methanol for 20 min. After rinsing with phosphate buffered saline (PBS), the sections were blocked with normal horse serum for mouse monoclonal and normal goat serum for rabbit polyclonal antibodies, and incubated with primary antibodies overnight at room temperature in a humidified chamber.

Antibodies utilized in this study included the following cellular markers: mouse monoclonal antibodies against glial fibrillary acidic protein (GFAP, DAKO, Clone 62F, 1:100 dilution), human CD-68 (Clone PG-M1, DAKO, 1:100 dilution) and an IgG1 pan-neuronal cocktail for neurofilaments (Sternberger Monoclonals Inc., Clone SMI-311, 1:1000 dilution). After thoroughly rinsing with PBS, sections were incubated with biotinylated secondary

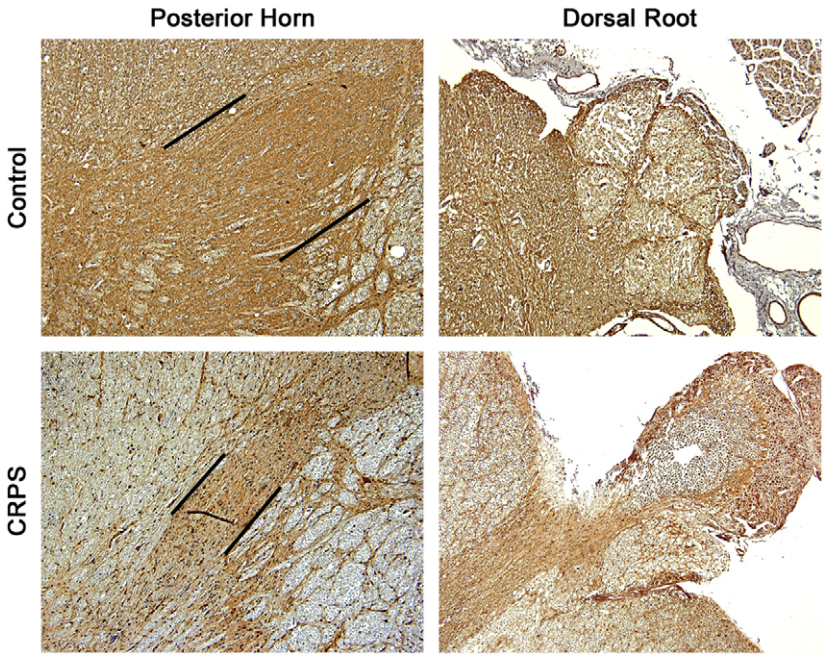

Fig. 2. Axonal loss in the posterior horn and root in a case of CRPS. In addition to the neuronal loss, there is a dramatic reduction in the size of the posterior horn and in the number of axons and diameter of the emerging root in the CRPS case in comparison with the normal control. Additional evidence of the neuronal loss is the presence of immunolabeled retracting axons in the posterior horn and the presence of vacuoles close to the emergence of the root. (All panels original magnification 100×.)

antibodies for 1 h, followed by incubation with avidin–biotin–peroxidase complexes (ABC Elite kit, Vector Laboratories) for 1 h at room temperature, and development with diaminobenzidine (Roche Applied Science) for 3 min. Finally, slides were counterstained with hematoxylin, dehydrated in ethanol, cleared with xylene and mounted with permount.

2.4. Cell counting

Consecutive sections from two spinal cord segments (cervical C5–C7 and lumbar L3–L5) for Controls #1 and #3, three segments (cervical C5–C7, thoracic T9–T11 and lumbar L3–L5) for Control #2 and six segments (cervical C5–C6 and C6–C7, thoracic T9–T10 and T10–T11 and lumbar L3–L4 and L4–L5) for Control #4 and the CRPS case were selected for immunolabeling of specific cellular phenotypes. Cell counts were performed by counting the total number of positive cells on the anterior and posterior horns of the left and right sides per cellular marker at 200× magnification. To corroborate our results, cells were counted again at a magnification of 100×. In case of a discrepancy, the procedure was repeated by manually counting cells per segment and marker. Negative cells (not immunolabeled) were not included in the counting despite their morphological characteristics. Tables 1–3 show the results from cell counts of specific phenotypes.

3. Results

The CRPS patient in this study demonstrated both increased glial activation and neuronal loss throughout the entire posterior horn of the spinal cord as compared to the control individuals. Neurofilament positive cells counts throughout the posterior horn were substantially decreased. The decrease was greatest in the left

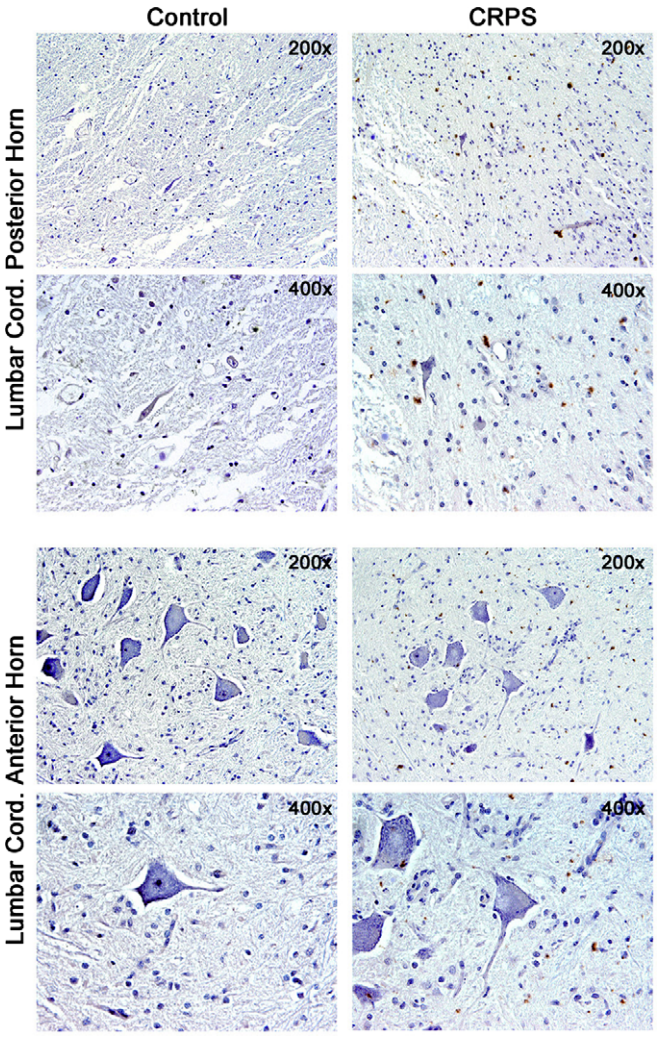

Fig. 3. Microglial cell activation in CRPS. Immunohistochemistry for CD-68 demonstrated an increased number of reactive cells in a case of CRPS in comparison to a normal control, particularly at the level of the posterior horn of lumbar segments.

lumbar (L3–4, L4–5) levels and least in the right cervical cord levels. Neurofilament positive cells in the anterior horn were relatively preserved at all levels (Fig. 1 and Table 1). Evidence for the neuronal damage and loss in the CRPS patient is demonstrated by the dramatic reduction in the size of the posterior horn and the number of axons as well as the decreased diameter of the emerging root in comparison with the normal control. Additional evidence is provided by the presence of immunolabeled retracting axons in the posterior horn and the presence of vacuoles close to the emergence of the root (Fig. 2).

CD-68 positive microglial cells were increased throughout the posterior horn of the entire spinal cord. There was a gradient of activation from lumbar to cervical cord with predominance to the left side. The greatest degree of activation was seen in the left lumbar segments (L3–4, L4–5) and least in the right cervical cord segments (Fig. 3 and Table 2).

There was a generalized increase of glial fibrillary acidic protein (GFAP) positive astrocytes throughout the spinal cord in both anterior and posterior horns, which indicates the activation of astrocytes as a response to tissue damage. The greater activation was noted in the lower lumbar cord L4–L5 with a slight left predominance. The lowest degree of activation was seen in the anterior horn at the cervical level (Fig. 4 and Table 3).

4. Discussion

The major findings of this study are that in longstanding CRPS there is significant microglial and astrocytic cell activation as well as neuronal loss in the posterior horn, most prominently at the level of the original injury (left gastrocnemius muscle, L4–S2 roots) but extending throughout the entire length of the spinal cord. There are several confounding factors for the observations in this study. The patient underwent radiofrequency neurolysis at (L4–L5) and had dorsal column stimulators (DCS) placed at both lumbar and cervical levels throughout the course of her illness. However, the neuronal cell loss was seen throughout the cord making it unlikely that neurolysis at L4–L5 or DCS at two levels would be responsible for cell loss and glial activation throughout the dorsal horn of the entire spinal cord.

In addition, the CRPS patient was on chronic opioid treatment. Chronic morphine administration has been shown to result in both astrocytic and microglial activation (Narita et al., 2004; Tawfik

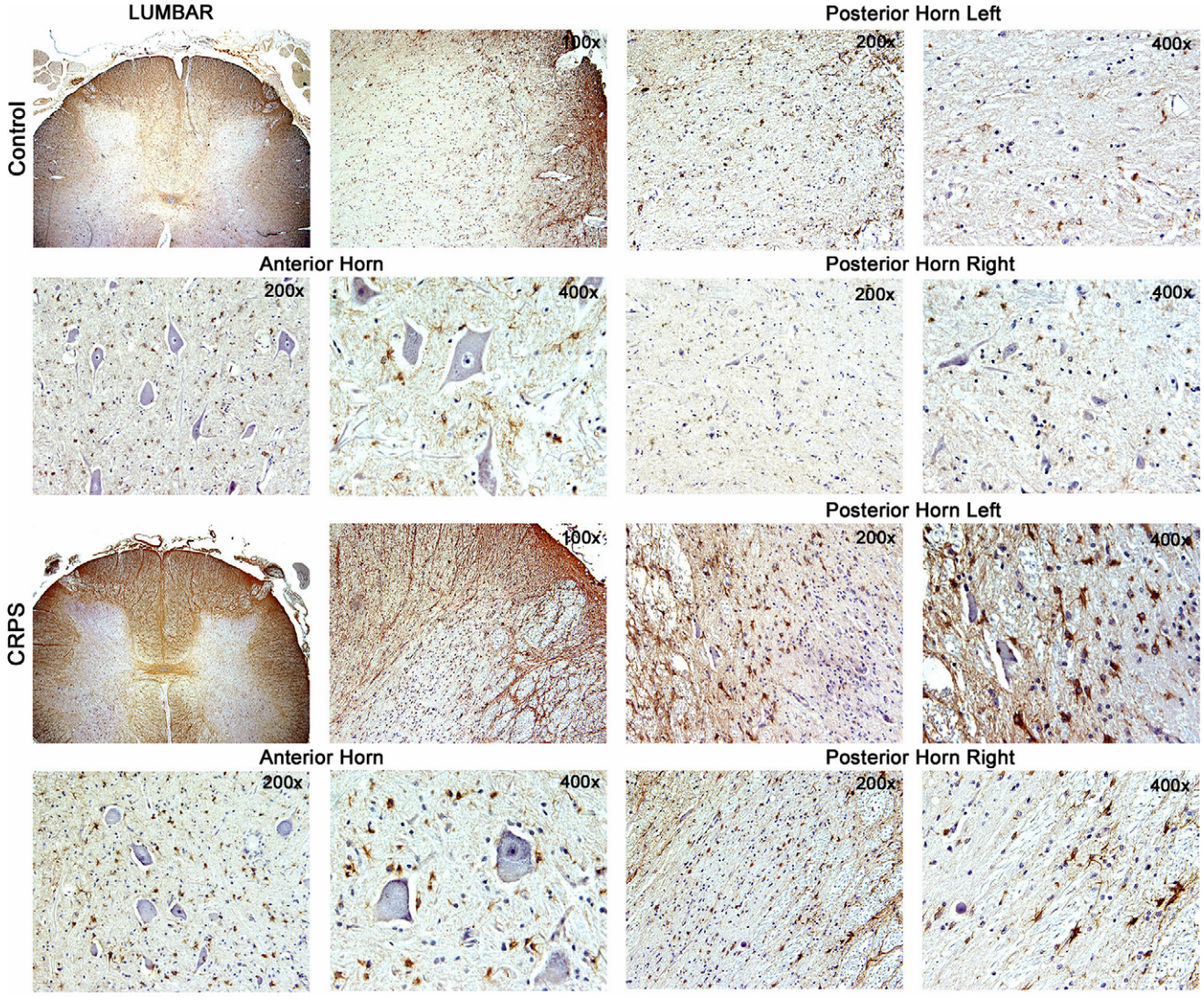

Fig. 4. Astrocytic activation in a case of CRPS: immunohistochemical experiments with a glial fibrillary acidic protein (GFAP) specific antibody revealed a significant elevation in the number of reactive astrocytes in the CRPS case. Although the astrocytic activation is observed in both the anterior and posterior horns of all segments, these changes are more robust in the left side of the posterior horn at the lumbar levels.

et al., 2005; Cui et al., 2008). Repeated morphine administration has also been shown to marginally exacerbate the glial activation seen following injury (Tawfik et al., 2005). We feel that the glial activation seen in the CRPS patient resulted mostly from her illness for several reasons. Glial activation seen following chronic morphine administration is restricted to the dorsal horn (Narita et al., 2004; Tawfik et al., 2005). In addition, chronic morphine administration should not show a side (right vs. left) or level (cervical vs. lumbar) preference. The CRPS patient showed astrocytic activation in both dorsal and ventral spinal cord and there was greater microglial and astrocytic activation on the side of the original injury (left lower extremity). Additionally, the patient demonstrated a gradient from lumbar to cervical of both astrocytic and microglial activation. Although chronic opioid treatment may have been an exacerbating factor, these facts support our finding that the microglial and astrocytic cell activation seen in the CRPS patient was predominantly a result of her illness.

There is clear neuronal loss throughout the dorsal horn of the spinal cord with the greatest loss in the left lumbar cord. This finding is in agreement with the reported loss of dorsal horn neurons in patients with post-herpetic neuralgia (Watson et al., 1988; Oaklander, 2008) and in rodent models of neuropathic pain (Whiteside and Munglani, 2001; Moore et al., 2002). Dorsal horn neuronal loss may be a contributing factor to the refractoriness of this patient's symptoms.

A possible mechanism for both symptom spread and neuronal loss is the activation of spinal cord microglial cells and astrocytes. Once activated, microglia and astrocytes secrete a number of substances known to excite dorsal horn neurons and influence the establishment and maintenance of neuropathic pain (Watkins and Maier, 2000). These substances include pro-inflammatory cytokines, nitric oxide, excitatory amino acids, prostaglandins and ATP (Wieseler-Frank et al., 2004; Abbadie, 2005; Marchand et al., 2005). We have previously shown that CRPS patients demonstrate elevated levels of pro-inflammatory cytokines (Alexander et al., 2005), as well as elevated glutamate and nitric oxide metabolites (Alexander et al., 2007) in their cerebrospinal fluid.

The findings from this study match the extensive data from animal models regarding glial activation and dorsal horn neuronal cell loss (Moore et al., 2002; Watkins and Maier, 2003).

However, this study has several limitations: (1) the patient underwent procedures and was receiving pain medications during the course of the illness that may have damaged neurons and activated glial cells and (2) this is a single case of CRPS and clearly more cases need to be studied and the results replicated.

Our hypothesis is that CRPS is not the result of a single pathway, but a complex syndrome in which several events take place. Activation of microglial cells with their inflammatory response may contribute to neuronal damage and loss, and the astrocytic activation and proliferation that follows may play a role in perpetuating the damage. Our hope is that the data obtained from this and other studies of autopsy material may aid in elucidating the mechanisms involved in the pathophysiology of CRPS, which may lead to the refinement of current therapies as well as novel treatments.

Acknowledgments

This study was supported by a grant from the Tilly Family Foundation.

References

Abbadie, C., 2005. Chemokines, chemokine receptors and pain. Trends Immunol. 26, 529–534.
Alexander, G.M., van Rijn, M.A., van Hilten, J.J., Perreault, M.J., Schwartzman, R.J., 2005. Changes in cerebrospinal fluid levels of pro-inflammatory cytokines in CRPS. Pain 116, 213–219.
Alexander, G.M., Perreault, M.J., Reichenberger, E.R., Schwartzman, R.J., 2007. Changes in immune and glial markers in the CSF of patients with complex regional pain syndrome. Brain Behav. Immun. 21, 668–676.
Calder, J.S., Holten, I., McAllister, R.M., 1998. Evidence for immune system involvement in reflex sympathetic dystrophy. J. Hand Surg. [Br.] 23, 147–150.
Cui, Y., Liao, X.X., Liu, W., Guo, R.X., Wu, Z.Z., Zhao, C.M., Chen, P.X., Feng, J.Q., 2008. A novel role of minocycline: attenuating morphine antinociceptive tolerance by inhibition of p38 MAPK in the activated spinal microglia. Brain Behav. Immun. 22, 114–123.
Harden, R.N., Bruehl, S., Stanton-Hicks, M., Wilson, P.R., 2007. Proposed new diagnostic criteria for complex regional pain syndrome. Pain Med. 8, 326–331.
Ishikawa, K., Tanaka, M., Black, J.A., Waxman, S.G., 1999. Changes in expression of voltage-gated potassium channels in dorsal root ganglion neurons following axotomy. Muscle Nerve 22, 502–507.
Janig, W., Baron, R., 2003. Complex regional pain syndrome: mystery explained? Lancet Neurol. 2, 687–697.
Kreutzberg, G.W., 1996. Microglia: a sensor for pathological events in the CNS. Trends Neurosci. 19, 312–318.
Maleki, J., LeBel, A.A., Bennett, G.J., Schwartzman, R.J., 2000. Patterns of spread in complex regional pain syndrome, type I (reflex sympathetic dystrophy). Pain, 259–266.
Marchand, F., Perretti, M., McMahon, S.B., 2005. Role of the immune system in chronic pain. Nat. Rev. Neurosci. 6, 521–532.
Matzner, O., Devor, M., 1994. Hyperexcitability at sites of nerve injury depends on voltage-sensitive Na+ channels. J. Neurophysiol. 72, 349–359.
Moore, K.A., Kohno, T., Karchewski, L.A., Scholz, J., Baba, H., Woolf, C.J., 2002. Partial peripheral nerve injury promotes a selective loss of GABAergic inhibition in the superficial dorsal horn of the spinal cord. J. Neurosci. 22, 6724–6731.
Narita, M., Suzuki, M., Narita, M., Yajima, Y., Suzuki, R., Shioda, S., Suzuki, T., 2004. Neuronal protein kinase C gamma-dependent proliferation and hypertrophy of spinal cord astrocytes following repeated in vivo administration of morphine. Eur. J. Neurosci. 19, 479–484.
Oaklander, A.L., 2008. Mechanisms of pain and itch caused by herpes zoster (shingles). J. Pain 9 (Suppl. 1), 10–18.
Siviloti, L., Woolf, C.J., 1994. The contribution of GABAA and glycine receptors to central sensitization: disinhibition and touch-evoked allodynia in the spinal cord. J. Neurophysiol. 72, 169–179.
Tawfik, V.L., LaCroix-Fralish, M.L., Nutile-McMenemy, N., DeLeo, J.A., 2005. Transcriptional and translational regulation of glial activation by morphine in a rodent model of neuropathic pain. J. Pharmacol. Exp. Ther. 313, 1239–1247.
Tsuda, M., Inoue, K., Salter, M.W., 2005. Neuropathic pain and spinal microglia: a big problem from molecules in "small" glia. Trends Neurosci. 28, 101–107.
Watkins, L.R., Maier, S.F., 2000. The pain of being sick: implications of immune-to-brain communication for understanding pain. Annu. Rev. Psychol. 51, 29–57.
Watkins, L.R., Maier, S.F., 2003. Glia: a novel drug discovery target for clinical pain. Nat. Rev. Drug Discov. 2, 973–985.
Watkins, L.R., Maier, S.F., 2005. Immune regulation of central nervous system functions: from sickness responses to pathological pain. J. Intern. Med. 257, 139–155.
Watkins, L.R., Milligan, E.D., Maier, S.F., 2001. Glial activation: a driving force for pathologic pain. Trends Neurosci. 24, 450–455.
Watson, C.P., Morshead, C., Van der Kooy, D., Deck, J., Evans, R.J., 1988. Post-herpetic neuralgia: post-mortem analysis of a case. Pain 34, 129–138.
Waxman, S.G., Dib-Hajj, S., Cummins, T.R., Black, J.A., 1999. Sodium channels and pain. Proc. Natl. Acad. Sci. USA 96, 7635–7639.
Waxman, S.G., Cummins, T.R., Dib-Hajj, S.D., Black, J.A., 2000. Voltage-gated sodium channels and the molecular pathogenesis of pain: a review. J. Rehabil. Res. Dev. 37, 517–528.
Whiteside, G.T., Munglani, R., 2001. Cell death in the superficial dorsal horn in a model of neuropathic pain. J. Neurosci. Res. 64, 168–173.
Wieseler-Frank, J., Maier, S.F., Watkins, L.R., 2004. Glial activation and pathological pain. Neurochem. Int. 45, 389–395.
Woolf, C.J., Salter, M.W., 2000. Neuronal plasticity: increasing the gain in pain. Science 288, 1765–1769.