

STILL TECHNIQUE FOR COMMON COUNTERSTRAIN TENDER POINTS

KELLEY JOY, DO
CLINICAL ASSOCIATE PROFESSOR
OSTEOPATHIC MANIPULATIVE MEDICINE
KCU – JOPLIN CAMPUS

COUNTERSTRAIN HISTORY

- Lawrence "Larry" Jones, DO
- 1955 Posterior tender points
- Anterior tender points
- 1964 "Spontaneous Release by Positioning"
- 1980 *Strain and Counterstrain*

COUNTERSTRAIN DEFINITION

- A system of diagnosis and treatment developed by Lawrence Jones, DO that considers the dysfunction to be a continuing, inappropriate strain reflex, which is inhibited by applying a position of mild strain in the direction exactly opposite to that of the false strain reflex; this is accomplished by the use of the specific point of tenderness related to this dysfunction followed by specific directed positioning to achieve the desired therapeutic response.

STILL TECHNIQUE HISTORY

- A.T. Still, MD, DO, Visionary
- Anatomy, Anatomy, Anatomy – Then fix it!
- Still Technique lost – easier to teach HV/LA
- Still Technique “Rediscovered” by Richard Van Buskirk
 - Reading Charles Hazzard, DO

STILL TECHNIQUE DEFINITION

- Characterized as a specific, non-repetitive articulatory method that is indirect, then direct.

STILL TECHNIQUE VIDEO

Play

Dr. A. T. Still in his 86th year
lecturing and demonstrating
osteopathic treatment to the
students.

CERVICAL REGION

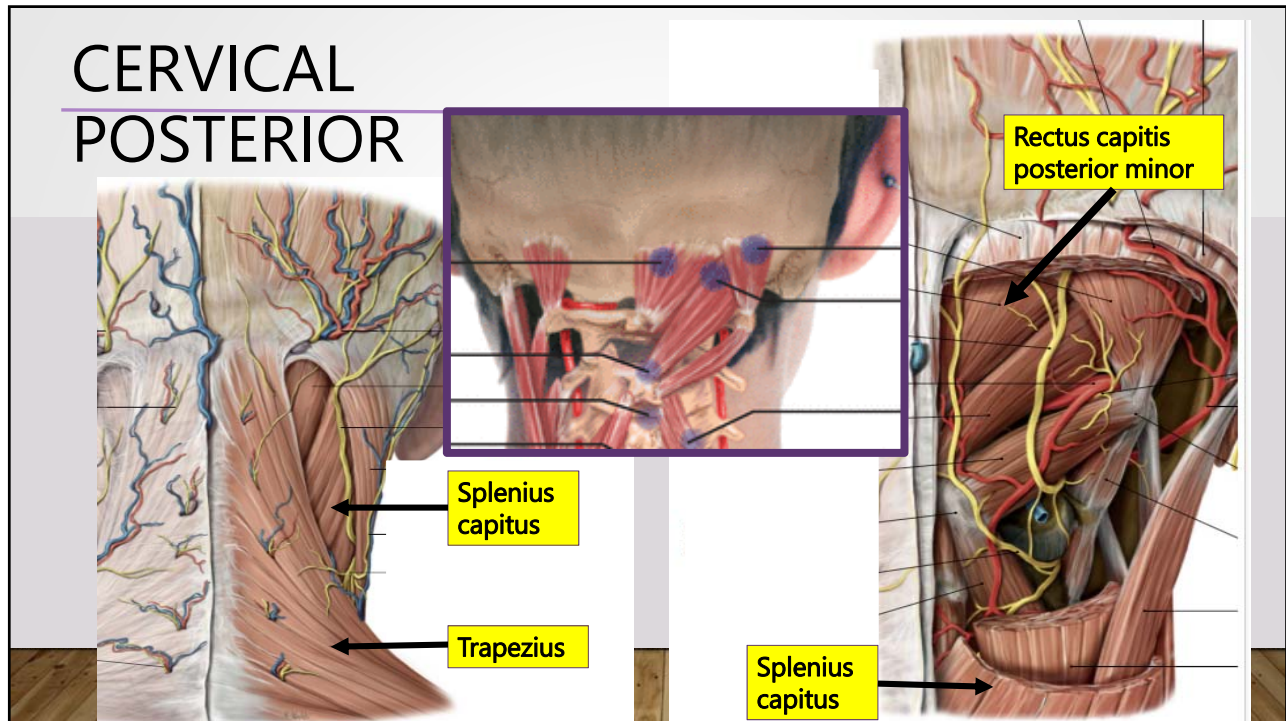
Posterior

- Trapezius
- Rectus Capitis Posterior/Superior
- Splenius Capitis


Anterior

- Scalenes

CERVICAL POSTERIOR



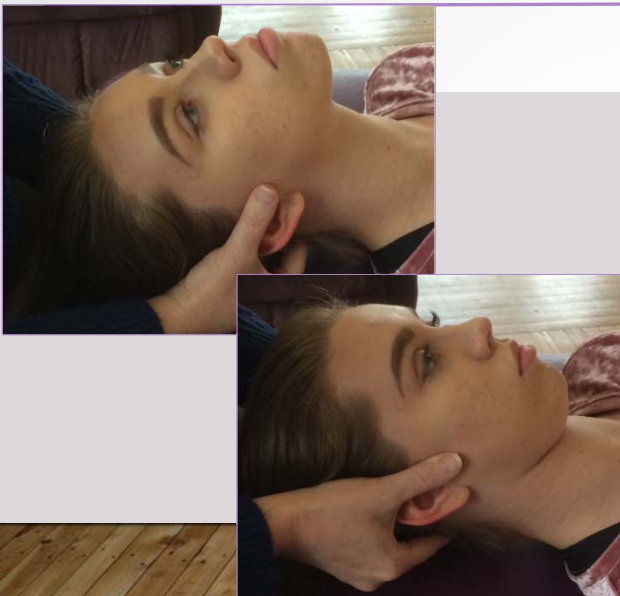
TRAPEZIUS



1. Place sensing finger at the trapezius origin at the base of the occiput
2. Lift the head and introduce traction
3. Slightly extend the head
4. Maintaining traction force, move the head into flexion, sidebending away from tender point
5. Remove traction and return to neutral
6. Reassess


Bonus: Also treats semispinalis capitus

RECTUS CAPITIS



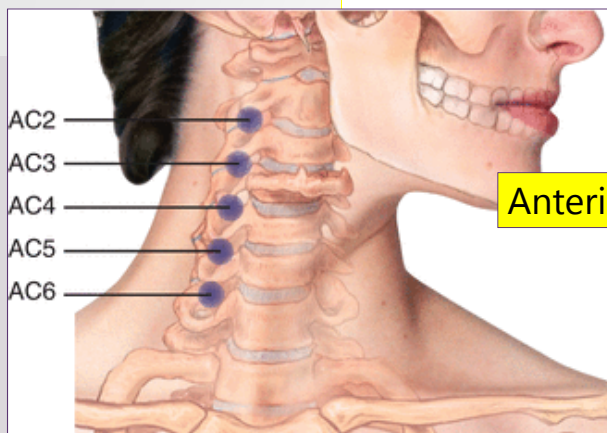
1. Index or middle fingers are placed below the basiocciput
2. Flex the basiocciput until relaxation is felt under the fingers
3. Induce traction toward the area of the posterior foramen magnum
4. Maintaining traction, extend the occiput posteriorly around the fingers
5. Remove traction.
6. Reassess.

SPLЕНИUS CAPITIS



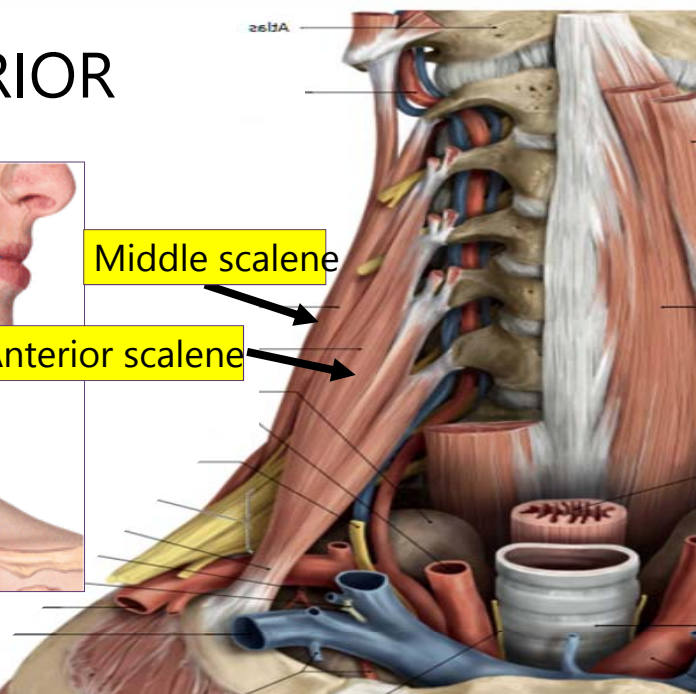
1. Sensing finger is posterior and medial to the mastoid body
2. Operating hand cups theinion
3. Extend the head, sidebending toward the tender point and rotating away
4. Induce traction and move the head and neck into flexion, then rotate the head toward the tender point
5. Release traction and return to neutral
6. Reassess

CERVICAL ANTERIOR

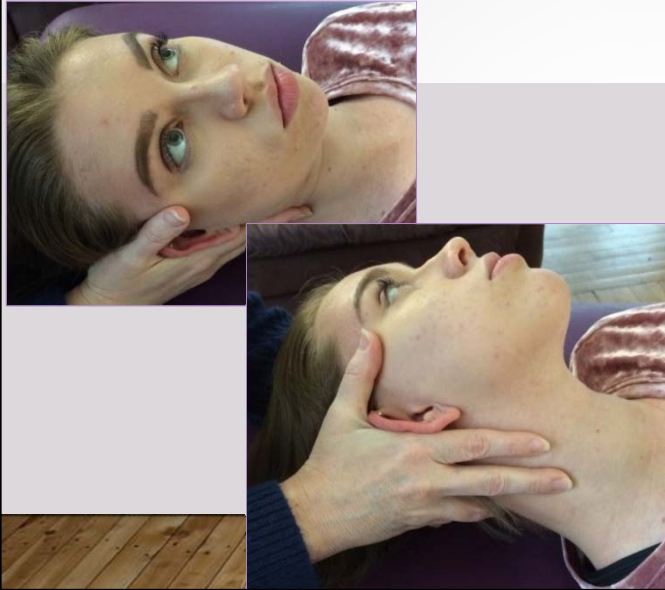

Middle scalene

Anterior scalene



MIDDLE SCALENE

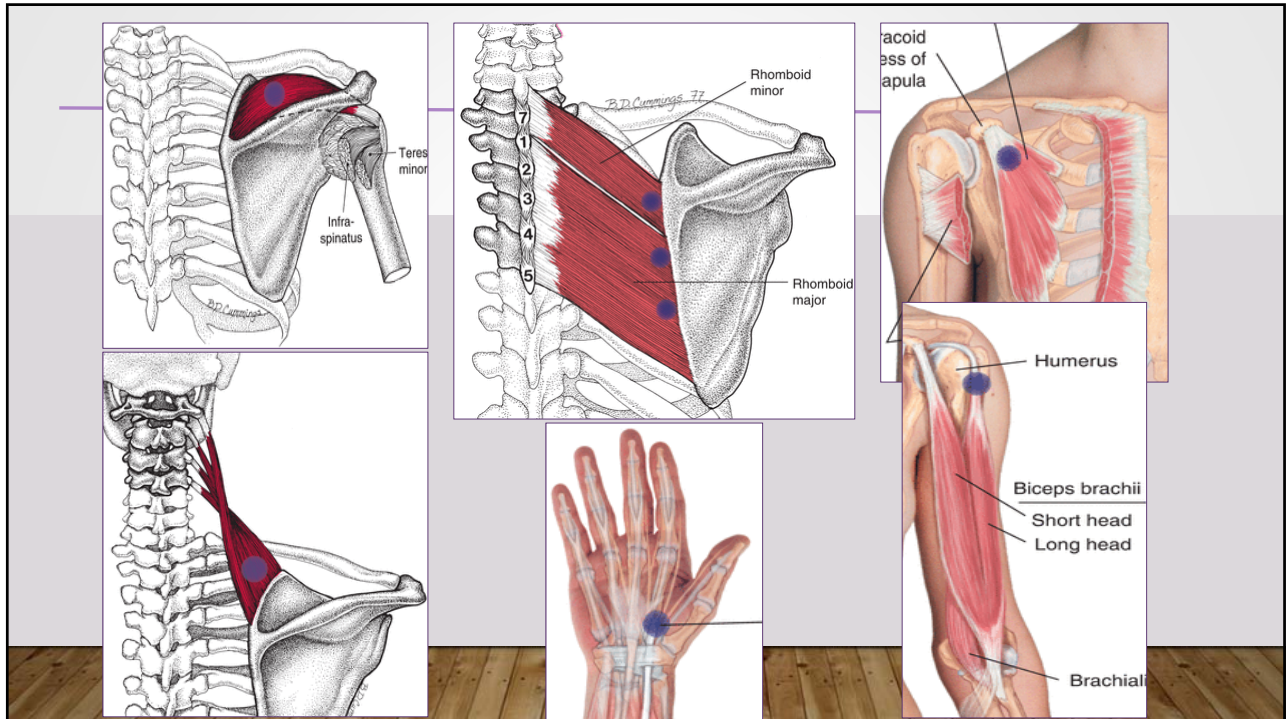
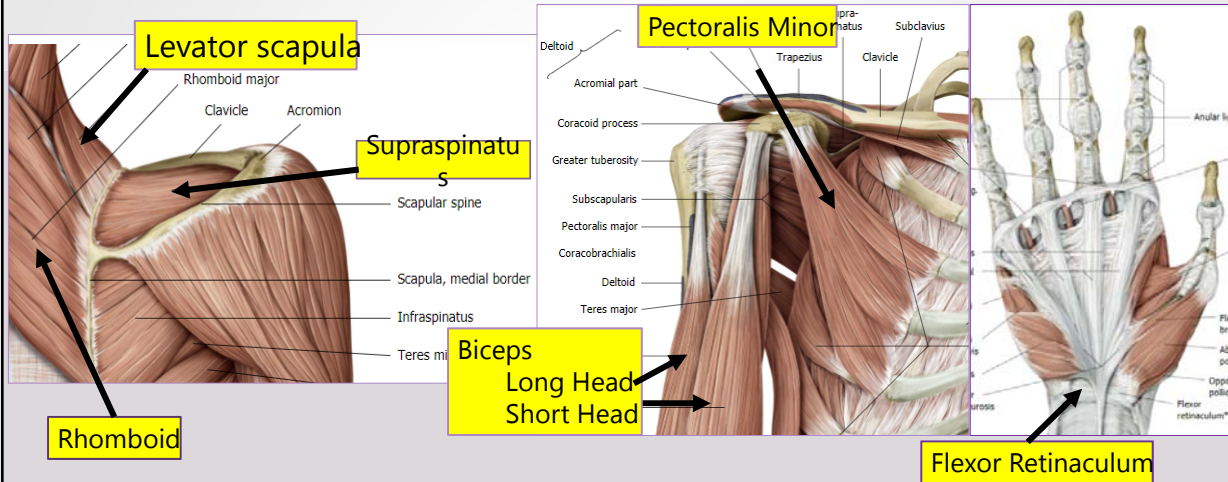


1. Sensing finger is placed on the posterior lateral shaft of the first rib
2. Sidebend head and neck toward the tender point
3. Operating hand compresses toward the tender point
4. Sidebend the head and neck away from the tender point
5. Return the head and neck to neutral
6. Reassess.

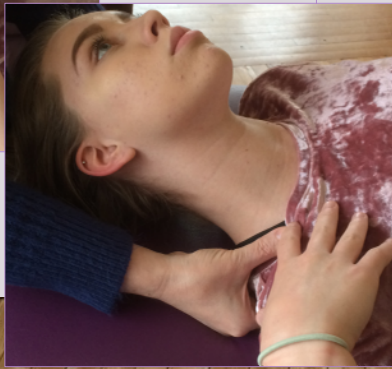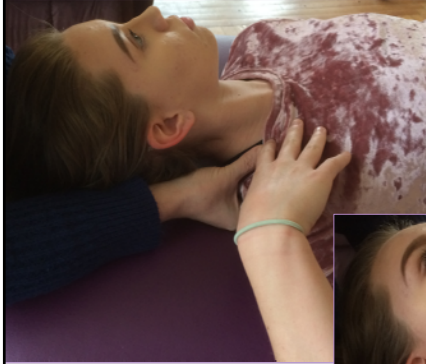UPPER EXTREMITY REGION

- Levator Scapula
- Supraspinatus
- Biceps tendon
- Pectoralis minor
- Rhomboid
- Carpal Tunnel Release

UPPER EXTREMITY - POSTERIOR




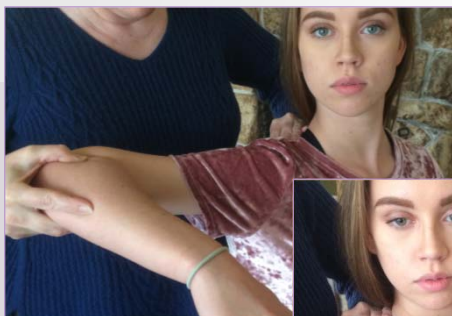
LEVATOR SCAPULA



1. Abduct ipsilateral arm, flex the elbow.
2. Sensing finger is placed over the superior medial border of the scapula.
3. Operating hand cups the upper neck and basiocciput.
4. Rotate the patients head and neck away from the tender point. Extend the neck and slightly sidebend toward the tender point.

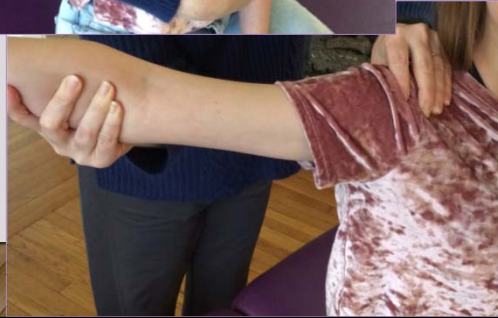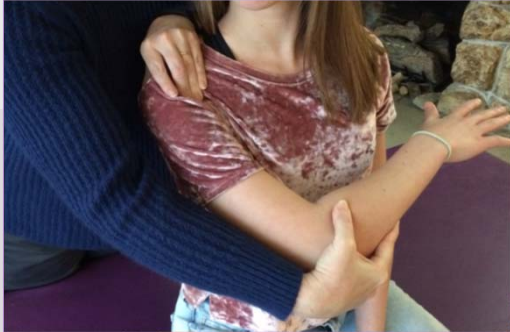Introduce traction and move the patient's neck into flexion, sidebending away, rotation toward the tender point. Release traction and return to neutral. Reassess.

SUPRASPINATUS



1. Sensing hand stabilizes the acromion with a finger on the supraspinatus.
2. Operating hand is on the elbow of the affected side.
3. Position the elbow at full shoulder abduction.
4. Introduce compression from the elbow to the supraspinatus muscle belly.
5. Take the arm inferiorly across the body into abduction (elbow should be near the umbilicus).
6. Release compression and return to neutral.
7. Reassess.

BICEPS TENDON



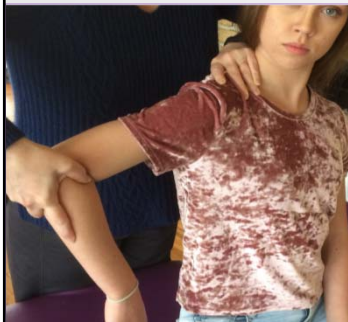1. Sensing finger is placed on the bicipital notch.
2. Operating hand is on the forearm of the affected side.
3. Adduct the arm, flex the elbow.
4. Introduce traction.
5. Abduct the shoulder and extend the elbow.
6. Release traction and return to neutral.
7. Reassess.

PECTORALIS MINOR



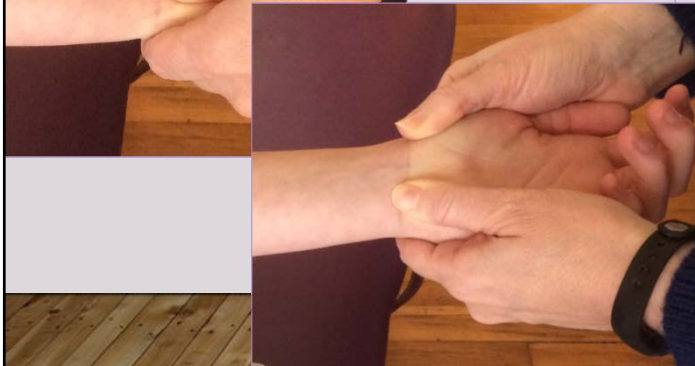
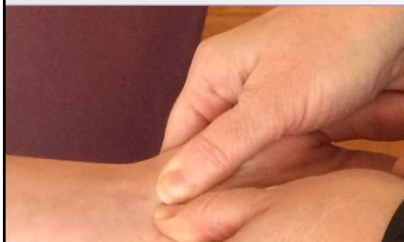1. Sensing finger is placed on the coracoid process.
2. Operating hand encircles the patient's forearm.
3. Arm is slightly flexed, then adducted.
4. Compress toward the coracoid.
5. Flex the arm, placing the elbow near the ear.
6. Release compression and return to neutral.
7. Reassess.

RHOMBOID



1. Sensing hand is on the rhomboid tender point. The rest of the hand stabilizes the shoulder.
2. Operating hand is on the ipsilateral elbow.
3. Extend the arm with the elbow flexed.
4. Introduce compression toward the rhomboid.
5. Flex and abduct the arm.
6. Release compression and return to neutral.

CARPAL TUNNEL

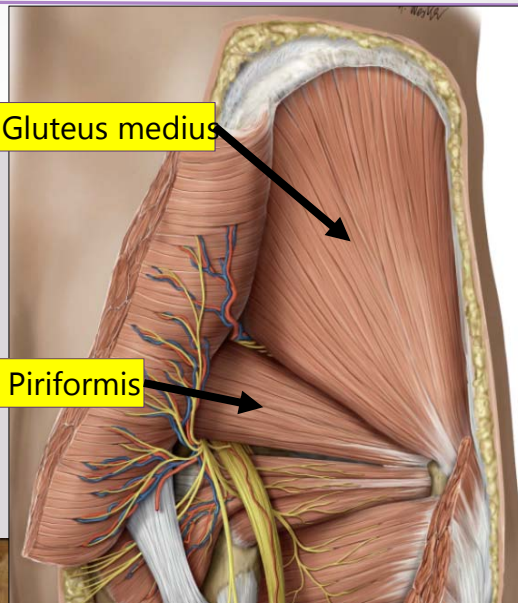
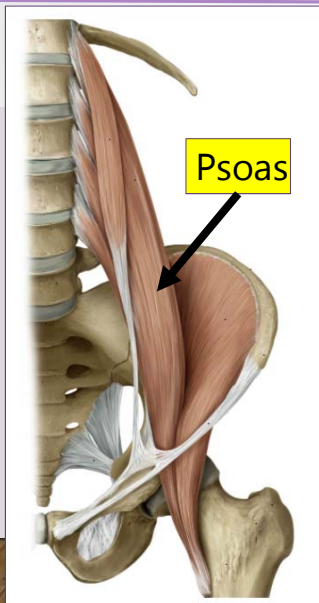


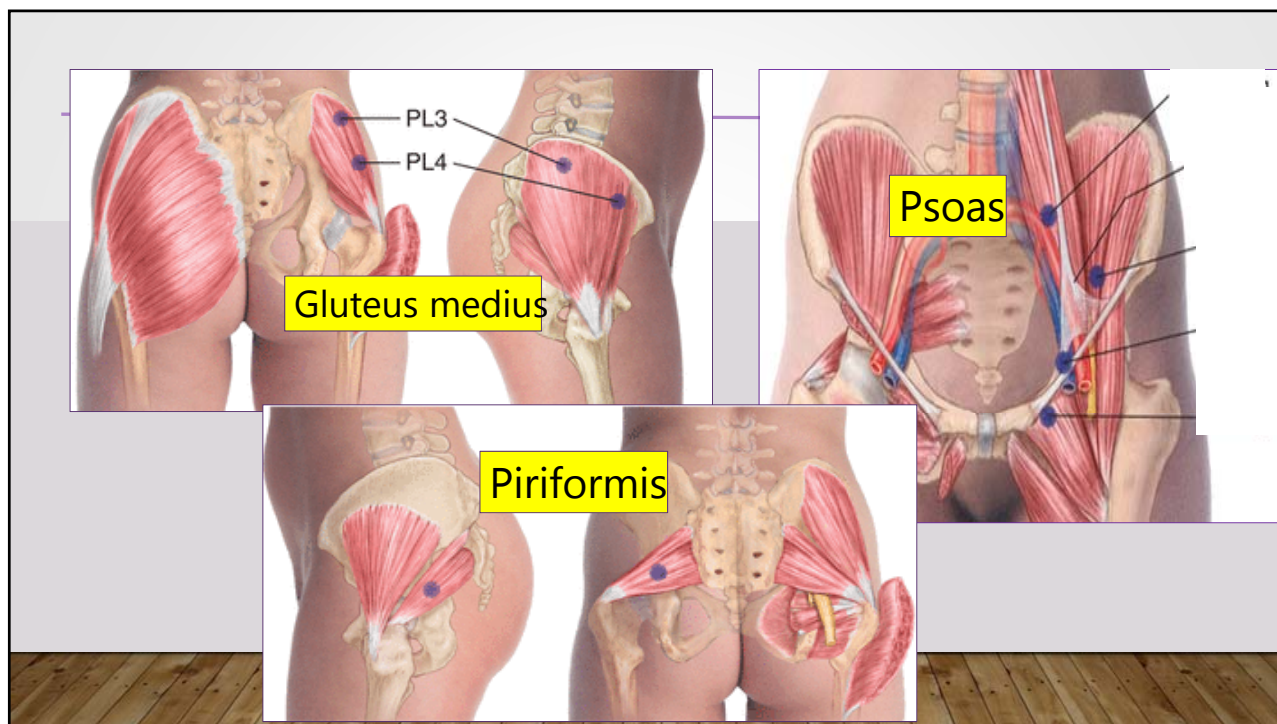
1. Both hands will be operating hands.
2. Grasp the patient's thenar and hypothenar eminences with your thumbs on the palmar surfaces.
3. Fold the eminences toward the palmar midline.
4. Introduce compression from both hands toward the carpal tunnel. Simultaneously externally rotate the thenar and hypothenar eminences. Release compression and return to neutral. Reassess.

LOW BACK & PELVIS REGION

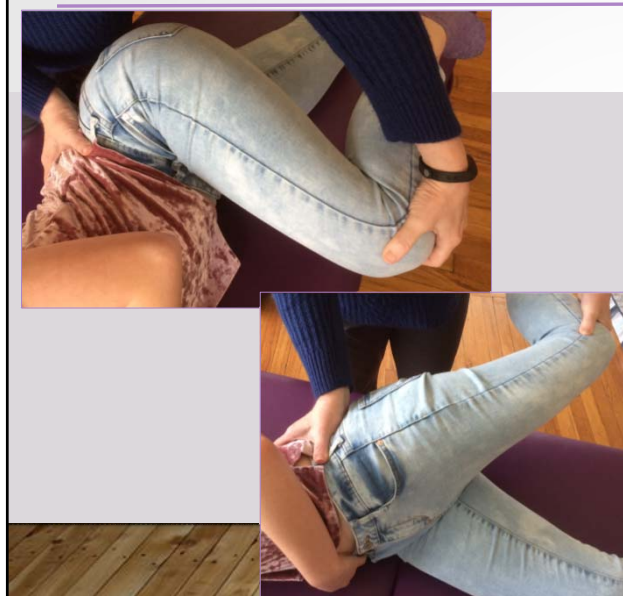
- Quadratus lumborum
- Psoas
- Gluteus medius
- Piriformis

LOWER BACK REGION



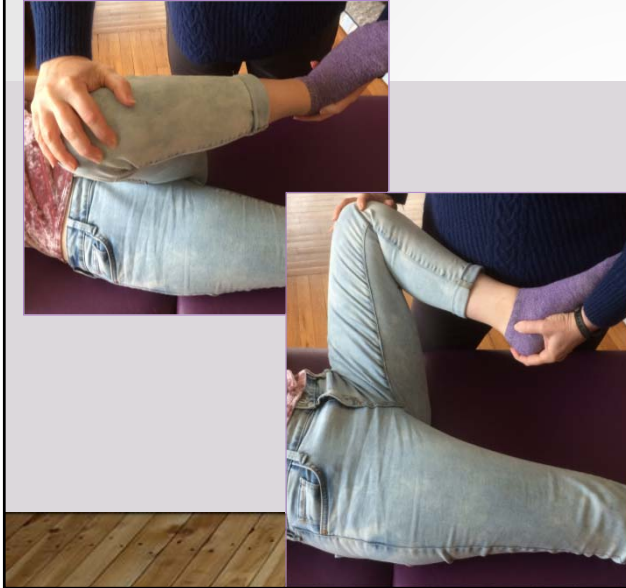

PSOAS



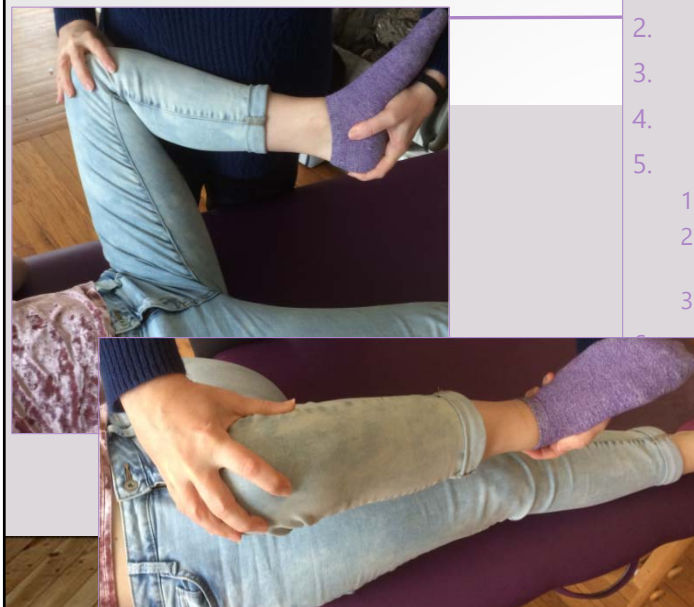
1. Sensing hand is on the transverse process of L2, the remainder of the hand stabilizes the lower spine and upper pelvis.
2. Operating hand is placed on the flexed knee.
3. Introduce compression through the patient's knee toward the sensing finger.
4. Bring the knee posteriorly and inferiorly with mild abduction, taking the hip into extension.
5. Release compression and return to neutral.

GLUTEUS MEDIUS



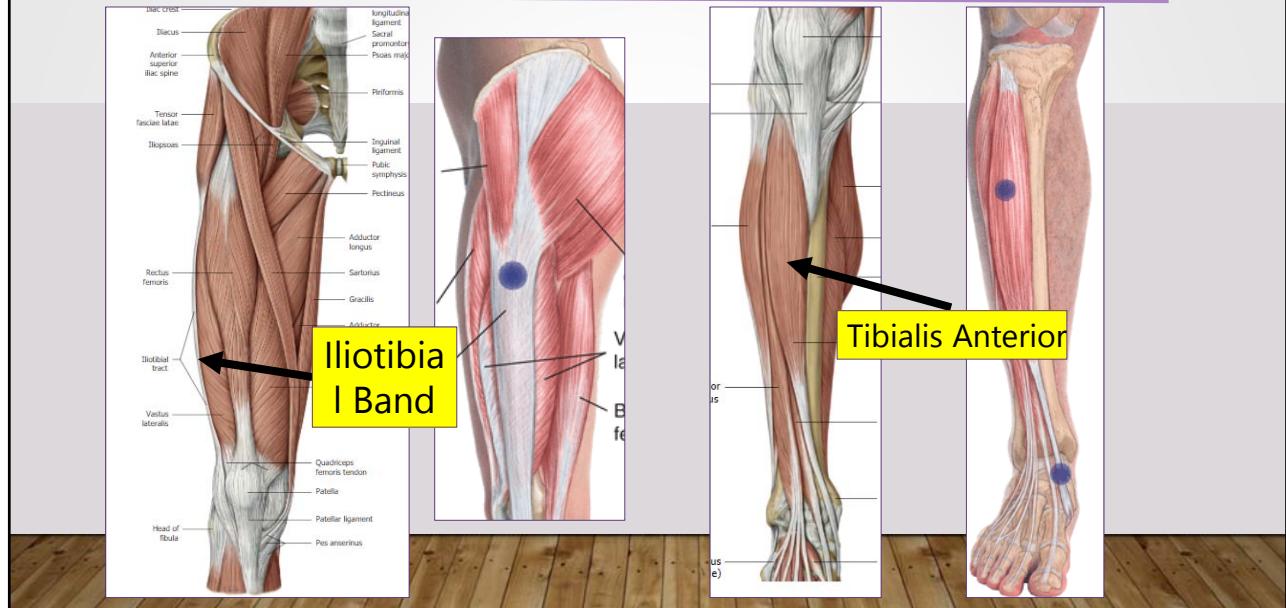
1. Sensing hand is placed under the patient at the gluteus medius tender point.
2. Operating hand 1 (caudal) is placed at the ankle.
3. Hip is flexed to ~100 degrees and adducted with slight external rotation.
4. Sensing hand is placed on the knee and becomes operating hand 2.
5. Compression through the knee toward the gluteus medius.
 - a. Bring the ankle laterally, inducing internal rotation.
 - b. Abduct the knee to about 60 degrees.
 - c. Extend the patient's knee.
6. Remove compression and return to neutral.

PIRIFORMIS



1. Sensing finger is at the tender point on the piriformis.
2. Caudal hand grasps the ankle.
3. Flex, abduct, and externally rotate the hip.
4. Place the cephalad hand on the knee.
5. Introduce compression toward the piriformis.
 1. Leading with the ankle, induce adduction.
 2. When the hip is fully adducted, internally rotate by abducting the ankle.
 3. Extend the knee toward neutral.
- Remove compression when the knee is at 45 degrees and return to neutral.
- Reassess.

LOWER EXTREMITY REGION



LOWER EXTREMITY REGION

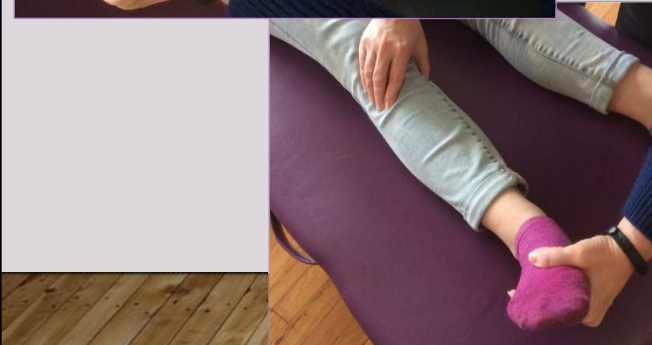
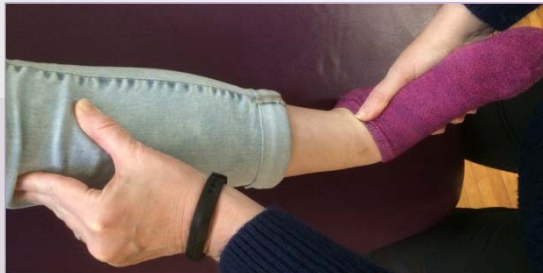- Iliotibial band
- Tibialis anterior

ILIOTIBIAL BAND



1. Sensing finger on the tender point of the iliotibial band
2. Operating hand grasps the ipsilateral ankle.
3. Abduct the leg until tenderness under the hand is diminished to <70%.
4. Introduce compression toward the tender point.
5. Adduct the leg to slightly past midline, adding slight flexion of the knee.
6. Release compression and return to

TIBIALIS ANTERIOR



1. Sensing finger is on the origin of the Tibialis anterior.
2. Operating hand grasps the patient's foot.
3. Place the patient's foot in supination and dorsiflexion.
4. Introduce compression towards the sensing finger.
5. Move the patient's foot into pronation and plantar flexion.
6. Release compression and return to neutral.
7. Reassess.

REFERENCES

- Nicholas, Alexander and Nicholas, Evan. Atlas of Osteopathic Techniques, 3rd Edition. Wolters Kluwer. 2016.
- Gilroy, MacPherson, Ross, Schunke, Schulte, Schumacher, Baker. *Gilroy Atlas of Anatomy, 3rd Edition*. Thieme Medical Publishers, Inc. 2018.
- Van Buskirk, Richard L, DO, PhD, FAAO. *The Still Technique Manual*. Fall, 2016.

THANK YOU

- Thank you to my daughter, Rose, and my husband, Micah for help with the pictures.