

Surgical Removal of a Radicular Cyst in a Thirteen Year Old Border Collie

Brett Beckman, DVM, FAVD, DAVDC, DAAPM
Affiliated Veterinary Specialists, Orlando, Florida
Florida Veterinary Dentistry and Oral Surgery, Punta Gorda, Florida
Animal Emergency Center of Sandy Springs, Atlanta, GA
www.veterinarydentistry.net
veterinarydentistry@gmail.com

Introduction:

Radicular cysts represent the most common type of oral cyst in humans(1,2) but have been reported infrequently in dogs and cats.(1,3) Radicular cysts are associated with inflammation of the periodontal ligament at the root apex whereas the more common dentigerous cyst is not.(4) Radicular cysts are commonly referred to as apical periodontal cysts(5). An additional periodontal cyst is described based on its location to the root and termed a lateral periodontal cyst.(6) The following is a case report describing the diagnosis and surgical excision of a large radicular cyst in a thirteen year old Border Collie.

History:

A thirteen year old twenty eight kilogram male neutered Border Collie presented for routine annual examination in May 2002. Dental cleaning had been performed routinely throughout the life of the patient. No other relevant history existed.

Diagnostics:

Physical examination of the patient was within normal limits. Oral examination revealed a gingivitis index of I, a calculus index of I, and a plaque index of I. A subtle swelling was present in the maxilla apical to the gingival margin adjacent to the maxillary left first (201) and second (202) incisors extending to the mucogingival line. (Figure 1) The swelling was firm and no pain was associated with palpation. No additional abnormalities were present. The patient was admitted for dental radiography of the swollen area and dental cleaning pending an appropriate pre-anesthetic evaluation.

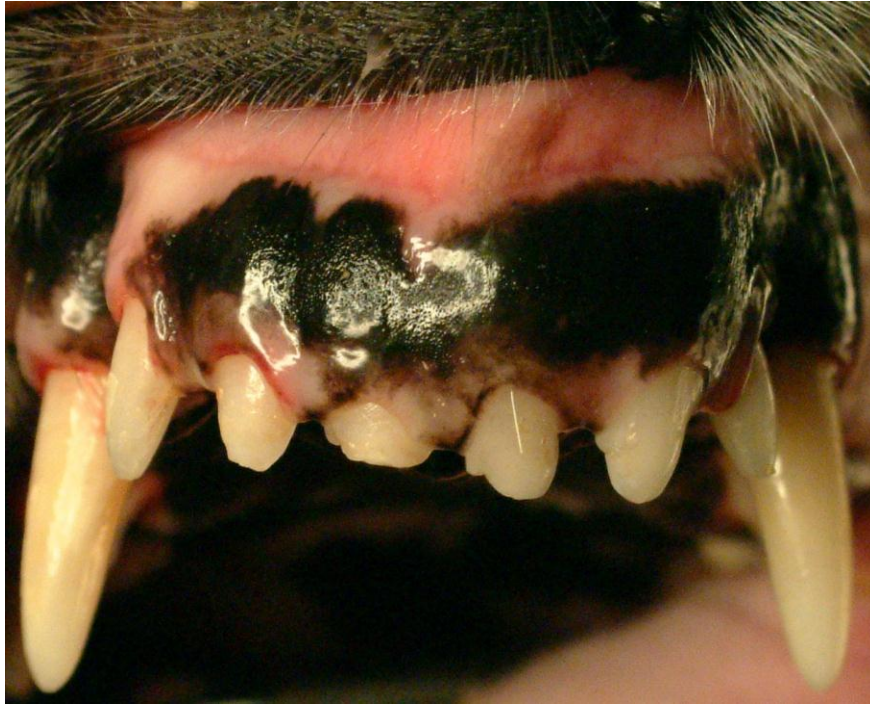

Figure 1

A swelling was present in the maxilla apical to the gingival margin adjacent to teeth 201 and 202. Teeth 101, 102 and 202 show fractures in this view.

The differential diagnosis for this mass included abscess, cyst, neoplasia, fibrous bone dysplasia and other fibrous bone lesions.⁽⁶⁾ Abscess was least likely due to the absence of discomfort upon palpation. Neoplasia was considered to be most likely due to the age of the patient.

Pre-anesthetic blood testing included a complete blood count, serum chemistry profile, urinalysis and EKG. EKG^a analysis showed a normal sinus rhythm, normal complexes and a heart rate of 120. CBC, serum chemistry profile and urinalysis were normal. Mucous membrane color, capillary refill time, pulse and chest auscultation were all within normal limits.

Butorphanol^b (8 mg IM) was given thirty minutes pre-operatively and a twenty gauge intravenous catheter^c placed in the right cephalic vein. General anesthesia was induced with ketamine^d (140 mg IV) and valium^e (5.6 mg IV). The patient was intubated with an 8.0 mm cuffed endotracheal tube^f and the cuff was gently inflated. The animal was maintained with isoflurane^g (2.0-2.5%) and oxygen (2.5 L/min) using a semi-closed anesthetic delivery system,^h placed on a water circulated heating padⁱ and leads for the EKG^a monitor positioned. A warmed

balanced electrolyte solution^j was administered at 10 ml/kg/hr. Temperature, respiration, pulse and capillary refill time were regularly taken and recorded by a technician.

A complete oral examination was performed and abnormalities noted on the dental chart. In addition to the changes discovered during the initial oral examination slight bleeding was present upon probing the palatal aspect of 104. All pocket depths were within normal limits. A Class VI, Stage 2 fracture (7) of the maxillary right first incisor (101) was present. The maxillary right second (102) incisor, 201, and 202 had Class VI, Stage 1 (7) fractures. Slight mobility was associated with 202. Owner inquiry revealed that the incisor fractures were likely induced by Frisbee play when the patient was a young adult.

The oral cavity was thoroughly rinsed with 0.12 % chlorhexidine^k solution. Complete supragingival and subgingival scaling^l was performed. The teeth were polished using a disposable prophylaxis angle^m on a slow speed handpieceⁿ and polishing paste^o. The oral cavity was rinsed thoroughly with saline followed again by 0.12 % chlorhexidine^k solution.

Dental radiographs^p were taken of the affected area. Radiography showed a large lucency expanding from the maxillary bone in the mesial apical region of 201 coursing along the midline of the rostral maxilla two centimeters in a caudal direction, rounding to course rostrally and terminating at the distal aspect of the apex of 202.(Figure 2) A soft tissue density was present within the silhouette of the lucency. This density was adjacent to the distal aspect of the root of 201, surrounding 202 and adjacent to the mesial aspect of the maxillary left third incisor (203). The interradicular space between 201 and 202 was increased compared to the contralateral side. The distal aspect of 201 and the mesial aspect of 202 showed evidence of external resorption.

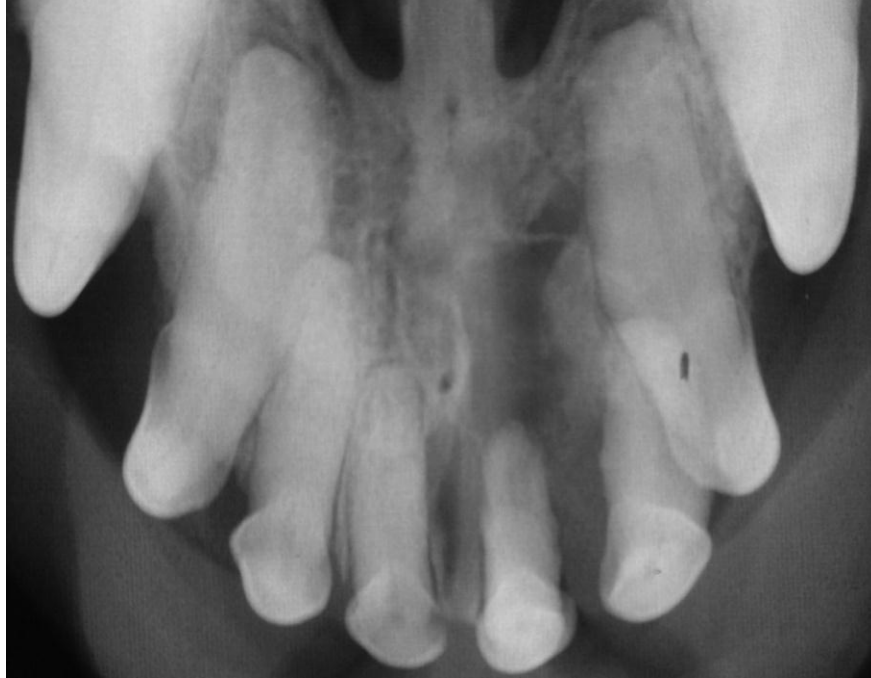

Figure 2

A lucency is seen in the maxillary bone mesial to tooth 201 coursing along the midline and terminating at the distal aspect of the apex of tooth 202. Root resorption is present on the distal aspect of tooth 201 and the mesial aspect of tooth 202.

The above findings were relayed to the owner who gave permission for biopsy and probable extraction of 202 to gain access to the center of the defect. Reentry and extraction of 201 and 203 pending biopsy findings were likely and discussed with the owner. The most likely causes of this radiographic presentation were cyst, neoplasia or both.

The patient was placed in dorsal recumbency. A left infraorbital nerve block was performed by injecting bupivacaine^q (2.5 mg) using a tuberculin syringe and a 25 gauge 1 inch needle^r at the entrance to the left infraorbital canal and holding digital pressure over the area for sixty seconds. Aspiration to confirm that the needle was not placed intravascularly was performed prior to injection. A 15 Bard Parker blade^s on a No. 7 scalpel handle^t was used to make two divergent vertical releasing incisions starting at the line angles of 201 and the maxillary left third incisor (203) extending one half centimeter beyond the mucogingival junction.(Figure 3) The releasing incisions were connected by an interproximal incision incorporating the buccal sulcus of 202. An EX-7^u periosteal elevator was used to reflect the flap apically. The scalpel blade^s was placed in the sulcus of 202 and the periodontal attachment released around its circumference. Tooth 202 was extracted with the aid of a #3 Winged elevator.^v

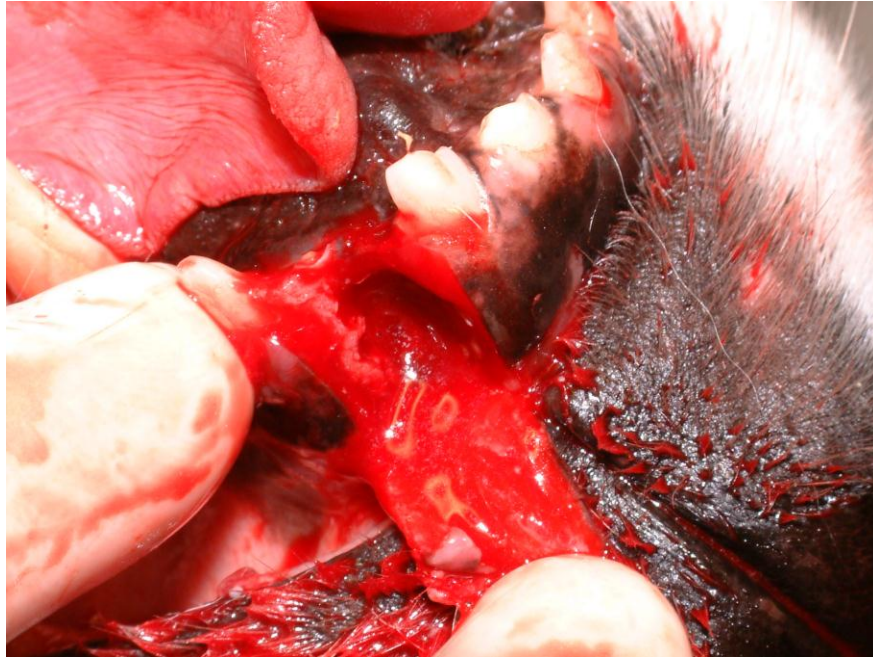

Figure 3

A mucoperiosteal flap with divergent releasing incisions aids in exposure for extraction and biopsy

A small segment of bone was attached to the tooth. The tooth was partially surrounded by granulation tissue, a fibrous tissue and a white caseous material. A cavity was present within the maxilla that corresponded to the lucency seen on the radiographs. The elevator was used to obtain samples of the granulation tissue, fibrous tissue and caseous material. These tissues were sent along with 202 and adherent bone for histopathology. The edge of the gingival flap was straightened with the scalpel blade and the periosteum incised to facilitate a tension free flap closure. The gingiva was sutured in a simple interrupted pattern using Mayo Hagar needle holders^w and 4-0 monocril with a 3/8” NFS-2 cutting needle^x. Ketoprofen^y (55 mg IM) was administered for pain control.

Post-Operative Care/Biopsy:

The patient was placed on a blanket in recovery and carefully monitored. At the first sign of swallowing the endotracheal tube^s was deflated and removed. The patient was monitored until sternal recumbency was achieved. Prior to discharge the IV catheter^d was removed and a light pressure bandage placed over the catheter site to aid in hemostasis. Carprofen^z was dispensed

with instructions to give 100 mg every twenty four hours for three days starting twenty four hours post-op.

Diagnosis:

Three days following discharge the owner was contacted by phone. A diagnosis of epidermoid cyst of bone with pyogranulomatous inflammation was relayed to the owner. Due to the proximity of the lesion to the incisors, the extent of the cavity in the maxilla, and the rare nature of the lesion described a second opinion was recommended and accepted by the owner. The conversation indicated that the patient showed no adverse effects from the procedure. Two weeks later the histopathology results revealed a keratin rich radicular cyst with a foreign body granulomatous inflammation associated with the release of keratin fragments.

Treatment Plan:

The owner was notified and surgery set for two weeks to remove the remainder of the cyst and its components. Teeth 201 and 203 would be extracted due to significant alveolar bone destruction.

Treatment:

The patient returned thirty three days following the original presentation for surgical removal of the cyst and its components and extraction of 201 and 203. EKG^a analysis showed a normal sinus rhythm, normal complexes and a heart rate of 112. Mucous membrane color, capillary refill time, pulse and chest auscultation were all within normal limits.

The induction and anesthetic protocol was identical to that of the previous surgery including a right and left infraorbital nerve block as previously described. A 15 Bard Parker blade^s on a No. 7 scalpel handle^t was used to raise a mucoperiosteal flap with two divergent vertical releasing incisions starting at the mesial line angles of the maxillary left canine tooth (204) and the maxillary right second incisor (102) extending one centimeter beyond the mucogingival junction. The releasing incisions were connected by incising the junction of the palatal and gingival mucosa. Visual inspection showed significant loss of alveolar bone surrounding the 201 and 203. The blade was placed in the sulcus of 201 and 203 and the periodontal attachment released

around the circumference of each. Teeth 201 and 203 were extracted without difficulty using a #3 Winged elevator.^v

Visual examination showed no organized structure to the cyst lining which was fibrous in nature. The cyst along with caseous material and granulation tissue were removed with a combination of ophthalmic thumb forceps^{aa} and the EX-7 periosteal elevator.^u (Figure 4) Following removal of the cyst and its contents the cavity was thoroughly lavaged with saline.^{bb} Ophthalmic thumb forceps^{aa} were used to demonstrate the caudal extent of the cavity radiographically. (Figure 5) The leading edges of the gingiva and palatal mucosa were contoured for cosmetic closure using the scalpel blade. The gingiva was sutured in a simple interrupted pattern using Mayo Hagar needle holders^v and 4-0 monocryl with a 3/8" NFS-2 cutting needle^x. (Figure 6) Ketoprofen^y (55 mg IM) was administered for pain control.

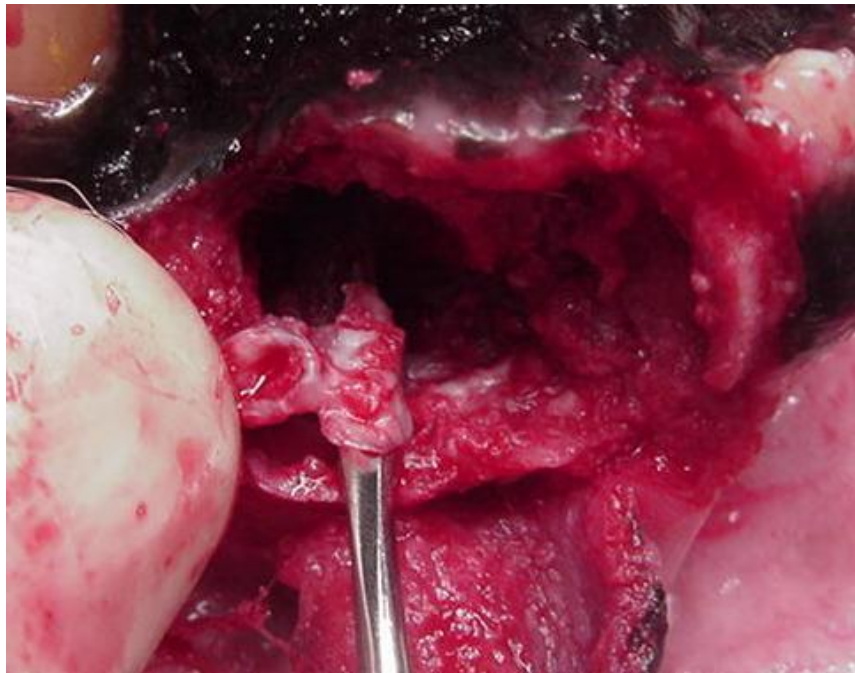


Figure 4

A portion of the caseous material and the fibrous cyst capsule can be seen here during reentry for cyst removal

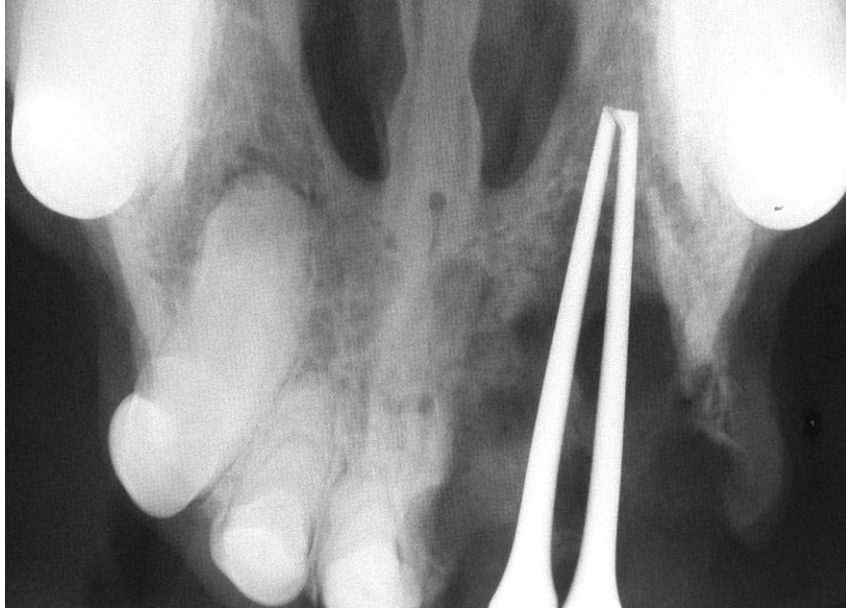


Figure 5
Thumb forceps demonstrate the caudal extent of the cavity post-op

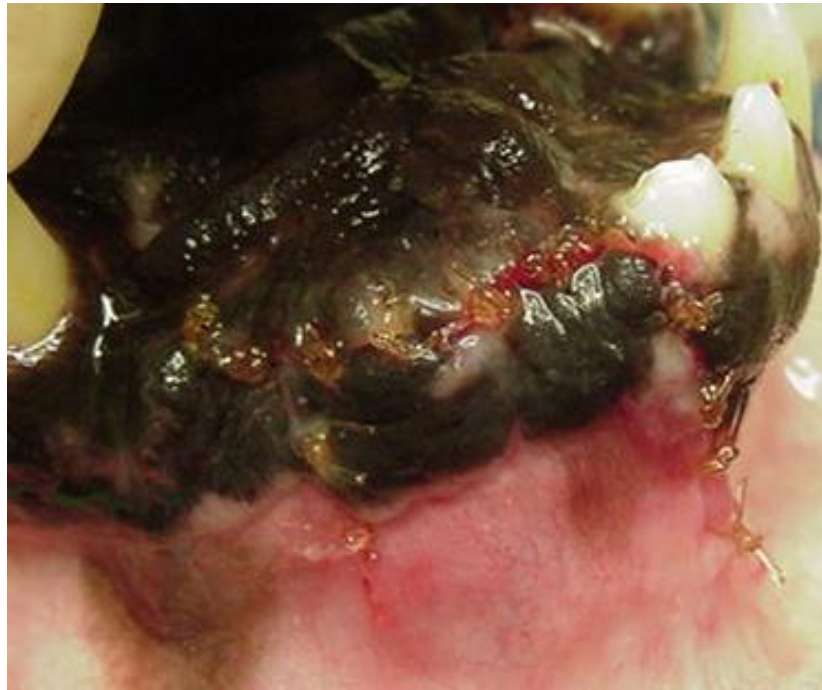

Figure 6
The mucoperiosteal flap is closed with a simple interrupted pattern using 4-0 Monocryl®.

Post-Operative Care/Excision:

Recovery was uneventful and similar to that described with the original surgery. Carprofen^z was dispensed with instructions to give 100 mg every twenty four hours for three days starting twenty four hours post-op.

Long Term Follow Up:

The owner was instructed to return in two weeks to examine the surgical site for healing and to schedule a radiographic evaluation of the area to ensure complete removal in four months. Two days after discharge the owner was contacted by phone and indicated that the patient was doing well.

Prior to the two week recheck the owner called and cancelled citing the patient convalesced without incident and the area looked normal with the exception of the sutures. Despite a recommendation to keep the appointment the owner declined and acknowledged her intent to keep the appointment for radiography four months post-op.

The patient returned four months post-op. The surgical site had healed completely. (Figure 7) The patient showed no discomfort upon palpation of the site. No other abnormalities were noted. Vitals and pre-anesthetic EKG were normal as in the prior anesthesia episodes. Butorphanol^b (8 mg IM) was given 25 minutes prior to sedation. Adequate sedation was achieved with ketamine^d (140 mg IV) and valium^e (5.6 mg IV). Radiography revealed increased bone density adjacent to the previous post-surgical margins. A small region of lucency was present within the region of new bone formation. (Figure 8) Although likely not of clinical significance the lucency should be reevaluated radiographically in 6 months.

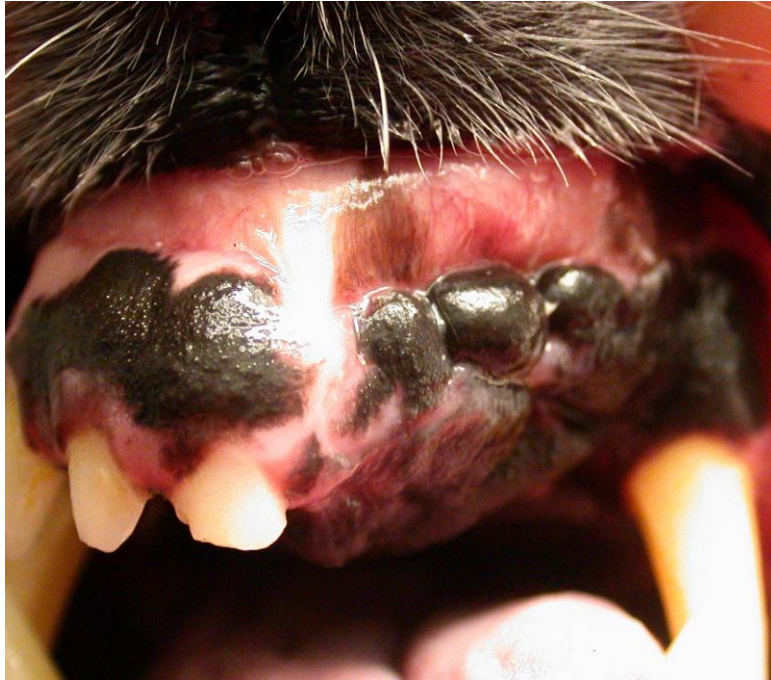

Figure 7

At six months post-op there is complete gingival healing and no discomfort upon palpation.

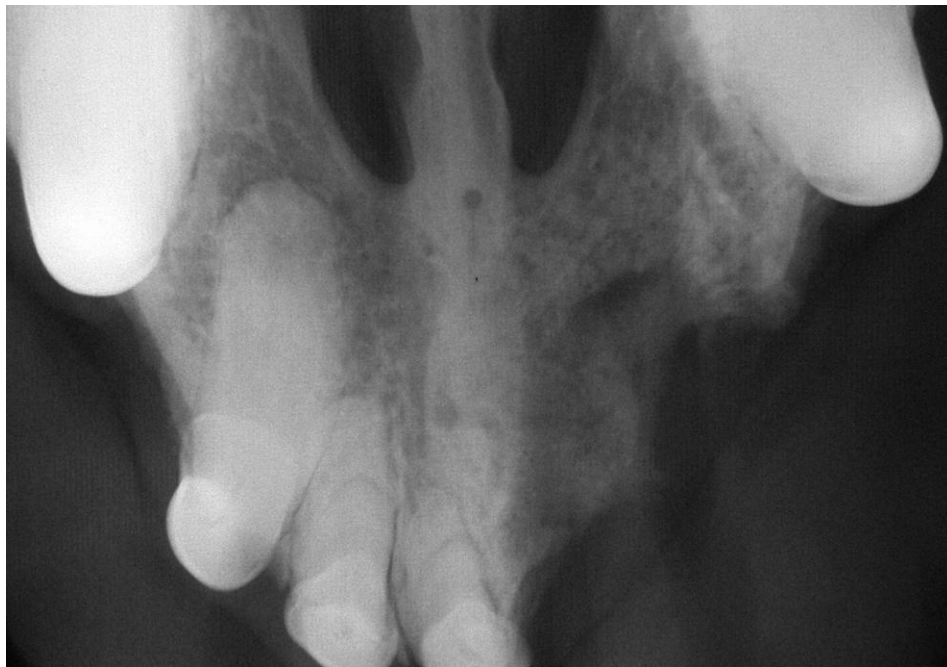

Figure 8

Radiographic appearance at the six month follow up exam shows evidence of new bone growth. A lucency is present within the bone.

Discussion:

The World Health Organization signifies radicular cyst, apical periodontal cyst and periapical cyst as synonyms.(5) Another text further categorizes periapical cysts as periapical true cysts and periapical pocket cysts both of inflammatory origin.(8) Periapical true cysts are enclosed with epithelium with no communication with the root canal. Periapical pocket cysts have a saclike epithelium with direct communication with the root canal. They cannot be differentiated radiographically but response of each to conventional endodontics makes them clinically relevant. A periapical pocket cyst is likely to heal following root canal therapy due to its communication with the endodontic system.(9) This is not the case with the true cyst which fails to resolve radiographically following root canal therapy.

Periapical or radicular cysts form as a result of chronic apical periodontitis which results from microbial invasion of the pulp cavity.(8) Apical periodontitis is generally described as the body's reaction to the destruction of the pulp and microbial occupation of the root canal. The various lesions that develop in response to this interaction of the host defense system and the invading microbes include the radicular cysts. It is likely that the cyst described in this case report originated with the fracture of either 201 or 202 and a resultant chronic apical periodontitis. Not every incident of chronic apical periodontitis results in the formation of a cyst in humans. A recent study shows that the incidence (n = 256) approximates 15%.(9) This figure includes both true cysts and pocket cysts.

In approaching oral swellings it is important to determine the nature of the lesion microscopically. The decision to biopsy this lesion and remove the mobile incisor was made based upon several factors. The large area visualized radiographically involving both a lucency and soft tissue could not definitively be deemed a cyst. Inspection of the region following excision of the mobile tooth for better visualization revealed a mixture of fibrous, granulomatous and caseous material not recognized in this author's previous experience with maxillary or mandibular cysts. Definitive recognition of the process through biopsy may be desirable prior to attempting an involved procedure in this geriatric patient. If prognosis for removal based upon microscopic examination was less than ideal the decision not to attempt reentry may have been in the best interest of the patient. A decision for an attempt at total excision could be supported, however had the surgeon's experience revealed similar findings in past experience.

The initial biopsy revealed an epidermoid bone cyst. This type of cyst had not been described in the maxilla in previous veterinary literature and only infrequently in the human literature.(10,11, 12) In order to further document the existence of an epidermoid cyst in the maxilla of this patient a second opinion was sought. The Department of Pathobiological Sciences at the University of Wisconsin was consulted and reported that the mass was a radicular cyst rather than an epidermoid cyst. The decision to reenter the surgical site and attempt total excision was based on the local aggressive nature and potential for malignant transformation of odontogenic cysts.(6)

New bone growth was evident at the four month follow up examination. Unfortunately a lucency was also present radiographically. Although no gross changes were evident recommendations for follow up radiography were made to ensure that the cyst was totally excised and that the lucency was static. The owner expressed the desire to forgo any additional anesthetic episodes unless absolutely necessary due to the patient's age. The decision was made to recheck the patient every four months for gross evidence of return of the cyst.

Only two additional cases describing radicular cysts in the dog have been published in the veterinary literature.(1,3) Both describe these lesions appearing in the anterior maxilla. It is possible that an association exists between the anterior maxillary dentition and the occurrence of radicular cysts in this region however a broader population must be evaluated to make that determination.

Conclusion:

The author's clinical experience with this type of lesion was confined to odontogenic cysts with well defined radiographic margins. Previous exposure to cases with similar characteristics as the one described in this report would have changed the approach in this case. Initial surgical management of the cyst and its contents would have resulted in attempt at complete surgical excision and biopsy in one anesthetic episode. This case may serve as a reference for decision making for those encountering similar presentations.

Products:

- a) EKG analyzer, Vetronics, Lafayette, IN
- b) Torbugesic, Fort Dodge Animal Health, Fort Dodge, IA
- c) Surflo intravenous catheter, Terumo Medical Corp, Elkton, MD
- d) Ketaset, Fort Dodge Animal Health, Fort Dodge, IA
- e) Valium, Abbott Laboratories, N Chicago, IL
- f) 5-0 Endotracheal Tube, Rusch,
- g) IsoFlo, Abbott Laboratories, N Chicago, IL
- h) VMS Anesthesia Machine, Matrix Medical, Inc., Orchard Park, NY
- i) T Pump, Gaymar Industries, Orchard Park, NY
- j) Lactated Ringer's solution, Abbott Labs, N Chicago, IL
- k) Chlorhexidine, First Priority, Elgin, IL
- l) Neosonic, Amdent, Cherry Hill, NJ
- m) Disposable prophylaxis angle, Carlisle Labs, Rockwell Centre, NY
- n) High Speed Delivery System, Beaverstate Dental,
- o) Prophylaxis 1 Paste, Carlisle Labs, Rockville Centre, NY
- p) DentX Image Vet X70, AFP Imaging, Elmsford, NY
- q) Bupivacaine, Abbott Laboratories, N Chicago, IL
- r) Tuberculin syringe and needle, Nipro Medical Corp, Miami, FL
- s) No. 15 surgical blade, Carlisle Labs, Rockville Centre, NY
- t) Scalpel handle, Spectrum, Stow, OH
- u) EX-7 periosteal elevator, Cislak Manufacturing Inc., Glenview, IL
- v) #2 Winged elevator, Dentalaire, Fountain Valley, CA
- w) Mayo-Hagar needle holders, Spectrum, Stow, OH
- x) 4-0 Monocryl, Ethicon, Inc. Somerville, NJ
- y) Ketofen, Fort Dodge Animal Health, Fort Dodge, IA
- z) Rimadyl, Pfizer, New York, NY
- aa) Ophthalmic Thumb forceps, Spectrum, Stow, OH
- bb) 0.9% saline solution, Abbott Labs, N Chicago, IL

References:

1. French SL, Anthony JMG. Surgical Removal of a Radicular Odontogenic Cyst in a Four year Old Dalmatian Dog. *J Vet Dent* 13(4);149-151 (1996)
2. Mosqueda-Taylor A, et al. Odontogenic cysts. Analysis of 856 cases. *Med Oral* Mar-Apr;7(2):89-96 (2002)
3. Reiter AM. Periapical Cyst Formation of the Left Maxillary Third Incisor Tooth in an Adult Standard Poodle. Presentation *Proceedings from 15th Annual Dental Forum*, 149-150 (2001)
4. Pavelic B, Placak D, Peric B. Histologic difference in epithelial linings between follicular and radicular cysts. *Coll Antropol* Dec;22 Suppl:167-71 (1998)
5. World Health Organization: Application of the international classification of the diseases to dentistry and stomatology. ed3, Geneva, 1995, The Organization.
6. Anderson JG, Harvey CE. Odontogenic Cysts. *J Vet Dent* 10(4):5-9 (1993)
7. Wiggs RB, Lobprise HB. Veterinary Dentistry Principles and Practice. Philadelphia, Lippincott, 352-355 (1997)
8. Cohen S, Burns RC. Pathobiology of the Periapex from: Pathways of the Pulp St Louis, Mosby (2002)
9. Nair PNR, Pajarola G, Schroeder HE. Types and incidence of human periapical lesions obtained with extracted teeth, *Oral Surg Oral Med Oral Pathol* 81:93 (1996)
10. Werner A, et al. A case of epidermal cyst of the maxilla. *Rev Stomatol Chir Maxillofac* 79(5):407-10 (1978)
11. White AK, Jenkins HA, Coker NJ. Intradiploic epidermoid cyst of the sphenoid wing. *Arch Otolaryngol Head Neck Surg* 1987 Sep;113(9):995-9.
12. Barrios JM, Garcia J, Moreno E. Malignant epidermoid cyst of the maxilla, *An Otorrinolaringol Ibero Am* 10(3):281-6 (1983)