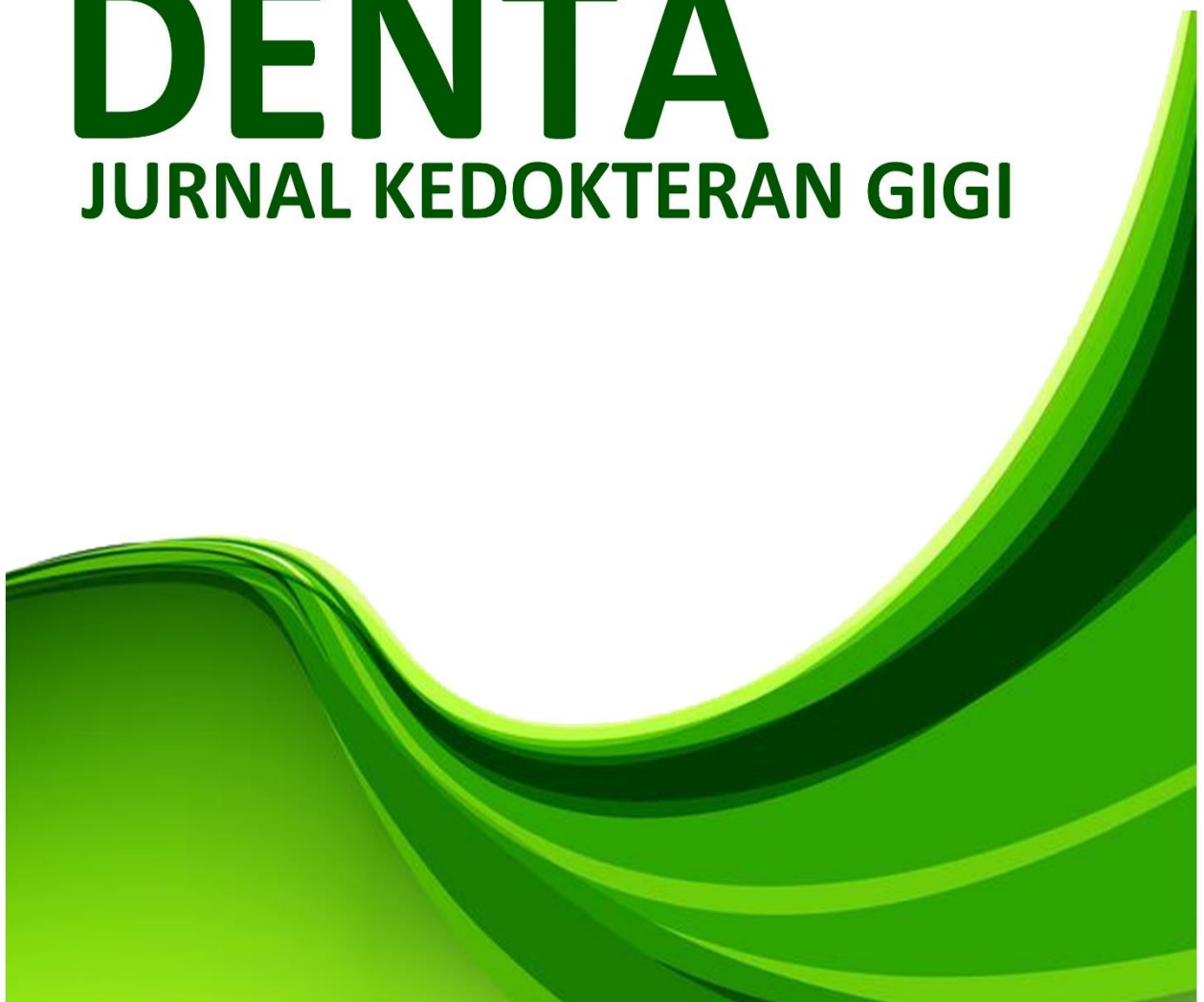

**Vol. 11 No.1 February 2017**

**ISSN : 1907-5987**

# **DENTA**

**JURNAL KEDOKTERAN GIGI**



**SUSUNAN REDAKSI**

***Pemimpin Umum***

Noengki Prameswari

***Ketua Penyunting***

Dian W Damaiyanti

***Sekretaris***

Agni Febrina Pargaputri, Carissa Endianasari

***Bendahara***

Maria Franciska

***Penyunting Pelaksana***

Fitria Rahmitasari, Kharina Widyowati,  
Endah Wahjuningsih, Widyastuti, Rima Parwati Sari, Dwi Andriani

***Penyunting Ahli (Mitra Bebestari)***

Setyo Harnowo, Arifzan Razak, Soetjipto, Dian Mulawarmanti, Sarianoferni,  
Mei Syafriadi, Bambang Sucahyo, Achmad Gunadi,  
Udijanto Tedjosasongko, Iga Wahyu Ardani

***Distribusi***

Trias Djohar Wirawan

Jurnal Kedokteran Gigi diterbitkan setiap bulan Februari dan Agustus oleh Fakultas  
Kedokteran Gigi Universitas Hang Tuah.

---

**ALAMAT REDAKSI**

Cp. Carissa Endianasari

Fakultas Kedokteran Gigi-Universitas Hang Tuah

Jl. Arief Rahman Hakim 150 Surabaya

Telp. 031-5945864, 5945894 psw 219/220 Fax. 031-5946261

E-mail: [journal.denta@hangtuah.ac.id](mailto:journal.denta@hangtuah.ac.id)/[jurnal.denta@gmail.com](mailto:jurnal.denta@gmail.com)

<http://journal-denta.hangtuah.ac.id/>

**DAFTAR ISI**

<b>Susunan Redaksi</b>	<b>i</b>
<b>Daftar Isi</b>	<b>ii</b>
<b>Correlation Dental Classification of Mandibular Impacted Tooth with a Duration of Action Odontectomy in Rumkital Dr. Ramelan Surabaya</b> <i>Muhammad Rizki Zulian, Eddy Hermanto, Sudiby</i>	<b>1</b>
<b>Influence Of Branding to Brand Awareness in Dental Hospital Of Hang Tuah University</b> <i>Ghita Hadi Holanda</i>	<b>9</b>
<b>Innovation of Stichopus hermanii and HBOT in Increasing the Number of Fibroblasts on Periodontal Ligament</b> <i>Robbi Akbar Dirmadana, Ghina Sucilia Mediani, I Ketut Ika Sandana, Febryan Alief, Jessica Jenuary Yasin, Arya brahmanta</i>	<b>15</b>
<b>Marketing Strategy Based on Image of Hang Tuah University Dental and Oral Hospital in 2015</b> <i>Annisa Mutiara Pertiwi, Dwi Hariyanto, Aprilia</i>	<b>25</b>
<b>The Effect of Acanthus ilicifilius Extract On Anticandida Albicans Antibody in Wistar Rats with Oral Candidiasis Immunosupressed Model</b> <i>Dwi Andriani, Dwi Setianingtyas, Nafi'ah</i>	<b>35</b>
<b>The Effectiveness of Golden Sea Cucumber Ethanol Extract on The Expression of Endoglin in The Maturation Phase of Healing Mice With Traumatic Ulcers</b> <i>Rima Parwati Sari, Endah Wahjuningsih</i>	<b>43</b>
<b>The Effect of Pluchea indica Less Leaves Extract Againts Biofilm of Enterococcus faecalis and Fusobacterium nucleatum In Vitro</b> <i>Agni Febrina Pargaputri, Elly Munadziroh, Retno Indrawati</i>	<b>51</b>
<b>The Effect of Propolis Extract To Increase Fibroblast In Remodeling Process at Tension Side of Orthodontic Tooth Movement</b> <i>Budi Handayani, Lisdiana Mardanus</i>	<b>62</b>
<b>Importance of Dental Stand Preparation Guide on Making Double Crown Telescopic with Friction Element</b> <i>Anindita Apsari, Chaterina Dyah Nanik K</i>	<b>69</b>

<b>The Expression of IL-8 in Gingival Rattus novergicus After Exposed by Silver Gel Nano Particles 15 µg/ml</b> <i>Kharinna Widowati</i>	<b>75</b>
<b>Management of Patient with Aggressive Periodontitis by Orthodontic and Prosthodontic Collaboration</b> <i>Chaterina Diyah Nanik. K, Anindita Apsari</i>	<b>80</b>
<b>Nonsurgical Endodontik Retreatment of Maxillary First Premolar</b> <i>Yongki Hadinata W, Karlina Samadi</i>	<b>88</b>
<b>Periodontal Surgery In Gingival Recession With Subepithelial Connective Tissue Graft Technic</b> <i>Erianti Dewi Utami</i>	<b>96</b>

## CASE REPORT

## Management of Patient with Aggressive Periodontitis by Orthodontic and Prosthodontic Collaboration

Chaterina Diyah Nanik. K\*, Anindita Apsari\*

\*Prostodontics Faculty of Dentistry, Hang Tuah University Surabaya  
[chaterina.nanik@hangtuah.ac.id](mailto:chaterina.nanik@hangtuah.ac.id)

### ABSTRACT

**Background:** One of the most common inflammation disease in the oral cavity for the past few years is the aggressive form of periodontitis. Common signs of aggressive periodontitis is the mobility of teeth especially in incisive and first molars, and occurring mostly in young patient. Young patients whose losing her anterior teeth, are a real challenge for dentist and prosthodontist. Prosthodontist need to consider both functional and esthetic aspects. **Objective:** Rehabilitation of young adult patient with aggressive periodontitis by an interdisciplinary approach of orthodontist and prosthodontist. **Case Description:** A young woman, suffered from aggressive periodontitis with major complain of her teeth mobility, especially incisive and first molar in mandible. She had undergone periodontal treatment, but the result was failed. The anterior teeth in mandible need to be extracted, therefore patient wished not to be in edentulous state. As preliminary treatment, we choose immediate denture to replace the anterior mandible teeth. We faced difficulties in mandible, because her right canine weren't in the proper dental arch. So we asked orthodontist to place fixed orthodontics in mandible, to get the canine back in the proper arch. We've chosen orthodontic treatment, because we didn't want to extract the canine teeth. We evaluated in six months and after the canine back in the proper arch, we proceed to long span bridge in mandible as our definitive treatment. **Conclusion:** By not extracting the canine teeth, we got some advantages, especially patient psychically was happier with her own teeth. The collaboration with another dentistry field, provides us better treatment for patient. After treatment, patient had no complaints and was happy with her new smile.

**Keywords:** Prosthodontic rehabilitation, aggressive periodontitis, orthodontic treatment, esthetic.

**Correspondence:** Chaterina Diyah Nanik. K; Department of Prostodontics, Faculty of Dentistry, Hang Tuah University, Arif Rahman Hakim 150, Surabaya; Phone 031-5912191, Email: [chaterina.nanik@hangtuah.ac.id](mailto:chaterina.nanik@hangtuah.ac.id)

---

## INTRODUCTION

The loss of periodontal support that occurs in generalised aggressive periodontitis leaves the clinician challenged with uncertainty about treatment outcomes and difficulty in making decisions. Generalised aggressive periodontitis affects systemically healthy individuals under 30 years of age, although patients may be older. The disease is characterised by rapid rate of progression, strikingly peculiar subgingival microflora, altered host immune response and a familial aggregation of diseased individuals. The destruction of periodontium appears to occur episodically with periods of advanced destruction followed by quiescence of variable length (weeks to months or years). These patients often have small amounts of bacterial plaque associated with the affected teeth.<sup>1</sup>

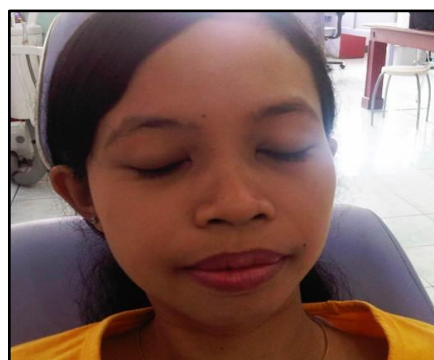
The gingival tissue response may be inflamed or appear pink and free of inflammation. During the acute phase, the gingiva appears inflamed, proliferating, ulcerated and fiery red, with bleeding and suppuration. Bone and attachment are actively lost during this destructive phase. In other cases, the gingiva appears normal and free of inflammation despite the presence of deep pockets. This kind of tissue response coincides with periods of quiescence in which bone levels remain stationary.<sup>2</sup> Cases of generalised aggressive periodontitis may be arrested spontaneously or may continue to progress to tooth loss despite treatment.

Rehabilitation of a patient with generalised aggressive periodontitis involves several challenges. Treatment objectives for generalised aggressive periodontitis include control of

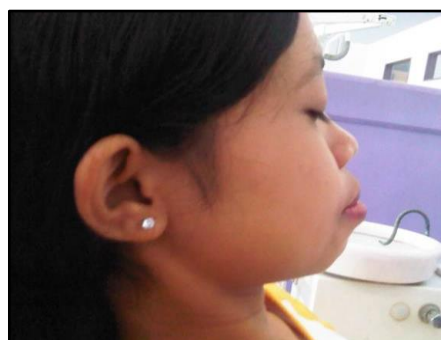
infections, arresting disease progression, correcting anatomic defects, replacing missing teeth and maintaining periodontal health.<sup>2</sup> This clinical report describes the sequenced treatment for a young adult patient with generalised aggressive periodontitis.

## CASE DESCRIPTION

A 28-year-old woman reported to the department for treatment of proclined teeth. She was very selfconscious about the appearance of her teeth (Fig 1-2). A detailed medical, dental and family history was obtained. Extraoral examination revealed incompetent lips.



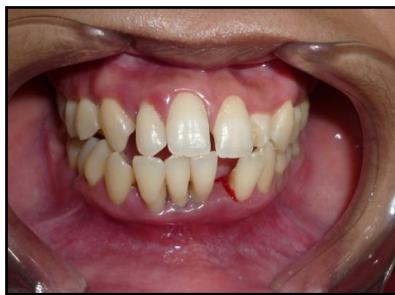**Figure 1.** Patient's profile (anterior view)



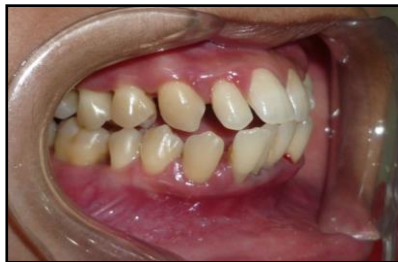**Figure 2.** Patient's profile (lateral view)

Clinical examination revealed presence of all teeth except maxillary left third molar and mandibular left first molar. There was pathological migration of mandibular right and left central and lateral incisors. Grade III

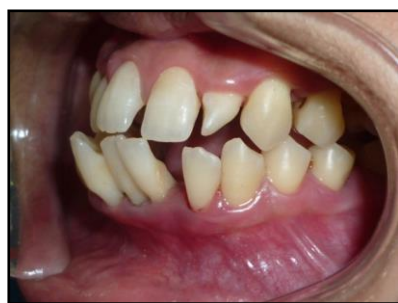mobility was present in mandibular left and right central and lateral incisors. Mild calculus deposits were also present in some teeth. The gingiva was swollen and was bleeding on probing. Grade I furcation was present in mandibular right and left second molars and grade II furcation was present in mandibular right first molar. The clinical view of patient were shown in figure 3-4.



**Fig. 3(A)**

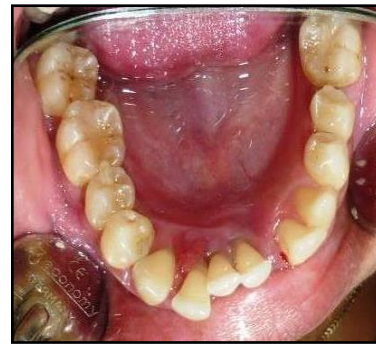

**Fig. 3(B)**

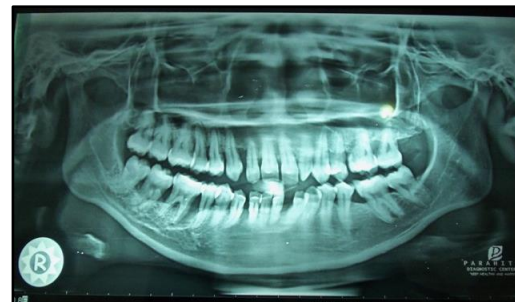

**Fig.3(C)**

Figure 3. (A) Pre-operative anterior clinical view, (B) Pre-operative right lateral clinical view, (C) Pre-operative left lateral clinical view.



**Fig.4** Pre-operative occlusal clinical view



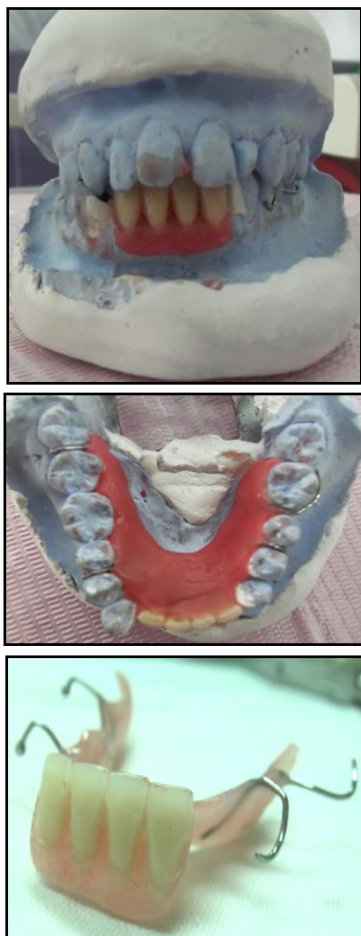**Figure 5.** Panoramic Radiograph

The radiographic examination with panoramic radiograph revealed generalised horizontal bone loss (figure 5). Routine blood investigations were performed and were normal.

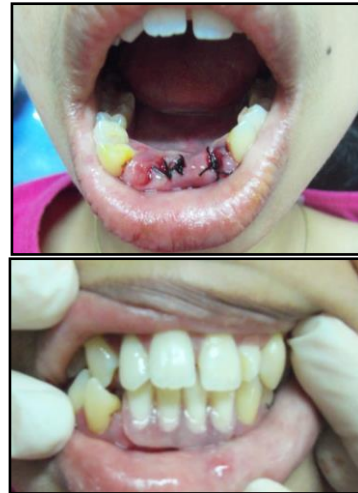#### TREATMENT

A treatment plan aimed at improving the patient's overall periodontal health was developed. In the first appointment, supragingival scaling was performed and the patient was given detailed oral hygiene instructions. She was advised to use 0.12% chlorhexidine mouth wash twice daily to enhance plaque control. Patient had undergone periodontal treatment 6 months before came to us by periodontist. The periodontist done the conventional flap surgery in all four quadrants in stages and patient were given adjuvant antibiotic therapy with 100 mg doxycycline once daily for 21 days and metronidazole 500 mg thrice

daily for 8 days. Extraction of mandibular right and left central and lateral incisors was planned in the second appointment. Maxillary and mandibular impressions were made before extraction and an immediate interim removable partial denture was fabricated (Figure 6). Extraction of mandibular right and left central and lateral incisors was performed and the interim removable prosthesis was placed (Figure 7).



**Figure 6.** Interim dentures in modelling wax and interim acrylic dentures ready to be inserted.

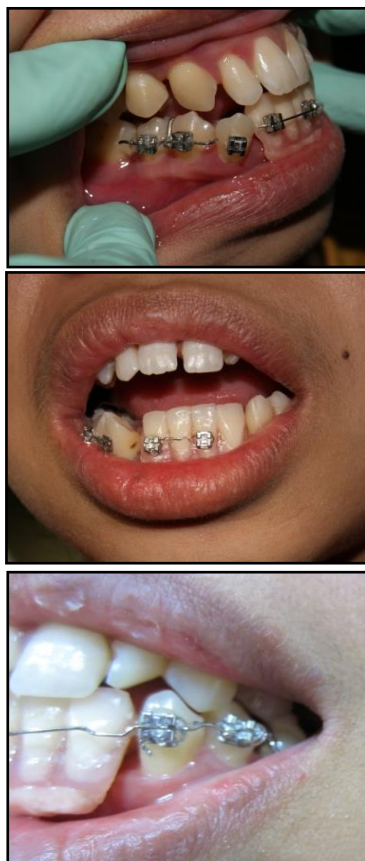

**Figure 7.** Extraction done in mandibular anterior teeth and insertion of immediate interim dentures.

Definitive prosthodontic treatment was planned after healing and when the patient was able to maintain good oral hygiene. The patient was not comfortable with the removable prosthesis and insisted on a fixed type of restoration. Diagnostic preparation and diagnostic wax up for a fixed partial denture, replacing mandibular right and left central and lateral incisors with the mandibular right and left canines and first premolars as abutments, was performed. The mandibular right canine wasn't in the proper arch, a bit too labially (as seen on Figure 7, right mandibular canine was in the labially position). Doing preparation in labially positioning canine surely harmed the pulp, because we need to make it back in a good position, good dental arch in harmony with another teeth. Hence, as an alternative to extract the labially positioned mandibular right canine, orthodontic treatment was planned to address aesthetics and labially positioned problem.

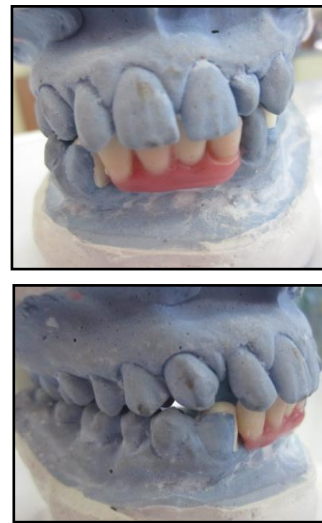


The orthodontic treatment done in combination with the interim removable prosthesis we had placed before. We had discussed with the orthodontist the best and effectively orthodontic treatment for this patient. The designed of orthodontic treatment was the used of ball clasp in mandibular right and left first premolar and mandibular right second molar, half jackson clasp was placed in mandibular left second molar (Figure 8). Orthodontic treatment was done for 6 months with monthly evaluation performed. After 6 months the result was a better position of mandibular right canine.

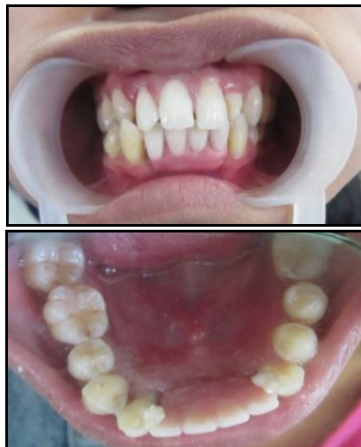

**Figure 8.** Orthodontic treatment done in combination with interim dentures.

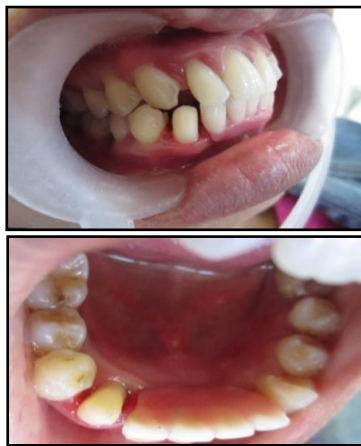A diagnostic wax up for definitive treatment in mandible were made. The definitive treatment was porcelain fused to metal fixed fixed bridge, with abutments teeth were mandibular left and right canine and first premolar. The wax up denture were made by placing an acrylic teeth in modelling wax and positioned it in the proper dental arch (Figure 9). The wax up denture was discussed with the patient, and patient was satisfied with the new positioned of her teeth (Figure 10). With the patient's consent, it was decided to proceed with the treatment plan. The wax up denture were used as a guide for doing preparation abutment teeth, so we didn't do over preparation for abutment teeth (Figure 11).



**Figure 9.** Try-in wax up of definitive prosthodontic treatment in modelling wax.

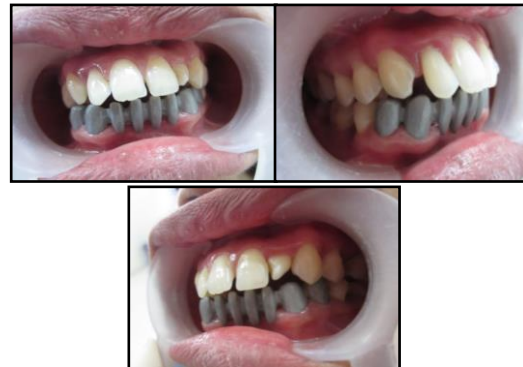

**Figure 10.** Try-in wax up modelling wax in patient.

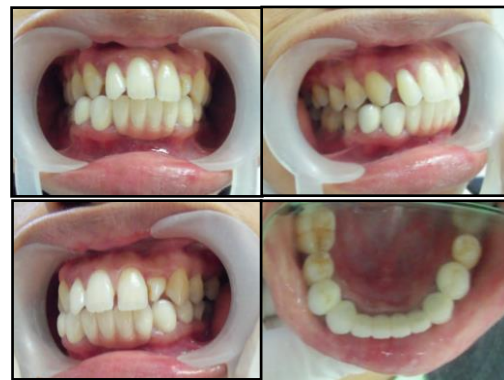

**Figure 11.** Preparation of abutment teeth using the wax up dentures as the guidance.

Crown preparations were made on the mandibular right and left canines and first premolars with chamfer finish line. Impression of the mandibular arch was taken with silicone impression material using a putty wash technique. The impressions were poured and dies were prepared. Wax pattern of the framework was fabricated and casting was done. A metal try-in was made to check the fit of the framework (Figure 12). Ceramic firing was carried out and the restoration was finished and polished. The fixed partial denture was tried and cemented with type I glass ionomer cement (Figure 13).

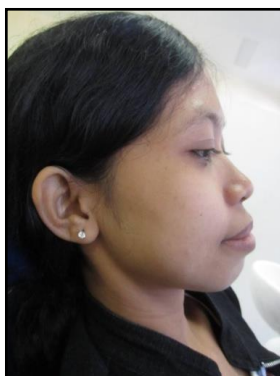


**Figure 12.** Try-in the framework of fixed fixed bridge in patient.



**Figure 13.** Final insertion of definitive prosthodontic treatment. Noticed the better position of mandibular right canine.

Regular follow-up of patients with aggressive periodontitis plays a major role in the overall success of the treatment. Recall every 3 months for a period of 1 year in this patient kept the disease under control. She was highly satisfied with the aesthetic and overall outcome of the treatment and was further motivated to achieve meticulous oral hygiene. With time there was also an improvement in the profile of the lip (Figure 14). The patient was also able to maintain good oral hygiene.



**Figure 14.** After treatment, patient got better lip profile.

## DISCUSSION

Early detection of aggressive periodontitis plays an important role since preventing further destruction is often more predictable than attempting to regenerate lost supporting tissue. Controlling the disease and restoring periodontal health is essential for successful prosthodontic rehabilitation. Studies have shown that individuals with aggressive (early-onset) periodontitis could be effectively maintained with clinical and microbiological improvements after active periodontal therapy.<sup>3</sup> Studies have also found that systemic antimicrobials in conjunction with scaling and root planing offer benefits over scaling and planing alone in terms of clinical attachment level, probing pocket depth and reduced risk of additional attachment loss.<sup>4</sup> Successful management of patients with aggressive periodontitis must include tooth replacement as part of the treatment plan. Replacing lost teeth can be achieved by using a removable partial denture, fixed partial denture and implant supported prosthesis. Since this patient could not tolerate a removable partial denture and could not afford dental implants, a fixed partial denture was fabricated to replace lost

teeth. The orthodontic treatment done in this patient improved the self confidence of patient, because she didn't need to loose her canine teeth eventhough her canine teeth was not in a proper dental arch.

One of the disadvantages of using orthodontic treatment is the difficulty in maintaining oral hygiene. In this patient, she need to regularly use a mouthwash to maintain good oral hygiene during the orthodontic treatment and she often got ulcer on her anterior mandibular mucosa because of the orthodontic bracket. In addition, the patient did report on speech difficulties in the initial period because of the interim removable dentures.

We chosen fixed fixed bridge as definitive treatment to this patient. From a biomechanical perspective, the control of potential movement owing to a non-rigid design under functional load is critical for survival of the prosthesis. So it's better to design with rigid connectors as present in this case. Conventional fixed dental prosthesis connectors are understandably more rigid as compared to loop connectors.<sup>5</sup>

In a 5-year follow-up study of patients with aggressive periodontitis, the periodontal disease progression was arrested in 95% of the initially affected lesions using comprehensive mechanical, surgical and antimicrobial therapy with supportive periodontal maintenance every 3–4 months.<sup>3</sup> Only 2–5% of the patients experienced loss of periodontal support.<sup>6</sup> Hence, longterm follow-up is mandatory in such patients.

## CONCLUSION

Controlling the disease and restoring periodontal health is essential for successful prosthodontic

rehabilitation in patients with aggressive periodontitis. Treatment of aggressive periodontitis is often complex and requires an interdisciplinary approach. In this patient, we done the collaboration between the orthodontic and prosthodontic treatment. The aesthetics were improved by using a fixed fixed bridge as her definitive treatment.

## REFERENCES

1. Deas DE, Mackey SA, Mc Donnell HT. *Systemic disease and periodontitis: manifestations of neutrophil dysfunction*. Periodontol Vol.32:82–104; 2003.
2. Delcourt-Debruyne EM, Boutigny HR, Hildebrand HF. *Features of severe periodontal disease in a teenager with Chediak-Higashi syndrome*. J Periodontal Vol.71:816–24; 2000.
3. Kamma JJ, Baehni PC. *Five-year maintenance follow-up of early-onset periodontitis patients*. J Clin Periodontol Vol.30:562–72; 2003.
4. Herrera D, Sanz M, Jepsen S, et al. *A systematic review on the effect of systemic antimicrobials as an adjunct to scaling and root planning in periodontitis patients*. J Clin Periodontol Vol.29(Suppl 3):136–59; 2002.
5. Carr AB, McGivney GP, Brown DT. *Direct retainers*. In: *McCracken's removable partial prosthodontics*. 11th ed. St Louis, MO: Mosby, 2005:86–8.
6. Buchmann R, Nunn ME, Van Dyke TE, et al. *Aggressive periodontitis: 5-year follow-up treatment*. J Periodontal Vol.73:675–83; 2002.