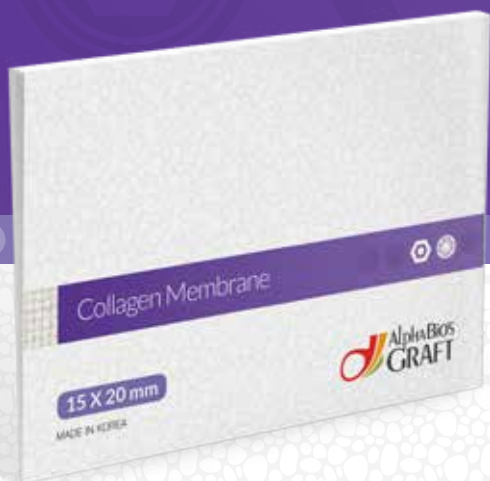

T-Gen Collagen Membrane

A Growing Success



T-Gen Collagen Membrane

T-Gen Collagen Membrane is a reliable biodegradable barrier for a wide range of osseous regenerative indications

Guided Bone Regeneration (GBR) and Guided Tissue Regeneration (GTR) rely primarily on four principles, exclusion of unwanted tissues and cells, space creation and maintenance, protection of the underlying blood clot and wound stabilization^[1]

For successful bone regeneration to occur, large bony defects require an underlying grafting material and a cell-occlusive membrane.

T-Gen Collagen Membrane fully supports this demand.

Clinical Indications:

T-Gen Collagen Membrane is a collagen barrier intended for use during Guided Bone Regeneration (GBR) and Guided Tissue Regeneration (GTR) procedures as a biodegradable barrier.

T-Gen Collagen Membrane indications:

- GTR procedures
- GBR procedures such as:
 - Extraction socket grafting
 - Site preparation for implant
 - Preservation of the alveolar ridge
 - Fenestration defect
 - Sinus floor augmentation over the lateral window and under the Schneiderian membrane tears

Handling

T-Gen Collagen Membrane Handling:

- Membrane is easy to shape and adapt to the osseous defect dimensions
- Fast hydration
- Excellent tensile strength
- Good adaptation to the defect
- Degradation time ~ 3 months

The package contains collagen membrane and a sterile template to be used for trimming the membrane according to the particular need of the regenerative site.



^[1] Wang HL. Principles in guided bone regeneration. Dent Implantol Update. 1998 May;9(5): 33-7.

Stability

T-Gen Collagen Membrane Stability

- Excellent tear resistance
- Prolonged barrier function and duration

T-Gen degradation

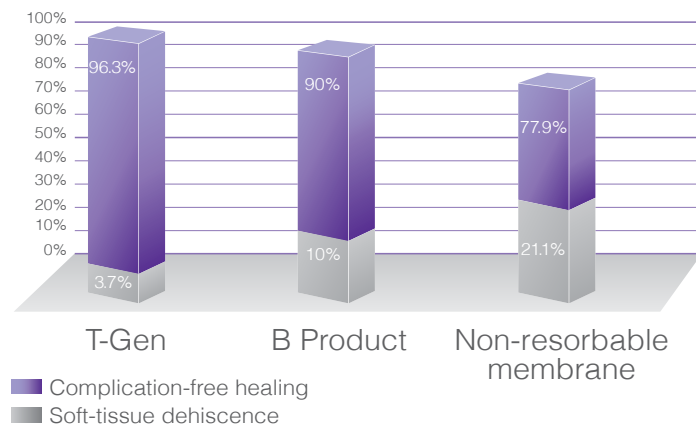
Product	Biodegradable period
T-Gen	More than 3 months
B product	Within 2 months

T-Gen provides a prolonged barrier function of more than 3 months as compared to product B.

Better Tissue Integration

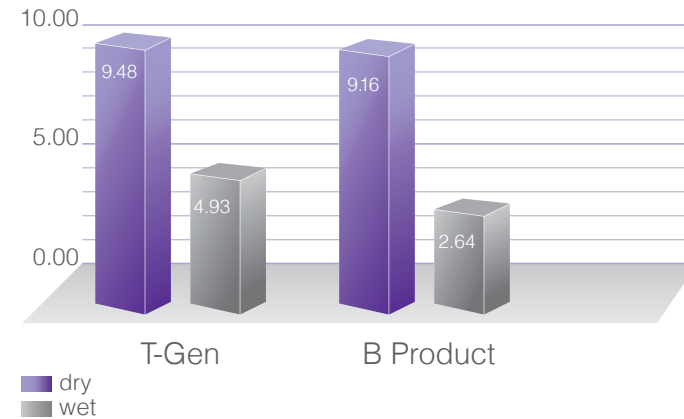
T-Gen Collagen Membrane tissue integration

- Allows fast blood supply to the defect
- Lower incidence of a dehiscence



Demonstrates lower incidence of soft tissue perforation following regenerative procedures as compared to cross-linked collagen membranes.

Tensile strength Test



T-Gen has excellent tensile strength therefore as compared to other products, it has stronger tear resistance during surgery.

Additionally, T-Gen adapts and contours to surfaces more firmly due to fast hydration and excellent flexibility.

Ordering Information

Code	TG-1	TG-2	TG-3
Size	15 x 20 mm	20 x 30 mm	30 x 40 mm
Ref. No.	TG-1	TG-2	TG-3

T-GEN Collagen Membrane Performance Treatment Concept and Indications:

By courtesy of Bioland

1 Fenestration defect treatment using autogenous bone and resorbable collagen membrane

Patient's medical and dental background

A 47-year-old male who presented with an osseous fenestration defect in the maxillary anterior. The patient was reported to have no specific medical and dental history. In exposing the patient's gingival, bone loss from buccal fenestration defect was observed (Fig.1). To maximize an aesthetic outcome and healing, the surgeon decided to use an autogenous bone graft and resorbable collagen membrane (T-Gen).

Treatment

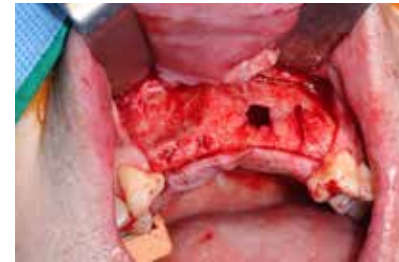An autogenous cortical bone graft (block and particles) were placed on and into the defect, where it filled the defect completely. The block was secured with two fixating pins (Fig.2 and 3). T-Gen was then applied to cover the entire site (Fig 4). A tension-free closure was achieved with 6-0 nylon sutures. 1 week after operation at the suture removal appointment, healing of soft tissue showed no sign of inflammation and the area was completely closed.

Results

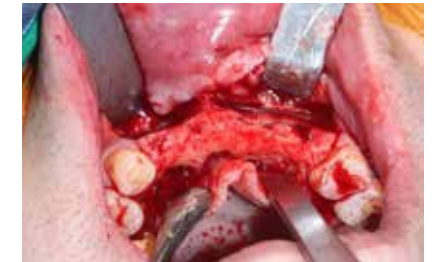Healed site, 4 months post-op.(Fig. 5). Good regenerated bone volume in the aesthetic zone is present following flap elevation (Fig.6).

Summary

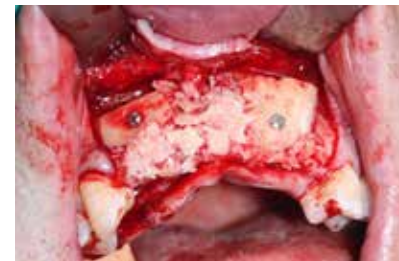The use of (T-Gen) has shown excellent results in bone formation in the esthetic zone. Due to its excellent adaptation and flexibility during surgery, such a regenerative result could be achieved. (T-Gen) resorbable collagen membrane provides a successful solution for this challenging treatment.



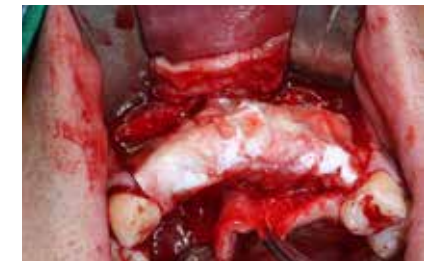1 After removing the soft tissue from the exposed bone, a fenestration defect was noticed.



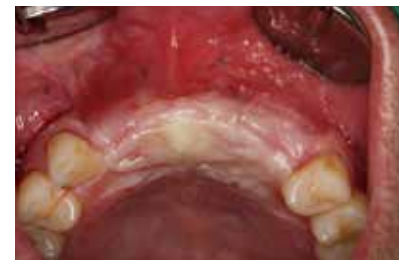2 After the elevation of the gingival flap a bone defect was observed.



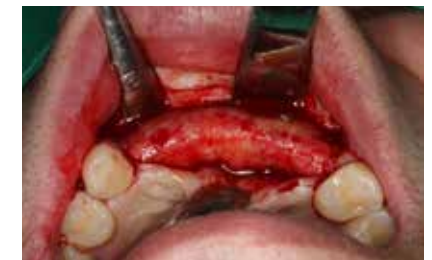3 Autogenous bone graft was placed over the defect.



4 Entire site was covered with T-Gen.



5 Favorable healing was observed at 4 month post-operation.



6 4 months post-op reentry demonstrates a good bone volume.

2 Treatment of dehiscence type osseous defect together with implant placement using xenograft and T-Gen collagen membrane

Patient's medical and dental background

A 41-year-old female who presented with buccal dehiscence defect in the mandibular molar area. The patient was reported to have no specific medical and dental history. A buccal dehiscence was noticed on the radiograph and demonstrated following the 1st implant placement (Fig.1 and 2). An indication for bone augmentation was clear and immediately performed. This would prevent a postoperative infection.

Treatment

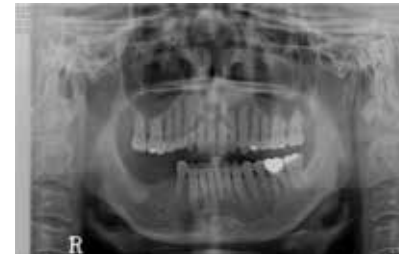Xenograft bone graft was applied to the bony dehiscence on the buccal aspect of the inserted implant (Fig.3). T-Gen was then applied to completely cover the grafted site (Fig.4). Primary closure was achieved over the membrane and graft, using 4-0 sutures (Fig.5). At the post-op appointment for suture removal, the soft tissue showed signs of good healing, without perforation of the gingival tissue. There were no signs of inflammation at the site.

Results

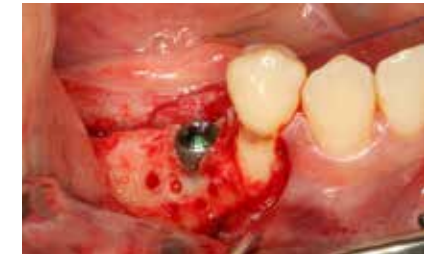1 month post-op photograph (Fig.6). soft tissue looks completely healed. At 4 months post-op, following flap elevation, good osseous healing was achieved around the implant (Fig.7). After a confirmation of the augmented site, healing abutments were applied to the fixtures, followed by the connection of implants healing abutments.

Summary

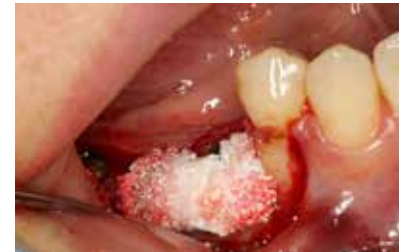Augmentation of an osseous dehiscence type defect was achieved with T-Gen membrane together with a particulated xenograft, simultaneously with implant placement. Healing following this procedure was smooth.



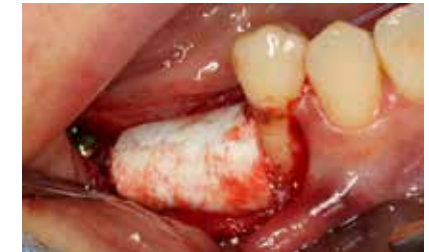1 Pre-operative radiograph



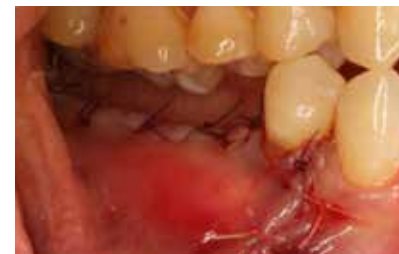2 Buccal dehiscence defect after implant placement



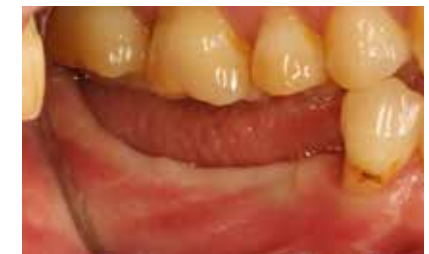3 The defects were filled with xenograft bone (Bio-Oss®)



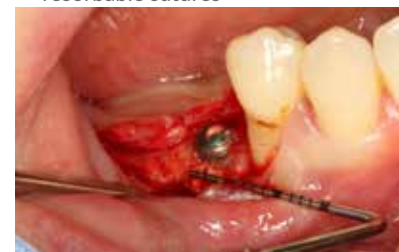4 Site was packed with T-Gen membrane



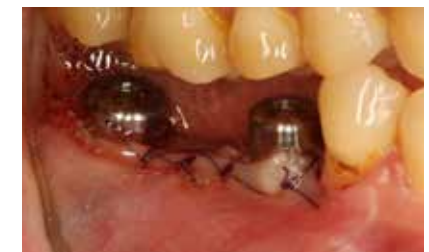5 A tension free suturing was performed using periosteal releasing incisions and resorbable sutures



6 Favorable healing is observed at 4 month post-operation



7 Reentry at 4 months shows the resolution of the previous defect.



8 Healing abutments are connected to the implants

3 Treatment of dehiscence type osseous defect using xenograft and T-Gen collagen membrane

Patient's medical and dental background

A 52-year-old female who presented with dehiscence type defect in the maxillary premolar area. The patient reported to have no specific medical and dental history. A pre-operative radiograph, is shown (Fig.1). A palatal defect at #25 tooth was noticed following 1st implant placement (Fig.2). The size of the defect was 3.5mm vertically and 4mm horizontally. The need for augmentation in such a situation is obvious.

Treatment

GBR procedure during implant placement was applied to the defect in order to build sufficient bone volume supporting the implant. Xenograft was applied around the implant on the Palatal aspect (Fig.3). T-Gen was applied to completely cover the entire site (Fig.4). Primary closure was achieved by a tension-free flap closure using 4-0 monosyn® sutures (Fig.5).

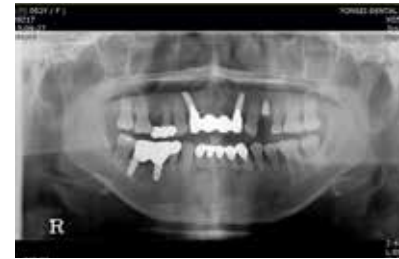
The 1 week post-op examination presented smooth healing.

Results

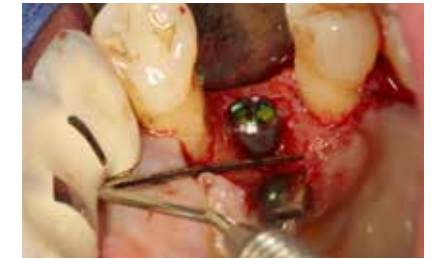4 months post-op, soft tissue in the palatal side appeared completely healed (Fig. 6). As sufficient bone volume in ridge height and width was achieved and demonstrated following surgical exposure. A complete regenerative result surrounding the implant is noticed (Fig. 7). Following the implant exposure, healing abutment was connected (Fig 8).

Summary

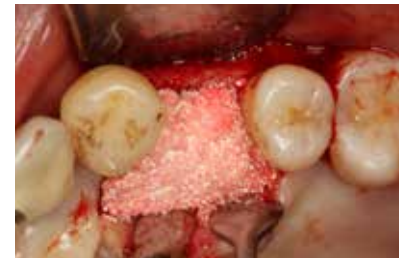This clinical case proved that the use of T-Gen in a complicated situation, combined with a good surgical technique, contributed to a successful result around an implant (GBR) and a tooth (GTR).



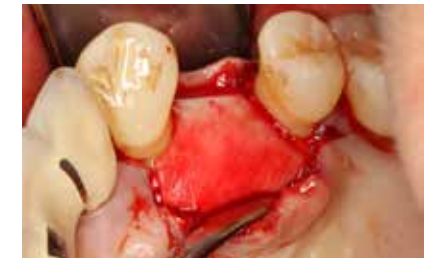1 Pre-operative radiograph



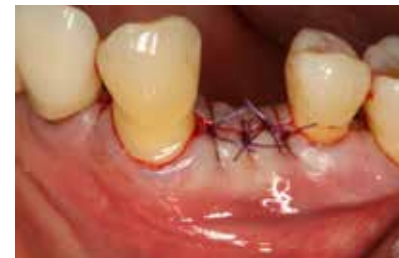2 Buccal dehiscence defect after implant placement



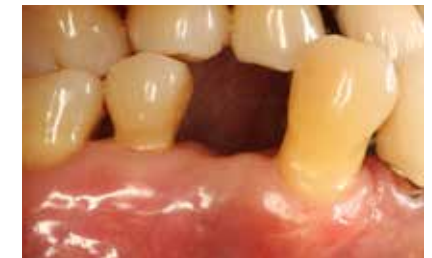3 The defects were filled with xenograft bone (Bio-Oss®)



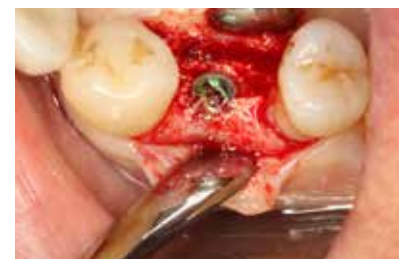4 Entire site was covered with T-Gen



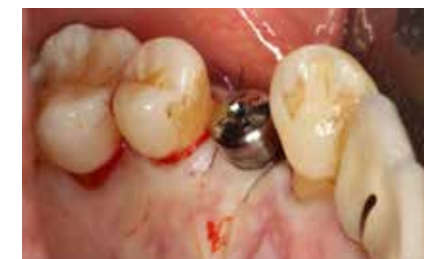5 A tension free flap closure is achieved using periosteal releasing incisions and resorbable sutures



6 Smooth healing is observed at 4 month post-operation



7 Reentry at 4 months post-op reentry shows complete healing of the previous defect



8 Healing abutment is connected to the implant

4 Ridge preservation following extraction using xenograft and T-Gen collagen membrane

Patient's medical and dental background

A 27-year-old female presented with bone loss and the resorption of buccal plate of the alveolus in the maxillary anterior region following the extraction of tooth #22 due to root resorption (Fig.1, 2).

This tooth had an apicoectomy surgery 18 months prior to its extraction. Extraction of tooth #22 and an immediate ridge preservation was indicated.

Treatment

Gingival and mucosal mesial vertical incision at #23 were performed followed by atraumatic extraction of tooth #22 (Fig.3).

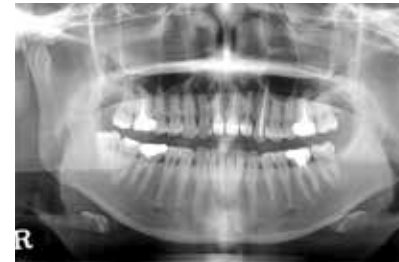A wide bone defect at the area of root apex of #22 tooth was observed, indicating the location of the previous apicoectomy performed in this location.

Xenograft was applied into the socket and bone defect of the buccal plate (Fig.4). T-Gen collagen membrane was applied to completely cover the entire site (Fig.5). Tension free closure was achieved using 4-0 and 6-0 monosyn sutures (Fig.6). Soft tissue healing with no sign of perforation without inflammation was noticed upon suture removal 1 week post-op.

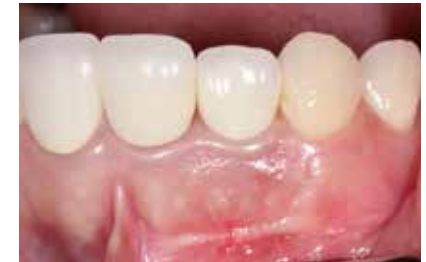Results

1 month post-op. shows nicely and completely healed soft tissue (Fig.7).

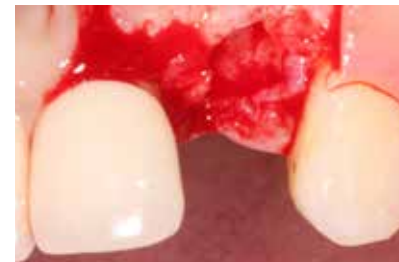4 months post-op. good bone volume is noticed, The area is restored by a temporary dental prosthesis.



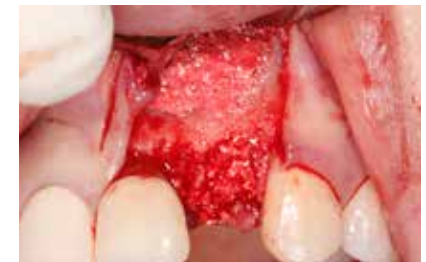1 Pre-operative radiograph



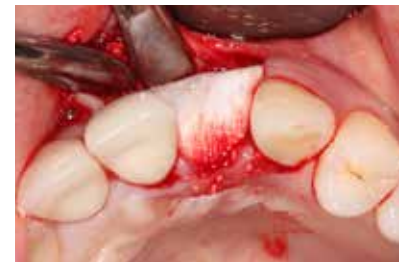2 Pre-operative clinical view



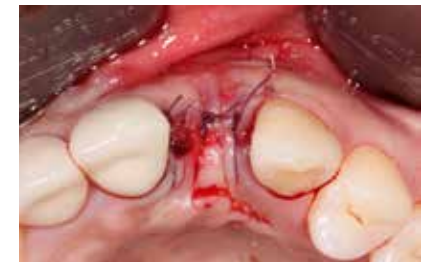3 Buccal bony defect



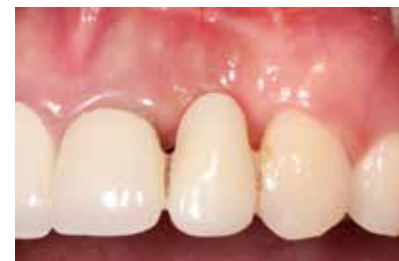4 The defects were filled with xenograft bone (Bio-Oss®).



5 Entire site was covered with T-Gen



6 A tension free flap closure is achieved by using periosteal releasing incisions and resorbable sutures



7 Treated site with temporary restoration

5 Extraction, immediate ridge preservation in the aesthetic site

Patient's medical and dental background

A 55-year-old male presented with severe bone loss in the anterior maxilla (Fig.1). The patient reported no specific medical and dental history. An old extraction site at #22 tooth neighboring a hopeless tooth, yielded a narrow osseous ridge that required its augmentation to allow a safe site for future implant placement.

Treatment

A hopeless tooth (#21) was extracted followed by socket grafting and defect augmentation with xenograft (Fig.2 and 3). T-Gen was applied to cover the entire site (Fig.4).

A tension-free flap closure was achieved using 4-0 Monosyn® sutures (Fig.5). Suture removal was done 1 week post-op. Soft tissue demonstrated good healing with no sign of inflammation.

Results

At 4 months post-op, successful and aesthetic healing of soft tissue was achieved (Fig.6 and 7).

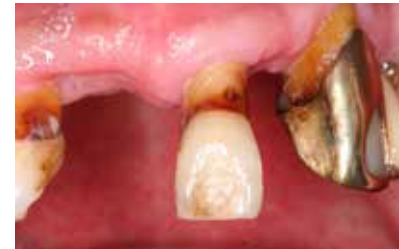At the 2nd stage implant placement procedure, complete healing of the bone was observed.

Summary

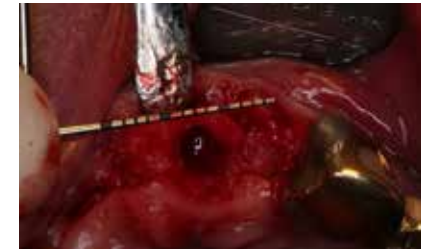
The ability of T-Gen membrane to support the goal and achievement of osseous augmentation in a complicated case was demonstrated.

T-Gen allowed good adaptation during graft covering due to its flexibility.

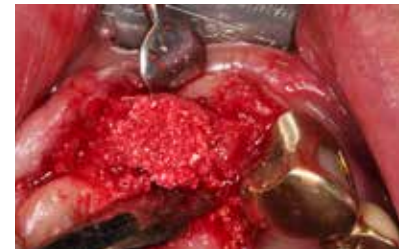
It also provides an excellent regeneration result without any adverse reaction, such as soft tissue perforation or infection.



1 Pre-operative clinical view



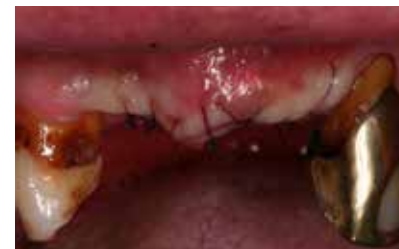2 Extraction socket of #21, and narrowing of the ridge in an old extraction of #22 is visible



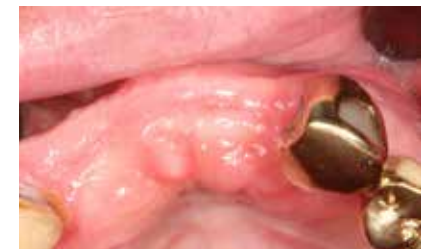3 The defects were filled with xenograft bone (Bio-Oss®)



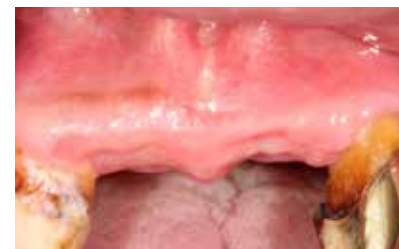4 Entire site was covered with T-Gen.



5 A tension free flap closure was achieved using periosteal releasing incisions and resorbable sutures

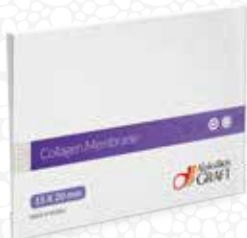

6 After 4 months, good bony healing of defect (occlusal view)



7 After 4 months, good bony healing of defect (vestibular view)

A Growing Success



T-Gen Collagen membrane is manufactured by Bioland,
162 Gwahaksaneop 3-ro, Ochang, Cheongwon, Chungbuk,
Korea

T-Gen is CE-marked in accordance with Council Directive
93/42/EEC.
Product availability may vary between countries

Distributed by:
Alpha-Bio Tec. Ltd
www.alpha-bio.net

Alpha-Bio Tec. complies with EN ISO 13485:2012 and ISO
13485:2003 the Canadian Medical Devices Conformity
Assessment System (CMDCAS).