

Technological Advances in Drug Delivery to Treat Noninfectious Posterior Segment Uveitis

Meeting Diagnostic and Management Challenges



Michael A. Singer, MD

ABSTRACT

When a patient presents with ocular inflammation, the hallmark of uveitis, the ophthalmologist is faced with a series of decisions. The first and most critical challenge is to determine whether the condition is infectious or noninfectious, as that will indicate which treatment pathway is to be followed. Once a patient has been diagnosed with noninfectious posterior uveitis, practitioners can choose between local and systemic treatments. If local therapy is selected, treatment may be topical or intravitreal; in either case, new medical options are available. Because of the complex nature of the condition and individual patient, it may be advisable in the course of either diagnosis or treatment for the ophthalmologist to consult the patient's internist or, in some cases, rheumatologist. While effective management of uveitis presents challenges, today's treatment options are safer, more efficacious, and more streamlined than in the past and offer the promise of enduring remissions from symptoms.

INTRODUCTION

Uveitis is a group of inflammatory diseases that can lead to severe vision loss if left untreated. The incidence of uveitis is estimated at between 17 and 52 cases per 100,000 per year, with a prevalence of 38 to 714 cases per 100,000.¹ Uveitis may originate from diseases occurring locally in the eye or as an extension of systemic inflammatory disease; 24% to 55% of cases are considered idiopathic.

Uveitis can involve inflammation not only of the uvea but also the lens, retina, optic nerve, and vitreous. Additionally, uveitis can be infectious or noninfectious, acute or chronic, and can affect the posterior segment, anterior segment, or both. Symptoms, which may include blurred vision, floaters, eye pain, redness, and light sensitivity, vary according to the type and site of inflammation.² Early and appropriate treatment of uveitis is critical: when incompletely treated, uveitis' characteristic recurrent inflammation impairs patients' functioning and quality of life and can lead to vision loss.³

Because uveitis can arise from any one of multiple causes and can vary in terms of the

type and extent of tissue involvement,⁴ it often presents as a diagnostic and therapeutic challenge. Inflammatory, infectious, and cancerous diseases of the eye often present with similar ocular and neurological features. Diagnosis and treatment of complex, chronic, or refractory cases, therefore, often require knowledge that crosses between internal medicine, infectious diseases, rheumatology, and immunology.⁵ Posterior uveitis, in particular, is usually treated by retinal specialists, who are familiar with treatments and procedures for the posterior segment.

Because of the multifaceted nature of uveitis diagnosis and treatment, practitioners caring for patients with uveitis face a series of challenges: arriving at an accurate diagnosis, treating the acute phase of the disease, and preventing symptom recurrence. As a result, educating practitioners on the treatment and diagnosis of uveitis is critical. This article will provide guidance for negotiating the noninfectious posterior uveitis pathway and discuss important technological advances that have been made in posterior segment drug delivery.

DIAGNOSTIC CHALLENGES

Diagnosis is the first step in treating patients with uveitis. Practitioners undertake a series of steps and tests to determine if a patient has uveitis and, if so, which type.

Classifying uveitis

Uveitis is classified in two ways, anatomic and etiologic. Anatomic classification is the purview of the ophthalmologist, whereas etiologic classification may involve teamwork with other medical specialists.

Anatomic classification: Ophthalmologists conduct clinical examinations to classify potential uveitis cases based on which tissues show inflammation. When inflammation appears in the front of the eye, the condition is classified as anterior uveitis, which is also known as iritis. Inflammation in the back of the eye indicates posterior uveitis; if inflammation occurs throughout the eye, it is diagnosed as panuveitis.⁶ To rule out panuveitis, the examining physician must ensure that observed anterior uveitis does not have a posterior component and vice versa.

TARGET AUDIENCE

This educational activity is intended for ophthalmologists and ophthalmologists in residency or fellowship training.

LEARNING OBJECTIVES

Upon completion of this activity, participants will be able to:

1. Define the screening, examination, laboratory analysis and imaging processes that drive accurate and detailed uveitis diagnoses.
2. Analyze the range of available and emerging treatment options for noninfectious and posterior noninfectious uveitis.
3. Explain how to make the best match of treatment and patient to decrease patient burden while optimizing treatment outcomes.
4. Review practice guidelines and options for adjustment in cases where treatment is intolerable or ineffective.

5. Use the knowledge of recent pivotal clinical trial outcomes by comparing and differentiating three critical technologies to manage posterior segment noninfectious uveitis: Ozurdex, Yutiq, and the CLS-TA injection. Phase 3 clinical trial data will be reviewed to close the educational gap.

EDITORIAL BOARD / FACULTY ADVISORS

Seenu Hariprasad, MD

Shui-Chin Lee Professor of Ophthalmology and Visual Science; Chief, Vitreoretinal Service; Director, Clinical Research; Director, Fellowship in Vitreoretinal Diseases and Surgery; The University of Chicago Medicine & Biological Sciences

Michael Singer, MD

Medical Center Ophthalmology Associates, San Antonio, TX

Tom Albini, MD

Bascom Palmer Eye Institute, Miami, FL

Technological Advances in Drug Delivery to Treat Noninfectious Posterior Segment Uveitis is jointly sponsored by Candeo Clinical/Science Communications, LLC, and the University of Florida College of Medicine. This publication is administered by an independent editorial board and supported by an unrestricted educational grant from ABBVIE.

Copyright 2020 Candeo Clinical/Science Communications, LLC. All rights reserved. Neither the university of Florida nor Candeo Clinical/Science Communications, LLC, assumes any responsibility for injury or damage to persons or property arising from the use of information or ideas contained in this publication.

CME REVIEWER

Gibran Khurshid, MD

*Associate Professor, Department of Ophthalmology
University of Florida College of Medicine*

When uveitis occurs in the posterior segment, it commonly involves the retina and choroid. In the United States, posterior uveitis is the third most common form of uveitis after anterior and panuveitis, respectively. In patients ≥ 65 years of age, however, posterior uveitis is more prevalent than other forms of nonanterior inflammation, comprising 53% of nonanterior cases. According to the Standardization of Uveitis Nomenclature (SUN) classification, posterior uveitis includes focal, multifocal or diffuse choroiditis, chorioretinitis, retinochoroiditis, retinitis, and neuroretinitis.⁶ Compared with anterior uveitis, posterior uveitis carries a greater morbidity and poorer prognosis.⁷ Vision-threatening complications in patients with noninfectious posterior uveitis include macular edema, cataract, glaucoma, vitreous debris, and retinopathy. Macular edema, which was reported in 8.3% of patients with noninfectious uveitis in a retrospective analysis of 334 patients from the Ocular Autoimmune Systemic Inflammatory Infectious Study (OASIS), is the most frequently encountered structural complication of uveitis that results in central visual impairment, followed by epiretinal membrane and glaucoma (6.3% and 4.2%, respectively).⁸

Etiologic classification: The origin of a patient's uveitis determines how it is best treated, and uveitis can stem from infectious or noninfectious causes. Because infectious and noninfectious uveitis can share many common clinical symptoms and signs, etiologic diagnosis is challenging. It is only when an infectious etiology is ruled out that the practitioner's focus can move to treating inflammatory rather than infective mechanisms.

Clinical Examination:⁹ One of the most critical steps in properly diagnosing and treating uveitis is the clinical examination. Clinical symptoms of anterior uveitis are a red, painful eye accompanied by anterior chamber cell and flare, posterior synechiae, and keratic precipitates. Posterior uveitis causes worsened vision and visual field changes, chorioretinal lesions, retinal whitening, and vascular sheathing. Inflammation in the vitreous may impede visualization of the posterior segment, in which case a PCR assay on an anterior chamber specimen may be required.¹⁰

Inflammation in the posterior segment may involve adjacent structures such as the retina, vitreous, optic nerve head, or retinal vessels, along with choroidal inflammation.¹¹ The examining physician may, therefore, find it helpful to keep the following questions in mind throughout the investigative process: Is this inflammation choroiditis, retinitis, or retinochoroiditis? Are the optic nerve head or the retinal vessels involved? Do the clinical features suggest any known infective or non-infective entity? Are there associated anterior segment inflammation, vitritis, or complications? Is the condition associated with other systemic features? Is it recurrent? If so, how has it responded to previous therapy? Finally, is it associated with an immunocompromised state?¹¹

History: A detailed medical history will help to determine whether the patient may have

Technological Advances in Drug Delivery to Treat Noninfectious Posterior Segment Uveitis

STATEMENT OF NEED

#1 Identified Need: Need for accurate uveitis diagnoses with details regarding cause, site, onset, duration, and course

Desired Result: Rapid, accurate, and reproducible diagnosis

Learning Objective: Define the screening, examination, and laboratory analysis process that drives accurate and detailed uveitis diagnoses

#2 Identified Need: Selection of uveitis treatment based on cause and type

Desired Result: Selection of treatment options that are effective, safe, and appropriate for each type of uveitis patient

Learning Objective: Analyze the range of available and emerging treatment options for noninfectious and posterior noninfectious uveitis

#3 Identified Need: Create "best-match" treatment to minimize patient burden

Desired Result: Determine treatment that will best minimize patient burden and optimize outcomes

Learning Objective: Understand patient needs in selecting treatment to minimize patient burden while optimizing treatment outcomes

#4 Identified Need: Need for vigilant management to maximize chances of treatment success and reduce incidence of treatment-related adverse events

Desired Result: Improved health outcomes (inflammation management, vision restoration, alleviation of pain) with reduced risk and burden to patient

Learning Objective: To review practice guidelines and options for adjustment in cases where treatment is intolerable or ineffective

#5 Identified Need: Compare and differentiate three new technologies to manage posterior segment noninfectious uveitis

Desired Result: Improved health outcomes (inflammation management, vision restoration, alleviation of pain) with reduced risk and burden to patient

Learning Objective: Knowledge of recent pivotal clinical trial outcomes for new technologies to treat noninfectious posterior uveitis

OFF-LABEL USE STATEMENT

This work may discuss off-label uses of medications.

GENERAL INFORMATION

This CME activity is sponsored by the University of Florida College of Medicine and is supported by an unrestricted educational grant from ABBVIE.

The University of Florida College of Medicine designates this enduring material for a maximum of **1 AMA PRA Category 1 Credit™**. There is no fee to participate in this activity. In order to receive CME credit, participants should read the report, and then take the posttest. A score of 80% is required to qualify for CME credit. Estimated time to complete the activity is 60 minutes. On completion, take the test online at <https://cme.ufl.edu/online-cme/tadd/>

System requirements for this activity are:

For PC users:

Windows® 2000, XP, 2003 Server, or Vista; Internet Explorer® 6.0 or newer, or Mozilla® Firefox® 2.0 or newer (JavaScript™ and Java™ enabled).

For Mac® users:

Mac OS® X 10.4 (Tiger®) or newer; Safari™ 3.0 or newer, Mozilla® Firefox® 2.0 or newer; (JavaScript™ and Java™ enabled).

DATE OF ORIGINAL RELEASE

January 2021. Approved for a period of 12 months.

ACCREDITATION STATEMENT

This activity has been planned and implemented in accordance with the accreditation requirements and policies of the Accreditation Council for Continuing Medical Education (ACCME) through the joint providership of the University of Florida College of Medicine and Candeo Clinical/Science Communications, LLC. The University of Florida College of Medicine is accredited by the ACCME to provide continuing medical education for physicians.

CREDIT DESIGNATION STATEMENT

The University of Florida College of Medicine designates this enduring material for a maximum of **1 AMA PRA Category 1 Credit™**. Physicians should claim only the credit commensurate with the extent of their participation in the activity.

FACULTY AND DISCLOSURE STATEMENTS

No one else in a position to control content has any financial relationships to disclose.

CME ADVISORY COMMITTEE DISCLOSURE

Conflict of interest information for the CME Advisory Committee members can be found on the following website: <https://cme.ufl.edu/disclosure/>

Seenu Hariprasad, MD Shui-Chin Lee Professor of Ophthalmology and Visual Science; Chief, Vitreoretinal Service; Director, Clinical Research; Director, Fellowship in Vitreoretinal Diseases and Surgery; The University of Chicago Medicine & Biological Sciences. Dr. Hariprasad is a consultant for Allergan, Novartis, EyePoint Pharmaceuticals and Alimera Sciences. He is on the Speaker's Bureau for Allergan, Novartis, Alimera Sciences, EyePoint Pharmaceuticals, Spark Therapeutics and Regeneron Pharmaceuticals.

Michael Singer, MD Medical Center Ophthalmology Associates, San Antonio, TX. Dr. Singer received Grant/Research support from Allergan, Aerie, Genentech, Regeneron, EyePoint, Optos, Kodiak and Senju. He is a consultant for Allergan, Aerie, EyePoint Pharmaceuticals, Genentech, Regeneron. Dr. Singer serves on the Speaker's Bureau for Allergan, EyePoint Pharmaceuticals, Genentech, Regeneron, and Spark Therapeutics and is a Stock Shareholder in Nancoscope and Inflammasome.

Tom Albin, MD Bascom Palmer Eye Institute, Miami, FL. Dr. Albin is a consultant for Allegro Ophthalmics, Allergan, Beaver, Visitec, Adverum Biotechnologies, EyePoint Pharmaceuticals, Novartis, Santen Pharmaceuticals, Genentech, Valeant Pharmaceuticals, Notal Vision, Janssen Biotech, Regenex Bio and Clearside Biomedical.

Gibran Khurshid, MD, is an associate professor in the department of ophthalmology at the University of Florida College of Medicine. He states that in the past 12 months, he has not had a financial relationship with any commercial organization that produces, markets, resells, or distributes healthcare goods or services consumed by or used on patients relevant to this manuscript.

DISCLAIMER

Participants have an implied responsibility to use the newly acquired information to enhance patient outcomes and professional development. The information presented in this activity is not meant to serve as a guideline for patient care. Procedures, medications, and other courses of diagnosis and treatment discussed or suggested in this activity should not be used by clinicians without evaluation of their patients' conditions and possible contraindications or dangers in use, applicable manufacturer's product information, and comparison with recommendations of other authorities.

COMMERCIAL SUPPORTERS

This activity is supported by an unrestricted educational grant from ABBVIE.

an infectious condition. Ophthalmologists should ask about any prior inflammatory events or infections in the eye, such as herpes or varicella, as well as any known infectious diseases, such as tuberculosis or Lyme disease. Practitioners should ask about high-risk sexual behavior, which could put the patient at risk for syphilis or human immunodeficiency virus. Additionally, exposure to pets or other animals might suggest toxoplasmosis or toxocaraiasis. In a 2015 study by Bajwa et al, toxoplasmosis was the most common cause of posterior uveitis.¹² Practitioners should ask about recent illnesses or hospitalizations. Lyme disease, syphilis, tuberculosis, and sarcoidosis all have significant systemic ramifications that can contribute to uveitis. In adolescents and adult patients, it is very important to exclude syphilis.³ The patient's internist may be able to provide important background information that will help in the diagnosis.

Age range: Underlying conditions affecting uveitis etiologies or severity may appear more or less commonly depending on patient age. For instance, younger patients are more likely to have juvenile rheumatoid arthritis, Behçet's disease, or ankylosing spondylitis, whereas in older patients, it is important to rule out lymphoma or syphilis.¹⁴

Laboratory tests: Additionally, ophthalmologists can order a battery of laboratory tests to determine whether uveitis is caused by bacteria, virus, fungus, or another source. A thorough workup for uveitis would include a complete blood count as well as sedimentation rate. Other blood tests might include rheumatoid factor, antinuclear antibody to rule out rheumatoid arthritis, and angiotensin-converting enzyme for sarcoidosis.¹⁴ In younger patients with back pain, it would be helpful to test for HLA-B27 or a simple lumbo-sacral Xray to rule out ankylosing spondylitis. Brewerton ref If the patient has cats or dogs or has been exposed to other animals, the practitioner should test for toxoplasmosis or toxocaraiasis. A skin test, blood interferon-gamma release assay, or chest X-ray should be conducted to rule out tuberculosis.¹⁴ Additionally, imaging techniques such as fundus fluorescein angiography (FFA), indocyanine green angiography (ICG), ultrasonography (USG), and optical coherence tomography (OCT) may be used to shed light on the presence or nature of infection in the eye.¹¹

Idiopathic uveitis: As has been noted, up to half of uveitis cases will, after careful workup, be classified as idiopathic. However, it has been suggested that some "idiopathic" cases may reflect incomplete patient medical history or imperfect laboratory testing and may actually be uveitis secondary to sarcoidosis, tubulointerstitial nephritis, or ankylosing spondylitis.^{21,22}

TREATMENT CHALLENGES

The first goal of treatment is to suppress the inflammation and improve the patient's symptoms quickly. The second goal is to prevent recurrences and thereby prevent the damage to optical tissues that can lead to permanent vision loss.

Local or systemic treatment: In deciding whether to use local or systemic treatment, it is important to consider whether the uveitis is unilateral, bilateral, or unilateral alternating. In unilateral alternating disease, either eye may be affected by an attack, but only one eye is affected at a time, and the attacks are recurrent in nature. Local treatment is more likely to be used in unilateral uveitis.

Topical steroids are typically the initial treatment for noninfectious uveitis. Topical steroids have the advantage of being relatively benign and easy to discontinue. They also don't penetrate very far past the anterior chamber, which means that they will not make an infectious disease worse.

Because of their limited penetration, however, steroids have less efficacy in the posterior segment than other options, such as injections. For that reason, patients with noninfectious, locally-treated posterior segment uveitis are likely to be started on intravitreal steroids, most often in the form of the dexamethasone intravitreal implant, due to its proven efficacy and safety.¹⁵ The dexamethasone intravitreal implant is effective at high doses, but it has a short duration of efficacy. It peaks within two weeks of initiation, and the benefits last approximately 4 months. Like other steroids, the dexamethasone intravitreal implant can raise IOP, but the elevations do not appear to be cumulative.¹⁶

In cases where the uveitis is unilateral and patients continue to have recurrent flare-ups after initial therapy with an intravitreal steroid, the fluocinolone acetonide (FAC) intravitreal implant is often effective as maintenance therapy. Many practitioners will choose to start their patients with noninfectious uveitis on the dexamethasone intravitreal implant, and then, once the inflammation is controlled and any macular edema has resolved, they convert them to the FAC intravitreal implant, which is long-acting, even at low doses.¹⁷

Systemic treatment options include systemic corticosteroids, biologics such as adalimumab and infliximab, or an immunosuppressive agent such as methotrexate. Patients with bilateral symptoms may be prescribed systemic corticosteroids when topical corticosteroids are insufficient, or when the patient has a systemic disease that also requires therapy. Systemic therapy for noninfectious uveitis is highly effective but also has a significant side effect profile. Practitioners prescribing systemic therapy may wish to consult a rheumatologist, as these specialists have experience in dealing with the side effect profile of these drugs.¹⁴ Because every patient is different, the systemic therapies need to be tailored to the patient's circumstances and based on the etiology of their disease. Some patients may not be candidates for systemic therapy because they have contraindications to it, such as pregnancy, where the potential for drug teratogenicity must be taken into consideration; other patients may simply prefer local treatment. Additional considerations common with systemic therapies for uveitis are insurance coverage and cost.

Concerns with local treatments: With local therapies, the two most significant concerns are intraocular pressure (IOP) elevation and cataract. A study investigating the frequency and degree of ocular hypertension associated with sequential injections of the dexamethasone intravitreal implant found that the frequency of mild (≥ 23 mmHg) and moderate (≥ 25 mmHg) ocular hypertension increases with repeated injections, but the frequency of severe ocular hypertension (≥ 30 mmHg) remains comparable regardless of the frequency of injections. Therefore, if a patient does not have an IOP spike of above 30 mmHg after a single implant, it is unlikely that subsequent implants would cause such an IOP spike.²⁰ Despite the therapeutic benefits of the dexamethasone implant, temporary IOP spikes have been described in 27% to 32% of patients.¹⁶ The significance of these spikes in terms of long-term visual damage was assessed in a retrospective review of 306 charts of patients who received the dexamethasone implant for a variety of diagnoses, including posterior uveitis. Eligible patients were divided into cross-sectional and prospective groups depending on the following criteria:

- Cross sectional: IOP spikes ≥ 22 mmHg up to 16 weeks post-implant and OCT retinal nerve fiber layer (RNFL) imaging of both eyes performed ≥ 3 months after the IOP spike (N = 48)
- Prospective: OCT RNFL imaging performed within one year prior to dexamethasone implantation, IOP spike ≥ 22 mmHg up to 16 weeks after DEX implant, and OCT RNFL imaging performed ≥ 3 months after the IOP spike (N = 21)

Up to 48% of these patients had a prior history of glaucoma.¹⁶ In the cross-sectional group, IOP spikes ≥ 22 mmHg after dexamethasone implantation demonstrated no significant difference in average RNFL thickness when compared with the contralateral untreated eye regardless of treatment diagnosis, magnitude of IOP spike, or history of glaucoma. Similarly, the prospective group also demonstrated no significant differences in average RNFL thickness when comparing measurements before and at least 3 months after the IOP spike.¹⁶ This study showed that a temporary elevation of IOP after dexamethasone implantation does not appear to cause a meaningful change in RNFL thickness when treated with IOP-lowering drops, regardless of etiology or magnitude of IOP increase. Also, in this study, topical IOP-lowering drops seemed to be adequate in the management of temporary IOP spikes to prevent RNFL damage even in patients with a past ocular history of glaucoma.

In younger patients, it may be preferable to use topical therapy because of the risk of cataracts with intravitreal steroids. Conversely, inflammation itself can potentially cause cataract formation,¹² so it is worthwhile to involve these patients in a discussion of risks versus benefits. The concept of cataract surgery may be less daunting to patients older than 40 years, who are, in general, more likely to be concerned

about IOP. Regardless of the patient's age, it is critical to prevent recurrences of uveitis over time, because multiple recurrences can damage ocular structures and lead to visual decline. Further, the chronic macular edema associated with recurrent uveitis causes loss of retinal pigment epithelium, with deleterious consequences for visual acuity.

The selection of appropriate therapy for a patient with noninfectious posterior uveitis must be as individualized as the diagnosis. It may depend on the patient's medical and optical history, the method or frequency of administration, contraindications to systemic or local therapies, and other circumstances, including patient preferences. For many adult uveitis patients, balancing their treatment with their work responsibilities is an important issue. There is potentially a place for subtenon injections, especially for patients who have cystoid macular edema, there may be a need for it. The clinician must take all of these factors into consideration to best serve the patient's needs while at the same time, providing safe, effective, and durable relief of the symptoms of uveitis.

The Multicenter Uveitis Treatment Trial (MUST): MUST compared the FAc 0.59 mg insert with systemic therapy (initially prednisone with the addition of an immunosuppressive agent if required) over a 7-year period in 255 patients. After 2 years, there was little difference in best corrected visual acuity (BCVA) between the FAc implant and systemic treatment groups. After 4.5 years, the implant provided better control of inflammation.¹⁸ However, after 7 years, visual outcomes in 180 patients were better in the systemic therapy treatment group, although patients receiving systemic therapy had a higher rate of antibiotic-treated infections. At 7 years, 45% of eyes in the FAc implant group had undergone glaucoma surgery compared with 12% of eyes in the systemic therapy group. In phakic eyes, 90% of patients in the implant group had had cataract surgery versus 50% in the systemic therapy group. Kempen 2017 These results suggest that for the early years, local control works well. However, if patients have underlying conditions, such as systemic rheumatologic disease, it may be necessary eventually to convert them to systemic treatment.

With respect to IOP elevations with FAc therapy in MUST, IOP data were available for 249 patients.¹⁹ Overall, 65% of patients assigned to the implant versus 24% of patients assigned to systemic therapy experienced an IOP elevation of at least 10 mmHg above the baseline measurement within the first 2 years of follow-up. Over the 2 years, 69% of patients assigned to the implant received IOP-lowering therapy as compared to 26% in the systemic treatment arm ($P < 0.001$), and 32% of patients assigned to the implant versus 5% of patients assigned to systemic therapy received a surgical intervention ($P < 0.001$).¹⁹ For patients receiving implants, IOP elevations were common in the first year: 58% experienced an elevation of at least 10 mmHg. Incident IOP elevation of 10 mmHg or more occurred in 8 additional

patients after 12 months in the implant group. The median time from implant surgery to an IOP increase of at least 10 mmHg was 9 months in patients assigned to implants. In patients with bilateral implants, once an event occurred in one eye, the risk of an IOP elevation or of having IOP-lowering surgery was higher in the fellow eye.¹⁹ Twenty-seven (23%) patients assigned to implant developed glaucoma, 9 of which developed it in both eyes. With the exception of 4 eyes in 4 patients, all cases of glaucoma observed were in eyes that received an implant regardless of the original treatment assignment.¹⁹ In general, IOP response to steroids is relatively predictable. The majority of IOP responders present relatively early, after the second or third injection. Those who are not steroid responders early on are unlikely to become steroid responders later. Because of the potential for harm if left untreated, the MUST investigators recommended that all patients receiving the FAc implant should be evaluated for IOP at least every 6 weeks and possibly more frequently.¹⁹

CONCLUSION

Patients with noninfectious posterior uveitis are likely to require multiple office visits and coordination with several providers. Practitioners will need to compile and interpret different pieces of information from a variety of sources. The challenge is to coordinate this information to create a treatment plan that is not only efficacious, but workable. Newer therapies and better understandings of how to work with them have greatly improved disease management and prognosis for these patients. Uveitis patients now have more efficacious, safer, and less expensive treatment options, which offer a greater potential for preserving vision, independence, and quality-of-life over the long term.

REFERENCES

1. Allegri P, Rissotto R, Herbot CP, Murialdo U. CNS diseases and uveitis. *J Ophthalmic Vis Res.* 2011;6:284-308.
2. Bahadorani S, Krambeer C, Wannamaker K, et al. The effects of repeated Ozurdex injections on ocular hypertension. *Clin Ophthalmol.* 2018;12:639-42.
3. Bajwa A, Osmanzada D, Osmanzada S, et al. Epidemiology of uveitis in the mid-Atlantic United States. *Clin Ophthalmol.* 2015;9:889-901.
4. Barry RJ, Nguyen QD, Lee RW, et al. Pharmacotherapy for uveitis: current management and emerging therapy. *Clin Ophthalmol.* 2014;8:1891-911.
5. Bispo PJM, Davoudi S, Sahn ML, et al. Rapid detection and identification of uveitis pathogens by qualitative multiplex real-time PCR. *Invest Ophthalmol Vis Sci.* 2018;59(1):582-89.
6. Brewerton DA, Caffrey M, Nicholls A, Walters D, James DC. Acute anterior uveitis and HL-A 27. *Lancet.* 1973;302:994-96.
7. Choi RY, Rivera-Grana E, Rosenbaum JT. Reclassifying idiopathic uveitis: lessons from a tertiary uveitis center. *Am J Ophthalmol.* 2019;198:193-99.
8. Dick AD, Tundia N, Sorg R, et al. Risk of ocular complications in patients with noninfectious intermediate uveitis, posterior uveitis, or panuveitis. *Ophthalmology.* 2016;123:655-62.
9. Duplechain A, Conrady CD, Patel BC, et al. Uveitis. Updated 2019 Nov 25]. In: StatPearls [Internet]. Treasure Island (FL): StatPearls Publishing; 2020 Jan. www.ncbi.nlm.nih.gov/books/NBK540993.

10. Durrani OM, Tehrani NN, Marr JE, Moradi P, Stavrou P, Murray PI. Degree, duration, and causes of visual loss in uveitis. *Br J Ophthalmol.* 2004;88:1159-62.
11. Foster CS, Kothari S, Anesi SD, et al. The Ocular Immunology and Uveitis Foundation preferred practice patterns of uveitis management. *Surv Ophthalmol.* 2016;61(1):1-17.
12. Friedman DS, Holbrook JT, Ansari H, for the MUST Research Group. Risk of elevated intraocular pressure and glaucoma in patients with uveitis; results of the Multicenter Uveitis Steroid Treatment Trial. *Ophthalmology.* 2013;120(8):1571-79.
13. Han YS, Rivera-Grana E, Salec S, et al. Distinguishing uveitis secondary to sarcoidosis from idiopathic disease cardiac implications. *JAMA Ophthalmol.* 2018;136(2):109-15.
14. Jabs DA. Standardization of uveitis nomenclature for reporting clinical data. Results of the first international workshop. *Am J Ophthalmol.* 2005;140:509-16.
15. Jabs DA, Busingye J. Approach to the diagnosis of the uveitides. *Am J Ophthalmol.* 2013;156(2):228-36.
16. Jaffe GJ, Foster CS, Pavesio CE, et al. Effect of an injectable fluocinolone acetonide insert on recurrence rates in chronic noninfectious uveitis affecting the posterior segment. Twelve-month results. *Ophthalmology.* 2019;126:601-10.
17. Kempen JH, Altaweel MM, Holbrook JT, et al. Writing Committee for the Multicenter Uveitis Steroid Treatment (MUST) trial and Follow-up Study Research Group. Association between long-lasting intravitreal fluocinolone acetonide implant vs systemic anti-inflammatory therapy and visual acuity at 7 years among patients with intermediate, posterior, or panuveitis. *JAMA.* 2017;317(19):1993-2005.
18. Kohari S, Foster CS, Pistilli M, et al, for the SITE Research Group. The risk of intraocular pressure elevation in pediatric non-infectious uveitis. *Ophthalmology.* 2015;122(10):1987-2001.
19. Lee JH, Agarwal A, Mahendradas P, et al. Viral posterior uveitis. *Surv Ophthalmol.* 2017;62(4):404-45.
20. Lee JH, Mi H, Lim R, et al. Ocular autoimmune systemic inflammatory infectious study -report 3: posterior and panuveitis. *Ocul Immunol Inflamm.* 2019;27(1):89-98.
21. Lowder C, Belfort R Jr, Lightman S, et al. Ozurdex HURON Study Group. Dexamethasone intravitreal implant for noninfectious intermediate or posterior uveitis. *Arch Ophthalmol.* 2011;129:545-53.
22. Massa H, Papis SY, Adewoyin T, et al. Macular edema associated with non-infectious uveitis: pathophysiology, etiology, prevalence, impact and management challenges. *Clin Ophthalmol.* 2019;13:1761-77.
23. McCluskey P, Powell RJ. The eye in systemic inflammatory diseases. *Lancet.* 2004;364:2125-33.
24. McCluskey PJ, Towler HMA, Lightman S. Management of chronic uveitis. *BMJ.* 2000;320:555-58.
25. MUST Study Group. Benefits of systemic anti-inflammatory therapy versus fluocinolone acetonide intraocular implant for intermediate, posterior, and pan-uveitis: 54-month results of The Multicenter Uveitis Steroid Treatment Trial (MUST) and follow-up study. *Ophthalmology.* 2015;122(10):1967-75.
26. National Eye Institute Web Site. <http://www.nei.nih.gov/health/uveitis/uveitis.asp>. Accessed March 23, 2013.
27. Rosenbaum JT, Dick AD. The eyes have it: a rheumatologist's view of uveitis. *Arthritis Rheumatol.* 2018;70(10):1533-43.
28. Rothova A, Suttrop-Van Schulten MSA, Treffers WS, et al. Causes and frequency of blindness in patients with intraocular inflammatory disease. *Br J Ophthalmol.* 1996;80:332-36.
29. Sudharshan S, Ganesh SK, Biswas J. Current approaches in the diagnosis and management of posterior uveitis. *Indian J Ophthalmol.* 2010;58(1):29-43.

30. Taylor SRI, Lightman SL, Sugar EA, et al, for the Multicentre Uveitis Steroid Treatment (MUST) Trial Research Group. The impact of macular oedema on visual function in intermediate, posterior, and panuveitis. *Ocul Immunol Inflamm*. 2012;20(3):171-81.
31. Thorne JE, Suhler E, Skup M, et al. Prevalence of noninfectious uveitis in the United States: a claimed-base analysis. *JAMA Ophthalmol*. 2016;134(11):1237-45.
32. van Laar JAM, Rothova A, Missotten T, et al. Diagnosis and treatment of uveitis; not restricted to the ophthalmologist. *J Clin Transl Res*. 2015;2:94-99.
33. Wannamaker KW, Kenny S, Das R, et al. The effects of temporary intraocular pressure spikes after intravitreal dexamethasone implantation on the retinal nerve fiber layer. *Clin Ophthalmol*. 2019;13:1079-86.

New Options for Intravitreal Therapy



Seenu M. Hariprasad, MD

ABSTRACT

Uveitis is an inflammatory ocular condition that can lead to vision loss if left untreated. Accurate diagnosis involves determining whether the uveitis is infectious or noninfectious, as the two conditions are treated differently. For patients with noninfectious uveitis, after the initial inflammation has resolved with steroid treatment, the focus must be on preventing recurrence, which can cause permanent damage to ocular structures. Further treatment can be systemic or local: however long-term systemic treatment may result in contraindications, adverse effects, or resistance to therapy. Local steroid therapy, therefore, has an important role for suppressing inflammation while mitigating the risks of systemic steroids. In the past, uveitis patients had limited options for local treatment and often required multiple medications to address recurrent symptoms. More recently new treatments have emerged that are more effective and have fewer adverse effects over the long term. These include a dexamethasone intravitreal implant, a fluocinolone acetonide intravitreal implant, and a suprachoroidal injection of triamcinolone acetonide that is expected to be approved in 2020. In addition, various biologic response modifiers are being studied for the treatment of noninfectious uveitis, only one of which, adalimumab, has so far been approved for this indication. These new therapies offer the possibility of greater control of inflammation, fewer recurrences, and enhanced safety in the many patients presenting with noninfectious uveitis.

INTRODUCTION

Uveitis is a sight-threatening ocular condition characterized by inflammation and macular edema that may or may not reflect underlying systemic disease. In the US, uveitis accounts for approximately 30,000 new cases of blindness each year.¹ In up to one third of patients with uveitis, vision loss is exacerbated by the presence of macular edema.^{2,3}

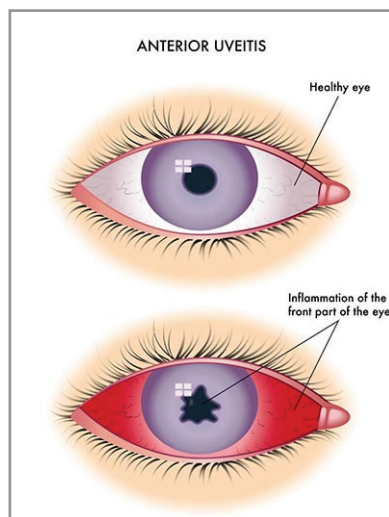


Figure 1: Photo of eye with uveitis

Uveitis is classified as anterior, intermediate, posterior, or pan-uveitis, according to the primary site of inflammation.⁴ In one study, 28% of patients with posterior uveitis developed macular edema.⁵

Uveitis may reflect one disease or a combination of several diseases, and the choice of treatment may depend on the type and extent of symptoms, patterns of recurrence, and the individual patient's need and preferences.

Clearly such a complex condition presents both diagnostic and treatment challenges. An initial step in diagnosis is to determine whether the uveitis is infectious or noninfectious in origin, in order to select the appropriate treatment, as the two conditions are treated differently. In addition to clinical examination and careful history, serology and/or imaging tests may be required for an accurate diagnosis.⁶ Some causes of infectious uveitis, such as toxoplasmosis or endogenous endophthalmitis, may be difficult to recognize, and PCR testing of ocular fluid may be required.⁷

LOCAL VS SYSTEMIC THERAPY IN THE TREATMENT OF NONINFECTIOUS UVEITIS

For the practitioner caring for a patient presenting with acute uveitis, it is essential to get the inflammation and macular edema under control; secondarily, it is important to prevent recurrence of the condition, as damage to ocular structures can occur with each recurrent episode. Currently the medical management of noninfectious uveitis affecting the posterior segment includes systemic administration of immunosuppressants or systemic or local administration of steroids. All of these have the ability to suppress inflammation in the back of the eye, and all are associated with varying degrees of ocular side effects. To achieve control initially, a course of systemic steroids is effective in most patients.⁸ However, it should be noted that in most cases uveitis is recurrent and will require long-term treatment. The long-term effects of systemic steroids are numerous and serious. Many patients develop resistance to long-term use of systemic steroids.⁹ In addition, many patients have contraindications to systemic treatment, such as pregnancy, and some patients who may be candidates for systemic treatment may refuse it simply because they have a

preference for local therapy. Local therapy with periocular or intravitreal administration of corticosteroid or the implantation of intraocular sustained-release delivery systems in the vitreous can provide therapeutically effective doses of drug to the posterior segment, thereby suppressing inflammation over the long term while decreasing the risks associated with systemic therapy.⁹

In the past, only systemic agents and off-label triamcinolone acetonide (TA) were available for the treatment of patients who required steroid therapy. Periocular or intravitreal injections had to be administered frequently, and repeated recurrences often resulted in poor long-term visual outcomes, as well as negatively impacting patients' quality of life.¹⁰ Frequent injections also carried potential risks, such as endophthalmitis. Efforts to improve the efficacy, durability, and safety of therapy have led to the development of newer agents designed to provide local steroid therapy to the eye for an extended period of time while mitigating the side effects associated with the systemic administration of corticosteroids.

Currently three new generation therapies offer improved options for local treatment. Two of these agents are relative newcomers to the uveitis market; the third is in development and is expected to be approved this year.

DEXAMETHASONE INTRAVITREAL IMPLANT (ABBVIE)

The dexamethasone intravitreal implant was the first steroid approved by the US Food and Drug Administration (FDA) for administration in the office setting.¹¹ It was approved in 2010 for the treatment of noninfectious uveitis affecting the posterior segment of the eye.¹² It is also indicated for the treatment of diabetic macular edema, as well as for macular edema following branch retinal vein occlusion or central retinal vein occlusion. It consists of a rod-shaped intravitreal implant that contains 0.7 mg dexamethasone in a sustained-release drug delivery system. The implant is preloaded into a single-use applicator and injected directly into the vitreous.

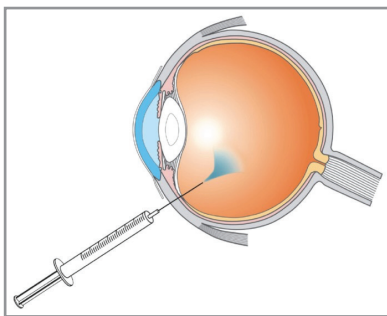


Figure 2: Illustration of the device and/or application procedure

The efficacy and safety of the dexamethasone intravitreal implant were established in a single 26-week multicenter, double-masked randomized clinical study that included 229 patients with noninfectious ocular

inflammation of the posterior segment, vitreous haze grade of > +1.5 on the 0-4 classification scale, and best corrected visual acuity (BCVA) of 10 to 75 letters on the Snellen eye chart.⁹ 2011 Seventy-seven patients received the a 0.7 mg dexamethasone intravitreal implant, 76 received a dexamethasone 0.35 mg implant, and 76 received sham injections. After a single injection, at the Week 8 primary end point, 47% of patients receiving the study drug reached a vitreous haze score of zero (no inflammation) vs 12% of patients in the sham injection group (P <0.001). In addition, the percentage of eyes achieving at least a 15-letter improvement from baseline BCVA was 2- to 6-fold greater in both dexamethasone implant groups than in the sham group throughout the study period and was statistically significant at all time points compared with sham.⁹

Contraindications to the dexamethasone intravitreal implant include ocular or periocular infections including most viral diseases of the cornea and conjunctiva, glaucoma, torn or ruptured lens capsule, and hypersensitivity. Adverse effects include those associated with ophthalmic steroids, including elevated intraocular pressure (IOP), and cataract formation.¹²

The dexamethasone intravitreal implant is a highly effective drug for controlling inflammation, but its effect peaks in the first 2 weeks post-injection; it has a relatively short duration of action, and symptoms may recur after approximately 4 months. For this reason, it is often used as initial treatment and then replaced by the fluocinolone acetonide (FAC) insert for longer-term maintenance.

FLUOCINOLONE ACETONIDE (EYE POINT PHARMACEUTICALS, WATERTOWN, MA)

Fluocinolone acetonide (FAC) 0.18 mg is a sustained-release corticosteroid intravitreal implant that was approved in 2018 for the treatment of chronic noninfectious uveitis affecting the posterior segment of the eye.¹³ This medication is not to be confused with an FAC 0.19 mg implant, Iluvien, licensed by Alimera Sciences, which is not currently FDA approved for treatment of uveitis. The implant discussed here, Yutiq, is the successor to an FAC implant⁽¹⁴⁾ that was approved in 2005. The older implant had a higher dose (0.59 mg) and had to be implanted surgically in the operating room.¹⁵ It is rarely used today because is invasive, has a poor side effect profile, and is very expensive. The newer compound is supplied in a preloaded 25-gauge needle applicator. It is designed to release 0.18 mg FAC into the eye at an initial rate of 0.25 mcg/day for a period of 36 months.³⁴ The FAC intravitreal implant can be administered in the physician's office.

The efficacy and safety of the FAC 0.18 mg implant were assessed in two parallel phase 3 double-masked, randomized

prospective studies.^{16,17} In both studies, patients with recurrent noninfectious posterior segment uveitis were randomized to the FAC 0.18 mg implant or sham injections. The primary endpoint was recurrence rate at 6 and 12 months. Both studies met their primary efficacy endpoint at both timepoints with statistical significance.

In the first study, 129 participants with noninfectious uveitis affecting the posterior segment in 6 countries were randomized to treatment; 87 patients were randomized to the FAC implant and 42 to sham injection. At 6 months, 27.6% of patients in the FAC group had a recurrence, compared with 95.5% in the sham group. Between 6 and 12 months, there was a slight increase in the recurrence rate in both groups, but it remained significantly lower in the FAC insert group compared with the sham group (P <0.001). At 12 months, patients in the FAC group had an average of 1.3 mm Hg IOP rise, compared with 0.2 mm Hg in the sham group. Cataract surgery was required in 33.3% of phakic patients in the FAC group compared with 5% in the sham group.¹⁶

Results were comparable in the second parallel phase 3 study. This was a prospective, multicenter, multinational, randomized, double-masked, sham-controlled 36-month trial.¹⁷ Eligible patients were randomized in a 2:1 ratio to receive either the FAC insert 0.18 g (N = 87) or sham injection (N = 42). The primary efficacy endpoint was the recurrence of uveitis within 6 months. The 6-month uveitis recurrence rate was 18.4% in the FAC group vs 78.6% in sham (P < 0.001). By 12 months, 27.6% of patients in the FAC group had a recurrence of inflammation, compared with 85.7% of patients in the sham group (P <0.001). In the FAC group, at 12 months there was a mean IOP increase of 1.3 ±3.6 mm Hg, compared with 0.2 ± 4.2 mm Hg in the sham group. By 12 months, ocular hypertensive medication had been used by 26.4% of patients treated with FAC, compared with 26.2% in the sham group. One patient receiving FAC required glaucoma surgery during the first 12 months. At 12 months, cataract surgery was required in 33.3% of phakic patients treated with FAC, compared to 5.0% in the sham group. The most common adverse events reported in the FAC treatment group were cataract formation and increases in IOP. In the sham group, they were macular edema and noninfectious endophthalmitis.¹⁷

SUPRACHOROIDAL ADMINISTRATION OF OCULAR CORTICOSTEROID (CLEARSIDE BIOMEDICAL, ALPHARETTA, GA AND BAUSCH & LOMB, BRIDGEWATER, NJ)

An investigational technique for delivering ocular corticosteroids is via suprachoroidal administration of triamcinolone acetonide (TA), known as CLS-TA.¹⁴ TA reduces inflammation in the eye as well as ocular edema and improves visual outcomes.¹⁸ The drug is provided with a prepackaged syringe containing a needle approximately 1000

µm in length.¹⁹ In this technique, 4 mg TA is injected into the suprachoroidal space 4 mm posterior to the limbus. The drug is quickly absorbed into posterior segment tissue, with no depot at the injection site, which allows for high concentrations at the target site while minimizing concentrations at anterior sites, thereby minimizing side effects. In preclinical studies, there were no adverse effects and no evidence of drug toxicity in a porcine model,²⁰ while in a study in New Zealand white rabbits, no toxic minimal amounts of TA were found in the lens and anterior segment following suprachoroidal injection compared with intravitreal administration, suggesting fewer ocular side effects. Systemic exposure also remained very low.²¹

In a small pilot study in patients with uveitis (N = 9), no ocular hypertension was seen over a 26-week observation period with the suprachoroidal injection.²² All eight efficacy-evaluable subjects had improvements in visual acuity. Four subjects, who did not need additional therapy, had on average a greater than 2-line improvement in visual acuity through week 26. Among the seven subjects who had macular edema at baseline, all had at least a 60-µm reduction in central subfield thickness (CST) at week 8 (mean reduction of 154 µm). Overall, a simple suprachoroidal injection of TA was well tolerated and no increases in IOP were observed.²² Results of this study suggested that suprachoroidal TA injection has the potential for good control of inflammation with less risk for cataract and glaucoma development. This hypothesis was tested in the PEACHTREE study, with 160 patients.

PEACHTREE was a phase 3 randomized, controlled, double-masked multicenter trial.²³ The primary efficacy endpoint was the proportion of patients in each arm gaining ≥15 ETDRS letters in BCVA from baseline at week 24. The secondary endpoint was reduction from baseline in CST at week 24. There were 96 patients in the CLS-TA study arm and 64 patients received the sham procedure. Patients received two injections, at day 0 and week 12. Suprachoroidal CLS-TA met the primary study endpoint, with a significantly greater proportion of subjects vs control having ≥15 ETDRS BCVA gain at 6 months (P <0.001)

Table 1

Drug	Indication	Duration of Action	Costs***	Other Comments
Dexamethasone intravitreal implant 0.7 mg	Noninfectious uveitis affecting the posterior segment of the eye; diabetic macular edema	4-6 months	\$2000	Effective in achieving early resolution of symptoms
Fluocinolone acetonide intravitreal implant 0.18 mg	Chronic noninfectious uveitis affecting the posterior segment of the eye	12-36 months	\$7000	Has the longest duration of action and can be used for long-term maintenance
CLS-TA triamcinolone intravitreal implant 4 mg	Macular edema associated with uveitis*	Up to 12 months **	\$40	Appears to be effective in resolving macular edema, the primary cause of vision loss in noninfectious uveitis.

*Pending FDA approval.

**6 months in the PEACHTREE trial, and an additional 6 months in MAGNOLIA; pending FDA approval.

***Published prices, does not reflect insurance or Medicare coverage cost

at week 24, meaning that patients were able to read ETDRS letters half the size after study therapy compared with study entry. At week 24, CST was reduced from baseline in CLS-TA patients by 153 µm compared with a reduction of 18 µm in the control group, a difference of 135 µm (P < 0.001). The overall safety profile was favorable, with low rates of IOP and cataract and no serious adverse events attributable to suprachoroidal CLS-TA. Longer-term outcomes are being assessed in the extension MAGNOLIA study (Clinical-Trials.gov identifier, NCT02374060). Two smaller studies, AZALEA and DOGWOOD,²⁴ showed similar results. Food and Drug Administration approval is pending for this new treatment for noninfectious uveitis, which is expected to be indicated as well for macular edema, the principal cause of vision loss in uveitis.²³

It is important to know how, when, and for which patients each of these new therapies is appropriate. The table below may be helpful in comparing them.

Therapies may be individualized according to particular patients' needs and preferences. For example, a patient who has done well on shorter acting steroids and did not have an uncontrollable IOP response may respond well to FAC 0.18 mg. Moreover, these agents are not necessarily mutually exclusive. Some patients may require a combination of local and systemic therapies, and even when local therapies alone are chosen, the practitioner may select one therapy to initiate treatment and another for longer-term treatment.

The experienced ophthalmologic surgeon should not find any of the intravitreal agents difficult to administer. However, before administering any of these agents for the first time, it may be useful to review on-line videos showing administration techniques or even to practice administering the agent using dummy eyes.

BIOLOGICS

The aim of therapy with biologic response modifiers (biologics) is to regulate the inflammatory process by suppressing immune effector responses. Biologics are used off-label for uveitis, except for adalimumab (AbbVie), which was approved in 2016 for

the treatment of noninfectious uveitis.²⁵ Several biologics have been proposed for noninfectious uveitis. These include monoclonal antibodies, soluble receptors, cytokines, and natural cytokine antagonists.

TNF-α is a pro-inflammatory cytokine that exacerbates immune disease including uveitis. Molecules that block TNF-α have been found to be effective in modulating the immune response and in reducing inflammation in patients with uveitis.²⁶ The most commonly used TNF-α inhibitors are infliximab and adalimumab. Infliximab, a chimeric IgG1 monoclonal antibody, impairs the binding of TNF-α to its receptor. The efficacy and safety of infliximab for uveitis have been investigated in patients with refractory uveitis²⁷ and with Behcet's disease²⁸. In the refractory uveitis trial, remission of uveitis was achieved in 60% of patients treated with infliximab in the first year and was maintained by 60% of those patients in the second year.²⁷ However, intravitreal infliximab causes immunogenic reactions and may cause retinotoxicity.²⁹

Adalimumab is a humanized recombinant IgG1 monoclonal antibody that binds to human TNF-α with high affinity. It has been studied in patients with juvenile idiopathic uveitis, in which it has been shown to be more efficacious than infliximab at maintaining remission.³⁰ A 2016 study showed adalimumab and infliximab to have comparable efficacy and incidence of serious adverse effects in refractory uveitis.³¹ However, while they show promise, TNF inhibitors may also increase risk of infections, including tuberculosis, and may reactivate chronic viral infections, as well as malignancy, and congestive heart failure.³²

In addition to the TNF inhibitors, biologics that have been investigated for this disease include the lymphocyte inhibitors daclizumab, rituximab, abatacept, basiliximab, and specific receptor antagonists, including anakinra, canakinumab, gevokizumab, tocilizumab, alemtuzumab, and efalizumab.³³ Rituximab has been studied in uveitis patients with juvenile idiopathic arthritis.³⁴ The IL-2 receptor daclizumab has been successful in treating patients with uveitis refractory to standard therapy.³⁵

Biologics may benefit some but not all patients with uveitis. They appear to be most useful in treating concomitant ophthalmic and systemic inflammation, such as in patients with rheumatoid arthritis, juvenile idiopathic arthritis, ankylosing spondylitis, Behçet's disease, or inflammatory bowel disease.³³ However, biologics are currently not considered to be first-line treatment because of the lack of long-term safety data. In addition their high cost is prohibitive.³³ Further randomized controlled trials evaluating the use of biologics in noninfectious uveitis are needed before they can be considered the optimal therapy for this condition.

CONCLUSION

Chronic noninfectious posterior uveitis can lead to permanent impairment or loss of vision. In the past, patients with chronic uveitis in the posterior segment were burdened with multiple medications, frequent office visits, often to more than one specialist, and high co-pays for those visits. While management of chronic noninfectious posterior uveitis remains challenging, new generation implants offer greatest efficacy and minimal adverse events compared with earlier treatment modalities. New medications and new administration techniques make it possible to continue local treatment without having to advance to systemic steroids or immunological options, with their greater potential for adverse effects over the long term. With the new generation of medications, we are closer to the goal of achieving effective control of inflammation, reducing recurrences, and enhancing safety, thereby improving ocular outcomes and quality of life in patients with chronic posterior uveitis.

REFERENCES

- Allergan Receives FDA Approval for OZURDEX® as Treatment Option for Noninfectious Uveitis Affecting the Posterior Segment of the Eye. Press Release. Available at: <https://www.businesswire.com/news/home/20100924005874/en/Allergan-Receives-FDA-Approval-OZURDEX%C2%AE-Treatment-Option>. Accessed April 14, 2020.
- Al-Rayes H, Al-Swailem R, Al-Balawi M, et al. Safety and efficacy of infliximab therapy in active Behçet's uveitis: an open-label trial. *Rheumatol Int*. 2008;29(1):53-57.
- Bispo PJM, Davoudi S, Sahn ML, et al. Rapid detection and identification of uveitis pathogens by qualitative multiplex real-time PCR. *Invest Ophthalmol Vis Sci*. 2018;59:582-589.
- Callanan D, Nguyen QD, Suhler EB, et al. Reduced risk of recurrence of noninfectious posterior segment uveitis after 0.18 mg fluocinolone acetonide insert: Randomized Trial. *Am J Ophthalmol*. 2020; S0002-9394(20)30064-7.
- Clearside Biomedical. Data on file. April 2018.
- Dick AD. The treatment of chronic uveitic macular oedema. *Br J Ophthalmol*. 1994;78:1-2.
- Edelhauser HF, Verhoeven RS, Burke B, et al. Intraocular distribution and targeting of triamcinolone acetonide suspension administered into the suprachoroidal space. *Invest Ophthalmol Vis Sci*. 2014 ; 55: 5259.
- EyePoint Pharmaceuticals Receives FDA Approval of YUTIQ™ (fluocinolone acetonide intravitreal implant) 0.18 mg. Available at: <http://investors.psvida.com/news-releases/news-release-details/eyepoint-pharmaceuticals-receives-fda-approval-yutiqt> Accessed April 14, 2020.
- Giganti M, Beer PM, Lemanski N, et al. Adverse events after intravitreal infliximab (Remicade). *Retina*. 2010;30:71-80.
- Gilger BC, Abarca EM, Salmon JH, Patel S. Treatment of acute posterior uveitis in a porcine model by injection of triamcinolone acetonide into the suprachoroidal space using microneedles. *Invest Ophthalmol Vis Sci*. 2013 ; 54: 2483-2492.
- Goldstein DA, Do D, Noronha G, et al. Suprachoroidal corticosteroid administration: a novel route for local treatment of noninfectious uveitis. *Transl Vis Sci Technol*. 2016; 5:14.
- Heiligenhaus A, Miserocchi E, Heinz C, et al. Treatment of severe uveitis associated with juvenile idiopathic arthritis with anti-CD20 monoclonal antibody (rituximab). *Rheumatology*. 2011;50: 1390-1394.
- HUMIRA (adalimumab). Prescribing Information. AbbVie Inc. N Chicago, IL; 2020.
- Jabs DA. Standardization of uveitis nomenclature for reporting clinical data. Results of the first international workshop. *Am J Ophthalmol*. 2005;140:509-516.
- Jabs DA, Akpek EK. Immunosuppression for posterior uveitis. *Retina*. 2005;25(1):1-18.
- Kok H, Lau C, Maycock N, et al. Outcome of intravitreal triamcinolone in uveitis. *Ophthalmology*. 2005;112:1916-1921.
- Lardenoye CW, van Kooij B, Rothova A. Impact of macular edema on visual acuity in uveitis. *Ophthalmology*. 2006;113:1446-1449.
- Lin P. Infectious uveitis. *Curr Ophthalmol Rep*. 2015;3(3):170-183.
- Lowder C, Belfort R Jr, Lightman S, et al. Ozurdex HURON Study Group. Dexamethasone intravitreal implant for noninfectious intermediate or posterior uveitis. *Arch Ophthalmol*. 2011; 129:545-553.
- Nguyen QD, Callanan D, Dugel P, et al. Treating chronic noninfective posterior segment uveitis: the impact of cumulative damage. Proceedings of an expert panel round table discussion. *Retina*. 2006; suppl 1:1-16.
- Nussenblatt RB. The natural history of uveitis. *Int Ophthalmol*. 1990; 14: 303-308.
- Nussenblatt RB, Peterson JS, Foster CS, et al. Initial evaluation of subcutaneous daclizumab treatments for noninfectious uveitis: a multicenter noncomparative interventional case series. *Ophthalmology*. 2005;112(5):764-770.
- OZURDEX (dexamethasone intravitreal implant) Highlights of Prescribing Information. Allergan USA, Inc. Madison, NJ; 2018.
- Pasadhika S, Rosenbaum JT. Update on the use of systemic biologic agents in the treatment of noninfectious uveitis. *Biologics: Targets and therapy*. 2014;8:67-81.
- Rabinovich CE. Use of tumor necrosis factor inhibitors in uveitis. *Curr Opin Rheumatol*. 2007; 19(5):482-486.
- RETISERT™ (fluocinolone acetonide intravitreal implant) 0.59 mg prescribing information. Bausch & Lomb Inc. Bridgewater, NJ; 2019.
- Rifkin LM, Birnbaum AD, Goldstein DA. TNF inhibition for ophthalmic indications: current status and outlook. *BioDrugs*. 2013 Aug;27(4):347-57.
- Rothova A, Suttorp-van Schulten MSA, Treffers WF, et al. Causes and frequency of blindness in patients with intraocular inflammatory disease. *Brit J Ophthalmol*. 1996;80:332-336.
- Simonini G, Taddio A, Cattalini M, et al. Prevention of flare recurrences in childhood-refractory chronic uveitis: an open-label comparative study of adalimumab versus infliximab. *Arthritis Care Res*. 2011;63(4):612-618.
- Suhler EB, Smith JR, Giles TR, et al. Infliximab therapy for refractory uveitis: 2-year results of a randomized, prospective clinical trial. *Arch Ophthalmol*. 2009;27(6):819-822. Research letter.
- Vallet H, Seve P, Biard L, et al. Infliximab versus adalimumab in the treatment of refractory inflammatory uveitis: a multicenter study from the French Uveitis Network. *Arthritis Rheumatol*. 2016;68(6):1522-1530.
- Yeh S, Khurana RN, Shah M, et al, for the PEACHTREE Study Investigators. Efficacy and safety of suprachoroidal CLS-TA for macular edema secondary to noninfectious uveitis: Phase 3 randomized trial. *Ophthalmology*. 2020; e-pub ahead of print.
- Yeh S, Kurup SK, Wang SC, et al. DOGWOOD Study Team. *Retina*. 2019;39(10):1880-1888.
- YUTIQ™ (fluocinolone acetonide intravitreal implant) 0.18 mg, for intravitreal injection. Full Prescribing Information. EyePoint Pharmaceuticals US, Inc. Watertown, MA. 2018.
- Yeh S, Khurana RN, Shah M, et al, for the PEACHTREE Study Investigators. Efficacy and safety of suprachoroidal CLS-TA for macular edema secondary to noninfectious uveitis: Phase 3 randomized trial. *Ophthalmology*. 2020; e-pub ahead of print.
- Yeh S, Kurup SK, Wang SC, et al. DOGWOOD Study Team. *Retina*. 2019;39(10):1880-1888.
- YUTIQ™ (fluocinolone acetonide intravitreal implant) 0.18 mg, for intravitreal injection. Full Prescribing Information. EyePoint Pharmaceuticals US, Inc. Watertown, MA. 2018.

EXAMINATION QUESTIONS

Technological Advances in Drug Delivery to Treat Noninfectious Posterior Segment Uveitis

This CME activity is sponsored by the University of Florida College of Medicine and is supported by an unrestricted educational grant from AbbVie. Participants must score at least 80% on this exam in order to receive credit. The University of Florida College of Medicine designates this enduring material for a maximum of 1 AMA PRA Category 1 Credit™. To take this exam and obtain credit, please take the test online at <https://cme.ufl.edu/online-cme/tadd/>. Expires: December 31, 2021.