

The Airway and Trauma Anesthesia

D. John Doyle MD PhD
Department of General Anesthesiology
Cleveland Clinic Foundation
9500 Euclid Avenue E31
Cleveland, Ohio, USA 44195
Email doylej@ccf.org
Tel 216-444-1927
Fax 216-444-9247

2011Edition

Loss of the airway is an immediately life-threatening potential complication of any trauma situation. Consequently, airway assessment and management of patients suffering major trauma is always a top priority, and maintaining oxygenation and ventilation are critical first steps in managing any trauma patient, especially if the patient has sustained a head injury or an injury to any airway structures. Similarly, patients who are unconscious or have signs suggestive of respiratory insufficiency (like tachypnea or stridor) require immediate attention.

Although any patient who is awake, alert and able to talk without difficulty likely has a patent airway, investigations to rule out injury to airway or respiratory structures may still be needed. Most trauma patients are given supplemental oxygen as determined by vital signs (especially by pulse oximetry) and physical exam.

Tracheal intubation is usually considered to be the gold standard for airway management in many patients with severe trauma, since it allows for protection of the airway from gastric material, allows for high concentrations of oxygen to be delivered, allows for positive pressure ventilation, allows for the administration of PEEP in patients with acute lung injury, and allows for hyperventilation in patients with increased ICP. However, despite the importance of tracheal intubation in this setting, for a variety of reasons achieving tracheal intubation may sometimes be difficult in the trauma setting: adequate pre-oxygenation may not be possible, particularly in agitated patients or in patients with facial injuries; cervical spine immobilization may make laryngoscopy difficult; and the presence of oropharyngeal vomitus, blood, tissue debris and edema may all contribute to poor visualization of the laryngeal structures.

Trauma patients may have an uncleared or unstable cervical spine with spinal cord at risk of injury from atlanto-occipital motion during laryngoscopy. In one airway management method frequently used in this setting, following anesthesia induction, one assistant maintains in-line stabilization (not traction) with the occiput held firmly to the backboard (hands are placed along the side of the head with fingertips on the mastoid holding the occiput down) while a second assistant applies cricoid pressure. The posterior portion of the cervical collar remains in place. Unfortunately, this arrangement limits attainment of the "sniffing" position and makes laryngoscopy more demanding. Fortunately, advanced airway devices like the Bullard laryngoscope or the GlideScope can be very helpful in intubating when the patient is not in the "sniffing" position. One common alternative to this arrangement is awake fiberoptic intubation and awake positioning. Here, the patient is given general anesthesia only when positioned correctly and found to be neurologically intact.

In this presentation we consider the following scenarios:

- **Closed-Head Injury/Intoxication**
- **Cervical Spine injury**
- **Airway Disruption**
- **Airway Compression**
- **Maxillary-Facial Trauma Algorithm**

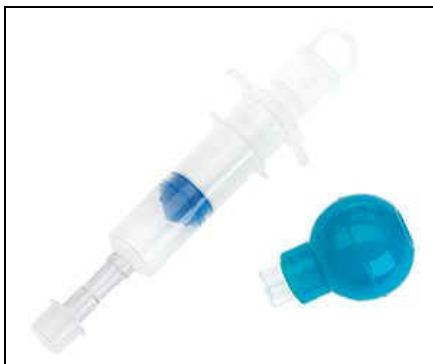The ASA difficult airway algorithm is a useful starting point to consider in airway management in the trauma patient. Table 1 lists the eleven for the components of the airway examination recommended ASA difficult airway algorithm. Table 2 lists some suggested contents of difficult airway box that can be useful in the trauma setting. Table 3 lists some airway management techniques for difficult intubation and difficult ventilation.

Table 1: Eleven Step Airway Examination [ASA Difficult Airway Algorithm 2003 Edition]

Step	Airway Examination Component	Non-reassuring Findings
1	Length of upper Incisors	Relatively long
2	Maxillary–mandibular incisor relationship	Prominent “overbite”
3	Ability To prognath jaw	Unable
4	Interincisor distance	< 3 cm
5	Visibility of uvula	Mallampati class III/IV
6	Shape of palate	Highly arched or narrow
7	Mandibular space compliance	Stiff, indurated, noncompliant
8	Thyromental distance	< 3 “normal finger” breadths
9	Length of neck	Short
10	Thickness of neck	Thick
11	ROM of head & neck Note: Cannot examine ROM in unstable C-spine patients!	Incomplete ROM. Assume incomplete ROM in C-spine (unless cleared)

Table 2: Suggested Contents of Difficult Airway Portable Storage Unit

1	Rigid laryngoscope blades of alternate design and size from those routinely used; this may include a rigid fiberoptic laryngoscope.
2	Tracheal tubes of assorted sizes
3	Tracheal tube guides. Examples include (but are not limited to) semi rigid stylets, ventilating tube changer, light wands, and forceps designed to manipulate the distal portion of the ETT.
4	Laryngeal mask airways of assorted sizes; this may include the intubating laryngeal mask airway and the LMA Proseal™ (<i>LMA North America, Inc., San Diego, CA</i>)
5	Flexible fiberoptic intubation equipment
6	Retrograde intubation equipment
7	At least one device suitable for emergency noninvasive airway ventilation. Examples include (but are not limited to) an esophageal-treacheal combitube (<i>Kendall-Sheridan Catheter Corp., Argyle, NY</i>), a hollow jet ventilation stylet, and a transtracheal jet ventilator.
8	Equipment for an emergency invasive airway (e.g., cricothyrotomy)
9	An exhaled CO2 detector + Esophageal Detector Device (S.I.B.)*
The items listed in this table represent suggestions. The contents of the portable storage unit should be customized* to meet the specific needs, preferences, and skills of the practitioner and healthcare facility.	



Esophageal Detector Device (from Ambu)

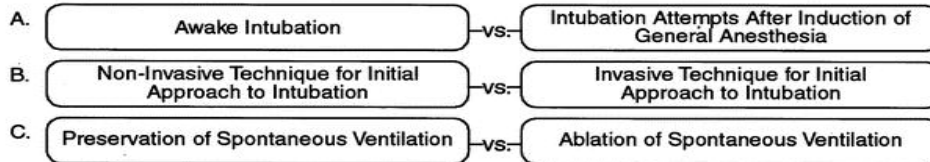
Table 3: Techniques for Difficult Airway Management

Technique of Difficult Intubation	Techniques for Difficult Ventilation
Alternative laryngoscope blades	Esophageal-tracheal Combitube (ETC)
Awake intubation	Intratracheal jet stylet
Blind intubation (oral or nasal)	Laryngeal mask airway (LMA)
Fiberoptic intubation (FOB)	Oral & nasopharyngeal airways
Intubating stylet or tube changer	Rigid ventilating bronchoscope
LMA as an intubating conduit	Invasive airway access
Light wand	Transtracheal jet ventilation (TTJV)
Retrograde intubation	Two-person mask ventilation
Invasive “surgical airway” access (e.g. Cricothyroidotomy kit)	Invasive “surgical airway” access (e.g. Cricothyroidotomy kit)
<p><i>This table displays commonly cited techniques. It is not a comprehensive list. The order of presentation does not imply preference for a given technique or sequence of use. Combinations of techniques may be employed. The techniques chosen by the practitioner in a particular case will depend upon specific needs, preferences, skills, and clinical constraints.</i></p>	

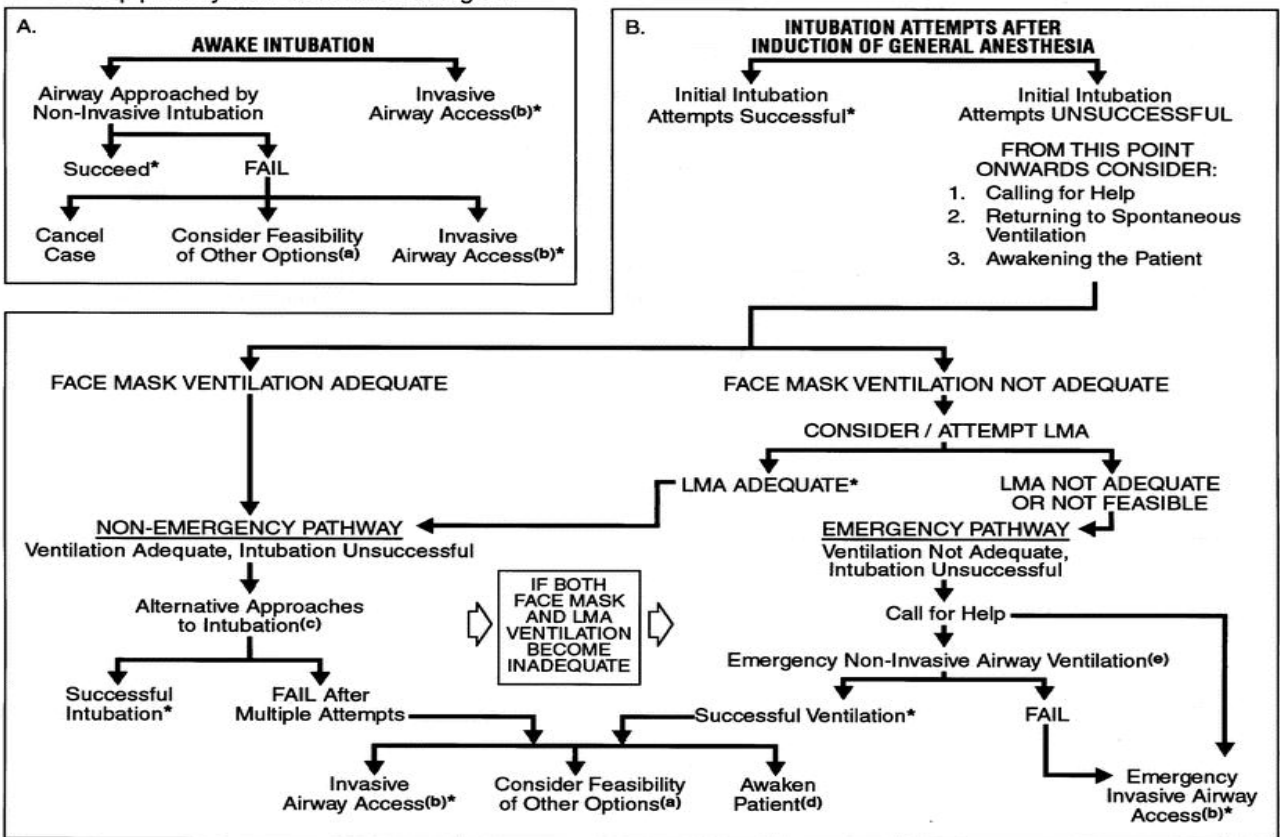
In addition to the above, a number of clinicians have had a favorable experience in using the **GlideScope Video Laryngoscope** in a difficult airway setting. The GlideScope is a novel system for laryngoscopy and tracheal intubation that utilizes a video camera embedded into a plastic laryngoscope blade. The blade is 14 mm wide at its maximum width and bends 60 degrees at the mid-line. This configuration was designed with the intent of providing a superior, unobstructed view to that obtained with a conventional laryngoscope. For more information go to www.glidescope.net

DIFFICULT AIRWAY ALGORITHM

1. Assess the likelihood and clinical impact of basic management problems:
 - A. Difficult Ventilation
 - B. Difficult Intubation
 - C. Difficulty with Patient Cooperation or Consent
 - D. Difficult Tracheostomy
2. Actively pursue opportunities to deliver supplemental oxygen throughout the process of difficult airway management
3. Consider the relative merits and feasibility of basic management choices:



4. Develop primary and alternative strategies:



* Confirm ventilation, tracheal intubation, or LMA placement with exhaled CO₂

a. Other options include (but are not limited to): surgery utilizing face mask or LMA anesthesia, local anesthesia infiltration or regional nerve blockade. Pursuit of these options usually implies that mask ventilation will not be problematic. Therefore, these options may be of limited value if this step in the algorithm has been reached via the Emergency Pathway.

b. Invasive airway access includes surgical or percutaneous tracheostomy or cricothyrotomy.

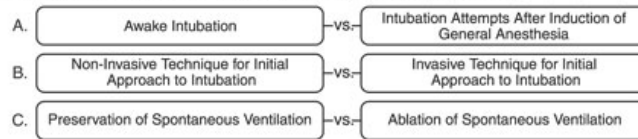
c. Alternative non-invasive approaches to difficult intubation include (but are not limited to): use of different laryngoscope blades, LMA as an intubation conduit (with or without fiberoptic guidance), fiberoptic intubation, intubating stylet or tube changer, light wand, retrograde intubation, and blind oral or nasal intubation.

d. Consider re-preparation of the patient for awake intubation or canceling surgery.


e. Options for emergency non-invasive airway ventilation include (but are not limited to): rigid bronchoscope, esophageal-tracheal combitube ventilation, or transtracheal jet ventilation.

2003 DIFFICULT AIRWAY ALGORITHM (MODIFIED FOR TRAUMA)

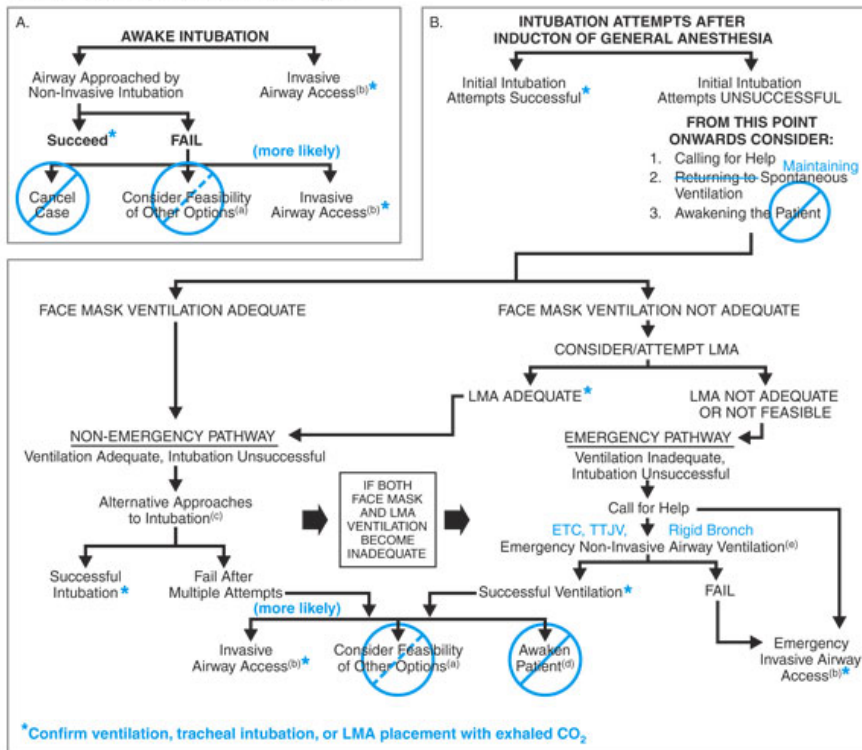
- Assess the likelihood and clinical impact of basic management problems.
 - Difficult Ventilation
 - Difficult Intubation
 - Difficulty with Patient Cooperation or Consent
 - Difficult Tracheostomy
- Actively pursue opportunities to deliver supplemental oxygen throughout the process of difficult airway management.
- Consider the relative merits and feasibility of basic management choices:



DIFFICULT INTUBATION



- Develop primary and alternative strategies:



- *Confirm ventilation, tracheal intubation, or LMA placement with exhaled CO₂
- Other options include (but are not limited to): surgery utilizing face mask or LMA anesthesia, local anesthesia infiltration or regional nerve blockade. Pursuit of these options usually implies that mask ventilation will not be problematic. Therefore, these options may be of limited value if this step in the algorithm has been reached via the Emergency Pathway. Judgment required. Rarely appropriate for trauma patients.
 - Invasive airway access includes surgical or percutaneous tracheostomy or cricothyrotomy.
 - Alternative non-invasive approaches to difficult intubation include (but are not limited to): use of different laryngoscope blades, LMA as an intubation

- conduit (with or without fiberoptic guidance), fiberoptic intubation (FOB), intubation stylet or tube changer (airway exchange catheter, AEC) light wand, retrograde intubation, and blind oral or nasal intubation.
- Consider re-preparation of the patient for awake intubation or canceling surgery. Rarely applicable in the trauma patient.
- Options for emergency non-invasive airway ventilation include (but are not limited to): rigid bronchoscope (Rigid Bronch), esophageal-tracheal combitube ventilation (ETC), or transtracheal jet ventilation (TTJV).
- Extubation strategies include: evaluation of the airway with FOB and extubation over an airway exchange catheter (AEC).

Modifications of the ASA DA Algorithm for Trauma (shown on above algorithm)

- A. Stopping to come back another day is seldom an option with trauma.
- B. A surgical airway may be the first/best choice in certain conditions.
- C. An awake ETT technique should be chosen in a DA patient providing the patient is cooperative, stable, and spontaneously ventilating.
- D. If the patient becomes uncooperative/combative general anesthesia (GA) may need to be administered — but if the airway is difficult, spontaneous ventilation (SV) should be continued (if possible).

E. **Awake limb of the ASA Algorithm—Trauma Notes.** An awake intubation technique is recommended for all trauma patients with a recognized difficult airway.... Providing the patient is cooperative, stable, and maintains spontaneous ventilation and adequacy of O₂ saturation. The ASA DA Algorithm does not endorse any particular airway technique. However, it does emphasize that the patient must be properly prepared (mentally & physically) for an awake technique.

F. **Anesthetized or uncooperative limb of ASA DA Algorithm — Trauma Notes.** There are three common conditions when the need arises to intubate the trachea of an unconscious or anesthetized trauma patient with a DA: [1] Clinician fails to recognize a difficult airway in preoperative evaluation prior to the induction of anesthesia. [2] The DA patient is already unconscious prior to being assessed by the trauma anesthesiologist. [3] The patient obviously has a DA, but is hemodynamically unstable (e.g., following trauma) or absolutely refuses to cooperate with an awake intubation (e.g., child, mentally retarded, drugged, or head-injured adult).

Once the patient is anesthetized or is rendered apneic or presents comatose and the trachea cannot be intubated, O₂, enriched mask ventilation (MV) is attempted.

If MV adequate, a number of intubation techniques may be employed. Techniques allowing continuous ventilation during airway manipulations are favored over those requiring an interruption of mask ventilation (e.g., FOB, via an LMA or an airway intubating mask, with self-sealing diaphragm).

Alternatively, techniques requiring a cessation of ventilation (at least temporarily) can be employed. These techniques are relatively contraindicated for patients with large right-to-left transpulmonary shunt, or decreased FRC.

G. **Confirmation of endotracheal tube (ETT) position.** Immediately after the patient's trachea is intubated, one must confirm ETT position with end-tidal CO₂ measurement. If end-tidal CO₂ measurement is unavailable, Wee's esophageal detector device (EDD) is reasonably reliable (close to 100% sensitive and specific).

H. **Extubation or ETT change of the DA.** If the conditions that caused the airway to be difficult to intubate still exist at the time of extubation, or if new DA conditions exist (e.g., airway edema, halo), then the trachea should be extubated over an AEC and or with the assistance of a FOB.

ASA DA Algorithm Applied to Specific Trauma Conditions

Closed-Head Injury/Intoxication

CLOSED HEAD INJURY / INTOXICATION

At left: CT of brain demonstrating severe closed- head injury with right temporoparietal subdural hematoma.

General Considerations

If DA, do an awake intubation, provided the patient is cooperative, stable, maintains SV and **has a GCS > 9**.

Key Questions:

How severe?

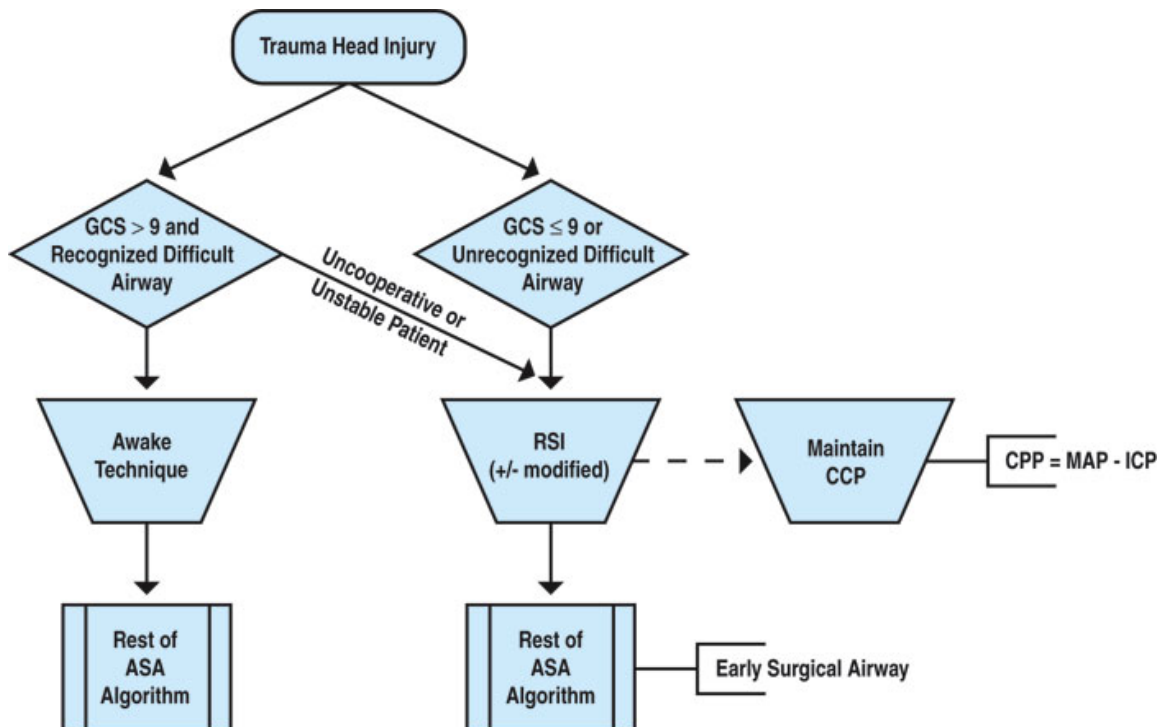
- GCS \leq 9 = RSI (\pm modified, i.e., cricoid pressure, \pm PPV)
- GCS > 9 = Awake option

Cooperative? If yes, do awake technique.

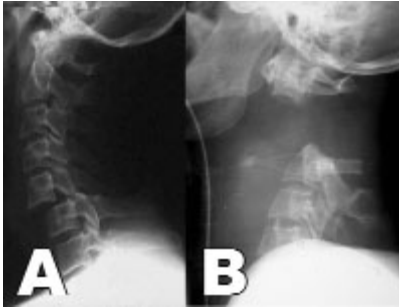
Key Management Points:

- Keep CPP > 70
- Avoid hypoxia
- Expedite airway management (*may need to temporarily hyperventilate*)

Closed Head Injury Algorithm



Cervical Spine injury



CERVICAL SPINE INJURY

A. Lateral C-spine X-ray showing C5-6 bifacet dislocation.

B. Lateral C-spine X-ray showing atlanto-occipital dislocation.

General Considerations

If DA, do an awake intubation, provided the patient is cooperative, stable, maintains SV, **especially if the patient has neurological symptoms from spinal cord injury (SCI).**

Key Questions:

Does the rest of the airway examination (HMD < 6 cm, Mallampati Class IV, small mouth) predict a DA? If yes, do awake.

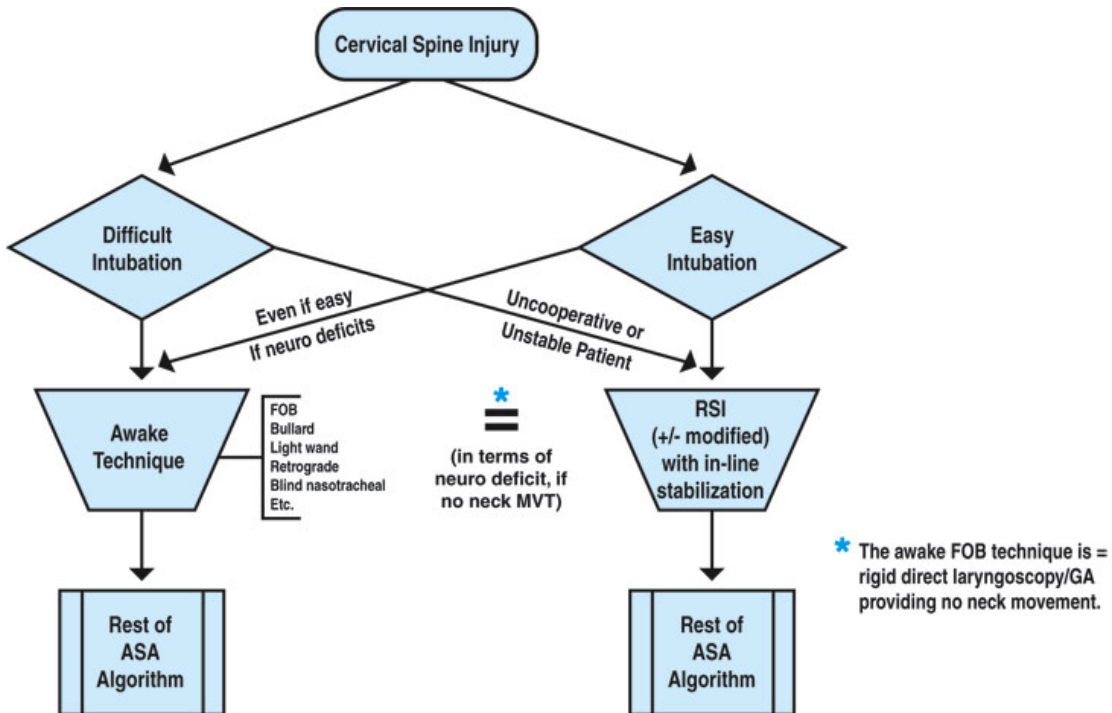
Does the patient have a neurological deficit? If yes, do awake technique.

Key Management Points:

A. Maintain In-line immobilization.

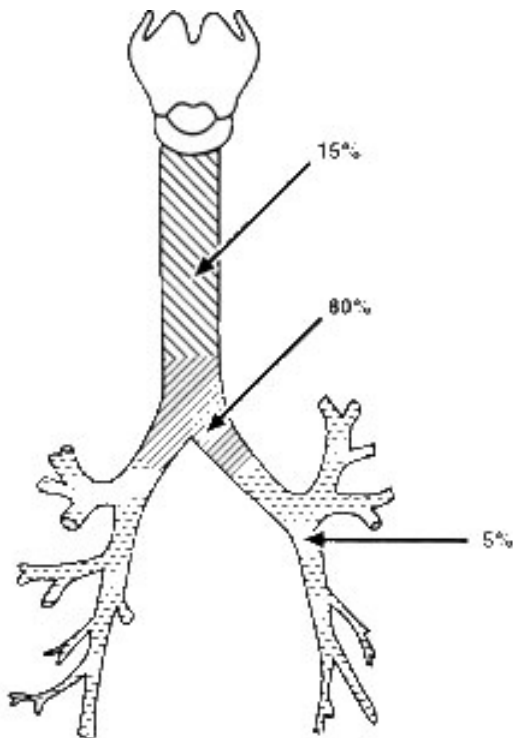
B. For RSI, maintain cricoid pressure with one hand supporting neck from behind.

Cervical Spine Injury Algorithm



Airway Disruption

The diagnosis of laryngeal injury in the trauma setting is made both by reviewing the mechanism of injury (such as steering wheel injuries) as well as checking the neck for findings such as bruising, bleeding, tenderness, swelling, and subcutaneous emphysema. Imaging studies such as computed tomography or magnetic resonance imaging can be very helpful, as can be bronchoscopy. One special concern is with patients with laryngeal fractures. Here, with attempts at ordinary intubation, the endotracheal tube may not traverse the fracture, possibly creating a deadly false passage. Thus, elective intubation should be attempted in this setting only in the presence of a surgical team prepared to carry out an emergency surgical airway below the level of the lesion. Finally, note that the use of spontaneous ventilation can be especially helpful for major laryngeal and tracheal tears.



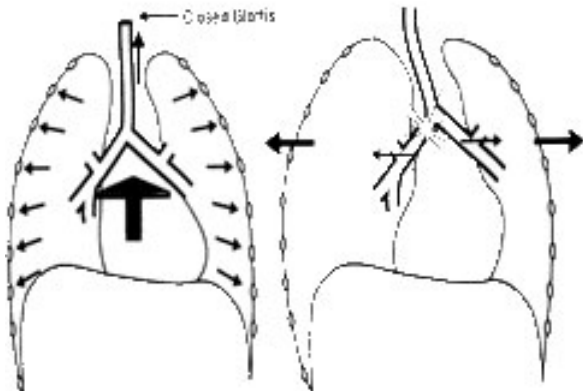
Airway Disruption

Left: Site-specific frequencies of blunt traumatic airway injuries.

Bottom: Biomechanics of blunt trauma to the major airways.

General Considerations

Do an awake intubation, provided the patient is cooperative, stable, maintains SV, **especially for major laryngeal/ tracheal tears.**



Key Questions:

Major laryngeal/tracheal tears?

If so, do awake technique.

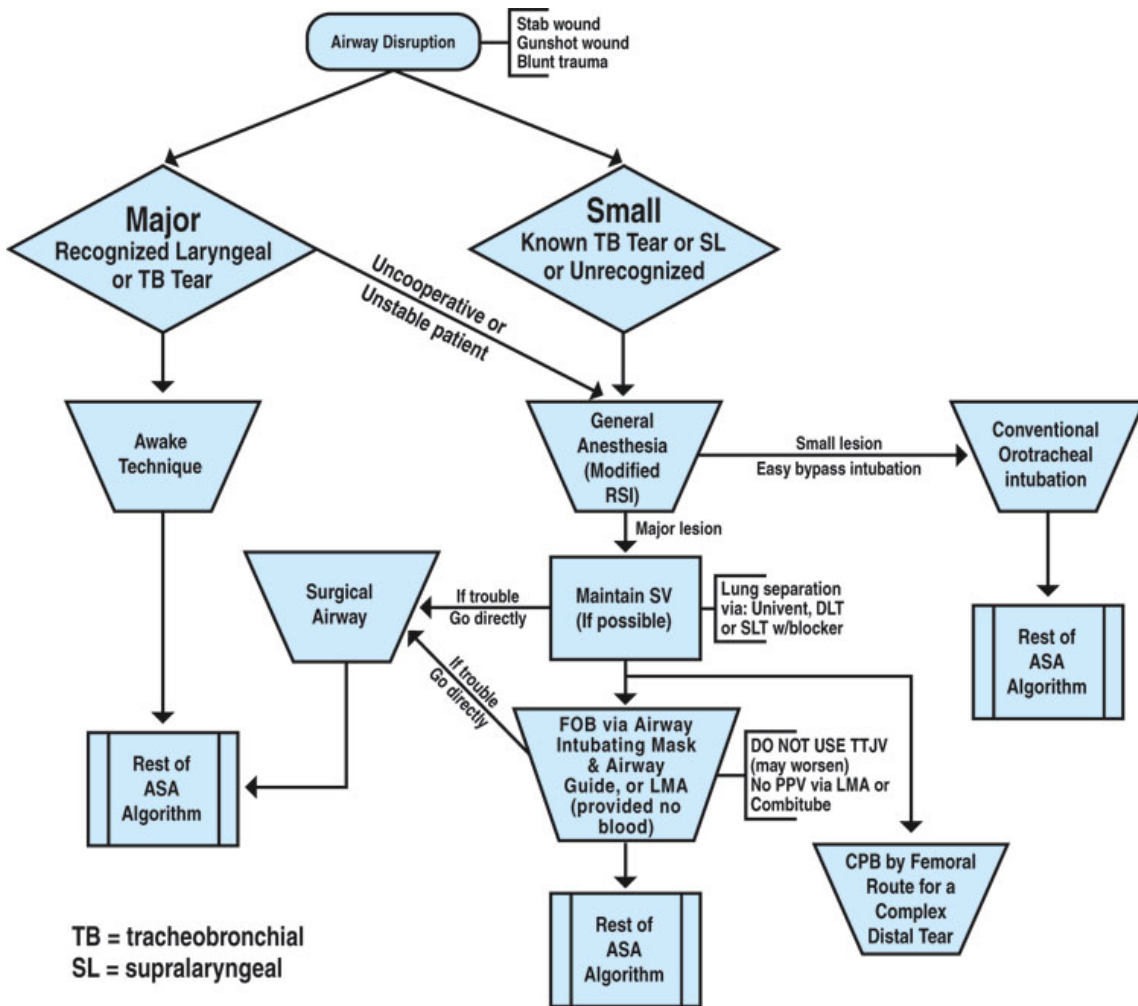
Small lesions? Or supralaryngeal?

If so, RSI (± modified).

Key Management Points:

- A. Maintain SV even with modified RSI technique.
- B. Get ETT below tear.
- C. Do not pressurize airway proximal to tear.
- D. No TTJV, LMA, etc.
- E. Consider DLT, Consider CPB.

Airway Disruption Algorithm



Airway Compression

Traumatic injury to face, maxilla and mandible.

General Considerations

- A. Do awake ETT, provided the patient is cooperative, stable, maintains SV and O₂ saturation and is able to clear airway of blood, foreign bodies, secretions and maintain patency.
- B. MV may be difficult even if ETT is easy.
- C. Blind nasal technique is contraindicated if: CSF leak, Le Fort or basal skull fracture.
- D. Initial decision-making based upon A.B.C.s; later, must be practical with the need for future jaw wiring.

Key Questions:

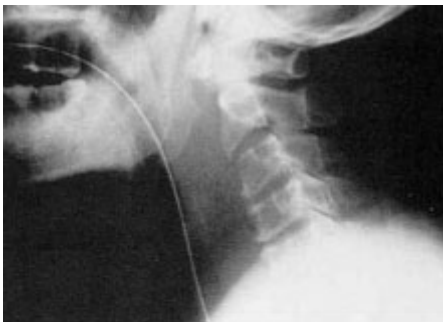Life-threatening obstruction?

If yes, surgical airway.

Not life-threatening (i.e., able to clear airway)?

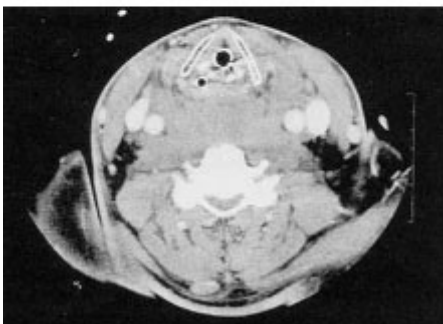
Then consider DA issues as well as need for jaw wiring.

Airway Compression



Airway Compression

Lateral C-spine X-ray (top) and CT scan (bottom) showing massive retropharyngeal hematoma



General Considerations

Do awake intubation, provided the patient is cooperative, stable, maintains SV, not life-threatening and able to maintain patency.

Maxillary-Facial Trauma

In severe maxillofacial trauma, oropharyngeal and nasopharyngeal injury may pose an immediate airway threat from structural deformity or from aspiration (teeth, dentures, bone fragments, blood). In addition, loss of consciousness from any associated head injury or other causes may contribute to airway obstruction. This may be particularly evident with mandibular fractures, which may result in a floating mandible when the fracture is bilateral. Maxillary fractures are less likely to lead to airway obstruction but may still compromise the airway as a result of hemorrhage. Lefort III fractures, involving separation of cranial and facial structures, are often associated with basal skull fractures, and nasal intubation or inserting of a nasogastric tube is contraindicated for fear of passing the tube past the cribriform plate into the brain. Awake tracheostomy is frequently employed in such a setting.

Key Questions:

Life-threatening obstruction?

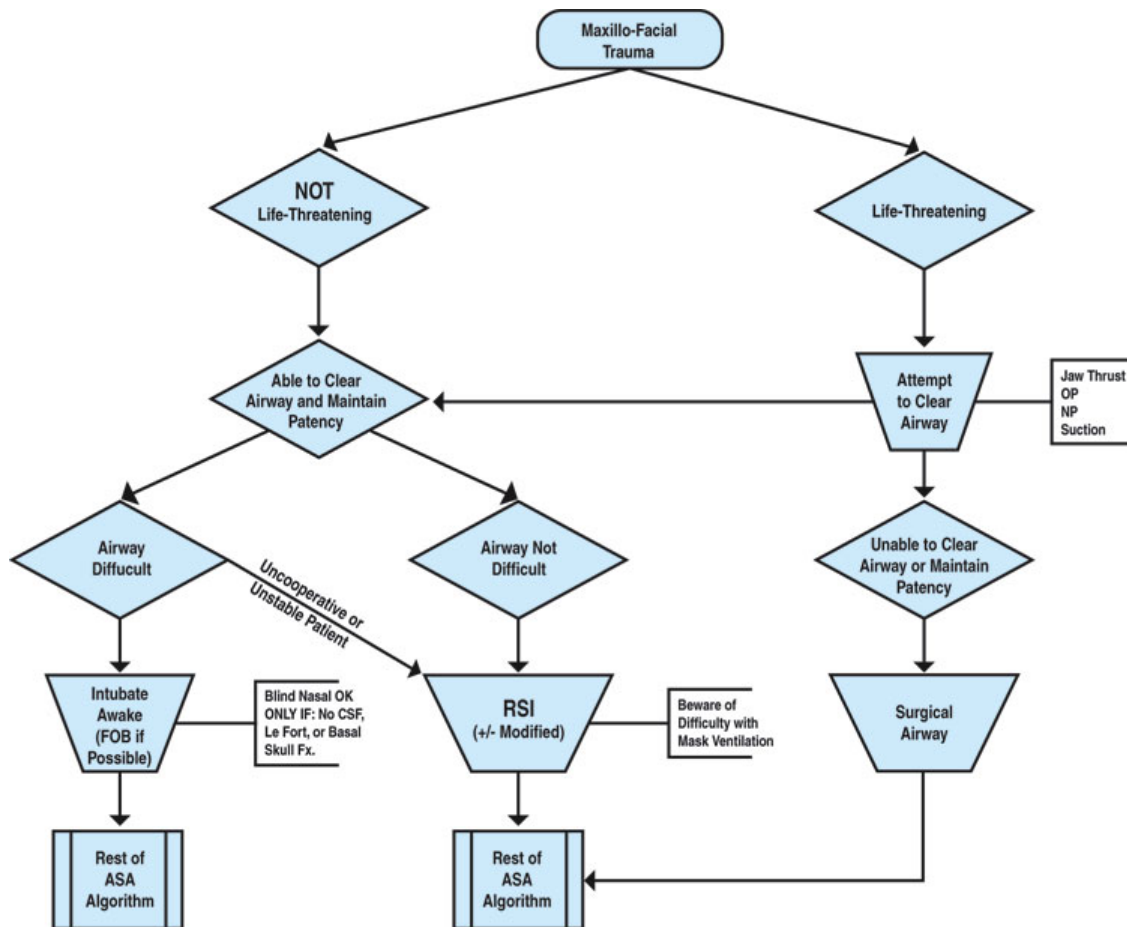
If so, surgical airway.

Not life-threatening?

If not, FOB a good choice as long as able to see entire way.

Key Management Points:

- A. Maintain SV even when with GA (modified RSI).
- B. Get ETT below obstruction.
- C. No supraglottic solutions (LMA, ETC, etc.).
- D. If using TTJV, may need help with exhalation. Consider opening wound if strider due to postoperative expanding neck hematoma.



N.B. May need to convert from oral to nasal or trach later (for jaw wiring considerations).

ACKNOWLEDGEMENTS

This presentation is based on the following article:

Trauma: Airway Management

**ASA Difficult Airway Algorithm Modified for Trauma — and Five Common
Trauma Intubation Scenarios**

William C. Wilson, M.D.

ASA Newsletter, November 2005, Volume 69, Number 11

http://www.asahq.org/Newsletters/2005/11-05/wilson11_05.html

I am grateful to the ASA and Drs. Wilson and Benumof, UCSD, for permission to use the material from the above-referenced article.