

THE CASE FOR GREENER CATARACT SURGERY P. 15 • HOW TO CATCH AND MANAGE IFIS P. 22  
ENHANCING PATIENTS' ADHERENCE TO MEDS P. 44 • RECOGNIZING AND TREATING OCULAR TB P. 51  
HOW TO MANAGE THYROID EYE DISEASE P. 56 • WILLS RESIDENT CASE REPORT P. 63

# REVIEW<sup>®</sup> of Ophthalmology

December 2018

reviewofophthalmology.com



## The Evolving Practice

*Ideas and technologies that keep practices on the cutting edge.*

Artificial Intelligence and  
Ophthalmology P. 24

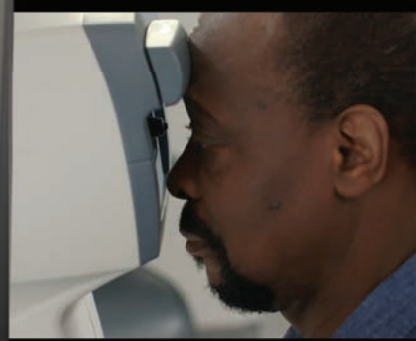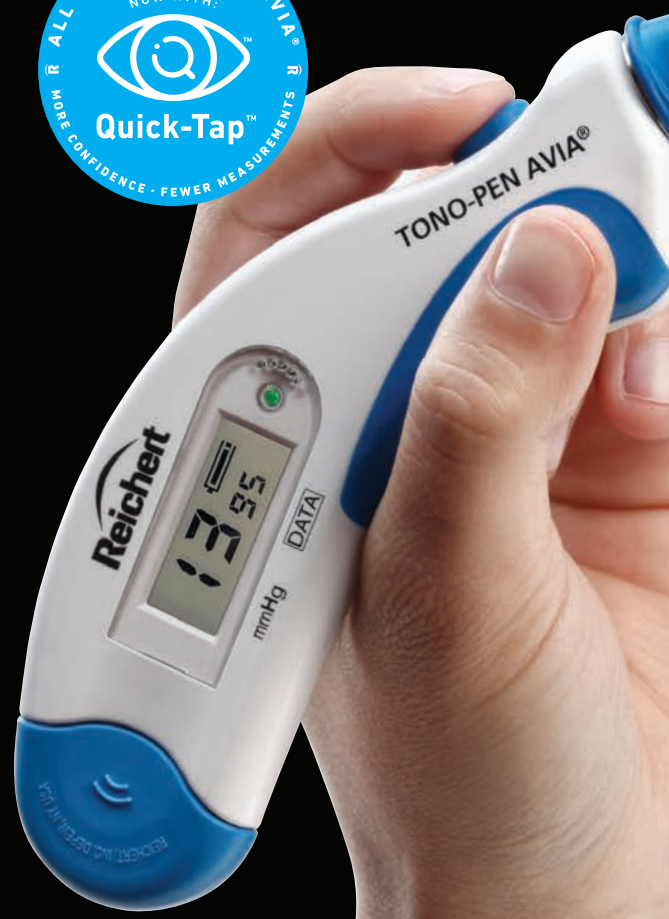Ensuring the Optimal Patient  
Experience P. 35

Innovations in Phaco Technology P. 40





ALL NEW! · TONO-PEN AVIA®  
NOW WITH:  
  
Quick-Tap™  
MORE CONFIDENCE · FEWER MEASUREMENTS



Right	
19.8	IOPcc
8.8	
17.9	
WS	



Passionate about glaucoma care?

WE ARE TOO.

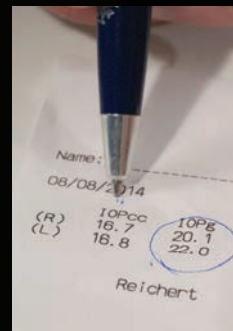
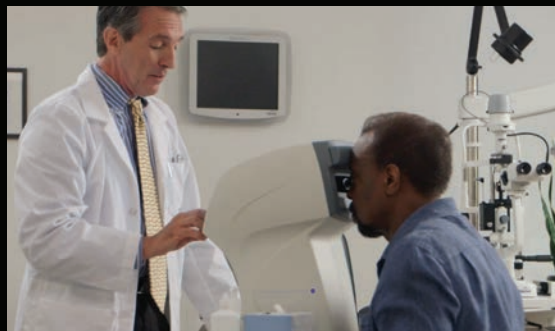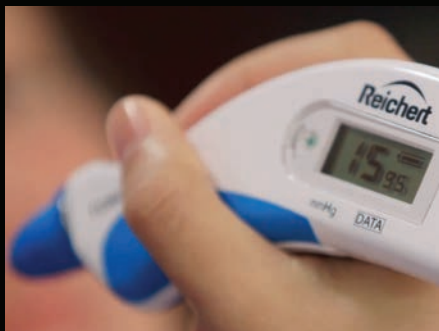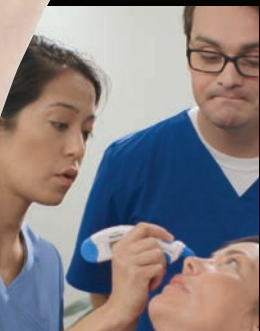We're striving to improve glaucoma care with **Ocular Response Analyzer® G3**, a more objective predictor of glaucoma development and progression. Ocular Response Analyzer® G3 uses patented technology to measure **Corneal Hysteresis**, which is more predictive of glaucoma progression than CCT or IOP\*, giving you a more personalized glaucoma risk assessment.


And we continue to advance handheld tonometry with the new **Tono-Pen AVIA®** featuring **Quick-Tap™** Mode for more confidence in fewer measurements.

Every day we bring American innovation to our glaucoma diagnostic devices, sharing in your passion to provide patients with the best care possible.

VISIT [REICHERT.COM/GLAUCOMA](http://REICHERT.COM/GLAUCOMA)

**Reichert**  
TECHNOLOGIES  
**AMETEK**



© 2018 AMETEK, Inc. & Reichert, Inc. (12-2018) · Ocular Response Analyzer and Tono-Pen are registered trademarks of Reichert, Inc. · Designed & assembled in USA 

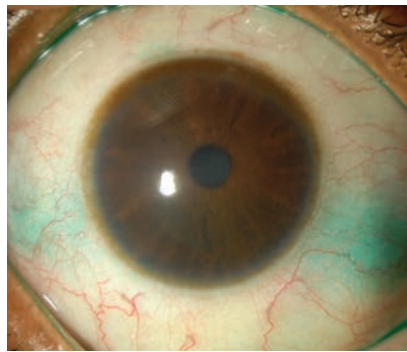
References: 1. Medeiros FA, Meira-Freitas D, Lisboa R, Kuang TM, Zangwill LM, Weinreb RN. Corneal hysteresis as a risk factor for glaucoma progression: a prospective longitudinal study. *Ophthalmology*. 2013 Aug;120(8):1533-40. 2. De Moraes CV, Hill V, Tello C, Liebmann JM, Ritch R. Lower corneal hysteresis is associated with more rapid glaucomatous visual field progression. *J Glaucoma*. 2012 Apr-May;21(4):209-13. 3. A Prospective Longitudinal Study to Investigate Corneal Hysteresis as a Risk Factor for Predicting Development of Glaucoma. Susanna CN, Diniz-Filho A, Daga FB, Susanna BN, Zhu F, Ogata NG, Medeiros FA. *Am J Ophthalmol*. 2018 Mar;187:148-152. doi: 10.1016/j.ajo.2017.12.018. CPT is registered trademark of the American Medical Association.

# OIS Offers a Snapshot of a Diverse Ophthalmic Pipeline

**Gene therapy, dry eye, refractive errors, retinal disease and microinvasive glaucoma surgery** are key therapeutic areas in ophthalmology that have had productive pipelines, with more on the way. At the annual Ophthalmology Innovation Summit before the American Academy of Ophthalmology annual meeting, OIS chair Emmett Cunningham Jr., MD, PhD, MPH, reported on Food and Drug Administration approvals of ophthalmology products in the past year—which he characterized as “a banner year”—and on drugs and devices that are expected to take significant steps toward approval in 2019. He focused on the following:

- **Gene therapy.** “If you follow this space you know gene therapy is active generally, but it’s particularly active in ophthalmology,” Dr. Cunningham said, noting that 16 companies are pursuing gene therapy programs in the space. He also cited a recent *New England Journal of Medicine* editorial in which FDA Commissioner Scott Gottlieb, MD, stated the agency is reviewing more than 700 active investigational new drug applications.<sup>1</sup> “You can see that gene therapy is valued at more than a 200 percent premium over the markets in the 12-month period that we’ve followed,” Dr. Cunningham said. “The world likes gene therapy. It’s come of age.”

- **Dry eye.** Six new dry-eye candidates are in Phase III studies, nine others are in Phase II, and more are in the pre-clinical phase.



Researchers took aim at dry eye, according to presentations at this year’s OIS meeting.

Christopher Rajuano, MD

Five investigative agents seem most promising, Dr. Cunningham noted: loteprednol etabonate ophthalmic solution, for which Kala Pharmaceuticals submitted a new drug application in October; TOP1630, a nonsystemic kinase inhibitor (TopiVert), for which a 200-patient Phase IIB trial is scheduled to start early next year; Aldeyra Therapeutics’ Reproxalap, for which a Phase III trial is due to launch in 2019; OC-02 (Oyster Point Pharma), a nicotinic acetylcholine inhibitor delivered intranasally that depolarizes the trigeminal nerves; and the PAD MC2-03 technology-based cyclosporine eye drop by MC2 Therapeutics, now in a Phase II/III trial.

Expect more options for dry-eye patients in the future. “There are literally three dozen companies in the dry-eye space that are active and advancing. It’s going to become a very complex and competitive market, and how that falls out is going to be hard to predict,” Dr. Cunningham said.

- **Refractive errors.** Pharmacotherapies for presbyopia and myopia represent the “holy grail” in ophthalmology, Dr. Cunningham noted. Novartis, Allergan, Orasis, Presbyopia Therapies and Viewpoint Therapeutics are all pursuing programs in presbyopia. Nevakar, Sydnexis and Eyenovia have candidates for myopia. “If presbyopia is a mega-market, [myopia] is twice that and growing,” Dr. Cunningham said, noting that 2 billion people worldwide have presbyopia and 5 billion are projected to have myopia by 2050.

- **Retinal disease.** Albeit a “mature field,” promising programs for treatment of age-related macular degeneration include brolicizumab (Novartis); the Port Delivery System with ranibizumab and faricimab bispecific antibody (Roche/Genentech); sunitinib tyrosine kinase inhibitor (Graybug Vision); the VEGF-C/D inhibitor OPT-302 (Opthea); RGX-314 (RegenXBIO); and the topical anti-VEGF platform PAN-90806 (PanOptica). Three candidates to treat diabetic macular edema—faricimab, lunate (Allegro Ophthalmics) and the small-molecule Tie-2 inhibitor AKD-9778 (Aerpio Therapeutics)—are in Phase II or III trials.

On the device side, Dr. Cunningham said the FDA has reduced review times of 510(k) applications by half in the past year, according to information the agency supplied. Minimally-invasive glaucoma surgery (MIGS) has been active, with FDA





**Editor in Chief**

**Walter C. Bethke**  
(610) 492-1024  
wbethke@jobson.com

**Senior Editor**

**Christopher Kent**  
(814) 861-5559  
ckent@jobson.com

**Senior Associate Editor**

**Kristine Brennan**  
(610) 492-1008  
kbrennan@jobson.com

**Chief Medical Editor**

**Mark H. Blecher, MD**

**Art Director**

**Jared Araujo**  
(610) 492-1032  
jaraujo@jobson.com

**Senior Graphic Designer**

**Matt Egger**  
(610) 492-1029  
megger@jobson.com

**Graphic Designer**

**Ashley Schmouder**  
(610) 492-101048  
aschmouder@jobson.com

**International coordinator, Japan**

**Mitz Kaminuma**  
Reviewophthalgo@aol.com

**Business Offices**

11 Campus Boulevard, Suite 100  
Newtown Square, PA 19073  
(610) 492-1000  
Fax: (610) 492-1039

**Subscription inquiries:**

United States — (877) 529-1746  
Outside U.S. — (845) 267-3065

**E-mail:**

revophthalmology@cambeywest.com

**Website:** www.reviewofophthalmology.com



approvals of the iStent inject (Glaukos) and Hydrus Microstent (Ivantis) in the past year—and the voluntary withdrawal of the CyPASS microstent (Alcon). Two MIGS devices—Micro-Shunt (Santen) and iStent SUPRA (Glaukos)—are in clinical development. He noted that MarketScope projects the number of MIGS procedures to more than double to 584,000 by 2023.

Two devices that received approvals in the past year were also discussed: TrueTear intranasal tear stimulator (Allergan and Oculeve) and IDx-DR (IDx), the first FDA-approved autonomous artificial intelligence-based diagnostic device, which is designed for screening for diabetic retinopathy.

“AI is a big deal and it’s going to totally transform our world,” Dr. Cunningham said. “We’ll all remember this approval for years to come. It will be very important.”

1. Collins FS, Gottlieb S. The next phase of human gene-therapy oversight. *N Engl J Med* 201;379:1393-1395.

## Astigmatism Approvals

The fall saw two new approvals for the correction of patients’ astigmatism.

Staar Surgical finally secured approval for myopic astigmatism treatment with its Visian ICL phakic intraocular lens. The Visian is implanted in the posterior chamber.

With the approval, the Visian’s treatment parameters have expanded to the following:

- the correction of myopic astigmatism with a spherical equivalent ranging from -3 to  $\leq$  -15 D (in the spectacle plane) with cylinder of 1 D to 4 D in the spectacle plane; and
- the reduction of myopic astigmatism with spherical equivalent ranging from greater than -15 to -20 D (in the spectacle plane) with cylinder of 1 to 4 D in the spectacle plane.

Visian patients must have an anterior chamber depth of 3 mm or greater when measured from the corneal endothelium to the anterior surface of the crystalline lens, and a stable refractive history (i.e., refractions that are within 0.5 D of each other for both spherical equivalent and cylinder for one year prior to implantation).

In addition to Staar’s astigmatism approval for its Visian ICL, Carl Zeiss Meditec received approval to correct astigmatism with its femtosecond-laser-based small-incision lenticule extraction procedure.

SMILE consists of using the Visumax laser to create a lenticule of tissue within the cornea, which is then removed via a side cut. The removal changes the patient’s refraction and corrects the refractive error. One of the initial limitations of SMILE when it was first approved, however, was its inability to correct a patient’s astigmatism. Now, however, it’s been approved to treat between -0.75 and -3 D of astigmatism, broadening its usefulness. **REVIEW**

### Corrections

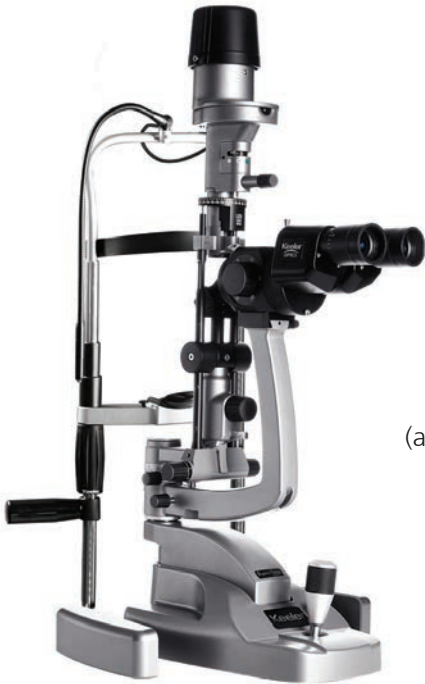In the October feature, “Solo Practice: Can You (Still) Go It Alone?” Alpharetta, Georgia, ophthalmologist Ajit Nemi, MD, MBA, was incorrectly referred to as “Anjit,” and his practice’s correct name is “Lotus Vision,” not “Lotus Eye.” In the November feature, “Making the Most of Corneal Cross-linking,” reference was made to the FDA’s limited approval of “epi-on” cross-linking; the approval in question was for “epi-off.” In November’s Technology Update, the Argus II requires a vitreous, not a retinal, detachment. The Alpha AMS device requires a power cable, contrary to what is stated in the article. *Review* regrets the errors.



# The Keeler<sup>3</sup> Trade In Program

## Buy 3 // Trade 3 // Get 1 Free

The Power of 3. Purchase any 3 Keeler Slit Lamps and trade in 3 of your old Slit Lamps and we'll send you a 4th Keeler Slit Lamp absolutely free of charge.



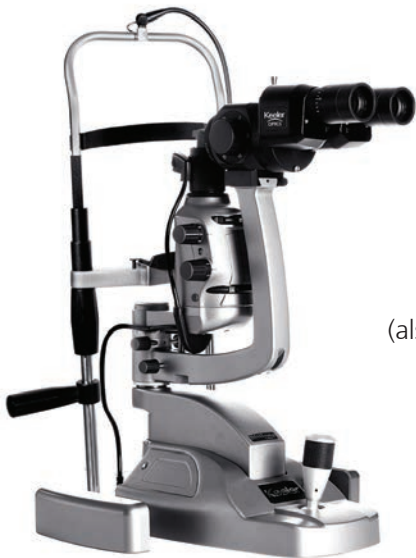KSL-H

(also in Digital Ready)



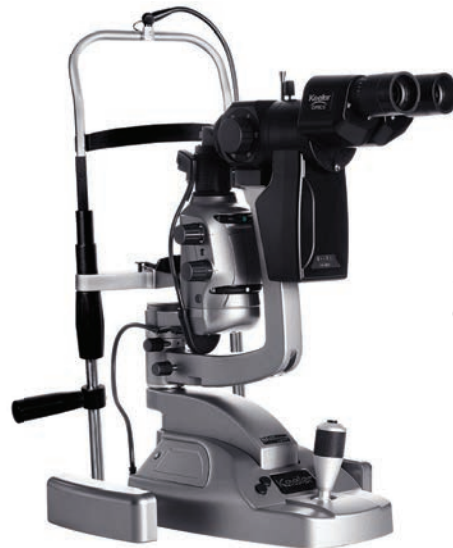KSL-H-D

(full Digital)



KSL-Z

(also in Digital Ready)



KSL-H-D

(full Digital)

**Keeler**  
OPTICS

Keeler Instruments, Inc. • 3222 Phoenixville Pike, bldg. 50 • Malvern, PA 19355  
Tel: (800) 523-5620 • Fax: (610) 353-7814 • email: keeler@keelerusa.com

**Offer valid until December 31, 2018.**

Contact Keeler or one of our authorized dealers for more information.

# CONTRIBUTORS

**CHIEF MEDICAL EDITOR**

Mark H. Blecher, MD

**CONTACT LENSES**

Penny Asbell, MD

**CORNEA / ANTERIOR SEGMENT**

Thomas John, MD

**GLAUCOMA MANAGEMENT**

Peter Netland, MD, PHD  
Kuldev Singh, MD

**MEDICARE Q & A**

Paul M. Larson, MBA

**PEDIATRIC PATIENT**

Wendy Huang, MD

**PLASTIC POINTERS**

Ann P. Murchison, MD, MPH

**REFRACTIVE/CATARACT RUNDOWN**

Arturo S. Chayet, MD

**RETINAL INSIDER**

Carl Regillo, MD, FACS  
Emmett T. Cunningham Jr., MD, PHD, MPH

**TECHNOLOGY UPDATE**

Steven T. Charles, MD  
Michael Colvard, MD

**WILLS RESIDENT CASE SERIES**

Jason Flamendorf, MD

# ADVISORY BOARD

**PENNY A. ASBELL, MD**, NEW YORK CITY

**WILLIAM I. BOND, MD**, PEKIN, ILL.

**ALAN N. CARLSON, MD**, DURHAM, N.C.

**Y. RALPH CHU, MD**, EDINA, MINN.

**ADAM J. COHEN, MD**, DOWNERS GROVE, ILL.

**UDAY DEVGAN, MD, FACS**, LOS ANGELES

**ERIC DONNENFELD, MD**, ROCKVILLE CENTRE, N.Y.

**DANIEL S. DURRIE, MD**, KANSAS CITY, MO.

**ROBERT EPSTEIN, MD**, MCHENRY, ILL.

**ROBERT D. FECHTNER, MD**, NEWARK, N.J.

**WILLIAM J. FISHKIND, MD**, TUCSON, ARIZ.

**JAMES P. GILLS, MD**, TARPON SPRINGS, FLA.

**HARRY GRABOW, MD**, SARASOTA, FLA.

**DOUGLAS K. GRAYSON, MD**, NEW YORK CITY

**THOMAS S. HARBIN, MD, MBA**, ATLANTA

**DAVID R. HARDTEN, MD**, MINNEAPOLIS

**KENNETH J. HOFFER, MD**, SANTA MONICA, CALIF.

**JACK T. HOLLADAY, MD, MSEE**, HOUSTON

**JOHN D. HUNKELER, MD**, KANSAS CITY, MO.

**THOMAS JOHN, MD**, TINLEY PARK, ILL.

**ROBERT M. KERSHNER, MD, MS, FACS**, BOSTON

**GUY M. KEZIRIAN, MD**, PARADISE VALLEY, ARIZ.

**TERRY KIM, MD**, DURHAM, N.C.

**TOMMY KORN, MD**, SAN DIEGO

**DAVID A. LEE, MD**, HOUSTON

**FRANCIS S. MAH, MD**, PITTSBURGH

**NICK MAMALIS, MD**, SALT LAKE CITY

**WILLIAM G. MARTIN, MD**, OREGON, OHIO

**MIKE S. MCFARLAND, MD**, PINE BLUFF, ARK.

**JEFFREY B. MORRIS, MD, MPH**, ENCINITAS, CALIF.

**MARLENE R. MOSTER, MD**, PHILADELPHIA

**ROBERT J. NOECKER, MD**, FAIRFIELD, CONN.

**ROBERT OSHER, MD**, CINCINNATI

**MARK PACKER, MD**, BOULDER, CO.

**STEPHEN PASCUCCI, MD**, BONITA SPRINGS, FLA.

**PAUL PENDER, MD**, BEDFORD, N.H.

**CHRISTOPHER J. RAPUANO, MD**, PHILADELPHIA

**AUGUST READER III, MD**, SAN FRANCISCO

**TONY REALINI, MD**, MORGANTOWN, W.V.

**KENNETH J. ROSENTHAL, MD**, GREAT NECK, N.Y.

**ERIC ROTHCHILD, MD**, DELRAY BEACH, FLA.

**SHERI ROWEN, MD**, BALTIMORE

**JAMES J. SALZ, MD**, LOS ANGELES

**INGRID U. SCOTT, MD, MPH**, HERSHEY, PA.

**JOEL SCHUMAN, MD**, PITTSBURGH

**GAURAV SHAH, MD**, ST. LOUIS

**DAVID R. STAGER JR., MD**, DALLAS

**KARL STONECIPHER, MD**, GREENSBORO, N.C.

**JAMES C. TSAI, MD**, NEW YORK CITY

**VANCE THOMPSON, MD**, SIOUX FALLS, S.D.

**FARRELL C. TYSON, MD**, CAPE CORAL, FLA.

**R. BRUCE WALLACE III, MD**, ALEXANDRIA, LA.

**ROBERT G. WILEY, MD**, CLEVELAND

**FRANK WEINSTOCK, MD**, CANTON, OHIO

**BUSINESS OFFICES**

11 CAMPUS BOULEVARD, SUITE 100  
NEWTOWN SQUARE, PA 19073  
SUBSCRIPTION INQUIRIES (877) 529-1746  
(USA ONLY); OUTSIDE USA, CALL (847) 763-9630

**BUSINESS STAFF**

PUBLISHER

**JAMES HENNE**

(610) 492-1017 JHENNE@JOBSON.COM

REGIONAL SALES MANAGER

**MICHELE BARRETT**

(610) 492-1014 MBARRETT@JOBSON.COM

REGIONAL SALES MANAGER

**MICHAEL HOSTER**

(610) 492-1028 MHOSTER@JOBSON.COM

**CLASSIFIED ADVERTISING**

(888)-498-1460

VICE PRESIDENT OF OPERATIONS

**CASEY FOSTER**

(610) 492-1007 CFOSTER@JOBSON.COM

PRODUCTION MANAGER

**SCOTT TOBIN**

(610) 492-1011 STOBIN@JOBSON.COM

**SUBSCRIPTIONS**

\$63 A YEAR, \$99 (U.S.) IN CANADA,  
\$158 (U.S.) IN ALL OTHER COUNTRIES.

SUBSCRIPTIONS E-MAIL:

REVOPHTHALMOLOGY@CAMBEYWEST.COM

**CIRCULATION**

PO BOX 71, CONGERS, NY 10920-0071  
(877) 529-1746

OUTSIDE USA: (845) 267-3065

SENIOR CIRCULATION MANAGER

**HAMILTON MAHER**

(212) 219-7870 hmaher@jhihealth.com

CEO, INFORMATION GROUP SERVICES

**MARC FERRARA**

SENIOR VICE PRESIDENT, OPERATIONS

**JEFF LEVITZ**

VICE PRESIDENT, HUMAN RESOURCES

**TAMMY GARCIA**

VICE PRESIDENT, CREATIVE SERVICES & PRODUCTION

**MONICA TETTAMANZI**

CORPORATE PRODUCTION DIRECTOR

**JOHN ANTHONY CAGGIANO**

VICE PRESIDENT, CIRCULATION

**EVELDA BAREA**

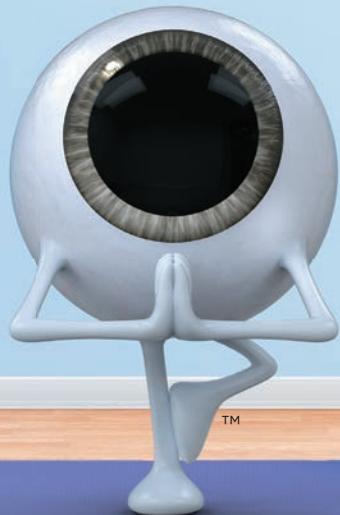


395 Hudson Street, 3rd Floor  
New York, NY 10014

REVIEW OF OPHTHALMOLOGY (ISSN 1081-0226; USPS No. 0012-345) is published monthly, 12 times per year by Jobson Medical Information, 440 Ninth Avenue, 14th Floor, New York, N.Y. 10001. Periodicals postage paid at New York, NY and additional mailing offices. Postmaster: Send address changes to Review of Ophthalmology, PO Box 71, Congers, NY 10929-0071. Subscription Prices: US One Year \$63.00, US Two Year \$112.00, Canada One Year \$99.00, Canada Two Year \$181.00, Int'l One Year \$158.00, Int'l Two Year \$274.00. For subscription information call (877) 529-1746 (USA only); outside USA, call (845)-267-3065. Or email us at revophthalmology@cambeywest.com. Canada Post: Publications Mail Agreement #40612608. Canada Returns to be sent to Bleuchip International, P.O. Box 25542, London, ON N6C 6B2.



# Less stress. Pure success.



OMIDRIA® (phenylephrine and ketorolac intraocular solution) 1% / 0.3% is added to ophthalmic irrigating solution used during cataract surgery or intraocular lens replacement and is indicated for maintaining pupil size by preventing intraoperative miosis and reducing postoperative ocular pain.

## The data are compelling and consistent—OMIDRIA makes cataract surgery better for you and your patients

Published and presented clinical studies report that in post-launch (i.e., not included in current labeling), prospective and retrospective, double-masked and open-label, cohort and case-controlled, single- and multi-center analyses, the use of OMIDRIA, compared to the surgeons' standard of care, statistically significantly:

- Prevents Intraoperative Floppy Iris Syndrome (IFIS)<sup>1</sup>
- Reduces complication rates (epinephrine comparator)<sup>2</sup>
- Decreases use of pupil-expanding devices (epinephrine comparator)<sup>2-7</sup>
- Reduces surgical times (epinephrine comparator)<sup>2,4,6,7</sup>
- Prevents miosis during femtosecond laser-assisted surgery (epinephrine comparator)<sup>5,8</sup>
- Improves uncorrected visual acuity on day after surgery (epinephrine comparator)<sup>2</sup>
- Delivers NSAID to the anterior chamber and related structures better than routine preoperative topical drug administration, resulting in effectively complete postoperative inhibition of COX-1 and COX-2<sup>9,10</sup>

## Separately reimbursed under Medicare Part B

Contact your OMIDRIA representative today or visit [omidria.com](http://omidria.com) to learn more

### IMPORTANT SAFETY INFORMATION

OMIDRIA must be added to irrigating solution prior to intraocular use.

OMIDRIA is contraindicated in patients with a known hypersensitivity to any of its ingredients.

Systemic exposure of phenylephrine may cause elevations in blood pressure.

Use OMIDRIA with caution in individuals who have previously exhibited sensitivities to acetylsalicylic acid, phenylacetic acid derivatives, and other nonsteroidal anti-inflammatory drugs (NSAIDs), or have a past medical history of asthma.

The most commonly reported adverse reactions at  $\geq 2\%$  are eye irritation, posterior capsule opacification, increased intraocular pressure, and anterior chamber inflammation.

Please see the Full Prescribing Information for OMIDRIA at [www.omidria.com/prescribinginformation](http://www.omidria.com/prescribinginformation).

You are encouraged to report Suspected Adverse Reactions to the FDA.

Visit [www.fda.gov/medwatch](http://www.fda.gov/medwatch), or call 1-800-FDA-1088.

**References:** 1. Silverstein SM, Rana V, Stephens R, Segars L, Pankratz J, Shivani R, et al. Effect of phenylephrine 1.0%-ketorolac 0.3% injection on tamsulosin-associated intraoperative floppy-iris syndrome. *J Cataract Refract Surg.* 2018;44(9):1103-1108. 2. Rosenberg ED, Nattis AS, Alevi D, et al. Visual outcomes, efficacy, and surgical complications associated with intracameral phenylephrine 1.0%/ketorolac 0.3% administered during cataract surgery. *Clin Ophthalmol.* 2018;12:21-28. 3. Bucci FA Jr, Michalek B, Fluet AT. Comparison of the frequency of use of a pupil expansion device with and without an intracameral phenylephrine and ketorolac injection 1%/0.3% at the time of routine cataract surgery. *Clin Ophthalmol.* 2017;11:1039-1043. 4. Visco D. Effect of phenylephrine/ketorolac on iris fixation ring use and surgical times in patients at risk of intraoperative miosis. *Clin Ophthalmol.* 2018;12:301-305. 5. Walter K, Delwadia N. Miosis prevention in femtosecond cataract surgery using a continuous infusion of phenylephrine and ketorolac. Presented at: 2018 American Society of Cataract and Refractive Surgery (ASCRS) and American Society of Ophthalmic Administrators (ASOA) Annual Meeting; April 13-17, 2018; Washington, DC. 6. Matossian C. Clinical outcomes of phenylephrine/ketorolac vs. epinephrine in cataract surgery in a real-world setting. Presented at: American Society of Cataract and Refractive Surgery (ASCRS) and American Society of Ophthalmic Administrators (ASOA) Annual Meeting; April 13-17, 2018; Washington, DC. 7. Al-Hashimi S, Donaldson K, Davidson R, et al. Medical and surgical management of the small pupil during cataract surgery. *J Cataract Refract Surg.* 2018;44:1032-1041. 8. Gayton JL. E-poster presented at: 15th International Congress on Vision Science and Eye; 2017 Aug 10-11; London, UK. 9. Katshev DA, Katshev CC, Pinnow J, Lockhart CM. Intracameral ketorolac concentration at the beginning and end of cataract surgery following preoperative topical ketorolac administration. *Clin Ophthalmol.* 2017;11:1897-1901. 10. Waterbury LD. Alternative drug delivery for patients undergoing cataract surgery as demonstrated in a canine model. *J Ocul Pharmacol Ther.* 2018;34:154-160.




**OMIDRIA®**  
(phenylephrine and ketorolac  
intraocular solution)  
1% / 0.3%

FROM THE EXPERTS IN LOTEPIEDNOL ETABONATE FOR OVER 20 YEARS

# COMING SOON

BAUSCH + LOMB'S NEWEST ARRIVAL



A **NEW** LOTEPIEDNOL ETABONATE FORMULATION

# BAUSCH + LOMB



# REVIEW<sup>®</sup> of Ophthalmology

December 2018 • Volume XXV No. 12 | [reviewofophthalmology.com](http://reviewofophthalmology.com)

## Cover Focus

### 24 | **AI and Ophthalmology: The Pros and Cons**

*Christopher Kent, Senior Editor*

Artificial intelligence has begun to transform ophthalmology—but caution is advised.

### 35 | **Upping the Patient-happiness Quotient**

*Kristine Brennan, Senior Associate Editor*

Experts share an assortment of “whys” and “hows” for you and your staff.

### 40 | **The Latest Phaco Innovations**

*Michelle Stephenson, Contributing Editor*

Advances in design and fluidics are giving surgeons more control over their procedures.



The Evolving  
Practice

# Departments

---

4 | [Review News](#)

15 | [Technology Update](#)

**Making the Case for Greener Cataract Surgery**

Current standards for OR safety in the U.S. are causing massive waste and pollution.

22 | [Refractive/Cataract Rundown](#)

**IFIS: Know the Risks and Manage the Signs**

Intraoperative floppy iris syndrome has the potential to derail cataract surgery, especially if it's a surprise.

44 | [Glaucoma Management](#)

**Helping Your Patients Adhere to Treatment**

Effective communication is crucial, including asking questions, providing education and offering assistance.

51 | [Retinal Insider](#)

**Recognizing and Treating Ocular TB**

Experts are attempting to reach a consensus on how to approach the treatment of ocular tuberculosis.

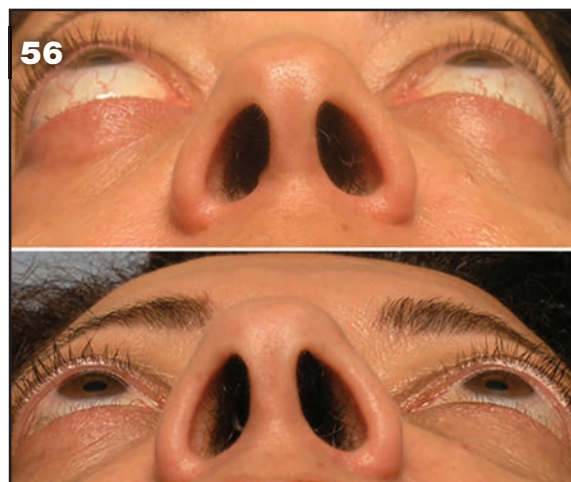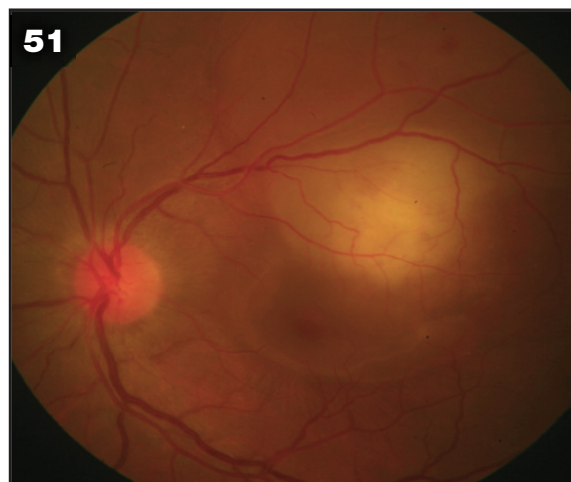
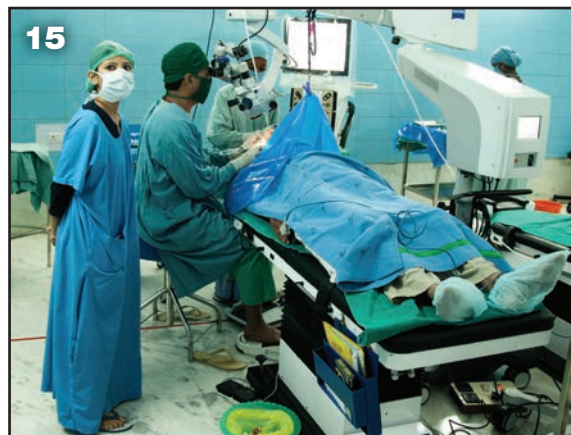56 | [Plastic Pointers](#)

**Management of Thyroid Eye Disease**

In the second installment of this two-part series on TED, an expert discusses the treatment options.

63 | [Wills Eye Resident Case Series](#)

66 | [Advertiser Index](#)





# **NEW** The first and only FDA-approved, single-dose, sustained-release, intracameral steroid for the treatment of postoperative inflammation<sup>1-3</sup>

## For Post-Cataract Surgery Inflammation **Target Within**<sup>1-3</sup>

With a single injection at the end of cataract surgery, anti-inflammatory efficacy begins as early as day 1 and continues through day 30<sup>1\*</sup>

- The percentage of patients who received DEXYCU (517 mcg) who had anterior chamber cell clearing on day 8 was 60% (N=94/156) vs 20% (N=16/80) in the placebo group<sup>1</sup>
- The cumulative percentage of subjects receiving rescue medication of ocular steroid or nonsteroidal anti-inflammatory drug (NSAID) at day 30 was significantly lower in the DEXYCU 517 mcg treatment group (20%; N=31/156) compared to placebo (54%; N=43/80)<sup>1</sup>

\*DEXYCU was studied in a randomized, double-masked, placebo-controlled trial. Patients received either DEXYCU or a vehicle administered by a physician at the end of the surgical procedure. The primary endpoint was the proportion of patients with anterior chamber cell clearing (cell score = 0) on postoperative day 8.

### INDICATION AND USAGE

DEXYCU™ (dexamethasone intraocular suspension) 9% is indicated for the treatment of postoperative inflammation.

### IMPORTANT SAFETY INFORMATION

#### CONTRAINDICATIONS

None.

#### WARNINGS AND PRECAUTIONS

##### Increase in Intraocular Pressure

- Prolonged use of corticosteroids, including DEXYCU, may result in glaucoma with damage to the optic nerve, defects in visual acuity and fields of vision
- Steroids should be used with caution in the presence of glaucoma

##### Delayed Healing

- The use of steroids after cataract surgery may delay healing and increase the incidence of bleb formation
- In those diseases causing thinning of the cornea or sclera, perforations have been known to occur with the use of corticosteroids

##### Exacerbation of Infection

- The use of DEXYCU, as with other ophthalmic corticosteroids, is not recommended in the presence of most active viral diseases of the cornea and conjunctiva including epithelial herpes simplex keratitis (dendritic keratitis), vaccinia, and varicella, and also in mycobacterial infection of the eye and fungal disease of ocular structures



Approved & Available Soon

# DEXYCU™

(dexamethasone intraocular suspension) 9%

Visit [DEXYCU.com](http://DEXYCU.com) for more details.

- Use of a corticosteroid in the treatment of patients with a history of herpes simplex requires caution and may prolong the course and may exacerbate the severity of many viral infections
- Fungal infections of the cornea are particularly prone to coincidentally develop with long-term local steroid application and must be considered in any persistent corneal ulceration where a steroid has been used or is in use. Fungal culture should be taken when appropriate
- Prolonged use of corticosteroids may suppress the host response and thus increase the hazard of secondary ocular infections. In acute purulent conditions, steroids may mask infection or enhance existing infection

#### Cataract Progression

- The use of corticosteroids in phakic individuals may promote the development of posterior subcapsular cataracts

#### ADVERSE REACTIONS

- The most commonly reported adverse reactions occurred in 5-15% of subjects and included increases in intraocular pressure, corneal edema and iritis

Please see brief summary of full Prescribing Information on adjacent page.

**References:** 1. DEXYCU™ (dexamethasone intraocular suspension) 9% full U.S. Prescribing Information. EyePoint Pharmaceuticals, Inc. July 2018. 2. Donnenfeld E, Holland E. Dexamethasone intracameral drug-delivery suspension for inflammation associated with cataract surgery: a randomized, placebo-controlled, phase III trial. *Ophthalmology*. 2018;125(6):799-806. 3. Data on file. EyePoint Pharmaceuticals, Inc.



**DEXYCU (dexamethasone intraocular suspension) 9%, for intraocular administration**

**Initial U.S. Approval: 1958**

**BRIEF SUMMARY: Please see package insert for full prescribing information.**

**1 INDICATIONS AND USAGE**

DEXYCU (dexamethasone intraocular suspension) 9% is indicated for the treatment of postoperative inflammation.

**4 CONTRAINDICATIONS**

None.

**5 WARNINGS AND PRECAUTIONS**

**5.1 Increase in Intraocular Pressure**

Prolonged use of corticosteroids including DEXYCU may result in glaucoma with damage to the optic nerve, defects in visual acuity and fields of vision. Steroids should be used with caution in the presence of glaucoma.

**5.2 Delayed Healing**

The use of steroids after cataract surgery may delay healing and increase the incidence of bleb formation. In those diseases causing thinning of the cornea or sclera, perforations have been known to occur with the use of corticosteroids.

**5.3 Exacerbation of Infection**

The use of DEXYCU, as with other ophthalmic corticosteroids, is not recommended in the presence of most active viral diseases of the cornea and conjunctiva including epithelial herpes simplex keratitis (dendritic keratitis), vaccinia, and varicella, and also in mycobacterial infection of the eye and fungal disease of ocular structures.

Employment of a corticosteroid medication in the treatment of patients with a history of herpes simplex requires caution. Use of ocular steroids may prolong the course and may exacerbate the severity of many viral infections of the eye (including herpes simplex). Fungal infections of the cornea are particularly prone to develop coincidentally with long-term local steroid application. Fungus invasion must be considered in any persistent corneal ulceration where a steroid has been used or is in use. Fungal culture should be taken when appropriate.

Prolonged use of corticosteroids may suppress the host response and thus increase the hazard of secondary ocular infections. In acute purulent conditions, steroids may mask infection or enhance existing infection.

**5.4 Cataract Progression**

The use of corticosteroids in phakic individuals may promote the development of posterior subcapsular cataracts.

**6 ADVERSE REACTIONS**

The following adverse reactions are described elsewhere in the labeling:

- Increase in Intraocular Pressure [see *Warning and Precautions (5.1)*]
- Delayed Healing [see *Warnings and Precautions (5.2)*]
- Infection Exacerbation [see *Warnings and Precautions (5.3)*]
- Cataract Progression [see *Warnings and Precautions (5.4)*]

**6.1 Clinical Trials Experience**

Because clinical studies are conducted under widely varying conditions, adverse reaction rates observed in the clinical studies of a drug cannot be directly compared to rates in the clinical studies of another drug and may not reflect the rates observed in practice.

The following adverse events rates are derived from three clinical trials in which 339 patients received the 517 microgram dose of DEXYCU. The most commonly reported adverse reactions occurred in 5-15% of subjects and included increases in intraocular pressure, corneal edema and iritis. Other ocular adverse reactions occurring in 1-5% of subjects included, corneal endothelial cell loss, blepharitis, eye pain, cystoid macular edema, dry eye, ocular inflammation, posterior capsule opacification, blurred vision, reduced visual acuity, vitreous floaters, foreign body sensation, photophobia, and vitreous detachment.

**8 USE IN SPECIFIC POPULATIONS**

**8.1 Pregnancy**

Risk Summary

There are no adequate and well-controlled studies of DEXYCU (dexamethasone intraocular suspension) in pregnant women. Topical ocular administration of dexamethasone in mice and rabbits during the period of organogenesis produced cleft palate and embryofetal death in mice and malformations of abdominal wall/intestines and kidneys in rabbits at doses 7 and 5 times higher than the injected recommended human ophthalmic dose (RHOD) of DEXYCU (517 micrograms dexamethasone), respectively [see *Data in the full prescribing information*].

In the US general population the estimated background risk of major birth defects and miscarriage in clinically recognized pregnancies is 2 to 4% and 15 to 20%, respectively.

**8.2 Lactation**

Risk Summary

Systemically administered corticosteroids are present in human milk and can suppress growth, interfere with endogenous corticosteroid production, or cause other unwanted effects. There is no information regarding the presence of injected DEXYCU in human milk, the effects on breastfed infants, or the effects on milk production to inform risk of DEXYCU to an infant during lactation. The developmental and health benefits of breastfeeding should be considered, along with the mother's clinical need for DEXYCU and any potential adverse effects on the breastfed child from DEXYCU.

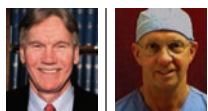**8.4 Pediatric Use**

Safety and effectiveness of DEXYCU in pediatric patients have not been established.

**8.5 Geriatric Use**

No overall differences in safety or effectiveness have been observed between older and younger patients.

Manufactured for: EyePoint Pharmaceuticals US, Inc. Watertown, MA 02472



# Making the Case for Greener Cataract Surgery

Current standards for OR safety in the U.S. are causing massive waste and pollution—and studies suggest they're not necessary.

*Christopher Kent, Senior Editor*

**T**oday, anyone working in medicine (or staying in a hospital) would find it hard to miss the extraordinary amount of waste produced by our health-care system. That's certainly true when it comes to surgery, and cataract surgery—one of the most common surgeries performed around the world—is no exception. In fact, not only does cataract surgery usually result in the discarding of contaminated materials, it often results in unused materials being discarded as well. In addition, manufacturing those materials produces all kinds of pollution that exacerbates climate change and impacts the health of those exposed to the polluted air and water.

"We're all trying to manage patients efficiently with minimal cost, but we should also be thinking about managing them in ways that are the least damaging to the environment," says Joel S. Schuman, MD, FACS, director of the NYU Langone Eye Center and chairman of ophthalmology at the New York University School of Medicine, who co-authored one of the key papers focused on the Aravind Eye Hospital in southern India, known for performing cataract sur-

gery with minimal creation of waste and pollution.<sup>1</sup> "We produce a lot of waste, especially in surgery—roughly 20 times the waste of a given operation at Aravind. There's no really good reason for that, except that we make a lot of assumptions about what we need to do in order for the surgery to be safe. What they're doing at Aravind puts the lie to a lot of the precautions that we take. I think there are a lot of lessons we can take home from their experience."

"Defensive medicine is a waste of expensive—and for many societies, precious—resources," agrees David F. Chang, MD, a clinical professor at the University of California, San Francisco. "I believe the same can probably be said about many of our operating room regulations. Although they're intended to reduce the risk of surgical infection, the benefit of some wasteful, but required, practices is unproven by any study. And added to many wasted health-care dollars is the wasteful carbon footprint associated with these practices. Indeed, the health-care sector produces approximately 10 percent of the total greenhouse gases and air pollutants

in the United States.<sup>1</sup> One of the largest problems is that operating room staff—surgeons and nurses—are not allowed to use their discretion with respect to reusing some products or devices."

## Uncovering the Problem

One of the people credited with spurring interest in this field is Cassandra L. Thiel, PhD, currently an assistant professor at the New York University School of Medicine. While earning her PhD, Dr. Thiel learned to use a tool called "life-cycle assessment." "This process takes any product or process and analyzes the steps and stages in its life cycle, from the original extraction of materials and manufacturing to its use and disposal," she explains. "Then, it sums up all the emissions and waste produced at each of those points.

"Initially I applied this tool to so-called 'green buildings,' " she continues. "Then I met a physician who was upset about the amount of garbage produced when she did surgery. She wanted to reduce her carbon footprint at work and was trying to determine

what steps she could take to accomplish that. The common suggestion you hear in hospitals is, ‘Let’s recycle more.’ She wasn’t satisfied with that answer because there was no data associated with it. I thought that the life-cycle assessment tool could be helpful in this situation.”

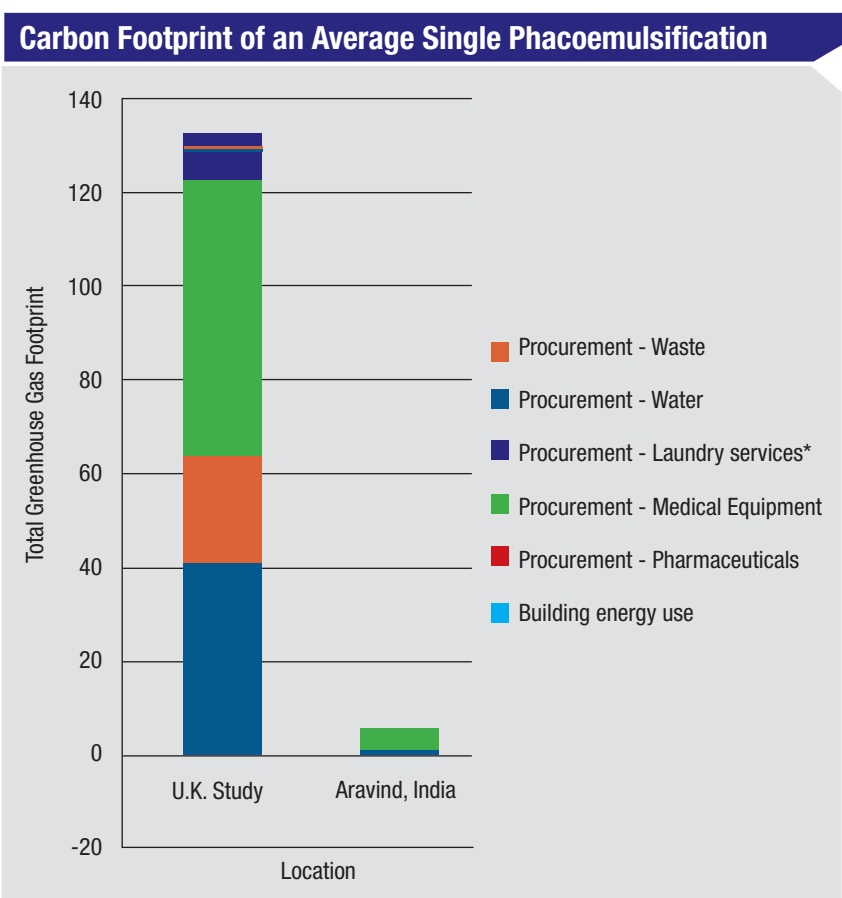
Dr. Thiel and her advisor began by running some studies in her physician mentor’s field, obstetrics and gynecology. “We compared four different approaches to hysterectomy and found that the more advanced the technology—e.g., laparoscopic and robotic procedures—the more waste and emissions were generated. Beyond that, one of the major results was that the environmental emissions were coming almost entirely from the production of disposable materials.

“Not surprisingly,” she adds, “recycling would have very little impact on that footprint.”

Dr. Thiel’s interest in ophthalmology in particular was sparked by a study performed in the United Kingdom that explored the carbon footprint of phacoemulsification surgery.<sup>2</sup> Then, she saw a TED Talk discussing the Aravind Eye Hospital in southern India. “Aravind was set up in the 1970s,” she says. “Their model was built around getting as many people through the system as possible in a safe and effective manner. In India they don’t have the same kind of legal/regulatory situation as we do in the United States, so they were able to innovate new approaches to delivering surgical care.”

### Proving It Can Be Done

Dr. Thiel visited numerous ORs in the United States to observe cataract surgery methodology in America. “What I noted was that health care is provided in pretty much the same manner everywhere,” she says. “You see the same setup, the same surgical supplies; there’s not a lot of variety.



A comparison of factors contributing to the carbon footprint associated with cataract surgery in the United Kingdom and the Aravind Eye Hospital in India, as determined by life-cycle assessment. (U.K. Data from Morris et al 2013<sup>2</sup>; Aravind data from Thiel et al 2017<sup>1</sup>.)

Then in 2014 I received a Fulbright fellowship to go to India and live at Aravind for about four months. I observed their physical setup, what was being done in the OR and what supplies they were using. Then, we did a full life-cycle assessment of their process.

“The most striking result was that one cataract surgery at Aravind only produced about 5 percent of the carbon emissions found for cataract surgery in the U.K. study,” she says. “Perhaps most remarkable, Aravind’s outcomes are on par with—or better than—United States cataract surgery outcomes.<sup>3-5</sup> That means that it’s possible to design your surgical-care pathway in such a way that it drastically reduces the carbon emissions

required for that surgery, while still providing the same quality in terms of outcomes.”

Dr. Thiel says the main reason for that result was the way Aravind set up its surgical-delivery system. “Patients go through the process almost like a factory assembly line,” she explains. “They’re flowing through the system constantly. The surgical staff is never waiting for a patient. The OR has two beds per physician; one bed is being prepped while the other is in use for surgery. The surgeons rotate back and forth between the two beds, using one microscope and one phaco unit.

“Aravind employs ‘task shifting’ by using highly trained mid-level ophthalmic professionals to conduct many of the tasks in the operating room,”



# SMART is Better

TRANSFORM YOUR PRACTICE WITH  
ARTIFICIAL INTELLIGENCE



OPHTHALMOLOGY'S

**EHR & PM Leader for**  
**33 YEARS**

Our Advantage SMART Practice™ suite of All-in-One Solutions use real-time data from your clinic to optimize efficiency, improve outcomes, and increase revenue.

---

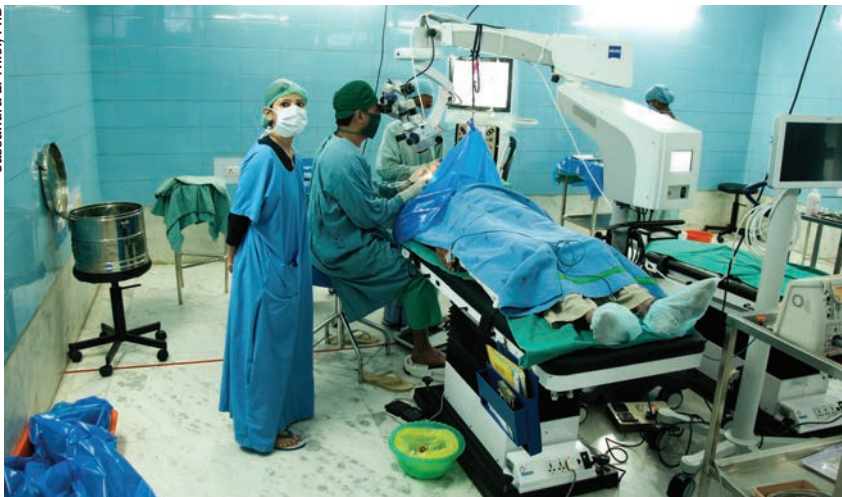EHR | PM | RCM | ASC | OPTICAL  
PATIENT ENGAGEMENT  
WORKFLOW OPTIMIZATION  
PROCEDURE OPPORTUNITY REMINDERS  
ENTERPRISE PROVEN | 2015 ONC CERTIFIED

SEE IT LIVE. **HAWAIIAN EYE 2019.**

[WWW.COMPULINKADVANTAGE.COM/ONETAB](http://WWW.COMPULINKADVANTAGE.COM/ONETAB) | 800.456.4522



Cassandra L. Thiel, PhD



At the Aravind Eye Hospital the surgical staff is never waiting for a patient. The OR has two beds per physician; one bed is prepped while the other is in use for surgery. The surgeons rotate back and forth between the two beds, using one microscope and one phaco unit.

she continues. “Two technicians who are not scrubbed-in help escort patients in and out and help with some of the prep and postoperative work. Two others are scrubbed in—one per table. They’re in charge of delivering surgical supplies and making sure that everything is sterile. The physicians are just doing the surgery, cut to close; they don’t do any of the pre- or postop stuff. Of course, they take a time out to make sure they’re doing the correct eye and so forth, but otherwise the surgeon just does the actual surgery. This process makes the duration of the cases very short. I watched one of their top surgeons do about 40 surgeries in about four hours. That’s especially impressive when you consider that these cases were often challenging patients who were clinically blind from the cataract.”

Dr. Schuman notes that it’s possible to do some things in India that would be much harder to do in the United States. “For instance, having multiple patients in the OR simultaneously would be frowned upon here,” he says. “It’s not because there’s any evidence that doing so is a bad idea; it’s because there’s an assumption that we’d increase the risk of infection.”

Nevertheless, Dr. Schuman believes there’s a lot of opportunity to improve the efficiency and decrease waste in our surgeries. “We’re not even close to being optimized,” he says. “If you look at a place like Aravind, they have efficiency down to a science. Their doctors do a very high volume of surgery of one specific type—cataract surgery. One surgeon may do 50 or 60 cases before lunch. They can do this because there’s not a wasted movement in the OR. Then, along with the efficiency of the operation comes a savings in terms of both supplies and also a reduction in the creation of waste.”

### Reusing Tools in the OR

Dr. Thiel notes two factors that contributed to the efficiency of the Aravind process. “They had a standardized instrument tray, with virtually no variability in what the surgeons were using and how they used the tools,” she says. “That means that purchasing supplies is pretty standardized. Also, they were reusing almost everything. The phaco tips were reused; the blades in some cases were reused. In some cases even the gloves were

reused, which is not something I’d recommend here in the States. To save the time it would take to change gloves between cases, they’d use a sterilizing gel on the gloves before moving on to the next patient. While this may sound dangerous, recent studies of the Aravind Eye Care System documented an endophthalmitis rate of 0.02 percent in 555,550 consecutive cataract surgeries using intracameral antibiotics.<sup>2,4</sup> That’s better than the current rate in the United States.”

Dr. Chang points out that published data strongly suggests that reuse and reprocessing of many “single-use” instruments and supplies does not pose a significant infection risk. “We’ve published the extremely low endophthalmitis rates at the Aravind Eye Care System,” he says.<sup>3</sup> “Their endophthalmitis rate in more than 237,000 consecutive phacos receiving intracameral moxifloxacin was 0.01 percent, which is lower than the current IRIS registry endophthalmitis rate of 0.07 percent. What’s striking about this data is that Aravind routinely reuses gowns, gloves, blades, cannulas, phaco tips, capsulotomy cystotomes, and irrigation solutions and tubing. These are all single-use items in the United States, where the licensing and regulatory agencies don’t give surgeons any discretion to reuse them.”

Dr. Chang is co-chair of the ophthalmic instrument cleaning and sterilization (OICS) task force, a collaboration between the American Society of Cataract and Refractive Surgery, Outpatient Ophthalmic Surgery Society and the American Academy of Ophthalmology. “Our recently released guidelines point out that there is now published data showing that reuse of certain instruments and products is not associated with high endophthalmitis rates,” he says.<sup>6</sup> “We also cited studies performed by OICS task force members that failed to show any dangerous ultrastructural changes re-

sulting from multiple simulated uses of phaco tips.<sup>7</sup> Because of how heavily regulated our hospital and ASC operating rooms are, it really falls on industry to permit responsible reuse of instruments and products via their labeling. However, profitability and liability create strong disincentives to doing that.”

## Switching to Reusables?

Many surgeons are coming to appreciate the problem and looking for things they can do to move cataract surgery in a “greener” direction. One obvious possibility is to consider using fewer single-use instruments and accessories. “I think the health-care system in the United States is way overboard in terms of single-use equipment,” says Dr. Thiel. “We’re not looking at the long-term consequences of this. We’re paying more for the instruments and we’re generating a lot more waste, including a lot of plastic. We already know we have a huge problem with plastic in the environment. In addition, producing all of those items from virgin plastics and metals has an impact on the environment, which has an impact on our health. We’re not just talking about climate change; we’re talking about air pollution and water pollution.”

Dr. Schuman agrees. “Whenever there’s a problem involving infection, or something comes up in medicine that involves sepsis or sterility, the answer—too often, I think—is disposable instruments or supplies,” he says. “That is not always the best answer. It may be that you could do just as well with a nondisposable that’s properly cleaned and sterilized. Furthermore, the quality of a single-use instrument is often not as good as a nondisposable one. And working with reusable instruments does not make the surgery take longer—the experience at Aravind definitely shows that.

“I think we need to take a step back

and look at how we’ve been addressing problems having to do with patient safety,” he continues. “We need to use an evidence-based approach, instead of simply assuming that we need to use disposable devices or instruments to ensure patient safety.”

*“Making this kind of change isn’t just about decreasing waste and pollution; it’s also value-based medicine.”*

*— Joel Schuman, MD*

Given that switching back to reusable surgical equipment is an obvious way to address this problem, why aren’t more surgeons doing so? Two practical concerns are a big part of the answer.

“Switching supplies is always a little challenging, because it’s tied to the contracts that exist in your institution,” Dr. Thiel points out. “I’ve heard stories from the food service industry about institutions that can’t get rid of soft drinks because they have to wait five years for the current contract to expire. That happens with surgical instrumentation, too. Of course, there are plenty of reusable supplies out there. If you’re willing and able to go through the negotiations with your institution and the manufacturers, please do. If not, that’s OK, but you can start getting people thinking about it before the next contract comes up. If you succeed, there might be enough motivation to make the switch to reusables when that happens.”

Another factor that has had a lot to do with the widespread use of single-use tools is the fear of being sued should something go wrong. “In any

surgery, I think there’s an expectation that everything will go well, and usually it does,” says Dr. Schuman. “However, there’s a tendency—especially in the U.S.—to assume that if things don’t go well, it’s somebody’s fault. One of the side effects of this is that if you’re doing things in an unconventional way, you’re more susceptible to legal action than if you’re doing things the same way as everybody else. That inhibits the introduction of different ways of doing things.

“Today,” he continues, “we have organizations that say, ‘In order to reduce risk and increase safety we have to use disposables.’ In fact, there’s no evidence that using disposables is safer. But if you say, ‘OK, this doesn’t really reduce risk, so I’m going to go back to working with reusable instruments,’ you’ve opened yourself up to legal action if something goes wrong. Something always goes wrong eventually, because we don’t live in a perfect world. Then, the first question you’re going to get is, ‘Why aren’t you doing this the way everybody else is?’—even if the problem didn’t come from reintroducing reusables.”

## Other Strategies That Can Help

Taking these steps can also reduce waste and pollution:

- **Standardize your equipment lists.** “Sit down with all of the other ophthalmologists in your group and figure out what’s the least amount of materials you need to do cataract surgery,” says Dr. Thiel. “Go through your custom-pack lists, your physician-preference cards, and look for items you don’t actually use that much. Those items could be available on an ‘as needed’ basis. You might even find items you used in the past that you rarely use today, items that shouldn’t even be on the list.”

- **Tell your surgical team not to open anything unless you explicitly say it’s needed.** “The less



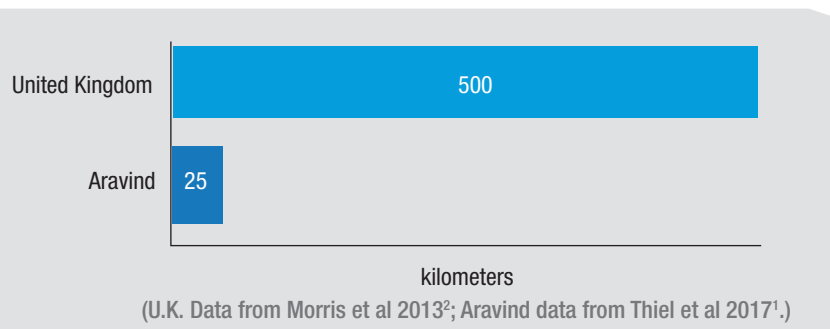
you bring into the OR, the better it is overall,” notes Dr. Thiel. “We see a lot of waste in the OR custom packs. I’ve observed that physicians in the same institution often use identical custom packs, but one physician might use two of them while another might only use a quarter of one. Sometimes the surgeon is missing one instrument, so the surgical team opens up another custom pack to grab that one item out. That’s the kind of waste that can be avoided if you have better communication with your team—and you let your team know that one of your priorities is reducing waste. Your staff should know not to open something just because you might need it. You want them to confirm that it’s needed before they open another pack.”

- **If possible, dedicate each OR to one type of surgery exclusively.** “One reason Aravind is so efficient is that their ORs do only one type of surgery per room,” says Dr. Schuman. “An OR that’s only used for one purpose can function more efficiently than one that’s used for different types of cases throughout the day. If you’re in a hospital OR, the personnel might be constantly switching throughout the day between different types of operations—or even different disciplines. That’s going to be much less efficient than having a room that’s just doing cataracts all day, and having personnel who staff that room on a regular basis and always do that type of case. Decreasing the variability would help to increase the efficiency with which the cases can be done—not to mention increasing the predictability of outcomes.”

- **Consider giving your cataract surgery patient the eye drops used in the OR to take home.** “This simple step would reduce the amount of waste tremendously,” Dr. Schuman notes.

- **See what’s available in terms of single-use device reprocessing and systems for recycling.** One idea

### Distance Driven to Equal the Carbon Emissions of One Phaco



that’s arisen to help offset some of the consequences of excessive use of single-use equipment is single-use device reprocessing. “There are third-party companies that will take single-use devices, break them apart, clean and sterilize them, test them and sell them back to hospitals for perhaps half the price of the original,” says Dr. Thiel. “This reprocessing market is becoming much more popular in the U.S. as a cost-saving method. The thinking is that it’s more environmentally friendly, because you’re clearly reducing waste. (We haven’t yet conducted life-cycle assessments of this process, so we don’t know about the level of emissions associated with it.) At this point, I’m not sure how many ophthalmic tools can be reprocessed, but if you find options that could reduce waste, advocate for using them.”

Dr. Thiel notes that the availability of this service has (predictably) resulted in a cat-and-mouse game in the industry. “Often, the original instrument manufacturer will try to change the design just enough so that the reprocessors have to get a separate FDA approval to be allowed to reprocess the device,” she says. “It’s a bit of a challenge for the reprocessing industry to keep up when the manufacturers are trying to discourage reprocessing.”

- **Consider donating unused supplies.** “In some situations there may be ethical issues here, but in many cases this can be done,” says

Dr. Thiel. “It will at least give those supplies some lifespan after being left unused in the OR.”

- **Get the people around you excited about reducing waste and increasing efficiency.** “You don’t have to preach about carbon emissions,” notes Dr. Thiel. “It can be as simple as asking, ‘How can we use fewer supplies?’ If you spread the word, you’ll find that everyone will have ideas that could help. Eventually, that ground-level engagement could potentially start a movement at your institution and get people from the top down prioritizing some of these things.”

- **Ask your ophthalmology organizations to get involved.** “Changing this situation will require the efforts of more than one person,” Dr. Schuman says. “The support of organized medicine will be critical to making these changes. This is more than a medical issue; creating change will require legal-political decision-making. Our organized ophthalmology associations need to take up the mantle and make the effort on our behalf. Those organizations can develop white papers supporting the types of innovation that would reduce surgical waste and increase efficiency. That would lend a lot of credence to groups and individuals that wish to adopt those methods.”

### Looking to the Future

With the world seeing more and

more unintended consequences of ignoring our prolific waste creation and oversized carbon footprint, one might well wonder: What will happen if nothing about the way we currently perform cataract surgery changes? “I see an increase in costs and production of waste,” says Dr. Schuman. “Aside from other consequences, the money to keep paying for this is simply not there. We have to find ways to do this work more efficiently and using fewer resources. Those ways are available; we just haven’t adopted them in the U.S.”

Dr. Thiel notes that in her experience, no doctors are happy with how much garbage their surgeries create. “Waste is everywhere in medicine,” she notes. “Ophthalmologists as a group have expressed the most interest in this of any medical specialty

I’ve spoken to. Maybe that’s partly because ophthalmologic surgery has a relatively low infection risk compared to something like orthopedic surgery, where there’s blood everywhere. That means there’s more opportunity to make changes that are safe and effective and don’t compromise care than there would be in some of these other clinical settings. That’s one reason I think ophthalmology can lead the way to start making some of these changes, and demonstrate that they’re safe and effective.”

“Green surgery is something we should all be thinking about,” Dr. Schuman concludes. “This is not just about helping the individual patient—we should be trying to help the planet as well. Besides, making this kind of change isn’t just about decreasing waste and pollution; it’s also

value-based medicine. This is about consuming fewer resources in order to produce a good outcome.” **REVIEW**

*Drs. Schuman, Chang and Thiel report no financial ties to anything discussed in this article.*

1. Thiel CL, Schehlein E, Ravilla T, et al. Cataract surgery and environmental sustainability: Waste and lifecycle assessment of phacoemulsification at a private healthcare facility. *J Cataract Refract Surg* 2017;43:11:1391-1398.
2. Morris DS, Wright T, Somner JE, Connor A. The carbon footprint of cataract surgery. *A Eye (Lond)* 2013;27:4:495-501.
3. Haripriya A, Chang DF, Ravindran RD. Endophthalmitis reduction with intracameral moxifloxacin prophylaxis: Analysis of 600,000 surgeries. *Ophthalmology* 2017; 124:768-775.
4. Chang DF, Haripriya A, Ravindran RD. Reply to letter RE: Endophthalmitis reduction with intracameral moxifloxacin prophylaxis: An analysis of 600,000 surgeries. *Ophthalmology* 2017; 124:e78-e79. Available at: [http://www.aaojournal.org/article/S0161-6420\(17\)30748-0/pdf](http://www.aaojournal.org/article/S0161-6420(17)30748-0/pdf).
5. Haripriya A, Chang DF. Intracameral antibiotics during cataract surgery: Evidence and barriers. *Curr Opin Ophthalmol* 2018; 29:33-39.
6. Mamalis N, Chang DF. Guidelines for the cleaning and sterilization of intraocular surgical instruments. *J Cataract Refract Surg* 2018;44:6:675-676.
7. Tsaousis KT, Chang DF, Werner L, et al. Comparison of different types of phacoemulsification tips. III. Morphological changes induced after multiple uses in an ex vivo model. *J Cataract Refract Surg* 2018;44:1:91-97.

# Prevent **Wrong-Site Surgical Error** with **Varitronics' EYE-DENTIFIER**



The **EYE-DENTIFIER** is a thoroughly designed, inexpensive and simple system of tape labels. The product ensures that you avoid wrong-site surgery, and fulfills your legal and medical obligation in this area. Each tape label has a central blank area, which can be used to record other information, such as IOL type and power, or as an indication that patient identity has been confirmed. The **EYE-DENTIFIER** has been used by thousands of ophthalmologists for more than 20 years to minimize the possibility of a wrong-site or wrong-procedure error, and is an elegant way to avoid a potentially serious problem.

## Product Features:

- Latex-free labels, made of flexible, silky, rayon tape.
- Their waterproof glue facilitates firm adherence to the patient's forehead, yet allows for easy, residue-free removal following surgery.
- Far superior to ink or surgical marker dyes, which can be difficult to read or interpret and often remain visible for days following surgery.

The **EYE-DENTIFIER** has been used by thousands of ophthalmologists for more than **20 years**

**VARITRONICS**

Call: 610-35-3995  
 Email: [varimed@varitronics.com](mailto:varimed@varitronics.com)  
[www.varitronics.com](http://www.varitronics.com)

**To receive a free sample pack or order a trial supply, call us at 610-356-3995**



# IFIS: Know the Risks And Manage the Signs

Intraoperative floppy iris syndrome has the potential to derail cataract surgery, especially if it comes as a surprise.

*Kristine Brennan, Senior Associate Editor*

**W**hen John R. Campbell, MD, and David F. Chang, MD, noted that certain cataract patients in their respective California practices experienced iris billowing, progressive pupil constriction and iris prolapse during surgery, they investigated. A retrospective review and a larger, prospective companion study published in 2005 led to the first description of intraoperative floppy iris syndrome.<sup>1</sup> Here's a look at where we are in terms of awareness of IFIS across specialties, and an overview of prevention and management techniques.

That 2005 study implicated the use of tamsulosin (Flomax; Boehringer Ingelheim; Ridgefield, Connecticut) an alpha-1 adrenergic antagonist used to treat benign prostate hyperplasia (BPH) in men. Tamsulosin has other uses too, including relaxing the smooth muscles in the bladder for women who have difficulty passing urine, facilitating the release of kidney stones and treating hypertension. Other alpha-blockers used for BPH therapy include terazosin, doxazosin, alfuzosin and silodosin.

"It also causes changes to the receptors that are responsible for contrac-

tion of the iris sphincter muscles," says Steven M. Silverstein, MD, of Silverstein Eye Centers in Kansas City, Missouri, of tamsulosin (and other alpha blockers). "Urology is the primary specialty that prescribes that class of drugs. Primary care, including internal and family medicine, do as well. And to a lesser degree, even OB-GYN specialists prescribe these medicines."

## Alpha-Blockers

As many as 80 to 90 percent of men develop BPH by their 70s or 80s.<sup>2</sup> This is important because IFIS complicates cataract surgery to varying degrees, potentially leading to iris trauma, posterior capsular tears and vitreous loss. The classic signs of iris billowing, pupil constriction and iris prolapse are collectively referred to as the IFIS triad. When the patient's history of taking tamsulosin or even other, less-selective alpha antagonists is known, however, surgeons can factor IFIS risk into their plans and deliver good outcomes. Getting a positive history of alpha-blocker use may not be that simple, however. Even one dose of tamsulosin seems to pre-

dispose patients to IFIS forever, so discontinuing treatment appears to be useless for mitigating IFIS risk,<sup>3</sup> and a patient may not remember a long-discontinued medication.

"The only real way to prevent IFIS is to avoid using this class of medicines in patients who haven't yet undergone cataract surgery," says Dr. Silverstein. "If you've taken the medicine as briefly as just two or three days and then discontinued it, you still have the potential for IFIS complications for the rest of your life. There's no benefit in terms of decreasing risk by stopping the medication prior to surgery."

Poor pupil dilation with mydriatic drop instillation during a preop workup is predictive of severe IFIS risk,<sup>3</sup> but surgeons should still strive to get a definitive history regarding the patient's use of tamsulosin and other alpha antagonists. To that end, the American Academy of Ophthalmology and the American Society of Cataract and Refractive Surgery have issued joint advisories on alpha-blockers for prescribing providers and patients. The latest educational update for providers, from 2014, urged them to consider initiating therapy with a



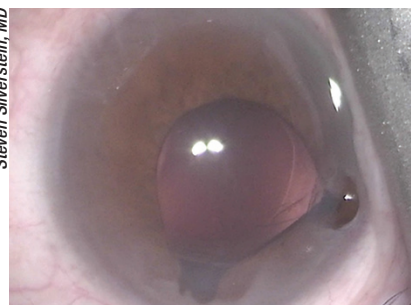
less-selective substitute for tamsulosin, based on research showing that one such alternative alpha-blocker, alfuzosin, was associated with a significantly lower incidence of severe IFIS than tamsulosin.<sup>4</sup> The update also advised that cataract patients slated for non-emergent tamsulosin therapy may wish to undergo cataract surgery prior to initiating the drug treatment. For patients, the AAO and ASCRS advise those with cataracts to consider the relationship between alpha-blocker use and increased risk of cataract-surgery complications before initiating drug therapy; caution patients taking alpha-blockers to inform their ophthalmologist prior to ocular surgery; and advise cataract patients who need alpha-blocker therapy to consider starting with a nonselective alpha antagonist instead of tamsulosin. The advisory also suggests that patients with symptomatic cataracts consider undergoing cataract surgery prior to starting any alpha-blocker treatment.

“From a primary-care, urology and OB-GYN standpoint, providers should check with the patient to see whether or not the patient and their ophthalmologist are contemplating cataract surgery in the near future,” says Dr. Silverstein. “If so, they should hold off on prescribing these medicines until after cataract surgery whenever possible.” He believes that awareness is growing among prescribing providers. “I would estimate that at this point, probably two-thirds of the providers prescribing alpha-1 antagonists are aware of the potential risks to the eye with surgery in patients who take these medicines,” he says.

## Pharmacological Prophylaxis

Intracameral mydriatic agents were found to be safe and effective prior to the identification of IFIS.<sup>5</sup> To prevent IFIS and its signs, Samuel Masket

described pre-medicating at-risk patients with topical atropine sulfate 1% three times a day for two days before surgery, standard mydriatics and intraoperative intracameral epinephrine, attributing success in 19/20 eyes to synergy between the pupillary block provided by atropine and the iris-dilator stimulation of the epinephrine.<sup>6</sup> The late Joel K. Shugar, MD, MSEE, subsequently described using intracameral epi-shugarcaine (9 cc fortified BSS; 4 cc bisulfite-free 1:1000 epinephrine, and 3 cc preservative-free lidocaine) and eliminating preoperative atropine.<sup>7</sup> Intracameral phenylephrine has also been used to prevent IFIS.<sup>8</sup>



Iris prolapse signifies severe IFIS progressing from iris billowing and miosis.

In 2017, the Food and Drug Administration issued an advisory letter to health-care providers warning that Par Pharmaceuticals, an important generic supplier of bisulfite-free epinephrine, had changed its formulation, adding tartaric acid, making it unsafe for intraocular use. In December 2017, the AAO and ASCRS both advised surgeons of the shortage. Among the coping strategies the ASCRS recommended were seeking preservative-free epinephrine from small suppliers; substituting phenylephrine and lidocaine and considering the use of Omidria (Omeros; Seattle) phenylephrine 1% ketorolac 0.3% as an alternative.

Dr. Silverstein has adopted Omidria in the irrigation bottle for cataract cases, regardless of known IFIS risk

factors. “Intraoperatively, it’s the only thing I use to decrease the risk of IFIS in a majority of cases,” he says. Dr. Silverstein was the first author on a study comparing men with a history of tamsulosin use who had Omidria in the irrigation bottle with those who didn’t have it. The treated group had significantly less miosis, pupil billowing and iris prolapse during cataract surgery than tamsulosin-treated men who did not.<sup>9</sup> “Its use showed a statistically significant reduction in the triad of signs and symptoms of IFIS—mainly iris billowing and flaccidity, pupillary miosis and iris prolapse—compared to those who did not receive treatment,” he says.

## Mechanical Measures

Although IFIS prevention and management isn’t standardized, a menu of accepted interventions exists. “I’m thankful to David Chang and John Campbell for doing the original epidemiology that brought attention to and awareness of the relationship between alpha-1 antagonists and IFIS,” says Dr. Silverstein. “With this awareness comes a variety of solutions we can employ.”

If mydriatic and/or pupilloplegic drugs don’t prevent IFIS signs, iris hooks and pupillary rings can help keep the pupil big enough for phaco to safely continue; each has its benefits. “Every case is unique and there are times you may use a pupil-expansion device such as a Malyugin ring or iris hooks,” Dr. Silverstein observes. “Sometimes, you can use a heavier molecular-weight OVD to help hold the iris back during phacoemulsification. I prefer the Malyugin ring for its ease of use, but iris hooks are more cost-effective since they can be sterilized and reused,” he says.

Further modifying surgical techniques may also prove helpful. A small  
*(continued on p. 66) (continued from p. 23)*

# AI & Ophthalmology: The Pros and Cons

*Christopher Kent, Senior Editor*

Artificial intelligence is already beginning to transform ophthalmology—but caution is advised.

There's no question that artificial intelligence is a tool with enormous potential. Because it can process information far faster than humans—and can manage vast quantities of data—it's slowly but surely becoming a part of medicine in the United States and around the world. Here, we'll review some of the ways AI could benefit ophthalmology; some of the research already underway; and potential pitfalls that are now becoming clear as the technology evolves.

## AI and “Deep Learning”

In the realm of artificial intelligence in medicine, the process referred to as “deep learning” is of particular interest. Dimitri Azar, MD, MBA, distinguished professor of ophthalmology at the University of Illinois College of Medicine in Chicago and senior director of ophthalmic innovations at Alphabet Verily Life Sciences, explains that, in the case of image analysis, deep learning involves constantly refining the weighting, or relative importance, of details in the images as system learning progresses. “These programs allocate a certain weight for criteria that they discover in these images,” he says. “With each new image the weights are modified to accommodate the new information, and the

process keeps repeating. Humans can do this type of analysis at a smaller scale, but when the amount of data soars, we need help from AI.”

Potential areas in ophthalmology that might eventually benefit from this process include:

- corneal topography;
  - the interpretation of fundus photography and OCT scans;
  - IOL power prediction;
  - screening for and diagnosing eye problems such as diabetic retinopathy, glaucoma, macular degeneration and dry eye;
  - predicting the speed of progression of diseases such as macular degeneration and glaucoma;
  - predicting treatment outcomes; and
  - predicting the likelihood of needing treatment in the future.
- At a more general level, AI may:
- help us capture photographs and scans more accurately;
  - act as an automatic scribe;
  - predict future medical crises that a patient may face;
  - improve patient flow;
  - analyze and sort data so that the physician has to view only the most relevant information; and
  - help to discover new associations between diseases and the characteristics of a patient's eye.

## Current Research: A Sampling

Here are just a few recent developments involving AI:

- IDx-DR (IDx Technologies) has become the first FDA-approved device that can make a screening decision without clinician input. Data from a prospective clinical trial of the IDx-DR system, involving 900 subjects with diabetes at 10 primary care sites across the United States, were recently published. The system exceeded all prespecified superiority endpoints with 87-percent sensitivity, 90-percent specificity, and a 96-percent imageability rate.<sup>1</sup>

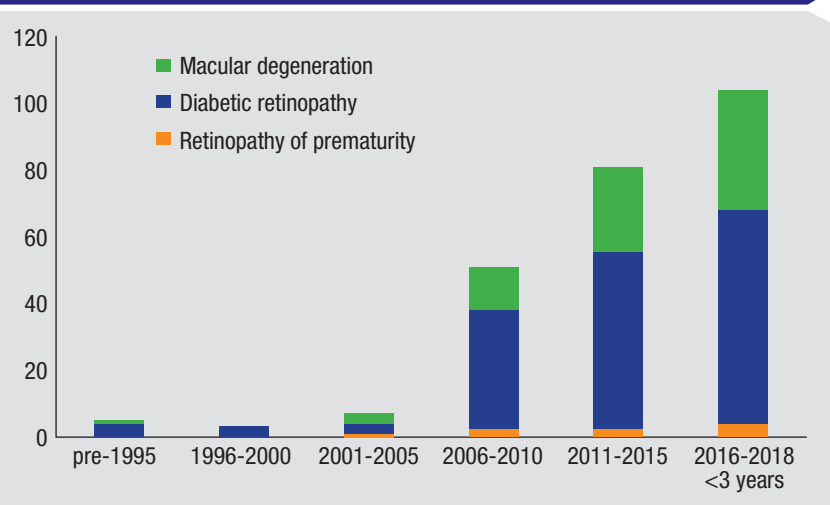
- Philippe M. Burlina, PhD, and colleagues have used two deep-learning algorithms to categorize more than 130,000 fundus images as falling into one of two categories: disease-free/early macular degeneration, or intermediate/advanced macular degeneration. The algorithms' accuracy ranged from 88.4 to 91.6 percent.<sup>2</sup>

- A research group used a deep-learning system to detect severe non-proliferative diabetic retinopathy and proliferative diabetic retinopathy—as well as macular degeneration and glaucoma.<sup>3</sup> A validation data set of 71,896 images revealed a sensitivity of 90.5 percent and specificity of 91.6 percent for referable diabetic retinopathy; a sensitivity of 96.4 percent and specificity of 87.2 percent for possible glaucoma; and a sensitivity of 93.2 percent and specificity of 88.7 for macular degeneration.

- Researchers in Japan used a deep-learning algorithm to detect rhegmatogenous retinal detachment in Optos ultra-widefield fundus images. It demonstrated a sensitivity of 97.6 percent and specificity of 96.5 percent.<sup>4</sup> The same research group conducted another study using Optos ultra-widefield fundus images to detect neovascular macular degeneration; the sensitivity was 100 percent; specificity was 97.31 percent.<sup>5</sup>

- Researchers in Germany trained

## Interest in Artificial Intelligence, as Reflected in the Literature



Dimitri Azar, MD, MBA

The quantity of published research reveals a steady increase in interest in AI.

a deep convolutional artificial neural network to predict patients' need for anti-VEGF injections, based on central retinal OCT scans and their intravitreal injection records. When applied to a validation data set after training, the algorithm showed a prediction accuracy of 95.5 percent, with a sensitivity of 90.1 percent and specificity of 96.2 percent.<sup>6</sup>

- Researchers in Vienna evaluated the potential of "random forest" machine learning to predict best-corrected visual acuity outcomes in patients receiving ranibizumab therapy for neovascular AMD, using structural and functional assessments during the initiation phase. The model's accuracy increased each month; at month three, final visual acuity outcomes could be predicted with an accuracy of  $R^2=0.7$ .<sup>7</sup>

- The same team conducted a pilot study to see if machine learning could predict the frequency of anti-VEGF injection requirements in neovascular AMD patients, using OCT images acquired during the initiation phase. The algorithm's accuracy for predicting low need for treatment was  $AUC=0.7$ ; its accuracy for predicting high treatment need was  $AUC=0.77$ .<sup>8</sup>

Despite the obvious promise of this technology, potential problems are also on the horizon. Now that AI screening is a reality, concerns include: Will a "clean" report from an AI screening lull people into a false sense of security about their overall eye health? Will over-reliance on technology cause doctors' skills to atrophy due to lack of use? Will AI cause technicians and physicians to lose their jobs? And perhaps most significant: Will imperfect technology cause patients to suffer harm due to a missed diagnosis or incorrect prediction?

Here, several experts address these and other questions.

## The Benefits of AI

Pradeep S. Prasad, MD, associate professor of ophthalmology at the Jules Stein Eye Institute, David Geffen School of Medicine at UCLA, and chief of the Division of Ophthalmology at Harbor-UCLA Medical Center, sees AI as having tremendous potential to help manage patients in a world of limited resources. "Part of my job here at UCLA is to oversee one of our county hospitals—Harbor-UCLA Medical Center, which takes care of

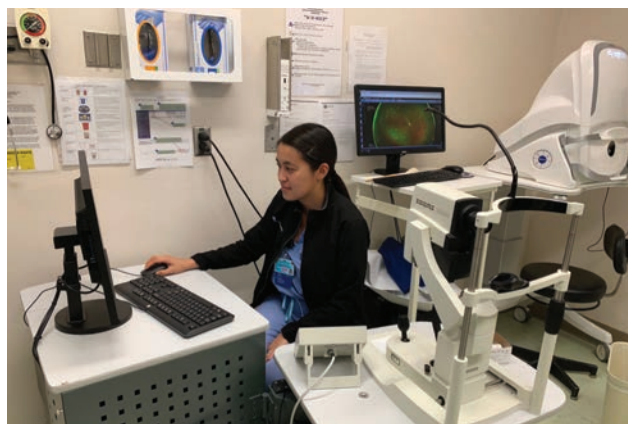


thousands of patients,” he explains. “One of the challenges we face is a very large number of diabetic patients, many of whom have very advanced stages of disease. As a result, the volume of patients we need to screen for vision-related complications of diabetes is very high.

“In the past, those patients would have been referred to the eye clinic, but the clinic only has so much capacity,” he continues. “So, we did what a lot of health systems are doing—we implemented a teleretinal screening program. Ours is based in the primary care setting, where fundus photos are taken of patients who are diabetic. Those images are then uploaded to a server; within a day or two, trained image readers review the images and grade them for two things: whether or not the patient has diabetic retinopathy and needs to be referred to an ophthalmologist for further evaluation, and whether there’s evidence of other nondiabetic disease, such as glaucoma or cataract.”

Dr. Prasad says this system has resulted in a significant increase in the number of patients who are screened. “The problem is, there’s still a huge volume of patients for us to see,” he says. “So, we’ve implemented a second-tier screening program, in which we do further imaging with wide-angle fundus photography and OCT. These two tests give us more information than we can acquire in the primary care setting. The result is that we can further pare down the number of patients who actually have to see an ophthalmologist. This has been very effective at decreasing the number of patients coming in who don’t really need to be seen.”

Dr. Prasad notes that AI has the potential to improve the current system in at least three ways. “The first way AI



Pradeep S. Prasad, MD

AI has shown significant skill at analyzing images, something still largely done by human readers (above). Some surgeons are not impressed by AI’s comparable accuracy, but the immediate turnaround time provided by AI is a significant practical advantage.

can help is in terms of time efficiency,” he says. “Right now, after an image of the retina is acquired, it’s sent to a server. At some point, usually within 24 to 48 hours, the image is read and a recommendation goes out. The problem is, by that time the patient has left the primary care setting. Of course, there are other opportunities to educate the patient about the disease later on, but it’s very powerful to be able to educate the patient and use the findings as a motivating factor immediately after the image is captured.

“The second way AI may help is in terms of cost,” he continues. “It’s expensive to hire people to read these images. We have limited resources, and we want to use our resources as effectively as possible. AI can get accurate readings in a cost-efficient way.

“The third potential advantage of AI is accuracy,” he says. “There’s a lot of evidence that AI can grade images as accurately—and potentially more accurately—than human graders, and do it quickly. For example, one criterion for moderate or intermediate-stage nonproliferative diabetic retinopathy might involve counting the number of hemorrhages, or other features in the image that would imply different stages of disease. If that’s done by a human being it can be very time-consuming

and potentially not as accurate as if a machine does the counting.”

Dr. Prasad says the other thing he finds exciting about AI is the possibility that it may uncover associations between disease and detectable characteristics in the eye—signs that doctors are currently unaware of. “Perhaps the software will detect a link between disease and vessel tortuosity, or ratios of vessel diameters, or some other features we’re not aware of,” he explains. “Maybe it will find a link to the location or

distribution of pathology and be able to correlate that with the patient’s risk going forward. It’s really exciting that AI may not only give us information about the patient’s current disease state, but also may give us some insight into what else is going on, including what a patient’s risk is going forward and what benchmarks a patient must achieve to reduce his risk.”

## Potential Downsides

Despite the possible benefits, many doctors worry about possible negative developments that could occur:

- **AI will miss things it’s not looking for, giving patients a false sense of security.** “This is true of any screening program, including the non-machine-based teleretinal screening-based programs,” Dr. Prasad points out. “It’s not necessarily inherent to machine learning.”

Dr. Azar says he’s not worried about this. “The condition a diabetic patient is likely to have is diabetic retinopathy, so it makes sense to screen for that,” he says. “Furthermore, the programs under development at places like Google are able to recognize many more diseases than just diabetic retinopathy. We have to start somewhere, and it makes sense to start with diabetic reti-

nopathy because it's the lowest-hanging fruit. But the field will not stop at diabetic retinopathy screening."

• **A machine will miss things that a human reader would notice.** "That has to do with training," Dr. Prasad points out. "If you're only asking the machine to look for certain things, then it will only look for those things. If the machine overlooks something, I'd say that's not the fault of the machine—it's the fault of the person who trained the machine."

• **AI could result in people losing their jobs as machines do those same jobs faster and more accurately.** Rich Caruana, PhD, is a principal research scientist at Microsoft Research; he's been involved with AI for 30 years and deep neural nets for five or 10 years. Although he's concerned about current limitations of AI in health care (more on that below), Dr. Caruana foresees it eventually becoming accurate enough to make some professions outmoded.

"Because deep learning works so well on images, some deep learning researchers suspect that one of the first specialties that will disappear in medicine will be image reading in radiology or diabetic retinopathy," he says. "For that reason, I wouldn't recommend that my kid go into radiology right now. Somewhere between five and 20 years from now, you'll want your radiogram read by a computer, not by a human. The computer will be more accurate."

Dr. Prasad points out that such changes are part of progress. "The industrial revolution changed the human economic landscape, too," he points out. "New technology appears and peoples' jobs change. What they thought was part of their job is no longer there, so they find other things to do. I don't think people should look at it as a threat; I think they should look at it as an opportunity."

Dr. Prasad adds that no artificial intelligence is going to eliminate the need for doctors. "There will always be

opportunities for human beings to take care of patients," he says. "It's a field that's very much based on human interpersonal interaction. You can give a patient a lot of information, but unless you have a trusting relationship and a dialogue between the provider and the patient, the implementation of a treatment plan will probably falter."

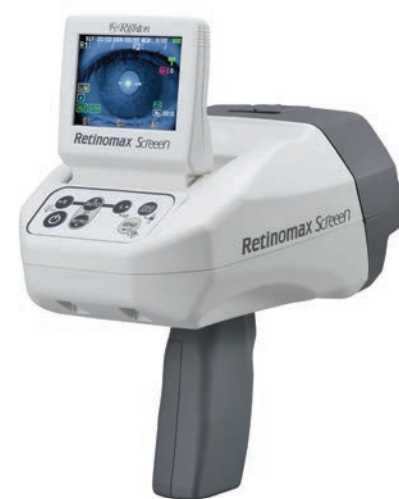"Doctors will never be replaced by AI technology," agrees Dr. Azar. "I believe there will be a greater emphasis on the humanistic elements of medicine to complement the inevitable use of data analytics and computers in medicine. For that reason there will be a greater need to educate medical students, residents and fellows in the art and science of compassionate patient care."

"I envision a health-care system in the future where I don't have to spend my time reviewing images," adds Dr. Prasad. "I can spend more of my time talking to my patients and explaining to them what the information means and what they can do to improve their health. I think that's a much more useful way to spend my day than doing something a machine could do."

• **AI could cause surgeons' skills to atrophy as machines take over more responsibilities.** Dr. Azar says he's not concerned about these changes causing surgeons' skills to atrophy. "We'll just depend on computers to do the tasks that they can perform better than us," he says. "Meanwhile, this will give us more time to focus on doing the things that computers can't do. The health-care system will become more efficient, and doctors will enjoy taking care of patients who really need their help. Instead of replacing ophthalmologists, AI will make their work more relevant."

### The Importance of Intelligibility

Dr. Caruana is a proponent of so-called "intelligible machine learning," which eliminates some of the down-



**NEW**  
HAND-HELD AUTOREFRACTOR  
**RETINOMAX**  
*Screen*  
Righton

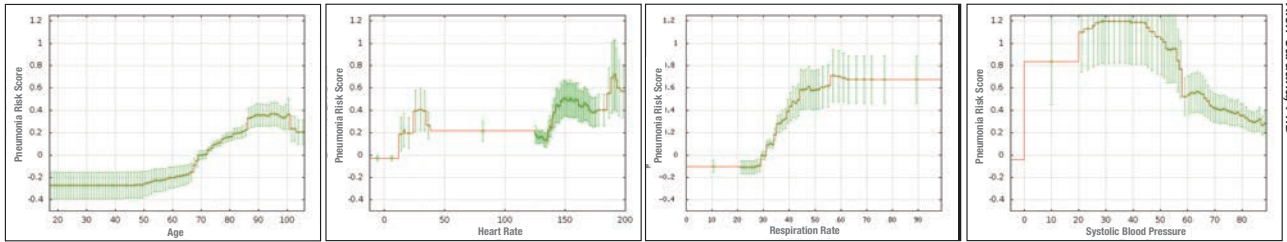
- NEW** Color LCD Screen
- NEW** Focus Assist with Color Coded Guides
- NEW** Children's Mode with Melody and Colors
- ✓ Fast and Accurate Measurements
- ✓ Perfect for Mobile Situations
- ✓ Ergonomically Balanced
- ✓ Flexible Positioning—Sitting, Standing, Supine

More Information: [info@s4optik.com](mailto:info@s4optik.com)

**S4OPTIK**

[www.s4optik.com](http://www.s4optik.com) | 888-224-6012

Sensible equipment. Well made, well priced.  
For today's modern office.



Rich Caruana, PhD

Above: Sample graphs produced by an intelligible deep learning system designed to predict the probability of death from pneumonia, revealing the correlations it’s found between pneumonia outcomes in its learning data set and 46 features such as age, blood pressure, blood sugar level, and having asthma or heart disease. The model also produces 10 pairwise interaction graphs (see examples, facing page). These are all intended to be used by a doctor as extra information to help assess patient risk and need for hospitalization.

sides of the “black box” approach. “Intelligible machine learning refers to systems that are able to describe what they’ve learned,” he explains. “I think that’s very important for health care. When we began this work seven or eight years ago, very few people were concerned about understanding what these systems were learning. Now, lots of research is being done in this area.”

Dr. Caruana says his interest in this began back when he was a graduate student at Carnegie Mellon in the mid-1990s. “I was asked to train a neural net to look at data from patients diagnosed as having pneumonia to figure out which patients should be put in the hospital,” he says. “Pneumonia is serious; five to 10 percent of those who get pneumonia die from it. But if you’re an otherwise healthy individual, it’s actually safer for you to be treated as an outpatient because of the possibility of picking up another infection in the hospital.

“The neural net I trained turned out to be very accurate,” he says. “But when I was asked whether we should use the program on real patients, I said no. Even though the model appeared to be very accurate, it was a ‘black box’; we didn’t understand how it was making its predictions. That meant that there could be problems in there we didn’t know about.

“My fears were based on experience,” he continues. “A colleague of mine trained a machine learning model to do the same thing using the same data set; his system concluded that

your risk of dying from pneumonia was smaller if you had asthma! We knew that wasn’t right. Later, when we attended a project meeting with MDs present, they confirmed that asthma is, in fact, a serious risk factor if a patient develops pneumonia. But they also explained why the program might have come to the opposite conclusion. They pointed out that asthmatics pay attention to how they’re breathing, and they probably have a doctor who is treating them. As soon as these individuals sense something is wrong they go to see the doctor. They get a proper diagnosis pretty quickly, and because they have asthma, they get high-quality, aggressive treatment. The result is that the asthmatics in the data set looked like they had less chance of dying—but only because they got to a doctor faster and received aggressive treatment when they got there.

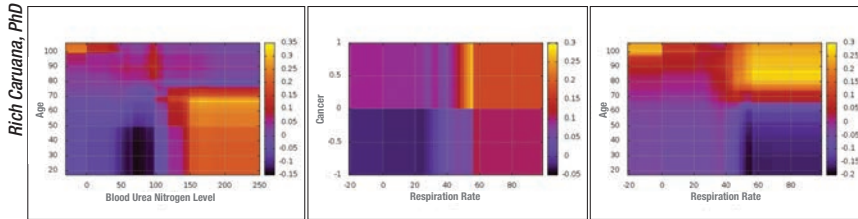
“A machine learning model doesn’t understand this at all,” he points out. “It just sees that the people with a history of asthma have a smaller chance of dying. It doesn’t know why. And because of that, it’s happy to go ahead and predict that asthmatics are lower-risk. That means that if we use this model to try to decide which patients diagnosed with pneumonia should get rapid attention or be put in the hospital or receive more aggressive treatment, we could be putting asthmatics at risk. We’d be denying them the sort of rapid, aggressive treatment that, in fact, made them look like they were at lower risk in the data set.”

Dr. Caruana notes that this particular problem could probably be fixed by altering the program. “What really worried me,” he says, “was what else the neural net might have learned that we couldn’t see. The real problem is the ‘unknown unknowns.’ I can’t fix a problem if I don’t know it’s there, and the neural net at that point was a ‘black box.’

“Unfortunately, today’s really accurate learning methods tend not to be very intelligible,” he says. “So, I’ve been working for the past seven years or so on developing intelligible machine learning methods that wouldn’t come with reduced accuracy. Thanks to a lot of hard work, our current intelligible model is just as accurate as the neural net. Now we’ve been able to apply it to the same data set, to see what it learned. It did indeed learn that asthma is good for pneumonia patients. It also learned that heart disease and chest pain and being more than 100 years old are good for pneumonia patients! In fact, it concluded that the most protective thing of all is having had a heart attack within the past few years. The explanation was the same: If you’ve had a heart attack, you waste no time getting help when you sense a problem exists.

“Now, with our new intelligible systems, we’re able to see things like this in the model and fix them before we deploy them,” he says. “This is why I believe intelligibility is critical if we’re going to use these models in health care.”





Sample pairwise interaction graphs produced by an intelligible deep learning system designed to predict the probability of death from pneumonia.

### Other Potential Problems

In addition to the problems inherent in the “black box” approach, Dr. Caruana points out a number of other potential problems that need to be accounted for before AI comes into widespread use in health care:

- **Testing accuracy on similar data sets hides potential problems.**

“Even though a machine learning system may be trained on one set of data and tested on another, both data sets usually look very similar,” notes Dr. Caruana. “That means that the same biases that appear in the training data—where, for example, it’s true that pneumonia patients with heart disease have half the probability of dying because they get care so quickly—are also true in the test data. As a result, the model is rewarded for predicting these things. It looks like the system has super-high accuracy, partly because the incorrect things it’s learned are true in both data sets. But if you were to deploy that model in the clinic to intervene in health care, it would actually hurt certain patients.

“The bottom line is: Accuracy in the real world is not the same as accuracy in the lab,” he says. “Unfortunately, the decision to release a model for use in the clinic is often based on its accuracy in the lab.”

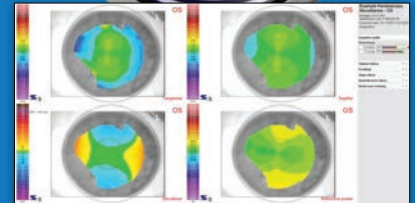
- **You can’t fix a problem you don’t know about.** “We’re all smart people,” notes Dr. Caruana. “Once we find a problem we can fix it. But if we don’t know about the problem, it won’t get fixed. In some situations, a few problems in a machine learning system

won’t hurt anyone; it might just be a little less efficient. But in health care, you’re talking about people’s lives. We have to put in a little more effort and be a little more cautious.

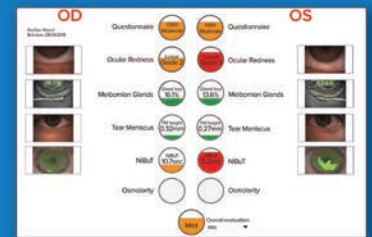“With ‘black box’ machine learning there’s an awful lot you don’t know,” he continues. “You don’t really know what was in the data, and you don’t know what the model learned. All you know is that the model seems to be accurate on test data—which looks a lot like the training data. That may be OK in some settings. However, in certain applications—like autonomous vehicle navigation or a nuclear power plant or health care for humans—you need to worry about these things. That’s why we’re trying to educate the community that there’s more going on here than people are normally aware of. We need to have some extra cautions and test procedures—and we need intelligibility.”

What about a system that’s just been trained to look for specific things? “Problems could occur there as well,” he says. “The data sets used to train the machines are always more complicated than we think. The system will learn from everything in the data that has a signal. Because of that, it’s probably learned some things that are not appropriate.”

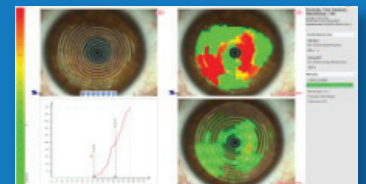
- **Data sets are imperfect.** Dr. Caruana points out a key problem with machine learning models: There are always imperfections in the data set the system learns from. “Data sets are always imperfect because of things they include or omit,” he says. “There are many ways for a machine learning



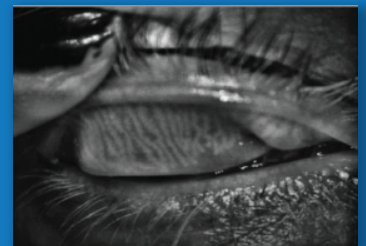
### Corneal Topography & More!



**NEW** Interactive OU Dry Eye Report



### Non-Invasive Tear Film Break-up Analysis



### Meibomian Gland Imaging & Analysis

More Information: [info@s4optik.com](mailto:info@s4optik.com)



I didn't realize  
**STARS**  
were little dots that twinkled

—Misty L, *RPE65* gene therapy recipient

WE'RE SEEING AMAZING RESULTS. **AND SO ARE THEY.**

Foundation Fighting Blindness is shining a light in the darkness of Inherited Retinal Degenerations. We are the world's leading organization searching for treatments and cures, and with many treatments already found, today's innovations are illuminating a future of possibilities.

**Patients with Inherited Retinal Degenerations are urged to partner with us to accelerate the discovery of treatment and cures.**

We have robust disease information, a national network of local chapters and support groups, local educational events, and our My Retina Tracker patient registry helps to keep your patients connected with clinical and research advancements.



Visit [ECPs4Cures.org](https://ECPs4Cures.org)  
to make a donation  
to help find more cures.

[FightBlindness.org](https://FightBlindness.org)

FOUNDATION **FIGHTING  
BLINDNESS**



## How Much of This is Hype?

Steve Charles, founder of the Charles Retina Institute in Memphis, Tennessee, and one of the world's leading vitreoretinal surgeons, points out that people sometimes get an overblown idea of what artificial intelligence is capable of. "We live in a country that thrives on hype," he notes. "Many things have been overhyped and are still not living up to expectations, including the usefulness of the human genome project for bringing us personalized medicine; nanotechnology; 3-D printing; and telemedicine. We have to be careful about making broad generalizations and succumbing to the hype. AI could never produce a major advance such as inventing the laser, phacoemulsification, a glaucoma filtering procedure, intraocular lenses or anti-VEGF therapy."

Dr. Charles is far from convinced that AI will be a boon in the area of image interpretation. "People assume it works well in tough cases, which it doesn't," he says. "If the conclusion is debatable, humans do better every time. I have an associate who reads 300 images a week or more. He'll tell you that AI works well if the image is straightforward. Otherwise, not so much."

"Another assumption seems to be that there's a shortage of people to look at fundus photographs, but that's also not the case," he says. "I have no argument against placing kiosks in malls and primary care offices to capture images; the automation involved is crucial, given the patient numbers. However, that's automation, not AI. In fact, there's no shortage of doctors to read the images. One doctor could read the images from every kiosk out there in one hour a day. If they proliferate, 20 people could do it. The reality is that qualified, experienced individuals do just as good a job as AI does, and do better when the image is borderline."

I think people will try AI for this purpose and find out it doesn't solve any real problems, and it will go away."

Despite his skepticism about some of the touted uses for AI in ophthalmology, Dr. Charles does believe it can really help in at least one area: refractive surgery and refractive cataract surgery. "Trying to improve refractive outcomes is an iterative, numerical process, not a first-principles process," he says. "Getting a good outcome requires accounting for a tremendous volume of data, coming from instruments like the Pentacam, corneal topography and anterior segment OCT. We need to consider interferometric axial length, manifest refraction, posterior corneal curvature, anterior chamber depth, the characteristics of various types of IOLs, and factors such as previous LASIK or PRK. All of these things have numbers associated with them. Warren Hill, MD, and his colleagues have shown that AI definitely helps to take those numbers and use them to get a better refractive outcome, so clearly, this type of use for AI makes sense. But I believe many of the other uses it's being touted for are mostly hype."

Dr. Charles points out that automated OCT scans will be significantly better for screening than fundus photographs. "But again, humans do a better job of interpreting OCT scans than AI," he says. "The AI autosegmentation algorithms for OCT are minimally effective. So I'm fine with the idea of nonmydriatic screening with OCT in kiosks or primary care offices, read by humans in an automated fashion. But the idea that AI is going to solve some problem beyond refining refractive surgery outcomes is not supported by the evidence."

—CK

model to learn things that are wrong and could be harmful for patients.

"For example, I heard about a radiology data set in which the system was trying to predict whether a breast cancer lump was a tumor," he continues. "In addition to learning what tumors look like, it also learned to recognize a tumor-size-measuring tool that surgeons would sometimes leave near the tumor while the image was taken. The tool would only have been used if the surgeon thought this really was a tumor, so the tool in the image was sure-fire evidence that this was cancer. The system learned that, and the accuracy of its predictions increased—but for a reason that was basically irrelevant."

Dr. Caruana adds that image analysis

can be confused by parts of an image that wouldn't faze a human. "There are systems that are really good at recognizing an object like a cow standing by a barn on grass in a natural image," he says. "However, it may not recognize the same cow standing by water, because the system is taking the background into account. Deep learning systems may end up drawing false conclusions based on information we wouldn't want them to include. In health care this could be lethal."

• **Intelligible machine learning technology doesn't help with image-based analysis.** Dr. Caruana notes that, unfortunately, an intelligible system that's able to tell you what it has learned isn't very helpful with

image analysis. "Ophthalmology is very heavy on imaging," he points out. "Unfortunately, the learning method I've been working on is not yet designed to work on images, because pointing out a correlation in an image isn't helpful the way pointing out a correlation to age or blood pressure or diabetes is. The system might say the patient's risk is higher if pixel 433 is a little red, and pixel 7,000 is black and white, and pixel 12 has a value greater than 7. Even if that was accurate, it wouldn't be useful. So the advantages we gain from intelligibility, such as catching bogus things the machine has learned, can't be used on systems that evaluate images—at least so far. When those systems make a mistake, the



reason won't be easy for us to uncover."

• ***A machine learning system will only be reliable on a population exactly like the one it learned from.*** Dr. Caruana notes that a system is sometimes unintentionally used on a different population from the one on which it was trained. "One model was trained to predict the likelihood of 30-day hospital readmission, using data from multiple hospitals," he says. "The data looked very good. It was then released to a much larger set of hospitals, including—by accident—a few children's hospitals. The system had not been trained on data from children, so its accuracy was suddenly not as good. Fortunately, this was not a critical prediction, so a mistake wasn't likely to injure patients. But it's inappropriate for a model to be used on a population that differs in key ways from the learning data set."

• ***When the input to the system evolves, the learning has to be redone.*** "One system was trained to read MRIs, and it did well," says Dr. Caruana. "Then it was used on a new MRI machine that had higher resolution and lower noise, which doctors were very happy about. However, the system was suddenly making less-accurate predictions, simply because the system wasn't trained on that level of data."

"These are the kinds of risks I'm worried about," he says. "Many people in the health-care community think these systems are really accurate—maybe more accurate than humans—so health care would be best served by getting them out there as fast as possible. I think they don't realize the risks, because they can't see the little land mines hidden inside their machine learning model."

## Nevertheless ...

Dr. Caruana admits that even an imperfect system could still be worth using. "A lot of what the models learn is wonderful," he notes. "Doctors are

sometimes intrigued by connections the systems uncover. They say, 'Oh, that's interesting. I'll bet that's true. Maybe we should change what we're doing because of that.' Or they say, 'We all believe this is true, but we've never seen it in data before.'

"Furthermore, if a system has been clinically tested, it might be as good, or better than, other methods for detecting disease," he continues. "That might be true even if it does make a few mistakes. If an AI tool on my smartphone lets me check skin lesions or moles every week to look for skin cancer, that could be an incredibly valuable addition to diagnosis, even if it's not as good as the best human doctors. If it causes people with a problem to get to a specialist sooner, that's great. But again—if it occasionally makes a mistake with certain skin types or some kinds of skin anomalies because of bogus 'rules' it learned, someone could end up paying a high price."

Dr. Caruana offers two pieces of advice to ensure the eventual success of AI in health care. "First, we need to proceed more cautiously," he says. "A bad outcome could set back the field. We want to make sure there's no 'AI winter' because a model gets deployed too quickly and recklessly and hurts patients. In addition to the injured patients, it might make people afraid of this type of technology."

"Second, when we deploy an AI learning system, we have to make sure that we have tracking and reporting, just like we have for drugs and procedures," he continues. "That way, if the model suddenly makes a big mistake, we'll recognize it as quickly as possible and pull the plug on it. Or, if the world changes over time and the model is no longer accurate, we'll recognize that it's not working as it was."

"No technology is perfect," agrees Dr. Prasad. "Even after AI is deployed on a larger scale, there's still going to be a period where we learn and refine. That's actually going to be the fun part."

We'll see how we can use it in ways that we can only imagine right now."

Dr. Caruana believes that an ideal AI system in the future will benefit from both machine and human input. "Doctors and AI systems will make different kinds of mistakes, so we'll probably have the highest accuracy if we get the best of both of them," he says. "The important thing is, there's no doubt that artificial intelligence and machine learning will be great additions to health care. Like anything else, it's a technology that can be tamed and improved and used safely. Ultimately, it will make health care better, producing more accurate and faster diagnoses and making care more cost-effective."

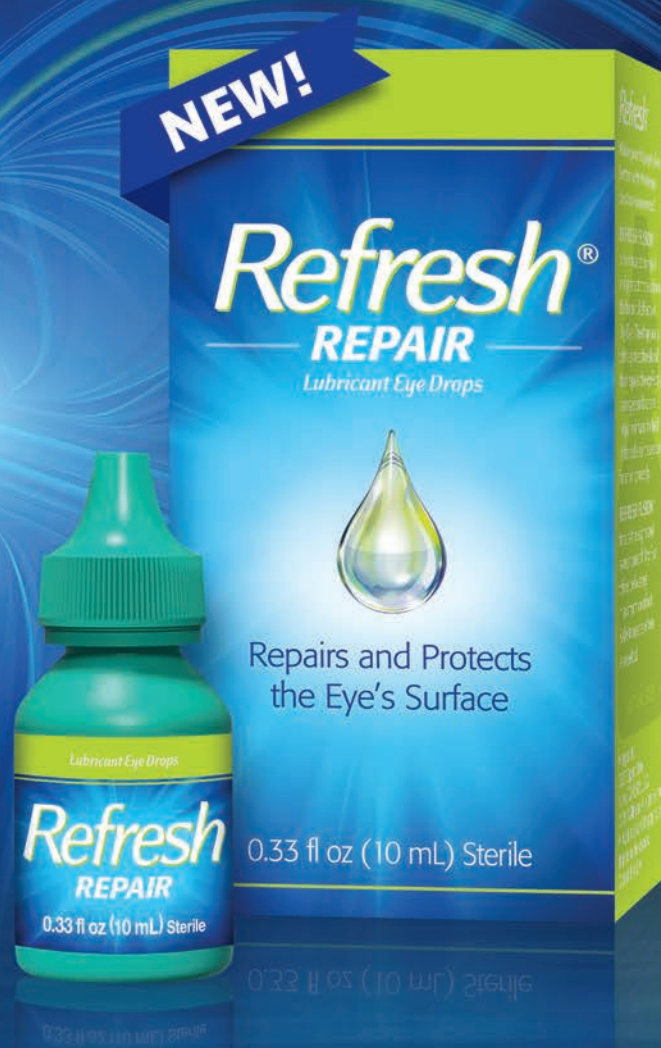"In my mind, the benefits outweigh the risks, by far," adds Dr. Azar. "I think AI will become a future foundation of medical care." **REVIEW**


*Dr. Azar is an employee of Alphabet Verily and is on the boards of Novartis and Verb Surgical, a robotics venture undertaken jointly by Johnson & Johnson and Google. Drs. Prasad, Caruana and Charles report no financial ties to any products discussed in the article.*

1. Abramoff MD, Lavin PT, et al. Pivotal Trial of an autonomous AI-based diagnostic system for detection of diabetic retinopathy in primary care offices. *NPJ Digital Medicine* 2018;1:39.
2. Burlina PM, Joshi N, Pekala M, Pacheco KD, Freund DE, Bressler NM. Automated grading of age-related macular degeneration from color fundus images using deep convolutional neural networks. *JAMA Ophthalmol*. 2017;135:1170-1176.
3. Ting DSW, Cheung CY, Lim G, et al. Development and validation of a deep learning system for diabetic retinopathy and related eye diseases using retinal images from multiethnic populations with diabetes. *JAMA*. 2017;318:2211-2223.
4. Ohsugi H, Tabuchi H, Enno H, Ishitobi N. Accuracy of deep learning, a machine-learning technology, using ultra-wide-field fundus ophthalmoscopy for detecting rhegmatogenous retinal detachment. *Sci Rep* 2017;7:9425.
5. Matsuba S, Tabuchi H, Ohsugi H, et al. Accuracy of ultra-widefield fundus ophthalmoscopy-assisted deep learning, a machine-learning technology, for detecting age-related macular degeneration. *Int Ophthalmol*. 2018 May 9. [epub ahead of print]
6. Prahns P, Radeck V, Mayer C, et al. OCT-based deep learning algorithm for the evaluation of treatment indication with anti-vascular endothelial growth factor medications. *Graefes Arch Clin Exp Ophthalmol*. 2018;256:91-98.
7. Schmidt-Erfurth U, Bogunovic H, Sadeghipour A, et al. Machine learning to analyze the prognostic value of current imaging biomarkers in neovascular age-related macular degeneration. *Ophthalmol Retina* 2018;2:1:24-30.
8. Bogunovic H, Waldstein SM, et al. Prediction of anti-VEGF treatment requirements in neovascular AMD using a machine learning approach. *Invest Ophthalmol Vis Sci* 2017;58:3240-3248.

INTRODUCING  
**REFRESH<sup>®</sup> REPAIR**

The first and only artificial tear in the U.S.  
formulated with CMC, HA,\* and Osmoprotectants.



REFRESH<sup>®</sup> REPAIR helps promote healing of the cornea and conjunctival epithelia and improves visual performance in Dry Eye patients. Safe to use with contacts. 

[refreshbrand.com/doc](http://refreshbrand.com/doc) | 

 **Allergan.**

\*HA is an inactive ingredient.

© 2018 Allergan. All rights reserved. All trademarks are the property of their respective owners. REF115212 05/18

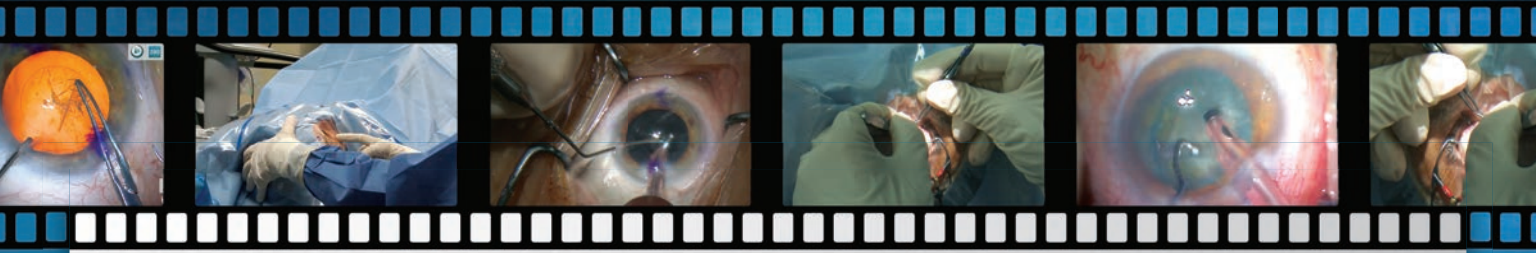



Monthly

# MACKOOL ONLINE CME

## CME SERIES | SURGICAL VIDEOS



To view CME video  
go to:

[www.MackoolOnlineCME.com](http://www.MackoolOnlineCME.com)

### Episode 35: "Resorbed Mature Cataract and Phacolytic Glaucoma"

Surgical Video by:  
Richard J. Mackool, MD

#### Video Overview:

Ocular trauma suffered 30 years ago has left this young man with a calcified and partially resorbed cataract, advanced phacolytic glaucoma and complete absence of zonular support. Completing our 3-part series of complicated cases, this video begins with a discussion of the preoperative OCT image. During the procedure I discuss its formidable challenges and explain the methods necessary to remove the extremely rigid lens.

## MackoolOnlineCME.com MONTHLY Video Series



Richard J. Mackool, MD

Welcome to the third year of Mackool Online CME! With the generous support of several ophthalmic companies, I am honored to have our viewers join me in the operating room as I demonstrate the technology and techniques that I have found to be most valuable, and that I hope are helpful to many of my colleagues. We continue to edit the videos only to either change camera perspective or to reduce down time - allowing you to observe every step of the procedure.

As before, one new surgical video will be released monthly, and physicians may earn CME credits or just observe the case. New viewers are able to obtain additional CME credit by reviewing previous videos that are located in our archives.

I thank the many surgeons who have told us that they have found our CME program to be interesting and instructive; I appreciate your comments, suggestions and questions. Thanks again for joining us on Mackool Online CME.



**CME Accredited Surgical Training Videos Now Available Online: [www.MackoolOnlineCME.com](http://www.MackoolOnlineCME.com)**

Richard Mackool, MD, a world renowned anterior segment ophthalmic microsurgeon, has assembled a web-based video collection of surgical cases that encompass both routine and challenging cases, demonstrating both familiar and potentially unfamiliar surgical techniques using a variety of instrumentation and settings.

This educational activity aims to present a series of Dr. Mackool's surgical videos, carefully selected to address the specific learning objectives of this activity, with the goal of making surgical training available as needed online for surgeons motivated to improve or expand their surgical repertoire.

#### Learning Objective:

*After completion of this educational activity, participants should be able to:*

- Demonstrate removal of a calcified cataract in an eye with no zonular support

**Satisfactory Completion** - Learners must pass a post-test and complete an evaluation form to receive a certificate of completion. Your chosen sessions must be attended in their entirety. Partial credit of individual sessions is not available. If you are seeking continuing education credit for a specialty not listed below, it is your responsibility to contact your licensing/certification board to determine course eligibility for your licensing/certification requirement.



JOINTLY ACCREDITED PROVIDER™  
INTERPROFESSIONAL CONTINUING EDUCATION

**Physicians** - In support of improving patient care, this activity has been planned and implemented by Amedco LLC and Postgraduate Healthcare Education. Amedco LLC is jointly accredited by the Accreditation Council for Continuing Medical Education (ACCME), the Accreditation Council for Pharmacy Education (ACPE), and the American Nurses Credentialing Center (ANCC), to provide continuing education for the healthcare team

**Credit Designation Statement** - Amedco designates this live activity for a maximum of .25 AMA PRA Category 1 Credits™. Physicians should claim only the credit commensurate with the extent of their participation in the activity.

Endorsed by:  
**Review of Ophthalmology®**  
Video and Web Production by:  
**JR Snowdon, Inc**

Jointly provided by:

**AMEDCO & PHE**

Supported by an unrestricted independent  
medical educational grant from:

**Alcon**

Additionally Supported by:

**Glaukos  
MST  
Crestpoint Management  
Carl Zeiss Meditec**

In Kind Support:

**Sony Healthcare  
Solutions**



# Upping the Patient-Happiness Quotient

*Kristine Brennan, Senior Associate Editor*

Experts share an assortment of “whys” and “hows” for you and your staff.

“I always tell students, techs and practices that products are consumed; services are experienced,” says Palm Coast, Florida’s Sharon Alamalhodaie, COMT, OSC. “We’re providing an experience to our patients. If they don’t have a phenomenal experience with you, they’re not going to be your patients for very long.” Thoughts on the elements of a great patient experience follow, along with measures you might consider to show your patients how much you value them.

## Superstar Staffing

In the age of online reviews, a rude or dismissive front-desk or clinical staff will eventually garner unwanted attention. There’s evidence that the elements of the Press Ganey patient-satisfaction survey most associated with high scores from ophthalmology patients are the amount of time the provider spends with the patient and the ease of scheduling appointments.<sup>1</sup> Another study compared mean Press Ganey survey scores of physicians with and without negative online reviews, and found no difference between the two groups’ mean satisfaction scores on physician-specific questions. The physicians with lower online reviews did, however, have lower mean satis-

faction scores on questions about non-physician-specific parameters.<sup>2</sup>

While your staff doesn’t control how much time you spend with each patient, they can increase satisfaction with many other aspects of the patient/physician encounter. A few key ways your staff can make patients want to return to your office include: managing the patient flow; helping patients manage wait times; and making a powerful first impression.

• **Direct the traffic.** Connecting patients with needed services quickly sets the tone, says Scott Neilson, COE, CPA, CGMA, executive director of Pacific Eye Associates in San Francisco. His high-volume office created a greeter position shortly before he joined the practice several years ago. “Since we have about 13 doctors at our practice, we can easily see between 200 and 250 patients per day,” he explains. “We noticed that especially at the beginning of our clinic shifts, we had many doctors all getting started at the same time, bringing in roughly 10 to 15 patients within about five minutes for the first of the morning or afternoon appointments. Additionally, people would often come into our optical shop around lunchtime or first thing in the morning to pick up glasses or contacts. Sometimes, patients just needed to be routed to the correct

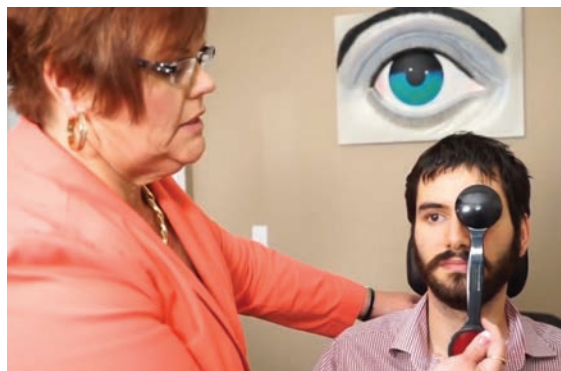person or department instead of standing in a line five or eight deep just waiting to check in or to have a basic question answered.”

They tried a stationary greeter standing at a kiosk, but eventually decided to give the greeter a mobile device and allow him or her to meet people as they came through the door. “We found that the line to check in or check out dramatically dropped as new arrivals could access different parts of the health-care transaction without having to wait in line to do it,” says Mr. Neilson. “It’s

definitely an expense to the practice, but the payoff comes in the form of higher patient-satisfaction scores. We frequently get good comments about the helpfulness of our greeter.”

He says the practice schedules one greeter per shift, but the director of communications has cross-trained front-office staff as greeters, check-in or telephone receptionist. “We have to be nimble,” Mr. Neilson says. The greeter isn’t a strictly dedicated position; by being flexible we have an extra person in the organization that can go where we need them to help keep our lines as short as possible.”

• **Manage the wait.** Ms. Alamalhodaie, who founded Eye Tech Training ([EyeTechTraining.com](http://EyeTechTraining.com)), a company specializing in ophthalmic technician training and education as well as onsite assessment and training, says a customer-focused staff helps your patients take waiting in stride. “You have to manage their perception of the passage of time,” she explains. “By way of example, I ask my students to imagine the Cheesecake Factory at 6 p.m. on a Friday night. When you’re seated, the server may come by your table and say, ‘I’ll be with you in just a moment.’ That action resets the clock we have in our heads. We all have an amount of time that we’re willing to wait happily and comfortably. For me, it’s about 15 minutes in a doctor’s office. Between



Sharon Alamalhodaie, COMT, OSC

Sharon Alamalhodaie, COMT, OSC (using occluder), emphasizes that members of the eye-care team must focus on serving patients whenever they are visible or within earshot.

15 and 30 minutes, I’m still fine, but I’m noticing the wait. But at 45 minutes, I’m thinking about going up to the front desk. I tell my students that by the time a patient approaches you and asks how much longer the wait is going to be, they’ve been stewing about it for a while. Most people don’t just stand up and ask that question spontaneously.

“When someone comes and tells me that it will only be a moment, it resets that clock in my head to zero,” she continues. “I’ve had a contact; they’ve acknowledged my presence, so I know that I’m not going to be forgotten. My timer’s back at zero. Suppose a doctor is running behind with one patient, and there’s another patient waiting in the room next door. Just sticking your head in and saying, ‘Mrs. Smith, I want to let you know that you’re next to see the doctor. He or she’s been with this other patient for a little while, but you’re the very next patient.’ That resets the clock.”

Ms. Alamalhodaie adds that it’s better to give patients a finite wait time rather than an unknown, “infinite” wait. “To apply this principle in the clinic, if the doctor is running behind, you should tell your patient, ‘Mrs. Smith, I want to let you know that the doctor’s running about a half-hour behind schedule.’ The patient will tolerate the wait better.” Ms. Alamalhodaie em-

phasizes that this also empowers patients to manage their time: If they know they’re facing a 45-minute wait, a heads-up gives them the option to quickly run a nearby errand instead of sitting idle.

“It just shows respect for the patient to let them know that,” she stresses.

• **Make an impression.** “Our opportunities to make a lasting impression are when patients first call on the phone and when they come into our office,” says Ms. Alamalhodaie.

Whether your staff is answering the first or the hundredth call of the day, callers should always sense engagement and a willingness to help. “They should never perceive that it’s the hundredth call, even if it is,” she says.

As a practice administrator, Ms. Alamalhodaie would employ a powerful, no-cost strategy to make new patients feel cared for. “I instructed my front desk staff to let me know when new patients came in,” she explains. “I would seek out that new patient and shake their hand, make eye contact, smile, welcome them, introduce myself and give them my card. I would say, ‘I’m Sharon, and I’m the practice administrator here. I want to welcome you to our practice. Here’s my card: If you ever have any questions or problems, I want you to feel free to contact me.’”

“I sure wouldn’t give my card to a patient if we had crappy service, poor billing procedures or nasty staff,” Ms. Alamalhodaie continues. “It was a way of holding myself accountable for providing a wonderful experience. It didn’t cost a penny, but it made a lasting impression.”

When Mr. Neilson noted negative online reviews regarding Pacific Eye’s front desk and check-in process, he implemented three mandatory aspects of customer service: smile, greet, and use the patient’s name.

“Before you say one word to a pa-

tient, you need to be smiling at them,” he says. “Before you get down to business, greet them. You have to say, ‘Hello.’ ‘Good morning.’ ‘Good afternoon.’ Our staff speaks a lot of different languages: At our front desk alone, we have five languages represented. We encourage our staff to learn greetings in languages other than their own. Even if a patient needs language-support services from one of our interpreters, at least they’ve heard a greeting in their native language,” he says.

“And sometime during that exchange with the patient, you have to use their name at least once,” Mr. Neilson continues. “Our name is so important to us that when we hear it, it activates certain pleasure centers in the brain. And using a patient’s name makes them an individual—not an account number, not ‘next in line.’ Forming that connection through the use of a name is very important. So every new hire, and anyone who’s been here for 20 years, needs to smile, needs to greet and needs to use the patient’s name at least one time during the initial interaction. Although [patient] volume is still important, so is being more focused on making sure we connect with our patients through basic customer-service skills.”

Ms. Alamalhodaie likens being wherever patients can see you or hear you to being onstage. “Being onstage is not being phony,” she says. “It means that you have your professional demeanor on, and that your talk and actions are all patient-centered. You’re not talking about the shoe sale at the mall, for example. Your focus is on your patient and on serving them.”

She adds that it’s also important that your talk be positive. “Instead of ‘Oh, our office doesn’t do that,’ you can say, ‘This is how our office handles that situation,’” she explains. “You’re saying the same thing, but you’re sending the message in a completely different way that will most likely be received in a very different way.”

### Consider a Physician Extender

Lee Schelonka, MD, a retina specialist in practice at the Department of Ophthalmology, Kaiser Permanente Lone Tree Medical Offices in Lone Tree, Colorado, says via email that the addition of physician assistant Chad LaRoche, PA-C, to his office has increased the efficiency of intravitreal injections and won rave reviews from patients, without compromising safety. “By performing the majority of the injection procedures, he’s improved access for evaluation appointments with our ophthalmologists,” he says. “Chad has great communication skills for patient education, and makes personal connections with them. He also helps our patients navigate the patient-assistance programs that help with their copays. Our surveys show that he has even better patient-satisfaction scores than our MD’s.”



# NuLids™ transformational dry eye therapy

Transforms your patients’ lives



Finally... A doctor-directed at-home treatment for dry eye disease that is safe, effective and easy to use.

A multi-center study<sup>1</sup> showed:

- 50% decrease in dry eye symptoms
- 65% improvement in TBUT
- 80% increase in meibomian glands yielding liquid secretions.

For more information visit  
[www.NuSightMedical.com/rophi12](http://www.NuSightMedical.com/rophi12)  
or call us at 833-368-5437



<sup>1</sup> Schanzlin, Olkowski, Coble, Gross. NuLids II Study, April 2018



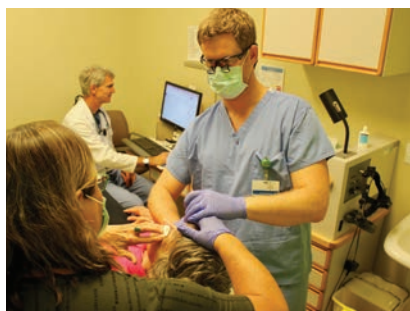
**NuLids™**

Doctor prescribed, at-home dry eye relief



Dr. Schelonka says that Kaiser Permanente explored the idea of adding a physician extender several years ago, after another retina surgeon wondered if his nurse could do injections. “In Great Britain and Denmark, most intravitreal injections are done by nurses,” he explains. “But in the United States, nurses have certain regulatory restrictions on their practices that could potentially limit a role in doing injections. On the other hand, in Colorado, the scope of practice of physician assistants is limited only by the supervising physician’s scope of practice, and the physician’s decision that it would be prudent and safe to delegate procedures to the PA. One other Kaiser Permanente retina specialist in Hayward, California, had a PA doing intravitreal injections under his supervision; he and his PA were very positive about the quality and patient satisfaction. As we researched further, we found a few other practices also using PAs for eye injections. We reviewed our plans with our quality and legal teams and hired Chad, our first physician assistant. Since April 2017, he has done more than 4,000 injections. Our patients love the care he gives, and his quality is great, as we reported at AAO 2018.” Dr. Schelonka presented a poster at the meeting assessing safety and patient satisfaction of the practice’s first 2,000 PA-administered injections.

One specific boon to patient happiness that Dr. Schelonka notes is decreased patient wait times. He cautions, however, that the laws governing the scope of practice and supervision of PAs vary by state, so adding a physician assistant may not be uniformly feasible. “Our PA was a great fit into our intravitreal-injection and oculoplastic practice,” he reports. “He does procedures which are beyond the scope of practice of optometrists, without encroaching on our optometrists’ refractive and primary eye-care practices.”



Lee P. Schelonka, MD

Lee Schelonka, MD, (background) says adding physician assistant Chad LaRoche, PA-C, to his retina practice has increased efficiency and patient satisfaction.

### Tech and Surveys

Mr. Neilson says that surveys like those conducted in Dr. Schelonka’s practice are important. He tries to keep his office’s surveys to a maximum of four or five questions, each carefully phrased to preserve statistical integrity by avoiding overlap. Some practices have long touted the convenience of online check-in and the ability to access personal medical records through a web portal. Mr. Neilson says, however, that Pacific Eye’s satisfaction surveys haven’t indicated that these are high priorities for their patients. “We have those features,” he says. “But we have separate EHR and practice-management systems, so giving someone the ability to access an appointment goes through one program; giving them the ability to look at their records goes through a different program. We’re currently exploring some options to possibly tie them together, instead of having the patient register for two different portals with two different logins and passwords. We’ve also found a number of our patients tend to be borderline-technophobic in some respects. Many of our patients are either non-English speakers or second-language English speakers, so that has created an additional hurdle to encouraging everybody to go online to access their medical records. Many patients have either indicated that they

don’t want or don’t find a lot of value in that service. So far, at least statistically, we haven’t seen a huge indication that our patients strongly desire electronic access. Some do, but not very many.

“One of the things we’ve wanted to be careful about was going more tech-centric within the practice at the expense of the human side of the equation,” Mr. Neilson continues. “We’d like to wait until we have a little more clarity on it. I think better electronic access might be somewhat important, but we currently get very few responses indicating that that’s a mission-critical aspect of our patients’ health care.”

### For Surgeons

Patient satisfaction is the surgeon’s job too, regardless of how good your front office and technicians are at providing it, according to Ms. Alamalhodaei. “The tail doesn’t wag the dog,” she notes.

Mr. Neilson adds, “Being competent in your profession is no longer sufficient. Twenty or 30 years ago, you could get by with that. In the current consumer-driven world of health care, just being a good clinician, physician or surgeon isn’t enough. You really have to convey the warmth of why you’re in this profession as well as your competency.”

He says that smiling is an important part of the physician’s therapeutic armamentarium. “We always encourage our physicians to smile,” he says. “We encourage them to greet patients when they walk into the room, whether it’s, ‘Welcome to the practice!’ or, ‘Glad to see you back again!’ It has to be somewhat enthusiastic, but not over the top. The other skill we try to teach them is a dual one: to listen and sympathize. Patients come to our practice because something’s wrong and it’s affecting their vision—and that’s really scary for a lot of people. We encourage doctors to listen to what the patient has to say. It’s important to listen and repeat back

what you just heard in order to show sympathy. For example, you could say, 'I'm so sorry that you're going through that. I know that must be scary.' It really does have an impact when patients know that you're not just a good doctor, but that you also care about them."

When you and your staff share the pursuit of patient satisfaction, they can alert you to potential challenges. "Empower and listen to your staff," said Vance M. Thompson, MD, of Thompson Vision in Sioux Falls, South Dakota, during a presentation on managing unhappy refractive patients at October's 2018 American Academy of Ophthalmology meeting in Chicago. "They spend the most time with the patient." He said that alert and empowered staff could tip surgeons off to cues in a patient's attitude or demeanor that would suggest a satisfactory outcome is improbable. "I won't operate on a patient that I don't feel a bond with," said Dr. Thompson. "Whatever else is going on, we need to connect."

Although his talk at the AAO meeting was specifically geared toward addressing unhappy refractive patients, much of Dr. Thompson's advice was applicable to surgeons from other subspecialties seeking to increase patient satisfaction. "Perception is reality," he said of the patient's experience of health care. "Think every step of the way how you'd feel," he urged. Dr. Thompson also advised his audience not to skimp on patient education. "Fifty to eighty percent of information is forgotten; of the information that is remembered, 50 percent is remembered correctly." He suggested writing your personal contact information onto a business card as a way of communicating personal care to patients.

Whether the encounter is a routine screening or a consultation for a sight-threatening condition, your patient wants to know that you and your staff are caring as well as skillful. "You should cultivate a culture in your practice where there's an unspoken and subtle peer pressure, so that everyone knows that providing high-quality service is what's expected," says Ms. Alamalhodaie. "It's about reaching a sort of critical mass, so that both newcomers to your practice and established employees who don't toe the line and embrace the culture will clearly stand out to everyone as falling outside of the standard." **REVIEW**

*Ms. Alamalhodaie is the author of two books: "How to Be the Tech Your Doctor Can't Live Without," and "10 Steps to a Phenomenal Patient Experience: Customer Service Secrets for the Eye Care Team." Mr. Neilson reports no relevant disclosures. Dr. Schelonka reports no relevant disclosures. Dr. Thompson reports no relevant disclosures.*

1. Long C, Tsay EL, Jacob SA. Factors associated with patient Press Ganey satisfaction scores for ophthalmology patients. *Ophthalmol* 2016;123:2:242-7.

2. Widmer RJ, Maurer MJ, Nayar VR, et al. Online physician reviews do not reflect patient satisfaction survey responses. *Mayo Clin Proc* 2018; 93:4:453-7.

# NuLids™ transformational dry eye therapy

## Transforms your practice

The NuLids System helps reduce patient out-of-pocket expenses while creating an additional revenue stream for the practice – all without impacting overhead costs or disrupting other in-office treatments.

A multi-center study<sup>1</sup> showed 95% were satisfied or very satisfied with the treatment.

For more information visit  
[www.NuSightMedical.com/rophi12](http://www.NuSightMedical.com/rophi12)  
or call us at 833-368-5437

<sup>1</sup> Schanzlin, Olkowski, Coble, Gross. NuLids II Study, April 2018



**NuLids™**

*Doctor prescribed, at-home dry eye relief*



# The Latest Innovations In Phaco Technology

Michelle Stephenson, Contributing Editor

Advances in design and fluidics are providing better control for surgeons.

Phaco recently turned 50. During these 50 years, phaco machines have undergone hundreds of incremental upgrades that have improved the safety and efficacy of cataract surgery. Today's phaco machines offer advanced fluidics, IOP control, and anterior chamber stability. Here's a review of the technology.

## Centurion

The Alcon Centurion was introduced in 2013; the company says that it automatically and continuously adapts to changing conditions within the eye, provides anterior chamber stability during each step of the surgery, and offers optimized energy technology through enhanced fluidic management and surgical precision.

Centurion combines multiple intelligent phaco technologies and other key features, including Active Fluidics Technology, Balanced Energy Technology and Applied Integration. Active Fluidics is an automated system that optimizes anterior chamber stability by allowing surgeons to proactively set and maintain a target IOP during cataract removal. Balanced Energy enhances phaco efficiency through OZil Intelligent Phaco (IP) and the Intrepid Balanced Tip probe. Applied Integration allows the new system to

be seamlessly integrated with multiple cataract surgical technologies, such as Alcon's LuxOR surgical microscopes with Q-VUE 3-D assistant and the LenSx Laser.



Centurion peristaltic pump, with seven spring-loaded rollers and torsional rotary vent valves.

James A. Davison, MD, who is in practice in Des Moines, Iowa, comments on moving from an earlier-generation machine to the Centurion. "When you first start using the Centu-



rior, you discover two huge improvements that you've never experienced before: tremendous emulsification efficiency and totally stable fluidics," he says. "The 30- and 45-degree balanced phaco tips have a slight bend in them before they merge into the sharp cutting edge, which generates a unique cutting-emulsification motion that makes them glide through firm cataracts easily. Torsional tip movement with IP then enhances nuclear followability for quadrant removal. Secondly, the fluidics controls are so exact and integrated that absolute iris and chamber stability is achieved throughout all cases."

He adds that the fluidics are much better on the Centurion than they were on the Infinity. "Because of IOP control, there are no variations in pressure and flow, and there are no iris motions as surgery proceeds," Dr. Davison says. "Patients stay well-dilated throughout the case."

The Centurion also allows the surgeon to use different modes during different phases of the surgery. "With hard lenses, you want to shave material away and you want to either chop or divide-and-conquer by aspirating emulsified quadrants using foot pedal surgeon control of torsional tip oscillation and preset maximum vacuum rise times," Dr. Davison says. "Interjected segments of longitudinal tip motion can be added at programmed vacuum levels to expedite material removal. Occlusion surge is never an issue because of programming and the 150- $\mu$ m ABS opening drilled into the phaco tip; because of that, total occlusion never occurs. However, with softer lenses, you can program a mode in which your foot pedal controls vacuum and flow just like it does during I/A, with a specified amount of torsional tip movement added once a preset amount of maximum vacuum has been achieved. I call this ability 'two-speed phacoemulsification' because it's like having two gears in a car. I might change speeds

four or five times in one softer case, while I might not change them at all in a harder one," he adds.

Newer phaco technology also may be a career extender. "I'm 68 now, and the microscopes and the phaco machines have gotten so much better that they allow older surgeons to work longer," Dr. Davison says.

## Stellaris Elite

The Bausch + Lomb Stellaris has been available for many years, and the Stellaris Elite became available in 2017. The Elite offers multiple innovations over past iterations, including Adaptive Fluidics, Attune energy management, and eyeTELLIGENCE. The company says that these improvements are designed to work synergistically to deliver responsiveness and optimize control.

"I've used the Stellaris for many years, and now, with Elite, I've seen both efficiency and safety improvements in my hands," says I. Paul Singh, MD, who is in practice in Kenosha, Wisconsin. "As surgeons, we want a controlled environment in the eye. We want chamber stability, followability and cutting efficiency. The Stellaris offers all of these. The Elite's vacuum-based system allows for linear control of flow and vacuum, as well as Dual-Linear control, providing simultaneous control of irrigation, ultrasound and aspiration. As you press down on your foot pedal, you are linearly increasing the amount of followability, giving you control of the lens pieces that are coming to the tip and engaging ultrasound at any vacuum level."

Stellaris Elite incorporates Adaptive Fluidics, which allows surgeons to maintain chamber stability at a high level of vacuum. This feature combines precise aspiration control with predictive infusion management. It's a

pressurized fluid delivery system that modulates fluid pressure in response to the aspiration vacuum the surgeon commands. "It can, in real time, measure the vacuum and can increase flow rate as needed. It keeps the flow rate above a certain threshold, so we can decrease the chances of post-occlusion surge. When a surgeon gets a piece of nucleus in the phaco tip and lets go, the chamber doesn't flatten or shallow. Adaptive Fluidics also gives the surgeon the ability to raise the IOP as high as 150 mmHg during surgery. This can help expand eyes with shallow anterior chambers or chambers subject to high posterior pressure. This vacuum control also allows for efficient removal of post-femtosecond-laser-treated lenses. As a glaucoma specialist, I see a lot of hyperopic, shallow eyes, and those with pseudoexfoliation and weak zonules. With Adaptive Fluidics and Dual-Linear control, adjusting fluidics based on vacuum in real time provides rock-solid chambers during surgery," Dr. Singh adds.

Additionally, the Stellaris Elite provides a six-crystal, 28.5-kHz handpiece frequency that its maker says balances mechanical cutting with acoustic cavitation. "The most efficient way of creating cavitation is dependent on the length of each stroke and how fast the needle goes back and forth. Cavitation allows for the mechanical disruption of the nuclear fragments," Dr. Singh explains. The speed of 28.5 kHz provides the most efficient cavitation profile for efficient lens removal, users say.

"It has an incredibly efficient cutting speed; the cutting is fantastic," Dr. Singh says. "It also has a MICS microincision phaco tip, which fits through a sub-2-mm incision," he says.

The Stellaris Elite continues to provide excellent followability, Dr. Singh avers. "The Attune energy management system truncates the front and



back part of the sound wave, allowing for high efficiency and less wasted energy,” he explains. “In multiburst mode, when you push down on the foot pedal, you keep the phaco power the same but change the amount of time it stays on. This allows the pieces to come to the tip and stay there. The environment is very stable and controlled,” he adds.

Stellaris Elite has also recently teamed up with IBM to offer eyeTELLIGENCE, which is a first-in-class set of applications leveraging the IBM cloud on Stellaris Elite, designed to provide expedited technical support and improved workflow for eye surgeons. “From a surgeon’s perspective, it saves his or her settings,” Dr. Singh says. “If you go to a different hospital that has Stellaris Elite, you can log in with your app, and it will bring in your settings that you’ve saved to the cloud. So, you can go from place to place and it will remember you and your settings.”

EyeTELLIGENCE can also be helpful from a servicing perspective, B+L says. It can save all of the information from your cases, so that, if you feel something isn’t working right, a tech specialist can view the system remotely and implement any corrective actions with the system or settings. This may save a service call to the hospital or ambulatory surgery center to see if there’s a problem, which can save time and money.

Additionally, researchers are currently working on a smartphone app to track surgeon outcomes. “I would be able to look at my last 500 cases and see my fluid usage,” Dr. Singh says.

### Whitestar Signature Pro

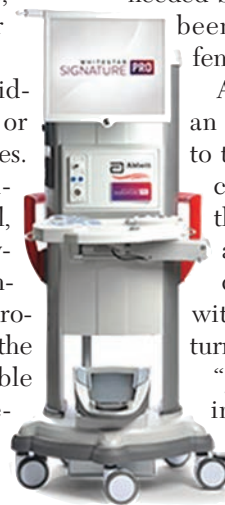The Johnson and Johnson Vision Whitestar Signature Pro system offers proactive IOP management with automatic occlusion sensing. It continuously monitors IOP and proac-

tively adjusts to maintain pressures. Additionally, it monitors vacuum levels throughout the case; optimizes power settings for enhanced control and improved efficiency; anticipates pressure changes and proactively responds to occlusion breaks; and protects the chamber during post-occlusion surge.

It offers on-demand fluidics with peristaltic, venturi or combination pump capabilities. Peristaltic offers holdability and intraoperative control, while venturi offers followability and improved efficiency; on-demand transition provides efficiency throughout the procedure. “It’s customizable to you, rather than you being customizable to it,” says Sumit (Sam) Garg, MD, who is in practice in Irvine, California. “If you’re a peristaltic surgeon, you can use peristaltic. If you’re a venturi surgeon, you can do venturi. If you want to use both on the same case, you can do that.”

Ultrasound with the Ellips FX handpiece balances power and control, the company says. “With the handpiece, we’re not restricted to a certain type of phaco needle or sleeve size,” explains Dr. Garg. “We can use smaller incisions or larger incisions. We can use a curved tip or a straight tip. We can customize these aspects to whatever we are most comfortable with.”

He adds that the Signature Pro provides a very stable chamber and a really quick response when it comes to surge. “It senses at a rate designed to provide the fastest compensation for any surge that may occur,” Dr. Garg says. “It also has a setting that can check for occlusion. When it feels like [the occlusion is] going to break, it automatically ramps down the vacuum so that you avoid surge. Additionally, it works well across a spectrum of cataract grades.”



Dr. Garg uses a femtosecond laser in 20 to 30 percent of his cases, and he says the venturi pump works well with femto. “You’re basically doing vacuum-assisted removal of the lens at that point, with bursts of phaco as needed because the lens has already

been pre-fractionated by the femtosecond laser,” he explains. Additionally, the system has an app that syncs wirelessly to the phaco unit, so surgeons can download the metrics of their case, such as energy usage and operation time. “You can even use it to track flow within the OR and measure turnover time,” Dr. Garg says.

“Johnson and Johnson has improved chamber stability by adapting a lower-bore, less-compliant tubing, which is important with regard to safety,” Dr. Garg adds. You can operate in the bag or at the iris plane and be assured that the chamber is going to stay quite stable.”

### The Future

Carl Zeiss Meditec recently purchased IanTECH, which is currently developing a new phaco machine. “It will probably be introduced next year, and it’s pretty wild,” Dr. Singh says. “It basically takes all the brains we have in the big console and puts them all in the handpiece. There’s no longer going to be a big console or foot pedal. All controls are in the handpiece. It’s a whole different way of approaching phaco. It has no cavitation creation, so no heat is generated, and it has a different way of breaking up the nucleus. It’s going to be interesting to see how that changes what we’re doing.” **REVIEW**

*Dr. Davison is a consultant to Alcon, Dr. Singh is a consultant to Bausch + Lomb and Dr. Garg is a consultant to Johnson & Johnson Vision.*

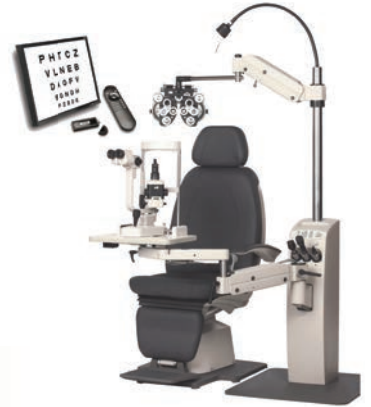## VALUE LANE PACKAGE

- ✓ LOMBART CS-5 Stand & Exam Chair
- ✓ Topcon SL-2G Slit Lamp
- ✓ Topcon VT-10 Refractor
- ✓ LOMBART CVSe Acuity System

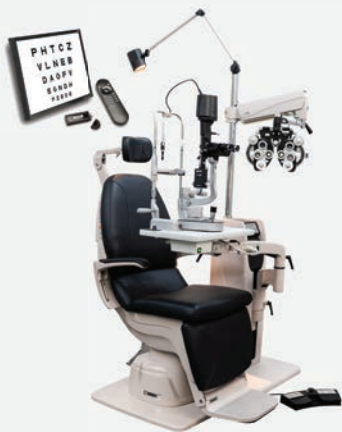~~\$23,794~~

**\$13,995**

Savings of up to \$9,799



Upgrade to a Digital Refraction Package! Starting at \$23,995



## MARCO MYLANE PACKAGE

- ✓ Marco Deluxe Stand
- ✓ Marco Encore Automatic Chair
- ✓ Marco M2 Ultra Slit Lamp
- ✓ Marco RT-700 Illuminated Refractor
- ✓ LOMBART CVSe Acuity System

~~\$26,957~~

**\$19,995**

Savings of up to \$6,962

## PREMIUM LANE PACKAGE

- ✓ Reliance 7900 Stand with Console
- ✓ Reliance FX 920 Examination Chair
- ✓ Haag-Streit BI900 LED Slit Lamp
- ✓ Reichert Ultramatic RX Master Phoropter®
- ✓ Haag-Streit Tonometer
- ✓ Reliance Stool
- ✓ LOMBART CVSe Acuity System

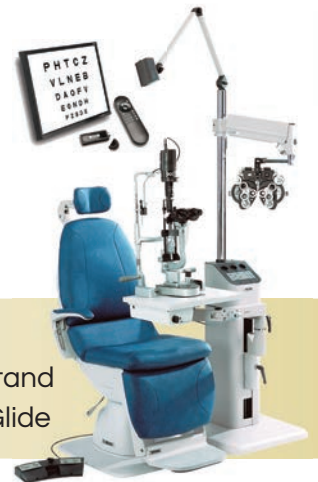~~\$40,460~~

**\$28,995**

Savings of up to \$11,465



ADA Compliant  
Wheelchair Accessible Stand  
Pre-Owned Wheelchair Glide



Imaging Upgrade Available for Only \$4,400!

**ASK US ABOUT QUICK DELIVERY!**

(1) FREE Preventative Maintenance in First Two Years

**CALL US TODAY AT 1-800-LOMBART**





# Helping Your Patients Adhere to Treatment

Effective communication is crucial, including asking key questions, providing clear educational materials and offering assistance.

*Kelly W. Muir, MD, Durham, N.C.*

**A**dherence to any treatment protocol can be challenging for a patient, but managing glaucoma can be especially daunting. Despite the proliferation of surgical options and the exciting possibility of sustained-release drug delivery, many of our glaucoma patients still have to take eye drops. So, even when we do everything right in the clinic, our patients' visual outcomes are largely dependent on how well the disease is managed after the patient leaves the clinic. Furthermore, it's one thing to come up with a plan for a medication you have to take for a week; with glaucoma, we're generally talking about patients taking medications for the rest of their lives. When you have to integrate something into your daily routine (and your budget) over the long term, it changes the nature of the challenge a bit.

The medications we have today are excellent, but there are still many ways that a prescription for glaucoma drops can go wrong, leading to short- or long-term intraocular pressure fluctuation:

- Even if your patients take their drops on time, they may use multiple

drops trying to get them onto the eye and as a result, run out of their drops before the end of the month. If they're not able to get a refill until the end of the month, they may go untreated for days. The American Glaucoma Society has successfully argued for legislation to make it possible for patients to refill a prescription before the end of the month when necessary, but needing frequent refills is disruptive, even if the financial burden is ameliorated.

- Patients may dose their medications late or forget to take them, resulting in gaps in therapeutic coverage. Yes, it helps if the medication (such as a prostaglandin) only needs to be taken once a day. However, prostaglandins are often prescribed to be taken at bedtime, and I frequently have patients tell me that they fall asleep without remembering to take the drops. So even a once-daily drop may be problematic.

- Patients can miss the eye altogether when instilling the drops, and not realize it.

- The cost of the drops can lead individuals to not use them as often as prescribed.

- The patient might be managing multiple treatments for multiple medical conditions, leading to confusion and missed doses.

- A given patient might have difficulty understanding your written instructions or the information on the eye-drop bottle.

- Your patient may not grasp the reasons that treatment is necessary, leading to inconsistent (or nonexistent) use of the drops.

- Changing personal situations (a family crisis, for example) may push timely use of the medication to the bottom of the patient's priority list—especially when the medication is addressing a potential future concern rather than a pressing current problem.

So: What can we do to help ensure that these obstacles don't keep our patients from receiving effective treatment?

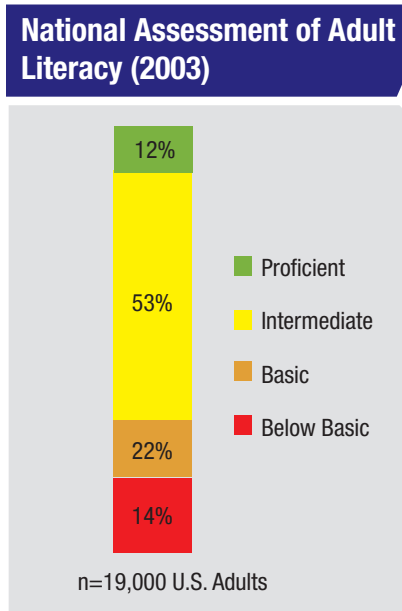
## Effective Written Materials

A significant part of getting patients to follow your instructions is clearly communicating the nature of the disease and what the patient needs

to do. As already noted, patients can have trouble understanding written information and instructions. Back in 2003, the National Center for Education Statistics conducted an assessment of the literacy of 19,000 American adults; about one-third of them had only “basic” or “below basic” health literacy.<sup>1</sup> People with “basic” health literacy skills may be able to read and write but not understand health-care information—at least not well enough to make decisions based on that information. For example, one of the questions testing for basic health-literacy skills asks the test-taker to report when he or she should return to the office after being given an appointment reminder slip. People testing at the basic or below-basic level could not accurately answer the question.

Fortunately, the American Academy of Ophthalmology now provides us with excellent educational materials to meet the needs of patients with a wide range of literacy skills. Back in 1997, the AAO’s recommended educational materials were written at a ninth-grade reading level. In 2008 the readability of the materials was adjusted to an eighth-grade reading level. As of 2014, the materials are written at a sixth-grade reading level, making them accessible to a far larger group of patients. (If you’re still using the older materials, it’s time to update.)

Some surgeons may worry that using simpler language and explanations could result in less engagement on the part of better-educated patients. This is apparently not an issue; a lot of work in the field of health-care literacy has shown that patients who have higher levels of literacy are going to ask questions to elevate the conversation to their level. They may ask which part of the trabecular meshwork is responsible for increased intraocular pressure, or ask for details about how the drop works. In response, we can



This study, conducted by the National Center for Education Statistics, found that about one-third of Americans function at basic or below-basic literacy. Educational materials need to take this into account in order to be helpful to the maximum number of patients.

start talking at that level as well.

However, research in health literacy suggests that the opposite is not true: If we provide information that our patients can’t understand, they’re unlikely to tell us. They’ll just shut down and not engage. This is certainly not what we want when we’re dealing with a disease that’s going to affect these patients for the rest of their lives.

Another aspect of this that may not be immediately obvious is that we’re not just asking patients to comprehend potentially complex written language; there are also a lot of numbers involved. For example, we often ask patients to take a drop twice a day in the right eye and another drop three times a day in the left eye. Comfort with “numeracy” is an important part of functional health literacy, and lack of numeracy skills is often harder to recognize than difficulty with verbal and written information.

## If You Create Your Own ...

It’s worth noting that some doctors create their own patient-education materials. If you’re one of them, keep in mind some of the general principles of presenting clear health-care communications:

- **Use an active voice, not a passive voice.** For example, “Be sure to let your doctor know if you’re having trouble using your medications,” not, “Problems using your medications should be reported to your doctor.”

- **Don’t fill pages with nothing but text.** Looking at a page that contains dense passages of nothing but text is intimidating to anyone at any reading level!

- **In terms of the content of your text, only use the level of detail that’s really necessary.** Most patients just want to understand the broad strokes regarding what they’re dealing with.

- **Include clear graphics in your materials that illustrate important points—but again, without too much unnecessary information.**

As much as I love a detailed drawing of the trabecular meshwork depicting the various regions, this is probably neither helpful nor particularly interesting to most of my patients.

Making your materials patient-friendly is crucial, because once people get turned off by what you’ve given them, they’ll decide not to read it and that’s that. You’ve lost the opportunity.

## Helping Patients Use the Drops


As everyone treating glaucoma understands, a central concern with glaucoma drops is making sure they reach the patient’s eye every day in a timely manner. Although it’s impossible to guarantee success in this arena, these strategies will shift the odds in your favor:

- **Ask patients about problems**

A PUBLICATION BY **REVIEW**  
of Ophthalmology

# RETINA SPECIALIST

Retina Specialist focuses on the latest advances in the diagnosis, medical management and surgical treatment of diseases of the retina, along with practical, real-world advice from leading clinicians and other experts on managing the successful retina practice.



Starting January 2019  
*Retina Specialist* will  
appear bimonthly.

Watch for issues in:

» **JANUARY**

» **JULY**

» **MARCH**

» **SEPTEMBER**

» **MAY**

» **NOVEMBER**

For inquiries contact

**RETINASPECIALIST@JOBSON.COM**

Advertising opportunities

JIM HENNE • PUBLISHER • 610-492-1017 • JHENNE@JOBSON.COM

MICHELE BARRETT • 215-519-1414 • MBARRETT@JOBSON.COM

MICHAEL HOSTER • 610-492-1028 • MHOSTER@JOBSON.COM

www.retina-specialist.com



*they're having taking the medications.* The reality is that every person is different, and people may miss their medications for any of a number of reasons. Patients could have problems related to cost, circumstances, memory, managing multiple disease conditions, or missing the eye and running out of the medication before the end of the month. There's only one way to know that there's a problem, and if so, exactly what the problem is: We have to ask. If we don't ask each patient what his or her particular challenges are, we won't know.

The reality is, even if we intend to do this, we often don't remember to do it. A couple of years ago I was one of 14 doctors involved in a multicenter study in which glaucoma patient visits, in both academic and private-practice offices, were video-recorded and the communication between doctor and patient was transcribed.<sup>2</sup> I was surprised to find that, even though we were trying to be on our best behavior and knew we were being videotaped, we frequently didn't ask about problems patients might have been having with their medications. (In fact, we often didn't even discuss the nature of the disease.)

It turned out that we only asked our patients if they were having problems with the medications in 51 percent of clinic visits. Given that we knew we were participating in a study, this result might even be better than what you'd find in the field. (In fairness, the study went on for three years, and it's hard to be on your best behavior for three years.)

Of course, once you do discuss these problems with patients and get a clear picture of the obstacles they're facing, the next step is to do whatever you can to help them avoid or surmount those obstacles. These strategies will help:

- **Always ask patients to show**

## More information about Glaucoma and your eyes.

This is what you might see **before** you had Glaucoma.

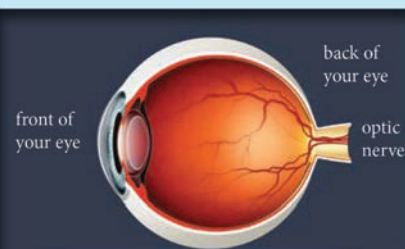

This is what you might see if Glaucoma took away your vision.



### Looking Inside the Eye

If you could look inside the eye, it would look like this.



Glaucoma damages the big nerve at the back of the eye. It happens because the eye doesn't drain fluid properly so pressure builds up inside the eye and presses on the nerve.



If you create your own educational materials for patients, be sure to follow a few basic rules to ensure good communication: Use an active voice; don't fill pages with nothing but text; provide only the level of detail that's necessary; and include clear graphics.

**you how they instill their drops.** If necessary, provide instruction. Some patients may do just fine on their own, but there's enough research now to show that plenty of glaucoma patients aren't able to get a drop onto their eye. For example, research done by Alan Robin, MD, has taught us that even among experienced drop users who deny any problems administering their drops, less than one-third can administer a drop successfully without contaminating the bottle tip.<sup>3</sup> In my work at the Durham Veterans Administration, I've found that 10 percent of my patients—patients who were experienced drop users—could

not get a drop into the eye at all under observation. And even if your patients succeed in getting a drop onto the eye without contaminating the tip, they may administer multiple drops in each attempt, causing them to run out of their medication before the next refill period is available. Furthermore, only a minority of patients report that anyone has ever shown them how to put in their eye drops.

So, ask your patients to demonstrate how they instill their drops. (We keep bottles of artificial tears in the clinic for this purpose, which is perfectly adequate to reveal any problems.) If a problem is obvious, show the patient

(and/or the patient's companion, if he or she is responsible for drop administration) the correct way to instill the drops.

- **Ask if someone else helps your patient instill drops.** We know from the work of Michael A. Kass, MD, that about 20 percent of patients don't instill their own drops.<sup>4</sup> This is not recent data, so the proportion of patients depending on assistance may be higher today, given that people are living longer and with multiple medical problems. We need to know if someone else is helping; if we're giving instructions for instilling drops, we need to be giving them to the person who's putting in the drops.

- **Ask your patients what time of day they take their drops.** If they say they take them right before bedtime, I ask whether they sometimes fall asleep before getting the drop in. You'd be surprised how many patients say, "Yeah, that happens a lot."

Prostaglandins are usually prescribed to be taken right before sleep because of the hyperemia associated with them. If that's a big issue for your patient, bedtime might be the better option, but for many of my patients a little hyperemia isn't a big deal. Certainly, it's better for a patient to take the drop in the morning and have a red eye than to not take it at all. I tell patients exactly that: If "red eye" is an issue, then take it at night, but if it's not a big deal, take it in the morning to avoid forgetting it at bedtime.

- **Suggest that patients pair taking their drops with other routine activities.** Having patients pair dosing with an activity such as taking other medications, brushing their teeth or drinking a cup of coffee in the morning, can help.

- **Suggest using a smartphone reminder app.** There are lots of apps out there designed to help patients remember to take their medications. They can use this type of aid for all of their medications or just for their

drops. (For a profile of some of these apps, see "Smartphone Apps: Aiding Compliance" in the June 2017 issue of Review.) Of course, if the patient has a companion who assists with taking the drops, both the patient and the assistant should use the reminder.

*Having patients pair their drop-taking with other routine activities can help.*

- **If a patient has difficulty managing the eye-drop bottle, suggest using an inexpensive aid.** Sometimes the problem isn't that patients can't get the drop in; they're just struggling a little bit. Many health issues can get in the way of being able to administer eye drops properly. For example, if the patient has osteoarthritis, that can make it difficult to squeeze the bottle, or a hand tremor could make it difficult to aim the bottle at the eye.

There are some relatively simple aids that might be helpful in this situation. I'm most familiar with the AutoDrop Eye Drop Guide and AutoSqueeze Bottle Aid (both made by Owen Mumford) because they're on the formulary in our prosthetics department. These aids only cost about \$5. The former is a cup that's open at both ends; the bottle is inserted into one end while the other end is placed over the eye. This can help patients who are struggling with aim. The latter aid has plastic wings that make it easier to squeeze the bottle; that can help those who have trouble with their grip strength. In addition, the two devices can be used together. (For a list of some additional options along these lines, see "Getting Drops Onto the Eye:

Low-tech Solutions" in the September 2017 issue of Review.)

Unfortunately, there's not a lot of evidence in the literature that these devices will make a huge difference. Different people have different problems, so if you're going to consider suggesting a device, you have to think about which one is most likely to help that patient; a one-size-fits-all approach to drop aids is probably not sufficient. Furthermore, you have to show them how to use it. Without a little instruction, your patient may never use the device.

Clearly, these aids are not a cure-all, but they can be helpful in some situations.

- **If it's clear the patient will have insurmountable difficulties instilling drops, consider pursuing a procedural intervention.** Sometimes a patient absolutely can't put in the drops, or is struggling significantly, and there's no companion available to help ensure that the drops get onto the eye. In that situation, you may want to move to a procedural intervention sooner rather than later. We all hope that in the near future we'll have sustained-release drug delivery options that will remove drop administration from the equation. But in the meantime, we have laser trabeculoplasty and multiple surgical options. We can move to those things sooner if we know that a patient is struggling. [REVIEW](#)

*Dr. Muir is an associate professor of ophthalmology at the Duke University School of Medicine in Durham.*

1. Committee on Health Literacy Board on Neuroscience and Behavioral Health. Health literacy: A prescription to end confusion. Lynn Nielsen-Bohman, Allison M. Panzer, David A. Kindig, eds. National Academies Press, 2004, p. 345.  
 2. Carpenter DM, Blalock SJ, Sayner R, Muir KW, et al. Communication predicts medication self-efficacy in glaucoma patients. *Optom Vis Sci* 2016;93:7:731-7.  
 3. Hennessy AL, Katz J, Covert D, Kelly CA, Suan EP, Speicher MA, Sund NJ, Robin AL. A video study of drop instillation in both glaucoma and retina patients with visual impairment. *Am J Ophthalmol* 2011;152:6:982-8.  
 4. Kass MA, Hodapp E, Gordon M, et al. Part I. Patient administration of eyedrops: Interview. *Ann Ophthalmol* 1982;14:8:775-9.

25<sup>TH</sup> ANNUAL

# OPHTHALMIC

## *Product Guide*



Innovative products to  
enhance your practice

The **future**  
is in your  
hands. One  
tap, many  
possibilities.

Experience the digital edition on your handheld device.  
Use your smart device to scan the code below or visit:



[www.reviewofophthalmology.com/publications/archive](http://www.reviewofophthalmology.com/publications/archive)

Download a QR scanner app. Launch app and hold your mobile device over  
the code to view [www.reviewofophthalmology.com/publications/archive](http://www.reviewofophthalmology.com/publications/archive).

**REVIEW**<sup>®</sup>  
of Ophthalmology



SAVE THE DATE



# Ophthalmology Update 2019

**FEBRUARY 16-17, 2019**

An interdisciplinary faculty of ophthalmic subspecialists will review the continuing progress in Cataract and Refractive Surgery, Glaucoma, Retina, Neuro-Ophthalmology, Pediatric Ophthalmology, Ocular Surface Disease, Cornea and Oculoplastics.

## PROGRAM CHAIRS

Don O. Kikkawa, MD  
Robert N. Weinreb, MD

## LOCATION

Cape Rey Carlsbad  
A Hilton Hotel  
1 Ponto Road  
Carlsbad, CA 92011  
(760) 602-0800

## PROGRAM TIMES

Saturday, February 16  
8:00am — 5:00pm  
Reception to follow  
  
Sunday, February 17  
8:00am — 12:15pm

## EARLY BIRD SPECIAL

Registration cost: \$95\*

## THREE WAYS TO REGISTER

[www.reviewofophthalmology.com/update2019](http://www.reviewofophthalmology.com/update2019)

Email: [reviewmeetings@jhihealth.com](mailto:reviewmeetings@jhihealth.com) | call: 855-851-9964



JOINTLY ACCREDITED PROVIDER™  
INTERPROFESSIONAL CONTINUING EDUCATION

In support of improving patient care, this activity has been planned and implemented by Amedco LLC and Postgraduate Healthcare Education LLC. Amedco LLC is jointly accredited by the Accreditation Council for Continuing Medical Education (ACCME), the Accreditation Council for Pharmacy Education (ACPE), and the American Nurses Credentialing Center (ANCC), to provide continuing education for the healthcare team.

Credit Designation Statement – This activity has been approved for *AMA PRA Category 1 Credit*™.

Shiley Eye Institute  
UC San Diego

Jointly provided by



PHE

Review of Ophthalmology®

\*See event website for additional information.



# Recognizing and Treating Ocular TB

Experts are attempting to reach a consensus on how to approach the treatment of ocular tuberculosis.

*Sarakshi Mahajan, MD, Palo Alto, California, Rupesh Agrawal, MD, Singapore, Quan Dong Nguyen, MD, Palo Alto, and Vishali Gupta, MS, Chandigarh, India*

**T**uberculosis is a global health challenge, affecting more than 2 billion people worldwide, with Asian countries like India and China being the hardest hit.<sup>1-4</sup> Although primarily affecting the lungs, extrapulmonary involvement, including intraocular TB (IOTB), can occur in up to 20 percent of patients.<sup>5</sup> The most common manifestation of IOTB is posterior uveitis, and the most common structure involved is the choroid.<sup>6,7,8</sup> In this article, we'll discuss ways to diagnose and manage this condition.

## Etiology and Diagnosis

The disease has protean clinical manifestations, and its phenotypic expression can mimic several other inflammatory and non-inflammatory diseases that cause intraocular inflammation, making it difficult to diagnose and manage. The disease can present as:

- granulomatous anterior uveitis;
- intermediate uveitis;
- choroidal tuberculomas;
- serpiginous-like choroiditis;
- multifocal choroiditis;
- retinal vasculitis neuroretinitis;

- optic neuritis;
- panuveitis; and
- scleritis.

Rarely, IOTB may present as panophthalmitis, endophthalmitis, optic neuropathy or optic nerve tubercle. These uncommon phenotypes are mostly seen in endemic regions. The varied spectrum of presentation, coupled with the difficulty of making a definitive diagnosis, due to lack of a tissue sample and uncertain guidelines and protocols for anti-tuberculosis treatment, make both diagnosis and treatment a challenge.

A recently completed multicenter retrospective collaborative study (the

Collaborative Ocular Tuberculosis Study [COTS-1]) collected data from 40 uveitis experts around the world in order to address the current controversies related to the diagnosis and management of intraocular tuberculosis.<sup>9-12</sup> The study had 945 subjects, 74 percent of whom were Asian. The study showed a higher prevalence of intraocular tuberculosis in the Asian population, in both native residents and immigrants. Among the Asian patients, the most common manifestation was TB serpiginous-like choroiditis (SLC), which was far less common in the Western population.<sup>9</sup> This study highlighted the variations in practice guidelines and lack of consensus among the experts about the diagnosis and management of this disease.

## Imaging Signs

Intraocular tuberculosis is usually suspected based on the clinical signs, and the diagnosis is further supported by ancillary and laboratory investigations. Ancillary investigations, including fundus autofluorescence, fluorescein angiography, indocyanine green

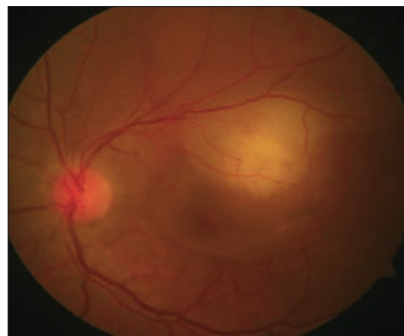


Figure 1. Color fundus photograph of the left eye shows choroidal granulomas as subretinal, elevated yellowish lesions.

angiography and optical coherence tomography, may detect characteristic features and are useful in detecting posterior segment disease.<sup>13</sup>

Choroidal tubercles are mostly located in the posterior pole or mid-periphery, and they show initial hypofluorescence in the early phases of FA, followed by hyperfluorescence in the later phases. These tubercles can also be seen as focal areas of choroidal elevation on OCT. Choroidal granulomas appear as subretinal yellowish lesions and may be associated with retinal detachment and subretinal fluid (*Figure 1*). The larger granulomas may form subretinal abscesses. Similar to choroidal tubercles, granulomas and abscesses are associated with early hypofluorescence and late hyperfluorescence. On ICGA, these appear hypofluorescent in both early and late stages. OCT in these lesions has become a helpful tool for detecting detachments as well as the location of granulomas. When compared with other pathologies, tubercular granulomas have a non-homogenous internal pattern with a lobulated shape.

Serpiginous-like choroiditis has three distinct patterns: multifocal; placoid; and mixed.<sup>14,15</sup> The multifocal pattern is characterized by multiple discrete, yellowish lesions with well-defined margins. The placoid pattern appears as a large plaque with yellowish edges and pigmentary changes in the center. When both features are present, the disease is characterized as mixed.

When observed on FA, multifocal SLC lesions are hypofluorescent in

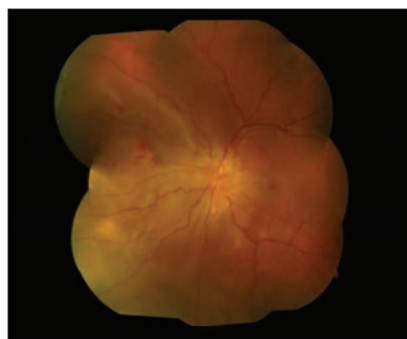

Figure 2. Color fundus photograph of the left eye shows large nasal choroidal granulomas with exudative retinal detachment.

early phases of the angiogram, with hyperfluorescence seen in late phases. Placoid lesions show mixed fluorescence in the center, with early hypofluorescence followed by late fluorescence on the edges. When SLC patterns are seen on fundus autofluorescence, early disease usually appears as hyperautofluorescent. As the lesion begins to heal, FAF shows a mixture of both hypo- and hyperautofluorescence, followed by an increase in hypoautofluorescence with a stippled intermixed pattern and finally a uniform hypoautofluorescence (*Figures 2 to 4*).<sup>16</sup>

Several newer imaging techniques

like ultra widefield imaging can play a significant role in identifying peripheral lesions in SLC that may be otherwise missed by conventional imaging.<sup>17</sup> OCT also helps detect retino-choroidal changes in TB SLC. OCT B-scans passing the active edge of TB SLC during the active stage show an area of hyper-reflectivity in the outer retinal layers with no increased back-scattering from the inner choroid. As the lesions heal, the hyper-reflective fuzzy areas disappear and are replaced by irregular, hyper-reflective knobby elevations of the outer retinal layers and other retinal layers, including RPE, ellipsoid and myoid zones; the ELM can't be identified at this stage.<sup>13</sup> Choroidal vascularity index measurement of the active SLC on OCT will show a relative decrease in choroidal vascularity, with choriocapillaris atrophy and the remodeling of the choroid during the healing stage.<sup>18</sup> OCT angiography has demonstrated novel findings that show voids in areas of choriocapillaris flow during the active stage of SLC that also correlate well with indocyanine green angiography.<sup>19</sup> ICGA is also very useful for detecting choroidal neovascular

membranes that may otherwise be missed.<sup>20</sup>

Presumed TB retinal vasculitis is peripheral occlusive retinal periphlebitis, with or without active retinal periphlebitis and features of peripheral capillary nonperfusion. Tubercular retinal vasculitis is mainly occlusive, and may result in peripheral neovascularization with recurrent vitreous hemorrhages, presenting as Eales' disease. The presence of coexis-

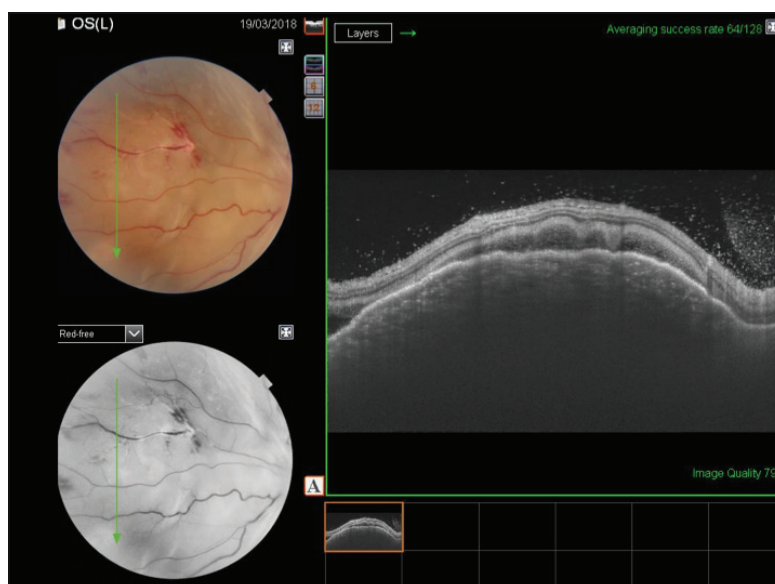
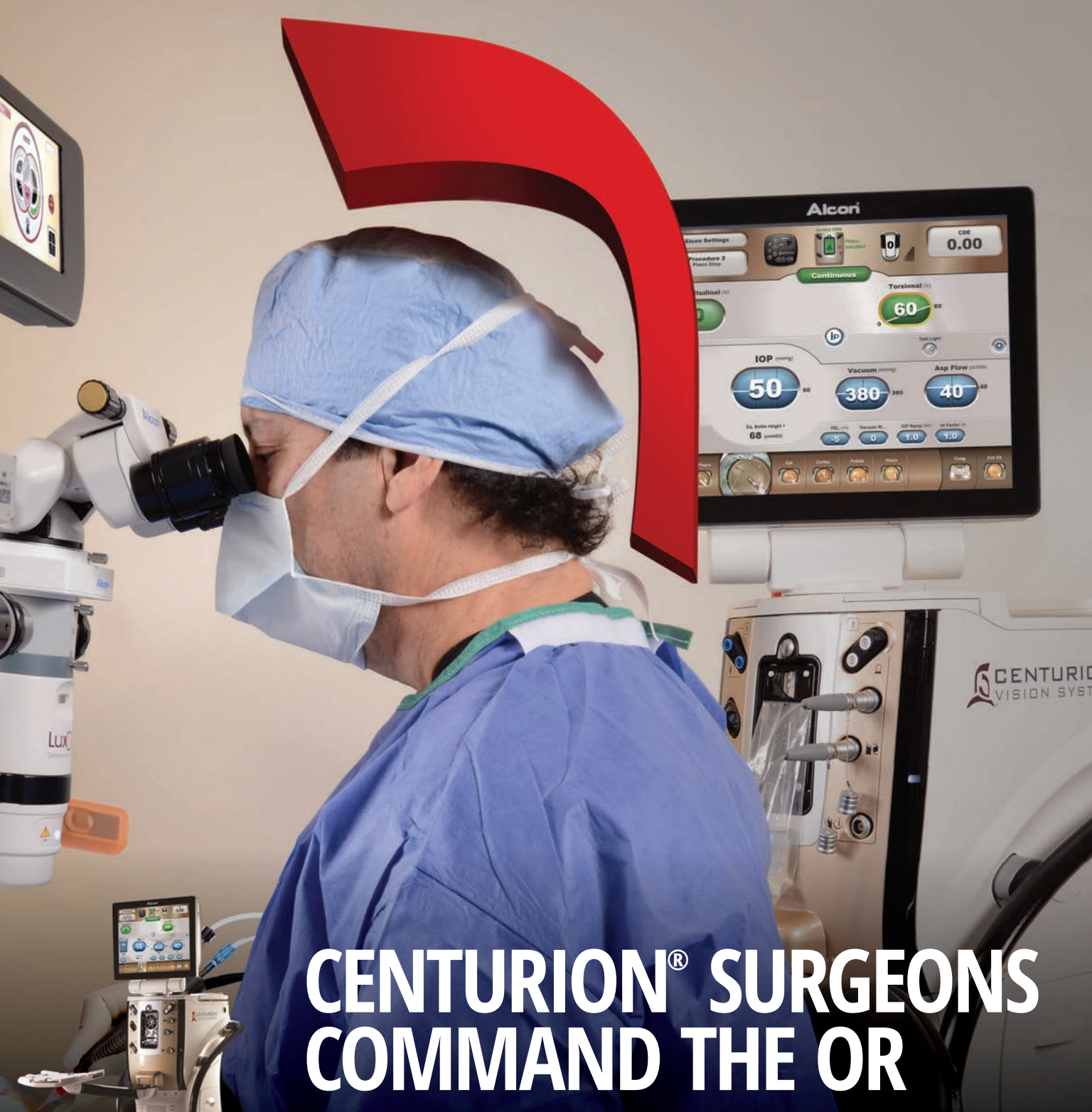

Figure 3. OCT line scan passing through the granuloma shows elevation of the choroid.





# CENTURION® SURGEONS COMMAND THE OR

Surgeons everywhere have taken command of their procedures with the Centurion® Vision System. **Thank you for partnering with us to remove more than 2 million cataracts every year.**

**Alcon** A Novartis  
Division

 **Centurion®**  
VISION SYSTEM

tent perivascular choroiditis lesions is suggestive of tubercular etiology.<sup>12</sup>

## Testing and Treatment

There is no single, gold-standard test for diagnosing IOTB. The confirmatory tests to isolate *Mycobacterium*, such as a positive acid-fast bacillus test or a positive culture from the ocular fluid, are rarely possible. Thus, detection of the mycobacterial genome by positive polymerase chain reaction for IS 6110 is often tried as an alternative.<sup>21,22</sup> However, the lack of standardization makes it difficult to recommend PCR as a diagnostic test.<sup>21</sup> Tests like QuantiFERON TB gold, Purified Protein Derivative (PPD) and CT chest are corroborative at best.

So far, the step-ladder approach to making the diagnosis of IOTB is widely followed. This approach involves identifying the clinical features and excluding other causes of uveitis, followed by looking at the results of a chest X-ray or computed tomography scan, PPD or QuantiFERON, and also considering intraocular sampling with molecular testing to confirm the diagnosis in certain situations.

Currently, there's no consensus regarding treatment for

IOTB due to a lack of guidelines regarding both initiation and duration of anti-tubercular drugs. The standard therapy for IOTB consists of isoniazid, rifampicin, ethambutol, pyrazinamide and pyridoxine. The therapy is initiated with 5 mg/kg/day of isoniazid, 10 mg/kg/day of rifampicin, 15 mg/kg/day of ethambutol, 20 to 25 mg/kg/day of pyrazinamide, and 10 mg/day of pyridoxine. The treatment should be started after carefully weighing the risks and benefits, along with monitoring liver function on a regular basis. There are no specific guidelines dictating the duration of treatment, and it's usually given for six months, with discontinuation of ethambutol and pyrazinamide after two months. Therapy helps reduce disease recurrence, and the COTS study reported treatment success in nearly 87 percent of 801 patients who received anti-TB therapy for various indications.<sup>9</sup>

The paradoxical worsening of the disease after the initiation of treatment further contributes to the contentious role of anti-TB therapy (ATT) in IOTB.<sup>23</sup> This phenomenon is most commonly observed in patients with TB SLC. Paradoxical worsening is observed due to a combination of multiple factors, including increased type IV hypersensitivity, increased exposure to *Mycobacterium* antigen such as tubercular proteins and the eye's response to them, and decreased suppressor mechanisms. The rate of detection of this worsening has increased significantly since the introduction of ultra-wide-field retinal imaging. UWF imaging detects 36 percent cases of worsening after two to six weeks of initiation of ATT versus only 14 percent with conventional imaging.<sup>17</sup> OCTA, too, has proven to be very useful in detecting paradoxical worsening by showing the alteration in choriocapillaris.<sup>24</sup> When detected, these patients require a higher dose of steroids or additional methylprednisolone pulses intravenously. In cases of anterior uveitis, topical steroids can be administered. The addition of steroid-sparing immunosuppressants is based on the patient's need for them, as well as the discretion of the uveitis specialist.<sup>25-30</sup>

Concomitant use of corticosteroids to manage inflammation of the eye is based on the hypothesis that the inflammation is secondary to a type IV hypersensitivity reaction to tubercular proteins. Steroids have also shown efficacy in reducing the macular edema secondary to the inflammation. Steroids are started with ATT with a dose of 1 mg/kg/day, which is then tapered over six to twelve months. Despite the supporting evidence, no one has defined clear guidelines specifying the use of corticosteroids, with certain authors supporting steroids' role and a few favoring their use only in cases of macular involvement.

The use of novel agents to treat tuberculosis has been on the rise, mainly to address the adverse effects associated with conventional therapy, as well as the challenges

### CENTURIUM® VISION SYSTEM IMPORTANT PRODUCT INFORMATION

#### CAUTION:

Federal (USA) law restricts this device to sale by, or on the order of, a physician. As part of a properly maintained surgical environment, it is recommended that a backup IOL Injector be made available in the event the AutoSert® IOL Injector Handpiece does not perform as expected.

#### INDICATION:

The Centurion® Vision System is indicated for emulsification, separation, irrigation, and aspiration of cataracts, residual cortical material and lens epithelial cells, vitreous aspiration and cutting associated with anterior vitrectomy, bipolar coagulation, and intraocular lens injection. The AutoSert® IOL Injector Handpiece is intended to deliver qualified AcrySof® intraocular lenses into the eye following cataract removal. The AutoSert® IOL Injector Handpiece achieves the functionality of injection of intraocular lenses. The AutoSert® IOL Injector Handpiece is indicated for use with the AcrySof® lenses SN60WF, SN6AD1, SN6AT3 through SN6AT9, as well as approved AcrySof® lenses that are specifically indicated for use with this inserter, as indicated in the approved labeling of those lenses.

#### WARNINGS:

Appropriate use of Centurion® Vision System parameters and accessories is important for successful procedures. Use of low vacuum limits, low flow rates, low bottle heights, high power settings, extended power usage, power usage during occlusion conditions (beeping tones), failure to sufficiently aspirate viscoelastic prior to using power, excessively tight incisions, and combinations of the above actions may result in significant temperature increases at incision site and inside the eye, and lead to severe thermal eye tissue damage. Good clinical practice dictates the testing for adequate irrigation and aspiration flow prior to entering the eye. Ensure that tubings are not occluded or pinched during any phase of operation. The consumables used in conjunction with ALCON® instrument products constitute a complete surgical system. Use of consumables and handpieces other than those manufactured by Alcon may affect system performance and create potential hazards.

#### AES/COMPLICATIONS:

Inadvertent actuation of Prime or Tune while a handpiece is in the eye can create a hazardous condition that may result in patient injury. During any ultrasonic procedure, metal particles may result from inadvertent touching of the ultrasonic tip with a second instrument. Another potential source of metal particles resulting from any ultrasonic handpiece may be the result of ultrasonic energy causing micro abrasion of the ultrasonic tip.

#### ATTENTION:

Refer to the Directions for Use and Operator's Manual for a complete listing of indications, warnings, cautions and notes.



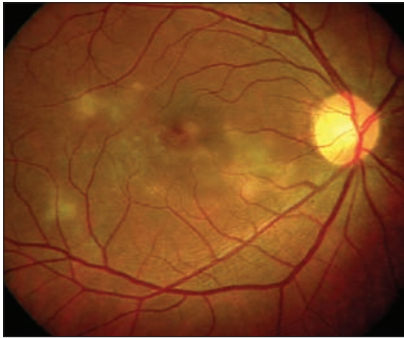


Figure 4. Color fundus photograph of the right eye shows multifocal serpiginoid choroiditis.

associated with paradoxical worsening of the disease. Intravitreal injections of depot steroids have been shown to improve outcomes in patients worsening on steroid and ATT therapy.<sup>25-27</sup> Other therapies proving to be effective as second-line treatments include intravitreal methotrexate and Interferon-alpha 2a.<sup>28-30</sup>

Treatment variability, including the use of concomitant steroids or immunosuppressants, is largely based on the standard clinical practice of a particular region. Treatment of IOTB is often managed with the help of a pulmonologist or an infectious disease specialist, following guidelines based on local practices. In COTS-1, researchers emphasized the difference in the outcome between patients from different ethnicities as well as geographic locations, with Asian patients having better overall survival outcomes after treatment.

Despite the advances in diagnostic tools for IOTB, clinical diagnosis remains a complex issue, and it influences the eventual treatment of the disease. To properly manage IOTB, the ophthalmologist and the internist have to work together, come to a consensus on the terminology they'll use with regard to IOTB, establish guidelines for their clinical investigation and determine the best treatment course to pursue in endemic and non-endemic regions. **REVIEW**

*Dr. Mahajan is a visiting instructor at Byers Eye Institute, Stanford Health Care in Palo Alto, where Dr. Nguyen is a professor of ophthalmology. Dr. Agrawal is an adjunct associate professor at the Tan Tock Seng Hospital in Singapore. Dr. Gupta is a professor in the department of ophthalmology at the Advanced Eye Centre, Post-graduate Institute of Medical Education and Research (PGIMER) in Chandigarh, India.*

*They have no financial interest in any products mentioned.*

*Direct correspondence to: Vishali Gupta, MS, Professor, Advanced Eye Center, Post Graduate Institute of Medical Education and Research (PGIMER), Sector 12, Chandigarh – 160012, India. Phone: +91 172 274 7837. Email: vishalisara@yahoo.co.in; vishalisara@gmail.com.*

1. Dye C, Scheele S, Dolin P, Pathania V, Raviglione MC. Consensus statement. Global burden of tuberculosis: Estimated incidence, prevalence, and mortality by country. WHO Global Surveillance and Monitoring Project. *JAMA* 1999;282:677–686.
2. Chakraborty AK. Epidemiology of tuberculosis: Current status in India. *Indian J Med Res* 2004;120:4:248–276.
3. Chadha VK. Tuberculosis epidemiology in India: A review. *Int. J. Tuberc Lung Dis* 2005;9:10:1072–1082.
4. GBD Tuberculosis Collaborators. The global burden of tuberculosis: Results from the Global Burden of Disease Study 2015. *Lancet Infect Dis* 2018;18:3:261–284.
5. Shakarchi FI. Ocular tuberculosis: Current perspectives. *Clin Ophthalmol* 2015;9:2223–7. doi: 10.2147/OPHT.S65254. (Epub ahead of print)
6. Gupta V, Shouhgy SS, Mahajan S, Khairallah M, Rosenbaum JT, Curi A, et al. Clinics of ocular tuberculosis. *Ocul Immunol Inflamm* 2015;23:1:14–24.
7. Gupta V, Gupta A, Rao NA. Intraocular tuberculosis—an update. *Surv Ophthalmol* 2007;52:6:561–587.
8. Gupta A, Bansal R, Gupta V, Sharma A, Bamberg P. Ocular signs predictive of tubercular uveitis. *Am J Ophthalmol* 2010;149:4:562–570.
9. Agrawal R, Gunasekaran DV, Grant R, Agarwal A, Kon OM, Nguyen QD, et al. Clinical features and outcomes of patients with tubercular uveitis treated with antitubercular therapy in the Collaborative Ocular Tuberculosis Study (COTS)-1. *JAMA Ophthalmol* 2017;135:12:1318–1327.
10. Agrawal R, Gunasekaran DV, Agarwal A, et al. The Collaborative Ocular Tuberculosis Study (COTS)-1: A Multinational Description of the Spectrum of Choroidal Involvement in 245 Patients with Tubercular Uveitis. *Ocul Immunol Inflamm* 2018 Aug 29;1-11. doi: 10.1080/09273948.2018.1489061 (Epub ahead of print)
11. Agrawal R, Gunasekaran DV, Rajee D, Agarwal A, Nguyen QD, Kon OM, Pavesio C, Gupta V; Collaborative Ocular Tuberculosis Study Group. Global variations and challenges with tubercular uveitis in the collaborative ocular tuberculosis study. *Invest Ophthalmol Vis Sci* 2018;59:10:4162–4171.

12. Gunasekaran DV, Agrawal R, Agarwal A, et al; COTS-1 Study Group. The Collaborative Ocular Tuberculosis Study (COTS)-1: A multinational review of 251 patients with tubercular retinal vasculitis. *Retina* 2018 Apr 24. [Epub ahead of print]
13. Agarwal A, Mahajan S, Khairallah M, et al. Multimodal imaging in ocular tuberculosis. *Ocul Immunol Inflamm* 2017;25:1:134–145.
14. Gupta V, Gupta A, Arora S, et al. Presumed tubercular serpiginous-like choroiditis: Clinical presentations and management. *Ophthalmology* 2003;110:9:1744–9.
15. Bansal R, Gupta A, Gupta V, et al. Tubercular serpiginous-like choroiditis presenting as multifocal serpiginoid choroiditis. *Ophthalmology* 2012;119:11:2334–42.
16. Gupta A, Bansal R, Gupta V, Sharma A. Fundus autofluorescence in serpiginous-like choroiditis. *Retina* 2012;32:4:814–25.
17. Aggarwal K, Agarwal A, Deokar A, et al. Ultra-wide field imaging in paradoxical worsening of tubercular multifocal serpiginoid choroiditis after the initiation of anti-tubercular therapy. *Ocul Immunol Inflamm*. 2017;11:1–6.
18. Agarwal A, Agrawal R, Khandelwal N, et al. Choroidal structural changes in tubercular multifocal serpiginoid choroiditis. *Ocul Immunol Inflamm* 2018;26:6:838–844.
19. Mandadi SKR, Agarwal A, Aggarwal K, et al; the OCTA Study Group. Novel findings on optical coherence tomography angiography in patients with tubercular serpiginous-like choroiditis. *Retina* 2017;37:9:1647–1659.
20. Aggarwal K, Agarwal A, Sharma A, Sharma K, Gupta V; OCTA Study Group. Detection of Type 1 choroidal neovascular membranes using OCTA in tubercular posterior uveitis. *Retina* 2018 Apr 23. [Epub ahead of print]
21. Agarwal A, Agrawal R, Gunasekaran DV, et al. The Collaborative Ocular Tuberculosis Study (COTS)-1 report 3: Polymerase chain reaction in the diagnosis and management of tubercular uveitis: Global trends. *Ocul Immunol Inflamm* 2017 Dec 20:1–9. Doi 10.1080/09273948.2017.1406529. [Epub ahead of print]
22. Sharma K, Gupta V, Sharma A, et al. Gene Xpert MTB/RIF assay for the diagnosis of intra-ocular tuberculosis from vitreous fluid samples. *Tuberculosis (Edinb)* 2017;102:1–2.
23. Gupta V, Bansal R, Gupta A. Continuous progression of tubercular serpiginous-like choroiditis after initiating anti-tubercular treatment. *Am J Ophthalmol* 2011;152:5:857–863.
24. Agarwal A, Aggarwal K, Deokar A, et al. Optical coherence tomography angiography features of paradoxical worsening in tubercular multifocal serpiginoid choroiditis. *Ocul Immunol Inflamm* 2016;24:6:621–630.
25. Fonollosa A, Valsero S, Artaraz J, Ruiz-Arruzal I. Dexamethasone intravitreal implants in the management of tubercular multifocal serpiginoid choroiditis. *J Ophthalmic Inflamm Infect* 2016;6:1:31.
26. Jain L, Panda KG, Basu S. Clinical outcomes of adjunctive sustained-release intravitreal dexamethasone implants in tuberculosis-associated multifocal serpiginoid choroiditis. *Ocul Immunol Inflamm* 2018;26:6:877–883.
27. Agarwal A, Handa S, Aggarwal K, et al. The role of dexamethasone implant in the management of tubercular uveitis. *Ocul Immunol Inflamm* 2018;26:6:884–892.
28. Julian K, Langner-Wegscheider B-J, Haas A, De Smet MD. Intravitreal methotrexate in the management of presumed tubercular serpiginous-like choroiditis. *Retina* 2013;33:9:1943.
29. Sahin O, Ziaei A. The role of methotrexate in resolving ocular inflammation after specific therapy for presumed latent syphilitic uveitis and presumed tuberculosis-related uveitis. *Retina* 2014;34:7:1451–1459.
30. La Distia Nora R, Walburg KV, van Hagen PM, et al. Retinal pigment epithelial cells control early Mycobacterium tuberculosis infection via interferon signaling. *Invest Ophthalmol Vis Sci* 2018;59:3:1384–1395.
31. Invernizzi A, Iannaccone F, Marchi S, et al. Interferon alpha-2a for the treatment of post-infectious uveitis secondary to presumed intraocular tuberculosis. *Ocul Immunol Inflamm* 2018 Feb 22:1–8. doi: 10.1080/09273948.2018.1431292. (Epub ahead of print)





# Management of Thyroid Eye Disease

In the second installment of this two-part series on TED, an oculoplastics expert discusses the treatment options.

*Sathyadeepak Ramesh, MD, Philadelphia*

**M**anagement of thyroid eye disease has shifted dramatically from conservative measures—observation and surgery—to targeted biologic therapy with a focus on cosmesis and quality of life. Surgical innovations have also allowed for more profound results with significantly less risk of complications. Treatments for active-phase disease have also multiplied, which significantly affects quality of life for these afflicted patients.

Last month, in part one of this two-part series on TED, I discussed the keys to diagnosing TED. Here, in part two, I'll discuss the best techniques for managing patients with TED.

## Medical Therapies

Medical therapy can be a good initial, noninvasive way to manage certain patients with TED. Following are the pros and cons of the various medical approaches.

- **Vitamins.** As discussed in part one of this series, data has shown that supplementation of selenium has reduced the severity and progression of disease in patients with mild thyroid eye disease.<sup>1</sup> Dosing is at 100 µg daily,

and is best started as early as possible in the course of the disease, preferably within six months of onset. While there have been no studies of vitamin D supplementation in patients with TED, laboratory studies have shown an anti-inflammatory effect. Checking vitamin D blood levels and supplementing appropriately does little harm to TED patients, and may even be helpful. Beyond this, a good multivitamin and a healthy diet low in fats and processed food is beneficial for both gastrointestinal and overall health. And of course, the number-one piece of advice for patients: Stop smoking.

- **Topical medicines.** Topical eye drops are chiefly prescribed to treat ocular surface disease. In the early, active phase of TED, ocular surface inflammation contributes to dry eye; this often responds to a low-dose topical steroid such as loteprednol or fluorometholone. In the later, stable phase of the disease, chronic exposure is the main cause of dry eye and can be addressed with lubrication—a regimen of artificial tears, gel and nighttime ointment is often necessary. While surgery may eventually be re-

quired, an aggressive topical regimen can greatly improve the quality of life for patients suffering with TED.

- **Steroids.** Steroids are excellent for reducing symptoms in TED, but aren't disease-modifying; rather, they improve soft-tissue symptoms in the active phase until the body can pass into the stable phase of the disease.

Steroids can be given as direct injections into the orbit, as pills or as intravenous infusions. Direct injections can be given as often as every four weeks in the clinic, and can provide significant symptomatic relief for patients with congestion, eye pain or a dull ache. They are particularly helpful if the disease is asymmetric or if a patient has diabetes or another health condition that makes systemic steroids risky (*Figure 1*).

In Europe, nearly every patient with a diagnosis of thyroid eye disease receives intravenous infusions of steroid once weekly for 12 weeks.<sup>2</sup> Intravenous steroids have been shown to have a greater efficacy than oral steroids (80 percent vs. 50 percent). While this doesn't cure the disease, it does reduce the clinical severity and improve the patient's quality of

life. However, 10 percent of patients are resistant to steroids. Steroids also carry the significant risks of liver failure, diabetes, insomnia, psychological changes and even death (if the cumulative dose exceeds 6 to 8 g).

Since the treatment doesn't alter the course of the disease, the decision of whether or not to undertake a course of intravenous steroids after a new diagnosis of thyroid eye disease is a very personal one and the patient and physician should discuss it in detail. The exception is for patients who are experiencing vision loss: Up to half of patients with optic nerve damage from thyroid eye disease may be able to avoid immediate surgery, or avoid surgery altogether, with a course of intravenous steroids.<sup>3</sup>

• **Orbital radiation.** This may sound scary, but it's a relatively gentle treatment considering the small doses that are used for TED. Radiation is helpful in patients who have persistent inflammation in active disease, and it's synergistic with steroids (i.e., the combined effect of radiation and steroids together is greater than either alone). Treatment is typically given in 10 sessions over two weeks, with a total dose of 20 Gy, which is well below the dose required to cause retinal damage (35 Gy) or nerve damage (50 Gy). Common side effects can include corneal dryness or development of an early cataract. Radiation may be particularly helpful in patients who have strabismus and double vision,<sup>4</sup> although it doesn't cure or shorten the course of active thyroid eye disease.

• **Biologic therapy.** Biologic therapy, or customized molecular medicines that specifically target the abnormal biochemical pathways in thyroid eye disease, are a promising hope for the future. These include currently available medicines such as adalimumab (Humira),

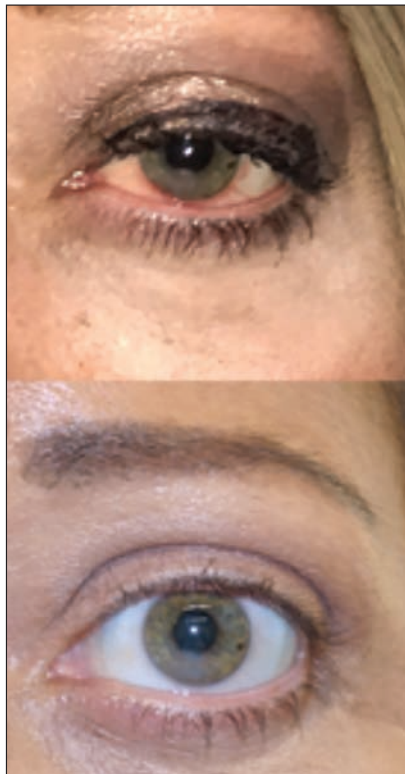

Figure 1. Eyelid swelling and ocular redness in a patient with thyroid eye disease (top). Improvement in redness and swelling after orbital steroid injection (bottom).

infliximab (Remicade) and etanercept (Enbrel), as well as many medicines yet to be approved. Unfortunately, these drugs are quite expensive, precluding a large-scale randomized trial

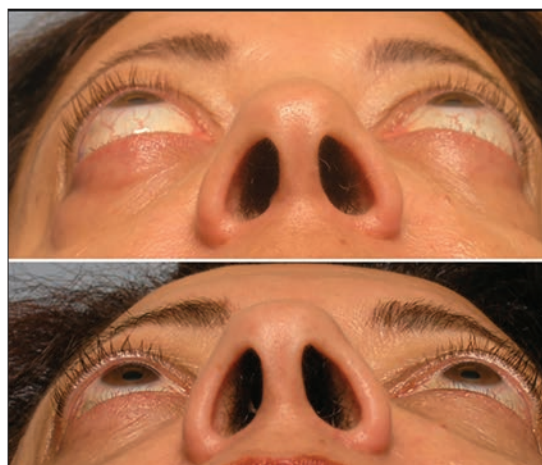

Figure 2. Bilateral proptosis in a patient with thyroid eye disease (top). Dramatic reduction in proptosis seen after orbital decompression surgery (bottom).

from being conducted. At the same time, insurance companies are hard-pressed to approve a medicine that hasn't been proven in a trial. As such, physicians are left with weak studies that are little more than anecdotes about clinical improvement with these medicines.<sup>5</sup>

Rituximab is a medicine well-described in its use against lymphoma. It targets the immune cells that produce antibodies (B-cells), and physicians were initially very hopeful that there would be a clinical effect in patients with TED. Two large, randomized, controlled, concurrent trials were conducted: one in Europe and one in the United States.<sup>6,7</sup> Unfortunately, the results were conflicting, with the European study suggesting a beneficial effect of rituximab<sup>6</sup> and the United States study showing no improvement.<sup>7</sup> While there are technical explanations for these confusing results, the bottom line remains that there is no clear evidence that rituximab improves the course of TED.

Tocilizumab (Actemra, Genentech) is a potent biologic medicine that was initially used for other severe autoimmune diseases such as giant cell arteritis. There have been case reports of improvement in TED,<sup>8,9</sup> and Genentech recently completed a randomized, controlled trial, the results of which are pending.

The most exciting drug to be developed in recent memory for thyroid eye disease is surely teprotumumab (RV 001). Teprotumumab is an antibody directed against IGF-1, the growth factor pathway associated with the thyroid-hormone receptor. Teprotumumab is the only medicine to date proven to reduce overall clinical severity and proptosis, and provide a sustained response.<sup>10</sup> In other words, teprotumumab can halt progression of active disease and reverse any changes

associated with TED, and the effects are long-lasting. Now that this trial has been published, the medicine is in the hands of the Food and Drug Administration, where the approval process could take several months or even years. The drug is still available to patients on an out-of-pocket basis if necessary, however, and the manufacturer can provide discounts based on need and disease severity.

Overall, biologic medicines and targeted molecular therapy are the wave of the future. More research is needed, but patients with TED live in exciting times, as these new medicines can truly be life changing.

### Surgical Therapies

Surgery for TED is often necessary, but is usually delayed until the disease is in its stable phase. There's a small (<10 percent) risk of reactivating the active phase of the disease after surgery, though this is rare. The surgical options consist of the following:

- **Orbital decompression.** Orbital decompression surgery is the mainstay of rehabilitation for TED; it can improve nearly every aspect of the disease, from vision-threatening optic nerve damage or corneal exposure (Figure 2) to cosmesis (Figure 3). Quality of life is often better after surgery, since orbital congestion, pain and dry eye can improve. Common complications include double vision and scarring (5 to 25 percent, depending on the technique used), while rare complications include vision loss (<0.5 percent, partial or total in the operated eye), though these can be minimized with newer, minimally invasive techniques.<sup>11,12</sup> Surgery is performed under general anesthesia through invisible skin incisions hidden in the natural folds of the eyelids, takes 60 to 90 minutes, and is performed on an outpatient basis.

- **Strabismus surgery.** Surgery to adjust the extraocular muscles and

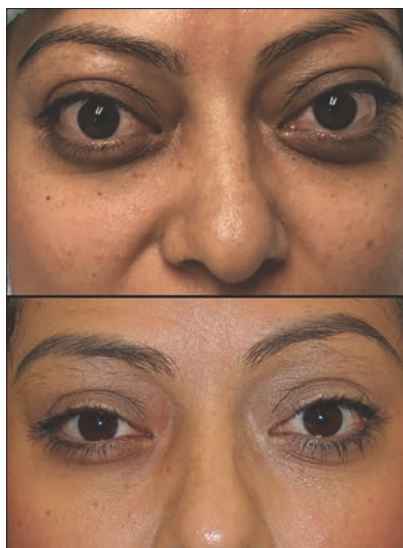

Figure 3. Patient with visual compromise, orbital congestion and pain from thyroid eye disease (top). Improvement in cosmetic appearance, as well as vision, orbital congestion and pain after decompression surgery (bottom).

improve double vision is commonly performed. However, this can be much more complicated than typical strabismus surgery, and needs to

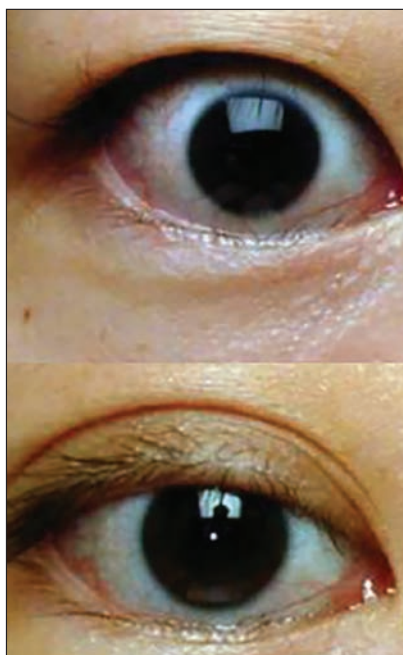


Figure 4. Eyelid retraction (top) with improvement in upper lid position after eyelid retraction surgery (bottom).

be performed by a surgeon who is experienced in thyroid eye disease. This surgery takes between 30 to 60 minutes, can be performed under general or twilight anesthesia, and is done on an outpatient basis. Patients can have significant improvement if the muscles aren't too scarred.

- **Eyelid surgery.** Surgery to improve eyelid retraction is often the final step in rehabilitation. This step can also be the most temperamental, as the eyelid structures are incredibly minute and unpredictable. However, significant improvement can be achieved (Figure 4). Surgery is performed under twilight anesthesia, can take between 30 to 60 minutes, and is done on an outpatient basis.

- **Cosmetic surgery.** While thyroid eye disease primarily affects the tissues inside the orbit, there are significant changes in the skin and fat in the eyebrows, cheeks, neck and other areas of the face. In fact, the eyebrow and cheek fat tends to grow alongside the orbital fat, creating a characteristic "hourglass" appearance (Figure 5). These various changes can be addressed with a combination of lasers, fillers, botulinum toxin (i.e., Botox), or even surgery for the eyelid, eyebrow, face and neck. Great care must be taken when undergoing cosmetic surgery in the context of thyroid eye disease: Treating a TED patient like any other cosmetic surgery patient can, at best, lead to a hollow, unnatural look and, at worst, lead to severe corneal exposure and loss of vision or even loss of the eye.

### Future Directions

With all the exciting research and medical and surgical innovations that have come to fruition in the past several years, it's an exciting time for patients with thyroid eye disease. In an ideal world, we'd be able to predict exactly which patients with Graves' disease will develop thyroid eye dis-



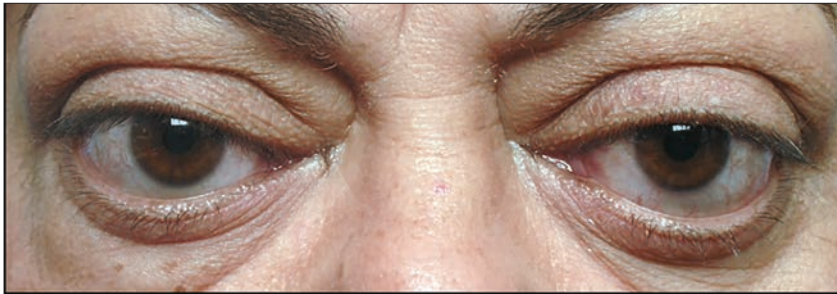

Figure 5. Fat growth in the brows and lower lids and cheeks after thyroid eye disease, causing an “hourglass” deformity.

ease, treat them with a medicine to prevent TED, and reverse any clinical manifestations that may have already occurred. This goal is within reach, since game-changing new medicines that can halt and reverse symptoms of TED are in the pipeline, and the focus has shifted from simply preserving vision to enhancing such things as cosmesis and quality of life. [REVIEW](#)

*Dr. Ramesh is a clinical assistant professor of ophthalmology at Sidney Kimmel Medical College at Thomas Jefferson University, and a member of the Wills Eye Hospital Orbital and Oculoplastic Surgery Service. He practices at Eye and Facial Plastic Surgery Consultants in Langhorne, Pennsylvania. His areas of interest include TED, facial trauma and cosmetic facial and eyelid procedures.*

1. Marcocci C, Kahaly GJ, Krassas GE, et al. Selenium and the course of mild Graves' orbitopathy. *N Engl J Med* 2011;364:20:1920-31.
2. Bartalena L, Baldeschi L, Boboridis K, et al. The 2016 European Thyroid Association/European Group on Graves' Orbitopathy guidelines for the management of Graves' orbitopathy. *Eur Thyroid J* 2016;5:1:9-26.
3. Wakelkamp IM, Tan H, Saeed P, et al. Orbital irradiation for Graves' ophthalmopathy: Is it safe? A long-term follow-up study. *Ophthalmology* 2004;111:8:1557-62.
4. Prummel MF, Terwee CB, Gerding MN, et al. A randomized controlled trial of orbital radiotherapy versus sham irradiation in patients with mild Graves' ophthalmopathy. *J Clin Endocrinol Metab* 2004;89:1:15-20.
5. Ayabe R, Rootman DB, Hwang CJ, et al. Adalimumab as steroid-sparing treatment of inflammatory-stage thyroid eye disease. *Ophthalmic Plast Reconstr Surg* 2014;30:5:415-9.
6. Salvi M, Vannucchi G, Curro N, et al. Efficacy of B-cell targeted therapy with rituximab in patients with active moderate to severe Graves' orbitopathy: A randomized controlled study. *J Clin Endocrinol Metab* 2015;100:2:422-31.
7. Stan MN, Garrity JA, Carranza Leon BG, et al. Randomized controlled trial of rituximab in patients with Graves' orbitopathy. *J Clin Endocrinol Metab* 2015;100:2:432-41.
8. Perez-Moreiras JV, Alvarez-Lopez A, Gomez EC. Treatment of active corticosteroid-resistant graves' orbitopathy. *Ophthalmic Plast Reconstr Surg* 2014;30:2:162-7.
9. Sy A, Eliasieh K, Silkiss RZ. Clinical response to tocilizumab in severe thyroid eye disease. *Ophthalmic Plast Reconstr Surg* 2017;33:3:e55-e7.
10. Smith TJ, Kahaly GJ, Ezra DG, et al. Teprotumumab for thyroid-associated ophthalmopathy. *N Engl J Med* 2017;376:18:1748-61.
11. Ramesh S, Nobori A, Wang Y, et al. Orbital expansion in cranial vault after minimally invasive extradural transorbital decompression for thyroid orbitopathy. *Ophthalmic Plast Reconstr Surg* 2018; 2018 Jun 6. (epub ahead of print).
12. Ramesh S, Eichhorn K, Leibowitz S, Goldberg R. Bony regrowth after deep lateral orbital decompression. *Ophthalmic Plast Reconstr Surg* 2018;34:6:533-35.

# Hiring Ophthalmic Staff?

More Ophthalmic Professionals find jobs on Local Eye Site than anywhere else.



Save 20% with coupon code: **REVOPH**

[localeyesite.com](http://localeyesite.com)



**Practice For Sale**

**Practice Consultants**  
 Practice Sales • Appraisals • Consulting  
[www.PracticeConsultants.com](http://www.PracticeConsultants.com)

**PRACTICES FOR SALE  
 NATIONWIDE**

Visit us on the Web or call us to learn more about our company and the practices we have available.  
[info@PracticeConsultants.com](mailto:info@PracticeConsultants.com)  
**800-576-6935**  
[www.PracticeConsultants.com](http://www.PracticeConsultants.com)

**Career Opportunities**

**OPHTHALMOLOGISTS**  
 Danbury, CT

Ophthalmologists to share office with long standing Ophthalmologist in Danbury, CT. High quality equipment. \$2,250 per month or adjoining office without equipment- \$1,750 per month.

**203-545-3539 or  
 email [mehrimd@aol.com](mailto:mehrimd@aol.com)**

**CONTACT US TODAY  
 FOR CLASSIFIED ADVERTISING**  
 Toll free: **888-498-1460**  
 E-mail: [sales@kerhgroup.com](mailto:sales@kerhgroup.com)

**REVIEW**  
of Ophthalmology

Do you have Products and Services for sale?

**CLASSIFIED  
ADVERTISING WORKS**

- JOB OPENINGS
- CME PROGRAMS
- PRODUCTS
- AND MORE...

Contact us today for classified advertising:  
Toll free: **888-498-1460**  
E-mail: [sales@kerhgroup.com](mailto:sales@kerhgroup.com)



For classified advertising call **1-888-498-1460** or e-mail us at [sales@kerhgroup.com](mailto:sales@kerhgroup.com)

**KERHGROUP**

**Career Opportunities**

**SEEKING A BOARD CERTIFIED OPHTHALMOLOGIST**

**cpt CONSUMER PRODUCT TESTING COMPANY**  
[cptclabs.com](http://cptclabs.com)

Consumer Product Testing Company (CPT) is a worldwide leader in the contract laboratory testing of cosmetics, personal care, pharmaceuticals, medical devices and specialty chemicals. Since 1975, our staff has assisted clients with their testing needs from conception to completion. Our technical staff has extensive experience that is used to assist clients through each phase of the testing process. This includes protocol design, subject recruitment, statistical analysis and report preparation. Our Quality Assurance and Regulatory staff monitors compliance to our internal SOPs and applicable regulations. We attribute our growth to our dedication to the needs of our clients. Well known for our superior customer service, we become an integral part of our clients' team, providing timely, reliable, accurate, and reproducible results.

We are currently seeking a Board Certified Ophthalmologist to assist our Medical Director and staff, in the review of clinical trial protocols, and participate in those trials, by providing your services in performing general eye examinations, including using a slit lamp. We can schedule your hours with us around your primary practice, and offer competitive hourly rates. If you have ever been interested in working on clinical trials, please call us to obtain additional information.

CPT is located in our own 45,000 sq. foot building in Fairfield, New Jersey in Essex County.

**If you are interested in working with us in our New Jersey facility, please contact:**

**Human Resources  
 Consumer Product Testing Company, Inc.  
 70 New Dutch Lane  
 Fairfield, NJ 07004  
 Email: [cptcjobs@cptclabs.com](mailto:cptcjobs@cptclabs.com)**

**REVIEW**  
of Ophthalmology

Targeting Physicians?

**CLASSIFIED ADVERTISING WORKS**

- JOB OPENINGS
- CME PROGRAMS
- PRODUCTS & SERVICES
- AND MORE...

Contact us today for classified advertising:  
Toll free: **888-498-1460**  
E-mail: [sales@kerhgroup.com](mailto:sales@kerhgroup.com)




## ENRICH YOUR PRACTICE

*Review of Ophthalmology* delivers current and comprehensive information focusing on topics such as disease diagnosis, surgical techniques and new technologies.

The *Review Group's Ophthalmic Product Guide* brings you the latest products and technology on the market. Published every February and July.



The *Review Group* also distributes a variety of supplements, guides and handbooks with your subscription to *Review of Ophthalmology*. These publications are designed to keep you informed on what's new and innovative in the industry on topics ranging from cataract refractive surgery to ocular surface disease.

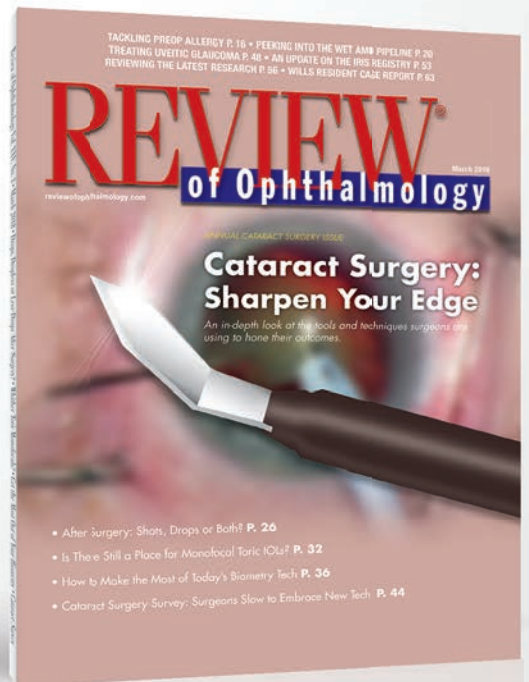


The *Review Group* also offers valuable continuing medical education sessions in both print and online formats, allowing a convenient way for you to earn CME credits. In addition, we also offer an impressive fleet

of free e-newsletters—such as *Review of Ophthalmology Online* and *Review of Ophthalmology's Retina Online*—so you can keep up to date on breaking news and the latest research.



The *Review Group* offers eyecare practitioners quality informational resources dedicated to the growth and education of the profession. The *Review Group* offers a variety of print and online products to enrich your patient care and practice needs.



The *Review Group* also spearheads meetings and conferences, bringing together experts in the field and providing a forum for practitioners that allows you to educate, and learn from others in the profession. These meetings cover a broad range of topics in the form of educational or promotional roundtables and forums.

[www.reviewofophthalmology.com](http://www.reviewofophthalmology.com)



Jobson Medical Information LLC  
The *Review Group*





I was only seeing light flashes early on, but light

# FLASHES

when you've not seen anything for  
so many years—it was wonderful.

—Keith H, retinal prosthesis recipient

WE'RE SEEING AMAZING RESULTS. **AND SO ARE THEY.**

Foundation Fighting Blindness is shining a light in the darkness of Inherited Retinal Degenerations. We are the world's leading organization searching for treatments and cures, and with many treatments already found, today's innovations are illuminating a future of possibilities.

**Patients with Inherited Retinal Degenerations are urged to partner with us to accelerate the discovery of treatment and cures.**

We have robust disease information, a national network of local chapters and support groups, local educational events, and our My Retina Tracker patient registry helps to keep your patients connected with clinical and research advancements.



Visit [ECPs4Cures.org](https://ECPs4Cures.org)  
to make a donation  
to help find more cures.

[FightBlindness.org](https://FightBlindness.org)

**FOUNDATION FIGHTING  
BLINDNESS**



An older man has an unexpected finding after presenting to the Wills Eye emergency room for orbital fractures.

*Kalla A. Gervasio, MD, and Robert B. Penne, MD*

## Presentation

A 76-year-old Caucasian male was referred to the Wills Eye emergency room for evaluation of blurred vision and diplopia after a fall. He had reportedly tripped over a hose, fell, and hit the left side of his face and his left eye on a lawn mower several hours prior to presentation. The patient was wearing safety glasses and didn't lose consciousness during the fall. He initially presented to an outside emergency room where a left brow laceration was repaired, and CT scans of the brain and cervical spine were negative. He was referred for further evaluation of left orbital floor and medial wall fractures on maxillofacial CT scan.

## Medical History

Two years prior to presentation, he was struck in the right eye by a high-tension wire while riding a tractor and suffered a vitreous hemorrhage and a retinal tear for which he underwent pars plana vitrectomy and laser retinopathy. Past ocular history also included cataract surgery and ocular hypertension in both eyes, and YAG capsulotomy in the right eye. Past medical history included hypertension, hyperlipidemia, type II diabetes mellitus, obstructive sleep apnea, Alzheimer's disease, restless leg syndrome, osteoarthritis and benign prostatic hypertrophy. Social and family histories were non-contributory. Current medications included dorzolamide-timolol in both eyes, amlodipine, lisinopril, atorvastatin, aspirin, pioglitazone, niacin, quetiapine, pramipexole, memantine, galantamine, sertraline, tamsulosin and meloxicam.

## Examination

Ophthalmic examination demonstrated a visual acuity of 20/40 OD (pinhole 20/20) and 20/25 OS (PH no improvement). Pupils and confrontation visual fields were normal, and Ishihara color plates were 8/8 OU. Motility of the right eye was full, while motility of the left eye demonstrated 0-percent supraduction, 95-percent adduction, 90-percent infraduction and 100-percent abduction. A right hypertropia was present in primary gaze (25 prism diopters), which worsened in upgaze (>30 prism diopters). Intraocular pressure by Goldmann tonometry was 14 mmHg in both eyes. External examination revealed sutured lacerations of the central forehead and left eyebrow, 360 degrees of ecchymosis and edema around the left orbit, and enophthalmos and hypoglobus of the left eye in primary gaze (*Figure 1*). There was no bony step-off palpated on external examination of the orbital rim. Hertel exophthalmometry demonstrated enophthalmos of the left eye with a base of 121 mm, 20.5 mm OD and 18 mm OS. Sensation was intact in the V1 and V2 distributions.

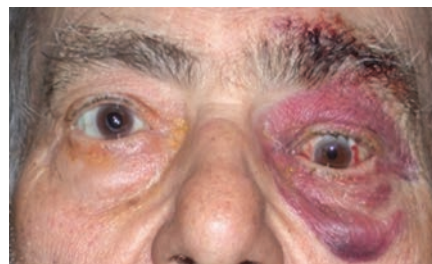

Figure 1. External photo showing left periorbital ecchymosis and edema with hypoglobus in primary gaze after a mechanical fall.

Slit lamp examination was notable for 1+ conjunctival injection, temporal subconjunctival hemorrhage, superior superficial punctate keratopathy of the left eye and posterior chamber intraocular lenses in both eyes. Dilated fundus examination was normal in both eyes. Forced duction and force generation testing were performed after instillation of viscous lidocaine. Forced duction testing was normal in the right eye and revealed restriction of vertical motility in the left eye. Force generation testing was normal in both eyes.

***What is your diagnosis? What further workup would you pursue? The diagnosis appears on p. 64.***

## Workup, Diagnosis and Treatment

Upon presentation to the Wills Eye emergency room, the patient underwent CT of the orbits, which re-demonstrated the left orbital floor and medial wall fractures and also showed a prolapsed orbital mass in the left maxillary sinus (*Figure 2A*). The restricted vertical forced ductions on the left side were not thought secondary to an entrapped extraocular muscle, so the patient was discharged with a follow-up appointment with the oculoplastics service. He was seen the next day, at which time a prior history of a left orbital mass was elicited. MRI of the orbits had been performed prior to the trauma and had revealed an extraconal mass in the left inferomedial orbit (*Figure 2B*). Given the patient's presentation with symptomatic diplopia, restriction of upgaze, and hypoglobus, the decision was made to perform surgery one week after the initial accident.

The patient underwent orbital exploration, during which the orbital floor was exposed and a mass was found in the left maxillary sinus. A cryoprobe was used to elevate the mass out of the maxillary sinus, and it was resected and sent to pathology. The orbital floor fracture was then repaired with placement of a 1.5 mm porous polyethylene implant. Histopathologic examination of tissue from the orbital mass revealed an en-

capsulated mass composed of bland spindle cells that stained positively for S-100 protein and negatively for smooth muscle actin and Stat6 with the presence of nuclear palisading. The pathologic findings were consistent with a diagnosis of benign

peripheral nerve sheath tumor, specifically orbital schwannoma. The patient healed well postoperatively with resolution of diplopia, restoration of extraocular motility and no recurrence of orbital schwannoma (*Figure 3*).

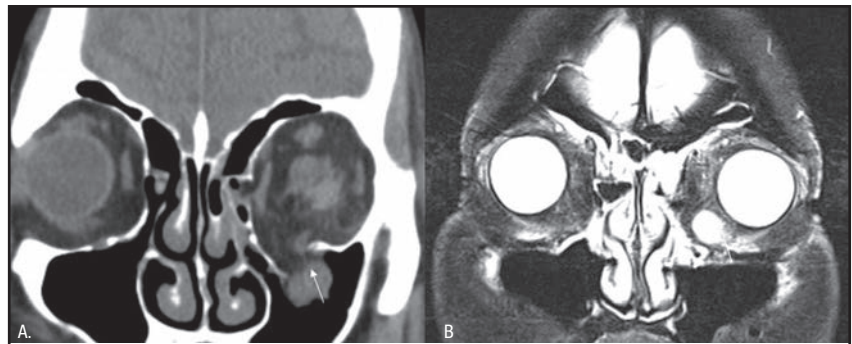


Figure 2. CT of the orbits after a mechanical fall, showing left medial and orbital floor fractures with prolapse of an orbital mass into the left maxillary sinus (A, arrow). MRI of the orbits prior to trauma shows an enhancing mass in the left inferomedial orbit (B, arrow).

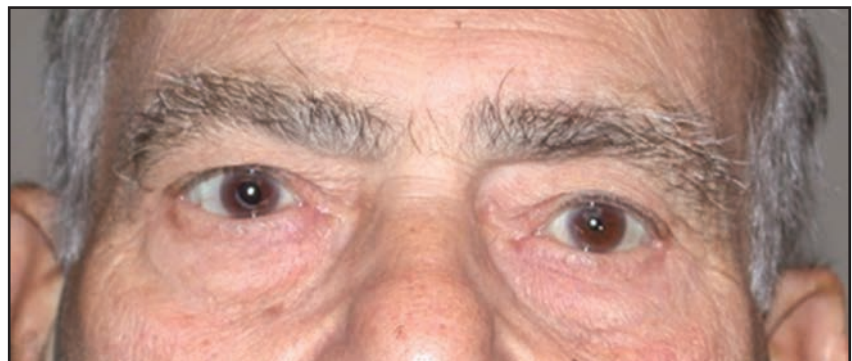

Figure 3. External photo showing resolution of left periorbital ecchymosis, edema and hypoglobus after removal of the left orbital mass and repair of the orbital floor fracture.

## Discussion

The differential diagnosis of a solitary orbital mass in an adult is broad and varies depending on the location within the orbit as well as the specific age of the patient. Overall, the most common benign orbital mass in adults is cavernous hemangioma, which is a well-encapsulated mass that tends to occur at the lat-

eral aspect of the intraconal space.<sup>1,2</sup> Also known as cavernous malformations, these are congenital vascular anomalies present at birth that grow slowly over time and tend to present in adults aged 43 to 48 years, particularly females.<sup>3</sup> If small and asymptomatic, cavernous hemangiomas are observed with annual or bian-

nual exams and imaging. However, if symptomatic with visual changes and/or diplopia, they are surgically excised.<sup>4</sup>

Initially, the patient in this case was thought to have a cavernous hemangioma that had prolapsed into the maxillary sinus after trauma, given that this is the most common





benign orbital tumor in adults. In addition to cavernous hemangioma, the differential diagnosis of well-encapsulated orbital tumors includes peripheral nerve sheath tumors (schwannoma and neurofibroma), hemangiopericytoma, fibrous histiocytoma, solitary fibrous tumor and melanoma. If this patient's lesion had been found without simultaneous trauma, the most likely management would have been observation. However, given recent trauma with concomitant orbital fractures and symptomatic diplopia, the orbital mass was removed surgically. It's likely that the mass being pulled into the maxillary sinus worsened the patient's restriction of upgaze. Upon histopathologic examination of the mass, a diagnosis of schwannoma was rendered.

Schwannomas, also known as neurilemmomas or neurinomas, are the most common type of benign peripheral nerve sheath tumor of the orbit, where peripheral nerve sheath tumors represent 2 percent of all orbital neoplasms.<sup>5</sup> Orbital schwannomas grow slowly and tend to affect adults in the third to seventh decades of life.<sup>6</sup> They typically arise from trigeminal nerve branches, particularly in the superior orbit with concomitant inferior displacement of the globe.<sup>7</sup> Patients with orbital schwannomas present with insidious proptosis and lid swelling, with later signs and symptoms including diplopia, restriction of extraocular movements, decreased visual acuity and sequelae of optic nerve compression.<sup>8</sup> Pain and paresthesia can also occur depending on the specific nerve involved and the extent of growth.

CT and MRI can both be used to further characterize orbital tumors. In the case of orbital schwannomas, CT scan will demonstrate a smooth, well-circumscribed mass that most commonly occurs in an extraconal location rather than the traditional intraconal

location of cavernous hemangiomas.<sup>1</sup> On MRI, the degree of heterogeneity of orbital schwannomas depends on the pathologic pattern of the tumor.<sup>6</sup> Pathologically, orbital schwannomas stain positively for S-100 protein and demonstrate one of two patterns, termed Antoni A or Antoni B. The Antoni A pattern consists of tightly packed Schwann cells with nuclear palisading, as in our case, while the Antoni B pattern consists of loosely packed Schwann cells within the capsule.<sup>6</sup>

  
*Orbital schwannomas  
grow slowly and tend to  
affect adults in the third  
to seventh decades of  
life.*  


One study found that the Antoni A pattern correlates with hyperintensity on T1-weighted and hypointensity on T2-weighted imaging, while the Antoni B pattern correlates with hypointensity on T1-weighted and hyperintensity on T2-weighted imaging.<sup>6</sup> In addition, if an orbital schwannoma is long-standing, degenerative changes on MRI such as hemorrhage, cavity formation and calcification may be evident.<sup>7</sup> In one retrospective interventional case series, patients with cavitary change or heterogeneous signal intensity on T2-weighted MRI images were more likely to demonstrate Antoni B patterns on pathologic examination, which also corresponded to a more friable tumor and fragmented surgical excision.<sup>9</sup>

Management of orbital schwannoma includes en bloc resection with

preservation of capsular integrity of the tumor. Surgical approaches vary depending on tumor location, with anterior orbitotomies used for schwannomas in the superior orbit, lateral orbitotomies used for superolateral tumors and inferior transconjunctival approaches used for inferior or medial lesions.<sup>10</sup> Alternatives for small, unresectable tumors include multisession gamma knife radiation therapy, though results are variable and the procedure involves a risk of vision loss from optic neuropathy.<sup>11</sup> Orbital schwannomas require long-term follow-up to monitor for recurrence or malignant transformation, both of which rarely occur with total excision.<sup>12</sup>

In conclusion, orbital schwannoma should be considered on the differential diagnosis of a well-circumscribed extraconal orbital mass, although they are rare among all causes of orbital neoplasm. Although observation was an option, the patient in this case underwent resection since he had diplopia and restriction of extraocular motility in the setting of unrelated orbital fractures. **REVIEW**

1. Tailor TD, Gupta D, Dalley RW, et al. Orbital neoplasms in adults: Clinical, radiologic, and pathologic review. *Radiographics* 2013;33:6:1739-58.
2. Harris GJ, Jakobiec FA. Cavernous hemangioma of the orbit. *J Neurosurg* 1979;51:2:219-28.
3. Smoker WR, Gentry LR, Yee NK, et al. Vascular lesions of the orbit: More than meets the eye. *Radiographics* 2008;28:1:185.
4. Shields JA, Shields CL. Orbital schwannoma. In: Shields JA, Shields CL, eds. *EyeLid, Conjunctival and Orbital Tumors. An Atlas and Textbook*, 3rd ed. Philadelphia: Wolters Kluwer, 2016:552-5.
5. Shields JA, Shields CL, Scartozzi R. Survey of 1264 patients with orbital tumors and simulating lesions: The 2002 Montgomery Lecture, part 1. *Ophthalmology* 2004;111:5:997-1008.
6. Pointdujour-Lim R, Lally SE, Shields JA, et al. Orbital schwannoma: Radiographic and histopathologic correlation in 15 cases. *Ophthalmic Plast Reconstr Surg* 2018;34:2:162-167.
7. Wang Y, Xiao LH. Orbital schwannomas: Findings from magnetic resonance imaging in 62 cases. *Eye (Lond)* 2008;22:8:1034-9.
8. Singh M, Singh U, Zadeng Z, et al. Clinico-radiological spectrum and management of orbital schwannomas: A tertiary care institute study. *Orbit* 2013;32:3:171-77.
9. Gunduz K, Shields CL, Gunalp I, et al. Orbital schwannoma: Correlation of magnetic resonance imaging and pathologic findings. *Graefes Arch Clin Exp Ophthalmol* 2003;241:7:593-597.
10. Goldberg RA, Rootman DB, Nassiri N, et al. Orbital tumors excision without bony marginotomy under local and general anesthesia. *J Ophthalmol [open-access journal]* 2014;2014:424852.
11. Kim MS, Park K, Kim JH, et al. Gamma knife radiosurgery for orbital tumors. *Clin Neurol Neurosurg* 2008;110:10:1003-7.
12. Kapur R, Mafee MF, Lamba R, et al. Orbital schwannoma and neurofibroma: Role of imaging. *Neuroimaging Clin N Am* 2005;15:1:159-74.

# REVIEW | Advertising Index

For advertising opportunities contact:

Michele Barrett (215) 519-1414 or mbarrett@jobson.com  
 James Henne (610) 492-1017 or jhenne@jobson.com  
 Michael Hoster (610) 492-1028 or mhoster@jobson.com

**Alcon Laboratories** 53, 54  
 Phone (800) 451-3937  
 Fax (817) 551-4352

**Allergan** 33  
 Phone (800) 347-4500

**Bausch + Lomb** 10  
 Phone (800) 323-0000  
 Fax (813) 975-7762

**Compulink** 17  
 Phone (800) 456-4522  
[www.compulinkadvantage.com](http://www.compulinkadvantage.com)

**EyePoint Pharmaceutical** 13, 14  
 Phone (617) 926-5000  
 Fax [eyepointpharma.com](http://eyepointpharma.com)

**Icare USA** 5  
 Phone (888) 389-4022  
[www.icare-usa.com](http://www.icare-usa.com)

**Keeler Instruments** 7  
 Phone (800) 523-5620  
 Fax (610) 353-7814

**Lombart Instruments** 43  
 Phone (800) 446-8092  
 Fax (757) 855-1232

**NuSight Medical Operations** 37, 39  
 Phone (833) 468-5437  
[www.NuSightMedical.com](http://www.NuSightMedical.com)

**Omeros** 9  
 Phone (206) 676-5000  
 Fax (206) 676-5005

**Reichert Technologies** 2-3  
 Phone (888) 849-8955  
 Fax (716) 686-4545  
[www.reichert.com](http://www.reichert.com)

**S4OPTIK** 27, 29  
 Phone (888) 224-6012

**Shire Ophthalmics** 67, 68  
[www.shire.com](http://www.shire.com)

**Varitronics** 21  
 Phone (800) 345-1244  
 Fax (610) 356-1222

This advertiser index is published as a convenience and not as part of the advertising contract. Every care will be taken to index correctly. No allowance will be made for errors due to spelling, incorrect page number, or failure to insert.

# REVIEW | Refractive/Cataract Rundown

study suggests that the creation of an additional incision near the original wound in the event of iris prolapse can provide as a secure place for the iris to go, or it can accommodate the phaco tip so that the procedure can continue.<sup>10</sup>

Whatever measure or measures the surgeon employs to prevent and manage IFIS, being forewarned helps set the stage for good outcomes.<sup>11</sup> A 2016 study indicated that a knowledge gap in the practice patterns of urologists when it comes to the ophthalmic risks of BPH medications remains, however.<sup>12</sup> The researchers received 175 responses to a questionnaire emailed to all of the urology residency programs in the United States, and all the members of the Western section of the American Urological Association. Twenty-one percent of respondents never asked patients about their ophthalmic health before initiating BPH treatment; 37 percent would routinely encourage patients with complaints about their vision to consult an ophthalmologist prior to starting BPH treatment; just 13 percent would routinely refer such patients to an ophthalmologist. Residents were significantly less likely to ask BPH patients about visual complaints or refer those with such complaints to an ophthalmologist prior to starting therapy than were fellows and attendings ( $p < 0.01$ ).

“Urologists and urology health-care providers need more education and awareness in the form of CME-type lectures, presentations, publications and inclusion in residency curriculums,” says one of the study’s authors, Sia Daneshmand, MD, associate professor of urology and director of the urologic oncology fellowship program at the USC/Norris Comprehensive Cancer Center. **REVIEW**

*Dr. Silverstein reports no financial ties to the products discussed in this article.*

1. Chang DF, Campbell JR. Intraoperative floppy iris syndrome associated with tamsulosin. *J Cataract Refract Surg* 2005; 31:664-673.
2. Roehrborn CG. Benign prostatic hyperplasia: An overview. *Rev Urol* 2005;7:Suppl 9: S3-S14.
3. Chang DF, Braga-Mele R, Mamalis N et al. ASCRS white paper: Clinical review of intraoperative floppy-iris syndrome. *J Cat Refract Surg* 2008;34:2153-62.
4. Chang DF, Campbell JR, Colin J et al. Prospective masked comparison of intraoperative floppy iris syndrome severity with tamsulosin versus alfuzosin. *Ophthalmol* 2014;121:4:829-34.
5. Lundberg B, Behndig A. Intracameral mydriatics in phacoemulsification cataract surgery. *J Cataract Refract Surg* 2003;29:12:2366-71.
6. Masket S, Belani S. Combined preoperative topical atropine sulfate 1% and intracameral nonpreserved epinephrine hydrochloride 1:4000 [corrected] for management of intraoperative floppy-iris syndrome. *J Cataract Refract Surg* 2007;33:4:580-2.
7. Shugar JK. Use of epinephrine for IFIS prophylaxis. *J Cataract Refract Surg*. 2006;32:7:1074-1075.
8. Gurbaxani A, Packard R. Intracameral phenylephrine to prevent floppy iris syndrome during cataract surgery in patients on tamsulosin. *Eye* 2007;21: 331-332.
9. Silverstein SM, Rana VK, Stephens R, et al. Effect of phenylephrine 1.0%-ketorolac 0.3% injection on tamsulosin-associated intraoperative floppy-iris syndrome. *J Cataract Refract Surg* 2018;44:9:1103-08.
10. Simaraj P, Lekhanont K, Charukamnoetkanok P. Modified surgical technique for managing intraoperative floppy iris syndrome. *Case Rep Ophthalmol Med* 2016; Article ID 1289834. <http://dx.doi.org/10.1155/2016/1289834>.
11. Chang DF, Osher RH, Wang L, Koch DD. A prospective multicenter evaluation of cataract surgery in patients taking tamsulosin (Flomax). *Ophthalmol* 2007;114:9:957-964.
12. Zhang Y, Shamie N, Daneshmand S. Assessment of urologists’ knowledge of intraoperative floppy iris syndrome. *Urology* 2016;97:40-5.



## BRIEF SUMMARY:

Consult the Full Prescribing Information for complete product information.

## INDICATIONS AND USAGE

Xiidra® (lifitegrast ophthalmic solution) 5% is indicated for the treatment of the signs and symptoms of dry eye disease (DED).

## DOSAGE AND ADMINISTRATION

Instill one drop of Xiidra twice daily (approximately 12 hours apart) into each eye using a single-use container. Discard the single-use container immediately after using in each eye. Contact lenses should be removed prior to the administration of Xiidra and may be reinserted 15 minutes following administration.

## CONTRAINDICATIONS

Xiidra is contraindicated in patients with known hypersensitivity to lifitegrast or to any of the other ingredients in the formulation.

## ADVERSE REACTIONS

### Clinical Trials Experience

Because clinical studies are conducted under widely varying conditions, adverse reaction rates observed in clinical studies of a drug cannot be directly compared to rates in the clinical trials of another drug and may not reflect the rates observed in practice. In five clinical studies of dry eye disease conducted with lifitegrast ophthalmic solution, 1401 patients received at least 1 dose of lifitegrast (1287 of which received lifitegrast 5%). The majority of patients (84%) had  $\leq 3$  months of treatment exposure. 170 patients were exposed to lifitegrast for approximately 12 months. The majority of the treated patients were female (77%). The most common adverse reactions reported in 5-25 % of patients were instillation site irritation, dysgeusia and reduced visual acuity. Other adverse reactions reported in 1% to 5% of the patients were blurred vision, conjunctival hyperemia, eye irritation, headache, increased lacrimation, eye discharge, eye discomfort, eye pruritus and sinusitis.

### Postmarketing Experience

The following adverse reactions have been identified during postapproval use of Xiidra. Because these reactions are reported voluntarily from a population of uncertain size, it is not always possible to reliably estimate their frequency or establish a causal relationship to drug exposure.

Rare cases of hypersensitivity, including anaphylactic reaction, bronchospasm, respiratory distress, pharyngeal edema, swollen tongue, and urticaria have been reported. Eye swelling and rash have been reported.

## USE IN SPECIFIC POPULATIONS

### Pregnancy

There are no available data on Xiidra use in pregnant women to inform any drug associated risks. Intravenous (IV) administration of lifitegrast to pregnant rats, from pre-mating through gestation day 17, did not produce teratogenicity at clinically relevant systemic exposures. Intravenous administration of lifitegrast to pregnant rabbits during organogenesis produced an increased incidence of omphalocele at the lowest dose

tested, 3 mg/kg/day (400-fold the human plasma exposure at the recommended human ophthalmic dose [RHOD], based on the area under the curve [AUC] level). Since human systemic exposure to lifitegrast following ocular administration of Xiidra at the RHOD is low, the applicability of animal findings to the risk of Xiidra use in humans during pregnancy is unclear.

### Animal Data

Lifitegrast administered daily by intravenous (IV) injection to rats, from pre-mating through gestation day 17, caused an increase in mean preimplantation loss and an increased incidence of several minor skeletal anomalies at 30 mg /kg /day, representing 5,400-fold the human plasma exposure at the RHOD of Xiidra, based on AUC. No teratogenicity was observed in the rat at 10 mg /kg /day (460-fold the human plasma exposure at the RHOD, based on AUC). In the rabbit, an increased incidence of omphalocele was observed at the lowest dose tested, 3 mg /kg /day (400-fold the human plasma exposure at the RHOD, based on AUC), when administered by IV injection daily from gestation days 7 through 19. A fetal No Observed Adverse Effect Level (NOAEL) was not identified in the rabbit.

### Lactation

There are no data on the presence of lifitegrast in human milk, the effects on the breastfed infant, or the effects on milk production. However, systemic exposure to lifitegrast from ocular administration is low. The developmental and health benefits of breastfeeding should be considered, along with the mother's clinical need for Xiidra and any potential adverse effects on the breastfed child from Xiidra.

### Pediatric Use

Safety and efficacy in pediatric patients below the age of 17 years have not been established.

### Geriatric Use

No overall differences in safety or effectiveness have been observed between elderly and younger adult patients.

## NONCLINICAL TOXICOLOGY

### Carcinogenesis, Mutagenesis, Impairment of Fertility

**Carcinogenesis:** Animal studies have not been conducted to determine the carcinogenic potential of lifitegrast.

**Mutagenesis:** Lifitegrast was not mutagenic in the *in vitro* Ames assay. Lifitegrast was not clastogenic in the *in vivo* mouse micronucleus assay. In an *in vitro* chromosomal aberration assay using mammalian cells (Chinese hamster ovary cells), lifitegrast was positive at the highest concentration tested, without metabolic activation.

**Impairment of fertility:** Lifitegrast administered at intravenous (IV) doses of up to 30 mg/kg/day (5400-fold the human plasma exposure at the recommended human ophthalmic dose (RHOD) of lifitegrast ophthalmic solution, 5%) had no effect on fertility and reproductive performance in male and female treated rats.



Manufactured for: Shire US Inc., 300 Shire Way, Lexington, MA 02421.

For more information, go to [www.Xiidra.com](http://www.Xiidra.com) or call 1-800-828-2088.

Marks designated ® and ™ are owned by Shire or an affiliated company.

©2018 Shire US Inc. SHIRE and the Shire Logo are trademarks or registered trademarks of Shire Pharmaceutical Holdings Ireland Limited or its affiliates.

Patented: please see <https://www.shire.com/legal-notice/product-patents>

Last Modified: 01/2018 533769





Xiidra may provide

# LASTING RELIEF

starting as early as 2 weeks<sup>1</sup>

.....  
**One drop in each eye, twice daily, about 12 hours apart.  
Discard the single-use container immediately after use.<sup>1</sup>**  
.....

## Choose Xiidra first for patients with signs and symptoms of Dry Eye Disease

Xiidra reduced symptoms of eye dryness at 2 weeks in 2 out of 4 studies, and in all 4 studies at 6 and 12 weeks. Xiidra also improved signs of inferior corneal staining at 12 weeks in 3 out of 4 studies.<sup>1</sup>

The safety and efficacy of Xiidra compared to vehicle were studied in 2133 patients in 4 well-controlled, 12-week trials.<sup>1</sup>

.....  
**Check it out at [Xiidra-ECP.com](http://Xiidra-ECP.com)**  
.....

### Indication

Xiidra® (lifitegrast ophthalmic solution) 5% is indicated for the treatment of signs and symptoms of dry eye disease (DED).

### Important Safety Information

Xiidra is contraindicated in patients with known hypersensitivity to lifitegrast or to any of the other ingredients.

In clinical trials, the most common adverse reactions reported in 5-25% of patients were instillation site irritation, dysgeusia and reduced visual acuity. Other adverse reactions reported in 1% to 5% of the patients were blurred vision, conjunctival hyperemia, eye irritation, headache, increased lacrimation, eye discharge, eye discomfort, eye pruritus and sinusitis.

To avoid the potential for eye injury or contamination of the solution, patients should not touch the tip of the single-use container to their eye or to any surface.

Contact lenses should be removed prior to the administration of Xiidra and may be reinserted 15 minutes following administration.

Safety and efficacy in pediatric patients below the age of 17 years have not been established.

For additional safety information, see accompanying Brief Summary of Safety Information on the adjacent page and Full Prescribing Information on [Xiidra-ECP.com](http://Xiidra-ECP.com).

#### Reference:

1. Xiidra [Prescribing Information]. Lexington, MA: Shire US.

©2018 Shire US Inc., Lexington, MA 02421. 1-800-828-2088. All rights reserved. SHIRE and the Shire Logo are trademarks or registered trademarks of Shire Pharmaceutical Holdings Ireland Limited or its affiliates. Marks designated ® and ™ are owned by Shire or an affiliated company. S42270 10/18

