

The Initial Encounter: Taking a History and Recognition of Neuro-Ophthalmic Emergencies

U. Schiefer and H. Wilhelm

Ninety percent of clinical neuro-ophthalmology is in the taking of a history (after W.F. Hoyt). Attentive listening, specific questioning and careful evaluation of the information gained make up the foundation of what is primarily a diagnostic subspecialty. The effort invested in gathering this information saves time and avoids unnecessary, potentially dangerous and/or expensive diagnostic procedures.

History Taking

When possible, the previous records of the patient's care should be reviewed prior to beginning the interview. Usually, if the patient will allow, it helps to include in the conversation those other persons who have come to the visit, such as the patient's spouse or close relatives. These people can often provide information that the patient does not know or cannot remember. Patients are often anxious or fearful, and the physician can put them more at ease by conversing in layperson's terms rather than in the technical jargon used by clinicians.

When caring for children, the history taken from one or both parents should not take too long, as the success of the ensuing examination may be hampered by the impatience of the child. When necessary, one should defer some of the more detailed questioning until after the examination has been completed.

The proposed schema for historical questioning, given in ■ Table 1.1, provides a rough outline of the more common details to be discussed, and those that can be compressed or expanded, depending on the details of the case.

When taking the current ophthalmic history, it is of particular importance to determine as precisely as possible the point in time and the speed with which the initial symptoms presented. The longer it has been since the onset of symptoms and the more slowly they may have developed, the more difficult it will be to obtain this information. One should also obtain an accurate account of the eliciting factors, the temporal relationships, accompanying symptoms, and subsequent course of events. Knowledge of these details will allow a quick initial recognition of the more likely sources and various classes of neuro-ophthalmic disease (■ Fig. 1.1).

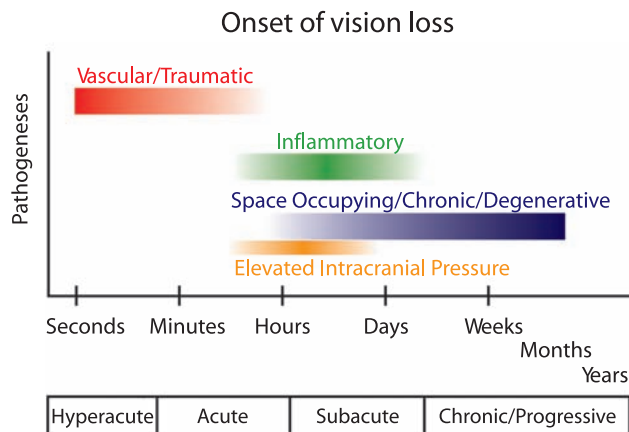


Fig. 1.1. Characteristic onsets and courses of neuro-ophthalmically relevant clinical syndromes

Neuro-Ophthalmic Emergencies

From the very start of history taking, one should be alert for clues to the presence of potentially life-threatening or catastrophically blinding disorders. The disorders in this category are listed in ■ Table 1.2, which also gives corresponding references to the appropriate chapters and sections of this text.

Further Reading

Purvin V, Kawasaki A (2005) Neuro-ophthalmic emergencies for the neurologist. *Neurologist* 11: 195–233

Table 1.1. Catalog of queries to consider when taking a neuro-ophthalmic history

Current ophthalmic history: <ul style="list-style-type: none"> ● Current symptoms: time and date of onset, inciting factors, course since onset ● Symptoms experienced during the encounter ● Associated symptoms of a general (nonvisual) nature ● Management of the problem to date
Comprehensive ophthalmic history (questions appropriate to the time of onset and the patient's age): <ul style="list-style-type: none"> ● For children: Do both eyes see equally well? Does the child have a lazy eye, or has an eye ever been patched for more than a day? ● At what age were glasses first needed, and what visual problem(s) required glasses? ● Since what age have contact lenses been used? Are they hard, semirigid, or soft? ● Has there ever been a problem with eye alignment? ● Has there been any ocular surgery? Eye injuries? Periods of ocular pain and redness? ● Has one or both eyes ever had elevated pressures? Has there been a diagnosis of glaucoma? ● Has there ever been a diagnosis of cataract? ● Is there a congenital color deficiency (for male patients)? ● Have there been other problems: loss of peripheral vision? A disturbance of reading? Photophobia? ● Poor dark adaptation? Problems understanding visual images? ● Ophthalmic medications? Eye drops?
Family history of eye disease? Birth defects? <ul style="list-style-type: none"> ● Have there ever been any severe, inherited eye diseases in the family? ● Very poor vision? Strabismus? Cataract? Retinal detachment? Elevated eye pressures? Glaucoma? Poor color vision? ● Optic atrophy? Blindness? Macular degeneration? Poor reading even with glasses in elderly family members?
General medical history (depending on time of onset and/or the patient's age): <ul style="list-style-type: none"> ● Systemic diseases: Heart? Lungs? Liver? Kidneys? GI tract? Brain? Vascular disease? Tumors? ● Operations? Hospital admissions? Accidents? Injuries? ● Metabolic disorders: high blood sugar? Overactive thyroid gland? High cholesterol? Gout? ● Hypertension? ● Tobacco, alcohol, and/or recreational drug use? ● Allergies? ● Medications? (Particularly important!)
Social history <ul style="list-style-type: none"> ● Level of education completed, occupation ● Marital status/number of children ● Handicapped? Disabled? Receiving social security benefits?

Note that many of the suggestions are redundant, a tactic that improves the likelihood of discovering useful information, even if the patient does not fully understand some of the questions

Table 1.2. Neuro-ophthalmic emergencies and their presenting symptoms

Emergency	Presenting signs and symptoms	Beware of:
Elevated intracranial pressure	<ul style="list-style-type: none"> ● Papilledema (see Chaps. 8 and 12) ● Bilateral sixth nerve palsies (see Chap. 10) ● Acuity initially unaffected – later stages marked by transient visual obscurations ● Parinaud's syndrome (see Chap. 11) ● Headache (increasing in recumbency; see Chap. 16) ● Vomiting while in a fasting state 	<ul style="list-style-type: none"> ● Brainstem compression ● Cardiovascular or respiratory arrest ● Hemorrhagic (retinal) infarcts in venous sinus thrombosis
Malignant hypertension	<ul style="list-style-type: none"> ● Optic disc swelling consistent with papilledema, but accompanied by signs of systemic hypertension: ● "Copper wiring" of arterioles ● Arteriovenous crossing changes ● Branch vessel occlusions ● Hard and soft exudates ● Visual acuity and general health initially unaffected 	<ul style="list-style-type: none"> ● Cerebral infarct ● Myocardial infarct
Carotid dissection	<ul style="list-style-type: none"> ● Acute Horner's syndrome (see Chap. 5) ● Excruciating pain, radiating ipsilaterally into the neck, jaw, and/or ear ● Spontaneous onset (predisposed in Marfan's or the Ehlers-Danlos syndromes) ● After trauma (sports injuries or chiropractic manipulations) 	<ul style="list-style-type: none"> ● Embolic brain infarction
Pituitary apoplexy	<ul style="list-style-type: none"> ● Hemianopic visual field defects (see Chaps. 3, 4, and 12) ● Relative afferent pupillary defect (see Chap. 2) ● Restricted ocular motility ● Trigeminal nerve involvement (nerve V₁₊₂) ● Optic atrophy in advanced stages of visual loss ● In extreme cases, decrease in or loss of consciousness leading to coma 	<ul style="list-style-type: none"> ● Subarachnoid bleeding ● Elevated intracranial pressure that is life threatening or potentially blinding
Cerebral infarct	<ul style="list-style-type: none"> ● Signs of elevated intracranial pressure (see Chaps. 8 and 12) ● Symptoms of hemiplegia or hemiparesis (see Chap. 21) ● Ocular motility disturbances ● Impairment or loss of consciousness 	<ul style="list-style-type: none"> ● Elevated intracranial pressure that is life threatening with loss of vital brain centers for respiration, thermoregulation and/or circulation
Aneurysms	<ul style="list-style-type: none"> ● Acute oculomotor paralysis with pupillary involvement (see Chap. 10) ● Abrupt and excruciating headache ● Nuchal rigidity ● Clouding or loss of consciousness (see Chap. 21) 	<ul style="list-style-type: none"> ● Subarachnoid hemorrhage
Multiple vascular occlusions	<ul style="list-style-type: none"> ● Numerous retinal infarcts (cotton wool exudates) in the setting of a known or suspected endocarditis, paraneoplastic disorder, or vasculitis 	<ul style="list-style-type: none"> ● Cardiac arrest ● Malignancies ● Life-threatening cerebral infarcts
Wernicke's encephalopathy (thiamine deficiency)	<ul style="list-style-type: none"> ● Nystagmus ● Oculomotor deficits ● Impaired consciousness ● Other cranial nerve deficits ● Alcoholic malnutrition ● Parenteral administration of thiamine (vitamin B1) produces a rapid recovery 	<ul style="list-style-type: none"> ● Death by multiorgan failure
Orbital cellulitis	<ul style="list-style-type: none"> ● Painful proptosis exophthalmos (see Chap. 9) ● Restricted ocular motility ● Inflammatory optic neuropathy (see Chaps. 8, 9 and 10) ● Regional and systemic signs of inflammatory disease 	<ul style="list-style-type: none"> ● Septic cavernous sinus thrombosis (particularly dangerous: mucormycosis)
Giant cell arteritis	<ul style="list-style-type: none"> ● Severe anterior ischemic optic neuropathy (AION), see Chap. 8) ● Pain and tenderness in the temples or scalp, aggravated when combing or brushing hair ● Jaw claudication ● Ocular motility deficits (rectus muscle ischemia) ● Erythrocyte sedimentation rate (ESR) and/or C-reactive protein (CRP) markedly elevated ● Anorexia ● Malaise 	<ul style="list-style-type: none"> ● Blindness and/or life-threatening myocardial or cerebral infarction

Table 1.2. (Continued)

Emergency	Presenting signs and symptoms	Beware of:
Whipple's disease	<ul style="list-style-type: none"> ● Rhythmic oculomasticatory movements are a pathognomonic disturbance of ocular motility: rhythmic convergence movements in synchrony with movements of the jaw and pharyngeal musculature ● Cause: bacterial enteritis (<i>Tropheryma Whippelii</i>) ● Clinical scenario: presents as a malabsorption syndrome 	<ul style="list-style-type: none"> ● Disease leads to death, when untreated, but curable with antifungal agent (clotrimazole)
Botulism	<ul style="list-style-type: none"> ● Initially symptoms of a gastroenteritis (nausea, vomiting, constipation) starting 4 days after exposure (eating spoiled food) ● Subsequent bilateral pupillary paresis with reduced light responses and complete paralysis of accommodation (see Chap. 5), eventually developing a complete external ophthalmoplegia ● Further systemic paralysis, including the pharyngeal and respiratory muscles, and xerostomia 	<ul style="list-style-type: none"> ● Death by respiratory failure ● Also wound botulism (puncture wound with deep anaerobic sepsis). Note: The entry wound may have already healed or may have been forgotten, making it difficult to find



Video 1.1

Visual Loss of Uncertain Origin: Diagnostic Strategies

H. Wilhelm, U. Schiefer, and E. Zrenner

The practicing ophthalmologist faces a common challenge on a daily basis: A patient's vision is worse than was expected, based on the appearances of the initial examination. Usually, a renewed and more careful examination explains the discrepancy. Often, however, additional examination finds nothing to explain the conflicting findings. Time is limited, and one is tempted to refer the patient to a neurologist or another ophthalmic service. The diagnostic modalities available at the next site often lead to an unguided attempt at diagnosis when it is felt that some sort of explanation for the visual loss must be found. This scenario can be both expensive and dangerous, subjecting the patient to a random wandering through neurodiagnostic procedures. At the end of this process, the patient is unsatisfied and anxiety ridden and returns to the ophthalmologist or seeks the counsel of other physicians or even alternative medicine practitioners. If the ophthalmologist wishes to find the correct diagnosis by the most efficient means, he/she must analyze the clinical findings carefully before referring the patient, to arrive systematically and rationally at a conclusive, problem-oriented working diagnosis.

Diagnostic Strategy in Schematic Form

● Pearl

An impairment of vision will have its source in one of the following categories: optical, macular, neural, chiasmal, or retrochiasmal visual pathway. There can also be an unrecognized developmental amblyopia, an open attempt at malingering, a functional or psychological disorder, or a simple exaggeration of the problem in an attempt to maximize a secondary gain (■ Fig. 2.1). For each of these categories, there are specific guidelines to the tests that will clarify the nature of the problem.

Ruling Out Optical Causes of Reduced Vision

The first crucial datum is the corrected visual acuity. Problems are evident from the start, however, beginning with determination of the best possible correction. Despite the availability of automated refractometers, an experienced examiner can be led down the wrong path. What is more, there are optical problems that cannot be detected by conventional methods of clinical refraction.

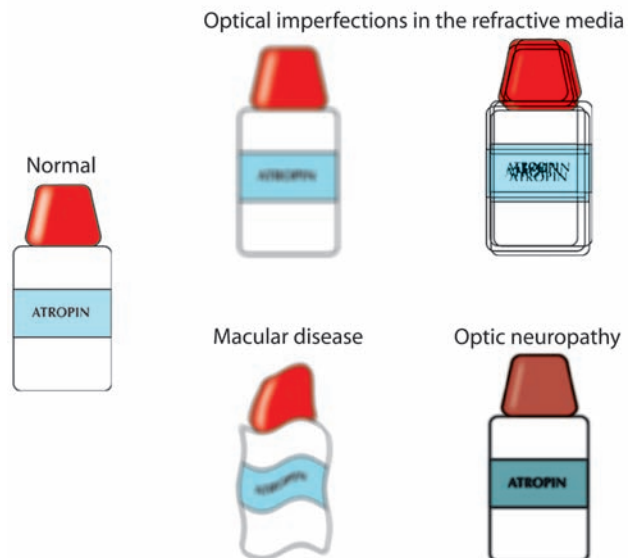
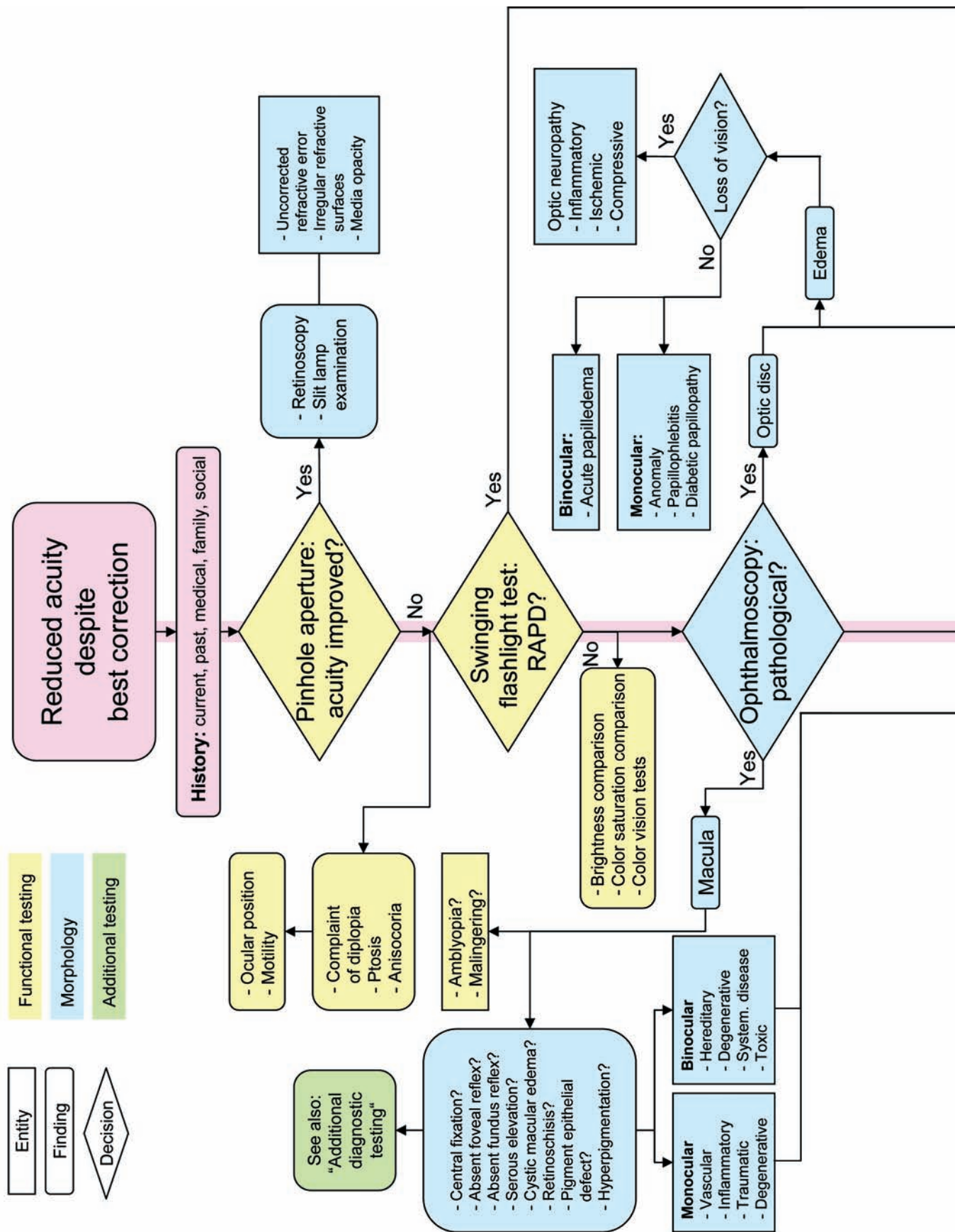


Fig. 2.1. How the patient characterizes his or her visual problem depends on the cause of the impairment. For refractive errors, the eye experiences blurring of images and double or ghosting of contrasting contours. The symptoms of macular disease are dominated by micropsia and metamorphopsia, whereas optic neuropathies more commonly are described as having darker images with poor color perception

Strategies for the Evaluation of Visual Loss of Unknown Cause





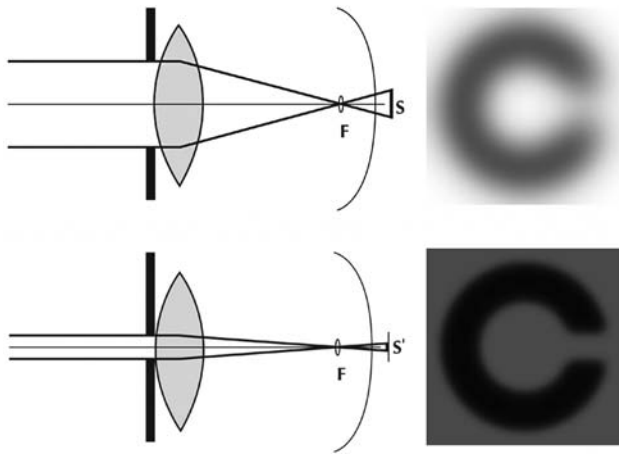


Fig. 2.2. The stenopeic slit minimizes the blur circle and enhances image focus in eyes with refractive errors

Use of the Pinhole Aperture, the Stenopeic Slit, and the Retinoscope

A simple stratagem is to provide the patient with a reduced aperture. The recommended type is a flat disc with several holes of about 1.5 to 2 mm in diameter, allowing the patient to locate the test characters quickly. Use of such reduced aperture devices will yield at least some improvement in spatial acuity in the presence of all possible (nonopaque) optical irregularities. Just as the diaphragm in a photographic camera allows control of the depth-of-field and permits both distant and near objects outside of the plane of focus to appear sharply defined, the artificial pupil serves as a stopped down diaphragm, giving the eye a focused image, despite optical imperfections (■ Fig. 2.2). All optical defects can be neutralized at least to some extent by this method, and not just the refractive ametropias. Irregularities in the corneal tear film, irregular corneal astigmatism (as with keratoconus), faults in the clarity of the lens, early cataract formation, and clouding of the posterior capsule after extracapsular cataract extraction are all frequent causes of unexplained reductions in acuity, which are easily missed or incorrectly dismissed as trivial.

Pearl

If the stenopeic slit or pinhole aperture results in an improvement of Snellen acuity by two lines or more, it is reasonably certain that an optical problem is playing a significant role in the patient's reduced vision.

To be sure, for most patients, improvement in visual acuity with the pinhole aperture is limited by the uncertainty of the method, so that an improvement of less than two lines must be viewed with some caution. Many patients find task of peering through the pinhole aperture difficult and cannot give a reliable response.

Note

For patients with visual disorders that cause photophobia, the light-reducing effect of the small aperture may be the factor responsible for visual improvement. If this is suspected, one should determine whether a neutral density filter has the same effect as the stenopeic aperture. If this is indeed the case, it suggests that the problem may be primarily retinal in origin.

Refractive errors can be verified objectively by retinoscopy. This simple test reveals disturbances of the refractive media very quickly, including subtle irregularities, and sometimes does so more effectively than the use of a slit lamp.

Visual acuity can also be measured objectively with laser interference instruments. However, this method is not always available, and in cases of amblyopia can produce an unrealistic overestimate of the true acuity.

Note

Patients with pituitary adenomas, chiasmal compression, and bitemporal hemianopias usually do not report a sensation like that of wearing horse blinders, because the function of each blind temporal hemifield is taken over by the nasal hemifield of the contralateral eye. Instead, they often report (with some difficulty) an unusual deficit in their vision, variously described as doubling of images or problems with reading. What they are noticing is the loss of all binocular vision. Each hemifield is seen by one eye only, thus removing the sensory basis for binocularity. This completely neutralizes the normal fusional vergence reflex that maintains ocular alignment, producing nasal visual hemifields that variously overlap (in those with esodeviations), separate (in those with exodeviations), or shift vertically (in those with hyperdeviations). This is often referred to as the hemifield slide phenomenon (■ Fig. 2.3a).

Another consequence of a complete bitemporal hemianopia is referred to as postfixational blindness. When both eyes fix on some object of regard, there is a triangular area of blindness, located with its apex at the point of regard and widening beyond that point, hence the term postfixational. This phenomenon results from loss of that portion of the visual field needed to see objects that are directly in the line of sight, but which are positioned beyond the object of regard (■ Fig. 2.3b).

Fig. 2.3. **a** The hemifield slide phenomenon in a case of complete bitemporal hemianopia, and its effect on object perception. **b** The effect of a complete bitemporal hemianopia when fixing on nearby objects: Objects beyond the point of fixation (red) disappear completely

Animation 2.1

When an Optical Disturbance Is Found

If the Snellen acuity can be improved by a reduced aperture device or if there are visible irregularities in the media (often best seen in the reflected light of the fundus reflex through a dilated pupil), there should be a systematic search for any or all of the following causes.

Incorrect Refraction

A repetition of the subjective and objective refractions with pupillary dilation and cycloplegia is necessary. This will occasionally uncover an undetected or an irregular corneal astigmatism.

Corneal Disorders

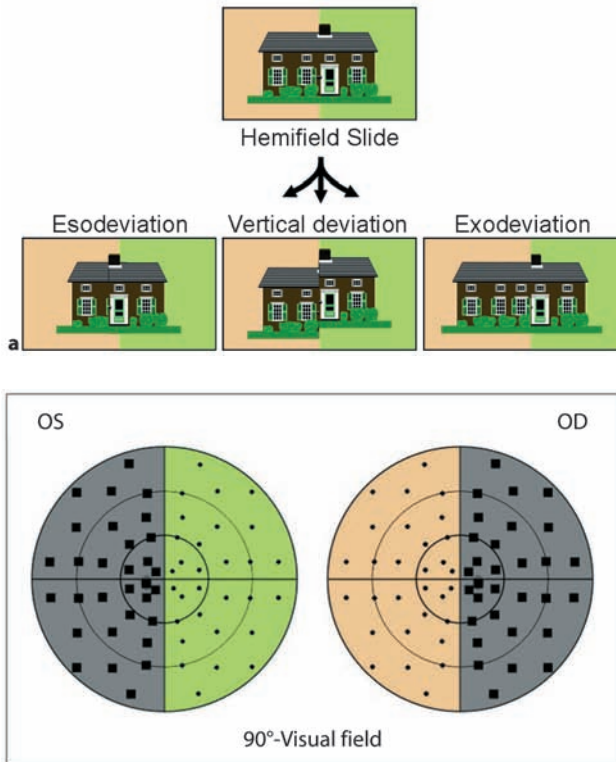
Corneal epithelial disease can cause profound losses of visual acuity. The most common cause of this problem is a defective tear film. Not uncommonly, patients with follicular conjunctivitis are referred to the ophthalmologist. Their symptoms, blurring and ocular pain that is sometimes aggravated by ocular movement, can falsely suggest the possibility of optic neuritis. This mistake can be corrected by everting the upper lid, exposing the (sometimes giant) follicles. In addition, the visual problems caused by marginal blepharitis and/or chalazions are frequently underestimated, though they can produce significant changes in corneal astigmatism with associated reductions in acuity.

Since the corneal surface is the strongest refracting interface of the eye, seemingly insignificant disturbances, such as off-axis corneal scars, dystrophies, or a roughened tear film, will sometimes have a profound effect on the Snellen acuity. Early keratoconus is easy to miss, and it is often first discovered in adults with established histories of unexplained vision problems. Ophthalmometry, retinoscopy, and use of the Placido disc for corneal topography scanning are often necessary to establish the diagnosis. In this instance, a rigid contact lens on the cornea will markedly improve the image clarity and confirm the refractive nature of the poor acuity.

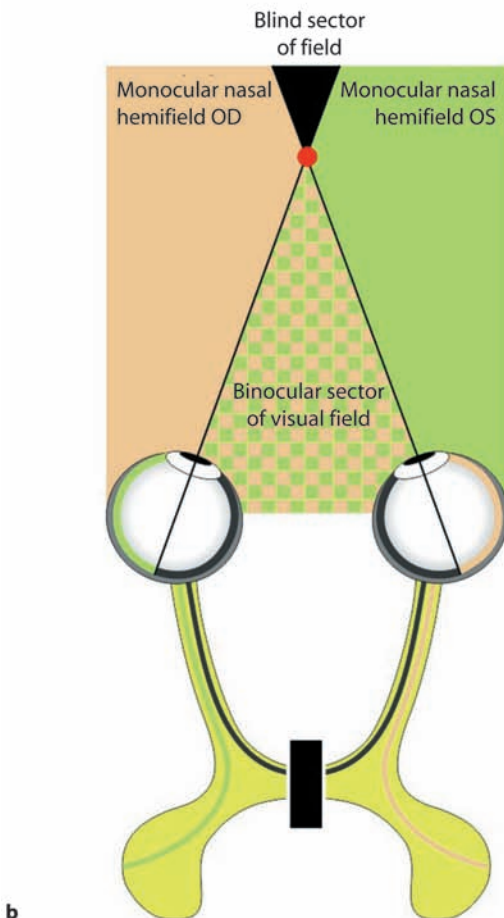
Lenticular Disorders

Cataracts are rarely missed. Nevertheless, subtle loss of lens clarity, early haziness, clefts, posterior subcapsular densities, and irregular refractive interfaces in nuclear sclerotic lenses can be difficult to see at the slit lamp. Occasionally, the problem is discovered only after repeated examinations. A contact lens will not improve the acuity, although a reduced aperture (pinhole disc) usually will. The problems are aggravated by decreasing illumination and/or increasing pupillary size. Rather typical for this problem is the complaint of monocular diplopia, shadowing, or ghost

Animation 2.2



Animation 2.3



images that parallel clearly defined contours of high contrast within images. Occasionally, patients with this problem are referred to the strabismus surgeon when the complaint of diplopia is mistaken for a binocular problem. The ghosting of images caused by faults in lens clarity will invariably improve with the pinhole aperture disc.

Swinging Flashlight Test

If an optical defect has been ruled out, the swinging flashlight test is the next step in defining the nature of the problem. It is used specifically to detect evidence of an (asymmetric) optic neuropathy.

The test is conducted as follows (■ Fig. 2.4). The patient is asked to fixate on a distant object in a dark room. An indirect ophthalmoscope or a halogen bulb flashlight can serve as the light source. One should illuminate the eyes with the light source held below the level of the line of sight, elevated at about a 45° angle (so that the patient can see over and beyond the light source). Initially both eyes are illuminated from two separate distances, during which one should note whether the two pupils are equal in size and whether they respond well to the light (see Chap. 5). If no anisocoria is found and the pupils respond well to the light stimulus, the test can begin.

Using a somewhat dimmer light, one eye is illuminated, and after 2 to 3 s, the light is shifted quickly to the contralateral eye. After another 2 to 3 s, the light is shifted back to the original eye. Since the pupillary responses can vary significantly, the process is repeated four or five times. During this alternation of monocular light stimuli, the following events take place. As the first eye is illuminated, its pupil constricts and stays small until the light is shifted to the contralateral eye. During the transfer, both pupils dilate somewhat. The more slowly one shifts the light, the greater the extent of bilateral dilation. In fact, 2 or 3 s is sufficient time for the level of retinal light adaptation to change: The unstimulated eye dark adapts to a small extent. For this reason, both pupils constrict again when the light arrives at the contralateral eye. The unstimulated eye dark adapts again, and the cycle begins anew. The examiner closely observes the speed and extent of the pupillary constriction in the newly illuminated eye and compares the results seen in each side. If one pupil consistently constricts more weakly than does its partner, the examiner has uncovered manifest evidence of pathology. If the initial constriction is weaker, or if the pupil actually dilates on arrival of the light stimulus (so-called pupillary escape), there is a relative afferent pupillary defect, and the examiner can be certain of an optic neuropathy.

It helps to remember that the crux of the test lies in a comparison of the pupils' consensual responses and their corresponding direct responses. If the consensual response is consistently and clearly better than the direct response, the ipsilateral optic nerve has a relative deficit, whereas if the direct response is consistently and clearly better than the consensual response, the contralateral optic nerve has a relative deficit.

Relative Afferent Pupillary Defect

Definition

If the swinging flashlight test detects an abnormality, one can conclude that there is a **relative afferent pupillary defect (RAPD)**. It is said to be relative, since the defect is always detected by comparison of one eye to the other.

The examiner must observe the patient rather closely during this test, since the pupillary light reactions can vary considerably. When the pupils react sluggishly, a slower transfer will allow better dilation and greater constriction on arrival at the contralateral eye. For briskly reactive pupils, on the other hand, a quicker transfer of the stimulus is more helpful. In addition, the brightness of the light and its distance from the eye can affect the extent of constriction. With a too strong (or bright) stimulus a subtle RAPD might be overlooked because the pupillary sphincter will always reach its maximally constricted size independent from the state of the afferent system.

Note

The test is simple, but care must be taken to avoid the following sources of error:

- Variations in the distance and angle of illumination (of one eye relative to the other)
- Variations in the time spent observing one eye, relative to the other
- A stimulus that is either too bright or too dim
- Changes in the patient's fixation or accommodation during the test

The test cannot be used validly if one or both pupils do not react to light, or if there is a significant anisocoria. However, since both pupils normally react synchronously, it is usually enough to focus attention on the better reacting pupil while comparing its direct to its consensual light reactions. To allow observation of the pupils in the darkened examination room, the examiner can illuminate the eye(s) tangentially from one side in a plane that is parallel to that of the pupil. Using a separate light source, one can then

Video 2.1

Video 2.2

Video 2.3

Video 2.4

Video 2.5

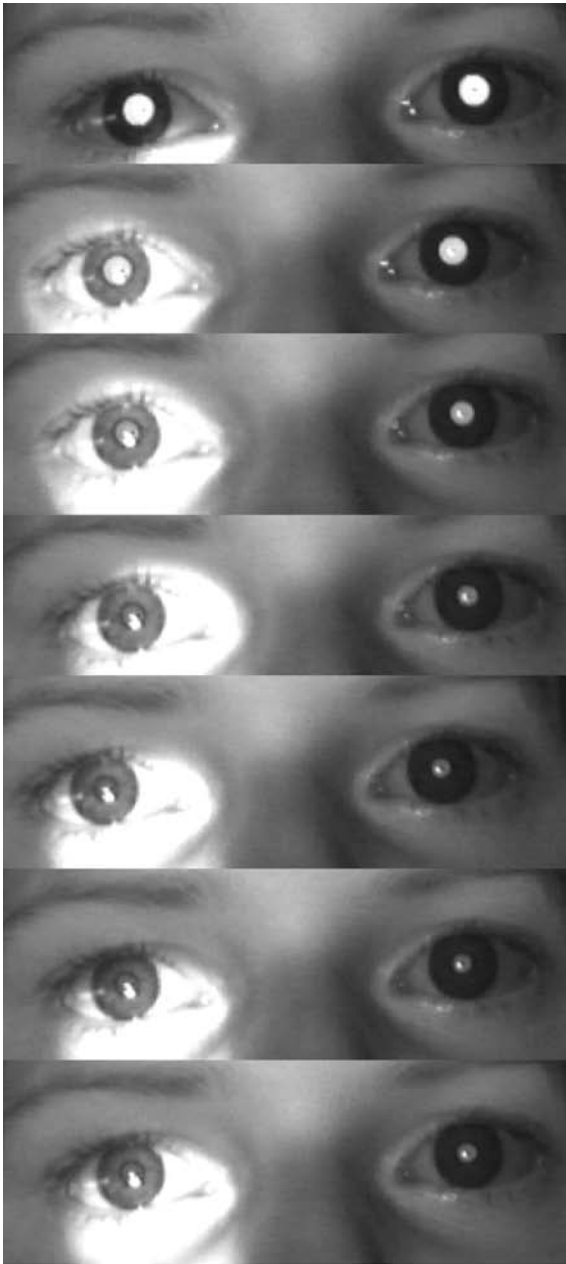
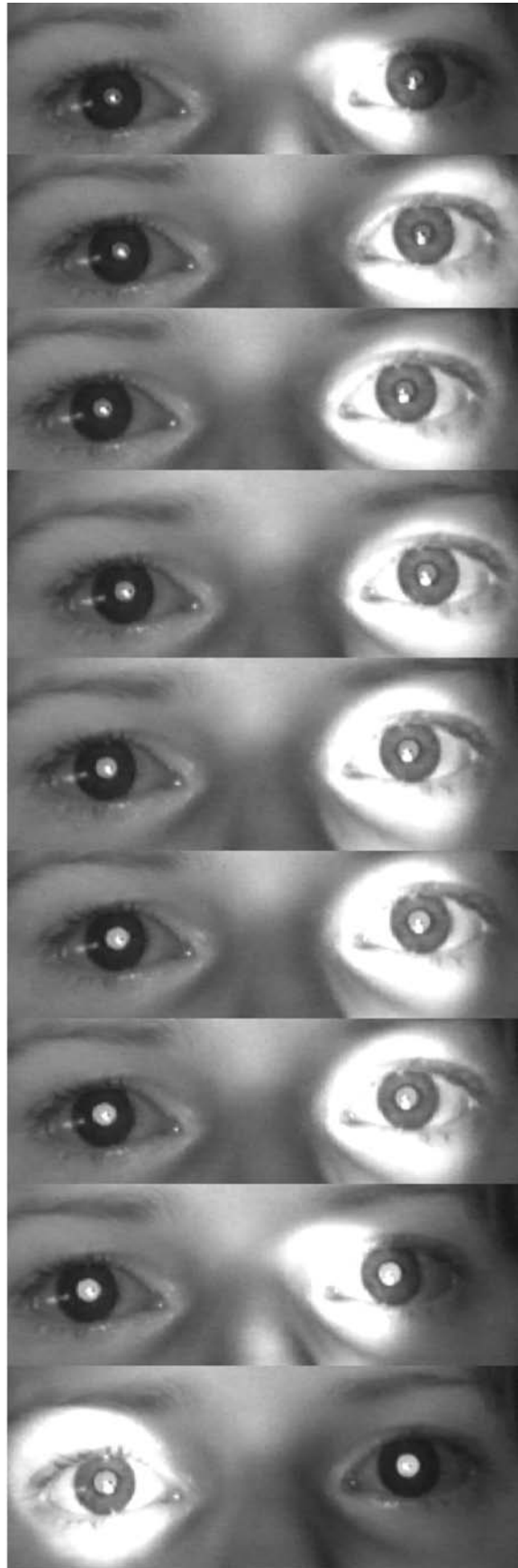


Fig. 2.4. The sequence of events during the swinging flashlight test. The individual photos were taken at intervals of 0.25 s. They show that the right pupil constricts visibly at about 1 s, after the onset of illumination. When the light is transferred to the contralateral eye, both pupils transiently dilate to a small degree, and this dilation even continues after the light has arrived at the contralateral eye. A relative afferent pupillary defect is demonstrated in the left eye. This pattern of movement is considerably easier to see in real time than it is when studying photographic sequences like the one shown here



perform the alternating test. If the direct response is better than the consensual, there is a relative afferent pupillary defect in the contralateral eye, whereas if the consensual response is better than the direct, the defect is in the ipsilateral eye.

If both pupils react very poorly to light, the test cannot be used.

● Pearl

If one is not certain whether there is an RAPD, it helps to repeat the swinging flashlight test with the use of neutral density filters. A weak filter with 30 to 40% absorption is held before one eye or the other while carrying out several repetitions of the test. If there is no RAPD, the artificially created afferent defect will be present in the eye with the filter in place, and will migrate to the opposite eye when the filter is transferred. This use of a filter sometimes fails to clarify the problem, but if there really is an RAPD, it will be significantly enhanced when the filter is held before the affected eye.

When examining infants or small children, the test can be done with the use of a direct ophthalmoscope. The examiner observes the fundus reflex from a distance of arm's length or greater, where the child is more likely to feel less threatened.

The presence of an RAPD cannot rule out the presence of an optic neuropathy in the contralateral eye. It is possible (and not uncommon with some diseases) for there to be bilateral optic nerve damage that is simply greater in one eye than in the other. Conversely, if both optic nerves are damaged to the same extent (no matter how severe it might be), there will be no detectable RAPD.

The crucial importance of the swinging flashlight test is apparent when one considers the many disorders in which an RAPD can develop (■ Table 2.1).

! Note

A disturbance of the optical media, including acuity reduction to the level of light perception, can (almost) never cause an RAPD in the affected eye. This surprising fact is explained by the scattering of light in eyes with cloudy media, causing indirect stimulation of the foveal macula, which has high pupillomotor sensitivity. If the lens of the eye is clear, the stimulus light will fall largely on the less sensitive portions of the peripheral visual field, illuminating the interior of the eye diffusely but after significant absorption of the light by the pigment epithelium of the retina and the melanocytes of the choroid. It is even possible for an eye with a clouding of the media to have a stronger pupillary light reac-

Table 2.1. The relative afferent pupillary defect (RAPD) and the differential diagnosis of the sign

The source of the visual loss	An RAPD is found . . . :
Optical defect in the refractive media of the eye	Never (with the sole exception of a very dense vitreal hemorrhage)
Macular disease	Only when the visual damage is strongly asymmetrical and very severe
Unilateral optic neuropathy	Always
Bilateral optic neuropathy	Only when asymmetrical
Chiasmal disease	Frequently
Optic tract disease	Nearly always (contralateral to the affected tract); remember that the contralateral temporal hemifield is larger than the ipsilateral nasal field
Retrogeniculate disease	Sometimes (contralateral to the affected side, and usually in developmental anomalies of a cerebral hemisphere associated with trans-synaptic degeneration at the lateral geniculate body)
Amblyopia	Rare (usually subtle defects that are most often associated with unilateral optic nerve or macular hypoplasia)
Psychogenic unilateral visual loss	Never
Marked anisocoria	Minor (on the side with the smaller pupil)
Uncovering of the eye (bandage, lid)	Transient (contralateral, caused by differing levels of dark adaptation that quickly equilibrate)

tion. A monocular or asymmetric optic neuropathy, on the other hand, will always produce an RAPD as a result.

● Pearl

Using neutral density filters or varying transmission, one can quantify an RAPD by weakening the light stimulus as it is presented to the better eye. The density of a filter that neutralizes the RAPD provides a measure of the deficit. The filters found to be useful for this method are separated in 0.3-log unit steps from 0.3 to about 2.0 log units. The strength of an RAPD correlates with the extent of visual field loss, when comparing one eye to the other, especially when the cause is a compression of the optic nerve.

When no filters are available, one can substitute a variation in the distance between stimulus and eye: Doubling the distance weakens the stimulus by about 0.6 log units. One can occasionally encounter unusual instances of a subtle RAPD in a healthy eye, but never one as large as 0.6 log units. Quantification of an RAPD is important in three specific situations:

1. As an additional objective measure of the course of optic neuropathies, especially when perimetry is not usable
2. When amblyopia is suspected as the cause of a visual deficit, an RAPD of 0.6 log units or more is very unusual and must initiate a critical reappraisal of the diagnosis. (An RAPD can be found in an amblyopic eye that has an identifiable developmental hypoplasia of the retina and/or optic nerve.)
3. In eyes with a central retinal vein occlusion, an RAPD of 0.9 log units or more is a reliable sign of the ischemic form of the disease, and alerts the physician to the risk of neovascularization

Brightness and Color Comparison Tests

The information obtained with the objective swinging flashlight test can be expanded with subjective tests. Thus, an eye with an optic neuropathy will see a light as less bright than will its unaffected, contralateral partner. Colors are, by similar comparison, seen as faded (desaturated) or darker than in the healthy eye. This test is easily done with the use of a small, colored object that is shown to one eye and then to the other (the red cap from a mydriatic bottle suffices). Patients with macular diseases see a light as brighter and colors – at least initially – as normal. The most important symptoms of macular disease are metamorphopsia and micropsia.

! Note

Color and brightness comparisons are subjective tests. The results are not always precise, and false positive responses are not uncommon. Very observant patients can accurately identify small differences in color or luminance perception caused by differing levels of retinal light adaptation. The uneven illumination of a desk lamp will commonly produce a higher level of light adaptation in the eye closer to the light, while the contralateral eye lies in the shade cast by the nose. While they are helpful as confirmation tests, these subjective comparisons are not at all as valuable as the swinging flashlight test, and cannot be substituted for the objective form of testing.

When a Relative Afferent Pupillary Defect Is Demonstrable

If the swinging flashlight test clearly demonstrates the presence of an RAPD, the next step in clinical analysis of the vision loss is testing of the visual field. The first priority is detection of an optic neuropathy, or an asymmetric chiasmal or optic tract lesion. For this purpose, perimetry is necessary. A detailed account of this testing can be found in Chaps. 4 and 8.

When no relative afferent pupillary defect is demonstrable, a bilateral, symmetrical optic neuropathy, a lesion of the chiasm, or a retrochiasmal lesion must be ruled out. Perimetry helps in this case also.

Perimetry

Perimetry is the primary testing modality for the detection of chiasmal and retrochiasmal disorders. The goal is to define the shape and extent of the visual field loss, which in turn provides decisive clues to the kind and location of responsible lesions (see Chaps. 3 and 4). Neuro-ophthalmology is not primarily concerned with measuring an index of the visual field's collective sensitivity or with statistical analysis for differentiating localized from more general forms of visual field loss. Rather, it is primarily concerned with the configuration or spatial pattern of the visual damage.

Perimetry is so important to neuro-ophthalmology that a separate chapter in this book has been devoted to the subject (Chap. 4). It determines not only whether diagnostic imaging is needed, but actually provides focally diagnostic clues and can help the radiologist by providing an indication of where the disease is most likely to be found. When perimetry and the appearance of the optic disc do not clarify the source of the problem, it is most likely that a maculopathy is at fault.

Search for a Macular Disorder

There are retinal disorders that produce a change neither in the ophthalmoscopic nor in the biomicroscopic appearance of the retina that would indicate the presence of a disease. In addition, many significant fundus signs can be very subtle. Most frequently, macular edema is overlooked. Its characteristic symptom is not so frequently metamorphopsia, but rather micropsia (■ Fig. 2.5). This is so typical that an observant patient could provide the decisive diagnostic clue in a telephone conversation. Haploscopic image separation by polarizing or colored filters is helpful, and even

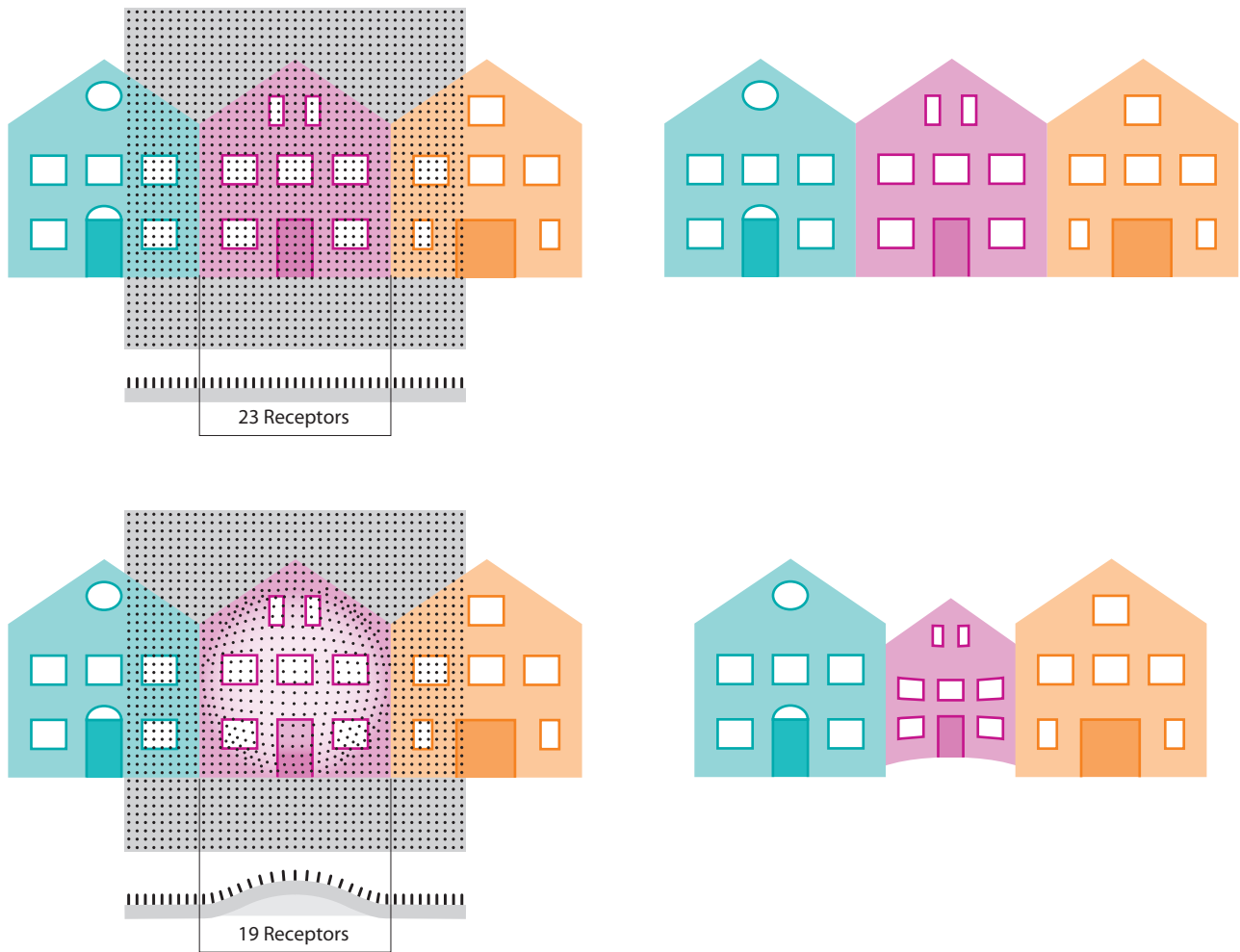


Fig. 2.5. The basis of micropsia in cases of macular edema: The photoreceptors are spread from one another, and the retinal image falls on a smaller group of receptors

simple alternating cover/uncover testing is sufficient. The diagnosis can be established objectively by optical coherence tomography (OCT) or by fluorescein angiography. Macular edema also produces a characteristic change in the visual field, allowing one to confirm the diagnosis even when the ophthalmoscopic appearance is hidden, e.g., by a small, rigid pupillary aperture. In this situation, one needs to use threshold static perimetry, which will demonstrate the presence of a relative central scotoma.

There are a number of disorders of the photoreceptors, the pigment epithelium, or the retinal neuronal circuitry in which the damage to vision is much more severe than one would expect based on the fundus appearance alone. In particular, hereditary and toxic disorders easily elude diagnostic detection. A well-done history taking is usually decisive. Photophobia and hue discrimination deficits suggest a problem with cone function, poor scotopic vision with rod function. One should note also that the problems of

nyctalopia must be specifically asked about. The statement “My night vision is very bad” is much too sweeping and is often spontaneously offered. As a rule, patients are only describing an awareness of physiological changes in vision with nocturnal dark adaptation. In other cases, there is poor refraction or dry eye, which, when combined with a large pupil, results in a blurred retinal image.

● Pearl

The patient with true nyctalopia, when asked “How easy is it for you to go for a walk outside on a moonless night?” will often reply “I would need to have someone lead me.”

Instruments like the mesoptometer and nyctometer test mesopic vision, i.e., a combined function of both rods and cones. These devices are not suited to the proper testing for evidence of nyctalopia. Patients with retinitis

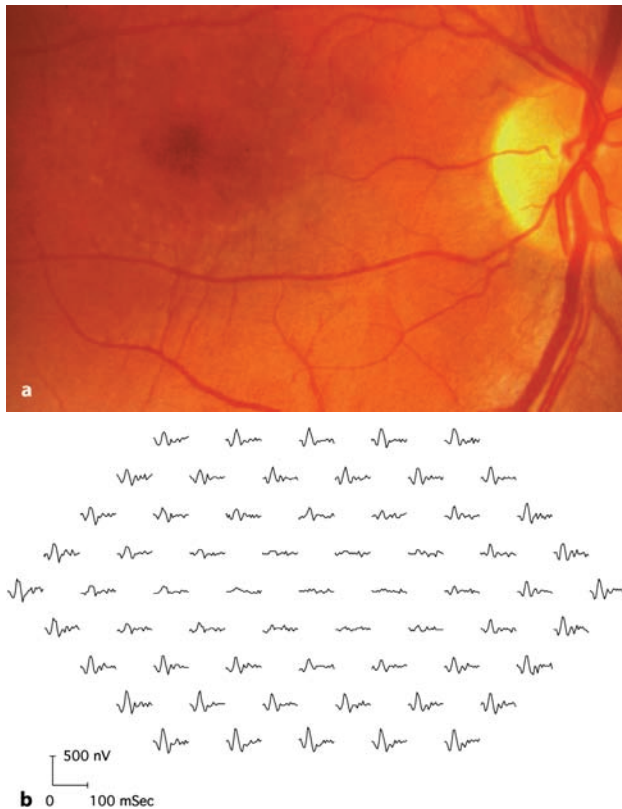


Fig. 2.6. **a** Stargardt's disease. The fundus is initially completely normal in appearance. **b** Multifocal electroretinogram (ERG) study shows the central defect. In this method, a local ERG is calculated for each retinal locus (see Chap. 7). In this manner, an electrophysiological campimetry of the central visual field is produced. In the study illustrated here, covering the central 30° of the visual field, normal ERG responses are seen in the peripheral loci of the examination, whereas in the center of the field they are either strongly reduced or completely lost

pigmentosa and pronounced nyctalopia can respond well when tested with these instruments. Conversely, uncorrected myopia can cause severe problems with vision at twilight, even when dark adaptation testing indicates normal function.

Further diagnostic testing for macular disease usually depends on the examiner's initial suspicion. In cases of cone disease, color discrimination tests help (see Chap. 6) to narrow the search more closely or even allow a confident diagnosis. If there is a disease of rods, on the other hand, dark adaptation testing is more helpful. A Ganzfeld electroretinogram (ERG) is likely to be helpful in both instances, since it includes both scotopic and photopic test conditions, providing objective and independent measures of rod and cone function (see Chap. 7). Still, there must be widespread damage to receptors to produce a clearly abnormal ERG. Local defects in foveal cones, such as in Stargardt's disease, can cause a substantial reduction without

affecting the Ganzfeld ERG. This problem has recently been solved with the use of the multifocal ERG, which when used with Sutter's m-sequence technique has revolutionized clinical electrophysiology of the retina (■ Fig. 2.6; see Chap. 7). With this method, one can produce a map of electroretinographic responses in which very small central or paracentral lesions are revealed. Testing for Stargardt's disease is a perfect example.

Recommended tests of color vision are the desaturated panel D-15 test and the use of anomaloscopy. The Ishihara plates are more suited to the screening for hereditary red-green dyschromatopsias. Anomaloscopes are not widely available, but are in use at a number of university medical centers and schools of optometry in North America. In addition to the diagnosis of classical dyschromatopsias, this instrument can demonstrate so-called scotopization, which is typical for Stargardt's disease as well as for hereditary familial achromatopsia.

In the differential diagnosis of retinal disorders, one should keep in mind that nearly all hereditary and toxic retinopathies are bilateral and are usually symmetrical. Fluorescein angiography, electrophysiology, family pedigrees with familial testing, and additional evaluation by an occupational medicine service, when indicated, can all contribute to a confident identification of the correct diagnosis of primary retinal disorders. Electrooculography (EOG) testing is of value specifically for diseases of the retinal pigment epithelium, e.g., for Best's vitelliform degeneration.

A steadily increasing portion of hereditary diseases that affect vision can be detected with the methods of molecular genetics (see Chap. 18).

When diagnosing macular disease, one encounters a number of limitations (■ Table 2.2). Choroidal ischemia, smaller retinal infarcts, and incompletely expressed forms of a variety of disorders (as well as by carriers of recessive traits) create many obstacles for the diagnostician. An example is those patients with modestly reduced acuity, a blond fundus, and a granular appearance to the macular pigmentation. Transillumination shows incomplete pigmentation of the iris, and all such patients have had nearly white hair during childhood. This is the typical clinical presentation of an abortive form of ocular albinism in which the usually associated nystagmus is absent.

For most of these disorders, there are no effective treatments, but arriving at a correct diagnosis is nonetheless important, since this will allow for a clear indication of the prognosis for future visual function, which in turn permits planning of social aspects of life, educational opportunities, and rehabilitation services. Finally yet importantly, the physician must be able to confidently differentiate between primary retinopathies and optic neuropathies.

Table 2.2. Examples of easily missed retinal disorders

Disorder	Decisive tests
Macular edema of various sources	Fluorescence angiography, perimetry, optical coherence tomography (OCT)
Early stage of Stargardt's disease	Multifocal electroretinogram (mf ERG)
Juvenile retinoschisis	ERG, family history of ocular disorders
Ocular albinism	Iris signs, VEP (asymmetric decussation at the optic chiasm)
Cone dystrophy	Ganzfeld ERG
Achromatopsia	Ganzfeld ERG
Retinitis pigmentosa sine pigmento	Ganzfeld ERG and molecular genetic tests where indicated
Toxic retinopathies	Ganzfeld ERG/electrooculogram (EOG)
Choroidal infarction	Multifocal ERG (mfERG)/indocyanine green angiography
Carcinoma or melanoma-associated retinopathy	Ganzfeld ERG
Unusual macular disorders, such as pattern dystrophy, acute zonal occult outer retinopathy (AZOOR)	If indicated, mfERG

● Pearl

Micropsia suggests macular edema; color tests and dark adaptation testing help with identifying primary retinal disorders. With anomaloscopy, one can buttress the validity of a diagnosis of Stargardt's disease or hereditary familial achromatopsia. The ERG is the court of final appeal for atypical cases of primary retinal diseases, but also fails to detect focal lesions, for which the multifocal ERG is needed. Family history, occupational history, and queries with regard to exposure to toxic substances are all important. Genetic analysis permits the early identification of a number of hereditary disorders of vision, and the EOG helps to identify primary pigment epithelial diseases.

Diagnosing Amblyopia

The diagnosis of amblyopia requires that there is no optic atrophy or maculopathy and there is no high-grade RAPD (defined as 0.6 log units when measured by neutral density filters). Typically, the patient will report that the vision in the eye has been poor since early childhood. Frequently,

Table 2.3. Amblyopia

Pros	Cons
"That eye has always had poor vision"	Good stereoacuity
Patching of an eye during childhood	RAPD
Monocular strabismus	Alternating fixation
Significant anisometropia	Difference of less than 2 D
High hyperopia	Hyperopia of less than 3 D
High astigmatism	Astigmatism of less than 2 D
Crowding phenomenon	Dominant eye poorer
Eccentric fixation	Steady central fixation
Ammann test: no further deterioration of acuity when viewing the chart through a neutral density filter (an amblyopic eye behaves as if it is already dark-adapted)	Pathological Ammann test, i.e., there is further deterioration of acuity when viewing the chart through a neutral density filter

D Diopters

the patient with an injury or an episode of inflammatory activity plausibly associates the cause of the poor vision. In all likelihood, the event was only a cause for drawing attention to the eye and discovery of its poor acuity. Not uncommonly, the history given by the patient and the patient's family can be useless. Some patients even forget that they have had strabismus surgery. Patient questioning and verification of the information (when possible) is needed.

! Note

If the Lang stereotest finds evidence of good stereopsis, one can rule out strabismic amblyopia and/or microstrabismus (even though occasional exceptions are found). Bilateral amblyopia must have a convincing cause: very high hyperopia, high corneal astigmatism, ocular malformations. A myopic eye (or the more myopic of a pair) only rarely develops a refractive amblyopia if the refractive error is not extreme. A dominant eye cannot be amblyopic relative to its nondominant partner (■ Table 2.3).

Further options for diagnosis of an amblyopia include the Ammann test, tests of the crowding phenomenon, and acuity when reading. In the Ammann test, there will be no further reduction in acuity when a neutral density filter is held before the amblyopic eye – the amblyopic eye behaves as if it were already dark-adapted. The crowding phenomenon compares legibility of single characters as opposed to rows of characters. The mode of fixation can (but should not) show evidence of eccentric fixation. A profound or

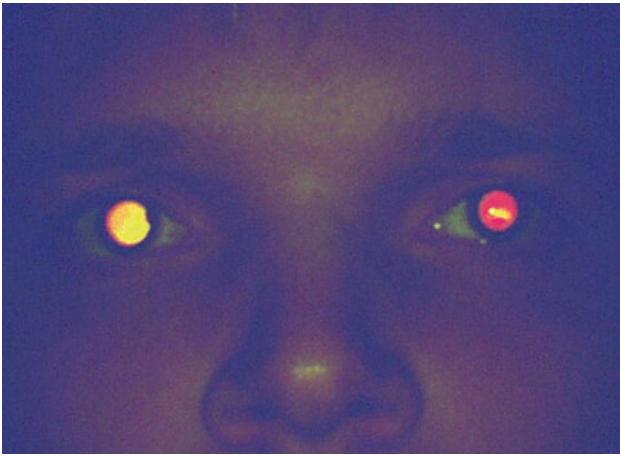


Fig. 2.7. The Brückner test: An interocular difference in the fundus reflexes is seen, signaling the presence of a problem. The possible sources include strabismic malalignment, a defect in the refractive media, or an interocular difference in fundus color (e.g., with high axial myopia or a fundus coloboma)

absolute central scotoma would exclude amblyopia as the principal cause of visual impairment, and would more commonly be the cause of eccentric fixation.

A quick and very helpful test of strabismic diagnosis is the Brückner test, in which one compares the fundus reflexes from both eyes (■ Fig. 2.7). The nonfixing, strabismic eye will have a brighter fundus reflex than its partner. However, a secondary strabismus because of damage to the visual system will also yield a positive Brückner test.

In short, one must use a number of measures for the diagnosis of amblyopia when the history is not clear.

● Pearl

There is no reliable test to prove or exclude amblyopia. There are, however, numerous tests whose results can make the possibility of amblyopia so improbable that one cannot consider amblyopia as a plausible source of an unexplained visual deficit. The examiner should never be satisfied with a single test, and in cases of doubt should be very reluctant to accept amblyopia as a cause.

Malingering

Simulation of visual loss plays a significant role among the patients attending any ophthalmic clinic, and is probably undetected in a number of cases. A separate chapter has been devoted to this subject (see Chap. 15).

Conclusion

The strategy outlined here should allow the examiner to classify quickly the source of the problem. No single method is certain to be effective. Any objective test can be conducted or interpreted incorrectly. Simply the combination of several different tests and proper attention to the logical context of the case help to ward off a mistaken diagnosis. Of course, a carefully taken history and a thorough ophthalmologic examination are necessary for correct interpretation of the patient's problem. Not uncommonly, successful analysis of visual loss of an uncertain nature will require the cooperation of several specialty fields. Nonetheless, the ophthalmologist must take part from the very start in the full spectrum of diagnostic studies needed to make a correct diagnosis.

Further Reading

- Hayreh SS, Klugman MR, Beri M, Kimura AE, Podhajsky P (1990) Differentiation of ischemic from non-ischemic central retinal vein occlusion during the early acute phase. *Graefes Arch Clin Exp Ophthalmol* 228: 201–217
- Kretschmann U, Seeliger MW, Ruether K, Usui T, Apfelstedt-Sylla E, Zrenner E (1998) Multifocal electroretinography in patients with Stargardt's macular dystrophy. *Br J Ophthalmol* 82: 267–275
- Levatin P (1959) Pupillary escape in disease of the retina or optic nerve. *Arch Ophthalmol* 62: 768
- Sutter EE, Tran D (1992) The field topography of ERG components in man. I. The photopic luminance response. *Vision Res* 32: 443–446
- Zrenner E (1998) Dysfunktion von Zapfen und Stäbchen. In: Huber A, Kömpf D (eds) *Klinische Neuroophthalmologie*. Thieme, Stuttgart, pp 239–244
- Zrenner E, Wilhelm H, Schiefer U (1993) Differentialdiagnostische Strategien bei unklaren Sehstörungen. *Ophthalmologe* 90: 104–119