
The Newborn Physical Examination

Assessment of a Newborn

with Joan Richardson

Joan Richardson's Assessment of a Newborn

What follows is a demonstration of the physical examination of a newborn baby as well as the determination of the gestational age of the baby using the Dubowitz examination.

Dubowitz examination

From L.M. Dubowitz et al, Clinical assessment of gestational age in the newborn infant. Journal of Pediatrics 77-1, 1970, with permission

Skin Color

When examining a newborn baby, start by closely observing the baby. Observe the color. Is the baby pink or cyanotic?

The best place to observe is the lips or tongue. If those are nice and pink then baby does not have cyanosis. The most unreliable places to observe for cyanosis are the fingers and toes because babies frequently have poor blood circulation to the extremities and this results in acrocyanosis. (See video below of baby with cyanotic feet)

Also observe the baby for any obvious congenital malformations or any obvious congenital anomalies. Be sure to count the number of fingers and toes.

Cyanotic Feet

The most unreliable places to observe for cyanosis are the fingers and toes because babies frequently have poor blood circulation to the extremities and this results in a condition called acrocyanosis.

Definitions you need to know:

Cyanotic

a bluish or purplish discoloration (as of skin) due to deficient oxygenation of the blood

acrocyanosis

Blueness or pallor of extremities, normal sign of vasomotor instability characterized by color change limited to the peripheral circulation. Occurs in healthy newborns and will eventually resolve.

congenital

1. Existing at or dating from birth
2. Acquired during development in the uterus and not through heredity

Respiration

Watch the baby breathe. Is the baby breathing easily or is she having problems. Time the respiratory rate. Normal babies breathe about 40 to 60 times a minute. Does the baby have intercostal, subcostal or sternal retraction? Is the baby demonstrating an expiratory grunting respiration, stridor or gasping.

Definitions you need to know:

grunting

forced expiration against a partially closed glottis

stridor

a harsh vibrating sound heard during respiration in cases of obstruction of the air passages.

gasping

slow and laborious breaths

Movement

Look at the baby's movement. Is the baby moving all extremities equally and symmetrically? And does the baby appear to have good muscle tone? If the baby is asleep, does the baby easily arouse, wake up, and cry when disturbed?

Generally, babies will start crying when disturbed, so start the examination by looking at those areas that are more easily examined if the baby remains quiet. Start by examining the heart, lungs and abdomen. Save the examination of the head and neck until last because that tends to irritate the baby and cause them to cry more

Cardiovascular - PMI

Start with the examination of the heart. Palpate the PMI that is the point of maximal impulse. The PMI should be at about the 3rd or 4th intercostal space at about the midclavicular line. If the PMI is shifted dramatically either to the right or to the left, you must be concerned about a pneumothorax. If the PMI is shifted remarkably to the right, then you have to consider the possibility of dextrocardia.

Cardiovascular - Pulses

Palpate the pulses. The pulses should be equal and of good intensity. Start by palpating the axillary pulse, then the brachial pulse, and then the radial pulse. Then move down to the palpate the femoral pulses and then the dorsalis pedis and the posterior tibial pulses.

Definitions you need to know:

axillary pulse

The part of the main artery of the arm that lies in the axilla and that is continuous with the subclavian artery

brachial pulse

Chief artery of the upper arm that is a direct continuation of the axillary artery and divides into the radial and ulnar arteries just below the elbow.

radial pulse

The smaller of the two branches into which the brachial artery divides just below the bend of the elbow and which passes along the radial side of the forearm to the wrist then winds backward around the outer side of the carpus and enters the palm between the first and second metacarpal bones to form the deep palmar arch.

femoral pulse

The chief artery of the thigh that lies in the anterior part of the thigh and is undivided until a point about two inches (5 centimeters) below the inguinal ligament where it divides into a large deep branch and a smaller superficial branch.

dorsalis pedis

An artery of the upper surface of the foot that is a direct continuation of the anterior tibial artery.

posterior tibial pulse

An artery located just posterior to the medial malleolus.

Cardiovascular - Auscultation

Auscultate the heart. Concentrate on evaluating four key elements. First, determine the heart rate (normal heart rate for newborn is about 140 beats per minute.) Then determine if heartbeat is of normal rhythm. Third, listen for the 2nd heart sound and make sure that it is split. A split second sound indicates the presence of two valves, aortic and pulmonic. The aortic valve closes slightly before the pulmonic valve, resulting in a biphasic, or split second sound. Murmurs - fourth, listen carefully for heart murmurs. About 25% of all babies have murmurs at the time they are delivered. These usually go away in the first few hours of life. Most of the murmurs are systolic ejection type murmurs. It's very rare to hear a diastolic murmur in a newborn baby.

Definitions you need to know:

systolic ejection

Murmur occurring after contraction of heart while the cavities are falling with blood

diastolic

Murmur occurring after contraction of heart while the cavities are filling with blood

Lungs

Once you have auscultated the heart, then listen to the lungs. Compare each side of the chest with the other side. Try to determine whether the breath sounds are of normal quality and are equal in intensity as you compare one side of the chest with the other.

Umbilicus

Once the chest has been examined, begin your examination of the abdomen. Start by looking at the umbilical cord. Determine that there are two arteries and one vein. The umbilical arteries are generally small white muscular structures that look like small worms. The umbilical vein is generally larger, less muscular and more patulous.

Abdomen

Palpate the liver and the spleen. The technique that I use is to start low in the abdomen and gradually move upward until you feel the edge of the liver, and the edge of the spleen. In palpating, be sure to use the tips of your fingers. They are much more sensitive. Normally, the liver is about 1-2 cms below the right costal margin. You can sometimes feel a spleen tip in a newborn but most of the time the spleen is not palpable. A very important part of the abdominal examination is the examination of the kidney. The kidneys are generally about 2 finger breadths in length. They lie very close to the midline. The method of examining the kidneys uses a bimanual palpation method. One hand is placed behind the baby's back, the other hand is placed on the abdomen next to the umbilicus. Then, press down, palpating the kidney between the two hands.

Definitions you need to know:

costal margin

edge of the last rib

Female Genitalia

Next examine the genitalia. In female babies, there is often a hymenal skin tag. The labia majora generally cover the labia minora. Often there are vaginal secretions present which are secondary to maternal hormonal stimulation.

Male Genitalia

In male babies, examine the penis. The foreskin is never easily retracted in the newborn male. Generally the penis is around 2 to 2-1/2 cms in length. Palpate the testes in the scrotum to make sure they are descended and palpable bilaterally. It is not uncommon to find hydrocoeles bilaterally.

Definitions you need to know:

hydrocoeles

an accumulation of serous fluid in a sacculated cavity (as the scrotum)

Hips

For examination of the hips, use a modified ortolani maneuver to check for laxity of ligaments or for hip dislocation. In the newborn, the femoral head fits into the acetabular fossa. If the hip is dislocated, it is generally dislocated posteriorly. Therefore when the hips are abducted, the femoral head slides into the acetabular fossa. This causes a click or a crunch and represents the sound of cartilage sliding over cartilage. This can either be felt with the fingers or sometimes even heard. In order to examine for dislocated hips, place the baby in the supine position. Position your hands such that your first two fingers overlie the hip joint. Place the thumbs on the medial side of the baby's thigh. Then abduct the hips slowly, feeling for any click, crunch, or clunk or any resistance to abduction.

Definitions you need to know:

Ortolani maneuver

Abducting the flexed hips while the examiner pushes upward on the posterior proximal femur.

Back

Check the baby's back for midline defects and check for sacral dimple.

Head and Neck

Now move on to examination of the head and neck. Palpate the clavicles to make sure there are no clavicular fractures. Palpate the neck and the thyroid gland. Examine the ears to make sure the ear canals are patent. It's not necessary to do an otoscopic examination on the newborn at the time of birth. Examine the nares to make sure they are patent. Examine the mouth to make sure there is no cleft palate and the baby has a good suck. Examine the anterior fontanelle, and the posterior fontanelle. Run your fingers over the sagittal suture, the coronal sutures and the lambdoid sutures to make sure they are not prematurely synostosed.

Definitions you need to know:

sagittal

the deeply serrated articulation between the two parietal bones in the median plane of the top of the head

coronal

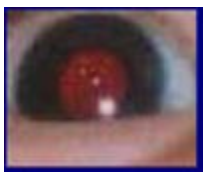a suture extending across the skull between the parietal and frontal bones called also frontoparietal suture

lambdoid

a suture extending across the skull between the parietal and frontal lobes

Eyes

This generally requires someone to help open the eyes using q-tips. Sometimes you can get the eyes to open just by turning out the lights. You may see small sub conjunctival hemorrhages. Look for the red reflex bilaterally. This is the reflection of the light coming off the retina. Sometimes the reflex is orange or gray. If not present, this could mean that the baby has a cataract or a retinal tumor.



Red Reflex

Neurological

Check the neurological exam including the Moro Reflex. Assess the baby's tone. Check for ankle clonus. Check the baby's reflexes. Determine whether the baby responds normally and has good tone.

Definitions you need to know:

Moro Reflex

The startle reflex, baby flings hands out and appears startled.

Dubowitz Exam

At this point perform a [Dubowitz Examination](#). This is the method used at our institution to determine the baby's gestational age. This examination evaluates both physical characteristics and neurological characteristics and in the aggregate, estimates the baby's gestational age within 1-2 weeks of the true gestational age.

External Criteria

Start by examining the baby's physical criteria. The first external sign is edema. Palpate the anterior tibia. If there is no edema, then mark that appropriate score on the Dubowitz examination sheet. Check for skin texture, and then check for skin color. Also check for skin opacity looking for blood vessels and how distinctly they are seen over the abdomen. Look at the baby's back to determine how much lanugo is present. Check the plantar creases. Evaluate nipple formation, breast size, ear formation and ear firmness and examine the genitalia. In this baby, the labia majora essentially completely cover the labia minora.

This is the method used at our institution to determine the baby's gestational age. This examination evaluates both physical characteristics and neurological characteristics and in the aggregate, estimates the baby's gestational age within 1-2 weeks of the true gestational age.

External (superficial) Criteria						Neurological Criteria						
External Sign	Score					Neurological Sign	Score					
	0	1	2	3	4		0	1	2	3	4	5
Oedema	No oedema	Swelling of feet and lower legs	Swelling of feet and lower legs and hands	Swelling of feet and lower legs, hands and face	Swelling of feet and lower legs, hands and face and chest	Recoil						
Skin Texture	Very fine granular	Normal smooth	Small granules or coarse hairs or scattered pebbles	High granules, scaly, cracked, scaling and peeling, dry, brittle, scaly	Edematous, pale, mottled, cyanotic, dusky	Square Window						
Skin Colour (distal extremities)	Pink and	Yellowish skin	Pale pink, mottled, cyanotic	Pink, dry, peeling, scaly, brittle, cyanotic		Ankle Dorsi Flexion						
Skin Quality (arms)	Maroon, red, and purple, blue, yellow, green, brown, black	Red and pink, normal	A few large macules, dusky, cyanotic, oedematous	A few large macules, dusky, cyanotic, oedematous	Healed, normal skin	Arm Recoil						
Lanugo (over body)	Normal	None	Hair thinning especially over lower body	Short, woolly hair on arms and legs	Abnormal or absent	Leg Recoil						
Thyroid Gland	Normal	Small, normal	Enlarged, nodular, or cystic	Enlarged, nodular, or cystic, with calcification		Popliteal Angle						
Nipple Formation	None	Small, normal	Small, normal, slightly enlarged	Small, normal, slightly enlarged, with calcification		Heel to Ear						
Chest Size	Normal	Small	Small, narrow	Small, narrow, with calcification		Scarf Sign						
Ear Form	Normal	Small	Small, narrow	Small, narrow, with calcification		Head Lag						
Ear Pinna	Normal	Small	Small, narrow	Small, narrow, with calcification		Vomiting Suspension						
Genital Nails	Normal	Small	Small, narrow	Small, narrow, with calcification								
Testes (with age adjusted)	Normal	Small	Small, narrow	Small, narrow, with calcification								

From L.M. Dubowitz et al. Clinical assessment of gestational age in the newborn infant, Journal of Pediatrics 77:1, 1970 with permission.

Neurological Criteria

Now assess the neurological criteria. Using the stick figures that are on the Dubowitz form, determine which posture most appropriately characterizes this baby. Check for the square window that is the angle that the hand makes with the wrist. Check for ankle dorsiflexion that is the angle that the foot makes with the ankle. The baby who is mature has more flexion and their tone is increased compared to a premature baby. Check for arm recoil, leg recoil, check the popliteal angle. This is done by placing the baby on the back, flexing at the hips and then extending at the knee until you meet resistance. Check for heel to ear. This is done by again placing the baby on his back and pulling the leg towards the ear to determine how closely the heel can come to the ear. Check the scarf sign. This checks the

resistance the baby has in terms of moving the arm across the chest. Check for head lag and then also for ventral suspension.

Posture

Observe with infant quiet and in supine position. Score 0 - arms and legs extended, 1 - beginning of flexion of hips and knees, 2 - stronger flexion of legs, arms extended, 3 - arms slightly flexed, legs flexed and abducted, 4 - full flexion of arms and legs

Square window

The hand is flexed on the forearm between the thumb and index finger of the examiner. Enough pressure is applied to get as full a flexion as possible, and the angle between the hypothenar eminence and the ventral aspect of the forearm is measured and graded according to diagram. [Care is taken not to rotate the infant's wrist while doing this maneuver.]

Ankle dorsiflexion

The foot is dorsiflexed onto the anterior aspect of the leg, with the examiner's thumb on the sole of foot and other fingers behind the leg. Enough pressure is applied to get as full flexion as possible, and the angle between the dorsum of the foot and the anterior aspect of the leg is measured.

Arm recoil

With the infant in the supine position, the forearms are first flexed for 5 seconds, then fully extended by pulling on the hands and then released. The sign is fully positive if the arms return briskly to full flexion (Score 2). If the arms return to incomplete flexion or the response is sluggish, it is graded as Score 1. If they remain extended or are only followed by random movements, the Score is 0.

Leg recoil

With the infant supine, the hips and knees are fully flexed for 5 seconds, then extended by traction on the feet, and released. A maximal response is one of full flexion of the hips and knees (Score 2). A partial flexion scores 1, and minimal or no movement score 0.

Popliteal angle

With the infant supine and his pelvis flat on the examining couch, the thigh is held in the knee-chest position by the examiner's left index finger and thumb supporting the knee. The leg is then extended by gentle pressure from the examiner's right index finger behind the ankle and the popliteal angle is measured.

Heel to ear

With the baby supine, draw the baby's foot as near to the head as it will go with forcing. Observe the distance between the foot and the head as well as the degree of extension at the knee. Grade according to diagram. Note that the knee is left free and may draw down along side the abdomen.

Scarf sign

With the baby supine, take the infant's hand and try to put it around the neck and as far posteriorly as possible around the opposite shoulder. Assist this maneuver by lifting the elbow across the body. See how far the elbow will go across the grade according to the illustrations. Score 0 - Elbow reaches axillary line 1 - Elbow between midline and opposite axillary, 2 - Elbow reaches midline, 3 - Elbow will not reach midline.

Head lag

With the baby lying supine, grasp the hands (or the arms if a very small infant) and pull him slowly towards the sitting position. Observe the position of the head in relation to the trunk and grade accordingly. In a small infant, the head may initially be supported by one hand. Score 0 - Complete lag, 1 - Partial head control, 2 - Able to maintain head in line with body, 3 - Brings head anterior to body.

Ventral suspension

Close

The infant is suspended in the prone position, with examiner's hand under the infant's chest (one hand in a small infant, two in a large infant). Observe the degree of extension of the back and the amount of flexion of the arms and legs. Also note the relation of the head to the trunk. Grade according to diagrams.

Record the Data

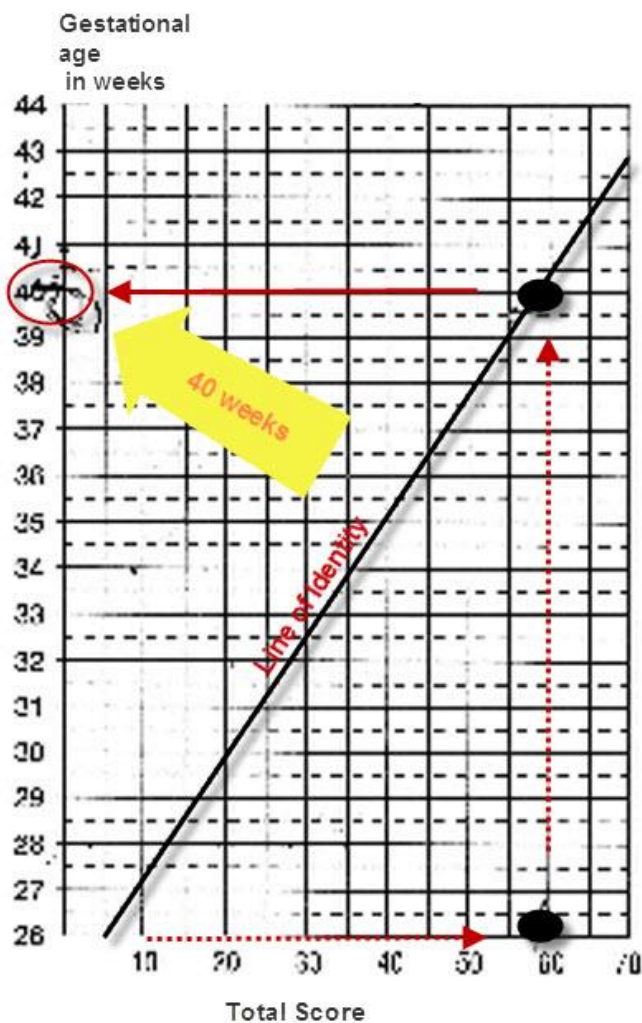
After each of these examinations, record the data on the Dubowitz form, add it up and then turn the form over to use the graph for reading the gestational age from the total score, the total score for the physical examination and the neurological examination, when plotted on the graph determine the baby's gestational age.

External (superficial) Criteria					Neurological Criteria						
External Sign	Score				Neurological Sign	Score					
	0	1	2	3	4	0	1	2	3	4	5
Oedema	Discrete oedema on feet and hands only	The oedema extends up to the knees and the ankles	No oedema			Reflexes					
Soft Tissues	Very little palpable	Trace of oedema	Small oedema of face and feet or oedema of palms of hands	Large oedema of face and feet, oedema of palms of hands, oedema of feet	Extensive oedema of face and feet	Skylark Winkles					
Soft Cornua (Bulging of eye)	None	Minimally	Palpable	Protruding	Protruding with redness	Arise Dorci Reflex					
Skin Quality (Jaundice)	Normal	Yellow	Absent	Absent	Normal	Arm Flexion					
Umbilical (over edge)	Normal	Retracted	Flattened	Swollen	Abnormal	Leg Flexion					
Plantar Creases	Normal	Retracted	Flattened	Swollen	Abnormal	Foot/heel Angle					
Nipple Formation	Normal	Retracted	Flattened	Swollen	Abnormal	Heel to Ear					
Chest Size	Normal	Retracted	Flattened	Swollen	Abnormal	Ear Form					
Ear Form	Normal	Retracted	Flattened	Swollen	Abnormal	Ear Firmness					
Ear Firmness	Normal	Retracted	Flattened	Swollen	Abnormal	Head Lag					
Genital Male	Normal	Retracted	Flattened	Swollen	Abnormal	Ventral Suspension					
Testes (with hip not abducted)	Normal	Retracted	Flattened	Swollen	Abnormal						

Final Score

Score	
External Criteria	33
Neurological Criteria	25
Total Dubowitz Score	58 which is <i>40 weeks gestation</i>

Graph for reading gestational age from total score



Head Circumference

*We examine the head **last** because this generally upsets the baby.*

Complete the physical examination by measuring the head circumference, chest circumference, and length. The head circumference should be measured by determining the largest occipito-frontal circumference. Measure the circumference until you obtain a reproducible measurement.

The head circumference is 34.5 centimeters

Chest Size

Measure the chest circumference. This is done by measuring at the level of the nipples. The chest circumference and the head circumference should be within one to two centimeters of each other.

The chest circumference is 32.25 centimeters

Length

Then measure the baby's length. This is crown to heel length.

The length is 52 centimeters

[CDC growth charts and/or data tables](#)
