

The posterior Monteggia lesion with associated ulnohumeral instability

E. J. Strauss,
N. C. Tejwani,
C. F. Preston,
K. A. Egol

From the New York
University Hospital
for Joint Diseases,
New York, New
York, USA

The type II Monteggia (posterior) lesion is a rare injury which is sometimes associated with ulnohumeral instability. We have reviewed 23 of 28 patients with this injury. A clinical and radiographic assessment was undertaken at follow-up. Functional outcome scores, including the Broberg and Morrey Index and the Disabilities of the Arm, Shoulder or Hand (DASH), were used. The results from the six patients with associated posterior ulnohumeral dislocation were compared with 17 without ulnohumeral injury. Those with dislocation had reduced movement of the elbow and had outcome scores indicative of greater disability compared to those without associated dislocation.

More than 90% of dislocations of the elbow in adults are posterior or posterolateral.¹⁻⁴ Because of the extensive ligamentous and soft-tissue support of the ulnohumeral joint, considerable force is required for dislocation to occur.^{2,5,6} Consequently, 10% to 15% of these injuries are complicated by associated fractures which may include a Monteggia lesion of the forearm, which may be defined as a fracture of the proximal ulna, accompanied by dislocation of the proximal radioulnar joint.⁷⁻¹⁰ Bado⁷ classified this lesion into four types according to the direction of displacement of the head of the radius and the angulation at the site of fracture of the ulna. He also described variant forms of the Monteggia lesion, the

most common of which includes fracture of the head or neck of the radius.^{1,7}

We describe the mechanism of injury, treatment and functional outcome of six patients with type II Monteggia lesions associated with posterior ulnohumeral dislocation (Fig. 1). This rare, high-energy injury is a complex variation of the posterior Monteggia lesion seldom described in the orthopaedic literature.¹ We have compared this pattern of injury to Monteggia variants without associated ulnohumeral dislocation and have hypothesised that the functional outcome of such injuries with accompanying ulnohumeral dislocation will be no different than those without dislocation.

■ E. J. Strauss, MD, Resident
■ N. C. Tejwani, MD,
Associate Professor
■ C. F. Preston, MD, Resident
■ K. A. Egol, MD, Assistant
Professor, Chief of
Orthopaedic Trauma Service
Department of Orthopaedic
Surgery
NYU-Hospital for Joint
Diseases, 301 E 17th Street,
New York, NY 10003, USA.

Correspondence should be
sent to Dr K. A. Egol; e-mail:
kenneth.egol@med.nyu.edu

©2006 British Editorial
Society of Bone and
Joint Surgery
doi:10.1302/0301-620X.88B1.
16704 \$2.00

J Bone Joint Surg [Br]
2006;88-B:84-9.
Received 3 May 2005;
Accepted after revision
7 September 2005

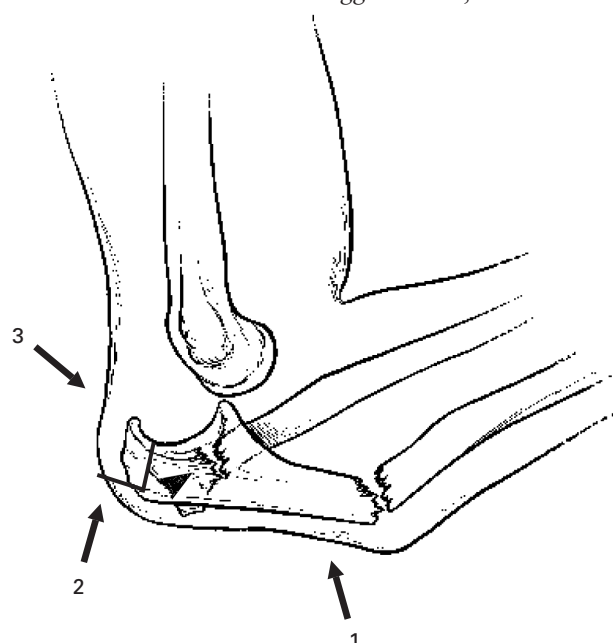


Fig. 1

Diagram of a type II Monteggia lesion with associated posterior ulnohumeral dislocation. Schematic illustration demonstrating 1, the proximal fracture of the ulna with posterior angulation; 2, posterior dislocation of the proximal radioulnar joint and fracture of the neck or head of the radius and 3, the posterior ulnohumeral dislocation accompanying the injury.

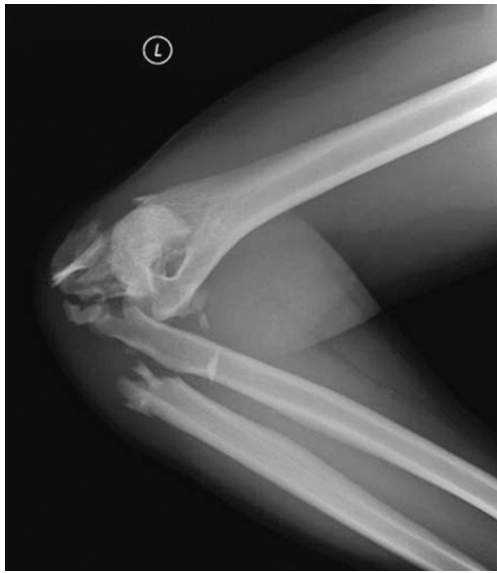

Fig. 2a

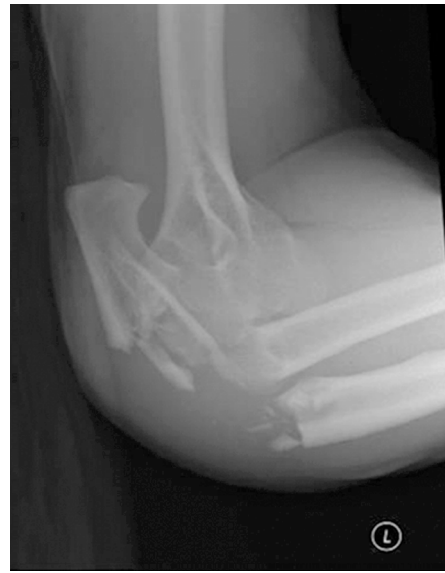

Fig. 2b

Type II Monteggia lesion with associated posterior ulnohumeral dislocation. Radiographs of the elbow showing posterior dislocation in association with a short oblique fracture of the proximal ulnar diaphysis (Jupiter 2C¹⁴) and concomitant posterolateral dislocation of the proximal radioulnar joint a) anteroposterior and b) lateral views.

Patient and Methods

We examined the trauma database and operative log at our institution in order to review retrospectively the management of 70 patients who presented with a Monteggia fracture between July 1997 and June 2003. We defined a Monteggia lesion as a fracture of the proximal ulna distal to the end of the olecranon process with an associated dislocation of the radiocapitellar joint. The medical records and radiographs of all the patients were reviewed; 28 had a type II (posterior) Monteggia injury with an associated fracture of the head or neck of the radius. Of these, 23 were available for follow-up and all gave informed consent to participate in the investigation. Six had an accompanying posterior ulnohumeral dislocation at the time of injury (Figs 1 and 2). Demographic information, details of the injury and the operation notes were extracted from the records. The 23 patients were contacted and returned for interview, examination and assessment of the outcome, including measurement of the range of movement using a hand goniometer, of the grip strength using a torque dynamometer and radiographic evaluation.

Functional outcome scores were calculated using the Disabilities of the Arm, Shoulder or Hand (DASH) Questionnaire¹¹ and according to the functional rating index of Broberg and Morrey.¹² The scores from the DASH questionnaire were converted to standardised symptom scores on a scale of 0 to 100.^{11,13} High scores on the DASH assessment are an indication of a high level of disability of the upper limb.¹¹ The Broberg-Morrey functional index scores were rated as excellent (95 to 100 points), fair (60 to 79) and poor (< 59).^{5,12,14}

The radiographs were examined for the presence of union of the fracture, congruency of the ulnohumeral and radio-capitellar joints and for signs of degenerative arthritis (Fig. 3). This was graded according to the system of Broberg and Morrey where a normal elbow is grade 0; an elbow with slight narrowing of the joint-space with minimum osteophyte formation is grade 1; an elbow with moderate narrowing of the joint space and moderate osteophyte formation is grade 2 and an elbow with severe degenerative changes and gross destruction of the joint is grade 3.^{6,12}

The functional outcome scores of the six patients who sustained ulnohumeral dislocation at the time of the injury were compared to those of the 17 in which dislocation did not occur. The data were calculated as the mean and standard deviation and the groups were compared using the unpaired Student's *t*-test. Statistical significance was set at $p < 0.05$.

Results

There were four men and two women with a mean age of 47 years (23 to 87) in the group with ulnohumeral dislocation. The dominant upper limb was injured in three cases. The mechanism of injury was a fall from a height in four, a fall from a motorised scooter in one and a motor vehicle accident in the other. Three presented as open injuries (Table I). According to the sub-classification of Jupiter et al,¹⁴ there was one type B, three type C and two type D injuries. The initial treatment of fractures of the ulna was with small fragment plates (Accumed, Portland, Oregon, Synthes, Paoli, Pennsylvania and Zimmer, Warsaw, Indiana) in all patients. The fragments of the coronoid fractures

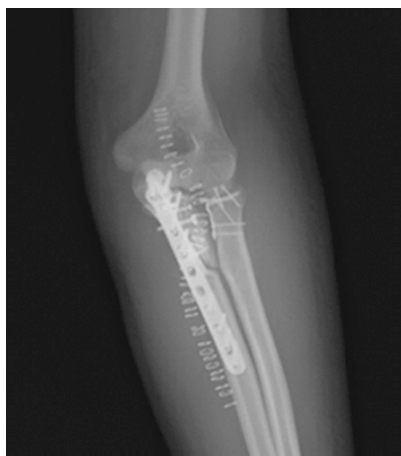

Fig. 3a

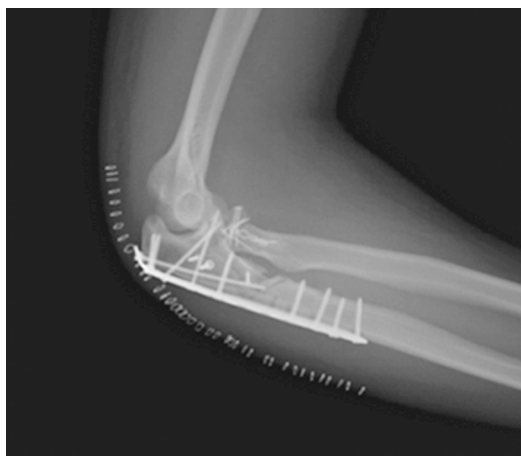

Fig. 3b

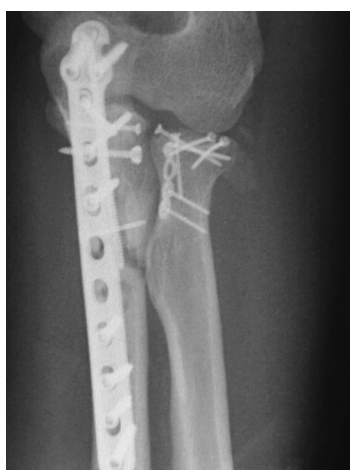

Fig. 3c

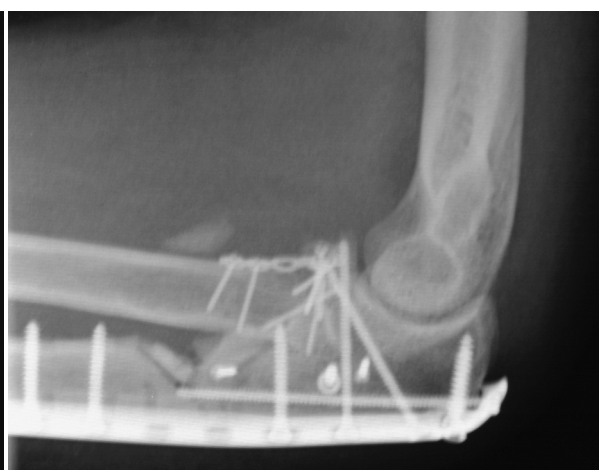

Fig. 3d

Radiographs of the elbow showing operative fixation of the type II Monteggia lesion with associated ulno-humeral dislocation a) anteroposterior and b) lateral views. A 12-hole periarticular plate was utilised for fixation of the fracture of the proximal ulna. The accompanying fracture of the head of the radius was treated with a mini-T plate. Figures 3c and 3d – Evidence of established nonunion of the ulna is seen after nine months with bending of the plate.

Table I. Details of the type II Monteggia fractures with associated posterior ulnohumeral dislocation

Case	Gender/ age (yrs)*	Dominance†	Side of injury	Mechanism	Classifications				Ulnar fixation‡	Radial head fixation	Re-operation
					Bado ⁷	Jupiter ¹⁴	Mason ¹⁶	Regan and Morrey ¹⁵			
1	M/42	R	R	Fall off scooter	2	2C	2	1	7-Hole LC-DCP	Interfrag screws	No
2 [§]	M/42	R	R	Fall three stories	2	2C	3	1	3.5-Recon	Implant	Yes¶
3 [§]	F/55	R	L	Fall from height	2	2D	3	3	3.5-Recon DCP w/ 100-mm screw	Implant	Yes**
4	M/23	R	R	Fall off ladder	2	2C	3	3	8-Hole DCP w/ 100-mm screw	Implant	No
5	F/87	R	L	Motor vehicle accident	2	2B	1	1	3.5 recon	Mini T-plate	No
6 [§]	M/32	R	L	Fall from height	2	2D	2	1	12-Hole DCP	Mini T-plate	Yes**

* F, female; M, male

† L, left; R, right

‡ DCP, dynamic compression plate; LC, limited contact dynamic compression plate; Recon, Reconstruction plate

§ open injury

¶ external fixator removal

** bone grafting secondary to nonunion of the ulna fracture

Table II. Post-operative results in type II Monteggia fractures with associated posterior ulnohumeral dislocation

Case	Flexion (°)	Extension (°)	Pronation (°)	Supination (°)	Instability	DASH* standardised symptom score ¹¹	Broberg-Morrey functional index ¹²
1	130	20	70	70	No	0	99
2	140	45	10	0	No	40	81
3	110	10	50	60	No	80	31
4	100	30	60	90	No	60	48
5	110	30	50	50	No	13.3	85
6	135	15	60	60	No	10.8	99

* DASH, disabilities of the arm, shoulder or hand

Table III. Post-operative results in type II Monteggia fractures without associated posterior ulnohumeral dislocation

Case	Flexion (°)	Extension (°)	Pronation (°)	Supination (°)	Instability	DASH* standardised symptom score ¹¹	Broberg-Morrey functional index ¹²
1	130	0	60	70	No	70	32.5
2	130	20	50	50	No	11	75
3	140	0	70	90	No	35	100
4	140	0	70	90	No	10	89
5	115	0	45	50	No	54	69
6	130	0	70	70	No	20	73
7	140	0	70	90	No	3	100
8	115	10	50	50	No	0	61
9	140	0	70	90	No	9	100
10	140	0	70	90	No	43	83
11	90	0	50	50	No	34	83
12	140	0	70	70	No	18	100
13	130	0	45	60	No	5	100
14	100	0	45	60	No	41	92
15	120	20	45	45	No	25	69
16	120	10	70	30	No	11	77
17	140	0	70	90	No	5	100

* DASH, disabilities of the arm, shoulder or hand

were repaired in step-wise fashion and incorporated into the fixation. According to the classification of Regan and Morrey¹⁵ the fractures of the coronoid process included four type I fractures which required no separate operative fixation and two type III fractures, one of which was treated with a lag screw through the plate and the other stabilised with a polydioxanone suture. Sub-classification of the associated fractures of the head and neck of the radius according to Mason,¹⁶ showed one class 1, two class 2 and three class 3 injuries. The initial treatment of these fractures included fixation using mini-fragment plates (Synthes) in three cases and replacement of the head of the radius with an uncemented monoblock prosthesis (Wright Medical, Memphis, Tennessee) in the other three. Re-approximation of the lateral soft-tissue structures was performed in all cases in an attempt to repair or reconstruct the lateral collateral ligament complex. In most the extent of the soft-tissue damage was such that it was not possible to identify a distinct lateral ligament. No attempt was made to repair the medial collateral ligament. One patient had a hinged elbow fixator (EBI, Parsippany, New Jersey) when residual ulnohumeral subluxation was noted at the completion of internal fixation. Of the six patients, three underwent further surgery, two for bone grafting and revision plating for

nonunion of the fracture of the ulna and one for removal of an external fixation device (Table I).

The mean follow-up of these six patients was for 28 months (14 to 48). The mean post-operative elbow flexion was to 120° (100° to 140°) and extension lacked a mean of 25° (10° to 45°). The mean pronation was 50° (10° to 70°) and supination 55° (0° to 90°). None had varus/valgus or anterior/posterior instability at follow-up. The mean standardised DASH score was 34 (0 to 80) and the mean Broberg-Morrey functional index score was 73.8 (31 to 99). This corresponded to two excellent outcomes, two good and two poor (Table II). Radiographic assessment of post-traumatic arthritis showed two patients with Broberg-Morrey grade 0 and four with grade 1 changes.

The patients without ulnohumeral dislocation included 12 women and five men with a mean age of 55 years (18 to 83). At a mean follow-up of 29 months (12 to 60), the mean post-operative elbow flexion was 127° (90° to 140°) and the loss of extension was 5° (0° to 20°). The mean pronation was to 60° (45° to 70°) and supination 67° (30° to 90°). None had varus/valgus or anterior/superior instability. The mean standardised DASH score was 23 (0 to 70) and the mean Broberg-Morrey functional index score was 83 (32.5 to 100). This corresponded to six excellent outcomes, four

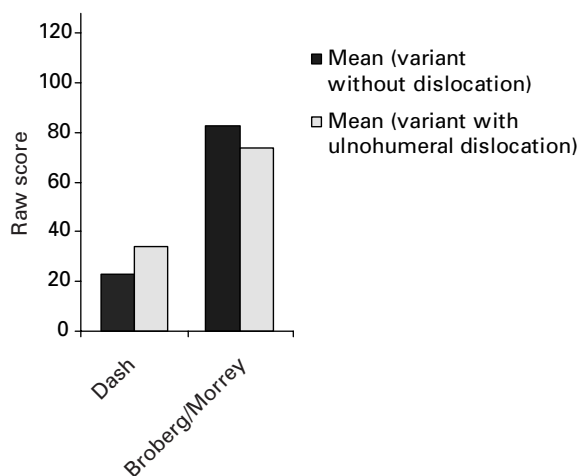


Fig. 4a

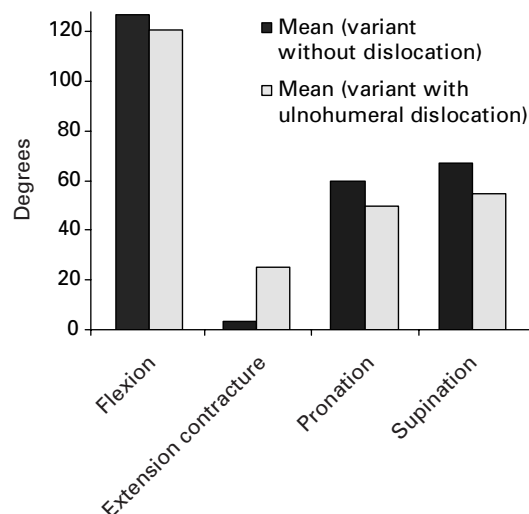


Fig. 4b

Bar charts showing functional outcome of type II Monteggia fractures with associated ulnohumeral dislocation *versus* Monteggia fractures without dislocation. Figure 4a – The lower Broberg-Morrey functional index scores and the higher DASH standardised symptom scores indicate a greater disability in patients whose injury included ulnohumeral dislocation. Figure 4b – The greater mean loss of extension seen with associated ulnohumeral dislocation was statistically significant ($p < 0.01$). Cases with dislocation had limitation of movement compared to those without dislocation.

good, six fair and one poor (Table III). Radiographic assessment of post-traumatic arthritis showed six patients with Broberg-Morrey grade 0, nine with grade 1 and two with grade 2 changes.

Patients with injuries which occurred in conjunction with ulnohumeral dislocation had significant difficulty regaining extension of the elbow after operation ($p < 0.01$). Loss of flexion, pronation and supination were also seen, but these differences did not reach statistical significance ($p = 0.40$, 0.15 and 0.26 , respectively). Posterior ulnohumeral instability led to poorer functional outcomes with a lower Broberg-Morrey index score and a higher DASH standardised symptom score, but again these differences were not significant ($p = 0.39$ and 0.34 , respectively) (Fig. 4).

Radiographically, three of the six fractures of the ulna had united. Three had not joined, reflecting the high-energy nature of the injury and associated comminution (Figs 3c and d). Two patients had a further operation with bone grafting and revision of the plating. The third declined treatment because he was free of symptoms, the elbow was stable and he had returned to work. Three of the four patients who developed degenerative changes had undergone replacement of the head of the radius. Mild heterotopic ossification was present anteriorly in two patients.

Discussion

Dislocation of the ulnohumeral joint is usually the result of a fall on the outstretched hand with the arm abducted.¹⁻³ Two mechanisms of injury have been described. First, with the elbow in extension at the time of impact, the olecranon will impinge on the distal humerus. This results in a lever-

ing of the coronoid posteriorly, underneath the trochlea, with enough lateral rotation to cause failure of the posterolateral capsular and ligamentous support system.² The second proposed mechanism suggests that the lateral slope of the trochlea acts as a cam during impact, causing valgus angulation and failure of the lateral collateral ligament complex and posterior capsule.^{2,17} In between one and two thirds of dislocations of the elbow the force involved results in associated fractures.² These injuries may require operative intervention and may result in a worse prognosis than in isolated dislocations.⁵

The Bado type II lesion with posterior dislocation of the head of the radius accounts for 70% to 80% of such injuries.^{9,18} Jupiter et al¹⁴ further subdivided the type II injuries based on the pattern of damage to the head of the radius and the site of the fracture of the ulna. They noted that fractures of the ulna, including the coronoid process (type A), and those distal to the coronoid process at the junction of the metaphysis and diaphysis (type B) were relatively common, whereas fractures involving the diaphysis (type C) and those extending from the olecranon to the diaphysis (type D) were rare.¹⁴ Associated fractures of the head of the radius were seen in 77% of these cases.¹⁴ In a later series, Ring et al⁹ noted that Bado type II lesions occurred following two different mechanisms of injury. Fractures resulting from low-energy injuries tended to occur in elderly female patients, whereas those associated with a higher-energy were seen in younger, male patients. An associated fracture of the head of the radius occurred in 68% of Type II injuries.⁹

Our six cases demonstrate a unique pattern of injury combining posterior ulnohumeral dislocation with a type II

Monteggia lesion. We believe that the high-energy basis of these injuries results in a higher percentage of the rarer Monteggia fracture-dislocation than has been previously described. The mechanism of injury suggests an initial ulnohumeral dislocation caused by a fall on the outstretched and abducted upper limb, with direct impact of the distal humerus on the proximal ulna. An alternative explanation is that the initial Monteggia injury occurs following a direct impact with the elbow in the flexed position, with subsequent ulnohumeral dislocation caused by the continued forward momentum of the patient.

Jupiter et al¹⁴ have reported the results after operative treatment of 13 posterior Monteggia fractures. In the 11 patients who were assessed post-operatively using the Broberg-Morrey functional index, the results were excellent in three, good in three, fair in four and poor in one, with an overall mean index of 82.3.¹⁴ In four there was no reduction in the power of elbow flexion, six had mild loss and in one it was moderate. The mean post-operative elbow flexion was 130° and the mean loss of extension was 17°. The mean pronation and supination were both 68°. None had post-operative varus-valgus instability.¹⁴ Two required further surgery after six and ten weeks, respectively because of loosening of the plate and screws from the ulna.¹⁴

Ring et al⁹ described 48 adult patients with Monteggia lesions; 38 had Bado Type II fracture-dislocations. According to the Broberg-Morrey functional index scores, 14 had an excellent, 18 a good, one a fair and five a poor result, with an overall mean index score of 85. They had a mean of 112° of ulnohumeral movement and 126° of rotation of the forearm. Nine required further surgery within three months of the initial procedure. Five had revision of loose fixation of the ulna fracture, three resection of the head of the radius and one removal of a wire that had migrated from the head of the radius into the ulnohumeral joint.⁹

We defined the posterior Monteggia lesion with associated fracture of the head or neck of the radius as a Monteggia variant. This pattern of injury has been noted to contribute to a worse outcome than similar injuries without such a fracture.^{8,19} In the series of Ring et al,⁹ the six patients with an unsatisfactory result had an associated fracture of the head of the radius and four a fracture of the coronoid process. Worse outcomes in injuries associated with fractures of the head or neck of the radius were also seen in the series of Jupiter et al¹⁴ and Givon et al.⁸

We noted that patients with posterior ulnohumeral dislocation had a greater loss of movement of the elbow, particularly of extension, and outcome scores indicative of greater disability compared to cases without an associated dislocation. We attribute the poor functional outcomes to the high-energy nature of the injury, the associated soft-tissue and ligamentous damage from the accompanying ulnohumeral dislocation and the higher incidence of associated fractures of the head and neck of the radius. The high rate of nonunion of the fracture of the ulna is probably also attributable to these causes. Two of the three cases healed

after bone grafting and revision plating. One declined further intervention.

Some authors have advocated excision of the head of the radius in Monteggia lesions with an associated fracture of the radial head.^{9,20} However, this structure plays an important role as a secondary stabiliser of the elbow joint in the absence of the medial collateral ligament.^{21,22} Retention of the length of the radial column by fixation or replacement is a mainstay of treatment in these injuries.²³ We had no cases of recurrent ulnohumeral instability probably because of the recognition of the associated ligamentous instability and aggressive treatment of radial and coronoid fractures.

The combination of injuries described in this series has rarely been reported before and our findings highlight the possibility of a poor outcome.

No benefits in any form have been received or will be received from a commercial party related directly or indirectly to the subject of this article.

References

1. Preston CF, Chen AL, Wolinsky PR, Tejwani NC. Posterior dislocation of the elbow with concomitant fracture of the proximal ulnar diaphysis and radial head: a complex variant of the posterior Monteggia lesion. *J Orthop Trauma* 2003;17:530-3.
2. Royle SG. Posterior dislocation of the elbow. *Clin Orthop* 1991;269:201-4.
3. Linscheid RL, Wheeler DK. Elbow dislocation. *JAMA* 1965;194:1171-6.
4. Neviaser JS, Wickstrom JK. Dislocation of the elbow: a retrospective study of 115 patients. *South Med J* 1977;70:172-3.
5. Broberg MA, Morrey BF. Results of treatment of fracture-dislocations of the elbow. *Clin Orthop* 1987;216:109-19.
6. Ring D, Jupiter JB. Fracture-dislocation of the elbow. *Hand Clin* 2002;18:55-63.
7. Bado JL. The Monteggia lesion. *Clin Orthop* 1967;50:71-86.
8. Givon U, Pritsch M, Levy O, et al. Monteggia and equivalent lesions: a study of 41 cases. *Clin Orthop* 1997;337:208-15.
9. Ring D, Jupiter JB, Simpson NS. Monteggia fractures in adults. *J Bone Joint Surg [Am]* 1998;80-A:1733-44.
10. Boyd HB, Boals JC. The Monteggia lesion: a review of 159 cases. *Clin Orthop* 1969;66:94-100.
11. Hudak PL, Amadio PC, Bombardier C. Development of an upper extremity outcome measure: the DASH (disabilities of the arm, shoulder and hand) [corrected]. *Am J Ind Med* 1996;29:602-8.
12. Broberg MA, Morrey BF. Results of delayed excision of the radial head after fracture. *J Bone Joint Surg [Am]* 1986;68-A:669-74.
13. Gummesson C, Atroshi I, Ekdahl C. The disabilities of the arm, shoulder and hand (DASH) outcome questionnaire: longitudinal construct validity and measuring self-rated health change after surgery. *BMC Musculoskeletal Disord* 2003;4:11.
14. Jupiter JB, Leibovic SJ, Ribbans W, Wilk RM. The posterior Monteggia lesion. *J Orthop Trauma* 1991;5:395-402.
15. Regan W, Morrey B. Fractures of the coronoid process of the ulna. *J Bone Joint Surg [Am]* 1989;71-A:1348-54.
16. Mason ML. Some observations on fractures of the head of the radius with a review of one hundred cases. *Br J Surg* 1954;42:123-32.
17. Osborne G, Cotterill P. Recurrent dislocation of the elbow. *J Bone Joint Surg [Br]* 1966;48-B:340-6.
18. Penrose JH. The Monteggia fracture with posterior dislocation of the radial head. *J Bone Joint Surg [Br]* 1951;33-B:65-73.
19. Biyani A, Olscamp AJ, Ebraheim NA. Complications in the management of complex Monteggia-equivalent fractures in adults. *Am J Orthop* 2000;29:115-18.
20. Boulas HJ, Morrey BF. Biomechanical evaluation of the elbow following radial head fracture: comparison of open reduction and internal fixation vs. excision, silastic replacement, and non-operative management. *Chir Main* 1998;17:314-20.
21. Morrey BF, Tanaka S, An KN. Valgus stability of the elbow: a definition of primary and secondary constraints. *Clin Orthop* 1991;265:187-95.
22. Morrey BF, An KN. Stability of the elbow: osseous constraints. *J Shoulder Elbow Surg* 2005;14(1 Suppl S):174-8.
23. McKee MD, Pugh DM, Wild LM, Schemitsch EN, King GJ. Standard surgical protocol to treat elbow dislocations with radial head and coronoid fractures: surgical technique. *J Bone Joint Surg [Am]* 2005;87-A(Suppl 1):22-32.