

# The Single Complete Denture – A Case Report

Usha M Radke,<sup>1</sup> Sham M Gundawar,<sup>2</sup> Rajlakshmi S Banarjee,<sup>3</sup> Aditi S Paldiwal<sup>4</sup>

## ABOUT THE AUTHORS

### 1 Dr. Usha M Radke,

Dean, HOD and Guide  
Department of Prosthodontics  
V.S.P.M.'s Dental College And  
Research Centre, Nagpur

### 2. Dr. Sham M Gundawar,

Professor and Guide  
Department of Prosthodontics  
V.S.P.M.'s Dental College And  
Research Centre, Nagpur

### 3. Dr. Rajlakshmi S Banarjee,

Reader  
Department of Prosthodontics  
V.S.P.M.'s Dental College And  
Research Centre, Nagpur

### 4. Dr. Aditi S Paldiwal

PG Student  
Department of Prosthodontics  
V.S.P.M.'s Dental College And  
Research Centre, Nagpur

### Corresponding Author:

#### Dr. Aditi S Paldiwal

PG Student  
Department of Prosthodontics  
V.S.P.M.'s Dental College And  
Research Centre, Nagpur

Email:  
[draditipaldiwal@gmail.com](mailto:draditipaldiwal@gmail.com)

## Abstract

The single complete denture is a complex prosthesis that requires a complete understanding of the basics of prosthetic rehabilitation of lost natural dentition. Several difficulties are encountered in providing a successful single complete denture treatment, the most common being repeated fracture of the prosthesis. An ideal solution to strengthen the single complete denture bases is to provide metal reinforcement by fabrication of metal based single complete denture. Another common problem in single complete denture is attrition of denture teeth while opposing natural dentition which can be taken care of by providing metal occlusals in single complete dentures. Metal occlusal surfaces preserve the established occlusion and prevent loss of vertical dimension. This case report describes the clinical management and step by step fabrication of single complete denture with metal denture base and metal occlusals in a patient with completely edentulous maxillary jaw and partially edentulous mandibular jaw.

**Key words:** Single complete denture, metal base, metal occlusals, occlusal template

## Introduction

The main objective of any prosthetic treatment should be based on De Van's statement that "*Perpetual Preservation Of That What Remains Rather Than Meticulous Replacement Of What Has Been Lost.*"<sup>1</sup> This is especially true in terms of completely edentulous jaw opposing natural dentition. Treatment planning of single complete dentures needs critical evaluation of various factors. Success of complete denture depends on many variables, but three factors stand out in terms of functional success: retention, stability and support. According to Koper<sup>2</sup> occlusal problems and denture-base fracture seen in single complete denture are the result of one or all of the following: occlusal stress on maxillary denture and underlying edentulous tissue from teeth and musculature accustomed to opposing natural teeth, the position of the mandibular teeth which may not be properly aligned for the bilateral balance needed for stability and flexure of denture base. The natural teeth which will oppose a complete denture almost always require recontouring to some degree to provide for a harmonious occlusion. The reasons for this are: the inclination of occlusal plane is usually unfavourable, the individual teeth may be malpositioned and may have assumed positions that present excessively steep cuspal inclinations and the buccolingual width of the natural teeth may be too wide. Failure to alter these conditions will often prevent the development of bilateral balance occlusion in eccentric positions.<sup>3</sup>

Heat polymerized dentures are the dominant material for the fabrication of denture bases. These heat polymerized denture base resins present acceptable physical, biologic and esthetic characteristics at moderate expense.<sup>4</sup> However, denture base resins in single complete dentures has been frequently found to fracture under excess masticatory forces. Metal bases have been proved to be a valuable alternative for denture bases opposing natural dentition to strengthen bases and to prevent them

from fracture. However, weight of metal can be a problem and to minimize weight, with maximum strength. Proper palatal contours should be ensured and the resin-metal junction must be carefully positioned and sculpted. Properly designed metal denture bases can aid in conserving the supporting tissues of the denture bearing areas.<sup>4</sup>

Acrylic resin denture teeth wear at an accelerated rate when opposed by natural teeth or porcelain or metal restorations. The wear patterns of the occlusal surfaces are critical in the maintenance of occlusal relationships and ultimately the health of supporting dentition. This excessive wear may lead to alterations in vertical dimension of occlusion and create deleterious occlusal interferences. Metal occlusal surfaces have clinically demonstrated compatibility with opposing natural teeth.<sup>5</sup> Use of metal occlusal surfaces reduces the wear of the denture teeth and significantly improves the longevity of the denture.

This case report describes step by step fabrication of single complete denture with metal base and metal occlusal surfaces opposing natural dentition.

### Case Report

A 70 year old female patient reported to the Department of Prosthetic Dentistry of V.S.P.M.'s Dental College And Research Centre, Nagpur with the chief complaint of repeated fracture of maxillary denture and for replacing the missing lower anterior teeth. Past medical history revealed that she was hypertensive since 2 years. Past dental history revealed that she had undergone extractions of her lower anterior teeth 8 months back due to trauma and periodontitis associated with them. Intraoral examination revealed that her maxillary arch was edentulous and mandibular arch was having posterior teeth and missing anteriors i.e. 31324142. Mandibular teeth were having good periodontal support with no mobility associated with them. (Fig.1 & 2) Radiographic evaluation was done. The treatment plan decided for the patient was to provide her with single complete denture for maxillary edentulous arch with metal base and metal occlusals and a lower porcelain fused to metal fixed partial denture with 31324142. Prior to construction of the denture, it was desirable to complete all rehabilitation procedures in the opposing dental arch.

#### Classification of single complete denture<sup>2</sup>

Class 1 - Patients for whom minor, or no, tooth reduction is all that is needed to obtain balance.

Class 2 - Patients for whom minor additions to the height of the teeth are needed to obtain balance.

Class 3 - Patients for whom both reductions and additions to teeth are required to obtain balance. The treatment of these patients usually involves a change in vertical dimension of occlusion.

Class 4 - Patients who present with occlusal discrepancies that require addition to the width of the occluding surface.

Class 5 - Patients who present with combination syndrome.

### Preprosthetic Phase

The patient was categorized as Class 1 patient in whom minor, or no, tooth reduction is all that is needed to obtain balance.

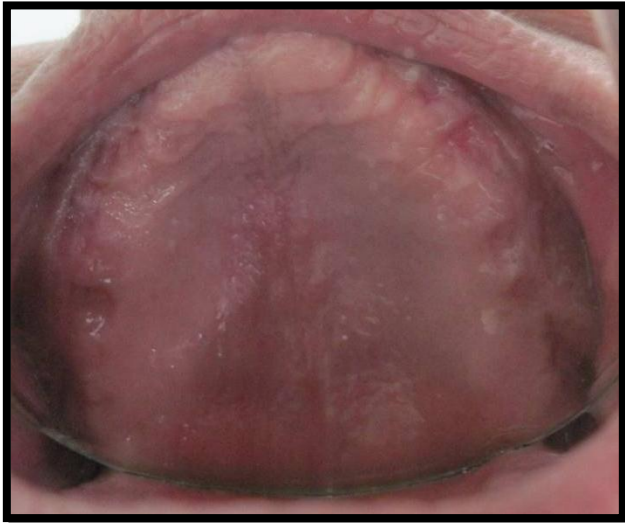All restorations, including fixed partial denture were planned. An acceptable level of oral hygiene, which is mandatory, should include maintenance instructions for both the edentulous arch and the remaining natural teeth.

Diagnostic casts were made and examined carefully to identify malposed or supraerupted teeth. All corrections required for improving the alignment of opposing dentition were carried out.

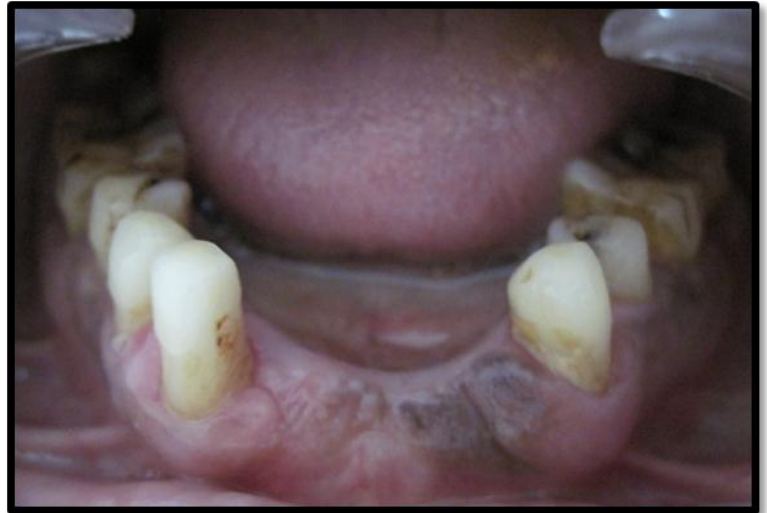### Procedure

At the first visit primary impressions of the maxillary and mandibular arches were made. Maxillary arch impression was made with medium fusing impression compound (Esquire, MDM corp. Link, Delhi) and mandibular arch impression was made with irreversible hydrocolloid impression material (Zhermak, Italy). (Fig.3) After making primary impressions, the impressions were poured in dental plaster and dental stone respectively. Autopolymerizing acrylic resin was mixed and adapted on the casts and modeling wax was also adapted on the temporary record bases. Tentative jaw relation was made and diagnostic mounting was done to check the inter-arch distance. (Fig.4)

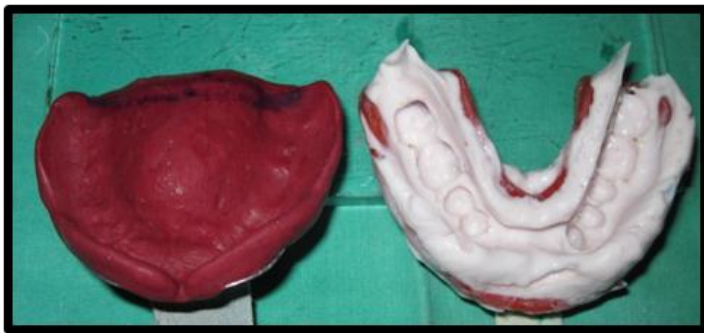At second visit on primary cast wax spacer (Maarc, Shiva Products, Thane, India) was adapted and on that custom tray was fabricated. On this custom tray border molding was done followed by making of the wash impression. (Fig.5) The master cast was obtained. The master cast was then duplicated with agar-agar (reversible hydrocolloid) (Wiradouble, Bego, Germany) to get a working cast. (Fig.6) On the working cast of maxillary edentulous arch, the pattern of the metal frame work was adapted. The pattern of the metal base was kept short of posterior palatal seal area for ease to relieve the area if required. (Fig.7) A lubricant was applied to the duplicated cast for easy removal of wax pattern. A stop of (2x2mm) was placed on the crest of the ridge. Three sprues of 4mm diameter and crucible former were attached to the wax pattern in a conventional manner. The wax pattern was lifted from the cast with care to prevent any distortion. The sprued wax pattern was then invested with care such that investment material flowed between the beads and all around the base plate wax. A cobalt-chrome alloy (Wironit, Bego, Germany) casting was prepared in a standard manner. The metal framework was then transferred to the master cast. (Fig.8) The denture base was invested in a standard manner to replace the wax with heat cure denture base resin between the metal denture base and tissue – bearing surface. A wax occlusal rim was fabricated on the temporary record base




**Fig. 1. Edentulous Maxilla**



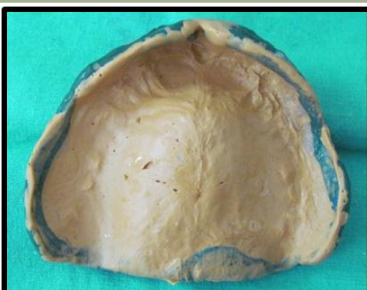**Fig. 2. Lower Natural Teeth**



**Fig.3.Primary impression**



**Fig.4.Tentative Jaw Relation**



**Fig.5.Wash Impression**



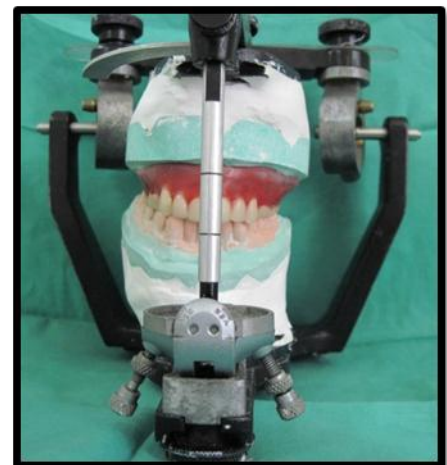**Fig.6. Master Cast**



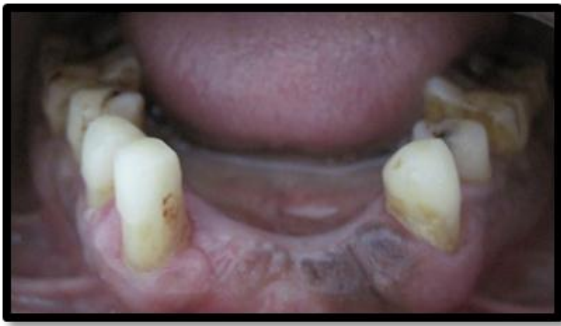**Fig.7. Wax Pattern**



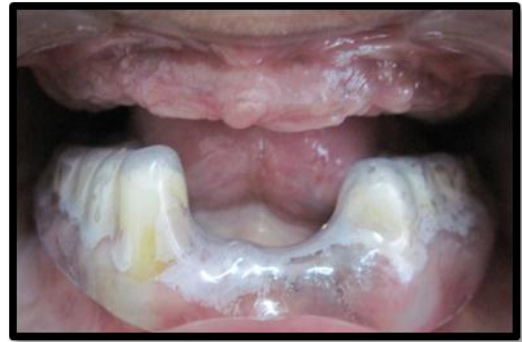**Fig.8. Metal Base**



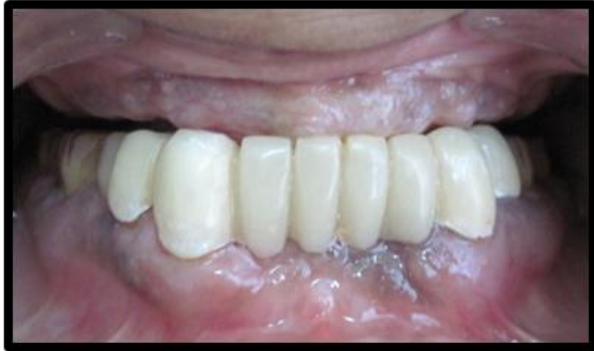**Fig.9.Teeth Arrangement**



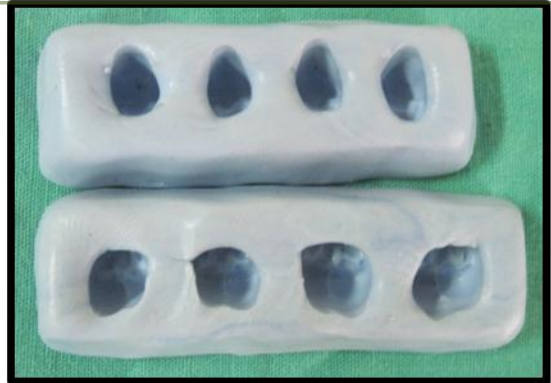**Fig.10.Tooth Preparation**



**Fig.11.Occlusal Template**



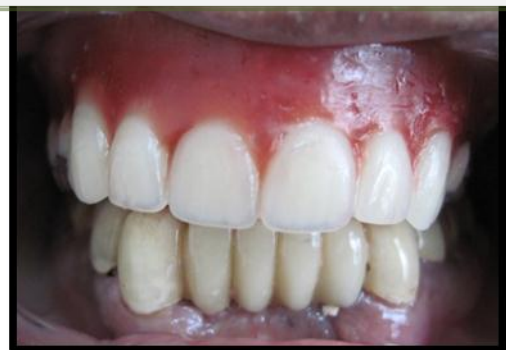**Fig.12.Provisionals Cemented**



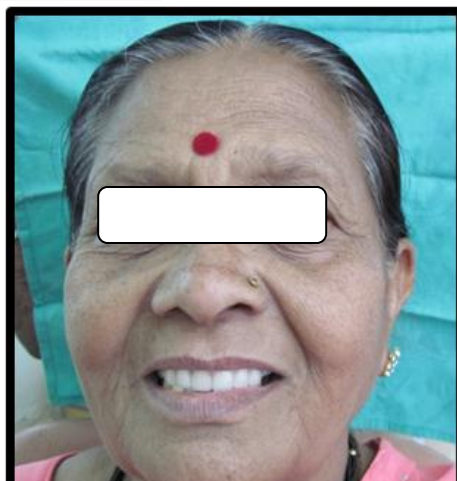**Fig.13.Putty Index**



**Fig.14.Wax Occlusals**



**Fig.15.Try-In Done**



**Fig.16.Post-Operative**

reinforced with metal to record jaw relation and teeth arrangement.

The lower natural teeth impression was made in an irreversible hydrocolloid impression material. On this impression the vacuum-formed clear template (Biostar) with 0.02 inch thick was adapted. The template was cut at the level of gingival margin around the entire cast to facilitate removal.<sup>6</sup> The template was removed from the cast. The maxillary and mandibular casts were mounted in centric relation with a good jaw relation record. The proper contour and vertical dimension was established with the maxillary occlusion rim. Maxillary teeth were arranged according to the contour of the maxillary occlusion rim and aligned the occlusal surface, in a compensating curve to facilitate the development of occlusal balance. In the course of arranging teeth, the denture teeth were grinded judiciously to achieve the best possible articulation with the natural stone teeth on mandibular cast. (Fig.9)

As the anterior 31 32 41 42 were missing the tooth preparation was done for 33 and 44. (Fig.10) The provisionals were fabricated and cemented with temporary zinc oxide non-eugenol cement (Temp LT, GC Fuji, America) in the patient's mouth. (Fig.11) The impressions of prepared tooth was made in elastomeric impression material putty (Aquasil, Dentsply, Germany) and light body impression material (Aquasil, Dentsply, Germany) and poured in die stone (Kalrock, Kalabhai Karson, India). The patterns were fabricated, followed by investing, casting, finishing and polishing. The metal trial procedure was carried out in the mouth. After thorough evaluation of marginal fit, shade matching (Vita, Vitapan Classic, Germany) procedure was done according to the adjacent natural teeth. After ceramic layering, bisque trial was done of the porcelain fused to metal restoration followed by proper finishing and polishing. The porcelain fused to metal fixed partial denture was cemented in the patient's mouth.

For the fabrication of metal occlusals the posterior teeth were removed from the teeth arrangement and putty index of the teeth was made. (Fig.13) The occlusal third of the putty index was filled with inlay wax. The patterns were removed and custom made hooks were incorporated onto the waxed occlusals for retention of metal with the heat cure resin. (Fig.14) These patterns were invested, casted, finished and polished. The metal occlusals were again placed in the putty index and modeling wax (Dental Modeling Wax, MDM Corp. Link, Delhi; India) was poured into it till the cervical portion. The wax was allowed to set and solidify following to which the metal occlusals with the attached wax patterns were retrieved from the putty index and were flaked for incorporating tooth colored material (DPI, Mumbai; India). The regular procedure of dewaxing, followed by packing of heat cure tooth colored material was done. After an hour the flasks were kept in acrylizer for curing. After retrieving from curing the tooth colored teeth were finished and polished. The custom made teeth with metal occlusals were then again placed in the jaw relation mounted on Hanau Wide Vue articulator and later was tried in patient's mouth. (Fig.15) The denture

try-in was carried out and patient's consent was obtained. The conventional procedures of flasking, dewaxing, packing, curing, finishing and polishing of heat cure dentures (Trevalon HI, Dentsply, Gurgaon; India) were carried out. Dentures were inserted and delivered to the patient. (Fig.16) Home care instructions were given to the patient.

## Discussion

A technique is described for designing and making the maxillary single complete denture with metal base and metal occlusals opposing the lower natural teeth. The natural teeth which will oppose a complete denture almost always require recontouring to some degree to provide some degree to provide for a harmonious occlusion.

The metal denture base has metal in contact with the edentulous ridge. Prosthetic teeth are attached to metal base with a plastic base or by cementation to a retentive post.<sup>6-9</sup>

### Indications:

1. A tooth supported edentulous space where further bone resorption is not anticipated.
2. When a facing, tube tooth, metal pontic, or metal reinforced denture tooth is to be used.
3. A tooth-tissue supported edentulous space when the "floating denture base" concept is being used.

### Contraindications:

1. Tooth-tissue supported edentulous space.
2. Tooth supported edentulous space where bone resorption is expected.

### Advantages:

1. Very rigid.
2. High thermal conductivity. Thermal conductivity may be decreased if plastic is processed onto the metal base.
3. Very stable form.
4. High abrasion resistance.
5. Less porous than plastic and therefore easier to clean.

### Disadvantages

1. More difficult to adjust tissue surface than a plastic base.
2. More difficult to relin the metal tissue surface.
3. Metal not esthetic.

## Summary

Many patients become edentulous in one arch while retaining some or all of their natural teeth, in the opposing arch. Several difficulties are encountered in providing a successful, single complete denture treatment.

Metal bases for complete dentures have been used successfully and provide many advantages over the

more commonly used acrylic resin. The few disadvantages are far outweighed by the many advantages. The possibility of allergy to the metal, although a valid concern, varies with the composition and electrochemical properties of the alloy and the susceptibility of the patient. With metal bases for dentures, the patient benefits by having a more comfortable, better fitting, and stronger prosthesis. The dentist benefits by reducing post insertion visits and providing a restoration that will better satisfy the patient.

#### References

1. Zarb GA, Bolender CL, Hickey JC, Carlsson GE. Boucher's prosthetic treatment for edentulous patients. 11<sup>th</sup> ed St. Louis: CV Mosby, 1990:503.
2. Carl F. Driscoll, Radi M. Masri. Single maxillary complete denture. Dent Clin N Am 2004;48:567-583.
3. Charles W. Ellinger, Jack H. Rayson and Davis Henderson. Single complete denture. J Prosthet Dent 1971;26:1:4-10.
4. Patrick A. Mattie and Rodney D. Phoenix. A precise design and fabrication method for metal base maxillary complete dentures. J Prosthet Dent 1996;76:496-9.
5. Martin Thomas Barco and Scoll A. Synnoll. Precision metal occlusal surfaces for removable partial dentures. Int J Prosthodont 1989;2:365-367.
6. Han-Kuang Tan. A preparation guide for modifying the mandibular teeth before making a maxillary single complete denture. J Prosthet Dent 1997;77:321-2.
7. The Glossary of prosthetic terms. 6<sup>th</sup> ed. St. Louis, C V Mosby, 1994.
8. Henderson D, McGivney G P, Castleberry D J. McCracken's removable partial prosthodontics. 7<sup>th</sup> ed. St. Louis, C V Mosby 1985:131.
9. Applegate O C. Essentials of removable partial denture prosthesis. 2<sup>nd</sup> ed. Philadelphia, W B Saunders, 1960:140.