

THE THERAPIST'S MANAGEMENT OF THE STIFF ELBOW

MARK PISCHKE, OTR/L, CHT
NOV, 17, 2014

ELBOW FUNCTION

1. Required to provide stability for power and precision tasks for both open and closed kinetic chain activities.

Open chain tasks: Bringing hand to mouth or reaching to throw a ball.

Closed chain task: Pushing an object or holding onto a power tool. (Elbow Fixed)

2. Our elbows permit hand placement within shoulder boundaries.

3. Limited elbow motion may prevent ability to perform center based activities...

(touch our face, ears, and mouth). Even limit ability to reach to tie shoes or reach into high shelves.



FUNCTIONAL ROM

- ✘ Elbow Flex/Ext: 30-130 degrees
- ✘ Pron/Supination: 50-50 degrees
- ✘ Functional elbow ROM on positional and functional tasks has been reported previously by Morrey et al. It was determined that **30° ext to 130°** of flexion, **50° of pronation**, and **50° of supination** are required for personal hygiene and sedentary tasks.
- ✘ These numbers have often been quoted as the standard for functional ROM about the elbow and have been used to formulate surgical indications regarding elbow stiffness, arthrodesis positioning, and validating outcomes in total elbow arthroplasty.



CLINICAL REASONING



- ✘ The elbow joint after trauma is prone to developing contractures. Loss of elbow range of motion is attributed to capsular and ligamentous thickening, adhesions of the musculotendinous structures, and intra-articular adhesions.

What Makes an elbow prone to stiffness?

- + 1. Brachialis muscle lies directly over the anterior capsule....
- + 2. The anterior capsule tends to tear more frequently than posterior.
- + 3. All 3 elbow articulations exist in 1 capsule....
Humeroulnar joint, Humeroradial joint, and Proximal Radioulnar joint,
- + 4. The elbow is prone to development of HO.
Heterotopic ossification generally means that bone forms within soft tissues, including muscle, ligaments, or other tissues.

CONTRACTURES

AND FUNCTION

- × Contractures are grouped by limitation...
- × Flexion Contracture = Lacks extension
- × Extension Contracture = Lacks Flexion

- × Elbow flexion contractures are more common than extension.
- × Lack of extension can be compensated with trunk flexion and shoulder motion.

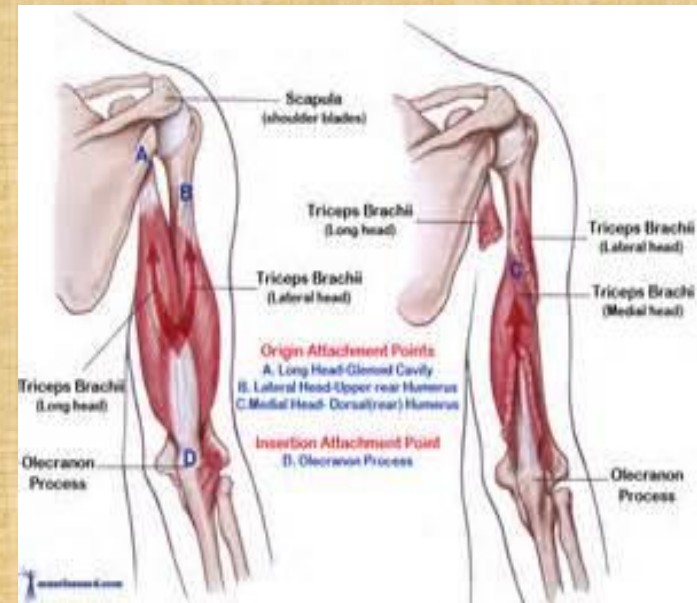
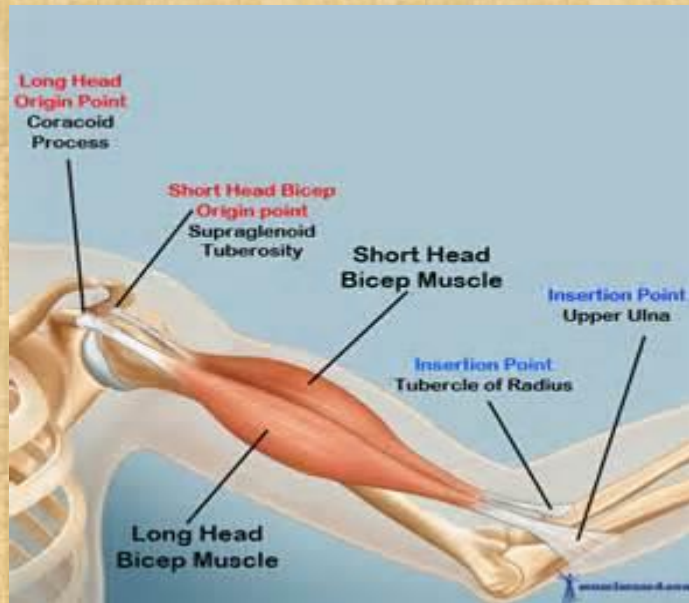
- × Elbow extension contractures
- × Because neck and wrist flexion are limited as compensatory patterns, loss of elbow flexion are more functionally limiting as a whole.

- × The posterior capsule is rarely the cause of extension contracture by itself. More often it is the triceps adhering to the humerus along with the joint capsule.

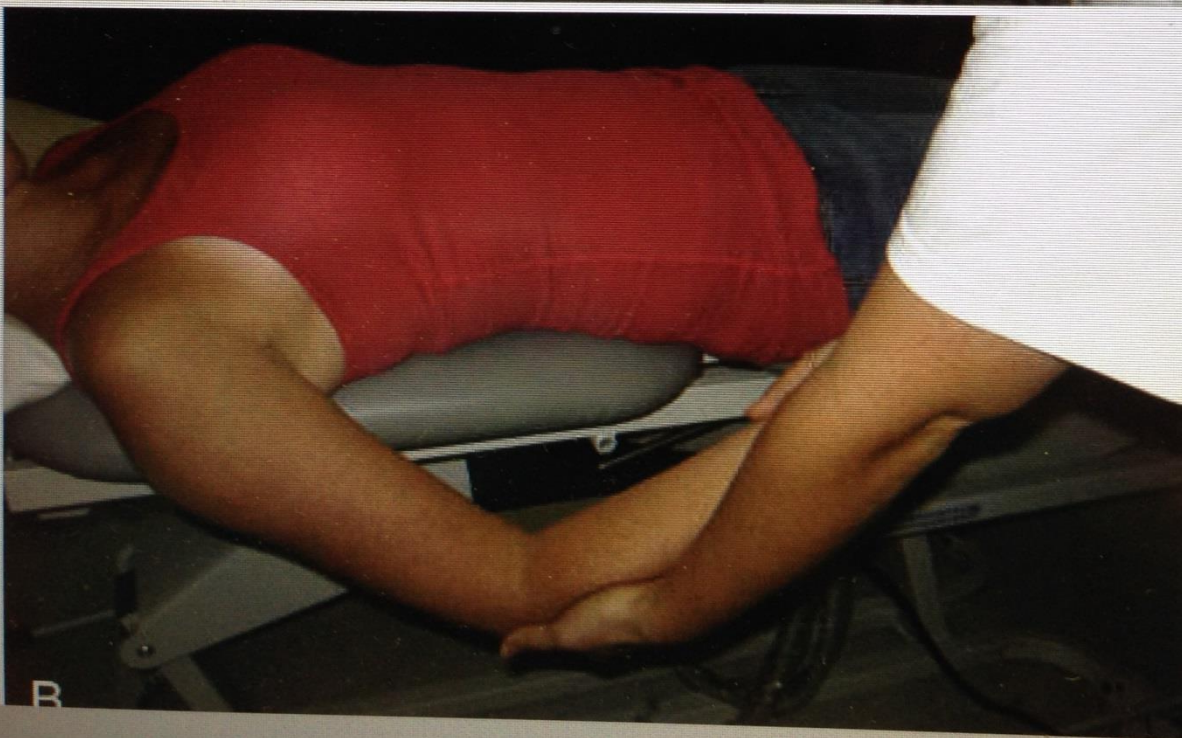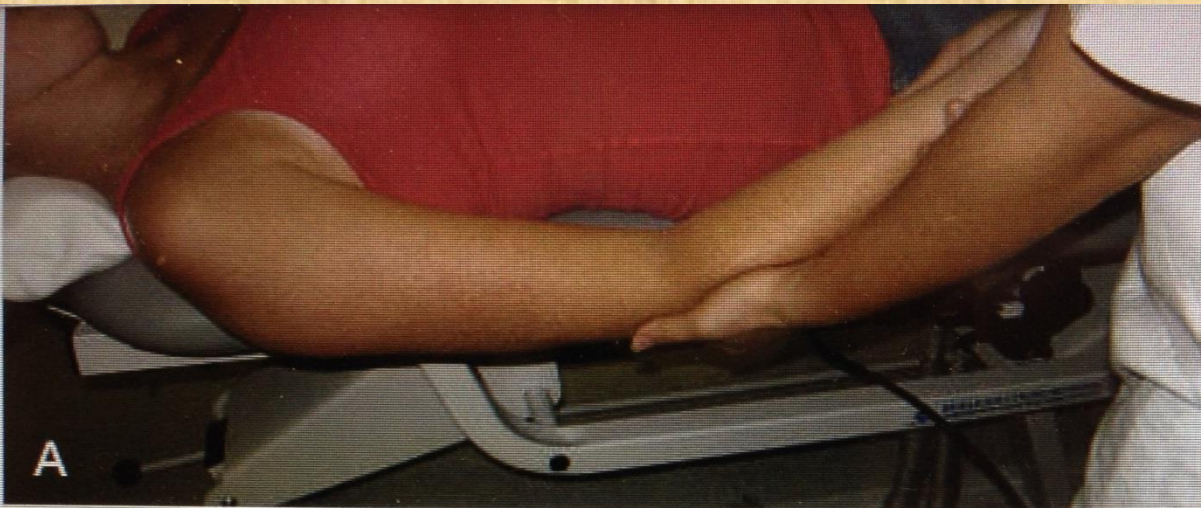
Muscle Length

The biceps muscle is prone to adaptive shortening following elbow injury. This is secondary to prolonged posturing in acute elbow flexion.

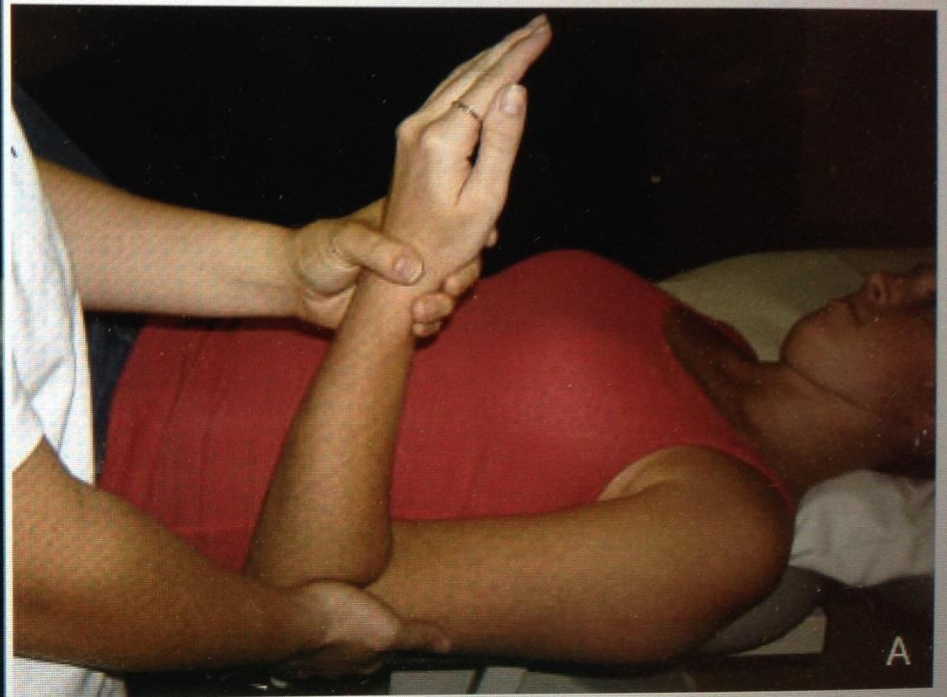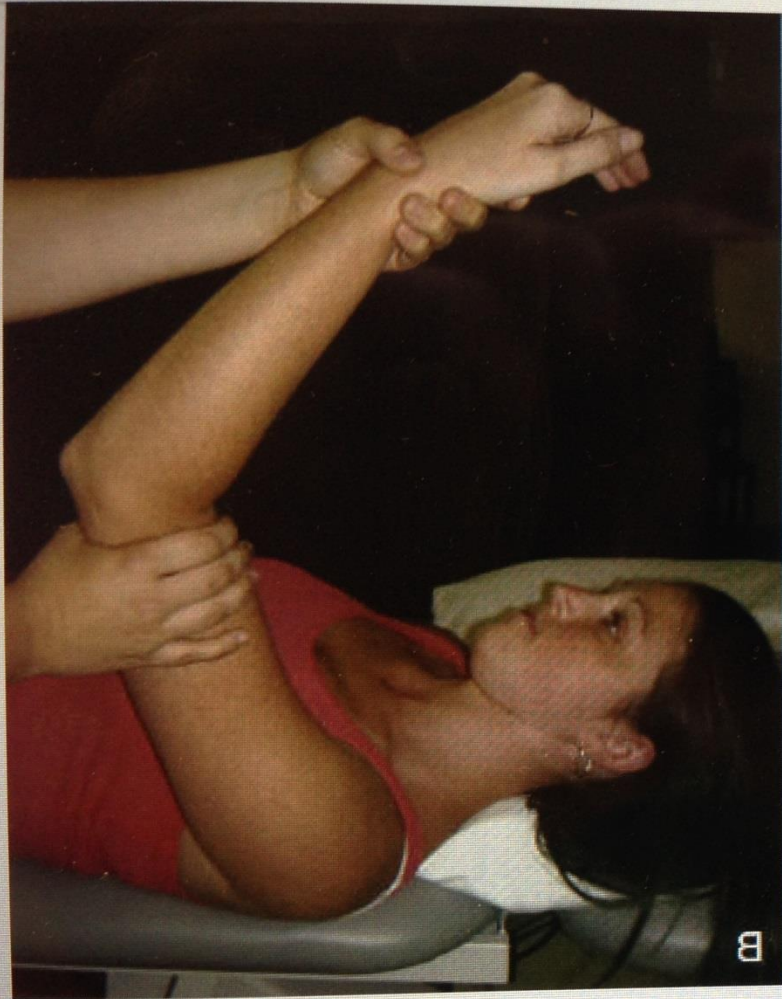
1. A pronated forearm position may relax the biceps and allow increased elbow extension.
2. It is important to remember that both the biceps and triceps are two-joint muscles and the position of the shoulder will impact their excursion at the elbow.



3. Most of the extensor-supinator muscles and the flexor-pronator muscles cross both the elbow and wrist joints, so their excursion at the elbow will be impacted by wrist and forearm positions.



Loss of elbow extension ROM with shoulder more extended vs neutral position.



Loss of Elbow Flexion with shoulder flexed vs neutral: Possible indication of adhered triceps .

Muscle Inhibition

Following elbow injury, patients often have trouble recruiting and firing the triceps muscle. This may be due to reciprocal inhibition resulting from hyperactivity of the biceps.

Examining and working the triceps with the patient in supine position and the shoulder at 90 degrees of forward flexion can be effective.



The pull of gravity on the biceps is eliminated so that reciprocal inhibition of the triceps is decreased, and the therapist can easily assist extension if the patient is not able to fully overcome the force of gravity.

Pain



Generally, post-traumatic elbow stiffness is not painful at rest or during motion through the available range.

Pain through the range can be indicative of intra-articular pathology such as arthritis, articular incongruity, articular cartilage damage, or HO.

Complaints of pain at the end-ranges of motion are quite common. A stretching pain (feels like a very tight rubber band) is expected.

Complaints of paresthesias or sharp, “electric” pain at end-range flexion are red flags for ulnar nerve adherence, irritation, or compression.

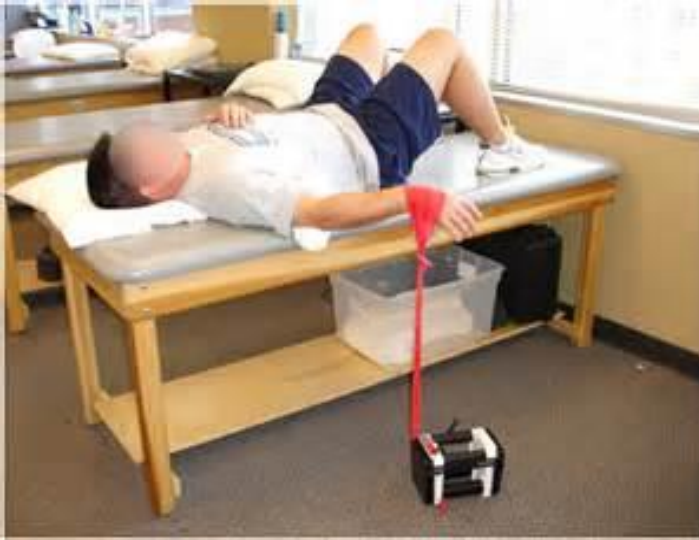Therapeutic Exercise

Activities and exercises that incorporate elbow motion into a functional task are recommended. An emphasis is placed on recruiting the triceps muscle.

Placing cones on a high surface and then retrieving them, Valpar – forward or elevated reach, Pulleys and upper body ergometers are also useful for repetitive, cyclical elbow motion.

Outside of therapy, patients may carry a bag with a light object (can of soup) during prolonged walking activities. Be sure to instruct them to let the bag lightly stretch the elbow. If they respond to the weight with biceps contraction, this is not a beneficial exercise for them.

In general, deficits of flexion and pronation respond well to functional activities, and deficits of extension and supination require the use of long-arm orthoses to restore motion.



Orthoses to Increase Motion

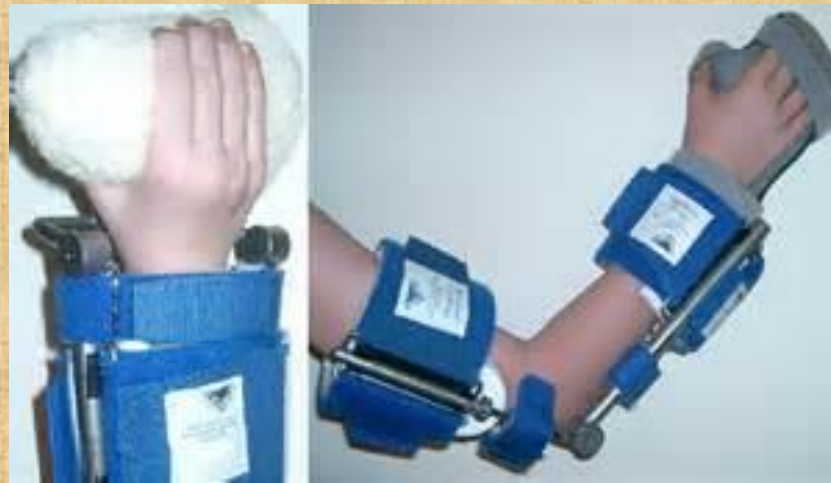The use of static and static progressive long-arm orthoses is an important component of treating the stiff elbow. Orthosis wearing schedules vary widely in the literature or brand name commercial unit.

Each patient's schedule will be based on tolerance, extent of motion loss, and their own availability to wear the splint.

The orthoses can be used for 30- to 60-minute periods, four to six times per day. If the patient requires orthoses for both flexion and extension, the schedule is modified.

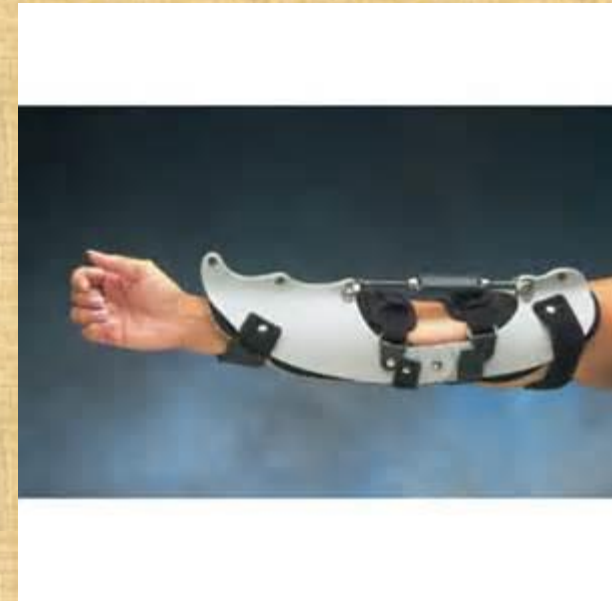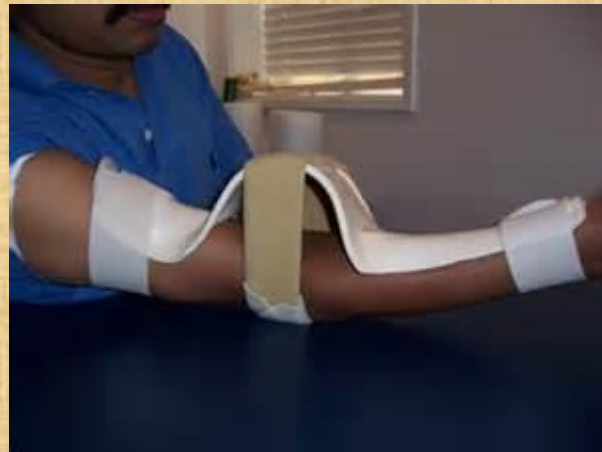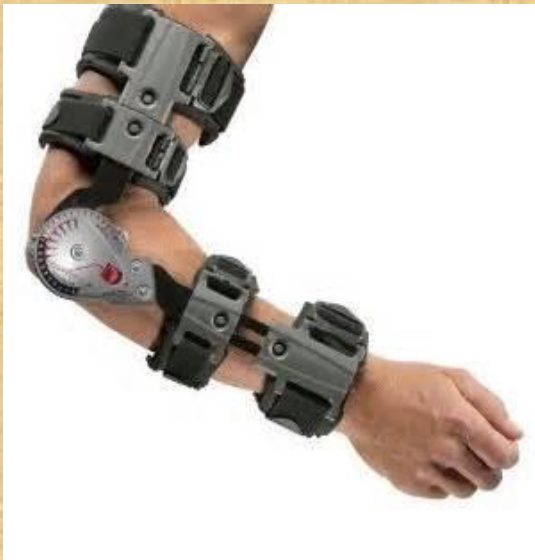At night patients usually wear an extension long-arm orthosis to position their elbow at end-range extension. Positioning the elbow in flexion during the night is poorly tolerated due to tensioning of the ulnar nerve if it has not been transposed.

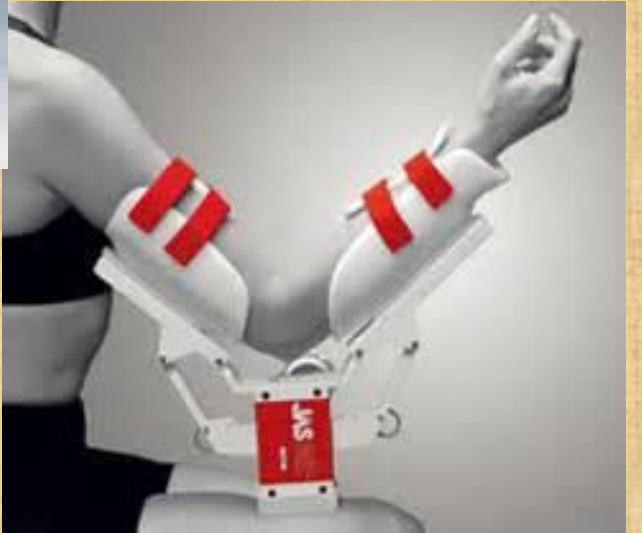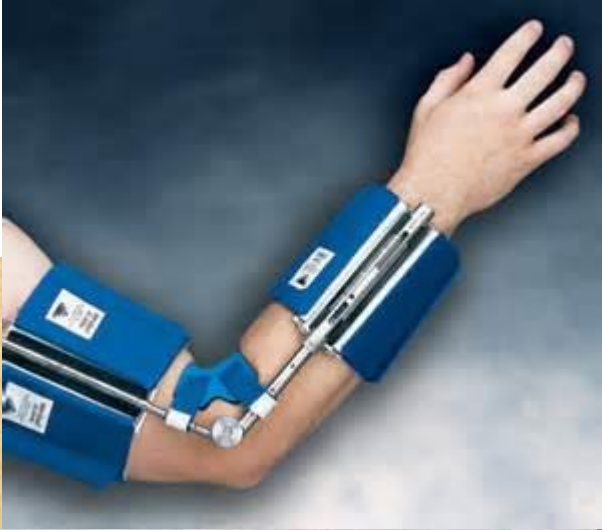Dynamic orthoses use a spring or elastic to exert a constant stretch. This unforgiving, constant stretch often provokes muscle spasm, which defeats the purpose of tissue elongation and is often poorly tolerated???





A ***static progressive*** orthosis is one that holds the elbow at an end-range, fixed position and imparts torque to the joint in that position. As the soft tissue and capsule elongate in response to the positioning, the force dissipates. The orthosis is then repositioned. The soft tissue is progressively elongated through cycles of stretch and accommodation.





SPLINTING

- ✘ Goal: address contractures by providing maximal rotational forces.

SPLINTING

- ✘ Research: All splints appear to be effective for elbow flexion contractures greater than 30 degrees.
- ✘ Open static progressive splints are ineffective in gaining the final 20-30 degrees of extension.
- ✘ As the contracture improves, greater rotational forces can be achieved through from the adjustable 3point splint strap.
- ✘ “This means that the TPSPS may be more optimally designed for later stages of therapy to regain terminal elbow extension.” Static Progressive versus Three-point Elbow Extension Splinting:A Mathematical Analysis: Journal of Hand Therapy, January-March issue, 2009.

A Prospective Randomized Controlled Trial of Dynamic Versus Static Progressive Elbow Splinting for Posttraumatic Elbow Stiffness

Anneluuk L.C. Lindenhovius, MD, PhD, Job N. Doornberg, MD, PhD, Kim M. Brouwer, MSc,
Jesse B. Jupiter, MD, Chaitanya S. Mudgal, MD, and David Ring, MD, PhD

Investigation performed at the Orthopaedic Hand and Upper Extremity Service, Department of Orthopaedic Surgery, Massachusetts General Hospital, Boston, Massachusetts

Background: Both dynamic and static progressive (turnbuckle) splints are used to help stretch a contracted elbow capsule to regain motion after elbow trauma. There are advocates of each method, but no comparative data. This prospective randomized controlled trial tested the null hypothesis that there is no difference in improvement of motion and Disabilities of the Arm, Shoulder and Hand (DASH) scores between static progressive and dynamic splinting.

Methods: Sixty-six patients with posttraumatic elbow stiffness were enrolled in a prospective randomized trial: thirty-five in the static progressive and thirty-one in the dynamic cohort. Elbow function was measured at enrollment and at three, six, and twelve months later. Patients completed the DASH questionnaire at enrollment and at the six and twelve-month evaluation. Three patients asked to be switched to static progressive splinting. The analysis was done according to intention-to-treat principles and with use of mean imputation for missing data.

Results: There were no significant differences in flexion arc at any time point. Improvement in the arc of flexion (dynamic versus static) averaged 29° versus 28° at three months ($p = 0.87$), 40° versus 39° at six months ($p = 0.72$), and 47° versus 49° at twelve months after splinting was initiated ($p = 0.71$). The average DASH score (dynamic versus static) was 50 versus 45 points at enrollment ($p = 0.52$), 32 versus 25 points at six months ($p < 0.05$), and 28 versus 26 points at twelve months after enrollment ($p = 0.61$).

Conclusions: Posttraumatic elbow stiffness can improve with exercises and dynamic or static splinting over a period of six to twelve months, and patience is warranted. There were no significant differences in improvement in motion between static progressive and dynamic splinting protocols, and the choice of splinting method can be determined by the patients and their physicians.

Level of Evidence: Therapeutic Level I. See Instructions for Authors for a complete description of levels of evidence.

Manual Therapy

Wide variety of soft tissue techniques can be effective for increasing elbow ROM. Some examples are soft tissue massage and mobilization, myofascial techniques, joint mobilization, ASTYM, contract-relax or hold-relax techniques, and muscle energy techniques.

Aggressive, painful PROM or stretching is contraindicated, as it provokes episodes of repeated, involuntary muscle guarding. This type of aggressive stretching can cause tissue injury and inflammation, which lead to secondary fibrosis.

It is convenient to start the patient's treatment in the supine position. Superficial heat (hot pack) is applied in a tolerable end-range position for 10 to 15 minutes. Ample layers of toweling, especially over bony prominences (e.g., olecranon process) should be used.

Soft tissue mobilization techniques follow the thermotherapy. This sequence prepares the patient for ROM.

The therapist guides the patient through repetitions of flexion, extension, pronation, and supination, providing tactile and verbal cues for muscle recruitment.

When working on flexion, grasping just the patient's wrist should be avoided. A wide contact over the entire length of the ulnar aspect of the patient's forearm with the therapist's hand and forearm is better tolerated.

When working on extension, the therapist's superior elbow and forearm may be used to stabilize the patient's shoulder and upper arm while the inferior arm guides the patient's forearm movement.

As stated previously, more extension may be obtained when the patient's forearm is in pronation because the biceps is inhibited.

After each motion has been addressed, combinations of flexion + supination and extension + pronation through a full arc of motion can be performed.

Joint mobilization to the Elbow, Wrist and Hand



REFERENCES:

1. **Kisner C, Colby LA: Therapeutic Exercise: Foundations and Techniques. Philadelphia: FA Davis Co., 5th ed., chap 5, 2007.**
2. **Kaltenborn FM: Manual Mobilization of the Extremity Joints. 4th ed., Oslo: Olaf Norlis Borkhandel, 1989**

**Hung Kuang University Department of Physical Therapy
Cheng, Hsiang-Chun 3310**



Humeroulnar and Humeroradial Joint

- **Structures and Movements**
 - Humeroulnar Joint
 - Convex: humeral (trochlea)
 - Concave: ulna (trochlea notch)
 - Humeroradial Joint
 - Convex: humeral (capitulum)
 - Concave: radius
- **Active movements**
 - Flexion, extension.

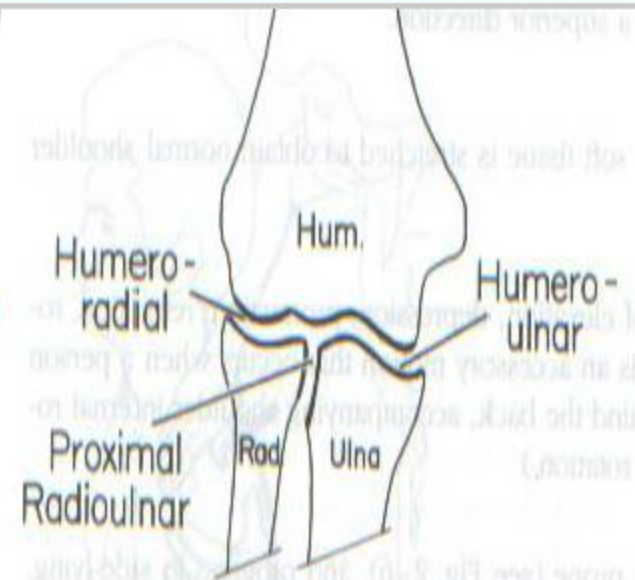
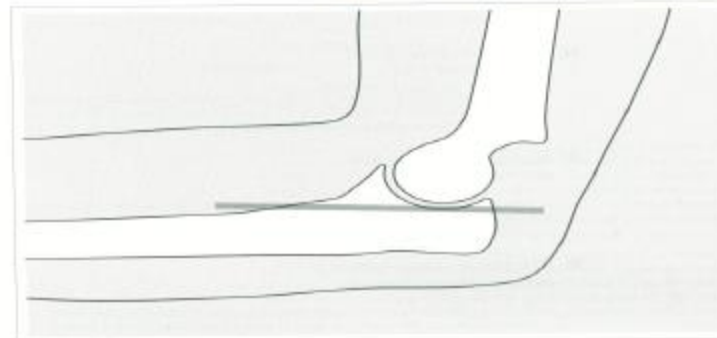


Figure 6-25. Bones and joints of the elbow complex.





Humeraloulnar and Humeroradial Joint

- Close packed position
 - Humeraloulnar Joint
 - Maximal extension
 - Humeroradial Joint
 - Elbow flexed 90°
forearm supination 50°
- **Loose packed position**
 - Humeraloulnar Joint
 - 70° - 90° elbow flexion, forearm 10° supination
 - Humeroradial Joint
 - Full extension, full supination
- Capsular pattern
 - Flexion—extension

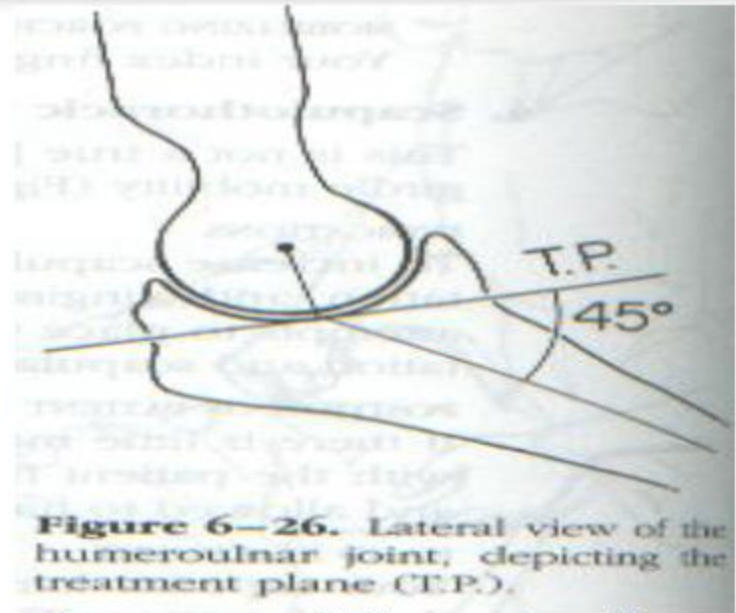


Figure 6-26. Lateral view of the humeraloulnar joint, depicting the treatment plane (T.P.).



Ulna Distraction (humeroulnar joint)

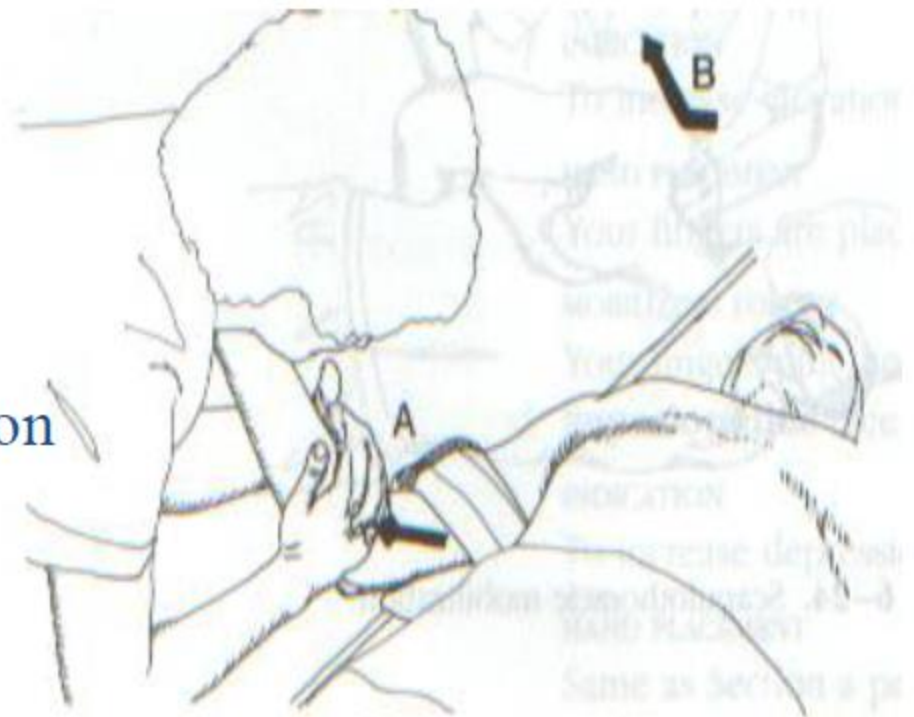- **Use: testing; to increase general mobility(extension or flexion)**
- P— supine with arm resting on table and elbow flexed
- O— The PT's stabilizing hand grasps the patient's anterior/distal surface of the humerus
- The mobilizing hand contacts the anterior/proximal surface of the ulna
- M--- The mobilizing hand exerts a caudal force through the finger contacts on the ulna. (consider the treatment plane)



Ulna Distraction

A----Ulnar distraction

B----Ulnar distal gliding
To increase elbow flexion





Radial traction

- Use: **testing; to increase general mobility**
- P— supine with arm support on table with the elbow placed in the loose packed position
- O—The patient's arm is fixated against the table with a belt. The PT's hand grasps with both hands around the ventral surface and proximal part of the patient's forearm.
- M---The PT shifts the body backward moving the ulna at a right angle to the forearm, thus producing traction in the elbow joint.
- Same technique can be done at the end of the elbow available range (traction progression)



Radial traction

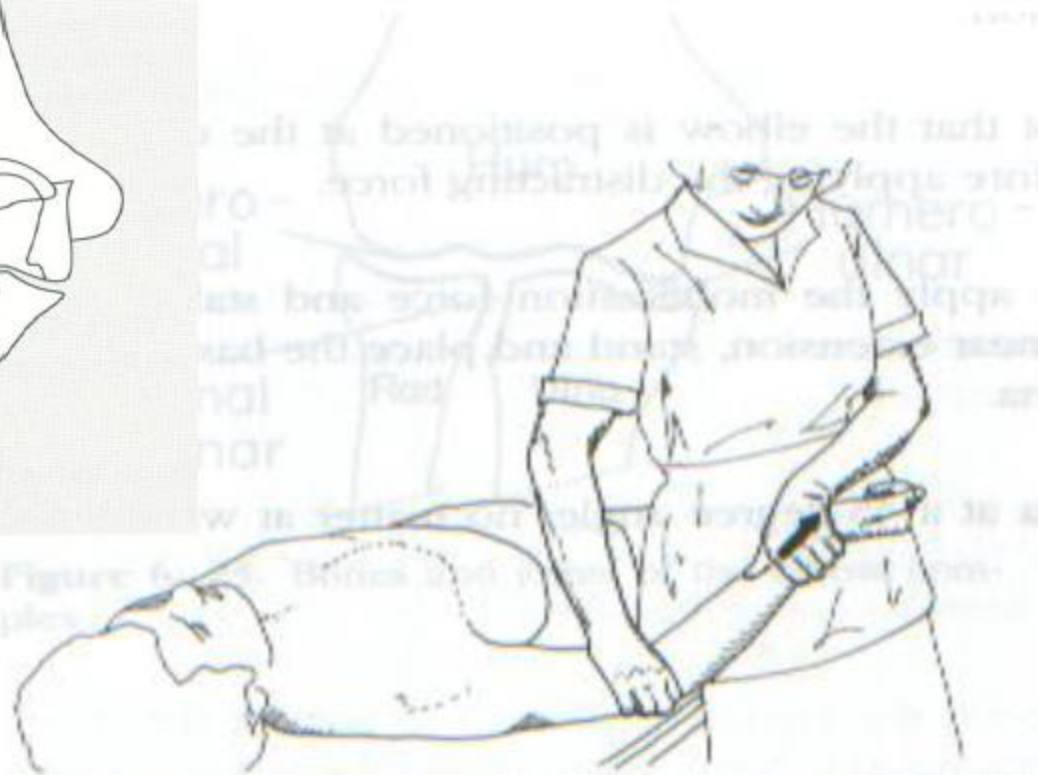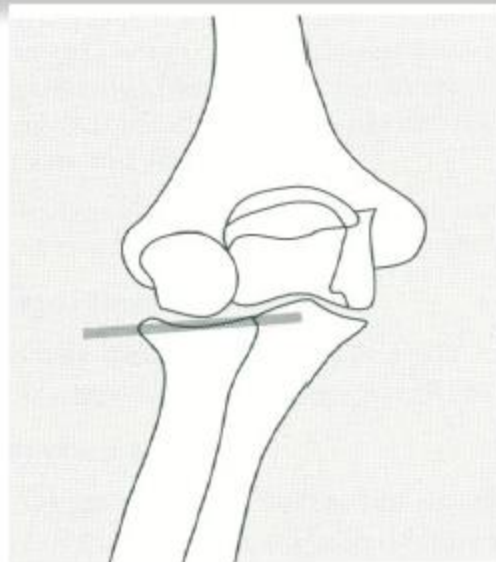


Figure 6–28. Joint traction; humeroradial articulation.

Fixate the humerus against the tray

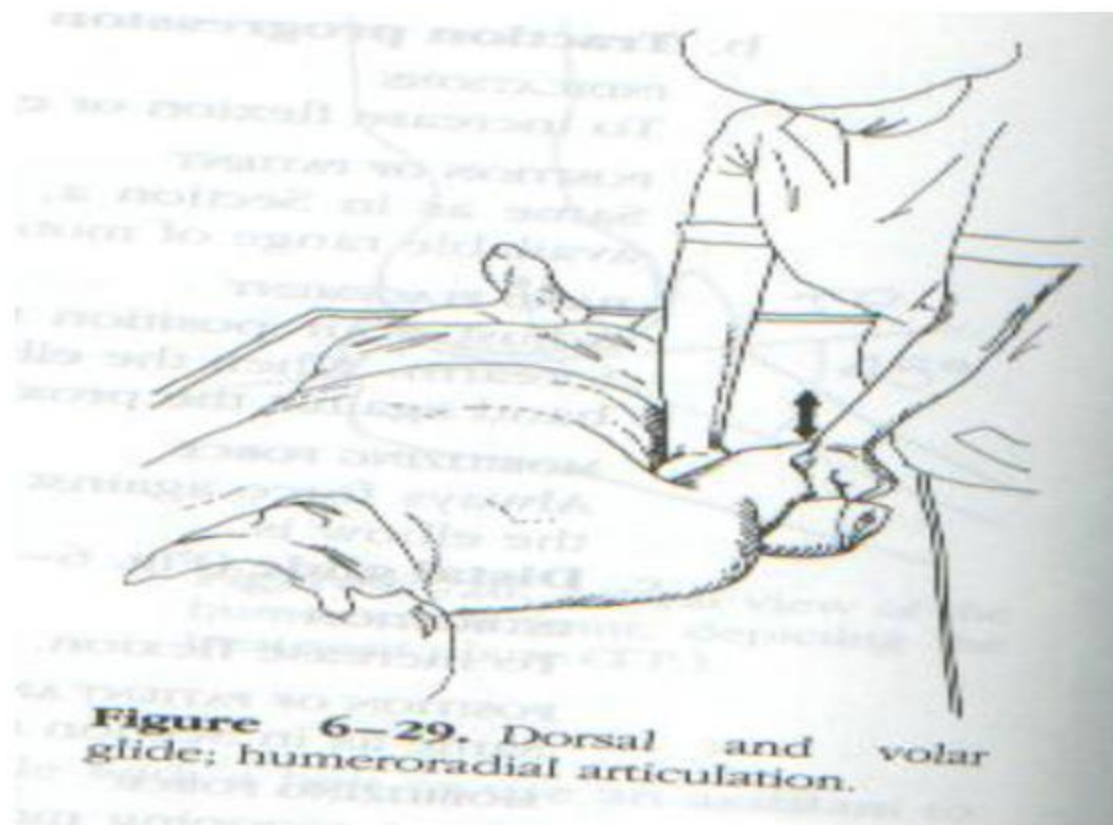

Dorsal Glide and Volar Glide of the Radial (Humeroradial joint)

- **Use:** to increase **elbow extension -- posterior glide** to increase **elbow flexion -- anterior glide**
- P— supine with arm support on table
- O—The PT's stabilizing hand grasps around the distal humerus. The mobilizing hand grasps the radial head.
- M--- The mobilizing hand exerts a anterior force through the thumb pad. The mobilizing hand exerts a posterior force through the index and middle fingers (or thenar eminence)



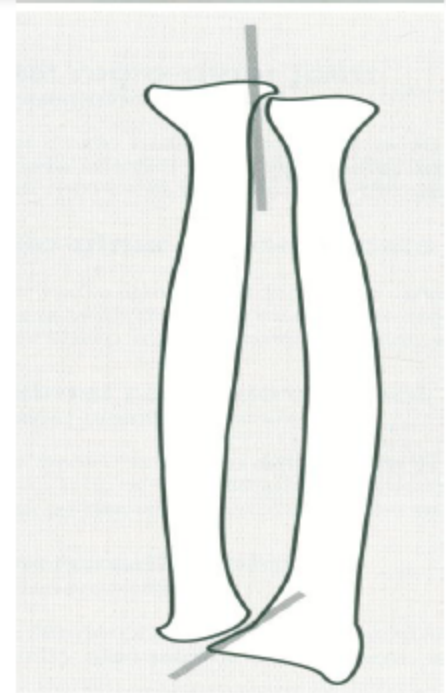
Dorsal Glide and Volar Glide of the Radial (Humeroradial joint)





Proximal Radioulnar Joint

- **Structures and Movements**
 - Convex: radial head
 - Concave: ulna (the radial notch)
- Active movements
 - Pronation, supination
- Close packed position
 - 5° supination
- **Loose packed position**
 - 70° elbow flexion, 35° forearm supination





Proximal Radioulnar Joint

- Component and joint play motions
 - Distraction
 - Dorsal/volar glide
 - Superior/inferior glide
- **Capsular pattern**
 - Pronation and supination are restricted equally



Proximal radioulnar joint

- **Posterior glide to increase forearm pronation**
- **Anterior glide to increase forearm supination**
- **P— supine with arm supported on table**
- **O—The PT's stabilizing hand grasps around the distal humerus. The mobilizing hand grasps the radial head.**
- **M--- The mobilizing hand exerts a anterior force through the thumb pad. The mobilizing hand exerts a posterior force through the index and middle fingers (or thenar eminence)**

Anterior Glide and Posterior Glide of the Radial Head

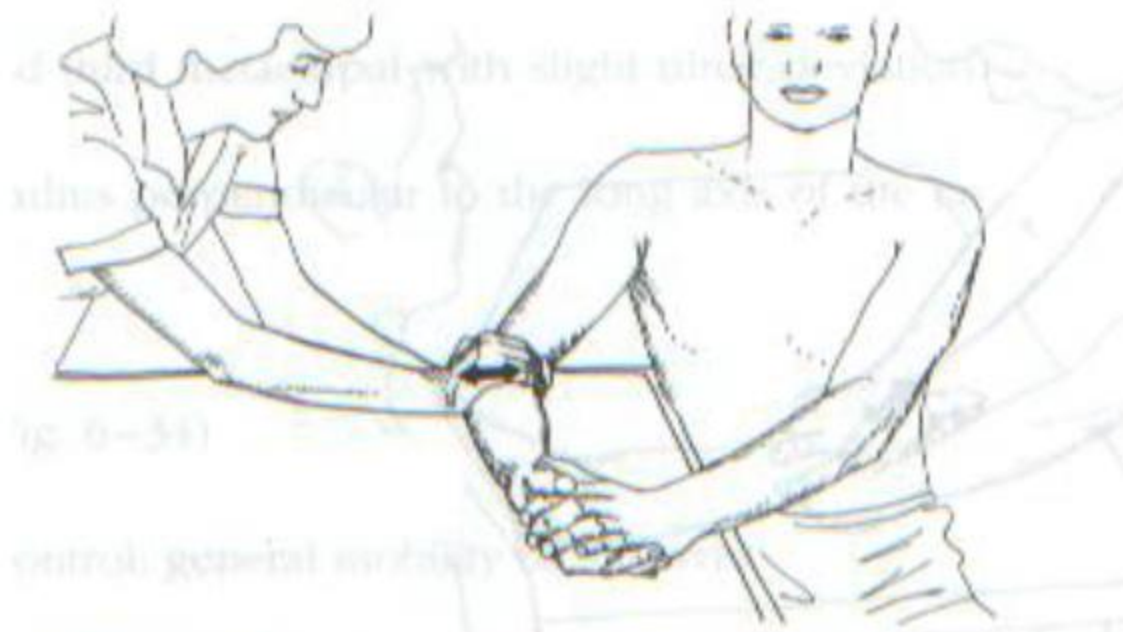


Figure 6–31. Dorsal-volar glide; proximal radioulnar joint.

REFERENCES:

1. Clinical Biomechanics of the Elbow: Journal of hand Therapy. April-June 2006
2. Electromyographic Activity in the Stiff and Normal Elbows during Elbow Flexion and Extension: Journal of Hand Therapy. 2003.
3. Splinting method doesn't affect elbow healing: AAOS NOW. June 2008 issue.
4. A prospective Randomized Controlled Trial of Dynamic Versus Static Progressive Elbow Splinting for Posttraumatic Elbow Stiffness. JBJS. 2012; 94:694-700
5. Static Progressive versus Three-point Elbow Extension Splinting: A Mathematical Analysis: Journal of Hand Therapy, January-March issue, 2009.
6. Management of the Stiff Elbow. Rehabilitation of the Hand and Upper Extremity. 6th edition.