

The Use of 3D-4D Ultrasound in Obstetrics

Prof.Dr.S.Cansun DEMİR

President of TSOG

Çukurova University Faculty of Medicine

Dept. Obstetrics & Gynecology

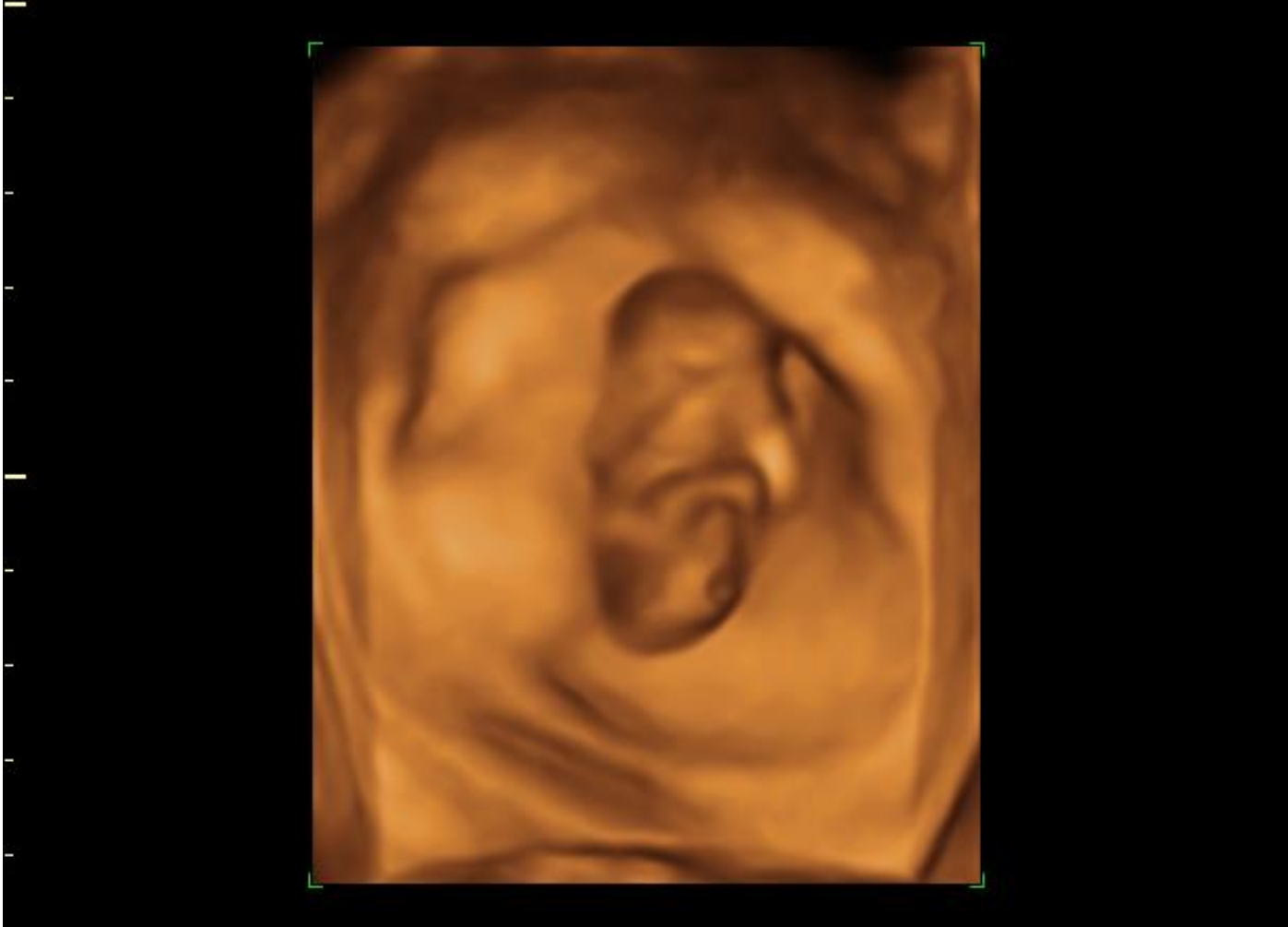

TAJEV 2014



3D/4D Ultrasonography

- **2D = 2 dimension**
- **3D = 3 dimension**
- **4D= 3 dimension real-time view**



- **The literature contains many articles addressing the use of 3D ultrasound in obstetrics and gynecology.**
- **Some articles have shown that, in certain situations, volume sonography adds diagnostic value to standard 2-dimensional (2D) ultrasound.**
- **Three-dimensional ultrasound can also provide accurate measurements in 3 planes with acceptable interobserver reliability**

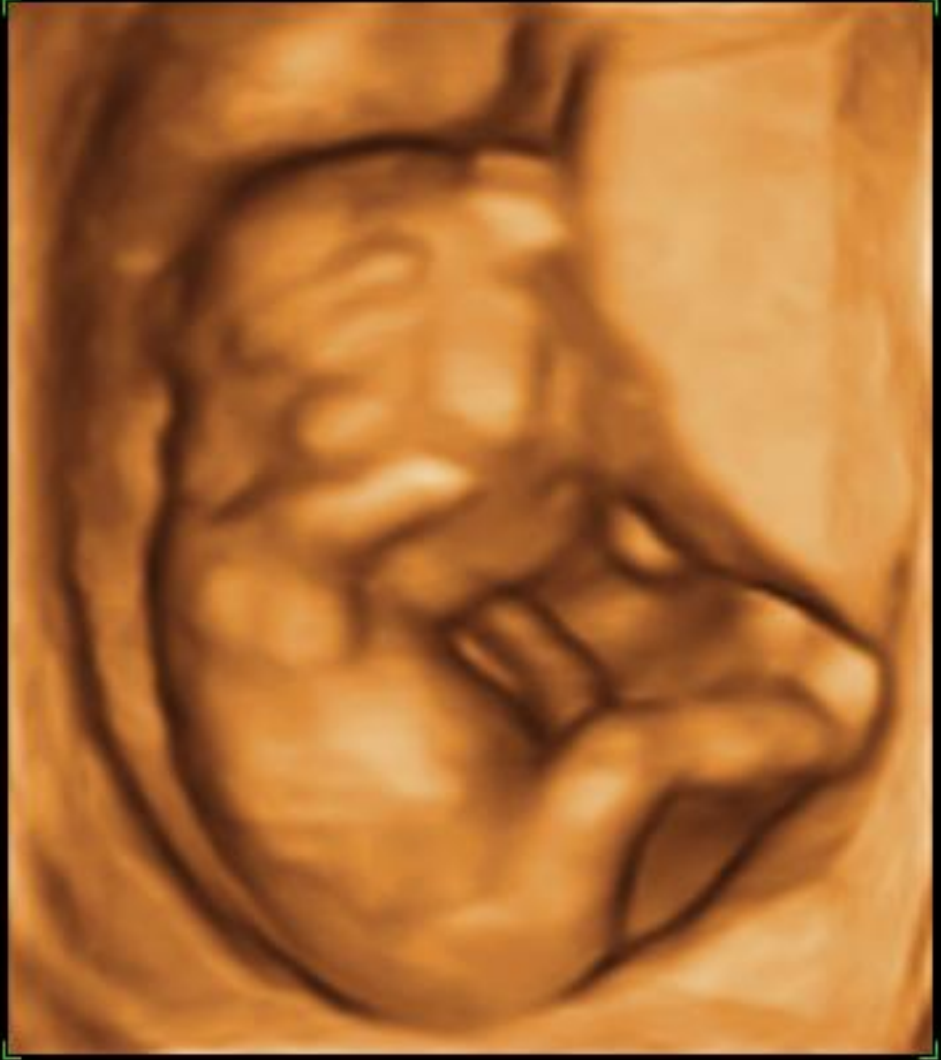Three- and 4-Dimensional Ultrasound in Obstetrics and Gynecology

Proceedings of the American Institute of Ultrasound in Medicine Consensus Conference

Beryl R. Benacerraf, MD, Carol B. Benson, MD, Alfred Z. Abuhamad, MD, Joshua A. Copel, MD, Jacques S. Abramowicz, MD, Gregory R. DeVore, MD, Peter M. Doubilet, MD, PhD, Wesley Lee, MD, Anna S. Lev-Toaff, MD, Eberhard Merz, MD, Thomas R. Nelson, PhD, Mary Jane O'Neill, MD, Anna K.

Parsons, MD, Lawrence D. Platt, MD, Dolores H. Pretorius, MD and Ilan E. Timor-Tritsch, MD

- **Three-dimensional ultrasound, is an imaging technology that involves acquisition of a series of 2D images covering a volume from a patient that may be displayed in different orientations after the acquisition.**
- **Three-dimensional ultrasound, may be acquired and displayed over time. This is variously known as 4D ultrasound, real-time 3D ultrasound, and live 3D ultrasound.**
- **When used in conjunction with 2D ultrasound, 3D ultrasound has added diagnostic and clinical value for select indications and circumstances in obstetric and gynecologic ultrasound.**
- **Volumetric acquisition of sonographic data with subsequent offline review and interpretation has the potential to improve patient throughput, efficiency of clinical practice, and teleimaging interpretation.**



3D/4D Ultrasonography

- **2D ultrasonography is the most important method used in obstetrics**
- **Wide usage of 3D/4D ultrasonography leads to question of its necessity in pregnancy follow-up.**
- **3D/4D ultrasonography is found to be efficient in analysis of some anomalies better than 2D.**
- **It is important in the detection of fetal body's protrusion anomalies: neural tube defect, omphalocele, gastroschisis.**
- **Fetal cardiac anomalies.**
- **American Institute of Ultrasound in medicine. Acoustic output measurement standards for diagnostic ultrasound equipment. Laurel (MD): AIUM; 1998**

- **Studies focusing on the added value of 3D capabilities to 2D ultrasound have shown that 3D volume sonography provides important diagnostic information for gynecologic evaluation of uterine duplication anomalies and for optimal evaluation of the uterine cavity.**
- **In the assessment of fetal anomalies, 3D ultrasound can enhance the prenatal characterization of congenital defects, such as facial and skeletal anomalies**

Clinical Utility of 3D and 4D Ultrasound (Gynecology)

- **Assessment for congenital anomalies of the uterus;**
- **Evaluation of the endometrium and uterine cavity with or without saline infusion sonohysterography;**
- **Mapping of myomata for planning myomectomy;**
- **Cornual ectopic pregnancies;**
- **Intrauterine device location and type;**
- **Imaging of adnexal lesions, to distinguish ovarian from tubal origin and ovarian from uterine origin;**
- **Abscess drainage in the pelvis and abdomen;**
- **Three-dimensional guidance in interventional procedures for infertility; and**
- **Evaluation and monitoring of patients with infertility, including patients with polycystic ovaries and tubal occlusion.**

Clinical Utility of 3D and 4D Ultrasound (Obstetrics)

- **Facial anomalies (eg, cleft lip and palate, micrognathia, abnormal midline profile, and genetic syndromes);**
- **Nasal bone;**
- **Ears;**
- **Central nervous system (eg, agenesis of the corpus callosum and Dandy-Walker malformation);**
- **Cranial sutures;**

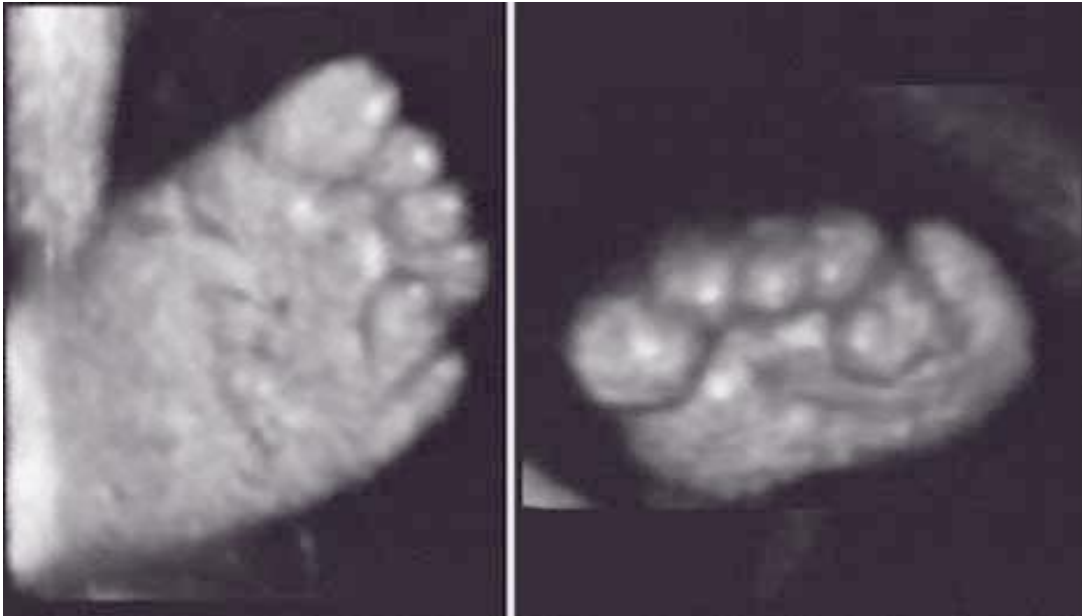
Clinical Utility of 3D and 4D Ultrasound (Obstetrics)

- **Thorax (eg, rib evaluation, intrathoracic masses, and lung volumes);**
- **Spine (eg, level of neural tube defect and vertebral abnormalities);**
- **Extremities (eg, clubfeet, amputation defects, and skeletal dysplasia);**
- **Heart (eg, conotruncal anomalies and evaluation of normal anatomy);**

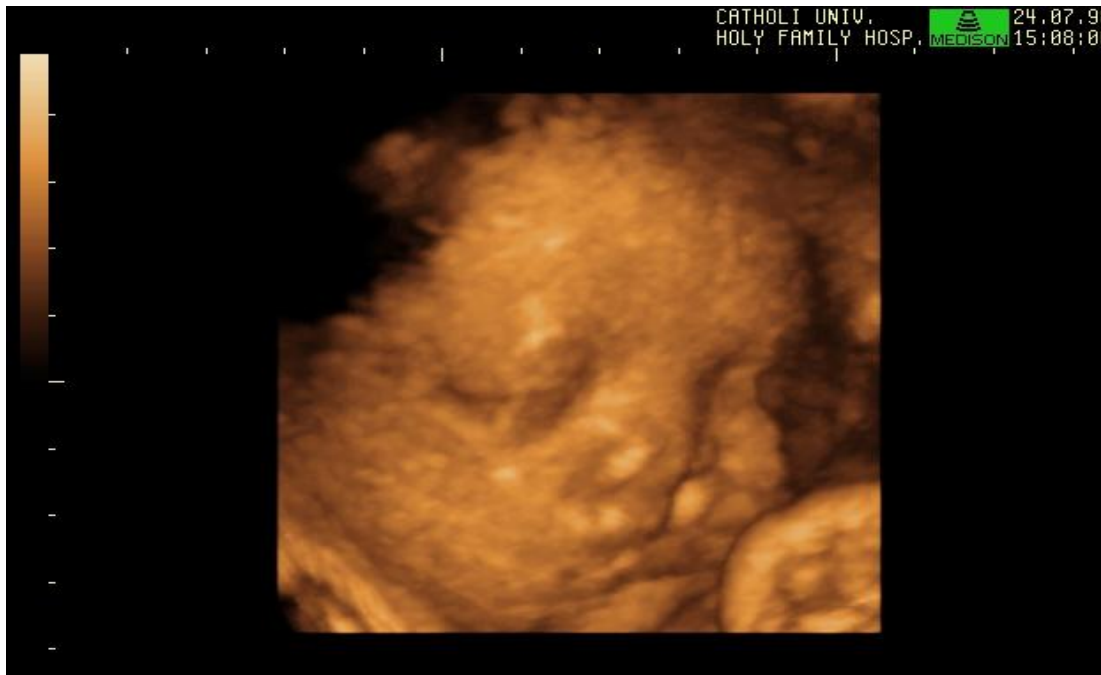Clinical Utility of 3D and 4D Ultrasound (Obstetrics)

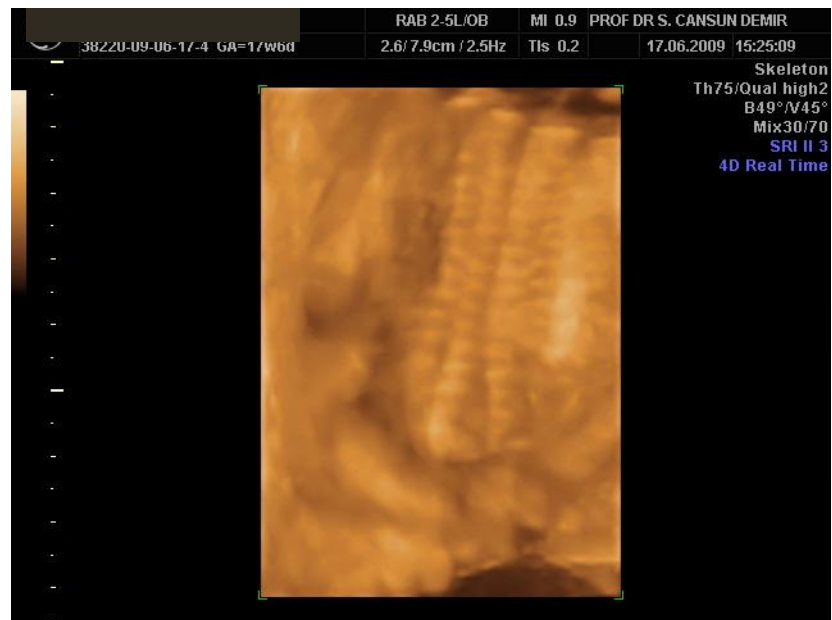
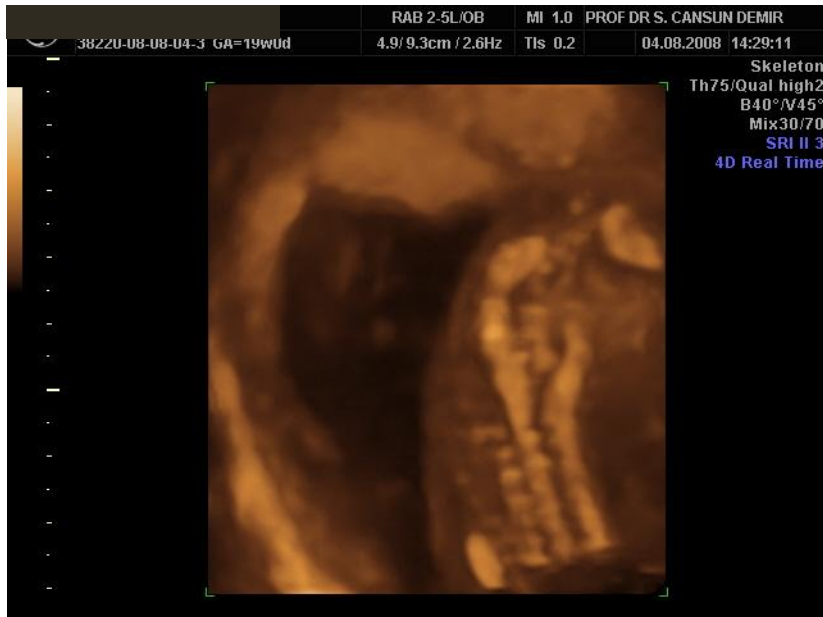- **Placenta (eg, vasa previa) such as to determine the relationship of the vessel to the internal os;**
- **Extent of anomalies, such as cystic hygroma;**
- **Multiple gestations (eg, conjoined twins and vascular mapping for twin-twin transfusion);
and**
- **Umbilical cord (eg, cord insertion sites or cord knots).**

3D image for fetal foot with six Toes.

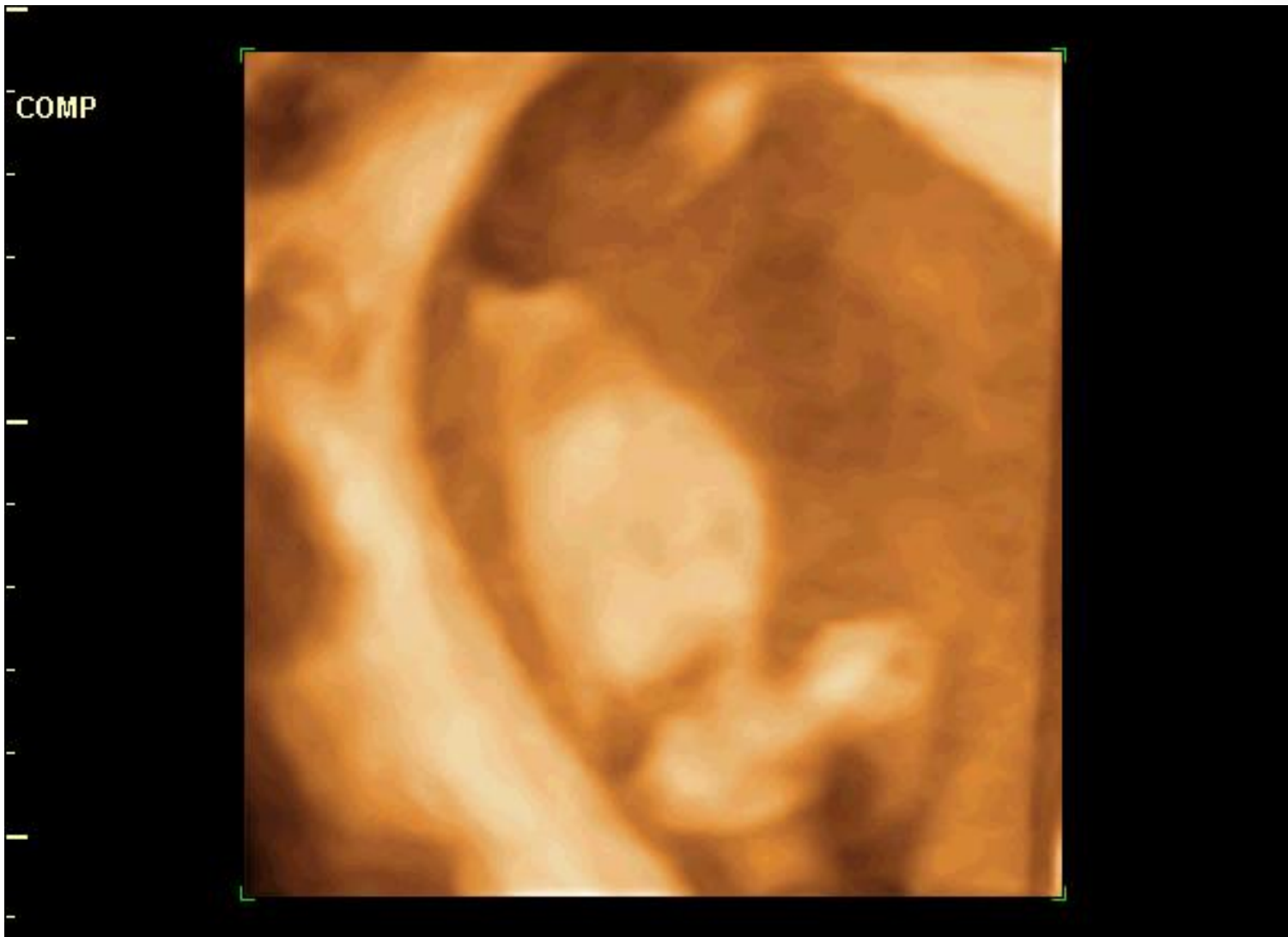


3D image for fetus with cleft lip.

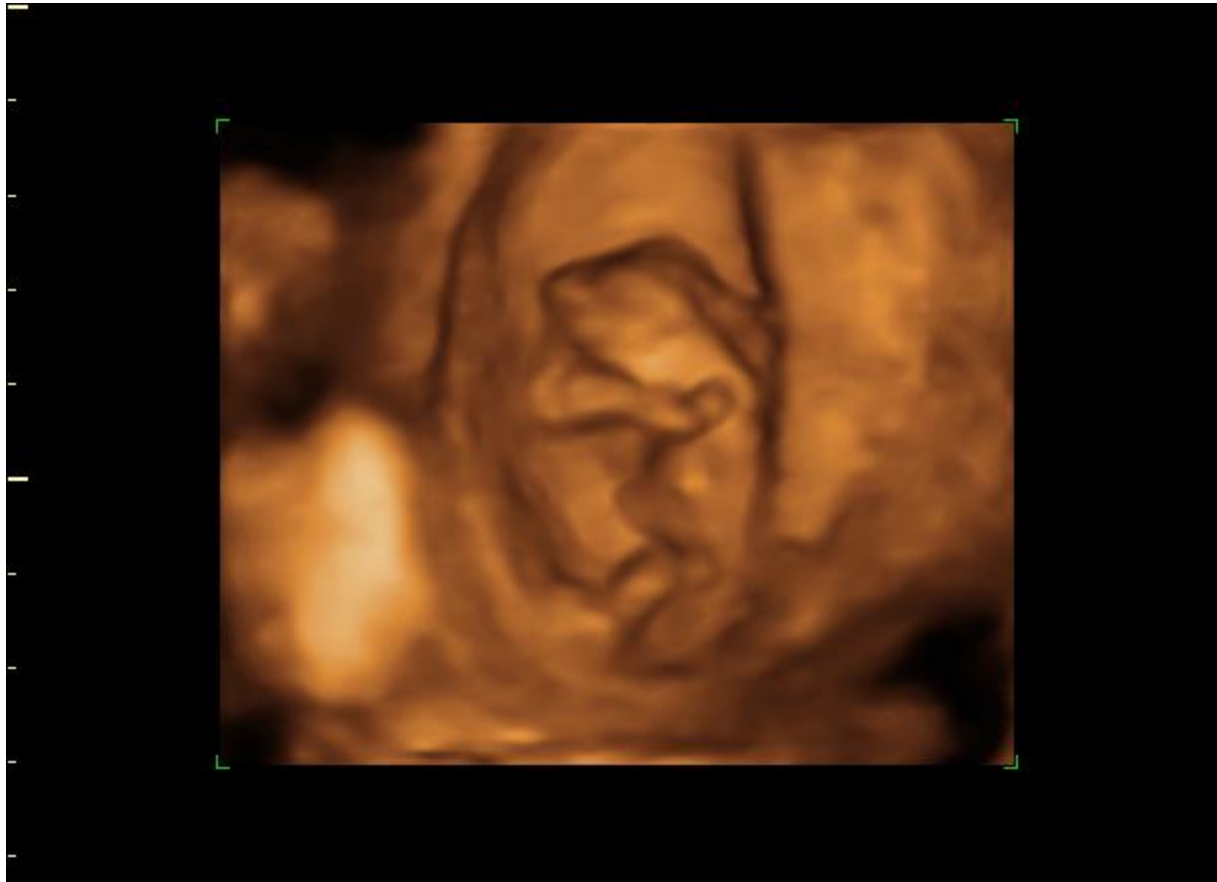




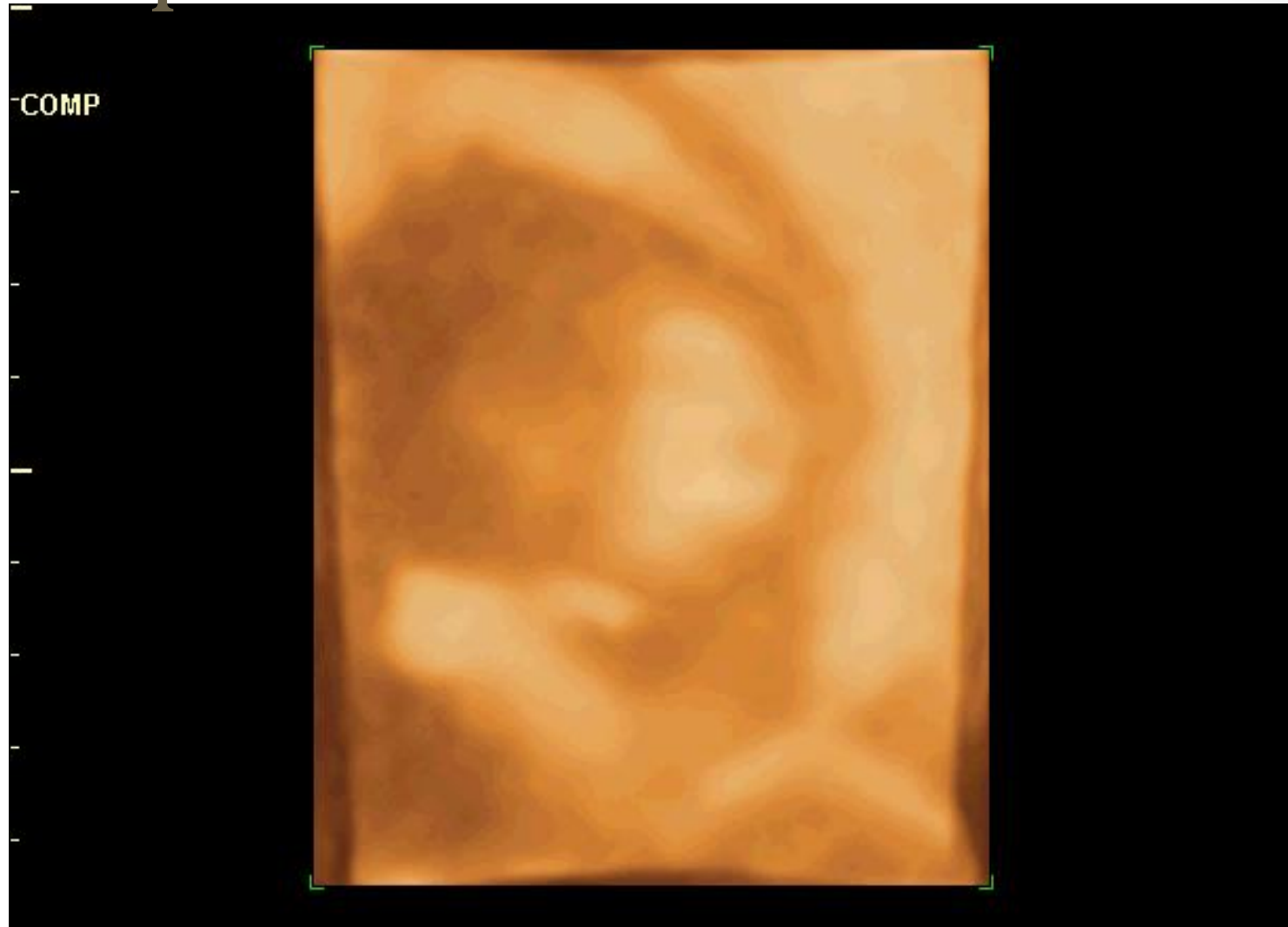
Acranii



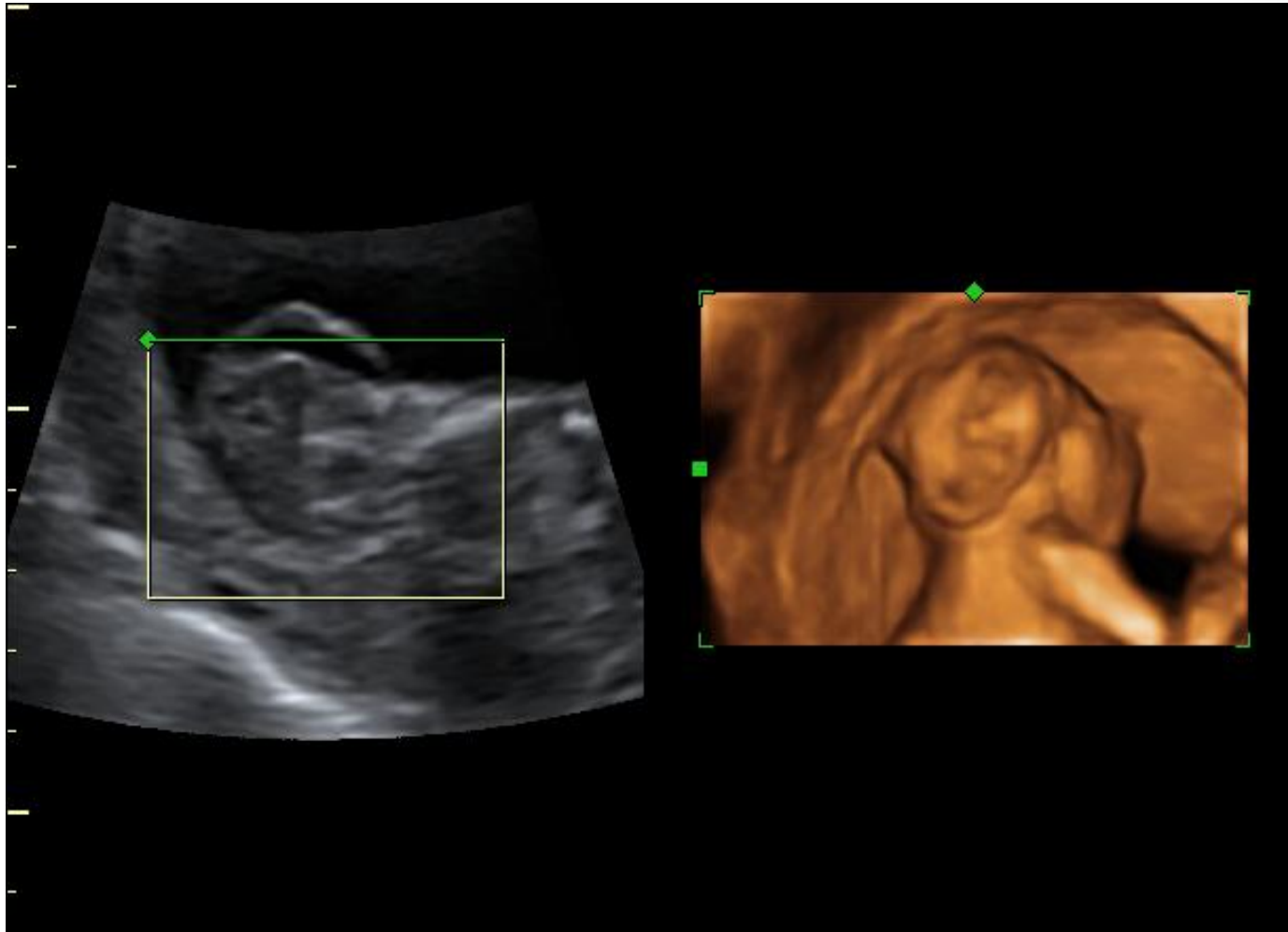
Anencephaly



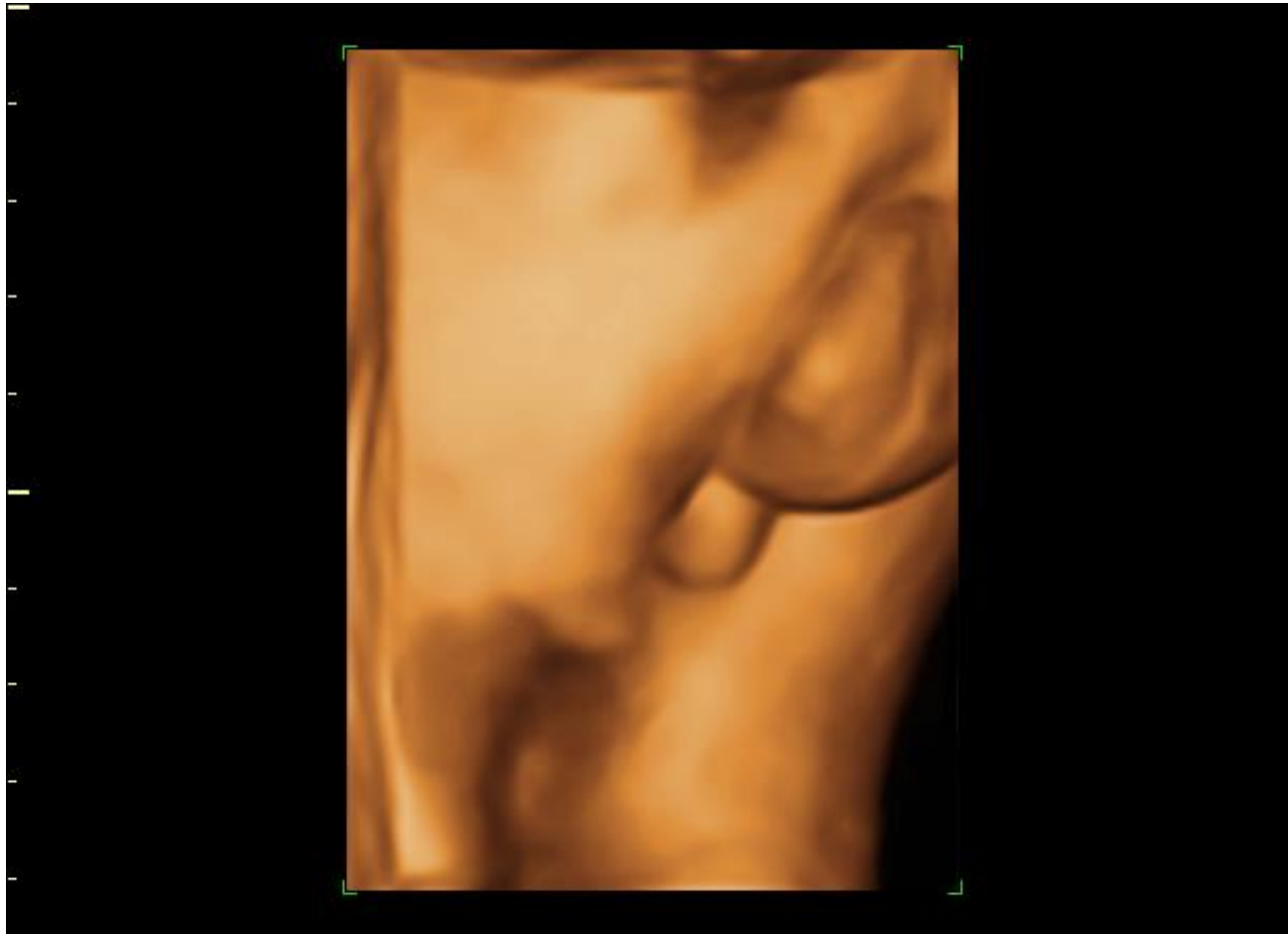Encephalocel



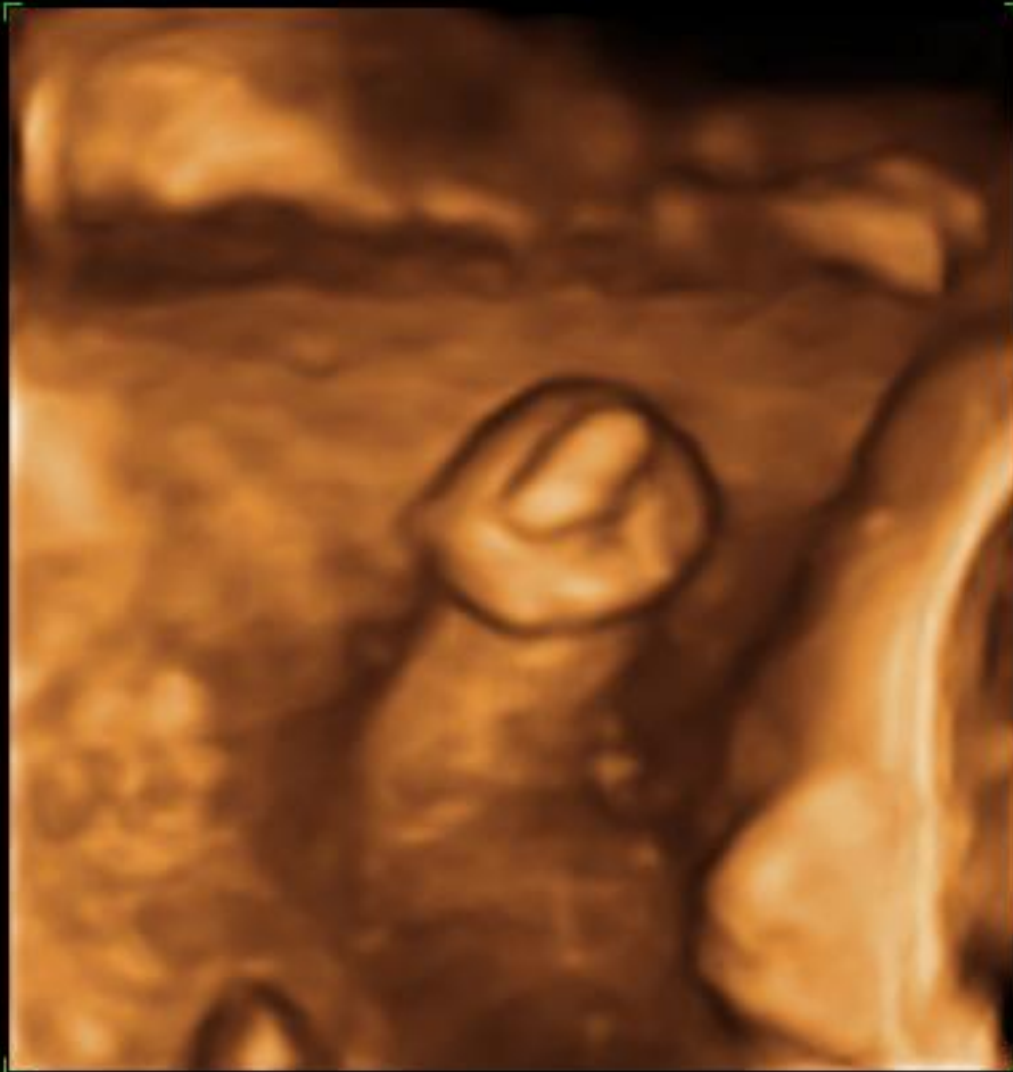Encephalocel



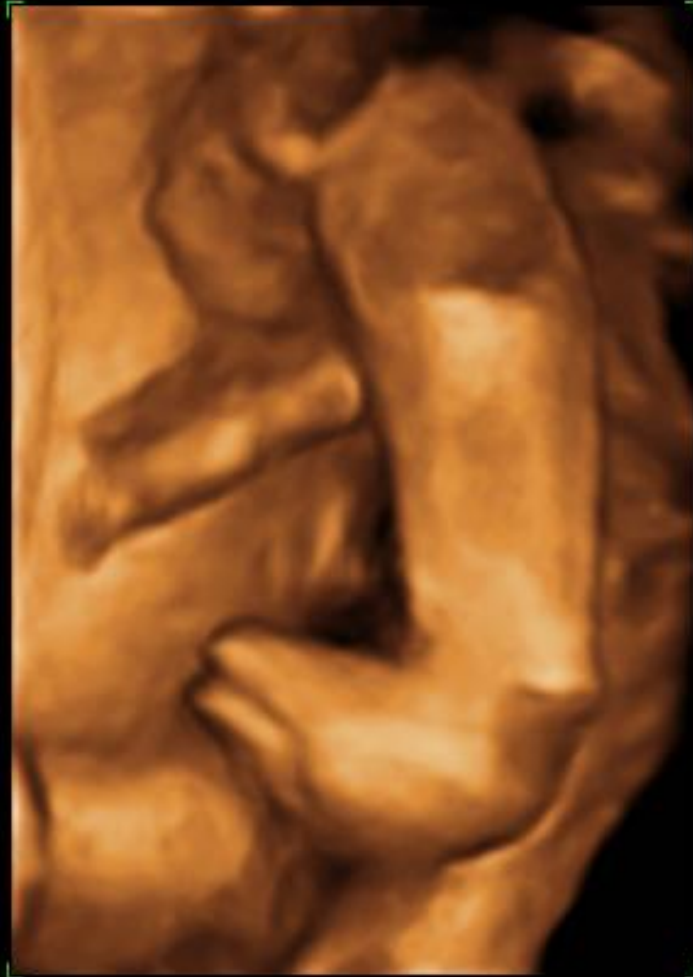Male gender



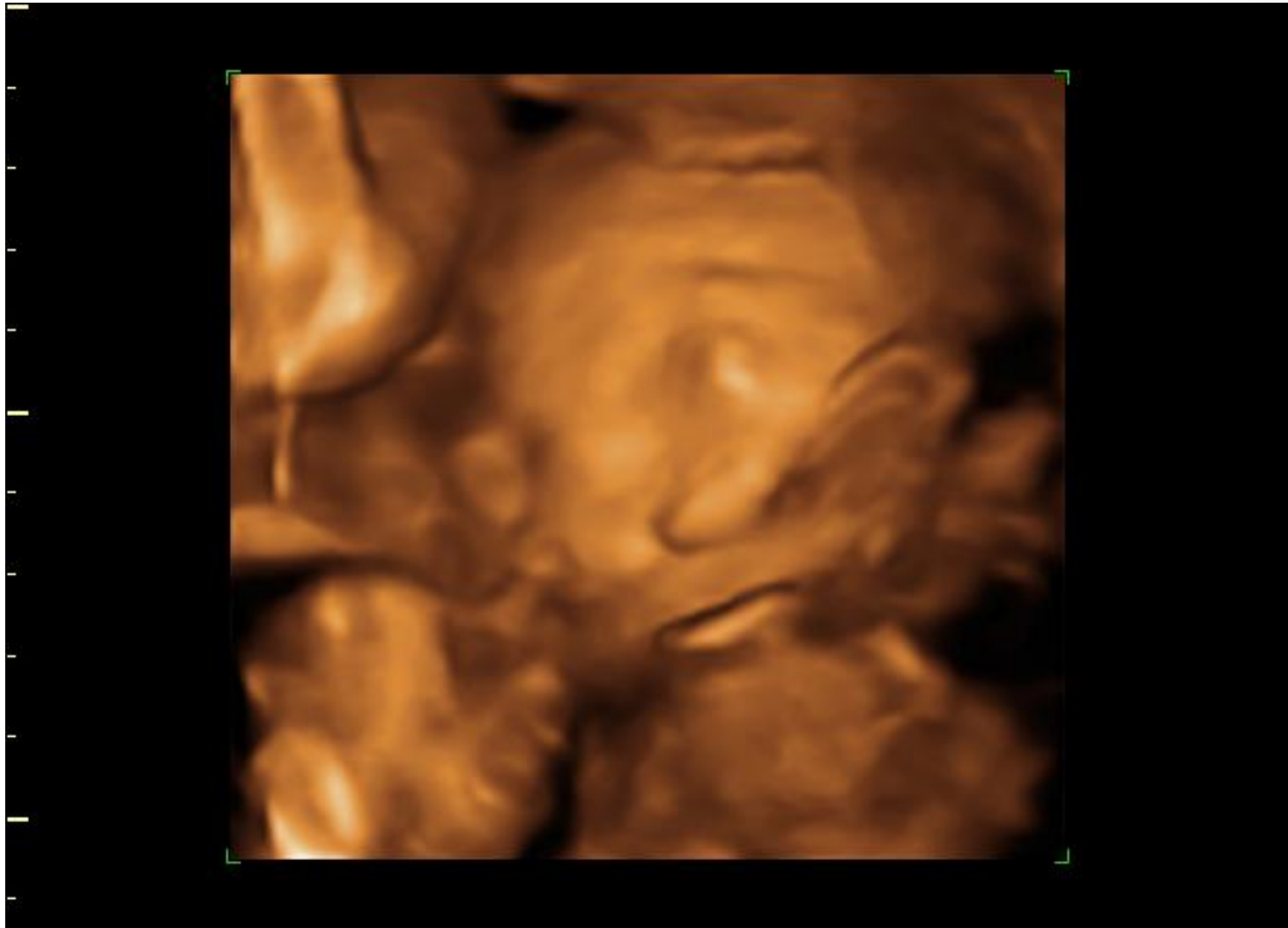Extremity



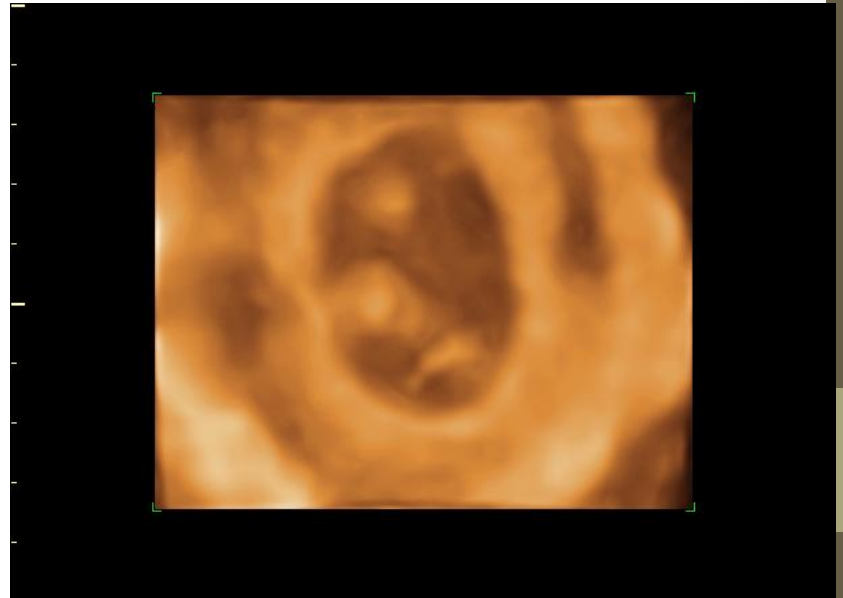
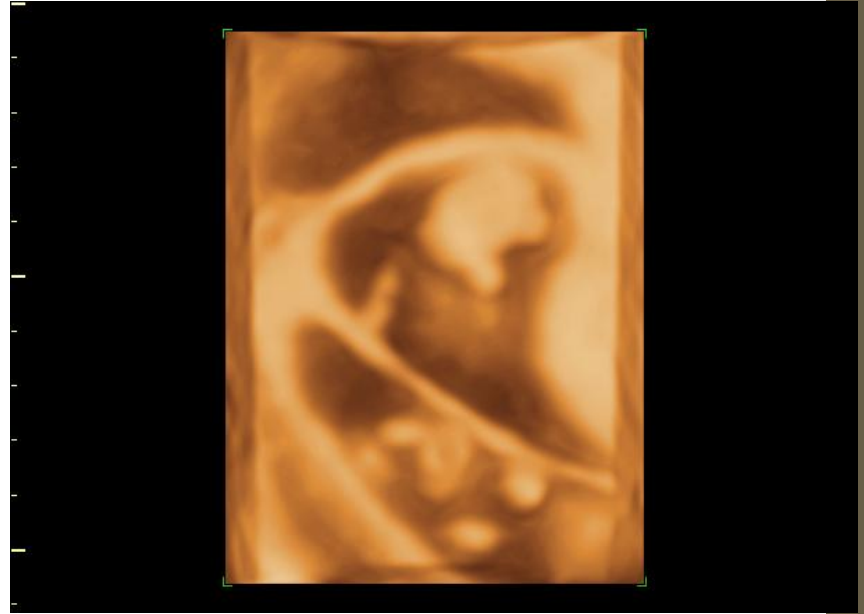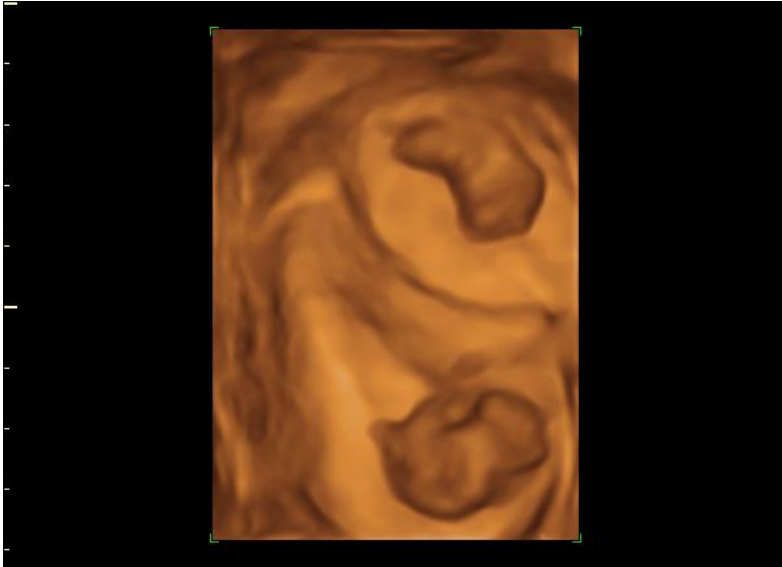
Talipes

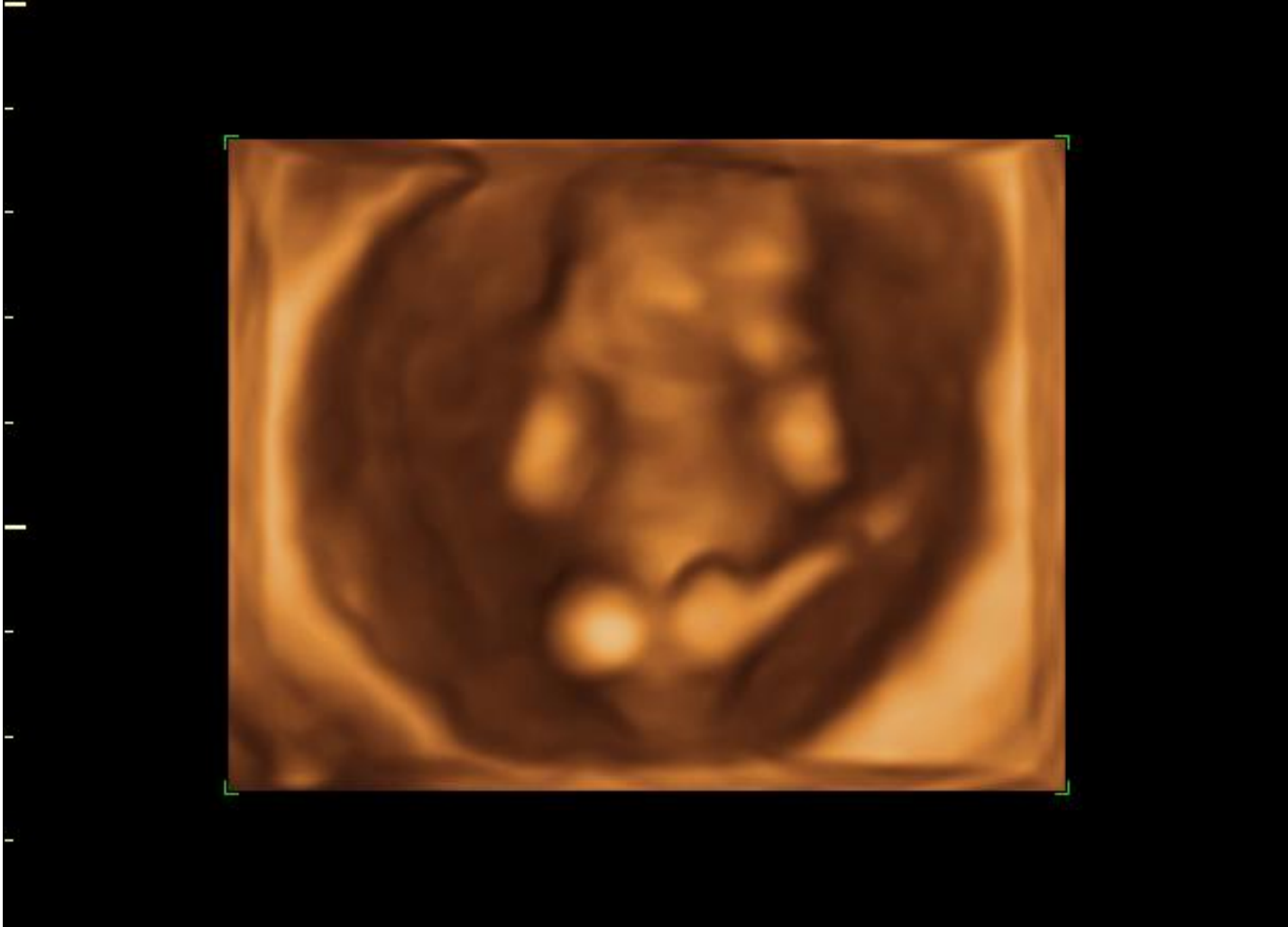

Cleft Palate

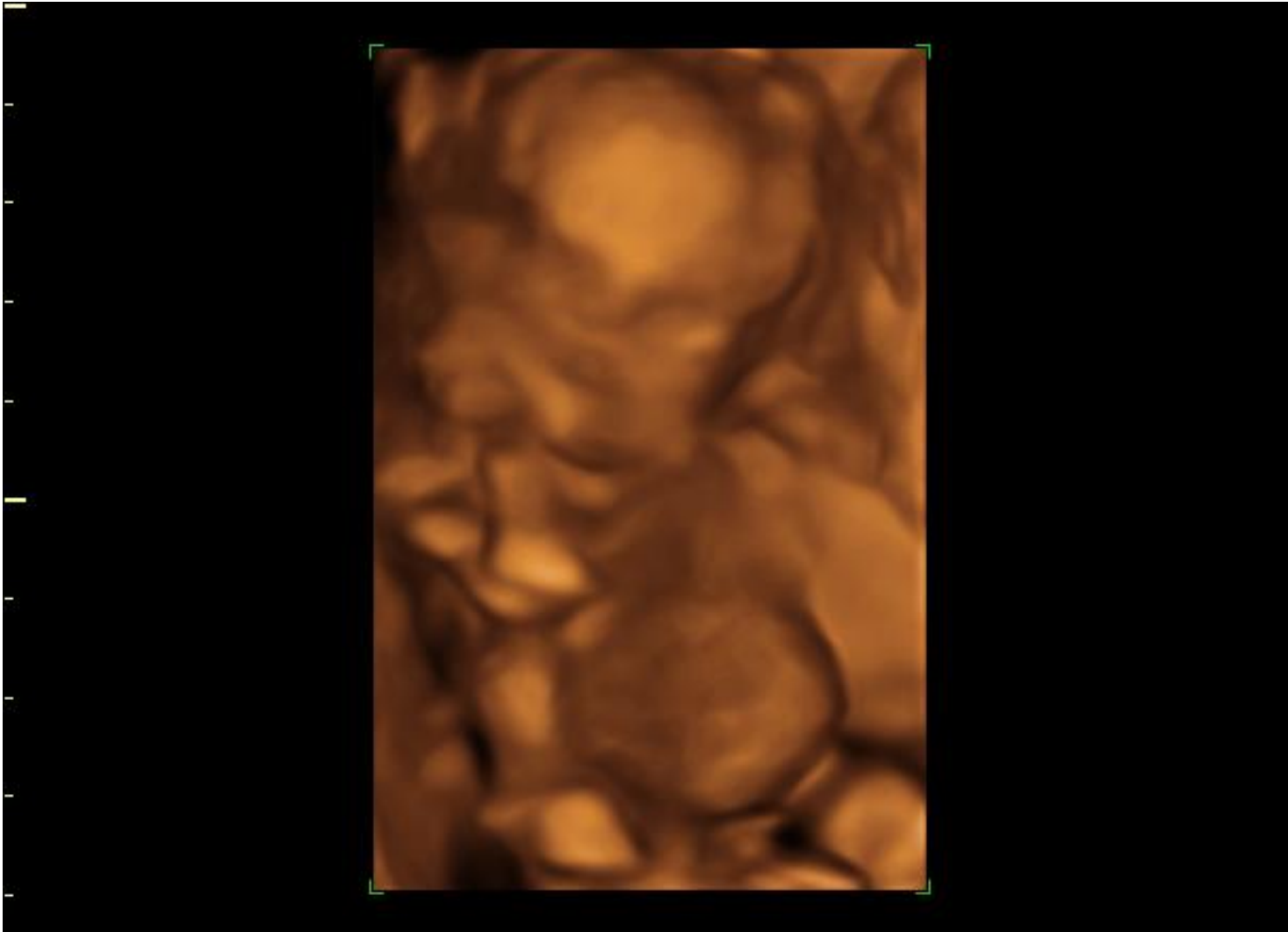


Multipl pregnancy

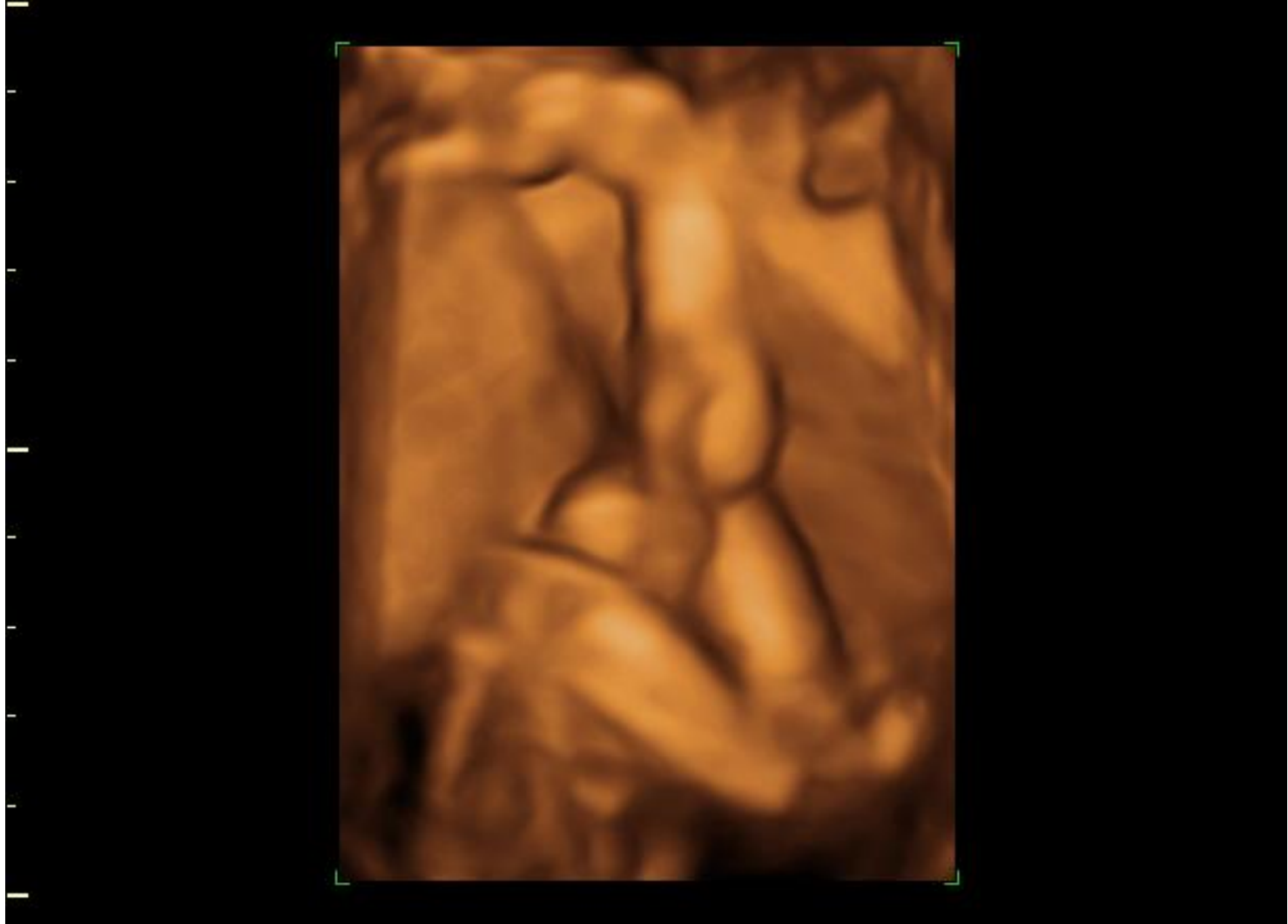



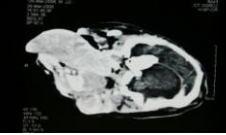











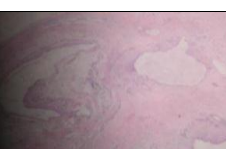




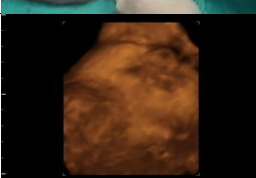



Omphalocel

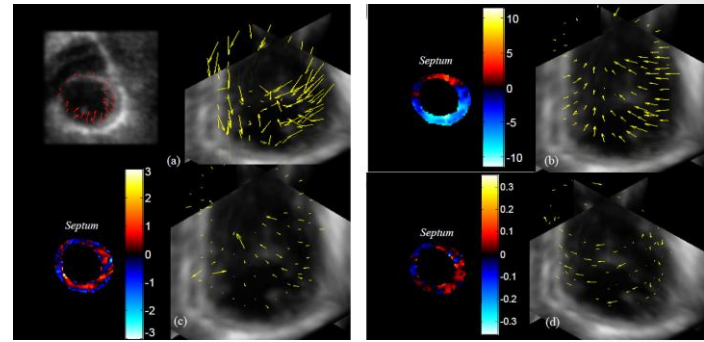


Gastrochisis



<p>CASE 1 *Oropharyngeal mass protruding from mouth *Postnatal appearance of vascular mass *Postnatal computerized tomographic appearance of the mass</p>			
<p>CASE 2 *Polyhydramnios and fetal oropharyngeal mass **3D sonographic appearance of the mass * Postnatal appearance of the protruding mass from mouth</p>			
<p>CASE 3 *Polyhydramnios and fetal oropharyngeal solid - mass *3D sonographic appearance of the mass *Endotracheal intubation by EXIT procedure</p>			
<p>CASE 4 *Cystic and solid structure of the fetal neck mass *3D sonographic appearance of the mass * Histopathologic examination of mass revealed that teratoma</p>			
<p>CASE 5 *Cystic mass with thin septa on fetal neck * Intrapartum photograph of the cystic mass in neck * Histopathologic diagnosis was lymphangioma</p>			
<p>CASE 6 *Color doppler examination of the cystic mass in fetal neck *Endotracheal intubation was performed after the delivery of the fetus</p>			
<p>CASE 7 *Calcific solid mass in fetal neck region with polyhydramnios * 3D sonographic appearance of the mass * This case had hydrops, polyhydramnios and demised in-utero and diagnosis was hamartoma</p>			

- **Three-dimensional imaging of the fetal face, either with multiplanar reconstruction or surface rendering, is a complementary technique to 2D sonography.**
- **A single volume acquisition of the fetal face can be used to reconstruct a true midline sagittal plane, often not possible with 2D ultrasound alone.**
- **Fetal nasal bone or**
- **Micrognathia.**
- **Cleft lip and palate or**
- **Orbital and mental abnormalities.**



- **Fetal echocardiography, using 3D ultrasound, is practiced by some experts in fetal imaging.**
- **They have used volume acquisitions to reconstruct images of the fetal heart to show normal cardiac structures.**
- **From a sonographic volume of the fetal heart, standardized planes of reconstruction can be displayed. In addition, automation can be used to display these standardized planes, diminishing operator dependence.**
- **Fetal heart volumes can also be acquired in real time and, with the use of gated technology, can be stored as a cine loop of the cardiac cycle. Thus, any reconstructed plane or surface-rendered image can be displayed as a cine loop of the cardiac cycle.**

3D and 4D ultrasound in fetal cardiac scanning: a new look at the fetal heart.

Yagel S, Cohen SM, Shapiro I, Valsky DV.

Department of Obstetrics and Gynecology, Hadassah-Hebrew University Medical Centers, Jerusalem, Israel.
simcha.yagel@gmail.com

Over the last decade we have been witness to a burgeoning literature on three-dimensional (3D) and four-dimensional (4D) ultrasound-based studies of the fetal cardiovascular system. Recent advances in the technology of 3D/4D ultrasound systems allow almost real-time 3D/4D fetal heart scans. It appears that 3D/4D ultrasound in fetal echocardiography may make a significant contribution to interdisciplinary management team consultation, health delivery systems, parental counseling, and professional training. Our aim is to review the state of the art in 3D/4D fetal echocardiography through the literature and index cases of normal and anomalous fetal hearts. Copyright (c) 2007 ISUOG.

PMID: 17200988 [PubMed - in process]

- **Three-dimensional color and power Doppler sonography can also be used for the assessment of extracardiac vasculature.**
- **Placental cord insertion site,**
- **Vascular anastomoses involving fetuses with twin-to-twin transfusion,**
- **Abnormal vessels from pulmonary sequestration,**
- **Aberrations of the central venous system such as an interrupted inferior vena cava with azygous venous return.**

- **Another important role of 3D ultrasound relates to the ability to store volume data that can be manipulated long after the patient has left the examination room.**
- **The acquisition of sonographic volumes rather than single tomographic or 2D images allows for storage of information that can be reconstructed in any plane or orientation for interpretation**

3D/4D Ultrasonography

Safety

- **Safety of ultrasonography is known for a long time .**
- **In human studies no side effects were detected.**
- **Especially in 3D/4D ultrasonography thermal index and mechanical index is controlled automatically , energy invasion to the rissue is minimized during sonographic examination.**

- **Stark CR et al. Short and long term risks after exposure to diagnostic ultrasound in utero. Obstet Gynecol 1984; 63; 194-200**

How Useful Is 3D and 4D Ultrasound in Perinatal Medicine

- **There are more than 580 studies published in Medicine literature for 3D and obstetrics**
 - **Facial anomalies**
 - **Neural tube defects**
 - **Skeletal anomalies**
 - **Congenital heart defect**
 - **Behaviour**

- **Kurjak A et al. How useful is 3D and 4D ultrasound in perinatal medicine. J Perinat Med 2007, 35 (1); 10-27**
- **Martin J et al. Births; final data for 2002. Natl Vital Stat rep 2003, 52 (10):1-113**

3D/4D Ultrasonography

- **3472 fetal anatomic screening, 2D vs 3D**
- **In 906 cases 1-5 anomalies**
- **Comparing 3D with 2D it is found that multiplanar tomographic investigation has 70% more accurate result**
- **Is it better than 2D to detect the severity of defect and evaluate the normality ?**

3D/4D Ultrasonography

- **99 fetus, first 3D/4D, later 2D**
- **Comparing 2D and 3D/4D for detection of anomalies is 90 %, intraclass correlation coefficient, 0.834; %95 CI, 0.774-0.879**
- **3D/4D detected 6 anomalies less than**
 - **VSD (2)**
 - **IVC blokage**
 - **Tetralogy of Fallot**
 - **Renal**
 - **Cystic adenoid malformation**
- **Comparing postpartum diagnosis, sensitivity/specificity**
- **2D %96 - %73**
- **3D/4D %92 - %76**
- **Statistically there is not significant difference**

Three- and four-dimensional ultrasonography for the structural and functional evaluation of the fetal face.

Kurjak A, Azumendi G, Andonotopo W, Salihagic-Kadic A.

Department of Obstetrics and Gynecology, Medical School University of Zagreb, Sveti Duh Hospital, Zagreb, Croatia.

Ultrasonographic examination of the fetal face can provide information that may lead to the diagnosis of anomalies in other organs or systems. Thus, the fetal face represents a "diagnostic window" for fetal diseases and syndromes. Three-dimensional ultrasonography (3DUS) improves the evaluation of anatomic fetal facial anomalies over what is possible by 2-dimensional ultrasonography (2DUS). Four-dimensional ultrasonography (4DUS), by adding the temporal component to the examination, allows visualization of facial expressions that might be useful in the study of fetal behavior and maternal-fetal bonding. In this article, we evaluate the potential of 3D/4DUS for the study of structural and functional development of the fetal face.

PMID: 17014807 [PubMed - indexed for MEDLINE]

Prenatal detection of fetal growth restriction by fetal femur volume: efficacy assessment using three-dimensional ultrasound.

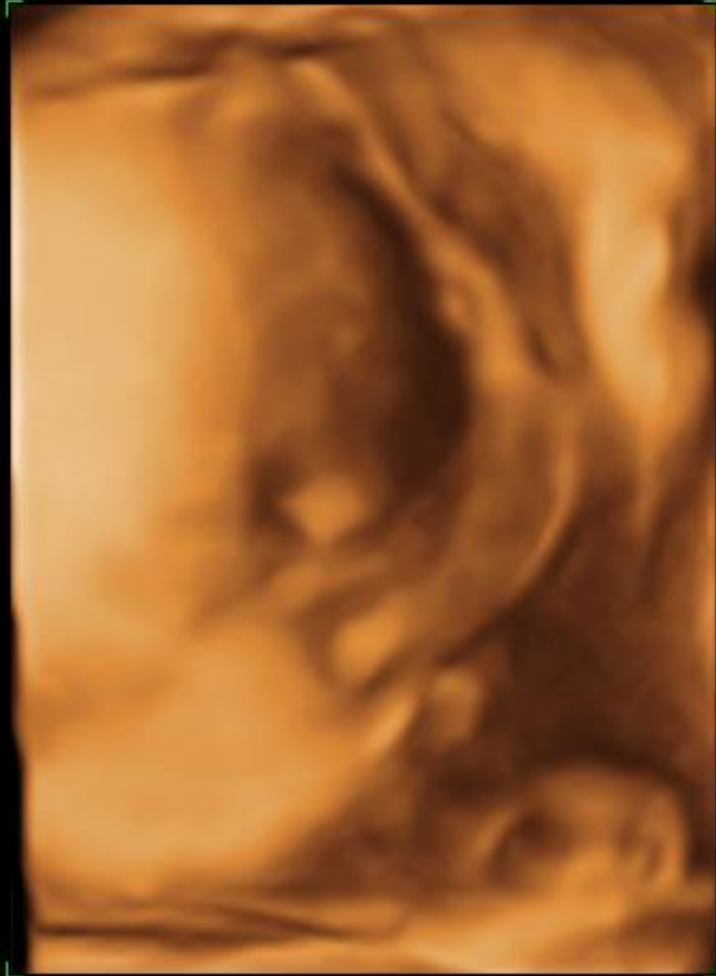Chang CH, Tsai PY, Yu CH, Ko HC, Chang FM.

Department of Obstetrics and Gynecology, National Cheng Kung University Medical College, Tainan, Taiwan.

As fetal growth restriction (FGR) may have increased risks with perinatal morbidity and mortality, it is very important to detect FGR prenatally. Fetal femur dysplasia is associated with a variety of congenital syndromes and FGR as well. To date, no prenatal assessment of fetal FV in predicting FGR using three-dimensional (3D) ultrasound (US) has been reported. In this study, we used 3D US to test the efficacy of fetal femur volume (FV) measurement in predicting FGR. We calculated the sensitivity, specificity, positive predictive value (PPV), negative predictive value (NPV) and efficacy of fetal FV assessed by 3D US in detecting FGR according to the Bayes' theorem. All the fetuses were singletons and were followed up to delivery to determine whether they were complicated with FGR or not. In total, 304 fetuses without FGR and 42 fetuses with FGR were included for FV assessment in utero by 3D US. Our results showed fetal FV assessed by 3D US can differentiate fetuses with FGR from fetuses without FGR well. The best predicting threshold for FGR is at the 10th percentile of FV. Using the 10th percentile as the cutoff, the sensitivity of fetal FV in predicting FGR was 71.4%, specificity 94.1%, positive predictive value 62.5%, negative predictive value 96.0% and accuracy 91.3%. In addition, fetal FV is superior to fetal biparietal diameter and fetal abdominal circumference in predicting FGR. In conclusion, fetal FV assessed by 3D US can be applied to detect FGR well prenatally. We believe fetal FV assessment by 3D US would be a useful test in detecting fetuses with FGR.

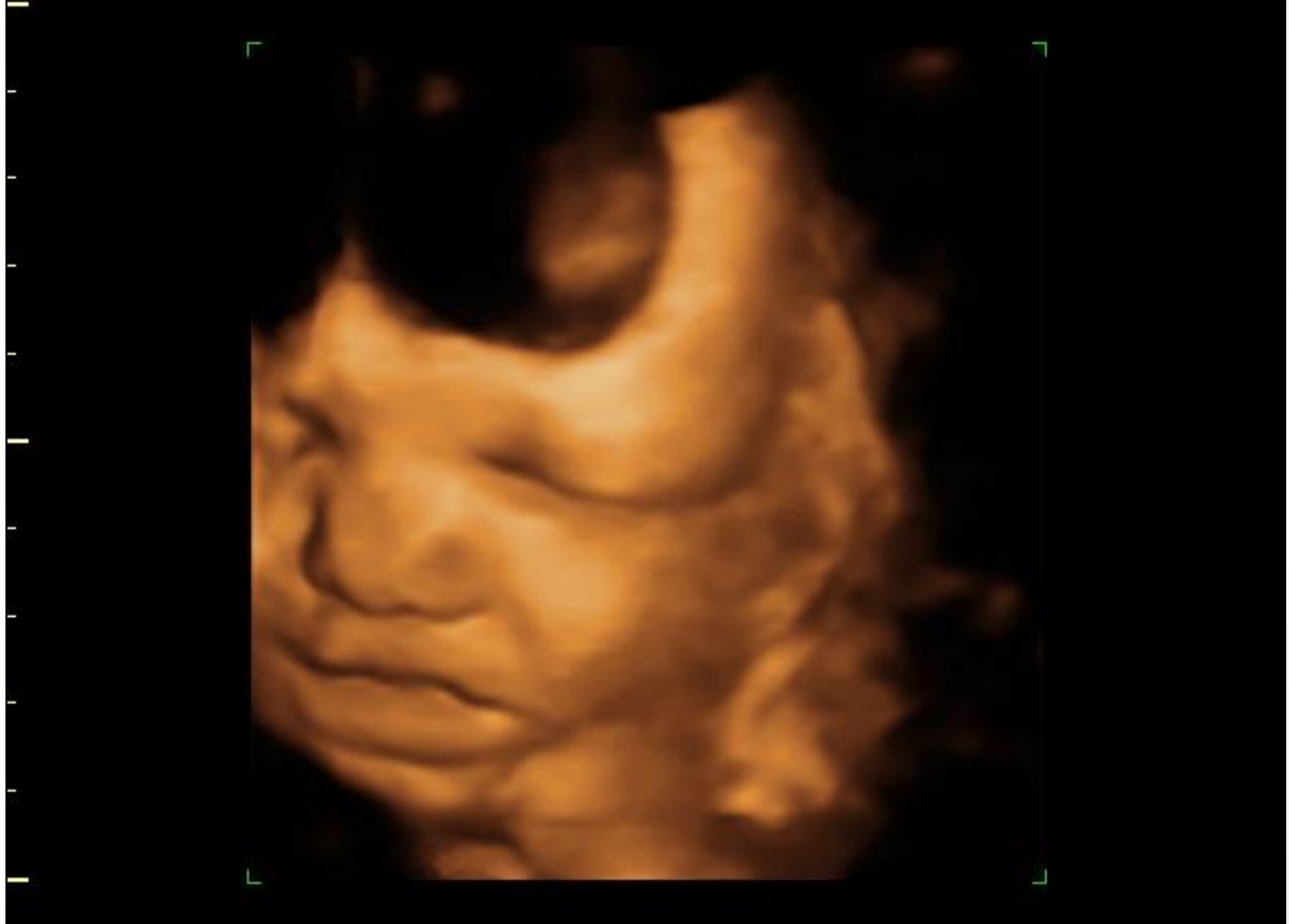Fetal Behaviour of IUGR Fetuses by 4D USG

- **Fetal face mimics, body movement quality**
- **Effect of brain development ?**
- **IUGR – decreased movement, number, order**
 - **Hand-head movement**
 - **Hand-face movement**
 - **Head retroflexion**
- **Good for antenatal knowledge but advantage ?**
- **Andonotopo W et al. The assessment of fetal behaviour of growth restricted fetuses by 4D ultrasound. J Perinatol Med 2006, 34 (6);471-8**



3D/4D Ultrason

- **The effects on maternal anxiety of 2D vs. plus 3D/4D ultrasound in pregnancies at risk of fetal abnormalities; A randomized study**
- **It is found that , 80% of the women said that usage of 3D ultrasonography is more convincing, comparing to 2D to say the fetus is normal.**
- **But anxiety is not found to be statistically lower.**

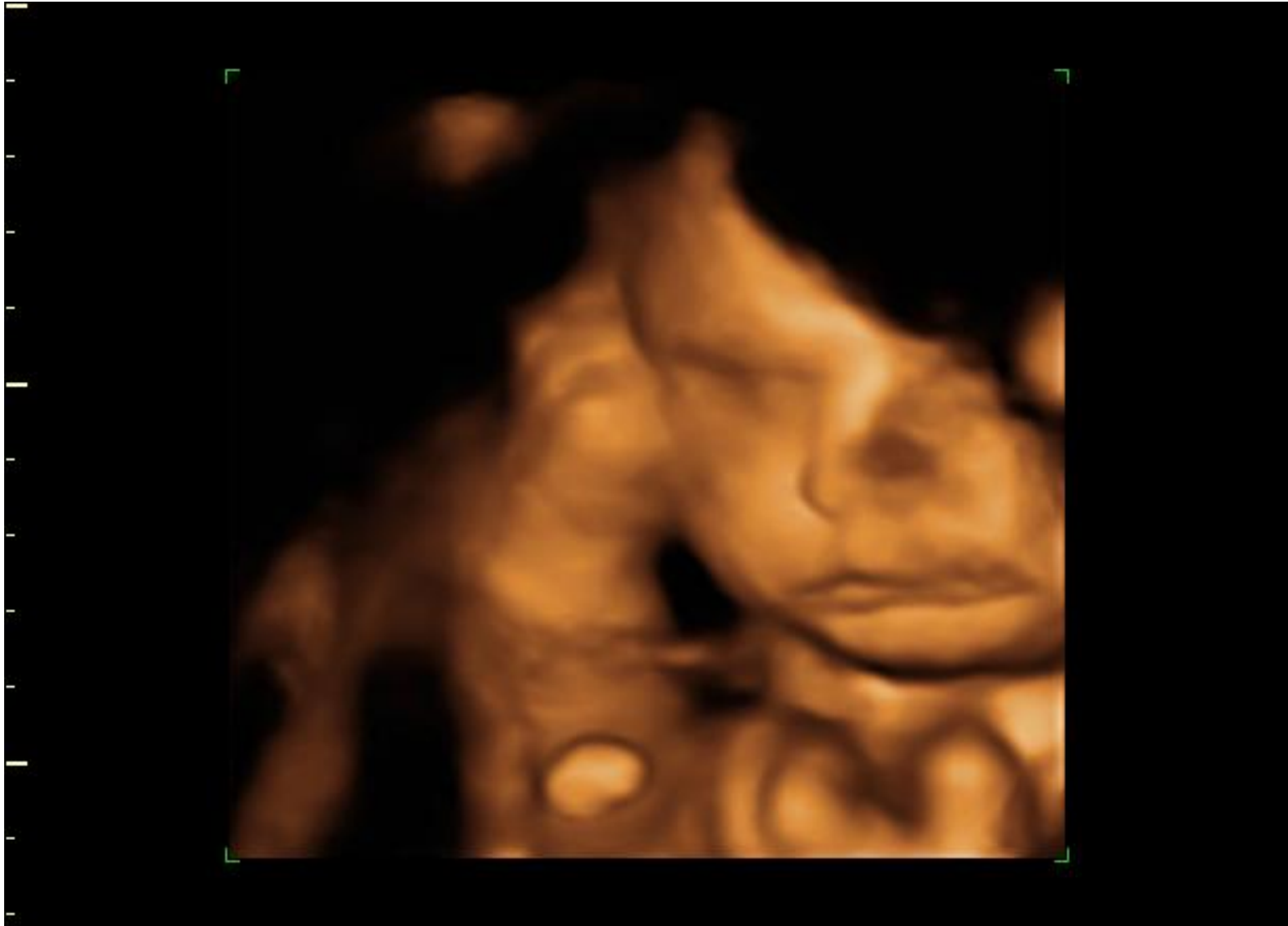

Maternal/paternal antenatal attachment and fourth-dimensional ultrasound technique: a preliminary report.

Righetti PL, Dell'Avanzo M, Grigio M, Nicolini U.

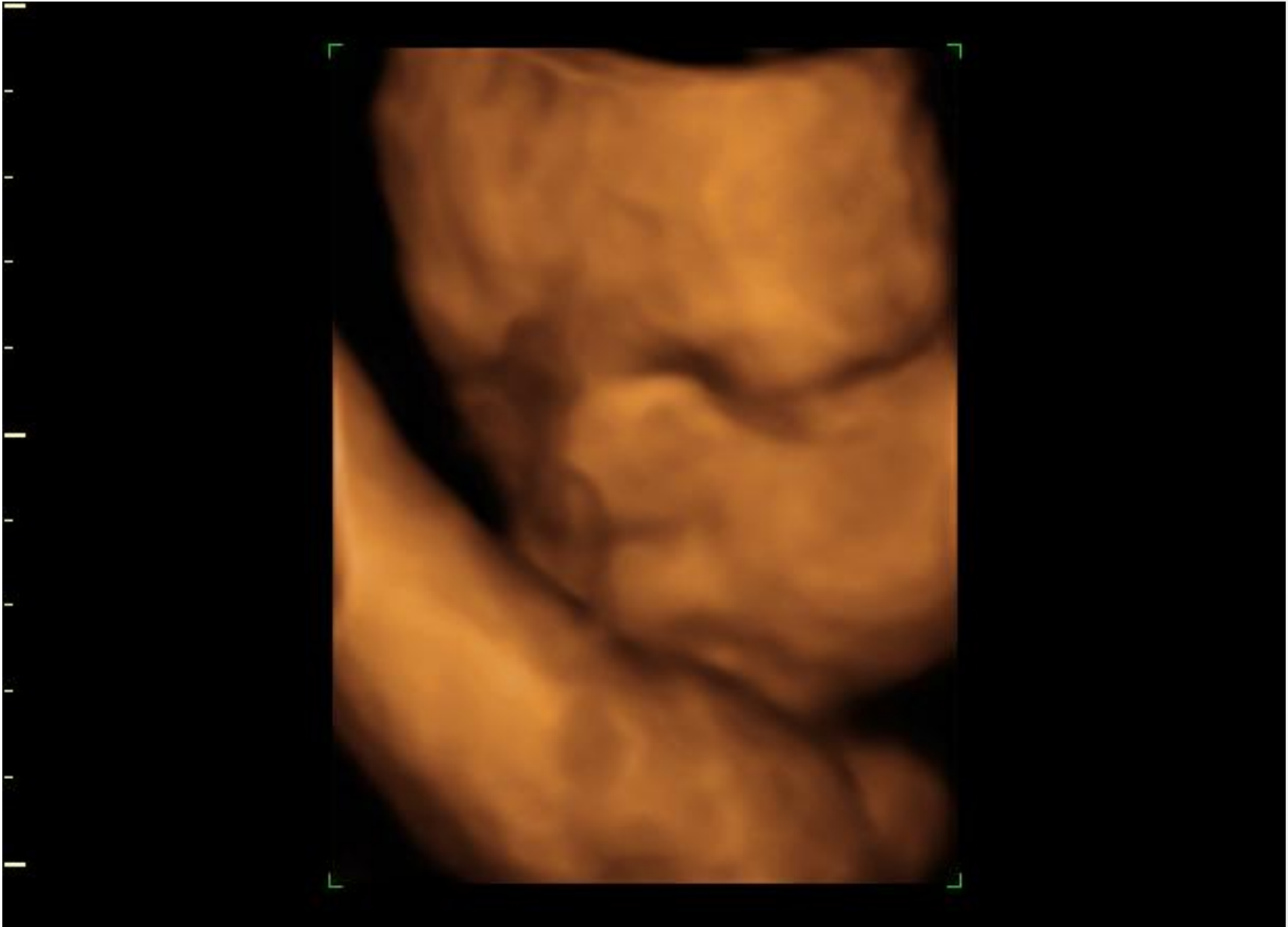Department of Obstetrics and Gynaecology, Conegliano Hospital,
Veneto, Italy. pl.righetti@libero.it

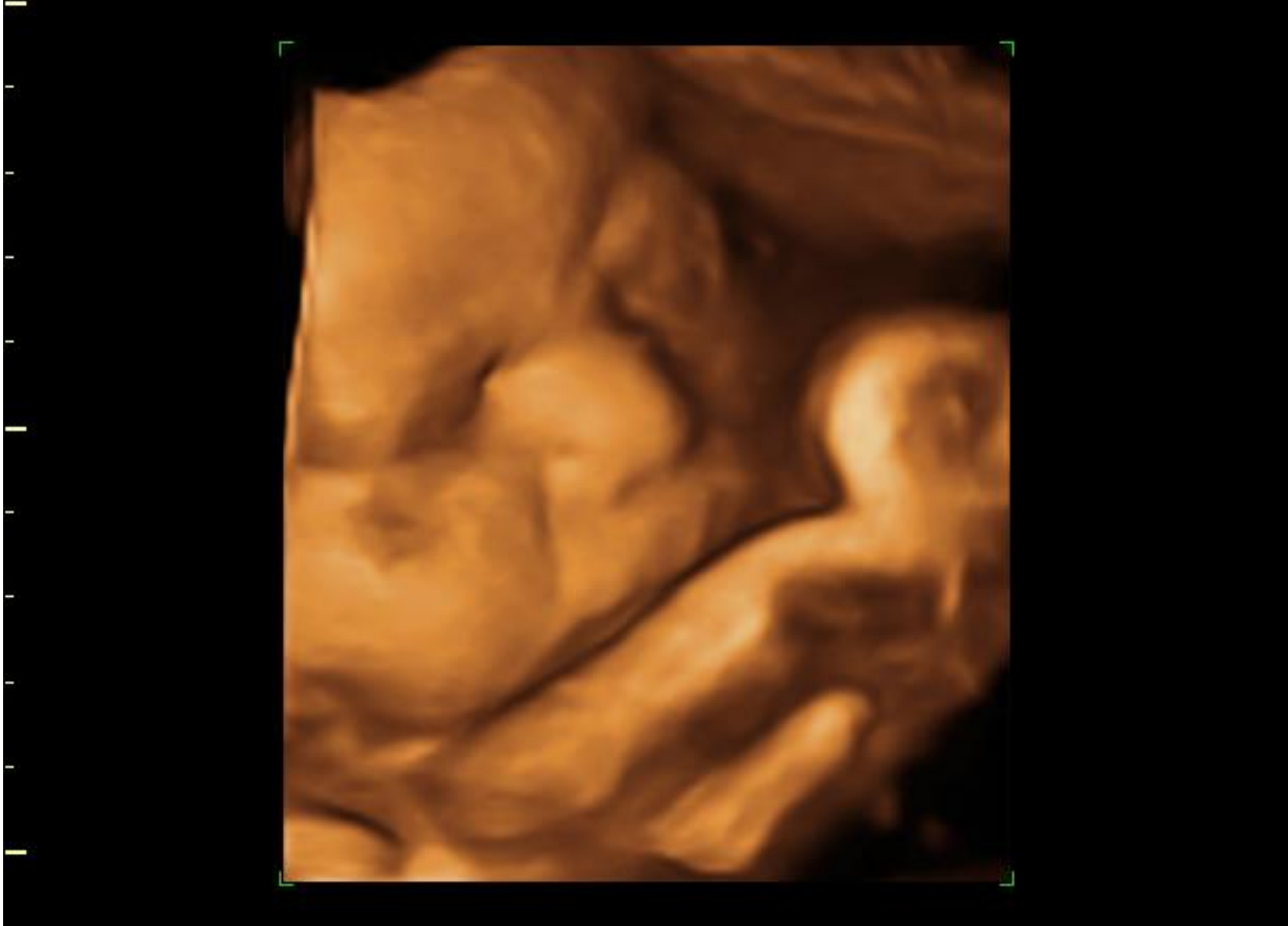The purpose of the present research was to investigate the role of the fourth dimensional (4D) ultrasound scanning on the antenatal attachment development, in pregnant women (19-23 weeks of gestation) and their partners. A total of 44 couples were asked to complete questionnaires about maternal and paternal antenatal attachment, before the two-dimensional (2D; control group) and 4D (experimental group) ultrasound scanning and 2 weeks later. In the groups of women, our findings underline the progressive increase in antenatal attachment throughout gestation: the mean level of antenatal attachment was significantly different between the first and the second assessment. No significant differences are shown between 2D and 4D ultrasound scanning groups. We do not eliminate the possibility that ultrasound scanning practice would be a helpful and crucial means of investigation for a complete explanation of prenatal attachment (Ainsworth, Blehar, Waters, & Wall, 1978; Fivaz-Depeursinge & Corboz-Warney, 2000) and parental mental representations (Stern, 1987, 1997).



3D/4D Ultrasonography

- **Psychologic bondage between mother and the baby with 2D and 3D/4D ultrasonography.**
- **In some studies this bondage is shown to be stronger with ultrasonography and in long term, both mother and fetus is found to have less disease.**
- **Is 3D/4D ultrasonography more effective**
- **Rados C. FDA cautions against ultrasound keepsake images. FDA Consum 2004; 38 (1); 12-6**





4D Ultrasonography in invasive procedures

- **4D for Prenatal invasive diagnosis and treatment ;, 93 fetus**
- **Amniosentesis, amnioinfusion, CVS, cordosentesis**
- **Procedure mean time : 5 mins. 100 % success**
- **Time shorter and complication risk is lower.**
- **Kim S et al. 4D ultrasound guidance of prenatal invasive procedures. Ultrasound Obstet Gynecol 2005, 26 (6); 663-5**

Three-dimensional ultrasound in prenatal diagnosis.

Chaoui R, Heling KS.

Center for Prenatal Diagnosis and Human Genetics, Berlin, Germany.

PURPOSE OF REVIEW: Several technological advances have greatly improved three-dimensional sonography, which have improved acquisition and display capabilities. This review describes these technical changes as well as current applications of 3D sonography in prenatal diagnosis. **RECENT FINDINGS:** Recently published papers have emphasized the potential of getting a precise 'any plane of choice' from a three-dimensional volume, as a new way of scanning, based on the off-line analysis of a volume dataset. Surface mode has been used to demonstrate malformations and genetic diseases. The maximum rendering mode, which highlights bones, has great potential for imaging the nasal bones and the frontal bones with the metopic suture. Organ volume can be measured, but the utility of this in clinical practice remains to be determined. Three-dimensional ultrasound needs to be standardized. **SUMMARY:** Three-dimensional ultrasonography is the most rapidly developing technique in fetal imaging. New features will permit the transition from the era of 'sonography in two-dimensional planes' to 'volume ultrasound'.

PMID: 16601481 [PubMed - in process]

Three-dimensional volume-rendered imaging of embryonic brain vesicles using inversion mode

- **Twenty-three women who were between 7.4 and 9.7 weeks of gestation were studied using 3D ultrasound**
 - **Normal embryonic brain vesicle shapes in the early first trimester of pregnancy, reconstructed by three-dimensional (3D) volume-rendered imaging using the inversion mode**
 - **Results suggest that transvaginal 3D volume-rendered imaging using the inversion mode provides accurate visualization of embryonic brain vesicle structures in utero**
- **Department of Perinatology and Gynecology, Kagawa University School of Medicine, Miki, Kagawa, Japan. J Obstet Gynaecol Res. 2009 Apr;35(2):258-61**

Maternal Obesity and Fetal Anomaly Screening 2D

- **Fetal anatomy ultrasound screening**
 - **American Institute of Ultrasound in Medicine (AIUM)**
 - **Over 25 structures**
- **18-22 weeks of gestation**

- **Variable sensitivity**
 - **34-60%**
 - **Decreases with increased BMI**

 - **Absence of markers, 80% reduction in Down syndrome risk**
 - **Experience**
 - **Standardization**

Obesity 2D

- **Significant ultrasound impairment**
- **Visualization decreases**
- **Mostly cardiac and spine + others**

- **Suboptimal visualization**
 - **Obesity 17%**

Maternal Obesity and Fetal Anomaly Screening 3D/4D

- **18-24 weeks**
- **11,000+ cases**
- **Body mass index (BMI) >25**
- **BMI >25, >30, >40**
- **Sensitivity decreases from %66' to %49, %25 '**
- **Advantage of 3D/4D ?**
 - **Dashe et al. Obstetrics/Gynecology, May, 2009.**

Conclusion

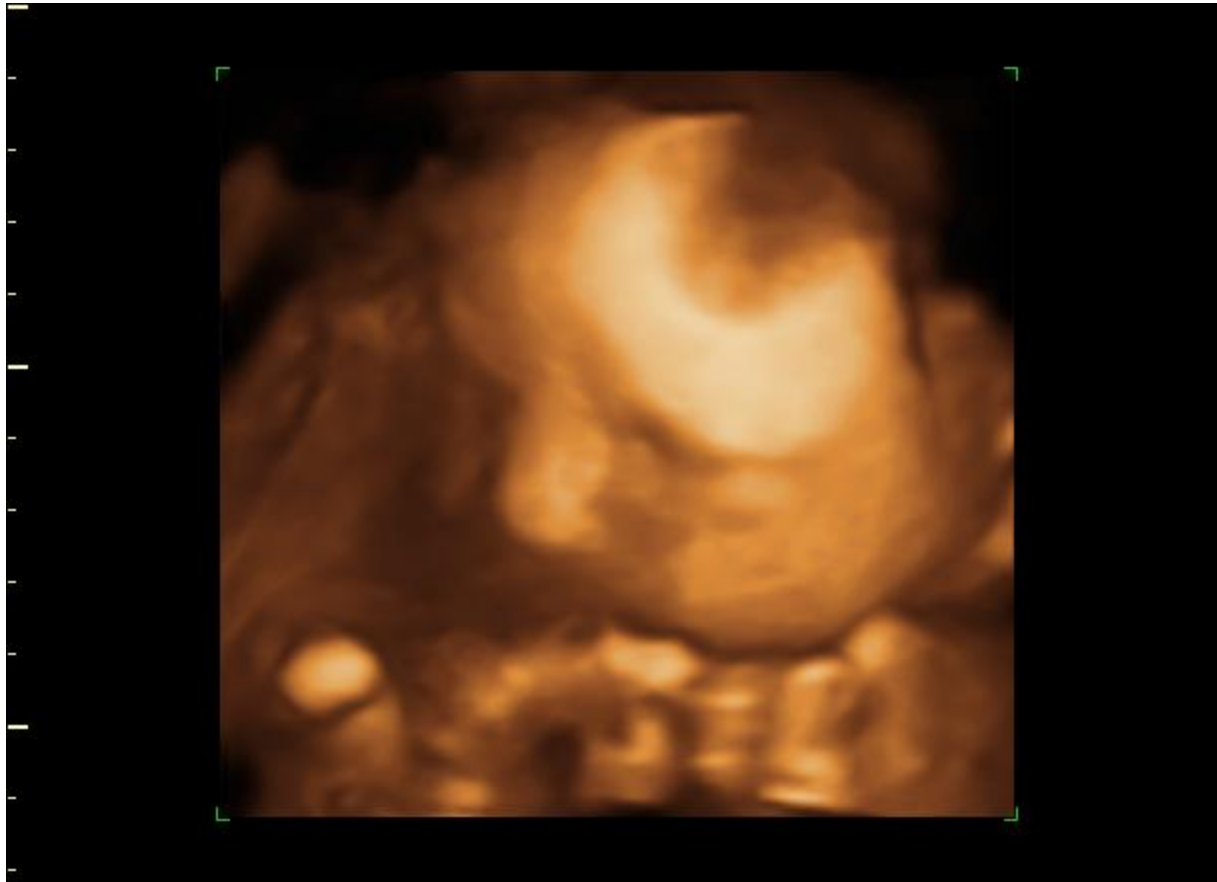- **Routine usage of 2D + 3D/4D is the most beneficial application**
- **Safe, no side effects**
- **Ideal for volumetric examination**
- **Better for invasive procedures**
- **Good for Mother-baby bondage and mother anxiety**
- **3D/4D is better for detection of some anomalies**
- **Soft tissue, protrusion, heart**

Conclusion-2

- **Tomographic views of 4D will be anatomically reconstructed by the computer and better results comparing to 2D or 3D for organs and measurements.**
- **4D examination will be shortened.**
- **Detection of abnormalities will be near to 100 %.**

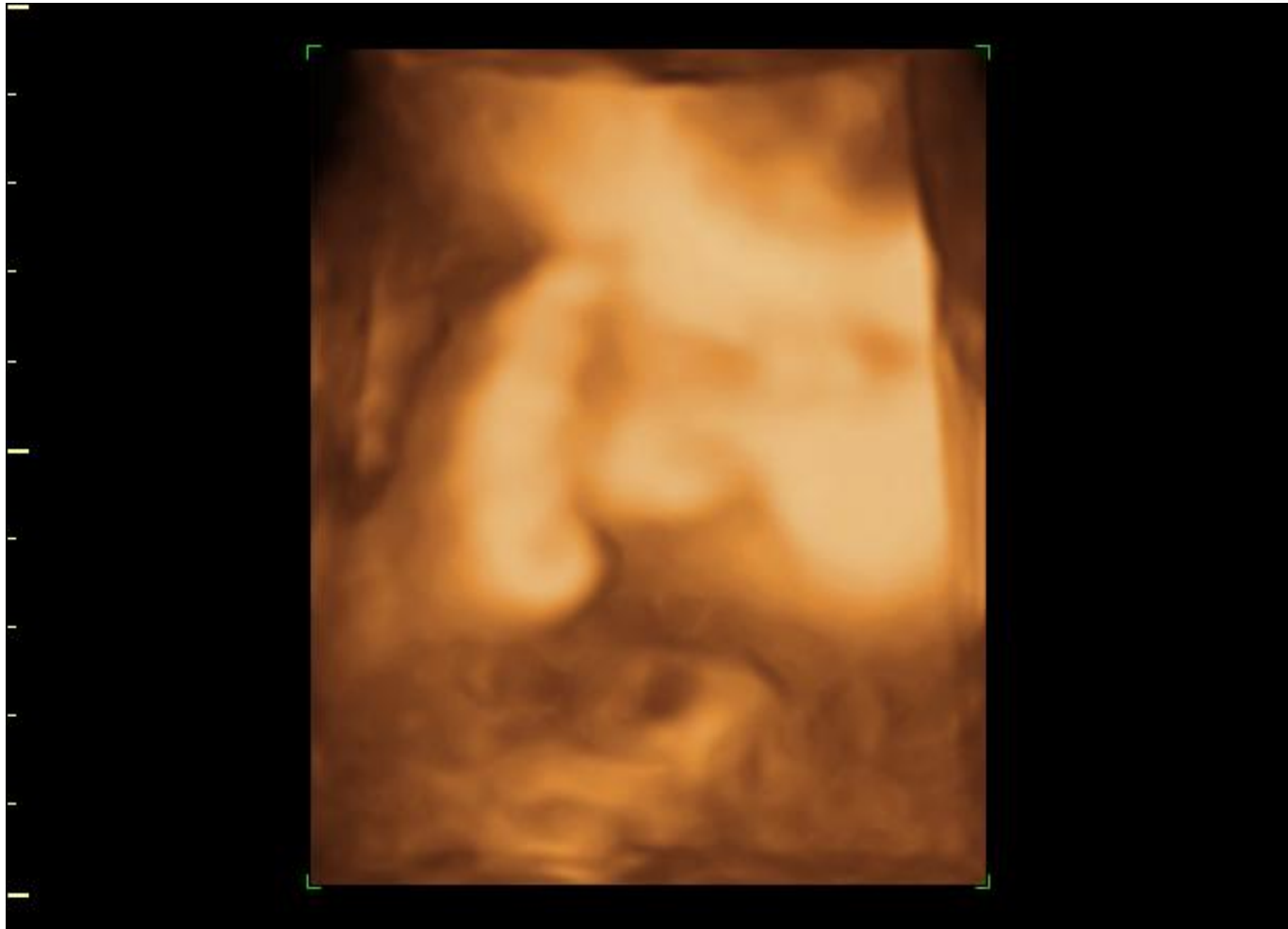Telemedicine and Offline Image Review

- **Storing of volumes for subsequent review and interpretation;**
- **Central monitoring of data for quality and accuracy in remote clinical sites and in multicenter research studies; and**
- **Telemedicine and offline image review on an independent workstation.**



Education

- **Teaching standardized views and postprocessing techniques for training; and**
- **Teaching normal and abnormal anatomy using volumes as simulated scans**



Where Do We Go Next?

- **To promote the clinical acceptance of 3D ultrasound for diagnostic applications in obstetrics and gynecology important points are.**
- **Encourage those who perform obstetric/ gynecologic ultrasound examinations to incorporate 3D ultrasound into their ultrasound practices.**
- **Achieve acceptance of 3D ultrasound as a valuable tool in medical imaging by providing education, training courses, publications, simulators, online training, and multimedia tools.**
- **Continue to develop quantitative applications for 3D ultrasound.**
- **Develop indications and protocols for 3D ultrasound.**
- **Standardize terminology for volume sonography so that it is universal and avoids proprietary terminology.**
- **Set standardized display algorithms to permit reproducibility and automation.**

- **The advantages of 3D/4D ultrasound in obstetrics are outlined including:**
- **1) improved understanding of normal fetal anatomy and fetal anomalies by the parents;**
- **2) improved maternal-fetal bonding;**
- **3) enhanced diagnosis of fetal anomalies;**
- **4) precise identification of the nature, size and location of certain fetal defects;**
- **5) precise volume measurement of organs with irregular shape;**
- **6) retrospective analysis, data exchange and education.**

Dimitrova V, et al . **[3D and 4D ultrasonography in obstetrics]**.Akush Ginekol (Sofia). 2007;46(2):31-40.

