The Use of Ultrasound for the Diagnosis and Treatment of the Musculoskeletal System

St. Joseph's Refresher Course

March 2020

Kenneth Iles, DC

John Finkenstadt, MD

ULTRASONOGRAPHY IN FAMILY MEDICINE

- **Musculoskeletal – Diagnosis and Injection**
  eg: Carpal Tunnel; Shoulder Rotator Cuff; Knee Aspiration;
  Ganglion Cysts; Dequervain's Tenosynovitis

- **Thyroid Nodules**
- **Enlarged Lymph Nodes**
- **Pericardial Effusion**
- **Abdominal Aortic Aneurysm**
- **Obstetrics**

REFERENCES:
ULTRASOUND IN FAMILY MEDICINE

1. **Point of Care Ultrasound in General Practice: A Systematic Review**
   Ann Fam Med Jan/Feb 2019 vol. 17 no. 1 61-69.

2. **Point of Care Ultrasonography in Family Medicine**
   Am Fam Physician. 2018 Aug 15;98(4):200-202.

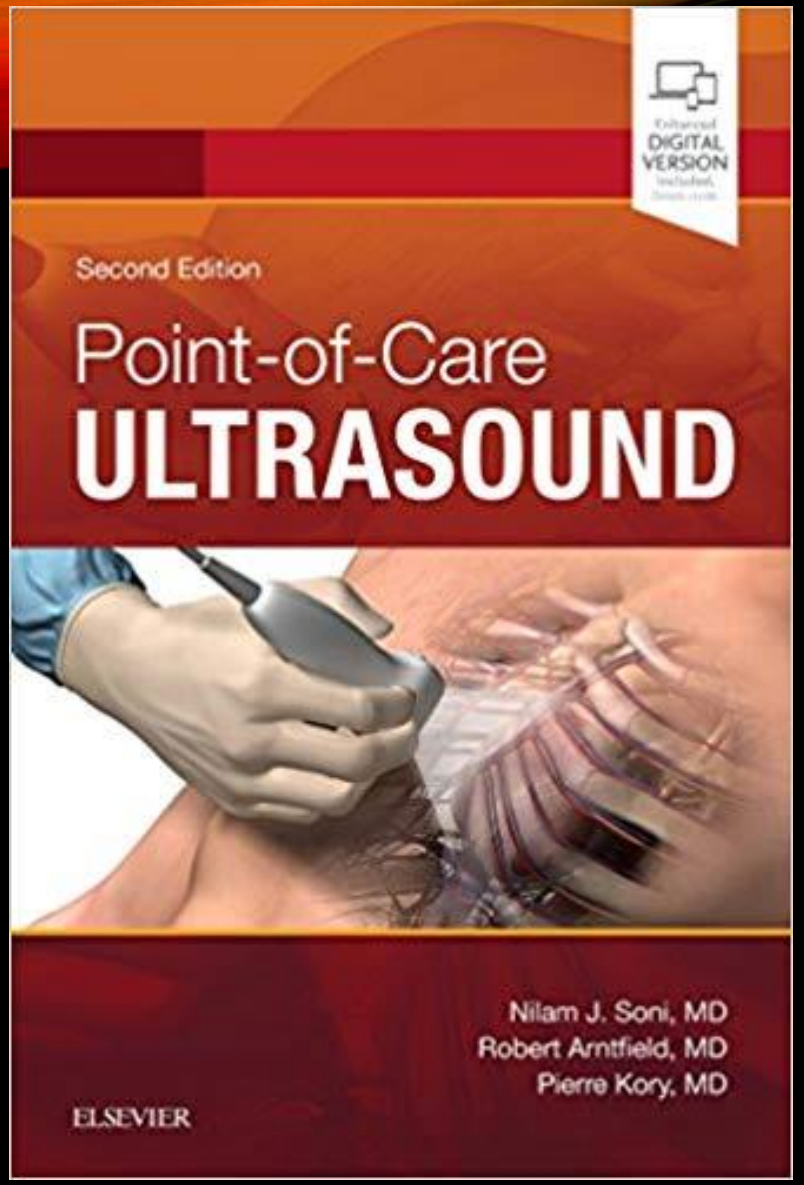
Enhanced DIGITAL VERSION
Second Edition
Point-of-Care
ULTRASOUND
Nilam J. Soni, MD
Robert Arntfield, MD
Pierre Kory, MD
ELSEVIER

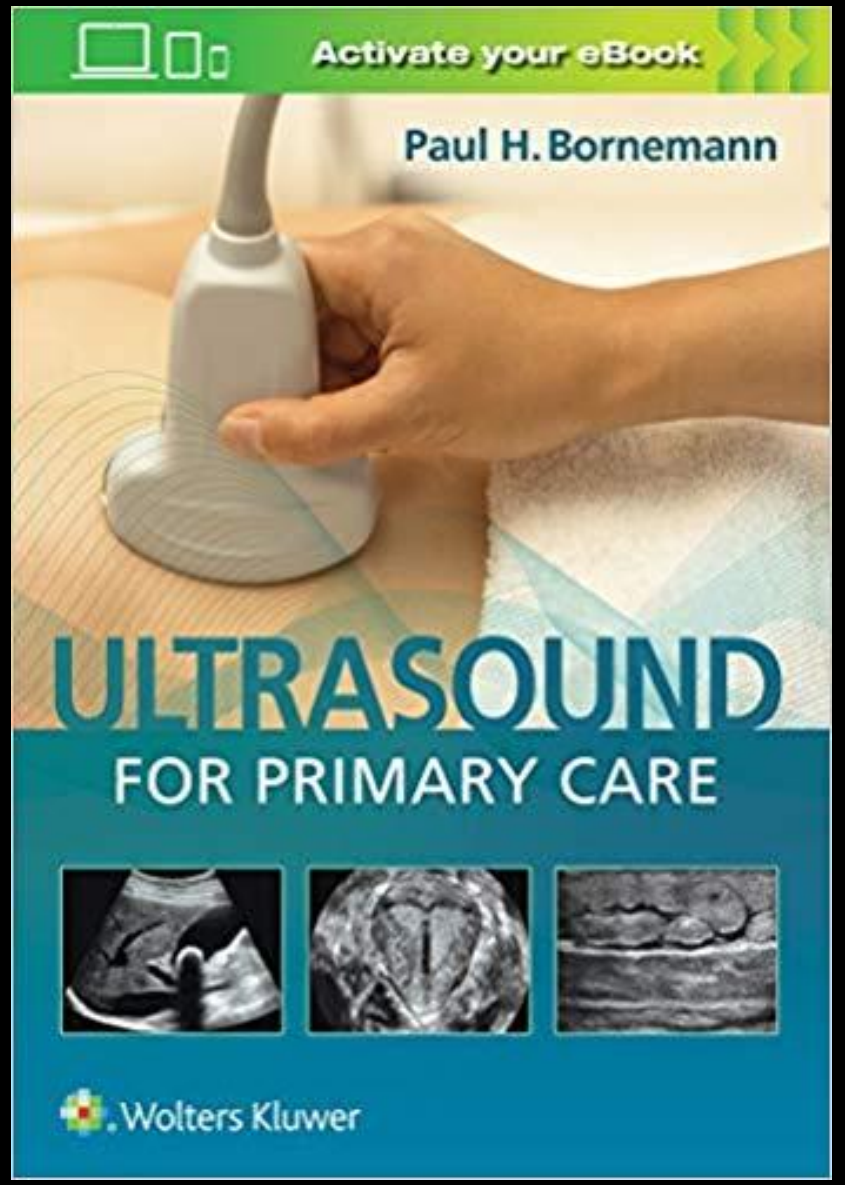
Activate your eBook
Paul H. Bornemann
ULTRASOUND
FOR PRIMARY CARE
Wolters Kluwer

THIS WORKSHOP WILL FOCUS ON 2 MAIN TOPICS:

DIAGNOSIS AND TREATMENT OF:

Carpal Tunnel Syndrome

Shoulder Rotator Cuff Tears

WHY ULTRASOUND?

- Portability
- Cost-Effective
- Patient Comfort
- High Resolution Imaging
- Real Time Dynamic Imaging

OTHER REASONS TO CONSIDER ULTRASOUND

- Every patient can undergo Ultrasound
- No problem with hardware
- No problems with claustrophobia or need for sedation
- Probe can be placed over symptomatic area
- Color Doppler shows inflammation
- Better for differentiating fluid from solid areas
- Facilitates bilateral comparison
- Can be used to follow the long course of a structure such as a nerve
- Useful in guiding interventions

LIMITATIONS OF ULTRASOUND IN MUSCULOSKELETAL DIAGNOSIS

Intra-articular Pathology
Degenerative Change
Labral Tears
Fractures
Bone Tumors

Operator Dependent

REQUEST FOR VOLUNTEERS FOR DEMOS

Carpal Tunnel Evaluation

Shoulder Pain Evaluation

CARPAL TUNNEL SYNDROME

- Compression of the Median Nerve beneath the Flexor Retinaculum

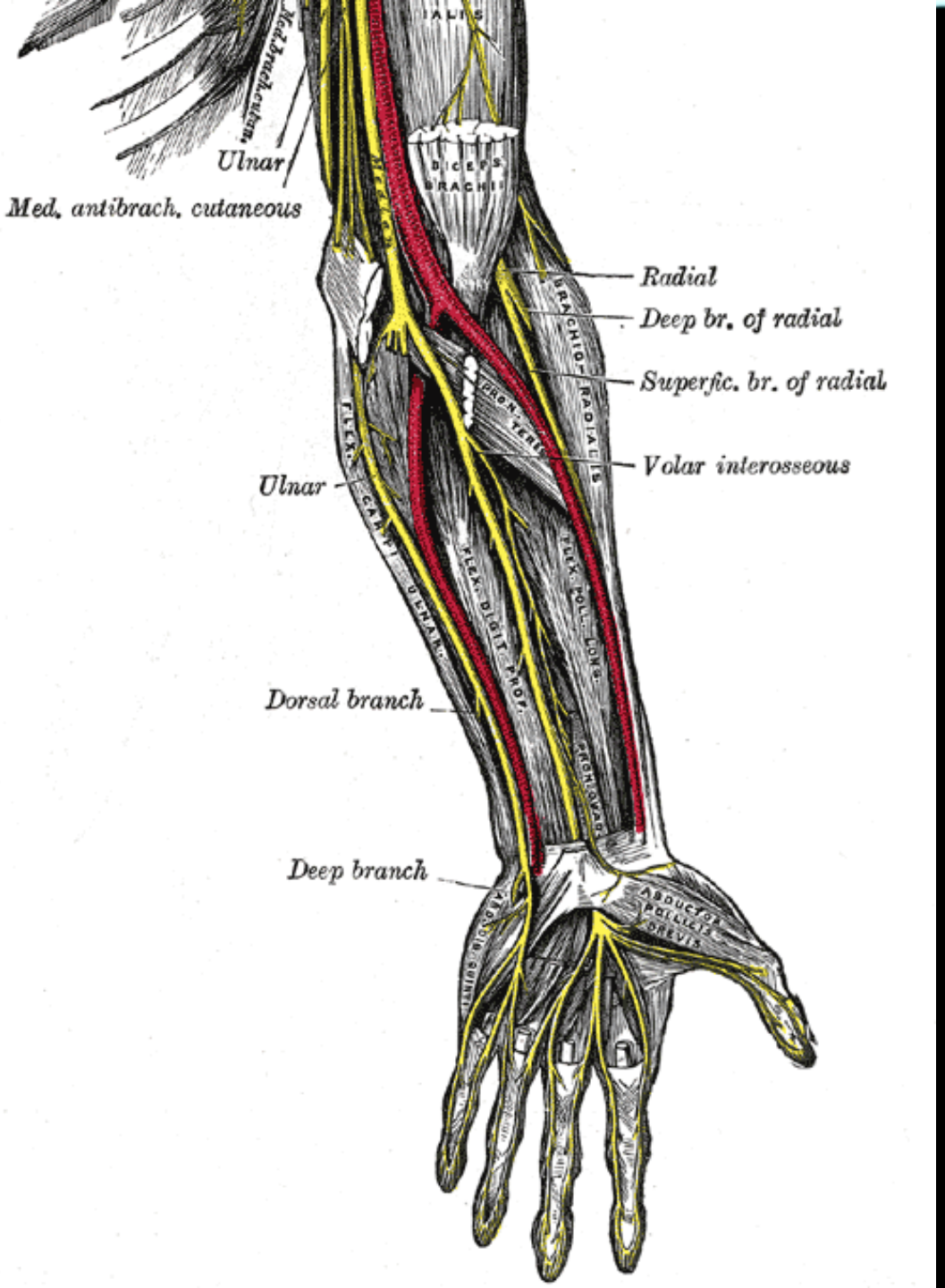
Ulnar
Med. antibrach. cutaneous
Radial
Deep br. of radial
Superfic. br. of radial
Volar interosseous
Ulnar
Dorsal branch
Deep branch

Flexor Retinaculum

A wide, thick ligament called the **flexor retinaculum** connects the pisiform and hamate hook to the scaphoid and trapezium.

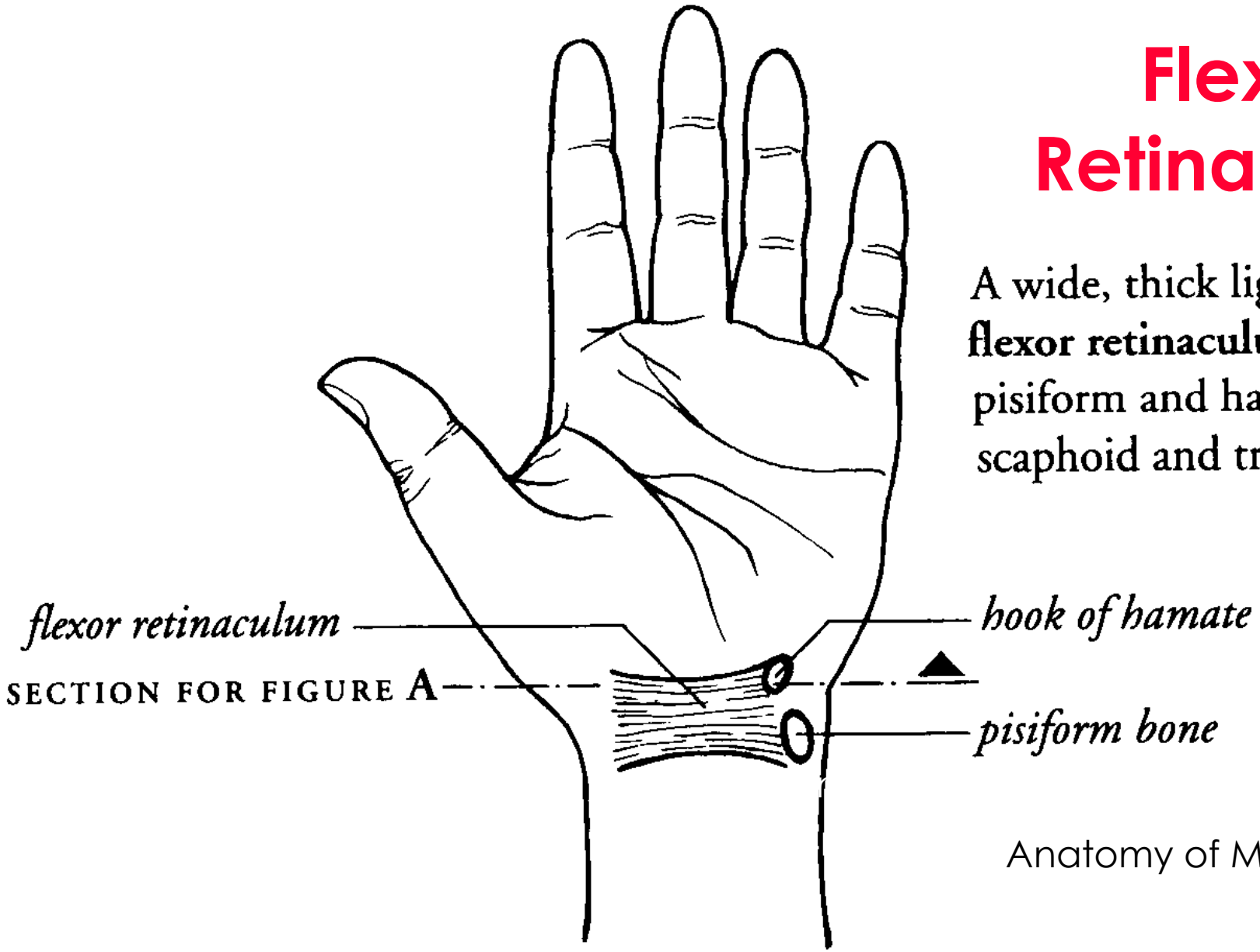

Anatomy of Movement p. 151

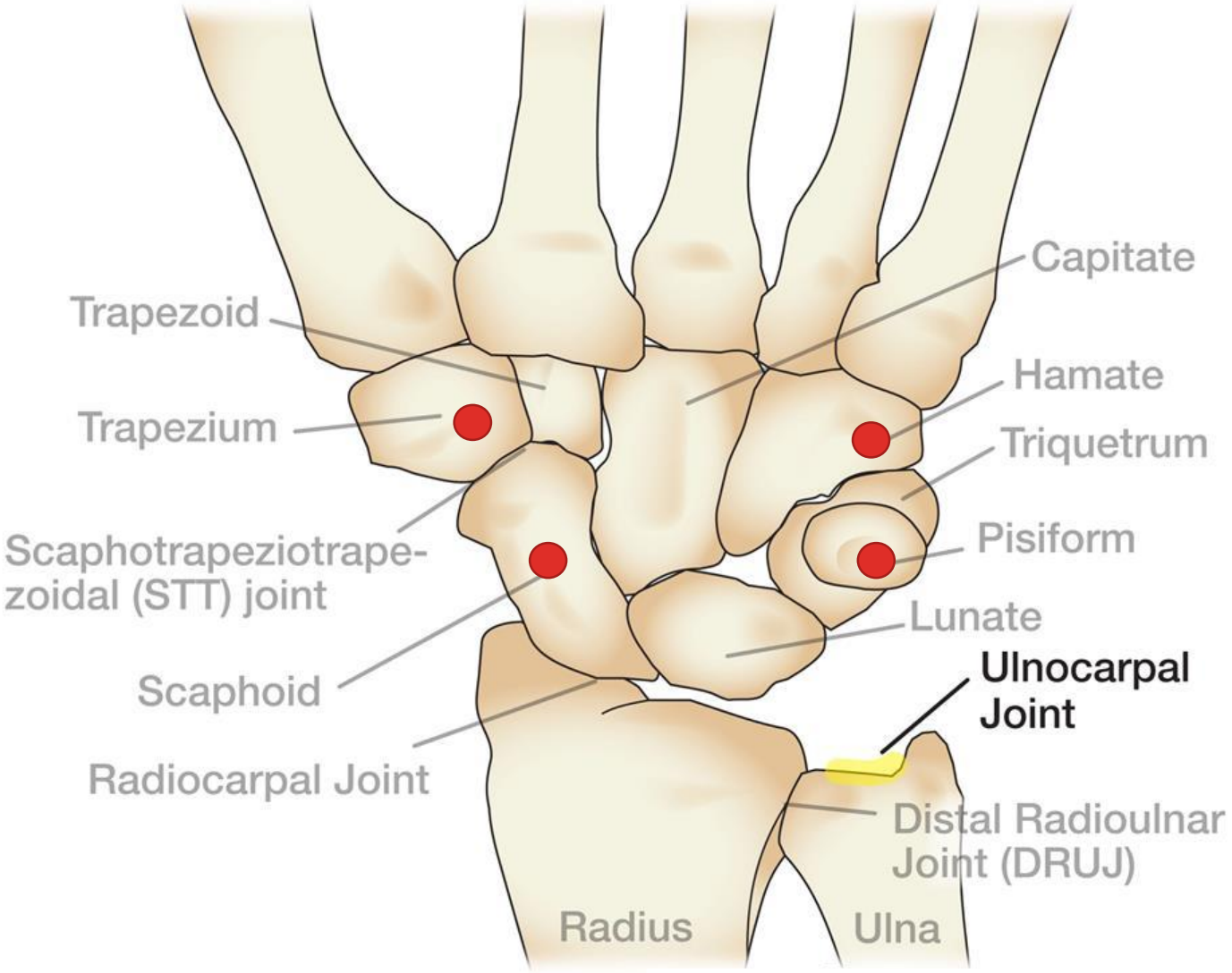
Capitate
Trapezoid
Hamate
Trapezium
Triquetrum
Pisiform
Scaphotrapeziotrape-
zoidal (STT) joint
Lunate
Ulnocarpal
Joint
Scaphoid
Radiocarpal Joint
Distal Radioulnar
Joint (DRUJ)
Radius
Ulna

Left Hand

Carpal Tunnel

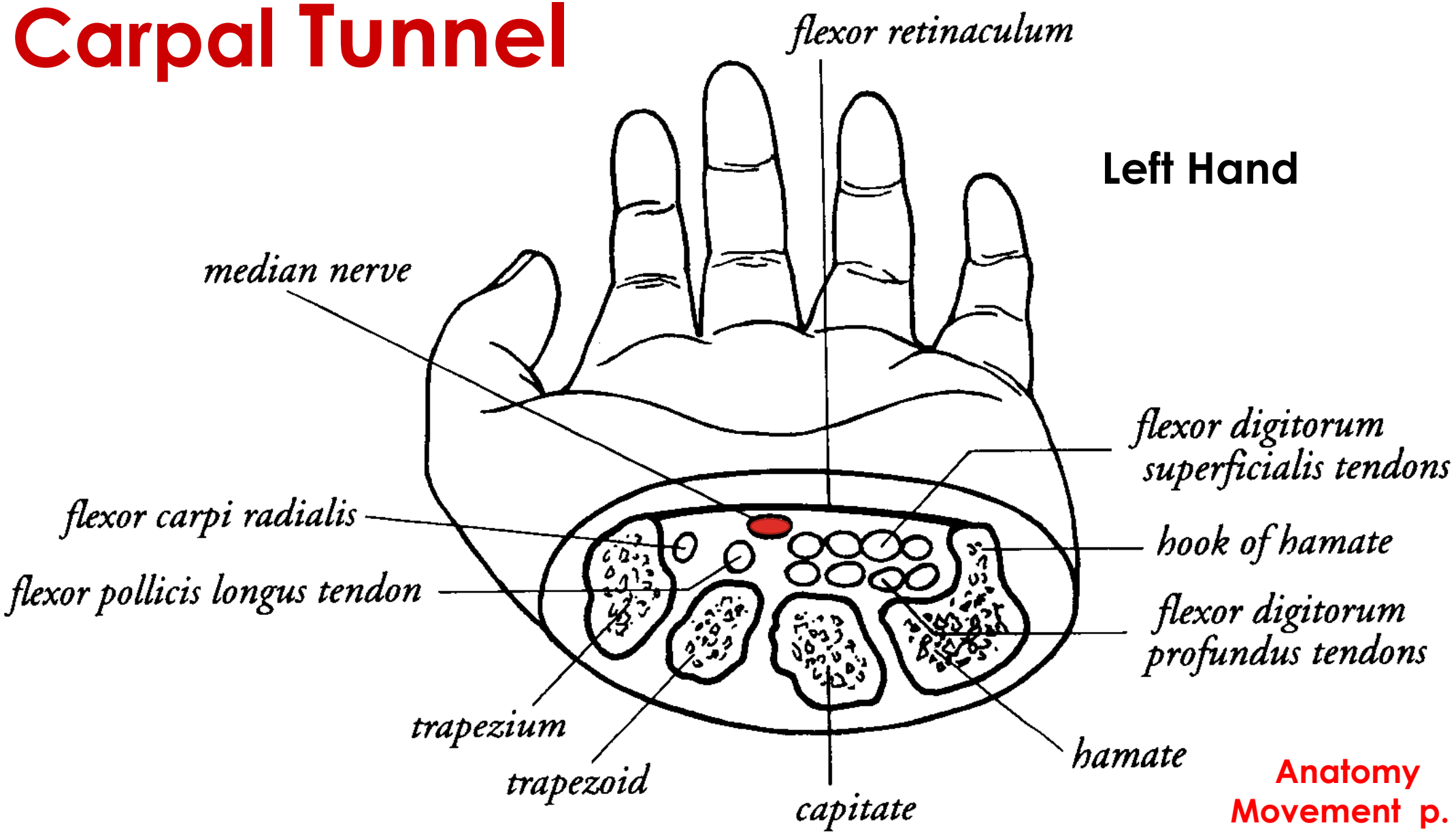

Anatomy Movement p. 151

PREVALENCE OF CARPAL TUNNEL SYNDROME

- 3.8% of the general population and up to 9.0% of Women
- The most common upper extremity entrapment neuropathy
- 90% of all compressive neuropathies
- Estimated $2 billion per year financial burden to society

RISK FACTORS FOR CARPAL TUNNEL SYNDROME

Obesity

Diabetes

Pregnancy

Hypothyroidism

Rheumatoid Arthritis

SYMPTOMS OF CARPAL TUNNEL SYNDROME

- Motor, Sensory and Autonomic Impairments
- Pain (especially at night) and Tingling
- Intrinsic Hand Weakness
- Reduced Grip Strength
- Alteration of Temperature Control

CARPAL TUNNEL SYNDROME PHYSICAL EXAM

- Tinel's Sign
- Phalen's Test
- Carpal Compression Test
- Pinch Grip (thumb and 5th finger)
- Sensory Examination – pin wheel

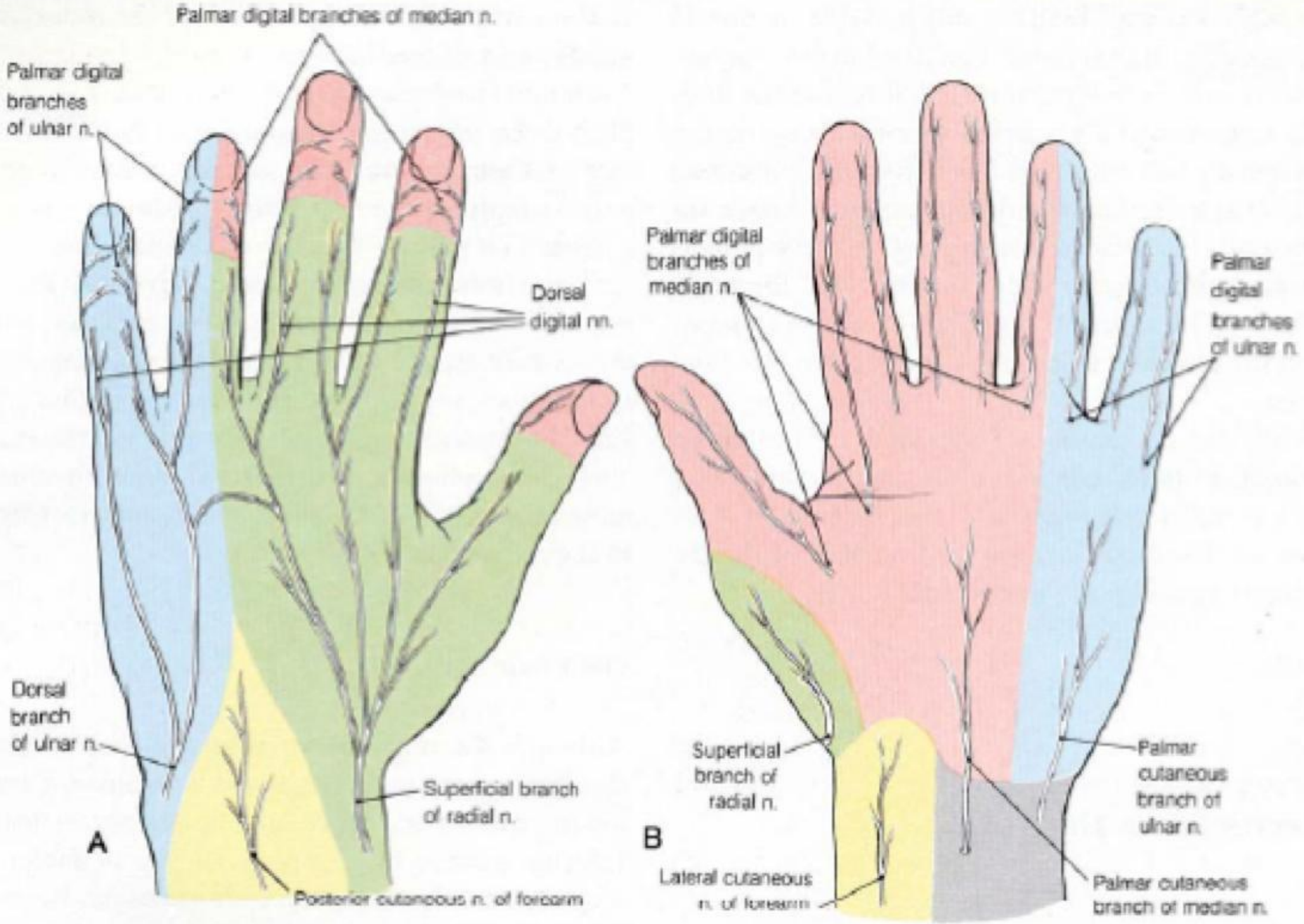

Ulnar n.

Radial n.

Median n.

3-110 The cutaneous innervation of the dorsal (*A*) and palmar (*B*) surfaces of the hand.

Phalen's Test

Reverse Phalen's Test

ULTRASOUND DIAGNOSIS OF CARPAL TUNNEL SYNDROME

- CSAc(Cross Sectional Area crease) >10 mm^2
- **WFR(Wrist-Forearm Ratio) >1.2**
- Enlarged Median N. proximal to the Carpal Tunnel inlet in longitudinal view(Notch Sign, or Dumbell Sign)
- **Bowing of the Flexor Retinaculum at the Scaphoid-Pisiform level**
- Distal flattening of the Median N. in the Carpal Tunnel
- **Decreased mobility of Median N. on dynamic imaging**

ULTRASOUND EVALUATION OF CTS

MSMPC DIAGNOSTIC PROTOCOL

- See Handout

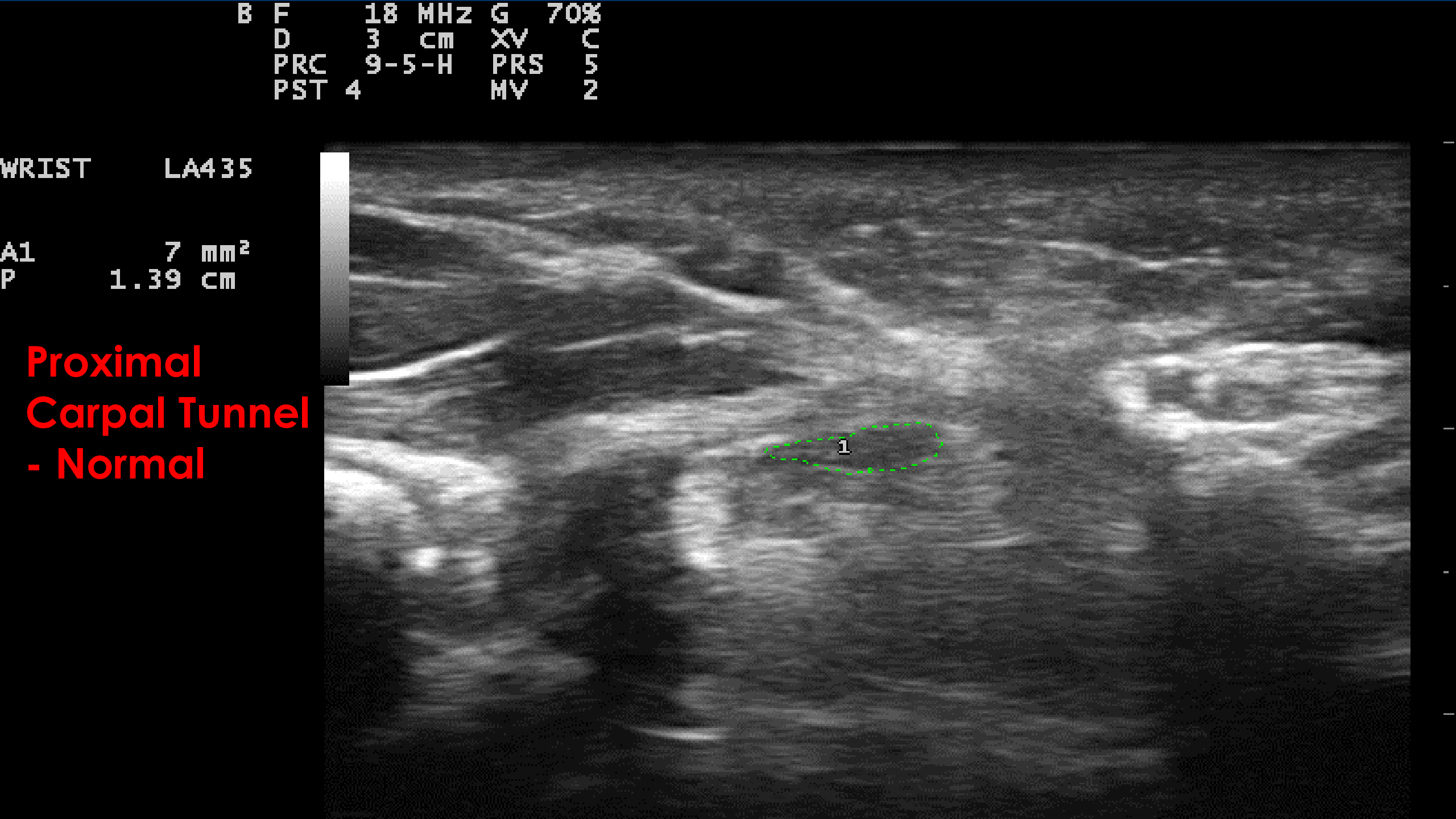
B F 18 MHz G 70%
D 3 cm XV C
PRC 9-5-H PRS 5
PST 4 MV 2
WRIST LA435
A1 7 mm²
P 1.39 cm
Proximal
Carpal Tunnel
- Normal
1

18 MHz G 70%
3 cm XV C
PRC 9-5-H PRS 5
PST 4 MV 2
WRIST LA435
A1 12 mm²
P 1.55 cm
Proximal
Carpal Tunnel
- Abnormal
1
LEFT

THE ROLE OF ULTRASOUND IN THE DIAGNOSIS AND MANAGEMENT OF CARPAL TUNNEL SYNDROME : A NEW PARADIGM

AUTHORS: MCDONAGH C, ALEXANDER M, KANE D.
RHEUMATOLOGY (OXFORD), 2015 JAN;54(1):9-19.

NERVE CONDUCTION – SENSITIVITY > 85%

ULTRASOUND – SENSITIVITY UP TO 97.9%

SPECIFICITY WAS SIMILAR WITH BOTH PROCEDURES

TEST **SENSITIVITY** - THE ABILITY OF A TEST TO CORRECTLY IDENTIFY THOSE **WITH THE DISEASE** (TRUE POSITIVE RATE).

TEST **SPECIFICITY** - THE ABILITY OF THE TEST TO CORRECTLY IDENTIFY THOSE **WITHOUT THE DISEASE** (TRUE NEGATIVE RATE).

DIAGNOSTIC ULTRASOUND
FOR
CARPAL TUNNEL SYNDROME

Patient Demonstration

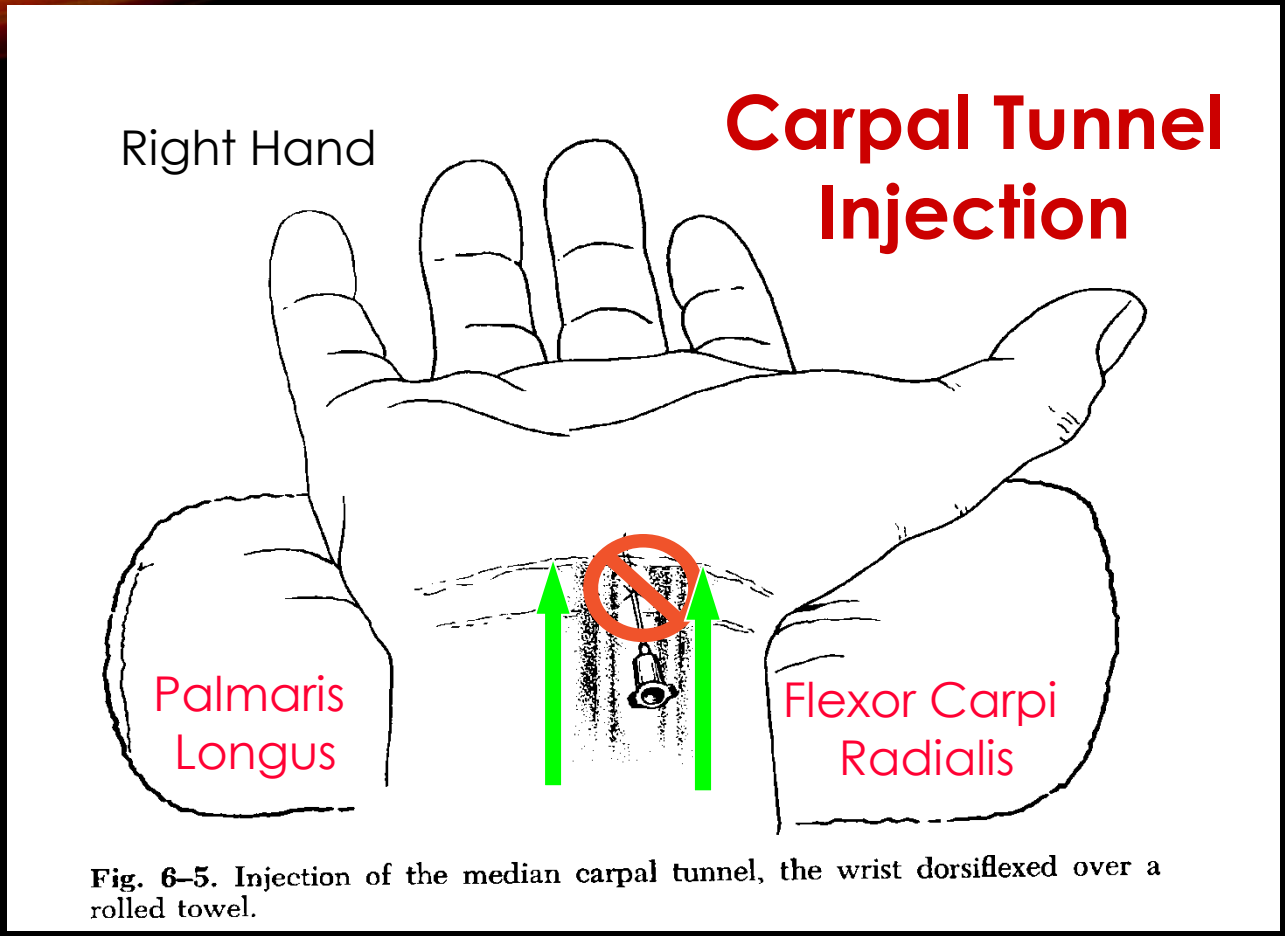

Fig. 6–5. Injection of the median carpal tunnel, the wrist dorsiflexed over a rolled towel.

N.B. - Inject in line with the radial aspect of the 3rd and 4th fingers.

Steinbrocker and Neustadt p. 59

CANDIDATES FOR ULTRASOUND GUIDED CARPAL TUNNEL HYDRODISSECTION

- Carpal Tunnel Surgical Failures
- **Pregnant Women**
- Poor Surgical Risks: eg. Elderly patient with multiple medical problems
- **Reasonable Alternative for Conservative Treatment Failures**
- Alternative for Patients Refusing Surgery

BENEFITS OF ULTRASOUND GUIDED CARPAL TUNNEL HYDRODISSECTION

- Overall Safety
- Better than Non-Imaged Guided
- Accuracy of Medication Placement
- Ease of Performance
- Lower Level of Invasiveness than Surgery
- Lower Cost vs. Surgical Release
- Shorter Recovery Period
- Effectiveness

CARPAL TUNNEL HYDRODISSECTION

Goal – Decrease pressure on the median nerve from the flexor retinaculum and decrease inflammation of the median nerve and underlying flexor tendons

27G - 1 ½ inch needle - 8 ml of fluid with Kenalog - 40 (0.5 to 1.0 ml)

Ultrasound Guided – Transverse position of the probe

Local skin anesthesia optional

Maintain slight extension of the wrist

Supine position

Inject in distal direction

Inject along the Radial and Ulnar aspects of the nerve

Start approx. 1.0 cm proximal to the wrist crease and aim for radial aspect of the 3rd and 4th fingers

Almost horizontal injection – the needle travels parallel to the tendons and nerve

Carpal Tunnel Hydrodissection

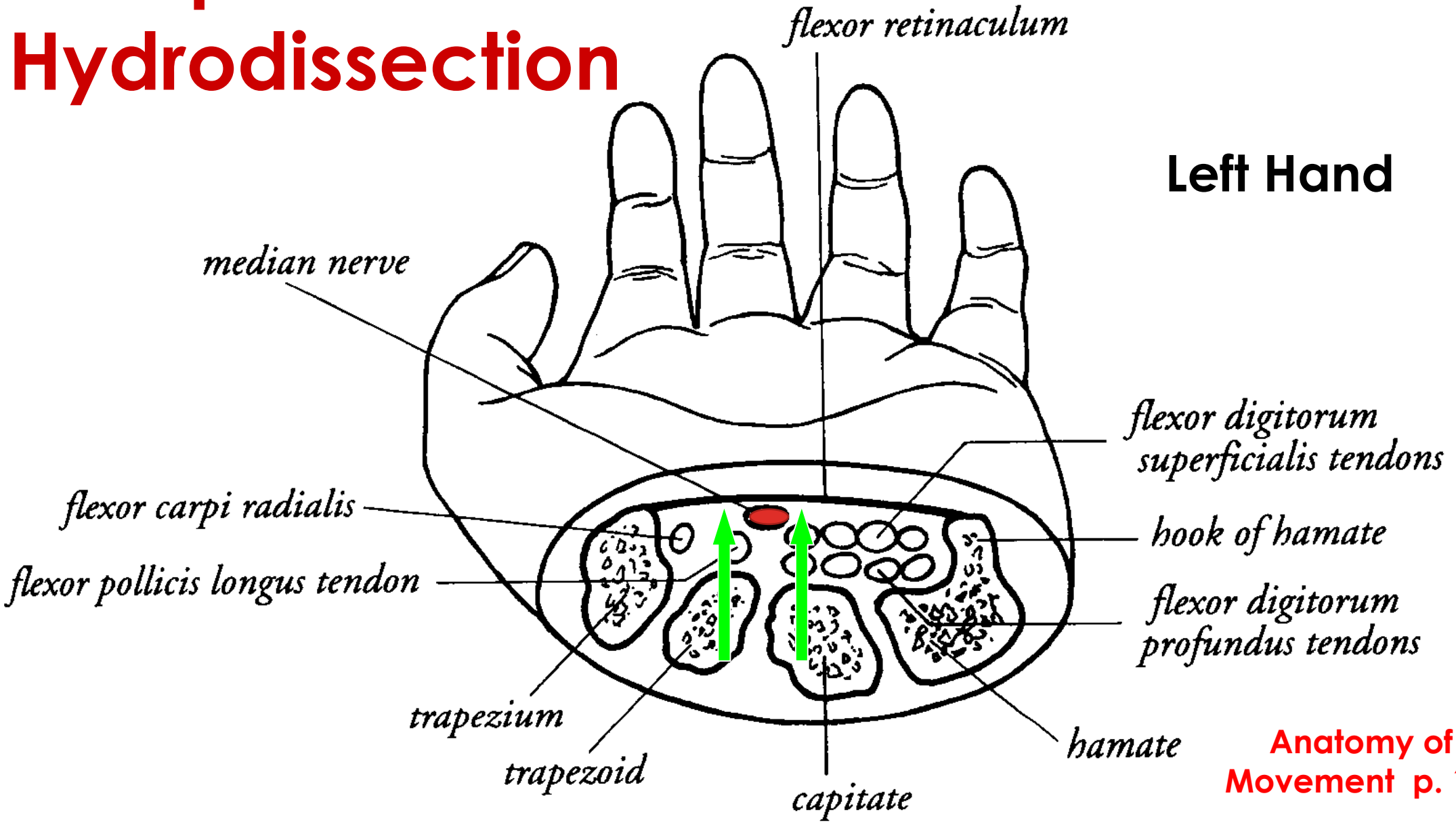

Left Hand

Anatomy of Movement p. 151

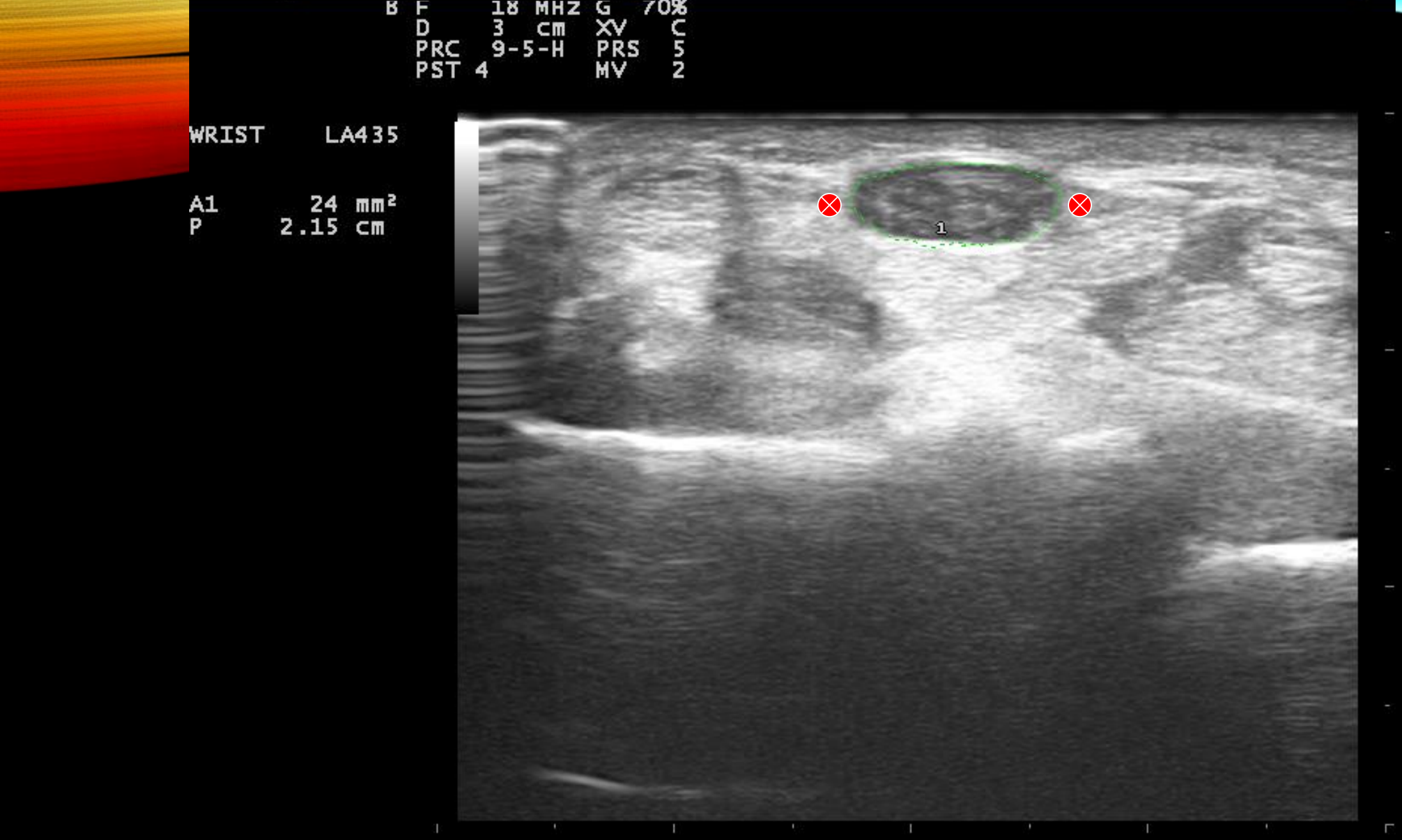
B F 18 MHz G 70%
D 3 cm XV C
PRC 9-5-H PRS 5
PST 4 MV 2
WRIST LA435
A1 24 mm²
P 2.15 cm
1

OTHER INJECTION TECHNIQUES

Recommendations for the best technique still being developed.

Smith J, Wisniewski SJ, Finnoff JT, Payne JM. Sonographically Guided Carpal Tunnel Injections: The Ulnar Approach. Journal of Ultrasound Medicine. 2008, Oct, 27(10);1485-90.

- uses an ulnar approach

Malone D, Clark T, Wei N. Ultrasound Guided Percutaneous Injection, Hydrodissection, and Fenestration for Carpal Tunnel Syndrome: Description of a New Technique. The Journal of Applied Research. 2010, 10(3);116-123.

– includes fenestration of the flexor retinaculum

CARPAL TUNNEL HYDRODISSECTION CASE STUDY

66 y.o. female – c/o recurrence of discomfort, numbness, tinging in the right hand.

S/P Carpal Tunnel Surgery on Right in 1999, Left 1996.

4/27/18: Dx Ultrasound on the Right consistent with CTS

Exam: mild tenderness, Phalen test equivocal, Pinch grip negative

5/17/18: Carpal Tunnel Hydrodissection – 40 mg Kenalog with D5W – 6 ml total.

6/21/18: F/U – Significantly improved. Tingling and numbness much better. c/o Mild recurrence of symptoms with activity.

2/11/19: F/U – Remains improved. Essentially pain free. Occasional tingling only.

QUESTIONS

ABOUT

CARPAL TUNNEL SYNDROME ?

DIAGNOSTIC ULTRASOUND

OF THE

SHOULDER

Rotator Cuff – Right Shoulder

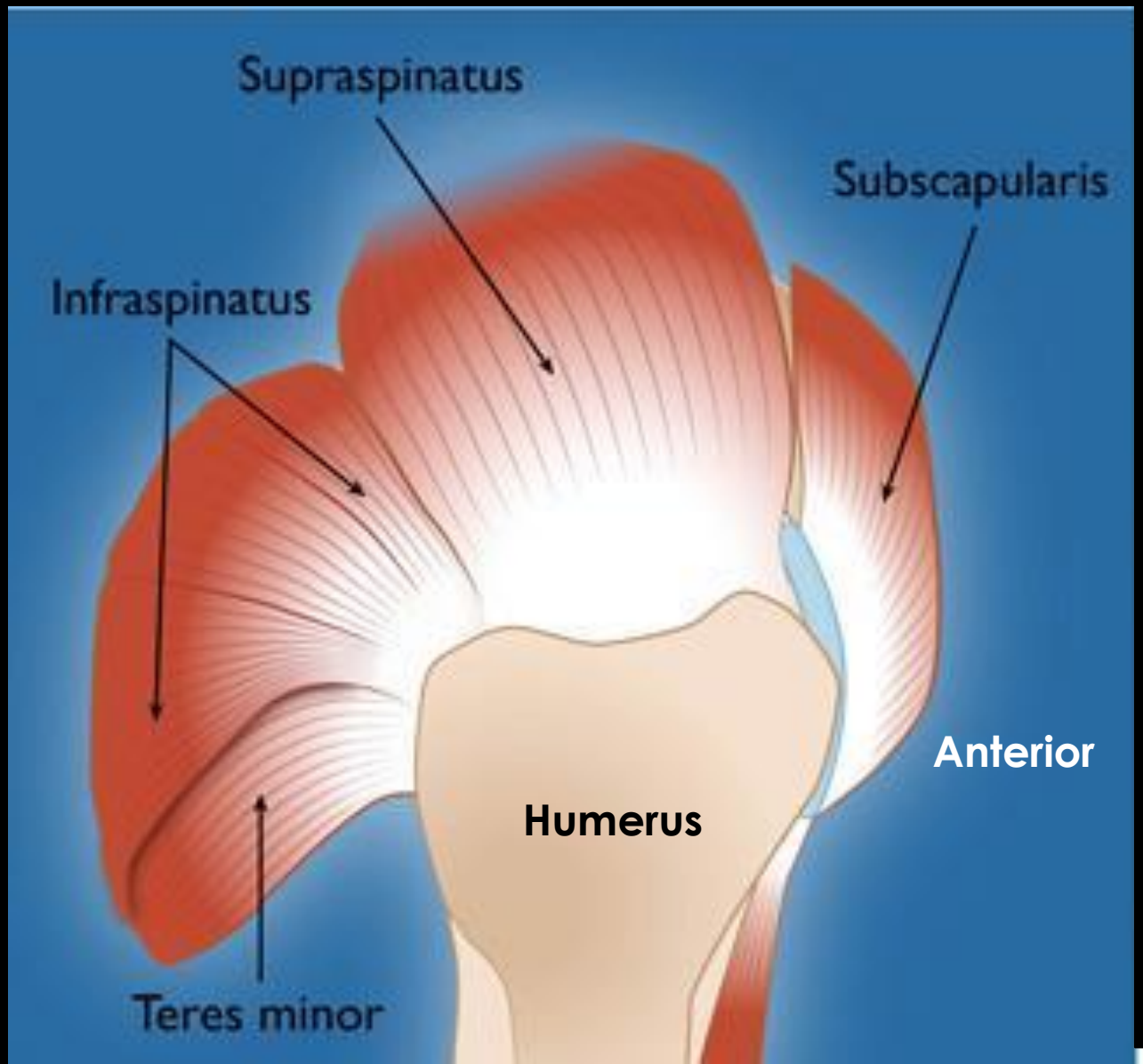

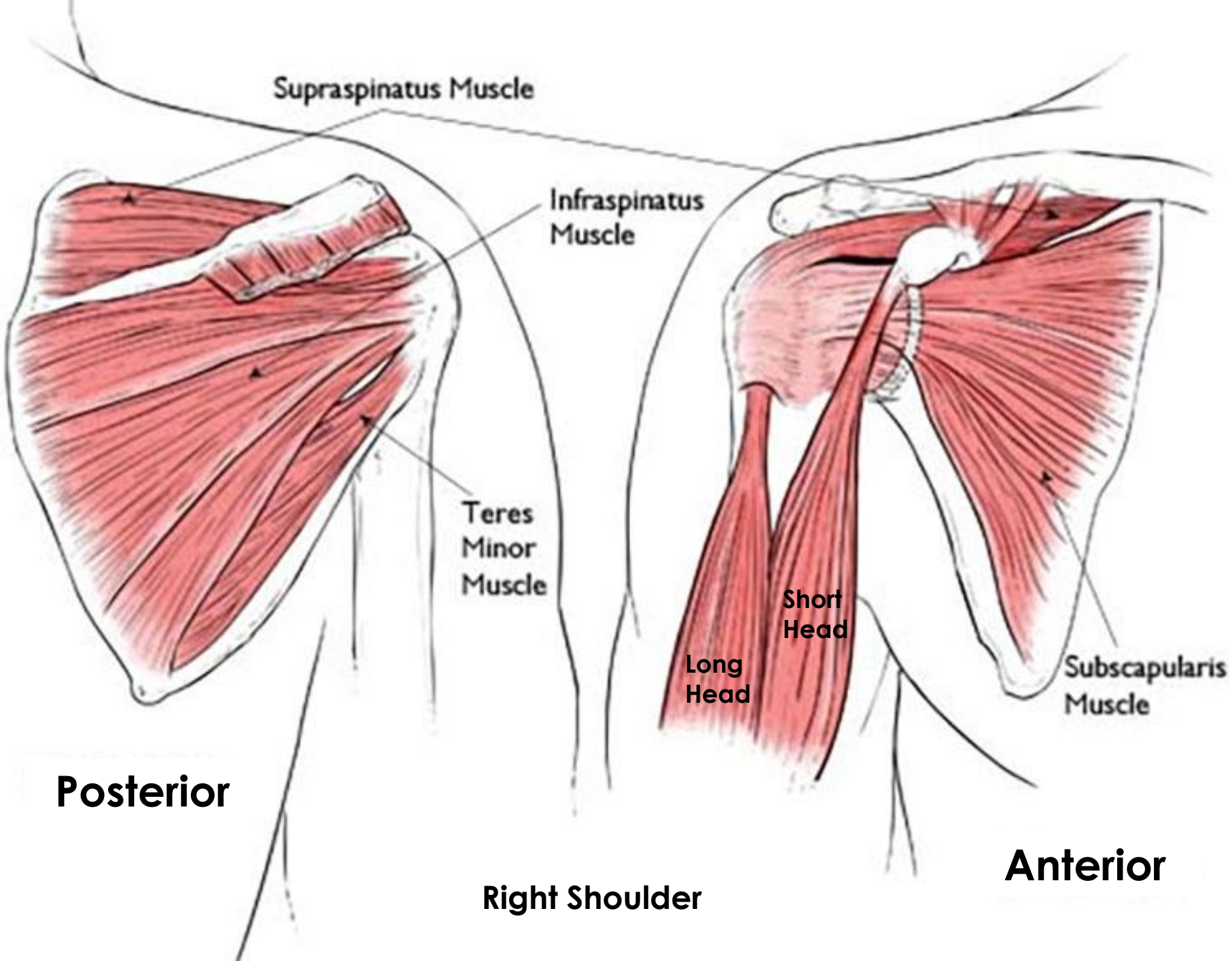
Supraspinatus Muscle
Infraspinatus Muscle
Teres Minor Muscle
Short Head
Long Head
Subscapularis Muscle
Posterior
Anterior
Right Shoulder

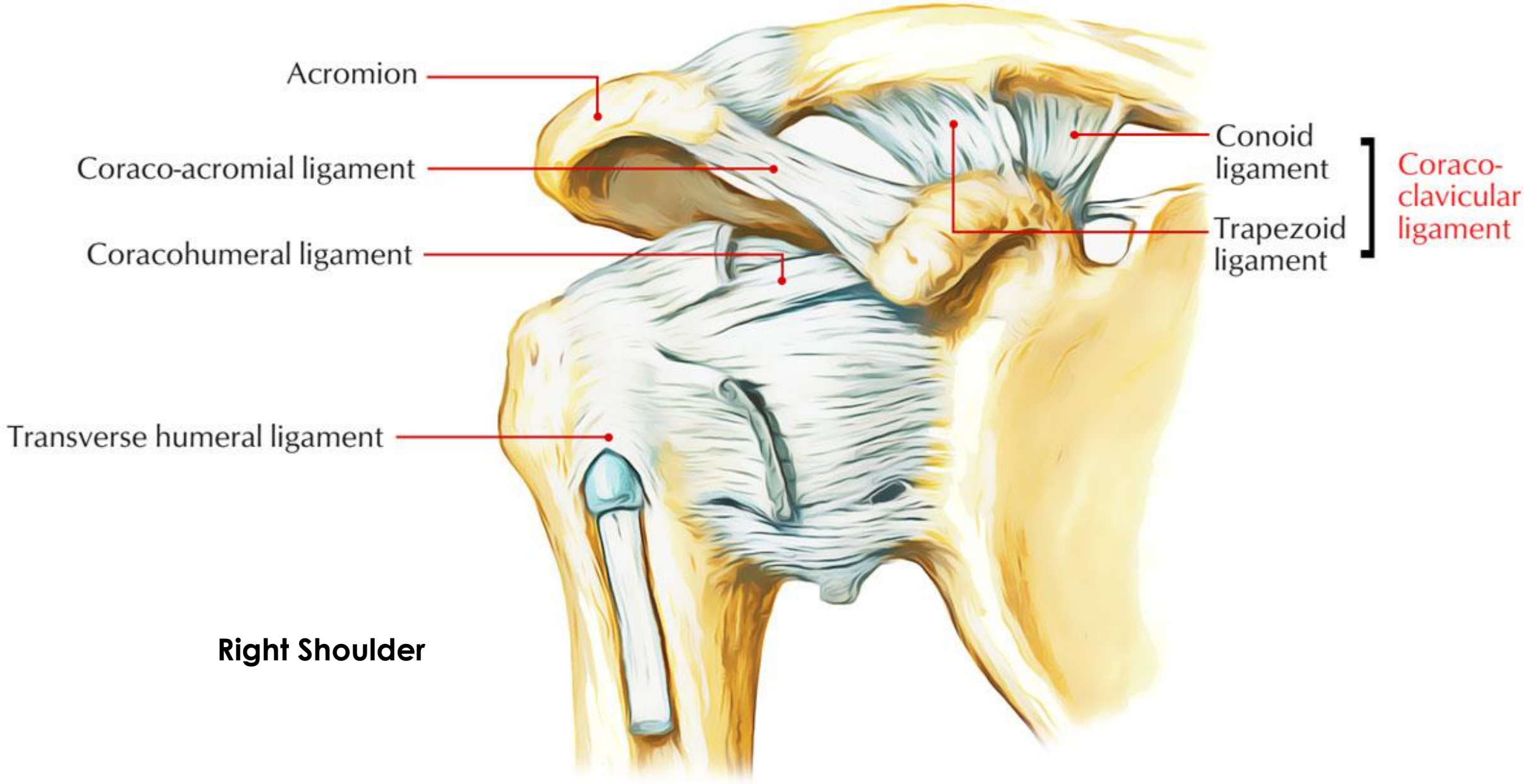

Right Shoulder

Dr. James H. Cyriax, M.D., M.R.C.P.

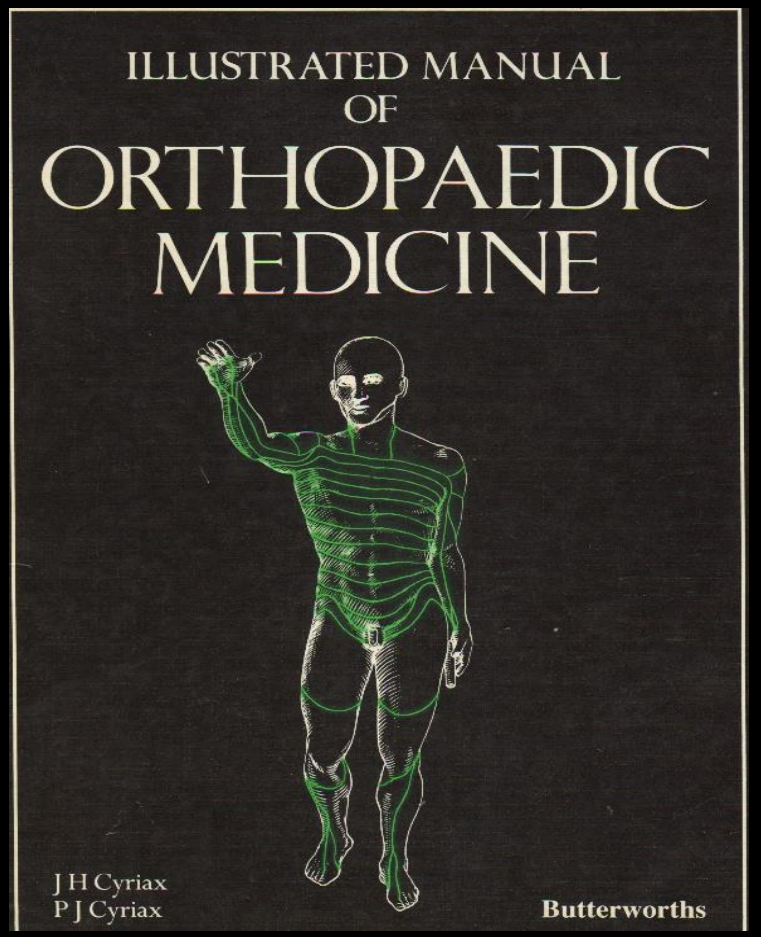

The shoulder

Summary
A straightforward joint producing clear findings. History of little importance diagnostically. Exclude neck as source of pain before proceeding to examination of shoulder. Nearly all shoulder structures are of C5 derivation.

For convenience, the acromio– and sternoclavicular joints are included in the following table.

Capsular pattern
Some limitation of medial rotation (except in a very mild case), greater limitation of passive abduction, greatest limitation of passive lateral rotation.

End-feel
Hard on elevation suggests arthritis.

Examination

Active elevation I: willingness.
Passive elevation: joint capsule, psychogenic limitation.
Active elevation II: painful arc (lesion lies in a pinchable position).
Passive abduction: glenohumeral range (cf active elevation I).
Passive lateral rotation: joint capsule.
Passive medial rotation: joint capsule.
Resisted abduction: supraspinatus.
Resisted adduction: pectoralis major, latissimus dorsi (both rare).
Resisted lateral rotation: infraspinatus.
Resisted medial rotation: subscapularis.
Resisted elbow flexion: biceps.
Resisted elbow extension: triceps (rare).

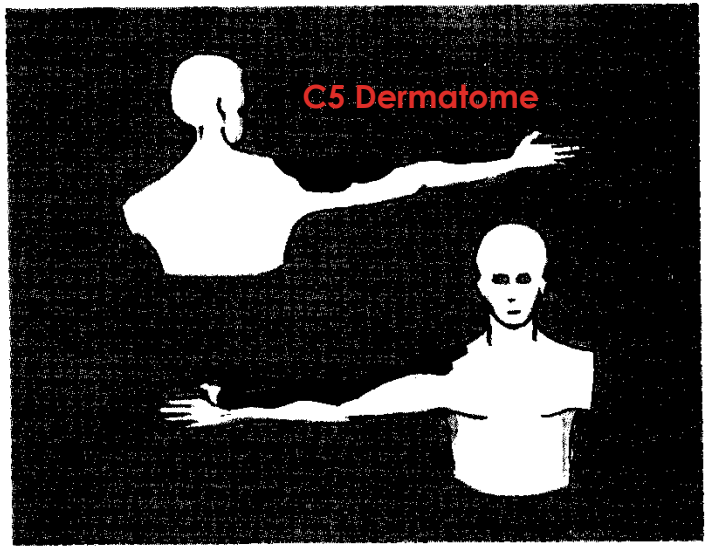

IV.1

Cyriax p.229

SHOULDER PHYSICAL EXAM

DEMONSTRATION

SHOULDER PHYSICAL EXAM

- Observation
- Neck Motion
- Active - Elevation
- Passive – Abduction, Lateral Rotation, Medial Rotation
- Resisted – Abduction / Adduction; Internal / External Rotation; Flexion / Extension
- Empty Can test
- Palpation – Rotator Cuff Tendons, A-C Joint, other
- DTR's
- Pulses

RESULTS OF PASSIVE TESTING

Capsulitis – Impaired
Elevation and Lateral Rotation

Rotator Cuff Pathology – Impaired
Elevation and normal Lateral Rotation

STRETCHING EXERCISES

The Essentials of Musculoskeletal Care p. 99

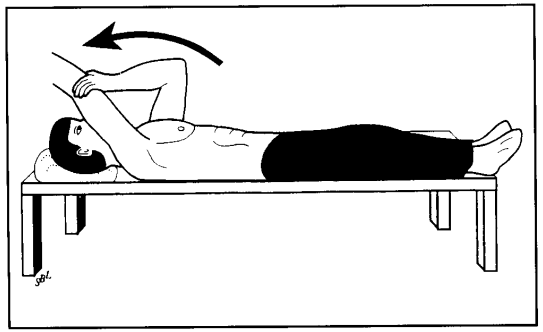

A *Stretching in overhead reach using the opposite arm as the "therapist"*

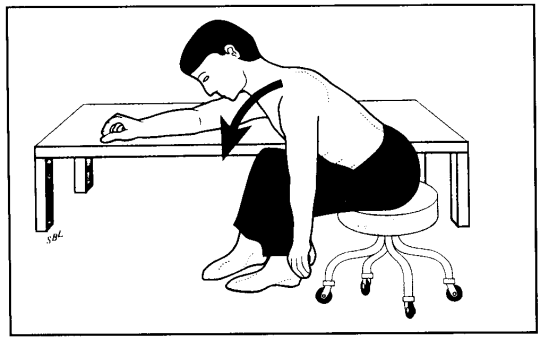

B *Stretching in overhead reach using the progressive forward lean to apply a gentle elevation force to the arm*

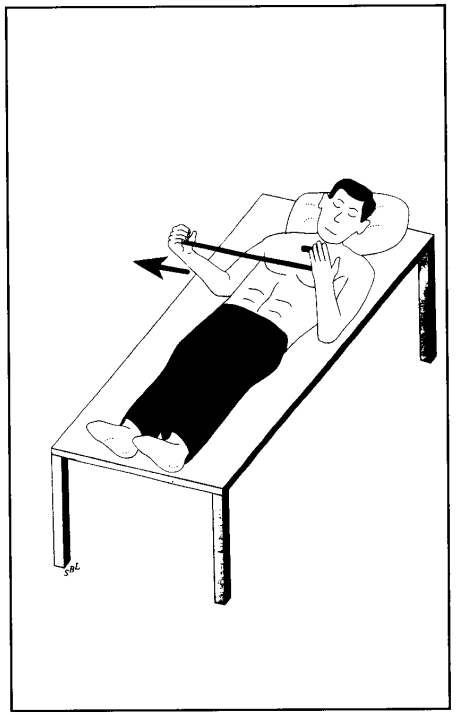

C *Stretching in external rotation using the opposite hand as the "therapist"*

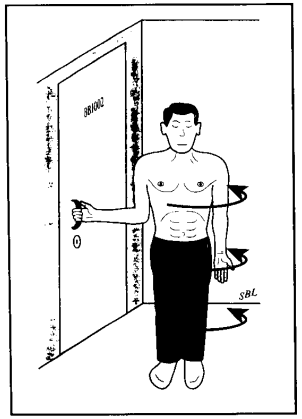

D *Stretching in external rotation by turning the body away from a fixed object to apply a gentle stretching force*

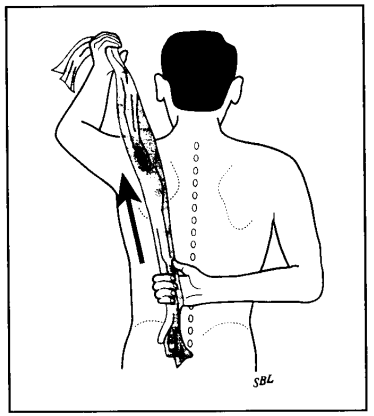

E *Stretching in internal rotation using a towel to apply a gentle stretching force*

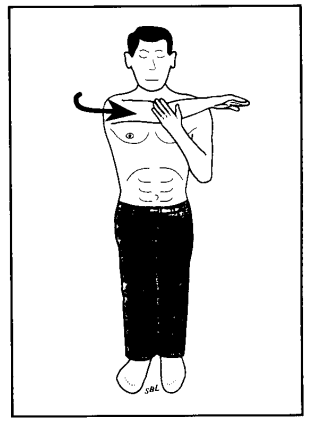

F *Stretching in cross-body reach using the opposite arm as the "therapist"*

Figure 3

University of Washington (Jackins) exercises for stiff shoulders

RESULTS OF RESISTED TESTING

Resisted **ABDUCTION** - **SUPRASPINATUS**
Resisted **ADDUCTION** - **PECTORALIS MAJOR, LATISSIMUS DORSI**

Resisted **LATERAL ROTATION** – **INFRASPINATUS**
Resisted **MEDIAL ROTATION** – **SUBSCAPULARIS**

Resisted **ELBOW FLEXION** – **BICEPS**
Resisted **ELBOW EXTENSION** - **TRICEPS**

PALPATION OF THE SUPRASPINATUS TENDON

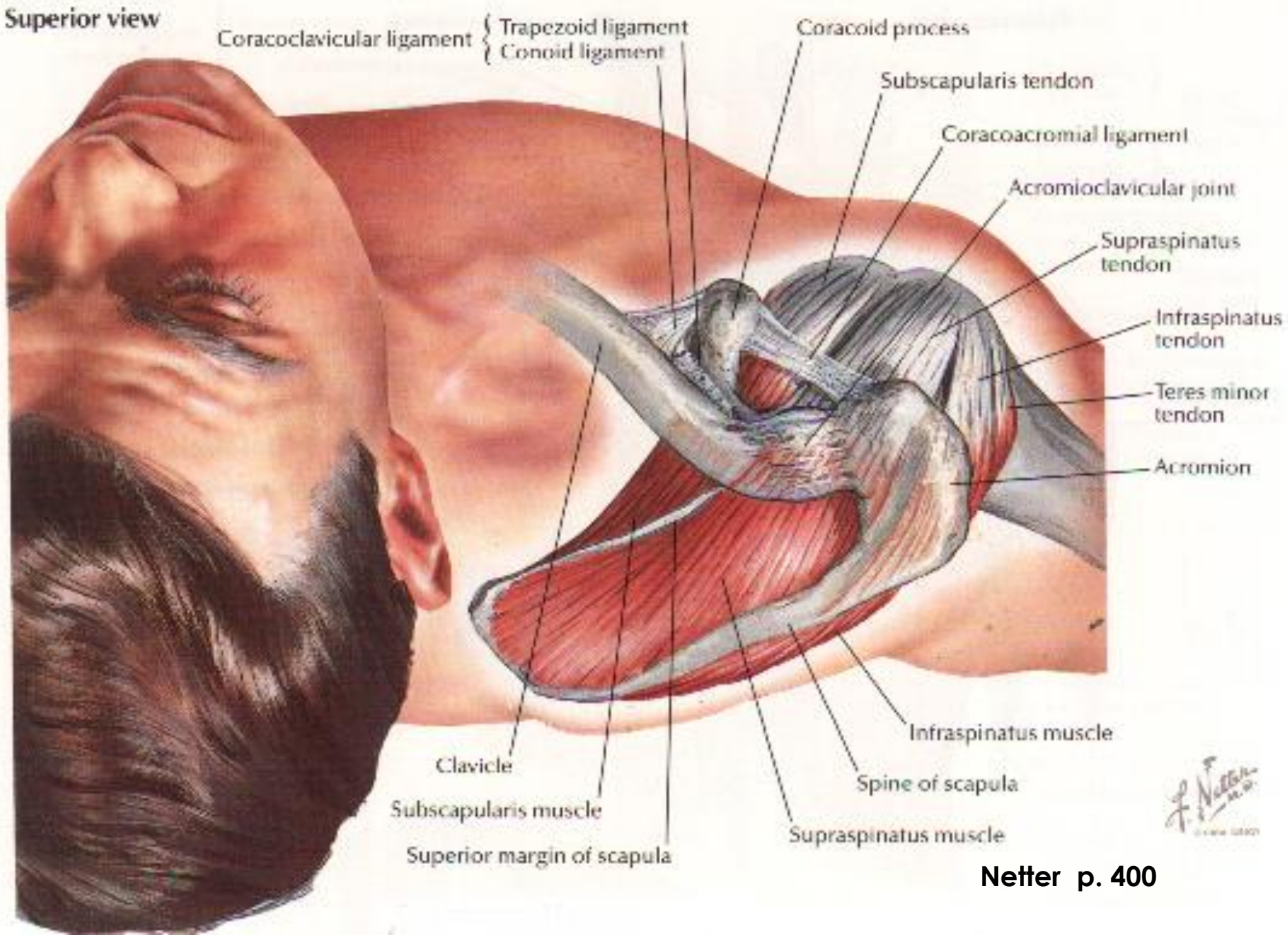
Superior view
Coracoclavicular ligament
Trapezoid ligament
Conoid ligament
Coracoid process
Subscapularis tendon
Coracoacromial ligament
Acromioclavicular joint
Supraspinatus tendon
Infraspinatus tendon
Teres minor tendon
Acromion
Clavicle
Subscapularis muscle
Superior margin of scapula
Infraspinatus muscle
Spine of scapula
Supraspinatus muscle

Netter p. 400

PALPATION OF THE SUBSCAPULARIS TENDON

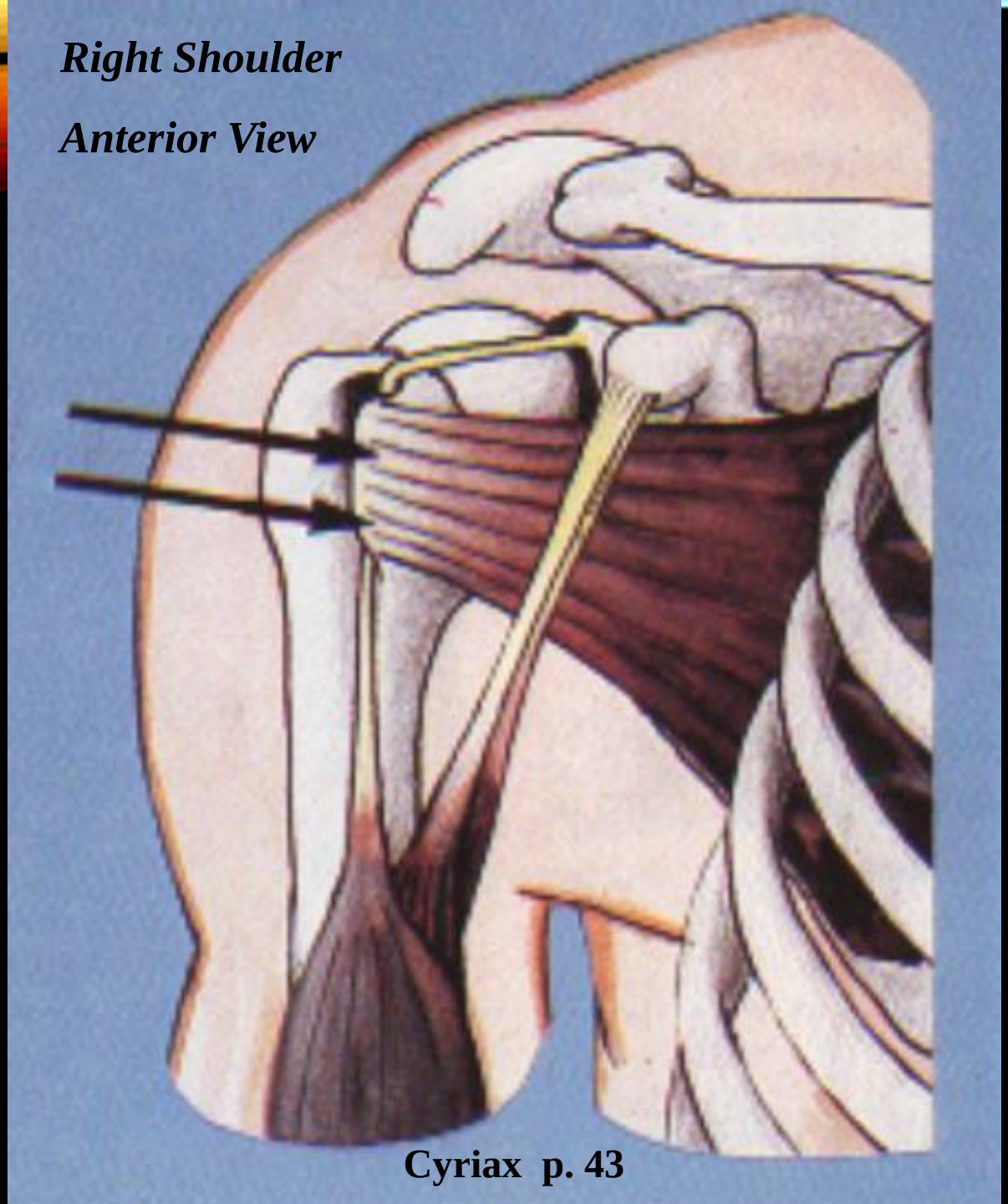

SUBSCAPULARIS TENDON

PALPATION OF THE INFRASPINATUS TENDON

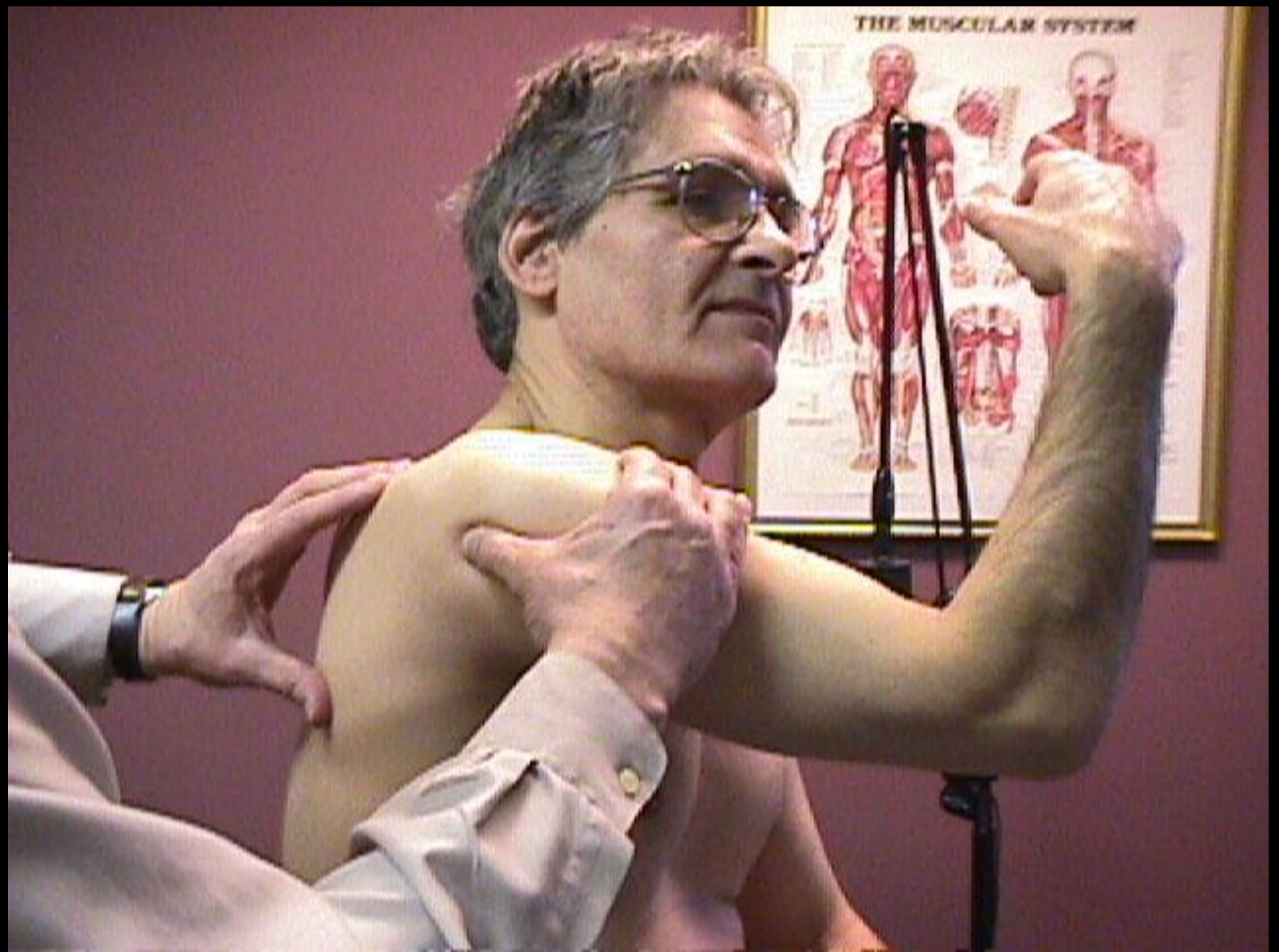

Infraspinatus Tendon

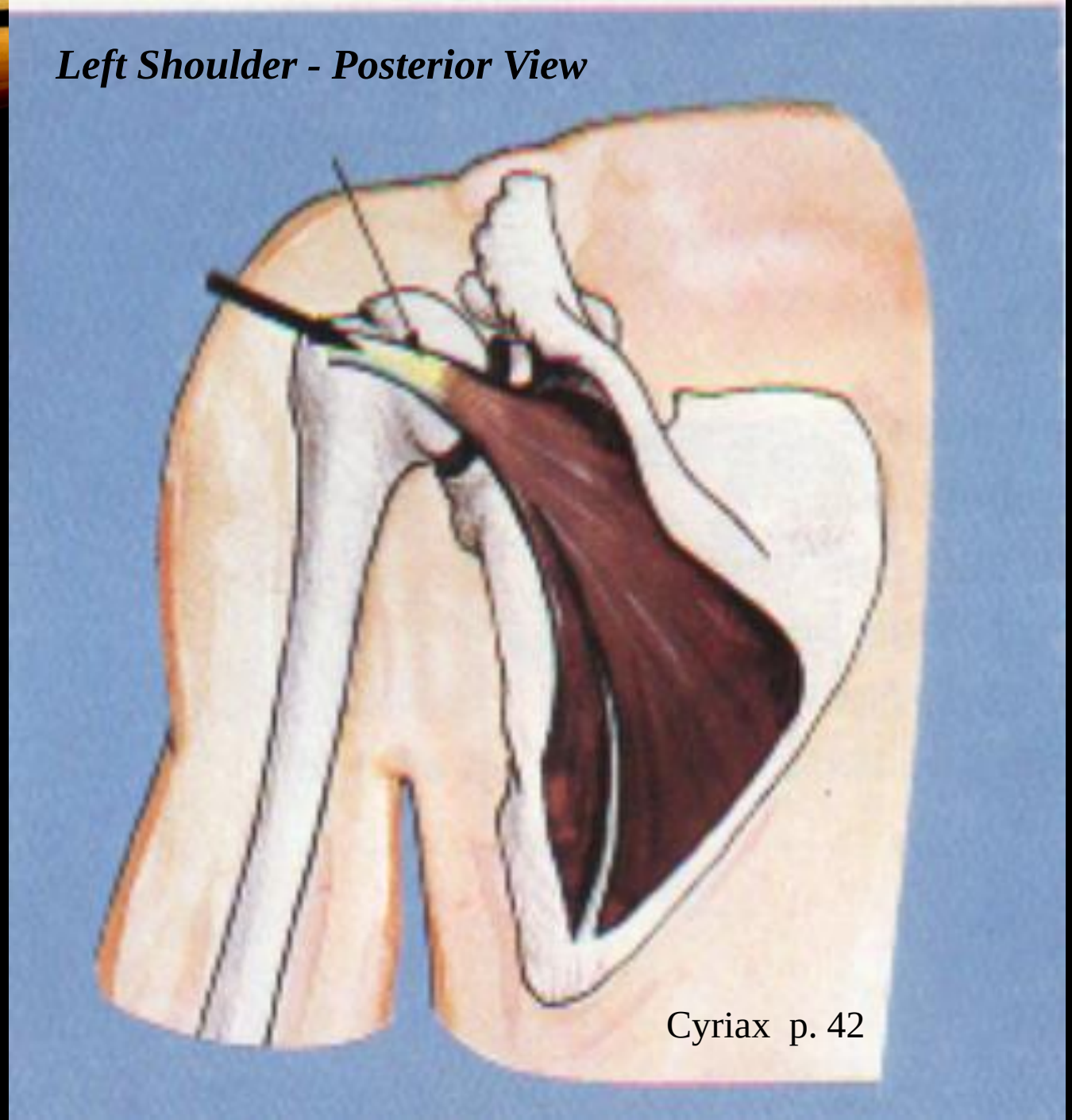

ROTATOR CUFF PALPATION

- **Supraspinatus** – Hand in back pocket
- **Subscapularis** – Elbow flexed and arm externally rotated
- **Infraspinatus** – Hand on opposite shoulder
- Other areas: A-C Joint, Biceps Tendon, Capsule, Coracoid, Etc.

PALPATION OF THE A-C JOINT

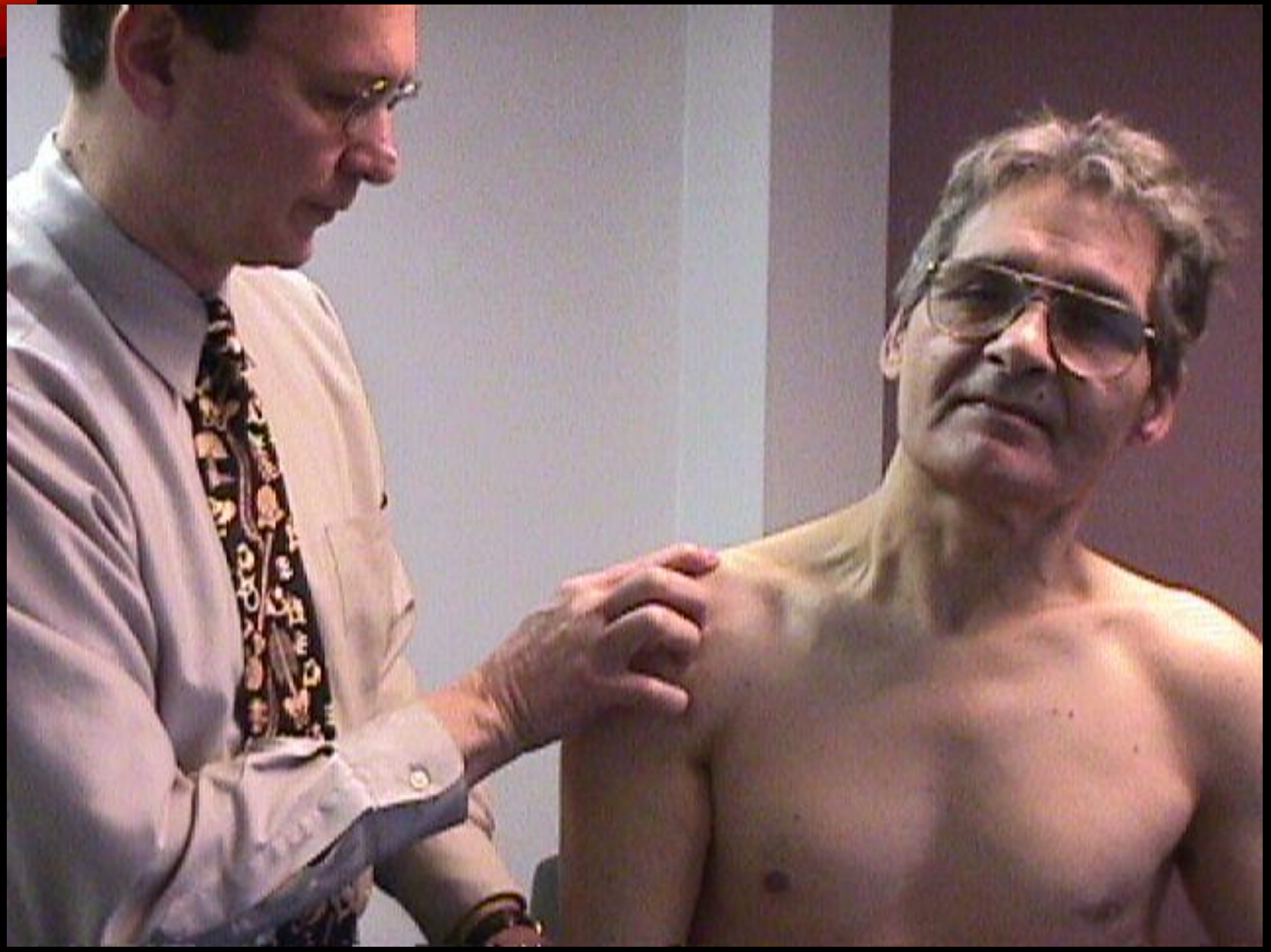

ORIENTATION OF THE A-C JOINT

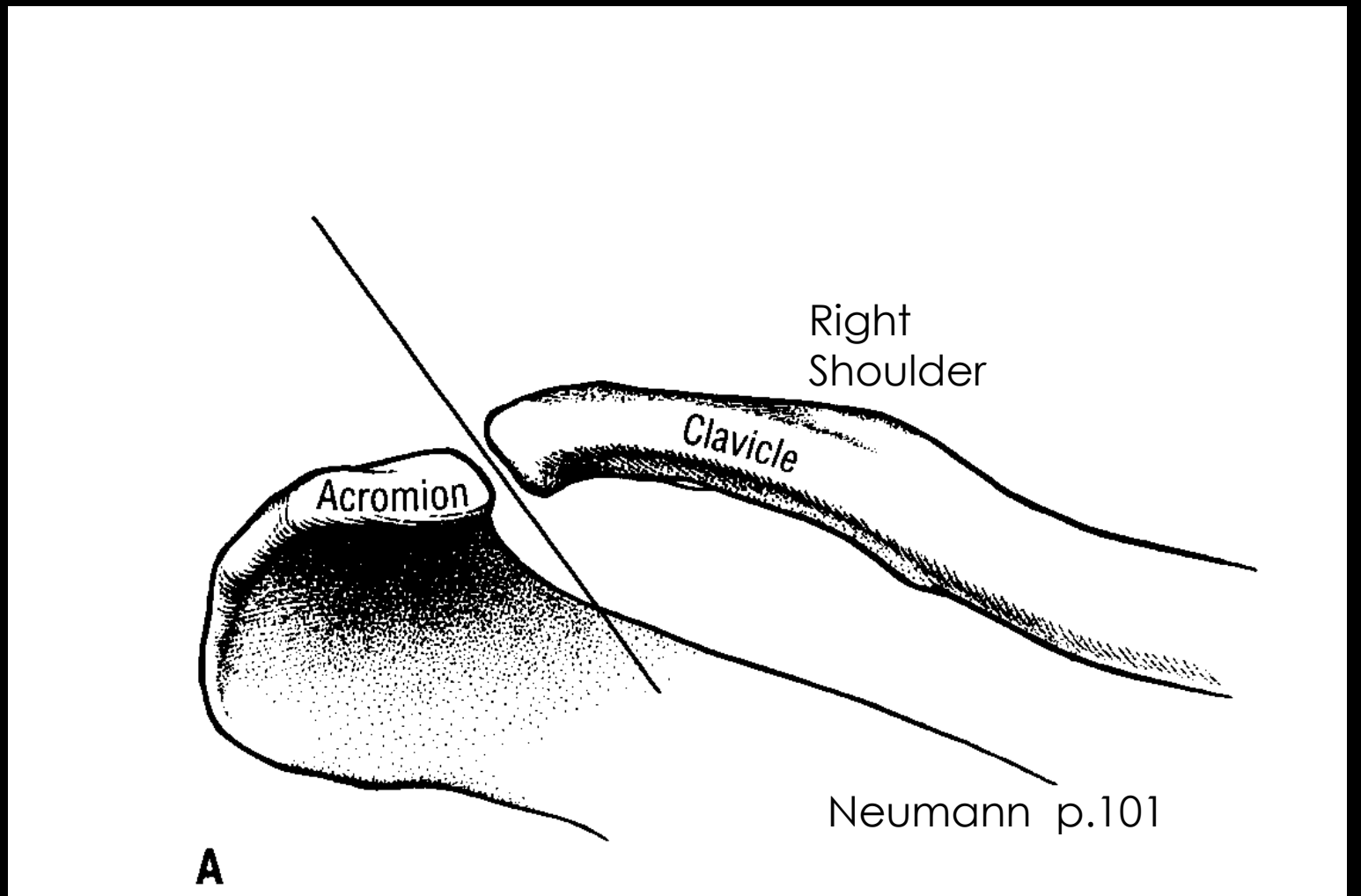

ULTRASOUND EVALUATION OF THE SHOULDER

MSMPC DIAGNOSTIC PROTOCOL

– See Handout

DIAGNOSTIC ULTRASOUND OF THE SHOULDER

Patient Demonstration

B F 10 MHz G 70%
D 4 cm XV C
PRC 10-5-L PRS 5
PST 4 MV 2
SHOULDER LA523
RIGHT LONG SUPRA POSTERIOR

Normal

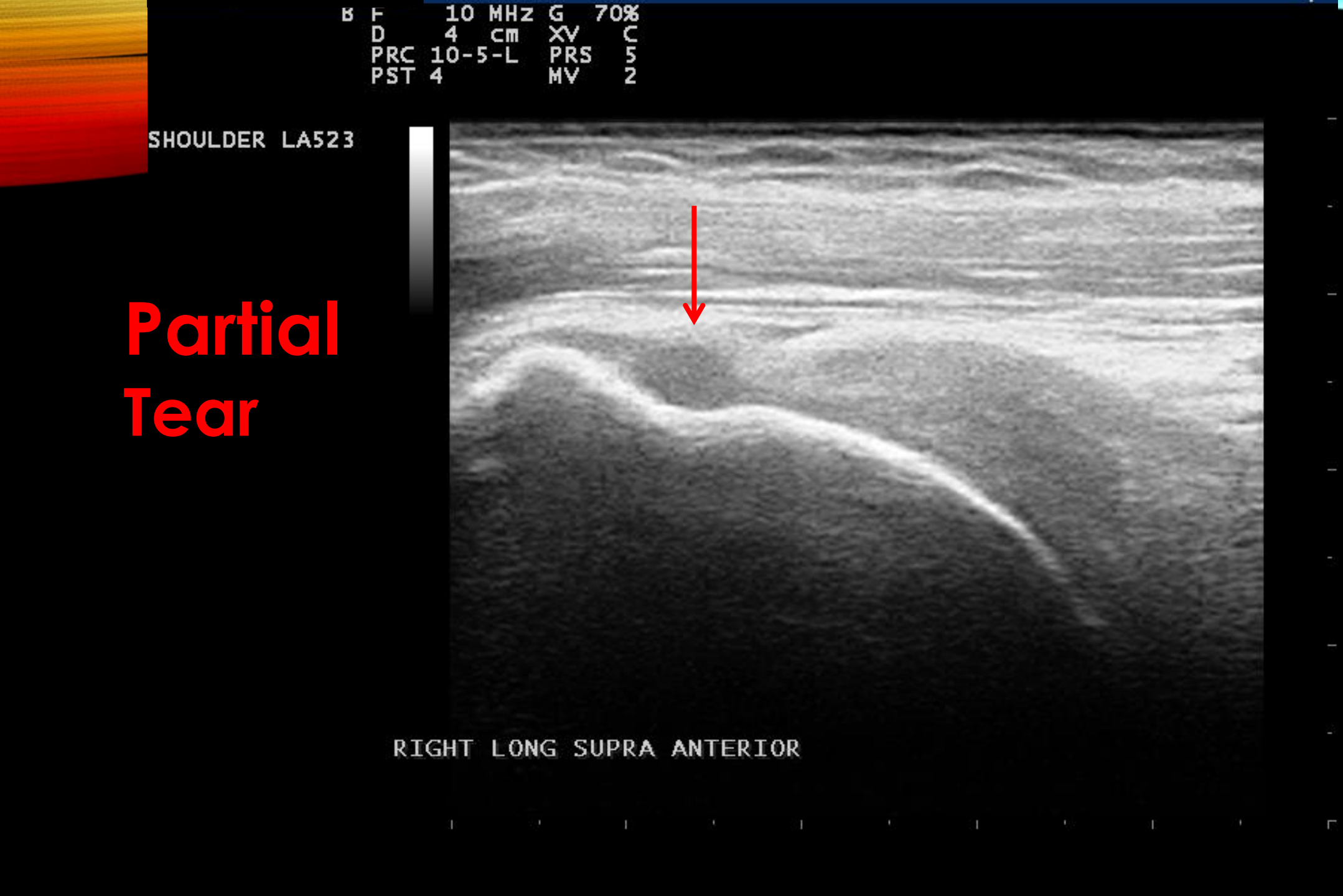

Partial Tear

B F 10 MHz G 70%
D 5 cm XV C
PRC 10-5-L PRS 5
PST 4 MV 2

SHOULDER LA523

Supraspinatus
Longitudinal View

Partial Tear

B F 10 MHz G 70%
D 5 cm XV C
PRC 10-5-L PRS 5
PST 4 MV 2

SHOULDER LA523

Supraspinatus
Transverse View

Partial Tear

B F 10 MHz G 70%
D 5 cm XV C
PRC 10-5-L PRS 5
PST 4 MV 2

SHOULDER LA523

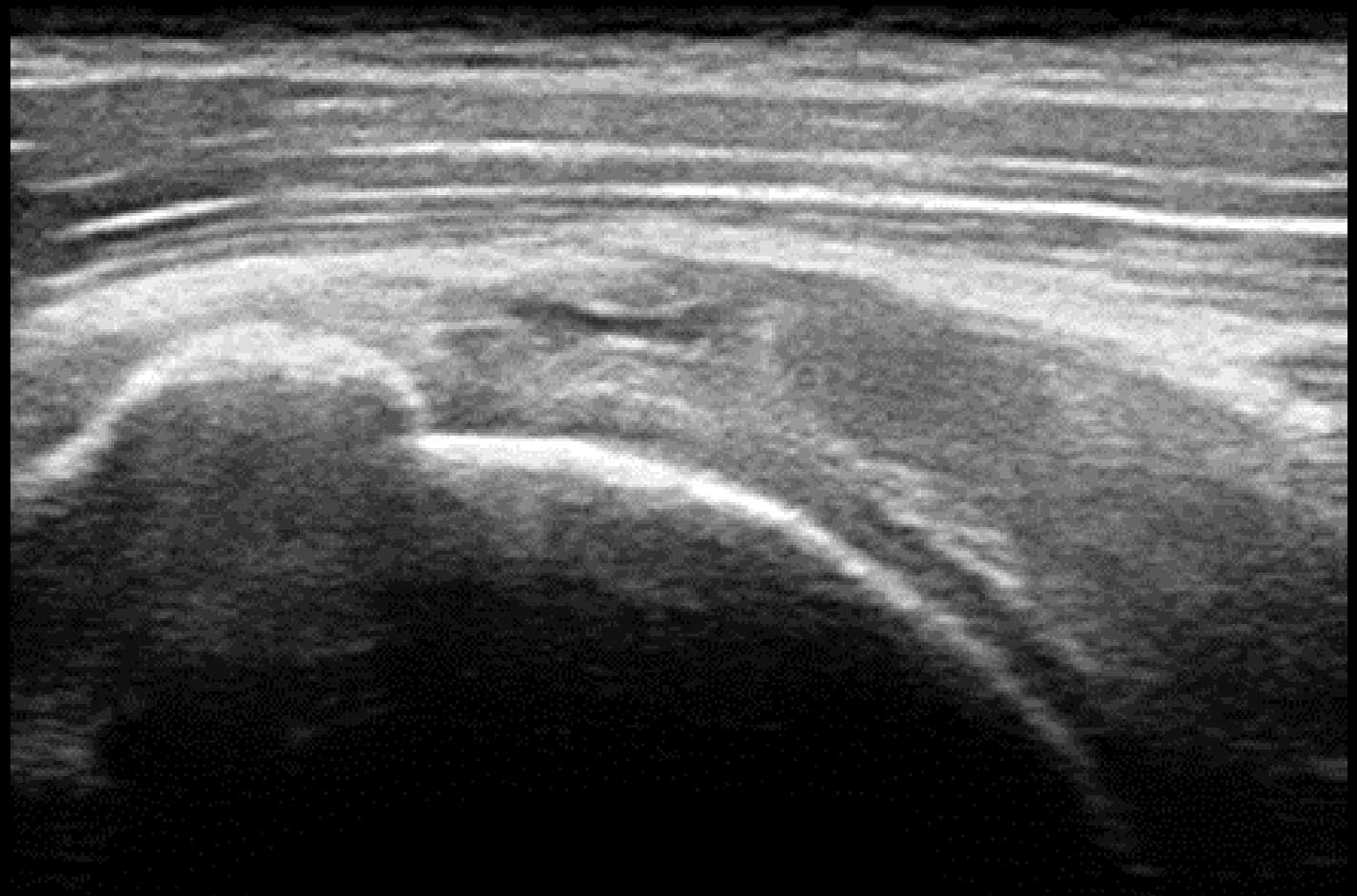

Supraspinatus
Longitudinal View

Partial Tear

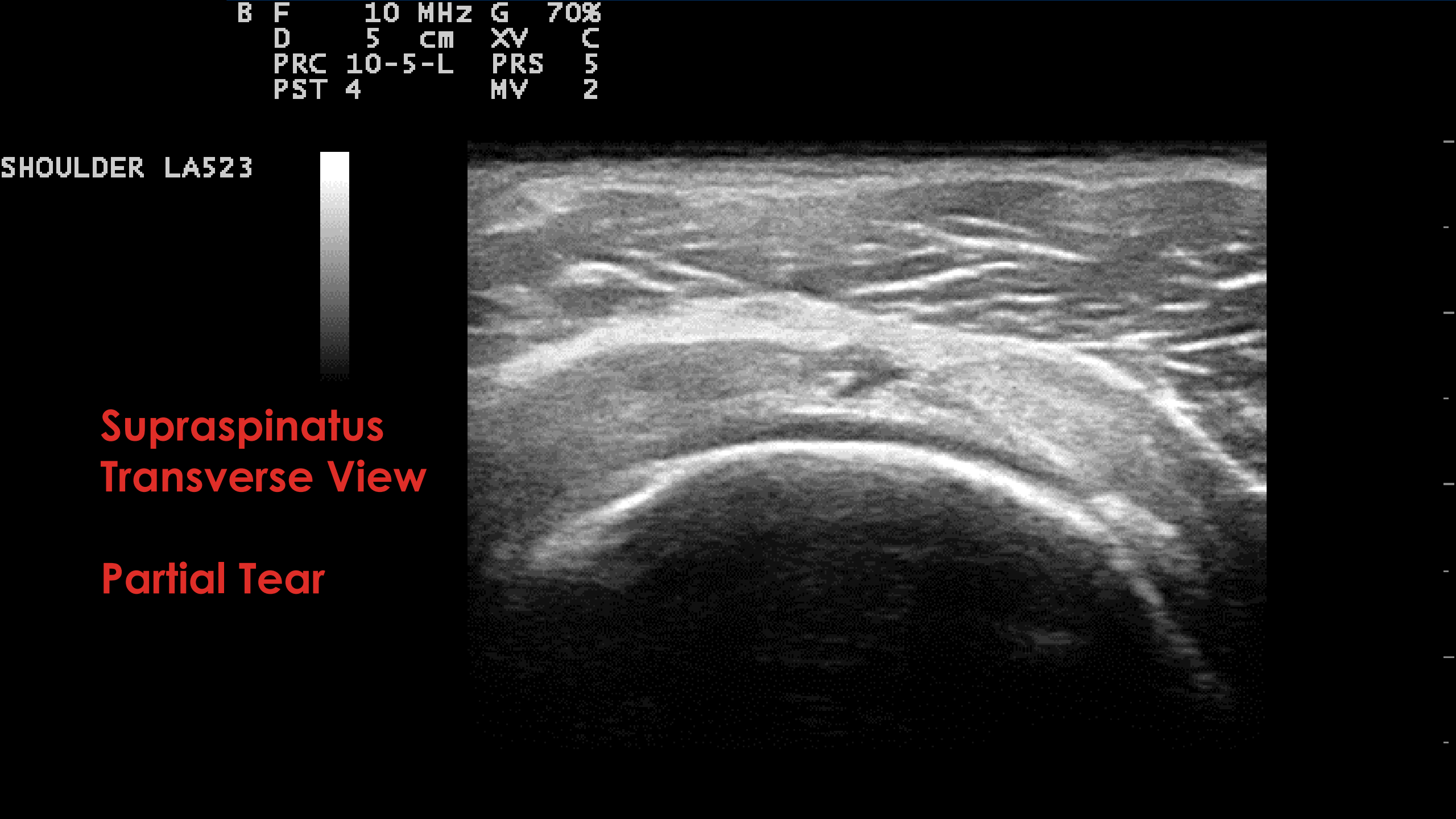
B F 10 MHz G 70%
D 5 cm XV C
PRC 10-5-L PRS 5
PST 4 MV 2
SHOULDER LA523
Supraspinatus
Transverse View
Partial Tear

Video Clip

B F 10 MHz G 70%
D 5 cm XV C
PRC 10-5-L PRS 5
PST 4 MV 2
0:00:00.48
SHOULDER LA523
LEFT LONG SUPRA ANTERIOR

B F 10 MHz G 70%
D 5 cm XV C
PRC 10-5-L PRS 5
PST 4 MV 2

SHOULDER LA523

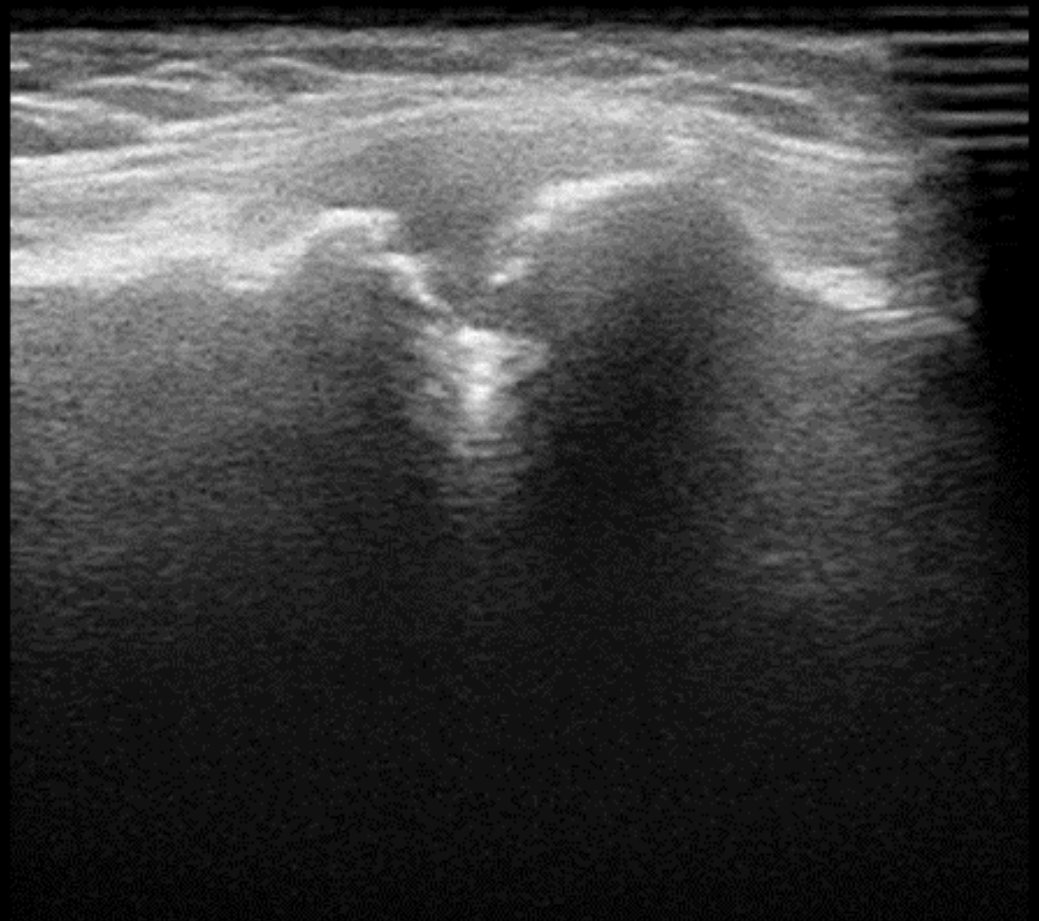

LEFT TRANS A-C JOINT MID PORTION

MRI VS. ULTRASOUND

- Accuracy of MRI, MR Arthrography, and Ultrasound in the Diagnosis of Rotator Cuff Tears: A Meta-Analysis. AJR:192,June 2009; 1701-1707.
  - Dept. of Radiology, Thomas Jefferson University Hospital

- A meta-analysis of 65 articles showed:

- **No significant difference between MRI and Ultrasound for the diagnosis of partial or full thickness tears of the rotator cuff.**

- MR Arthrography was slightly superior to both of the above.

PLATELET RICH PLASMA (PRP)

PRP promotes natural healing mechanisms by release of growth factors and other bioactive substances.

PDGFs – Platelet Derived Growth Factors alpha and beta

- Plays a role in cell differentiation and neovascularization

TGF – Transforming Growth Factors beta 1 and beta 2

- Stimulates Tendon Differentiation and Formation of Collagen

EGF – Epithelial Growth Factor

- Induces Fibroblast Proliferation

VEGF – Vascular Endothelial Growth Factor

- Stimulates Neovascularization

PLATELET RICH PLASMA (PRP)

- AUTOLOGOUS CONCENTRATION 0F PLATELETS OBTAINED BY WHOLE BLOOD CENTRIFUGATION

Mention Secondary Processing to remove rbc's

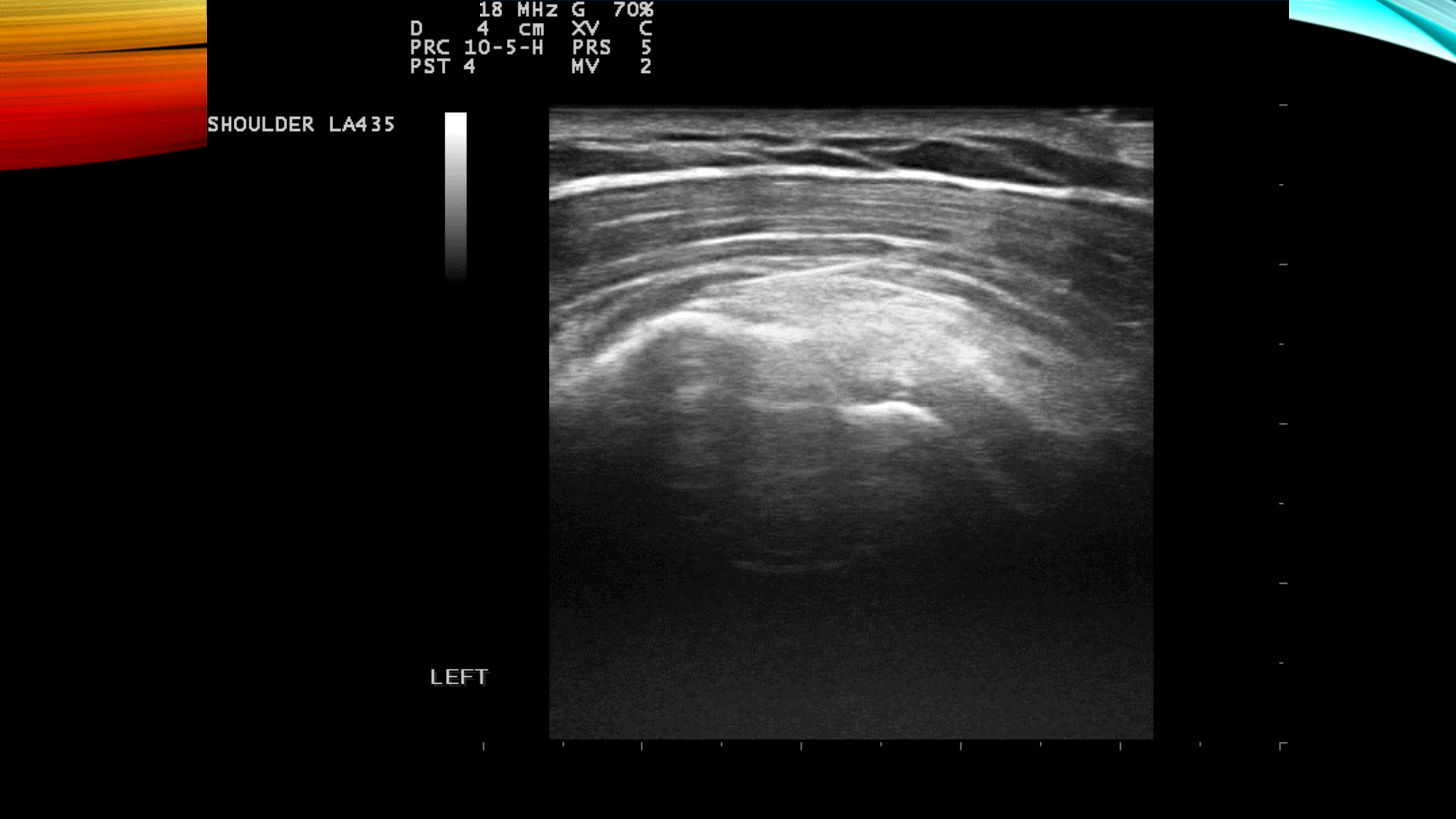
18 MHz G 70%
D 4 cm XV C
PRC 10-5-H PRS 5
PST 4 MV 2
SHOULDER LA435
LEFT

43 y; F;
FEB 14 2018 10:30am
B F 15 MHz G 70%
D 3 cm XV C
PRC 10-5-H PRS 5
PST 4 MV 2

43 y, F,
FEB 14 2018 10:32am
B F 15 MHz G 70%
D 3 cm XV C
PRC 10-5-H PRS 5
PST 4 MV 2

PRP SHOULDER INDIVDUAL CASE STUDY

61 yo accountant and avid weight lifter c/o R shoulder pain.

Hx of Right shoulder surgery. Several years of pain with activity.

Pain is primarily anterior.

Exam: Restriction to elevation – 170 degrees (180 left), lateral rotation 60 degrees.

Positive empty can test, Tender over the supraspinatus

Prolotherapy with aqueous testosterone: 12/28/16 and 5/9/17

– with a marginal response.

6/09/17: Dx Ultrasound– partial thickness tear supraspinatus, A-C joint degenerative changes, subscapularis tendinosis

PRP Right shoulder

7/07/17: F/U - Sore for 2 days, no improvement as yet

8/17/18: F/U –About 30% improved, restarted working out

9/08/17: F/U and Repeat Ultrasound –partial thickness tear supraspinatus. Continues to improve clinically.

4/18/18: Phone – Significantly improved, about 80% better.

2/04/19: Phone –Essentially pain free. Full workouts. Still limited tightness.

EFFICACY OF TREATING ROTATOR CUFF PATHOLOGY WITH PRP

- **American Academy of Orthopaedic Surgeons:** 2013 Poster Presentation
  Study on rotator cuff tendinopathy without a full thickness tear

- **204 patients** – 102 injected directly into tendon with PRP
  - 102 controls injected into the subacromial space with steroid
- **1- year follow-up:** PRP group had significantly better ROM
  48 steroid treated patients and only 3 PRP treated patients required surgery

EFFICACY OF TREATING ROTATOR CUFF PATHOLOGY WITH PRP

- Multiple studies have shown mixed results.
- Our impression is that over 90% of patients have had positive results.
- We hope to have our case study results completed later this year.
- More research needed.

QUESTIONS ?

You are all invited to our office on a select Friday to witness our clinical use of ultrasound imaging.

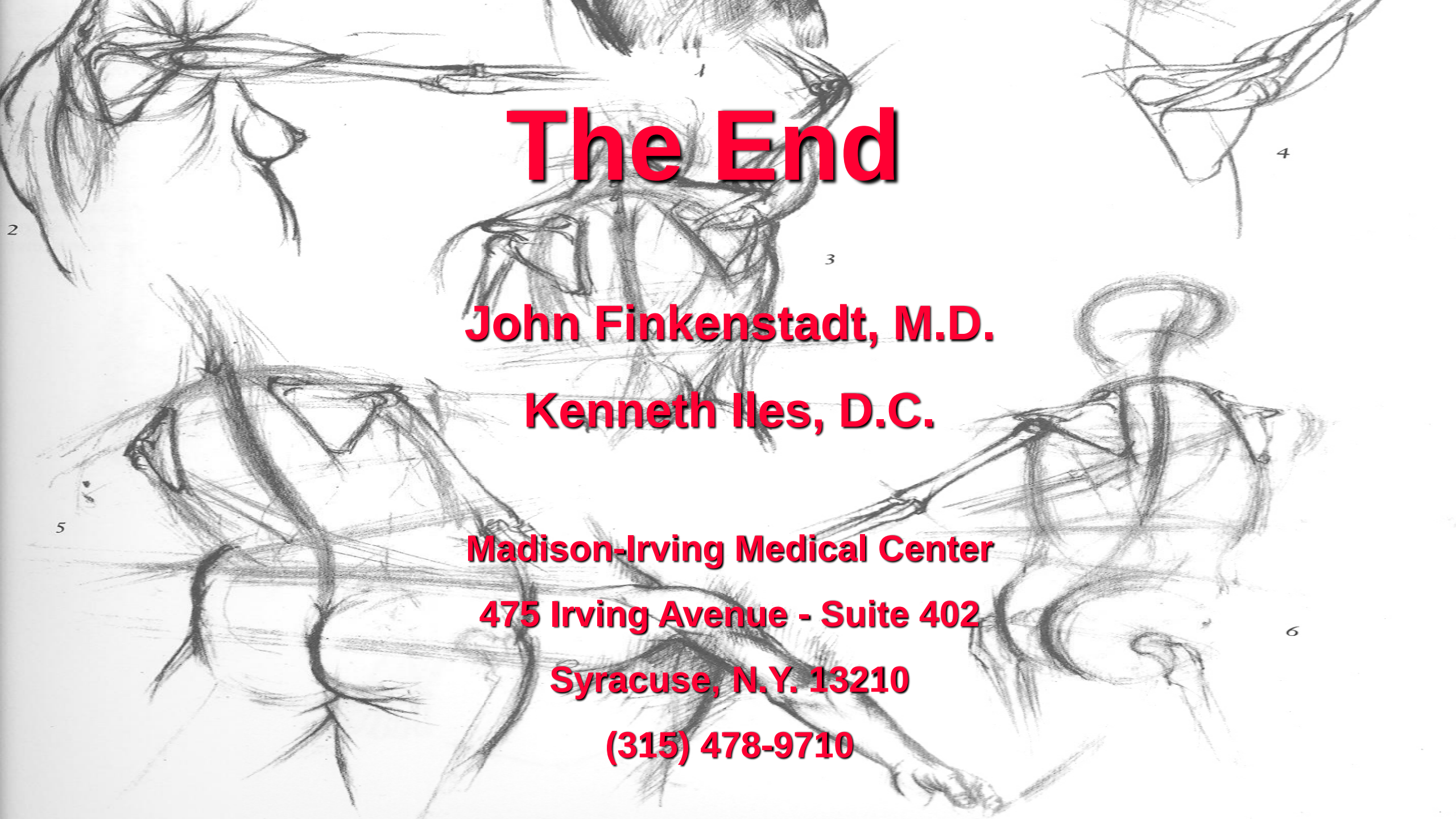

The End

John Finkenstadt, M.D.

Kenneth Iles, D.C.

Madison-Irving Medical Center

475 Irving Avenue - Suite 402

Syracuse, N.Y. 13210

(315) 478-9710