

Abtin Tabae, M.D.

Department of Otolaryngology—
Head and Neck Surgery,
New York Presbyterian Hospital,
Weill Medical College of
Cornell University,
New York, New York

Vijay K. Anand, M.D.

Department of Otolaryngology—
Head and Neck Surgery,
New York Presbyterian Hospital,
Weill Medical College of
Cornell University,
New York, New York

Justin F. Fraser, M.D.

Department of Neurosurgery,
New York Presbyterian Hospital,
Weill Medical College of
Cornell University,
New York, New York

Seth M. Brown, M.D., M.B.A.

Department of Otolaryngology—
Head and Neck Surgery,
New York Presbyterian Hospital,
Weill Medical College of
Cornell University,
New York, New York

Ameet Singh, M.D.

Department of Otolaryngology—
Head and Neck Surgery,
New York Presbyterian Hospital,
Weill Medical College of
Cornell University,
New York, New York

Theodore H. Schwartz, M.D.

Departments of Neurosurgery,
Otolaryngology—Head and Neck Surgery,
and Neurology,
New York Presbyterian Hospital,
Weill Medical College of
Cornell University,
New York, New York

Reprint requests:

Theodore H. Schwartz, M.D.,
Departments of Neurosurgery,
Otolaryngology—Head and Neck Surgery,
and Neurology,
New York Presbyterian Hospital,
Weill Medical College of
Cornell University,
525 East 68th Street, Box 99,
New York, NY 10065.
Email: schwarh@med.cornell.edu

Received, May 27, 2008.

Accepted, September 19, 2008.

Copyright © 2009 by the
Congress of Neurological Surgeons

THREE-DIMENSIONAL ENDOSCOPIC PITUITARY SURGERY

OBJECTIVE: We describe a novel 3-dimensional (3-D) stereoendoscope and discuss our early experience using it to provide improved depth perception during transsphenoidal pituitary surgery.

METHODS: Thirteen patients underwent endonasal endoscopic transsphenoidal surgery. A 6.5-, 4.9-, or 4.0-mm, 0- and 30-degree rigid 3-D stereoendoscope (Visionsense, Ltd., Petach Tikva, Israel) was used in all cases. The endoscope is based on “compound eye” technology, incorporating a microarray of lenses. Patients were followed prospectively and compared with a matched group of patients who underwent endoscopic surgery with a 2-dimensional (2-D) endoscope. Surgeon comfort and/or complaints regarding the endoscope were recorded.

RESULTS: The 3-D endoscope was used as the sole method of visualization to remove 10 pituitary adenomas, 1 cystic xanthogranuloma, 1 metastasis, and 1 cavernous sinus hemangioma. Improved depth perception without eye strain or headache was noted by the surgeons. There were no intraoperative complications. All patients without cavernous sinus extension (7 of 9 patients) had gross tumor removal. There were no significant differences in operative time, length of stay, or extent of resection compared with cases in which a 2-D endoscope was used. Subjective depth perception was improved compared with standard 2-D scopes.

CONCLUSION: In this first reported series of purely 3-D endoscopic transsphenoidal pituitary surgery, we demonstrate subjectively improved depth perception and excellent outcomes with no increase in operative time. Three-dimensional endoscopes may become the standard tool for minimal access neurosurgery.

KEY WORDS: Endoscopic, Minimal access, Minimally invasive, Pituitary, 3-dimensional, Transsphenoidal

Neurosurgery 64[ONS Suppl 2]:ons288–ons295, 2009

DOI: 10.1227/01.NEU.0000338069.51023.3C

Initially described by Schloffer (21) and Cushing (9) and subsequently popularized by Guiot (12) and Hardy and Wigser (14), the transsphenoidal approach to the sella now represents the preferred approach for removing pituitary adenomas. Traditionally performed with a microscope and a sublabial incision, the implementation of the endoscope and endonasal access has rendered the transsphenoidal approach less invasive and provided improved visualization into and around the sella (4, 5, 16–18). Nevertheless, one of the primary restrictions of endoscopic or endoscope-assisted surgery is the lack of binocular or stereoscopic vision. Monocular endoscopes and displays create a 2-dimensional (2-D) image that impairs depth perception, hand-eye coordination,

ABBREVIATIONS: 3-D, 3-dimensional; 2-D, 2-dimensional

and the ability to estimate size (1, 24). Operating in a 2-D environment requires surgeons to train their hand-eye coordination to respond to visual cues received by the interaction of the operative instruments with the environment to accurately understand the relative depth of structures in the 2-D projection. Surgeons will often move the endoscope in and out or side to side to gain a motion parallax depth cue. This lack of stereoscopic vision has contributed to the steep learning curve in the field of neuroendoscopy. The next obvious step in the evolution of minimal access endoscopic surgery is the development of high-definition stereoendoscopes that produce a 3-dimensional (3-D) image. Although such stereoendoscopes exist (1, 2, 24), their use in neurosurgery has been limited because of the larger diameter and poor resolution of earlier generations. Hence, only 1 report exists of using stereoendoscopes

in neurosurgery, and only as an adjunct to the microscope (7). Herein, we describe the first purely stereoendoscopic 3-D neurosurgery in a series of patients with pituitary adenomas, and we introduce a new high-definition 3-D stereoendoscope with a diameter suitable for neurosurgical application.

PATIENTS AND METHODS

A prospective case series of endoscopic pituitary operations incorporating a 3-D stereoendoscope was performed after institutional review board approval. All procedures were performed by the senior authors (VKA, THS). Three-dimensional endoscopic visualization was used for the entire operation, including the transnasal, transsphenoidal approach, the tumor resection, and the sellar reconstruction. Patients were followed prospectively for incidence of perioperative complications including hemorrhage, cerebrospinal fluid leak, deterioration in visual acuity or fields, and new-onset diplopia. Extent of resection was determined based on volumetric comparison of preoperative to approximately 2-month postoperative contrast-enhanced T1-weighted magnetic resonance imaging scans performed by an independent neuroradiologist. The surgeons completed a questionnaire at the end of each operation listing the subjective benefits and limitations of the 3-D stereoendoscope and any physical discomfort associated with its use. Operative time and extent of resection were retrospectively compared with a cohort of control patients who underwent endoscopic surgery using 2-D endoscopes (including 0-, 30-, and 45-degree endoscopes) during the same time period. Patients were controlled for age, sex, location of tumor, pathology, and cavernous sinus extension. Statistical comparisons were performed using Student's *t* test for parametric data and Mann-Whitney tests for non-parametric data; significance was defined as $P < 0.05$.

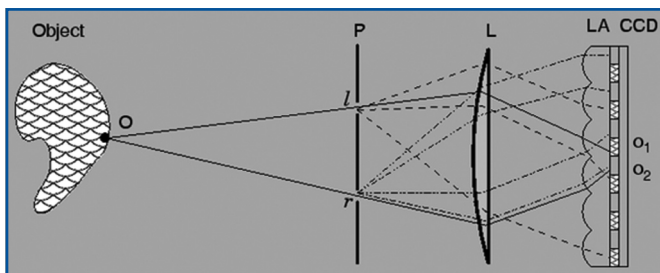


FIGURE 1. Schematic representation of the imaging technology of the 3-dimensional (3-D) endoscope. The imaging objective is represented by a single lens (L) with 2 pupil openings at the front focal plane (P). This arrangement generates a telecentric objective, in which all the light rays passing through the center of each pupil emerge as a parallel beam behind the lens. The charge-coupled device chip is covered by a lenticular array (LA)—an array of 0-power cylindrical microlenses with their axes perpendicular to the plane. Rays that pass through a point at the left aperture (l) are emitted as a parallel beam (dashed lines in the drawing) behind the imaging lens. These rays are focused by the lenticular array on the pixels on the right side under the lenslets. Similarly, rays that pass through the right aperture (r) (dashed-dotted lines) are focused by the lenslets on the left pixels. A point O on the object is imaged twice, generating images on both pixels O₁ and O₂. The pixels O₁ and O₂ are left and right views of point O, and the distance between a pixel of the left view to the that of the right view (disparity) is a function of the distance of the object (O) from the camera.

Technology

For 3-D visualization, a 6.5-, 4.9-, or 4.0-mm, 0- and 30-degree rigid endoscope (Visionsense, Ltd., Petach Tikva, Israel) was used during the study. At the start of this project, the manufacturer had only developed a 6.0-mm, 0-degree scope, but after receiving feedback from the authors, the company eventually developed smaller scopes with angled tips. The 3-D visualization is based on a lenticular array, similar to the compound eye of an insect (Fig. 1). The spatial relations are conveyed by the single video chip mounted in the endoscope. The endoscope and camera unit and separate light-emitting diode illumination unit connect directly to the tower and monitor (Fig. 1). The interpupillary distance is 0.8 mm. The images were displayed using a Planar (Planar Systems, Inc., Beaverton, OR) 20-inch stereomirror (dual-flatscreen) system, which uses a double-coated polarized mirror to overlay right and left images. Polarizing light-weight glasses are worn for 3-D visualization. The variance in the image by the lens array allows for a 3-D rendering of the displayed object. The system also calculates volumetric information that can be used to create hybrid images with other data sets, including radiographic studies. Additionally, measurements can be taken from the 3-D images.

For 2-D visualization, the Storz endoscope system was used (Karl Storz GmbH & Co., Tuttlingen, Germany). The 2-D endoscopes were Hopkins II telescopes measuring 30 cm in length and 4 mm in diameter; both 0-degree and angled (30- and 45-degree) endoscopes were used. A Radiance 23-inch high-resolution medical display (National Display Systems, Morgan Hill, CA) with a native resolution of 1920 × 1200 was used.

RESULTS

Thirteen patients underwent 3-D endoscopic surgery of the sella. The final diagnoses in this cohort were: pituitary adenoma in 10 patients, metastasis in 1 patient, cystic xanthogranuloma in 1 patient, and cavernous sinus hemangioma in 1 patient. All patients underwent a purely endoscopic transnasal, transsphenoidal approach to the sella. Additional transplanum or cavernous sinus dissection was performed in 3 of these patients for suprasellar extension. Endoscopic examination of the tumor cavity revealed gross tumor removal in 10 patients (81.8%). Intentional subtotal tumor resection was achieved in 3 patients (18.2%) who presented with pituitary macroadenoma with extension into the cavernous sinus; in each case, tumor that was adherent to the cavernous sinus was left behind. There were no intraoperative complications in this study. One patient experienced transient postoperative diabetes insipidus requiring desmopressin.

Table 1 provides a comparison of the 3-D endoscopic cases to the matching retrospective cohort of 2-D endoscopic cases. Patients were matched based on diagnosis, use of extended approaches, and cavernous sinus invasion. Hence, in each group, 3 patients had extended approaches beyond the standard transsphenoidal approach. There were no significant differences in operative time, rate of gross total resection, or length of stay.

The senior authors reported subjectively improved depth perception throughout the procedure when using 3-D visualization. There were no occurrences of physical discomfort, headache, nausea, or ocular fatigue reported by the operating surgeons during the reported procedures. Noted advantages

TABLE 1. Summary of 3-dimensional and matched 2-dimensional cases^a

Characteristics	3-D (n = 13)	2-D (n = 13)	P value
Age, y (mean ± SD)	55.5 ± 11.3	57.3 ± 13.1	NS
Sex, female, no. (%)	4 (30.8)	8 (61.5)	NS
Lesion size, cm (largest diameter)	2.2 ± 0.6	2.6 ± 0.8	NS
Complexity, extended, no. (%)	3 (23.1)	3 (23.1)	NS
Length of stay, median (d)	4	3	NS
Diagnoses			
Total pituitary adenoma	10	11	
GH-producing pituitary adenoma	2	2	
Pituitary apoplexy	1	1	NS
Carcinoma	1	1	
Cystic lesions, Rathke's cleft (2-D) and xantho- granuloma (3-D)	1	1	
Cavernous hemangioma	1		
Total tumors involving cavernous sinus	2	2	
Operative time, mean ± SD (min)	142.6 ± 44.3	143.5 ± 28.9	NS
Gross total resection, no. (%)	10 (76.9)	9 (69.2)	NS
Unintended subtotal resection, no.	0	1	

^a 3-D, 3-dimensional; 2-D, 2-dimensional; SD, standard deviation; NS, not significant; GH, growth hormone.

of the stereoendoscope included subjectively increased depth perception and “a more natural feeling” during surgery. Limitations included difficulties in cleaning the endoscope in the absence of a sheath, lack of angled scopes, and increased diameter of the 3-D compared with the 2-D scope (6.5 or 4.9 versus 4 mm). However, these limitations were overcome with the development of an irrigation sheath and smaller-diameter scopes as well as angled scopes. Figures 2 and 3 illustrate comparable images acquired with 2-D and 3-D endoscopes.

DISCUSSION

The evolution in surgical approaches to the sella has largely paralleled advances in visualization and technology. The sublabial, transsphenoidal approach initially described by Schloffer (21) and popularized by Cushing (9) used headlight illumination through a speculum. Cushing himself largely abandoned this technique in favor of a transcranial approach in the latter stages of his career, likely secondary to the improved visualization and direct access associated with open surgery. The inte-

gration of operative microscopy and radiofluoroscopy in the second half of the 20th century ushered in the era of modern transsphenoidal pituitary surgery (12, 14). The use of rigid endoscopes represents the latest technological solution to the visualization issues of transsphenoidal surgery, including the long, narrow operative corridor that limits the field of view and the extension of the pathology behind and around critical neurovascular structures. The placement of the visualization source (endoscope) immediately proximal to the surgical field represents a clear contrast to microscopic surgery whereby the visualization source is outside of the patient and funneled through a speculum. Hence, endoscopic visualization using a combination of 0-degree and angled endoscopes provides panoramic visualization of the entire surgical field including the extension of the pathology behind other structures. Additionally, the endoscope provides a mobile eye, allowing the surgeon to focus the light and visualization on diverse regions of the operative field. Several researchers have suggested the possibility of improved rates of hospital length of stay, gross tumor resection, and postoperative complications of endoscopic compared with microscopic surgery (4, 5, 10, 17, 18).

The major criticism and limitation of endoscopic surgery relates to the lack of depth perception of the 2-D endoscopes. Depth perception is thought to be critical to precise motor movement. Two distinct aspects of the control of fine surgical movements have been described. The first involves initiation of a gross movement in the general desired direction. This is followed by multiple correctional movements that are modified based on a combination of visual cues (8). The number of required movements and accuracy of each movement are affected by the clarity of the visual feedback and experience of the surgeon. In endoscopic surgery, the lack of tactile cues and 2-D visualization represent barriers to efficient and accurate movements. The acquisition of endoscopic skills inherently involves the ability to translate a 2-D image into a mental 3-D representation of a given area. This occurs partially through monocular cues including relative structure, size, texture gradients, linear perspectives along anatomic trajectories, and motion parallax. Trained surgeons additionally learn to infer spatial relations from haptic cues and surgical movements. Despite these compensatory factors, 2-D visualization does not match the depth perception gained by binocular cues including vergence, stereopsis, and vertical disparities (11). Studies of human kinematics have demonstrated the negative consequences of monocular vision including longer movement times and a tendency to underestimate distances between objects (22). In a performance analysis of 252 laparoscopic bile duct injuries, for example, Way et al. (26) identified inaccurate visual perception as the cause in 97% of cases of error. Therefore, it is not difficult to appreciate that several prior studies have shown a benefit in speed, efficiency, and learning when the 3-D is compared with the 2-D scope (1, 2, 24).

Nevertheless, surgeons with significant experience in 2-D endoscopic surgery overcome these limitations by using visual and tactile cues. Hence, the 3-D stereoendoscope makes a more significant difference for novice users (2, 3, 20, 23–25). Similarly, several independent laboratories and clinical studies using exper-

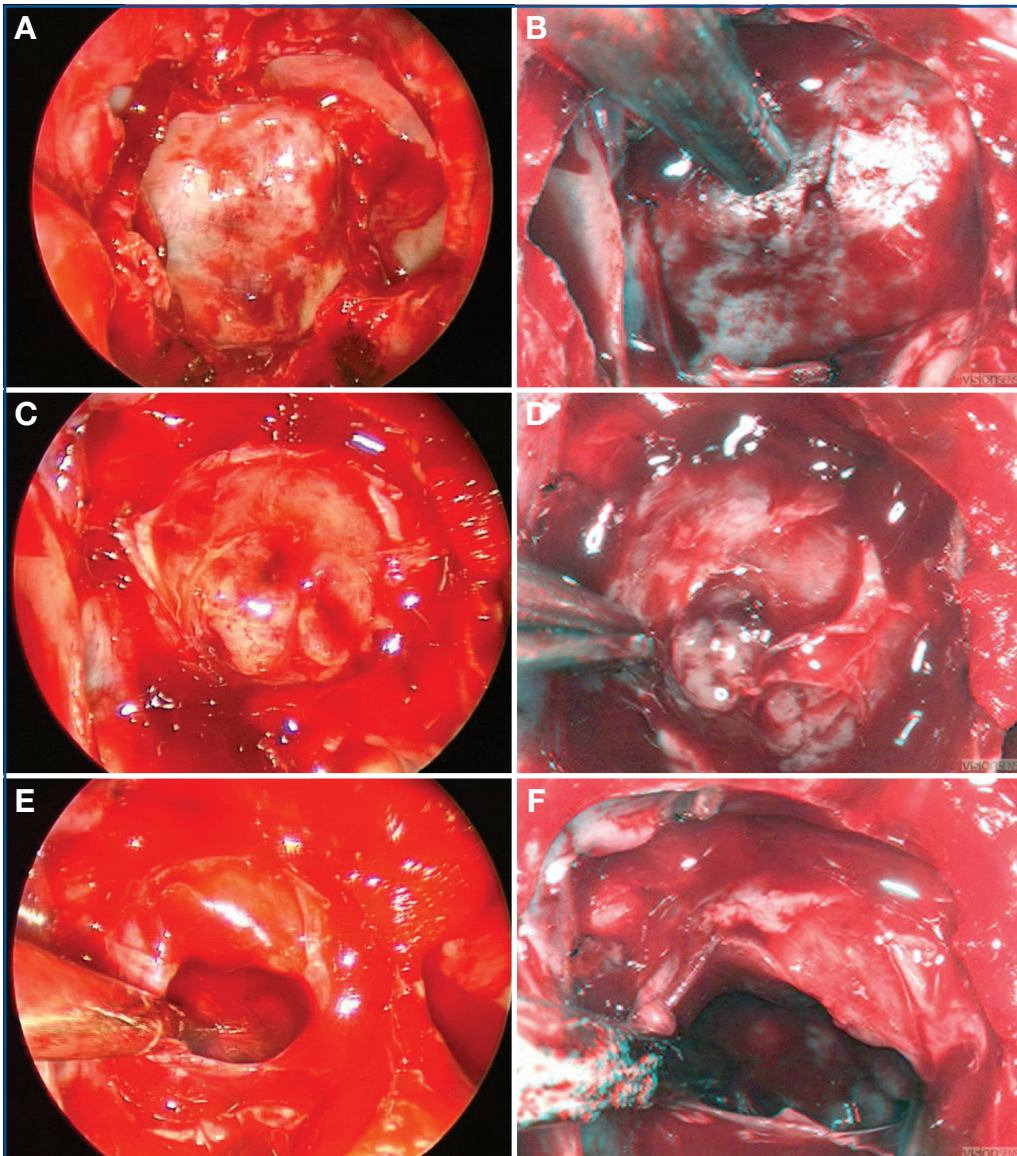


FIGURE 2. Comparable images of similar surgical steps in a transsphenoidal case using 2-D (A, C, E) and 3-D (B, D, F) endoscopes (3-D glasses are included with this issue for optimal visualization). A and B demonstrate the eggshell of bone overlying the dura. C and D show the opened dura with tumor herniating into the operative field. E and F demonstrate the cavity within the sella after tumor resection.

rienced laparoscopic surgeons reported improved subjective depth perception but failed to identify any difference in task performance using 2-D versus 3-D visualization (6, 13, 19). Therefore, it is likely that the greatest impact for 3-D stereoscopic use would be in decreasing the learning curve for new users. However, interpreting the results of these studies is limited by several factors. Surgeons experienced in using 2-D scopes might also experience some learning curve in the 3-D operative environment. Additionally, although objective measures show early improvement in learning curves with the use of a 3-D scope, determining significant differences in such factors as

of angled endoscopes, the decreased resolution compared with 2-D endoscopes, and the need to wear 3-D glasses, which permit 3-D sensation only at certain viewing angles and result in eye strain. The Visionsense 3-D scope is based on novel technology that addresses many of these obstacles. The technological designs of other systems currently available for 3-D visualization are different in that they are based on dual optical channel technology. Dual channel technology incorporates information from 2 distinct perspectives to render a single 3-D view, similar to human vision. This can be achieved with 2 separate endoscopes and cameras, or separate video chips incor-

complication rates, operative time, and visualization between 2-D and 3-D require large sample sizes, which have thus far been lacking in this arena of research. For these reasons, it can be very difficult to find any objective significant end points when comparing experienced users' outcomes between 2-D and 3-D scopes. The purpose of this report was to show, first, that these endoscopes can be used successfully in neurosurgical procedures with outcomes comparable to those achieved with standard 2-D endoscopes. In addition, the authors, experienced in 2-D endoscopy, did not find the 3-D images disorienting or lacking in resolution. This report also provides examples of 2-D versus 3-D images of the same operative field so that readers can see the differences and render their own judgment. Note that the 2-D images were not acquired with the newer high-definition cameras that provide higher-resolution images. Hence, any comparisons between the 2 technologies must be predicated on the current platform, which is evolving for both 2-D and 3-D scopes.

Technology of the Scope

Previous 3-D endoscopes have found little use in neurosurgery because of a variety of technical limitations, namely, their large diameter, the lack

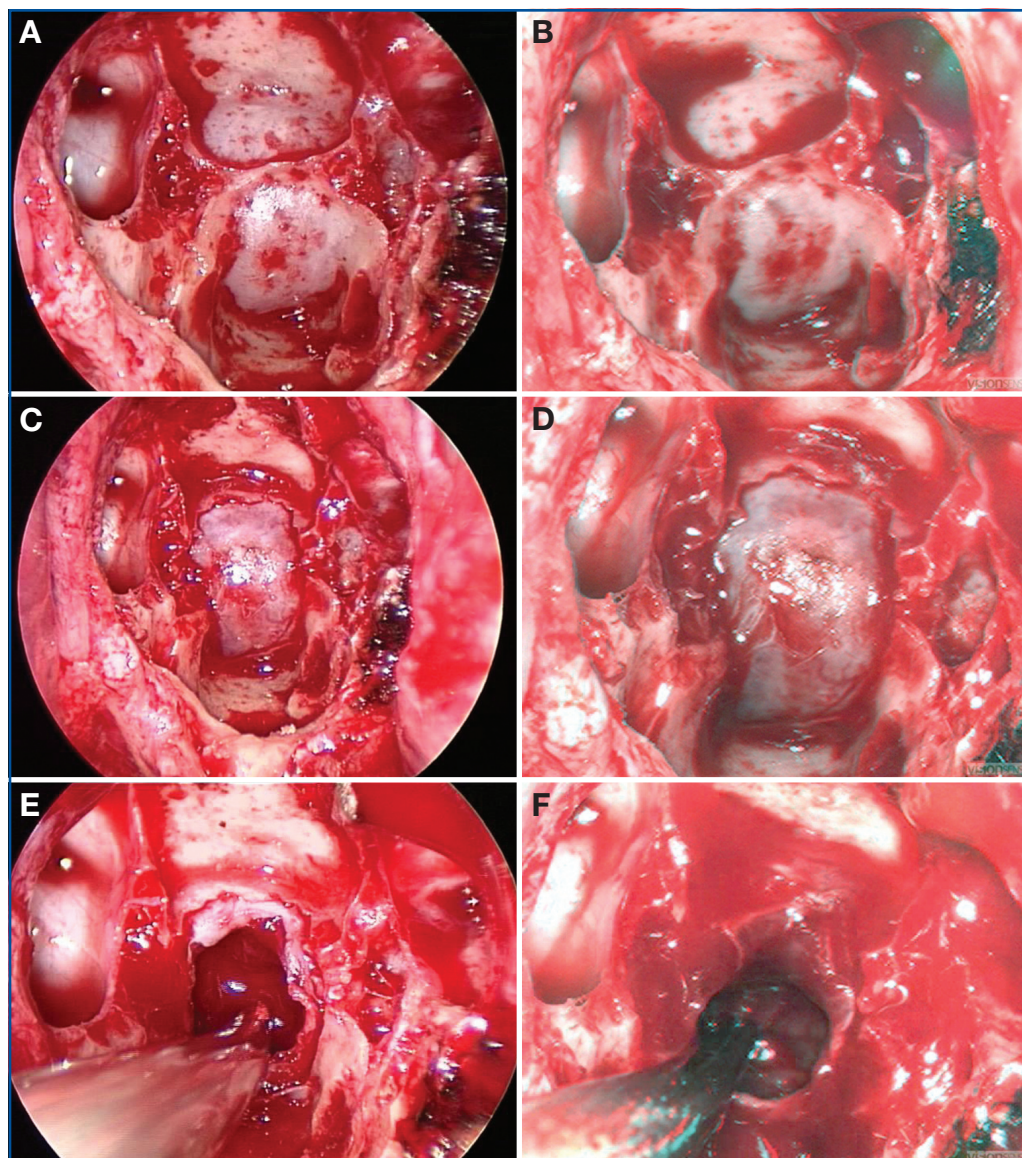


FIGURE 3. Images of similar steps in another transsphenoidal case using 2-D (A, C, E) and 3-D (B, D, F) endoscopes (3-D glasses are included with this issue for optimal visualization). A and B illustrate the bone of the posterior aspect of the sphenoid sinus before its removal. C and D show the dura of the sella. E and F demonstrate the cavity within the sella after tumor removal.

porated into a single tip. Subtle unmatched characteristics from the 2 visualization sources including vertical shift, focus, color balance, and magnification can result in ocular fatigue, headache, and nausea (15). Shutter mechanism technology, using a single camera, renders a 3-D view from the 2 pupils with a slight temporal shift, causing discomfort from variation between the right and left images, caused by continuous movement of the camera (enhanced by the optical magnification of the scope). “Insect eye” technology, or a “plenoptic” camera, as described herein, uses a single objective lens that splits light into 2 paths using 2 pupils, focusing them onto an array of

pixels, differentiated by a microlens on top of every pixel pair. These data are processed through a single video source to reconstruct a 3-D image. The avoidance of 2 separate image sources negates the side effects related to ocular strain. In a 2-D endoscopic environment, the emphasis is on increasing resolution, the goal of which is to provide more well-defined contrast between adjacent objects or targets to enhance the ability of the surgeon to use visual cues to judge relative depth and the 3-D nature of a nonplanar environment. In addressing the visual acuity of a 3-D endoscopic image, using 2-D image resolution as a basis of comparison is not the most relevant benchmark. Simply comparing the numerical pixel resolution of the image on an *x-y* axis understates the ability of a 3-dimensionally rendered and visualized image to provide real-time, immediate depth information on *x*, *y*, and *z* axes. For this reason, we have endeavored to directly compare 2-D and 3-D systems in their ability to help endoscopic surgeons perform the operative tasks. Ultimately, even if the systems are objectively at equipoise in affecting such variables as operative time, gross total resection, and complication rates, the surgeons’ subjective preferences might be just as important.

The limiting factor in scope/camera quality is the optics; the smaller the scope’s outer diameter, the larger the depth of field, and the poorer the image quality. The resulting optical blur spot limits the size of the minimum pixel. The blur spot of this plenoptic camera is smaller; thus, it is able to provide better image quality (27). For this reason, the resolution of the digital 3-D plenoptic endoscope can be superior to a 2-D endoscope because it is less constrained by the blur spot. With regard to diameter, the scopes described in this article have been decreased from 6.5 to 4.9 mm and are now 4.0 mm, which is adequately small for endoscopic endonasal surgery. The inter-

pupillary distance of the system remains 0.8 mm. In addition, angled scopes are now available. Semirigid (deflecting tip) scopes are also in development. Finally, the glasses will soon be replaced by autostereoscopic monitors that display the images in 3-D space without the need for glasses.

This study was also limited by the small sample size of the cohorts. Although we found no statistical difference between operative times and extent of resection between groups, the small sample size limits the power of the study, exposing the analysis to beta error. However, we aimed to describe an initial experience with a rapidly evolving technology. Our goal was to demonstrate the feasibility of 3-D endoscopic technology for practical use, rather than to statistically examine superiority of 1 visualization technique. We used the 2-D group as a “gold standard” control and succeeded in demonstrating that similar results could be achieved with a novel visualization technology. More rigorous controlled studies will be necessary to assess the objective value of 3-D visualization in neuroendoscopic cranial base surgery. This analysis was further limited by the fact that we could not compare 2-D and 3-D visualization objectively within each patient. Variables such as operative time and extent of resection require that 1 visualization method be used throughout a procedure to accurately value its effect. As such, within-patient comparisons of 2-D and 3-D endoscopy are limited to subjective interval comparisons of photo-documented portions of each case. For future research, such a limitation will require rigorous control of study groups to compare these visualization methods.

CONCLUSION

Our early experience with the use of a novel 3-D visualization system for endoscopic endonasal transsphenoidal surgery supports the feasibility and safety of this technology. A subjective improvement in depth perception was appreciated by both senior surgeons involved, and there was no increase in complications or operative time. As this technology becomes available to practicing transsphenoidal surgeons, it has the potential to correct the limitations of traditional 2-D endoscopic technology.

Disclosure

The authors have no personal financial or institutional interest in any of the drugs, materials, or devices described in this article.

REFERENCES

- Badani KK, Bhandari A, Tewari A, Menon M: Comparison of two-dimensional and three-dimensional suturing: Is there a difference in a robotic surgery setting? *J Endourol* 19:1212–1215, 2005.
- Blavier A, Gaudissart Q, Cadière GB, Nyssen AS: Comparison of learning curves and skill transfer between classical and robotic laparoscopy according to the viewing conditions: Implications for training. *Am J Surg* 194:115–121, 2007.
- Byrn JC, Schluender S, Divino CM, Conrad J, Gurland B, Shlasko E, Szold A: Three-dimensional imaging improves surgical performance for both novice and experienced operators using the da Vinci Robot System. *Am J Surg* 193:519–522, 2007.
- Cappabianca P, Cavallo LM, Colao A, de Divitiis E: Surgical complications associated with the endoscopic endonasal transsphenoidal approach for pituitary adenomas. *J Neurosurg* 97:293–298, 2002.
- Cappabianca P, Cavallo LM, de Divitiis E: Endoscopic endonasal transsphenoidal surgery. *Neurosurgery* 55:933–941, 2004.
- Chan AC, Chung SC, Yim AP, Lau JY, Ng EK, Li AK: Comparison of two-dimensional vs three-dimensional camera systems in laparoscopic surgery. *Surg Endosc* 11:438–440, 1997.
- Chen JC, Levy ML, Corber Z, Assifi MM: Concurrent three dimensional neuroendoscopy: Initial descriptions of application to clinical practice. *Neurosur Focus* 6:e12, 1999.
- Chua R, Elliott D: Visual regulation of manual aiming. *Hum Mov Sci* 12:365–401, 1993.
- Cushing H: III. Partial hypophysectomy for acromegaly: With remarks on the function of the hypophysis. *Ann Surg* 50:1002–1017, 1909.
- Frank G, Pasquini E, Farneti G, Mazzatenta D, Sciarretta V, Grasso V, Faustini Fustini M: The endoscopic versus the traditional approach to pituitary surgery. *Neuroendocrinology* 83:240–248, 2006.
- Goodale MA, Meenan JP, Bühlhoff HH, Nicolle DA, Murphy KJ, Racicot CI: Separate neural pathways for the visual analysis of object shape in perception and prehension. *Curr Biol* 4:604–610, 1994.
- Guiot G: Transsphenoidal approach in the surgical treatment of pituitary adenomas: General principles and indications in non-functioning adenomas, in Kohler PO, Ross GT (eds): *Diagnosis and Treatment of Pituitary Tumors*. New York, American Elsevier, 1973, pp 159–178.
- Hanna GB, Shimi SM, Cuschieri A: Randomised study of influence of two-dimensional versus three-dimensional imaging on performance of laparoscopic cholecystectomy. *Lancet* 351:248–251, 1998.
- Hardy J, Wigser SM: Trans-sphenoidal surgery of pituitary fossa tumors with televised radiofluoroscopic control. *J Neurosurg* 23:612–619, 1965.
- Hofmeister J, Frank TG, Cuschieri A, Wade NJ: Perceptual aspects of two-dimensional and stereoscopic display techniques in endoscopic surgery: Review and current problems. *Semin Laparosc Surg* 8:12–24, 2001.
- Jankowski R, Auque J, Simon C, Marchal JC, Hepner H, Wayoff M: Endoscopic pituitary tumor surgery. *Laryngoscope* 102:198–202, 1992.
- Jho HD: Endoscopic transsphenoidal surgery. *J Neurooncol* 54:187–195, 2001.
- Laufer I, Anand VK, Schwartz TH: Endoscopic, endonasal extended transsphenoidal, transplanum transtuberulum approach for resection of suprasellar lesions. *J Neurosurg* 106:400–406, 2007.
- McDougall EM, Soble JJ, Wolf JS Jr, Nakada SY, Elashry OM, Clayman RV: Comparison of three-dimensional and two-dimensional laparoscopic video systems. *J Endourol* 10:371–374, 1996.
- Perez-Cruet MJ, Foley KT, Isaacs RE, Rice-Wyllie L, Wellington R, Smith MM, Fessler RG: Microendoscopic lumbar discectomy: Technical note. *Neurosurgery* 51 [Suppl]:S129–S136, 2002.
- Schloffer H: Erfolgreiche Operation eines Hypophysentumors auf nasalem Wege [Successful operation of a hypophyseal tumor through the nasal passage]. *Wien Klin Wochenschr* 20:621–624, 1907.
- Servos P, Goodale MA, Jakobson LS: The role of binocular vision in prehension: A kinematic analysis. *Vision Res* 32:1513–1521, 1992.
- Sidhu RS, Tompa D, Jang R, Grober ED, Johnston KW, Reznick RK, Hamstra SJ: Interpretation of three-dimensional structure from two-dimensional endovascular images: Implications for educators in vascular surgery. *J Vasc Surg* 39:1305–1311, 2004.
- Taffinder N, Smith SG, Huber J, Russell RC, Darzi A: The effect of a second-generation 3D endoscope on the laparoscopic precision of novices and experienced surgeons. *Surg Endosc* 13:1087–1092, 1999.
- Votanopoulos K, Brunnicardi FC, Thornby J, Bellows CF: Impact of three-dimensional vision in laparoscopic training. *World J Surg* 32:110–118, 2008.
- Way LW, Stewart L, Gantert W, Liu K, Lee CM, Whang K, Hunter JG: Causes and prevention of laparoscopic bile duct injuries: Analysis of 252 cases from a human factors and cognitive psychology perspective. *Ann Surg* 237:460–469, 2003.
- Yaron A, Shechterman M, Horesh N: Blur spot limitations in distal endoscope sensors. Presented at Stereoscopic Displays and Virtual Reality Systems XIII, San Jose, California, January 16, 2006.

Acknowledgments

We thank Visionsense for technical support of this project.

COMMENTS

A theoretical limit of the currently available scopes is the lack of 3-dimensional (3-D) images. This problem is overcome by the reconstruction of the anatomy in the surgeon's mind through the use of multiple landmarks, but this requires additional effort, a steeper learning curve, and a sort of telekinetic slowing of the surgical action. The new 3-D endoscope studied by the authors, which until now has been limited to use in thoracoscopy and laparoscopy, represents a very interesting innovation in endoscopic transsphenoidal surgery. All those who already have experience with standard 2-dimensional (2-D) technology know that most of the improvements have been reached step by step (i.e., from mono- to 3-charge-coupled devices [CCDs] to full high-definition [HD] cameras, etc.) and have then resulted in real and major advantages for surgical procedures. This is why we are interested in such new proposals and eager to test them in our own hands, too.

Paolo Cappabianca
Naples, Italy

Tabaee et al. present their initial clinical experience in 13 patients who had endonasal endoscopic tumor removal with a 6.5-, 4.9-, or 4-mm 3-D endoscope. Overall, a subjective improvement in depth perception was noted in operations performed with the 3-D endoscope, compared to procedures performed in a matched cohort of patients with standard 2-D endoscopes.

The development of effective 3-D endoscopes would certainly be a welcome addition to the present endoscopic armamentarium. An important consideration not addressed in this assessment is how 3-D endoscopes will compare with 2-D endoscopes using the increasingly available HD cameras and video monitors. In future studies, it would be useful to directly compare 3-D versus HD 2-D images in the same patients. Given the current state of HD technology, whether 3-D endoscopic imaging can have a tangible clinical impact beyond that provided with 2-D HD imaging remains to be seen.

Daniel F. Kelly
Santa Monica, California

This is an important article promoting technological advances in neuroendoscopy. The authors show a practicable way to achieve a "natural" 3-D image comparable to today's standard in microsurgery with 4-mm Hopkins scopes. One of the limitations not only of endoscopy but also of video imaging-based microsurgery is the missing 3-D information; the restriction to the use of relative size and anatomic information alone during surgery with the 2-D-screen image requires considerable experience, and resulting tissue lesions or even getting stuck in the tissue with the 2-D endoscope are some of the main risks that may cause bleeding and functional damage in endoscopic neurosurgery. Thus, the authors are right that the missing 3-D information is an obstacle in the transition from the microscope to the endoscope. This is true even for the experienced microsurgeon who relies on 3-D information from today's microscopes, which is far better than that obtained with the naked eye—one of the main advantages of the surgical binocular microscope, aside from magnification and illumination.

The authors use a promising principle for endoscopic 3-D imaging. The conventional "telescope-type" stereoendoscopy with 2 separate endoscope channels does not allow diameters below 8 to 10 mm, as required in cranial neurosurgical endoscopy. Here, the authors used "compound eye technology" with a single lens and 2 pupils projecting on a CCD chip with a lenticular array, which is nicely illustrated in Figure 1 in the article. This allows an effective, less complex stereo imaging with 1 camera, even with 4-mm Hopkins II optics as the

"gold standard" in endoscopic transnasal pituitary and cranial base approaches; this technology is similar to the "Greenough principle," dating back to 1896, which allows single front lens stereoscopy (2), as used in many stereomicroscopes.

One of the disadvantages is certainly the relatively small (virtual) interpupillary distance (IPD) of less than 1 mm as the main factor for the stereoscopic effect; here, the stereoscopic performance of a microscope with typical stereoscopic bases of between 20 and 25 mm and almost unlimited stereoscopic depth in telescope-principle microscopes at $\times 3$ to $\times 13$ magnification, as well as of dual-lens stereoendoscopes with more than 3 mm (virtual) interpupillary distance (IPD), cannot be achieved (1). However, the IPD of almost 1 mm gives an adequate 2-D impression in a target distance of 1 to 2 cm, based on the typically ideal IPD to target ratio of 1:10 to 1:30 for stereoscopic imaging.

According to the authors, the precision of the IPD of the endoscope camera is controlled during manufacturing. Thus, the system will not provide true depth information, but it gives usable 3-D information in the high-magnification phase at short target distance in transnasal pituitary surgery. At longer distances, e.g., in the initial phase of the transnasal approach and preparation of the sphenoid sinus, the stereoscopic information will probably be marginal (no figures are provided with an endoscopic longer-distance overview).

That the use of stereoendoscopy will achieve better results in transnasal endoscopic approaches or in general in small-diameter endoscopic neurosurgery is not demonstrated (and not stated) by the authors. The "historical" comparison with 13 patients (similar age, similar pathology) who underwent operations with classic 4-mm glass rod Hopkins scopes using 2-D imaging is certainly not significant regarding the reported higher gross resection rates and 0 versus 1 unintended subtotal resections. The comparison, however, shows, at least, that the use of stereoendoscopy, even in this early phase, did not prolong the operation time and gives no worse result. So I do agree that 3-D endoscopy offers a chance for reducing the "learning curve" in endoscopic neurosurgery; a more familiar 3-D image will facilitate the transition from microsurgery to endoscopy for the microsurgically experienced neurosurgeon. Also the quality may improve, as has been shown for stereolaparoscopic surgery over the course of 2 decades, e.g., with a 25% increase in speed and accuracy as measured in 3-D laparoscopic suturing and knot tying (1).

However, 3-D endoscopy has to compete with another recent development, "full-HD endoscopy" with a resolution of 1920×1080 pixels. The limited resolution of conventional videoendoscopy, which only achieves standard television quality, is certainly an adverse factor which, in my opinion, might have greater importance than stereoscopic imaging. Therefore, future evaluations of stereoendoscopy should compare 3-D endoscopy with high-resolution imaging. Certainly, the ideal solution would be full-HD endoscopy with 3-D imaging. However, this might not be possible with today's endoscope technology: effective HD endoscope resolution requires at least 4-mm or larger Hopkins rods without split imaging; 2-mm Hopkins optics (probably comparable to 4-mm stereoscopy) do not profit much from HD cameras.

Also the reduced illumination and distorted colors might diminish the usefulness of 3-D small-diameter endoscopy. The figures presented by the authors seem to be of less color fidelity than standard 2-D imaging—another factor that should be compared in future studies. In my opinion, stereo-video imaging might be more useful in microsurgery. There do not exist limitations in stereoscopic base or illumination in microscope optics; here, full-HD stereoscopic imaging could allow "video screen surgery" instead of classic binocular inspection. Advantages are more lightweight, easier-to-handle microscopes; less difficult patient positioning, with the surgeon sitting comfortably in any approach; and the possibility of inte-

grating multimodal imaging, including navigation, endoscopy, etc., in 1 optical device, as in modern electronic flight instrument system displays, which allow safe precision flying and landings with artificial imaging at zero outside “conventional” visibility.

Michael R. Gaab
Hannover, Germany

1. Durrani AF, Preminger GM: Three-dimensional video imaging for endoscopic surgery. *Comput Biol Med* 25:237–247, 1995.
2. Grebenyuk KA, Petrov VV: The condition for eliminating spatial distortions in the Greenough stereoscopic microscope. *J Opt Technol* 75:500–503, 2008.

In this article, Tabaee et al. present a novel technology that may have potential benefits in the field of transsphenoidal surgery. Recently, the purely endoscopic transsphenoidal approach to sellar and parasellar lesions has been a significant advance in this field of neurosurgery. Increasingly, many centers around the world are adopting and reporting their experience with this technique.

Although there are many advantages to the endoscopic technique, among the criticisms has been the lack of stereoscopic vision. In our hands, this has not been a major disadvantage, as the movement of the endoscope and instruments can provide many important cues that allow for a virtual 3-D perception; however, any technology that would overcome this limitation would be welcomed. As noted by the authors, the use of a 3-D endoscope may reduce the learning curve for surgeons. The size of the endoscope required (4.9 or 6.5 mm), which is significantly larger than commonly used endoscopes, may represent a disadvantage, as a difference of a few millimeters may, in certain circumstances, add a significant obstacle during this minimally invasive surgery.

In conclusion, we believe that the work of Tabaee et al. represents a potentially important step toward the development of a 3-D endoscope. Nevertheless, one has to be aware that any further limitations in the movements inside the nose, especially in expanded procedures, may preclude the use of this technology in certain types of surgery.

Fred Gentili
Giorgio Carrabba
Toronto, Canada

The authors describe a novel 3-D stereoendoscope and discuss their early experience during transsphenoidal pituitary surgery in 13 patients using 6.5-, 4.9-, or 4.0-mm 0-degree and 30-degree rigid 3-D stereoendoscopes. They noted improved depth perception without eye strain or headache. There were no intraoperative complications. There were no significant differences in operative time, length of stay, or extent of resection compared with cases in which a 2-D endoscope was used. Depth perception, as perceived by the surgeon, was improved in comparison to depth perception with standard 2-D scopes.

The authors note no compromise after use of the endoscope. Stereoscopic depth perception, stereopsis, is a very sensitive phenomenon. The binocular vision system can resolve angles as small as approximately 10 arc seconds. This angle corresponds to the arc subtended by an IPD of 65 mm and a target at 1300 m. Furthermore, the human visual system is quite adept at achieving stereo fusion despite serious artifacts. There are 2 undesirable consequences resulting from viewing images with such artifacts. First, the viewer’s extraocular muscles may become fatigued, owing to the effort needed to keep the 2 images fused, resulting in diplopia either during or after use. This will resolve as the viewer readapts to the real world, but this adaptation may take several minutes. During adaptation, it is not uncommon for the viewer to experience the nausea of simulator sickness. These

adverse effects must be avoided, by design, in any device that is intended to be useful for surgical visualization.

It is encouraging that the pursuit of 3-D endoscopy is still active. I always believed that it would be a tool that could only complement our current practice. In 1999, we described 4 cases in which stereoendoscopy was used as either a primary means of visualization or as an adjunct to the operating microscope in conventional open neurosurgical procedures. We believed that stereoscopic vision was a significant advance in endoscope technology and was going to play a larger role in the popularization of minimally invasive techniques in neurosurgery. However, progress has been slow. As of 2000, we had completed 25 cases with concurrent frameless stereotaxy, 12 with concurrent 3-D modeling and integration, and 44 with concurrent endoscopy. To date, our experience with 3-D endoscopy includes more than 300 cases in a number of approaches. Our initial error was 2-fold. We believed that the opportunity to use a 3-D endoscope would be welcomed by those practicing neurosurgery. It turned out that this was not the case. Secondly, we sought to devise a 3-D endoscope that would eventually replace the operating microscope, and, based on this premise, we put a great deal of effort into the software components of the unit. This was also a mistake.

Historically, we have used a Vista Medical Technologies endoscope with an external diameter of 4.7 mm and a single glass rod optical element. A prismatic optical path separator is mounted behind the rod lens, and dual CCD devices of 640×480 matrixes were used to capture stereoscopic images. The effective IPD is 1.0 mm, with a working distance of 15 mm. The most salient problems with our system were the lack of ports and the visualization of 640×480 . Despite this, the endoscope has performed without problems for more than 10 years.

Despite the theoretical advantages of stereoscopic display technology, data regarding task performance with stereoscopic versus monoscopic displays is unclear. A number of investigators have undertaken performance studies with various standardized tasks. In general, it appears that stereoscopic vision does not seem to improve speed or error rate in experienced surgeons. In students or inexperienced surgeons, however, there does appear to be a reproducible if small advantage to stereoscopic vision. Notable, however, is that when tasks are performed using direct vision through the objective of the endoscope, significant improvement in performance is seen. The data, therefore, seem to suggest that a number of other factors in video processing, display, and endoscope optics conspire to degrade the ability to perceive important cues that might facilitate task performance. These factors have not been adequately identified to date.

I would disagree, in a sense, with the comments that simply comparing the numerical pixel resolution of the image on an x - y axis understates the ability of a 3-D rendered and visualized image to provide real-time, immediate depth information on x , y , and z axes. There is no doubt that the addition of depth contributes significantly to the ability of an individual to work in an environment, whether virtual or surgical. On the other hand, the contribution of resolution to the understanding or perception of depth is also well documented and of significant importance.

Problems with size (I still believe that 4 mm is too large a diameter), image resolution, and the lack of working channels continue to decrease the utility of 3-D endoscopes. Despite this, we will continue to use these scopes and find them to be of significant benefit in numerous surgical scenarios. It will be interesting to see whether the robotic endoscopes currently in development (e.g., EndActive) will eventually supplant our current technologies.

C. Ben Newman
Michael L. Levy
San Diego, California