
Treatment of Edentulism Using Astra Tech Implants and Ball Abutments to Retain Mandibular Overdentures

Lyndon F. Cooper, DDS, PhD*/Mark S. Scurria, DDS**/Lisa A. Lang, DDS, MS**/
Albert D. Guckes, DDS, MS*/John D. Moriarty, DDS, MS***/
David A. Felton, DDS, MS****

The goal of this study was to provide evidence to support simplified treatment of mandibular edentulism using denture fabrication and implant placement to circumvent the need for second-stage surgeries or prosthodontic superstructures. A 5-year prospective clinical trial is reported, which involved treatment of mandibular edentulism using the single-stage surgical placement of a TiOblast microthreaded titanium screw implant with immediate replacement of a relieved mandibular overdenture and eventual retention of the overdenture with reduced ball abutments. Fifty-eight patients were treated; 116 implants were placed using a single-stage surgical approach, with a duplicate mandibular denture as the tomographic/surgical template. Mandibular dentures were relieved and relined with a tissue conditioning material and placed immediately after implant surgery. After 3 months, Conical Seal Design ball abutments were placed and attachments were secured in the overdentures by heat-polymerizing laboratory reline methods. Five of the 116 consecutively placed implants failed at 2 to 4 months, providing an immediate implant survival rate of 95.69% at the time of attachment connection. Pain and inflammation were not common to all failures, and infection was not reported in any of the 5 failures. The immediate placement of implants by a single-stage surgical procedure in the parasymphysis region of the mandible, followed by placement of a relined mandibular denture, results in predictable and asymptomatic healing of implants that display the clinical and radiographic features of osseointegration. Encouraging results at the immediate observation period (attachment connection) must be tempered by the need for prudent and detailed clinical and radiologic evaluation over the 5-year trial period.

(INT J ORAL MAXILLOFAC IMPLANTS 1999;14:646-653)

Key words: endosseous implants, overdentures, single-stage surgery

*Associate Professor, Department of Prosthodontics, University of North Carolina School of Dentistry, Chapel Hill, North Carolina.

**Assistant Professor, Department of Prosthodontics, University of North Carolina, School of Dentistry, Chapel Hill, North Carolina.

***Associate Professor, Department of Periodontics, University of North Carolina, School of Dentistry, Chapel Hill, North Carolina.

****Associate Professor and Chair, Department of Prosthodontics, University of North Carolina, School of Dentistry, Chapel Hill, North Carolina.

Reprint requests: Dr David A. Felton, 404 Brauer Hall CB #7450, Department of Prosthodontics, University of North Carolina School of Dentistry, Chapel Hill, NC 27599. Fax: 919-966-3821.

Edentulism is an unresolved health care issue of sustained significance and prevalence in the increasing aged population of the United States. Existing estimates indicate that more than one fourth of the population older than 65 years of age is edentulous and that nearly half of the octogenarian population is edentulous.¹ Weintraub and Burt concluded that more than one third of the population over the age of 70 is edentulous.² Looking forward to another decade of estimated life expectancy, these individuals also anticipate continued alveolar bone atrophy³ and the problems associated with complete denture use.⁴

It is estimated that over 50% of the "oldest old" are edentulous, and many more are nearly edentulous. This is the fastest growing portion of

the population,⁵ and their rehabilitation needs are great. In one study, over 20% reported never wearing a mandibular denture, 50% of all dentures were old and in dysfunction, and 18% of the study participants showed soft tissue lesions associated with ill-fitting dentures.⁴ These problems relate to the interactive effects of limited access to and motivation for complete denture therapy and the changes in physiology and anatomy of the aging individual.

Over the past 40 years, several different interventions have been proposed to alleviate the difficulties associated with mandibular denture use and continued resorption of the alveolar ridges. Achieving stability and retention of the mandibular denture can be elusive when using conventional denture techniques. The application of surgical ridge augmentation and implantation has a varied history that is presently culminated by the unequivocal success of the osseointegrated titanium screw-type implant. Dentistry's aggregate experience with subperiosteal implants,⁶ blade implants,⁷ ramus frame implants,⁸ mandibular staple bone plate implants,⁹ and hydroxyapatite ridge augmentation with vestibuloplasty¹⁰ has shown that the promise of physical support for function is fleeting. Most of these methods are relatively expensive, major surgical interventions which, upon failure, render the alveolar ridge and mandible less able to support denture function. The questionable success of these different methods was the subject of a pioneering consensus conference, which established new criteria for judgment of dental implant success and restorative outcomes.¹¹

The establishment of osseointegrated implants as a highly successful method for retaining and supporting artificial teeth must be viewed as a landmark in clinical medicine. Osseointegration as a highly successful clinical intervention provides the basis for various prosthetic rehabilitation strategies for the completely edentulous patient. Some strategies propose the use of 2 implants to support overdentures. It has been reported that loaded, osseointegrated, root-form implants under mandibular overdentures can provide implant survival rates of 97 to 100%.¹² Secondary physiologic advantages may be gained by the use of implant-supported overdentures in the mandible. For example, Jacobs et al indicated that maxillary bone resorption lessened when the mandibular dental arch was restored with implant-supported overdentures than when complete dentures or a fixed-detachable implant prosthesis were utilized.¹³

It is the aim of this paper to argue that the application of osseointegration for the placement

of 2 implants in the parasymphiseal region of the edentulous mandible to support an overdenture is a minimal treatment objective for the majority of edentulous individuals. This report introduces the initial outcome of a 5-year prospective clinical trial designed to measure the success of a single-stage surgical procedure using Astra Tech microthreaded TiOblast implants (Lexington, MA) followed by immediate overdenture replacement.

Materials and Methods

This ongoing prospective study includes patients with extremely resorbed mandibles that have a superior-inferior dimension (height) at the parasymphysis of 10 mm or greater. The other inclusion criteria were: age between 35 and 75, sufficient amount of bone of good quality to allow use of 11-mm or longer implants, and good physical and mental health. Patients were excluded if they had uncontrolled diabetes, abused alcohol or drugs, showed signs of pathology or bruxism, had a history of recurrent aphthous ulceration or mucosal irritation, or if they had a severe Class I or Class II skeletal jaw relationship. All 60 patients were treated after signing an informed consent document that was approved by the UNC School of Dentistry's Committee on Investigations Involving Human Subjects.

To assure ideal implant placement that was congruent with osseous anatomy, denture esthetics, and attachment connection, dentures were fabricated prior to implant surgery. After denture placement and patient adaptation, the mandibular denture was duplicated and used as both a tomographic template and surgical template. This assured that implants were placed beneath the planned prosthetic attachment location, which was determined, in part, by ideal denture contours and esthetics.

The implant surgical procedure was based upon Astra Tech implant system requirements and recommendations.¹⁴ The implant was of an experimental design (Fig 1). Instead of the typical 0.6-mm pitch screw morphology, a 0.185-mm microthread design (based upon a finite element analysis of thread design that sought to maximize holding power and minimize thread pitch¹⁵) was used. The implant has a titanium oxide grit-blasted surface and surface preparation associated with strong biomechanical interlocking with bone.^{16,17}

The implants were placed through mucoperiosteal flaps of minimal dimension, essentially representing gingival or mucosal windows to the underlying bone (Figs 2a and 2b). A series of surgi-




Fig 1 The experimental microthread implant, which has a TiOblasted microdesign and a microthread macro design. It is made of type IV commercially pure titanium.

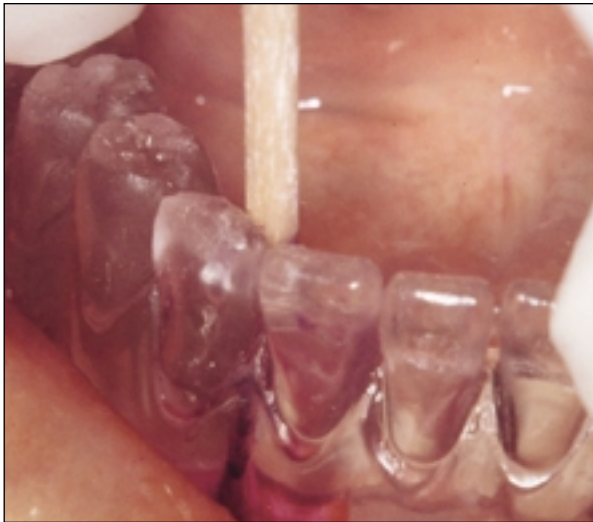

Fig 2a Surgical placement of implants was guided by a surgical/tomographic template made by duplication of the mandibular denture with acrylic resin. Note the use of an indelible stick to mark the mucosa prior to elevation of a small mucogingival flap.

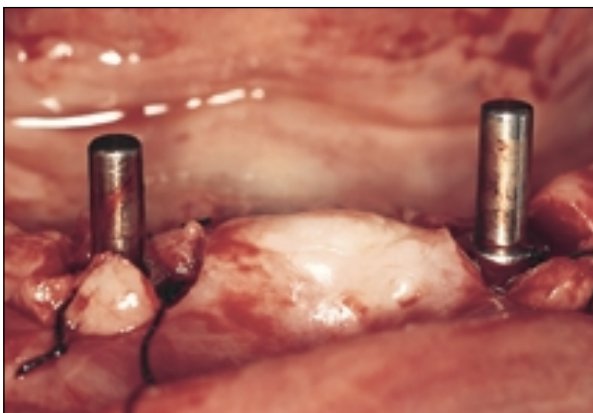


Fig 2b Implant placement. Osteotomy and placement of self-tapping implants were performed with minimal soft tissue elevation and trauma.

cal burs was used to prepare 3.5- or 4.0-mm osteotomies, and the microthread implants were threaded into bone. Primary implant stability proved to be essential to the outcome of osseointegration. In a few instances where stability of the 3.5-mm implants was not achieved, a 4.0-mm implant was subsequently placed.

After implant placement, a healing abutment was selected to extend through the mucosa and 1 to 3 mm beyond. The abutment was placed and tightened with finger pressure, and the mucosa was sutured with interrupted Gore-Tex (3i/Gore, West Palm Beach, FL) sutures. The denture base was relieved to provide a 1-cm diameter relief space (Fig 2c). The patients were dismissed with their prosthesis in place and, after a 1-week follow-up for suture removal, the relieved region of the denture was relined with Coe-Comfort (Coe Laboratories, Chicago, IL) to assure a good relationship with the healing abutment. Patients left this 1-week postplacement appointment with a functional mandibular denture and initiated a process of immediate loading to the implant site.

After 3 months of healing, the patients returned for connection of ball abutments and attachments. The healing abutments were removed without discomfort or the need for anesthesia, and the solid Conical Seal Design ball abutments (Astra Tech) were placed using the dedicated wrench with finger pressure. Abutment lengths were selected to assure approximately 1 mm of clearance of the attachment above the peri-implant mucosa. The reline material was removed, and further relief of the denture was created to accommodate the ball abutment impression copings. Impression copings were placed and a reline/pick-up impression was

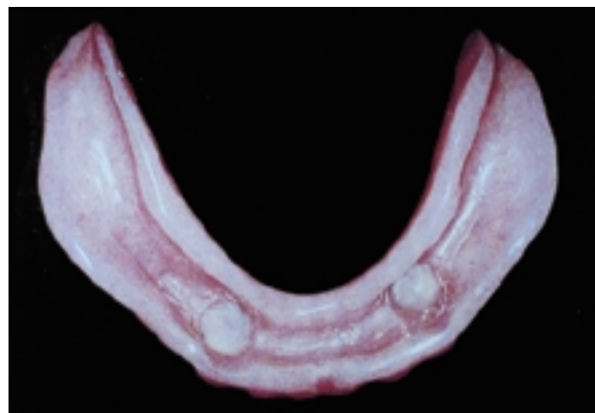


Fig 2c Prior to dismissal of patients, the mandibular dentures were markedly relieved to allow subsequent placement of Coe-Comfort without interference with the acrylic resin and the healing abutment.

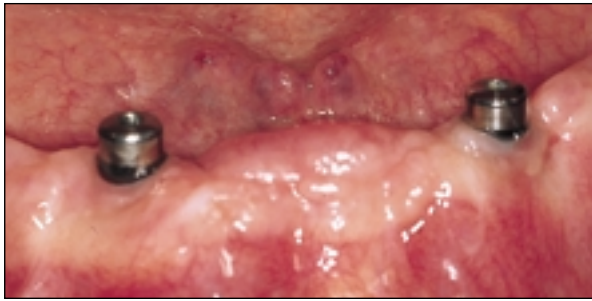


Fig 3a Presentation of patients 3 months after implant placement. Note mucosal healing and adaptation to healing abutment.

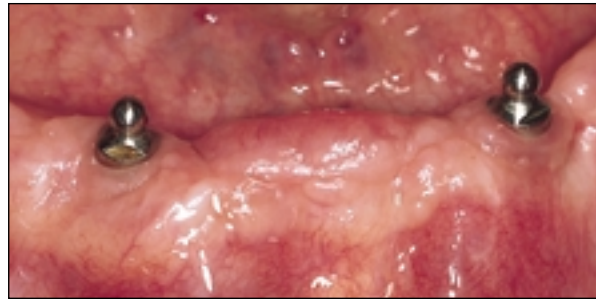


Fig 3b Replacement of ball abutments. The markings present on the healing abutment assisted in the selection of abutments of proper dimension.

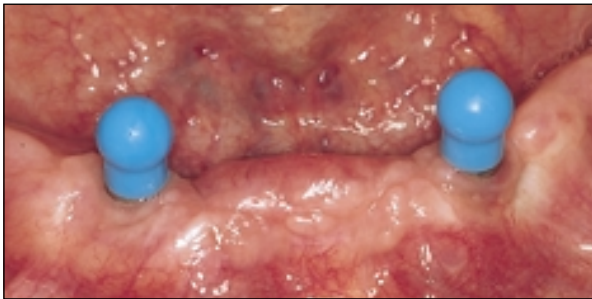
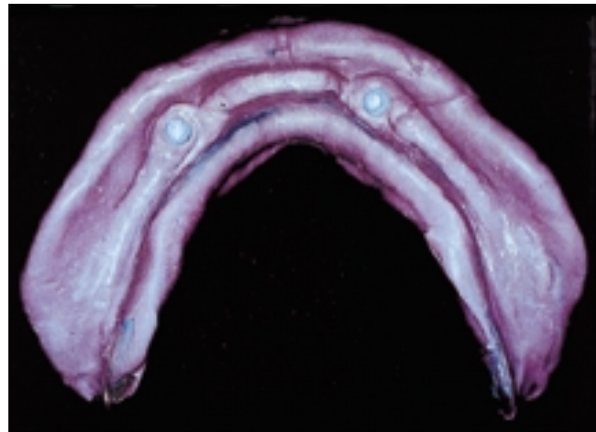


Fig 3c Transfer copings aided in the pick-up impression procedure.

Fig 3d (Right) A polyether reline impression is made that incorporates the transfer copings.



made (Fig 3) using Impregum (ESPE Premiere Dental Products, King of Prussia, PA). A cast was poured incorporating ball abutment replicas, the Dalla-Bona style ball housings were placed, and the denture was relined with heat-processed acrylic resin. The denture was returned and seated using pressure-indicating paste and articulating paper. Some dentures were remounted on an articulator to correct occlusal discrepancies.

Results

During a period of 24 months, 58 patients were recruited and treated with maxillary and mandibular dentures, followed by single-stage implant surgery and immediate placement of a relieved denture, which was connected to ball abutments following 3 months of healing.

Denture Treatment. Denture treatment occurred in all 58 patients without complications or difficulty. Despite an esthetic try-in of all dentures, 1 patient requested significant changes to the prostheses after placement. The patient was satisfied

by alteration of the occlusal plane and alternate tooth form. At the 1-week follow-up appointment, 2 of the attachments were dislodged from the acrylic resin. These overdentures were subsequently relined to assure the integrity of the attachment connection within the denture. After abutment placement, a mean of 0.65 visits per patient were required to address prosthetic complications. These complications included 1 fractured abutment, 3 loose ball housings in the processed denture relines, 1 loose abutment, 1 mandibular denture that had fractured in the midline, and 2 requests for improved maxillary denture retention, which required a laboratory-processed relining procedure (Fig 3).

All patients accommodated to their new dentures. There were no reported adverse events or associated complications, such as mucositis, candidal infection, bullous or erosive lesions, bony spicules or sequestra, or ulceration of the lips, tongue, palate, gingiva, or oral mucosa. At a minimum, each patient was provided with a stable and retentive maxillary denture and a stable mandibular denture.

Single-Stage Implant Placement. Implants were placed in 30 male subjects aged 40 to 75 (mean, 59.3 years) and 28 female subjects aged 25 to 73 (mean, 58.5 years). Sixteen patients admitted to smoking 0.5 to 2.0 packs of cigarettes per day (9 males, 7 females); all smoking patients were encouraged to stop smoking for 2 weeks following implant surgery. All implants were placed in the parasymphyseal region of the edentulous mandible. The single-stage implant surgery was tolerated well by all patients.

During the first month following surgery and replacement of the relieved mandibular denture, there were no reported adverse events or associated complications with soft tissue or osseous healing. The clinical records of these 58 patients indicated that patients required 0 to 5 postoperative visits, with a mean of 1.8 visits per patient. These visits included suture removal, biopsy, peri-implant gingivectomy, and removal of failed implants. In addition, 1 healing abutment loosened, 1 abutment fractured and was replaced, and multiple prosthetic denture teeth debonded in a single patient. Two patients were seen for denture-related pain, and adjustments were made to their dentures.

During the 2- to 4-month period of healing, 4 patients presented with implant failure. These failures occurred in male subjects between the ages of 55 and 70. One patient reported a history of smoking cigarettes. Two of the 4 patients had symptoms of pain, and 1 patient indicated mobility of the failed implant. One patient experienced asymptomatic, bilateral implant failure, which was noted at the time of abutment connection, and further treatment was discontinued. There were no clinical signs of infection or inflammation associated with these failures. Thus, there was limited morbidity or absence of morbidity associated with these implant failures. Eight weeks after implant removal, new implants were placed into the site which, after 3 months, did indicate clinical signs of osseointegration. To date, these 5 implant failures following placement of 116 implants indicate a 95.69% short-term survival rate for this single-stage surgery associated with immediate denture placement.

Discussion

Edentulous patients display moderate to severe dysfunction, as measured by both subjective and objective physiologic criteria. Osseointegrated implants provide a partial or nearly total solution for the individual's denture-related problems.¹⁸⁻²⁰ The outcome of several clinical reports describing patient treatment with mandibular overdenture

prostheses indicates that patient satisfaction is improved beyond that reported for conventional complete mandibular dentures in terms of comfort, function, retention, and speech. Participants in these studies have advised others to undergo similar treatment.²¹⁻²³

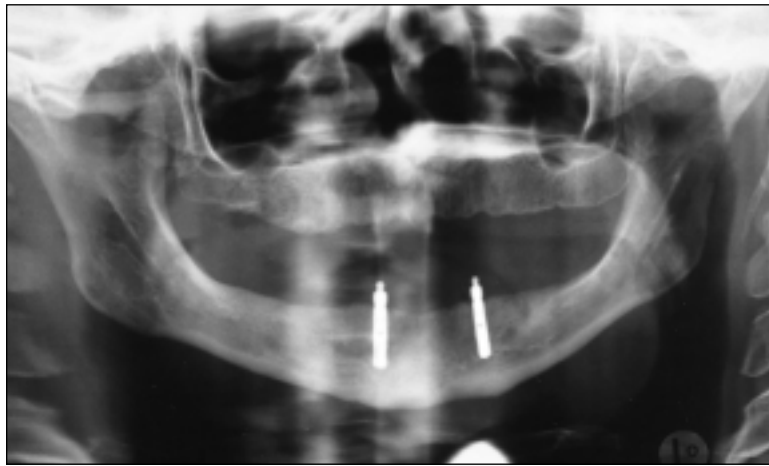
To date, the initial stage of this trial has been completed. Fifty-eight patients have undergone denture treatment, single-stage implant surgery, and overdenture conversion within the guidelines of the Institutional Review Board's approved informed consent document. The immediate implant survival data at this early time point compare favorably with other reports for implants supporting overdentures.^{15,24,25} All patients are entering the recall phase of this 5-year study. The loss of 5 of 116 implants (4.31%) prior to abutment connection to the overdenture is comparable to failures reported for 1-stage and 2-stage implants used in similar situations or in situations where a superstructure was used.

The high percentage of implants that demonstrated clinical and radiographic evidence of osseointegration after a single-stage procedure indicates the potential for long-term success (Fig 4). Similar, yet not identical, Astra Tech implants have been used in other clinical overdenture trials. In a previous mandibular overdenture trial, 1 of 40 implants placed in a 2-stage surgical method failed at abutment connection, and no implants were lost during the 2- to 4-year observation period.²⁶ Where different types of implants were used to support a mandibular overdenture, clinical and radiographic results were good.^{15,25} Previous indications suggest that low incidences of early failures are followed by the long-term success of the remaining implants.¹⁵ One study reported the prosthetic complication of the ball abutment loosening.²⁶ However, in this project, where a single-piece ball abutment was utilized, such loosening problems were negligible.

Further optimism for the eventual success of this trial is provided by the recent report of 95.6% implant survival 1 year after one-step surgical placement of 135 Brånemark implants (Nobel Biocare, Göteborg, Sweden) in 63 adult patients²⁷ and other reports of similar applications for this implant.²⁸⁻³⁰ Astra Tech implants have also been successfully used in single-stage approach.³¹

There are several advantages to one-stage implant placement. The number of patient surgeries is reduced, the extent of surgical manipulation can be reduced, surgical healing time is reduced minimally by the period of time required for soft tissue maturation after second-stage surgery (4 to 6 weeks), and there is a perceived decrease in treatment time.²⁷

Fig 4 Six-month postoperative radiograph. This typifies the result of asymptomatic healing and osseointegration of the microthread implants after the ball abutments are connected to the mandibular overdentures.



Use of the ball abutment/ball housing retention mechanism in deference to a custom superstructure was accepted by all patients; there were no complaints of unexpected lack of retention or stability. Experimentally, this ball abutment system has been shown to be the most retentive system available for implant abutments.³² When splinted and unsplinted Brånemark implants were compared as overdenture abutments, it was preliminarily concluded that the state of connection did not influence the subjective satisfaction ratings or the clinical success of the implants.³³ While this prior study indicated a higher incidence of early abutment screw loosening for 2-piece ball abutments, the current application of the 1-piece Conical Seal Design ball abutments may preclude this potential complication. Based on the behavior of Conical Seal Design abutments in other instances,^{26,34} these components may be well suited to the overall objectives of treatment simplification and limited complications for the expanded use of implant-retained mandibular overdentures.

When compared to fixed prostheses, overdenture use has been shown to cause fewer complications and to require less maintenance.³⁵ It is clear that different approaches to mandibular overdenture treatment with implants are associated with different complication rates.^{35,36} Bar-clip retention systems require costly superstructures, and the attachment clip has been implicated as a site of clinical weakness.³⁷

With respect to other complications and clinical accommodation to implant-retained overdentures, a within-subject, crossover-design, clinical comparison of hybrid and long-bar implant prostheses indi-

cated that patient satisfaction was greater when dentures were not supported by the mucosa. This was particularly true of patient perceptions of prosthesis stability.³⁸ The potential need for relining of the tissue-bearing surface of these implant-supported overdentures will be assessed throughout the duration of this clinical trial. The reported preference for long-bar versus hybrid implant-supported prostheses over a tissue-bearing overdenture should be considered in the context of the third and less desirable alternative of a complete denture. Several studies clearly define the improvement of oral function and patient satisfaction following placement of mandibular implants.^{18-20,39,40} Many, but not all, of the advantages of implant-supported mandibular prostheses can be provided by a minimum of 2 implants.^{15,24-42}

The ability to examine individual implants without connection using clinical and radiographic assessment techniques will allow the data to be reported at the level of Grade 1 success as required by Roos et al.⁴² The placement of these implants in moderately to severely resorbed mandibles, using a single-stage surgical method that advocates the immediate placement of a relieved denture without any subsequent provision for implant splinting, represents an extreme test of their clinical usefulness. This reflects the demographic realities (aging and economic demands for simplified implant-supported overdentures) of a patient population (those with edentulous mandibles) that may be treated with dental implants.

Conclusion

Improving the life quality of edentulous patients may require the use of dental implants. In cases in which the fixed-detachable solution is financially elusive, enhancement of patient function and physiology can be provided by using 2 implants without a prosthetic superstructure to retain or support the overdenture. Using an integrated approach to prosthodontic therapy and single-stage surgical management for implant placement, cost savings are anticipated. Loading of unsplinted implants following single-stage surgery may facilitate care and increase utilization. The actual biologic and psychologic outcome of this treatment method is the focus of a 5-year prospective clinical trial in which 58 patients to date (24 months) have experienced this integrated treatment with the immediate outcome of accommodation to overdentures retained by clinically and radiographically successful implants.

References

- White BA, Caplan DJ, Weintraub JA. A quarter century of changes in oral health in the US. *J Dent Educ* 1995;59:19-57.
- Weintraub JA, Burt BA. Oral health status in the US: Tooth loss and edentulism. *J Dent Educ* 1985;49:367-378.
- Nishimura I, Atwood DA. Knife-edge residual ridges: A clinical report. *J Prosthet Dent* 1994;71:231-234.
- Marcus PA, Joshi A, Jones JA, Morgano SM. Complete edentulism and denture use for elders in New England. *J Prosthet Dent* 1996;76:260-266.
- Hooyman NR, Kiyak HA. Growth of the older population. In: Hooyman NR, Kiyak HA. *Social Gerontology*, ed 2. Boston: Allyn and Bacon, 1991:15-42.
- Bodine RL, Yanase RT, Bodine A. Forty years of experience with subperiosteal implant dentures in 41 edentulous patients. *J Prosthet Dent* 1996;75:33-44.
- Kapur KK. Veterans Administration cooperative dental implant study—comparisons between fixed partial dentures supported by blade-vent implants and removable partial dentures. Part II: Comparisons of success rates and periodontal health between two treatment modalities. *J Prosthet Dent* 1989;62:685-703.
- Chamoun EK, Lemons JE. Clinical longevities of ramus frame implants. *J Oral Implantol* 1990;16:121-124.
- Knapp JG, Small IA. Fixed mandibular complete denture prostheses supported by mandibular staple bone plate implant. *J Prosthet Dent* 1990;63:73-76.
- Mercier P. Failures in ridge reconstruction with hydroxyapatite. Analysis of cases and methods for surgical revision. *Oral Surg Oral Med Oral Pathol Oral Radiol Endod* 1995;80:389-393.
- Conference proceedings: Dental implants. National Institutes of Health consensus development conference. *J Dent Educ* 1988;52:678-827.
- Chao YL, Meijer HJ, van Oort RP, Versteegh PA. The incomprehensible success of the implant-stabilized overdenture in the edentulous mandible: A literature review on transfer of chewing forces to bone surrounding implants. *Eur J Prosthodont Restorative Dent* 1995;3:255-261.
- Jacobs R, van Steenberghe D, Nys M, Naert I. Maxillary bone resorption in patients with mandibular implant-supported overdentures or fixed prostheses. *J Prosthet Dent* 1993;70:135-140.
- Arvidson K, Bystedt H, Frykholm A, von Konow L, Lothigius E. A 3-year clinical study of Astra dental implants in the treatment of edentulous mandible. *Int J Oral Maxillofac Implants* 1992;7:321-329.
- Jemt T, Chai J, Harnett J, Heath MR, Hutton JE, Johns RB, et al. A 5-year prospective multicenter follow-up report on overdentures supported by osseointegrated implants. *Int J Oral Maxillofac Implants* 1996;11:291-298.
- Hansson S, Werke M. On the role of the thread profile for bone implants, with special emphasis on dental implants. In: *Towards an Optimized Dental Implant and Implant Bridge Design* [thesis]. Göteborg: Chalmers Univ of Technology, 1997.
- Ericsson I, Johansson CB, Bystedt H, Norton MR. A histomorphometric evaluation of bone-to-implant contact on machined-prepared and roughened titanium dental implants. A pilot study in the dog. *Clin Oral Implants Res* 1994;5:202-206.
- Grogono AL, Lancaster DM, Finger IM. Dental implants: A survey of patients' attitudes. *J Prosthet Dent* 1989;62:573-576.
- Harle TJ, Anderson JD. Patient satisfaction with implant-supported prostheses. *Int J Prosthodont* 1993;6:153-162.
- Humphris GM, Healey T, Howell RA, Cawood J. The psychological impact of implant-retained mandibular prostheses: A cross-sectional study. *Int J Oral Maxillofac Implants* 1995;10:437-444.
- Boerrigter EM, Stegenga B, Raghoobar GM, Boering G. Patient satisfaction and chewing ability with implant-retained mandibular overdentures: A comparison with new complete dentures with or without preprosthetic surgery. *J Oral Maxillofac Surg* 1995;53:1167-1173.
- Haraldson T, Jemt T, Stalblad PA, Lekholm U. Oral function in subjects with overdentures supported by osseointegrated implants. *Scand J Dent Res* 1988;96:235-242.
- Wismeyer D, van Waas MA, Vermeeren JI. Overdentures supported by ITI implants: A 6.5-year evaluation of patient satisfaction and prosthetic aftercare. *Int J Oral Maxillofac Implants* 1995;10:744-749.
- Engquist B, Bergendal T, Kallus T, Lindén U. A retrospective multi-center evaluation of osseointegrated implants supporting overdentures. *Int J Oral Maxillofac Implants* 1988;3:129-134.
- Mericske-Stern R, Steinlin Schaffner T, Marti P, Geering AH. Peri-implant mucosal aspects of ITI implants supporting overdentures. A five-year longitudinal study. *Clin Oral Implants Res* 1994;5:9-18.
- Gotfredson K, Holm B, Sewerin I, Harder F, Hjørtting-Hansen E, Pederson ES, Christensen K. Marginal tissue response adjacent to Astra dental implants supporting overdentures in the mandible. A 2-year follow-up study. *Clin Oral Implants Res* 1993;4:83-89.

27. Becker W, Becker BE, Israelson H, Lucchini JP, Handelsman M, Ammons W, et al. One-step surgical placement of Brånemark implants: A prospective multicenter clinical study. *Int J Oral Maxillofac Implants* 1997;12:454-462.
28. Bernard JP, Belser UC, Martinet JP, Borgis SA. Osseointegration of Brånemark fixtures using a single-step operating technique: A preliminary prospective one-year study in the edentulous mandible. *Clin Oral Implants Res* 1995;6:122-129.
29. Henry P, Rosenberg I. Single-stage surgery for rehabilitation of the mandible. Preliminary results. *Pract Periodont Aesthet Dent* 1994;6:15-22.
30. Schnitman PA, Wohrle PS, Rubenstein JE, DaSilva JD, Wang NH. Ten-year results for Brånemark implants immediately loaded with fixed prostheses at implant placement. *Int J Oral Maxillofac Implants* 1997;12:495-503.
31. Tarnow DF, Emtiaz S, Classi A. Immediate loading for threaded implants at stage 1 surgery in edentulous arches: Ten consecutive case reports with one- to five-year data. *Int J Oral Maxillofac Implants* 1997;12:319-324.
32. Del Valle N, Faulkner G, Wolfaardt J, Rangert B, Tan HK. Mechanical evaluation of craniofacial osseointegration systems. *Int J Oral Maxillofac Implants* 1995;10:491-498.
33. Naert I, Quirynen M, Hooghe M, van Steenberghe D. A comparative prospective study of splinted and unsplinted Brånemark implants in mandibular overdenture therapy: A preliminary report. *J Prosthet Dent* 1994;71:486-492.
34. Kemppainen P, Eskola S, Ylipaavalniemi P. A comparative prospective clinical study of two single-tooth implants: A preliminary report of 102 implants. *J Prosthet Dent* 1997;77:382-387.
35. Hemmings KW, Schmitt A, Zarb GA. Complications and maintenance requirements for fixed prostheses and overdentures in the edentulous mandible: A 5-year report. *Int J Oral Maxillofac Implants* 1994;9:191-196.
36. MacEntee MI, Walton JN. A prospective study on the maintenance of implant prostheses in private practice. *Int J Prosthodont* 1997;10:453-458.
37. Watson RM, Jemt T, Chai J, Harnett J, Heath MR, Hutton MR, et al. Prosthodontic treatment, patient response, and the need for maintenance of complete implant-supported overdentures: An appraisal of 5 years of prospective study. *Int J Prosthodont* 1997;10:345-354.
38. Tang L, Lund JP, Tache R, Clokie CML, Feine JS. A within-subject comparison of mandibular long-bar and hybrid implant-supported prostheses: Psychometric evaluation and patient preference. *J Dent Res* 1997;6:1675-1683.
39. Ekfeldt A, Johansson LA, Isaksson S. Implant-supported overdenture therapy: A retrospective study. *Int J Prosthodont* 1997;10:336-374.
40. Zarb GA, Schmitt A. The edentulous predicament. II. The longitudinal effectiveness of implant-supported overdentures. *J Am Dent Assoc* 1995;127:66-72.
41. Parel SM. Implants and overdentures: The osseointegrated approach with conventional and compromised applications. *Int J Oral Maxillofac Implants* 1986;1:93-99.
42. Roos J, Sennerby L, Lekholm U, Jemt T, Grondahl K, Albrektsson T. A qualitative and quantitative method for evaluating implant success: A 5-year retrospective analysis of the Brånemark implant. *Int J Oral Maxillofac Implants* 1997;12:504-514.