



Treatment of stable and unstable intertrochanteric fractures with selfdynamisable internal fixator (concept of double dynamisation)

Lečenje stabilnih i nestabilnih intertrohanternih preloma samodinamizirajućim unutrašnjim fiksatorom (koncept duple dinamizacije)

Igor M. Kostić, Milan M. Mitković, Milorad B. Mitković

Clinic of Orthopaedics and Traumatology, Clinical Center Niš, Faculty of Medicine,
University of Niš, Niš, Serbia

Abstract

Background/Aim. Intertrochanteric fractures of the femur are the third most common fractures among all bone fractures. Today in everyday orthopedic practice a number of different methods of treatment of trochanteric fractures of the femur are applied. Despite the improvement in the development of new implants, the percentage of serious complications of the treatment of these fractures remains very high, varying from 10% to 20%. One of the most serious complications of internal fixation of intertrochanteric fractures is nonunion of fractures due to the lack of additional axial dynamisation of implants. The aim of this study was to determine the efficacy of double dynamisation in stable and unstable intertrochanteric fractures treatment using the self dynamisable internal fixator. **Methods.** During the period from 2000 to 2009 we analyzed the use of selfdynamisable internal fixator (SIF implant) in the treatment of 247 patients with stable and unstable intertrochanteric fractures. Fracture types were classified according to the AO Fracture Classification/Orthopaedic Trauma Association Scheme. Salvati and Wilson scoring systems were used for functional assessment considering pain, walking ability and hip movements of operated patients. **Results.** Of the total number of treated patients, 134 were males and 113 females, aged 19 to 90 (average 49.6) years. More than a half of the patients were older than 50 years. Monitoring of the patients after

the operation was carried out clinically and radiographically for a period of three to six months in all the patients, whereas a 2-year follow-up was conducted in 176 (71.2%) patients. The average duration of surgery was 47 min, the average blood loss 145 mL, and the average fluoroscopy time was 16 sec (8–97 sec). The average time for union was 3.7 months (3–6.5 months). Double dynamisation (dynamisation along the neck and shaft of the femur) was observed in 85 (34.4%) patients, and was on average 4.3 mm (1.5–8 mm). All fractures managed with dynamisation implants healed completely within no later than six months after the surgery. In 17 cases there was a cut-out phenomenon of implant, while in seven cases there was mechanical implant failure. Complications were detected within 3 to 6 weeks after the surgery, and treated by the method of intramedullary fixation. During the study, there were no cases of infection and thromboembolic complications detected. **Conclusion.** The concept of double dynamisation improves the fracture healing in the stable and unstable intertrochanteric fractures using the selfdynamisable internal fixator. This biological method of fixation provides healing of intertrochanteric fracture in the optimum period of time, significantly reducing the risk for mechanical failure.

Key words:

hip fractures; orthopedic procedures; internal fixators; fracture healing; treatment outcome.

Apstrakt

Uvod/Cilj. Intertrohanterni prelomi femura treći su po učestalosti prelomi od svih preloma koštanozglobnog sistema. Danas se u svakodnevnoj ortopedskoj praksi primenjuju različite metode fiksacije intertrohanternih preloma femura. Uprkos napretku u razvoju novih implantata, procenat ozbiljnih komplikacija lečenja ovih preloma i dalje je veoma visok i kreće se u opsegu od 10% do 20%. Jedna od najtežih komplikacija unutrašnje fiksacije intertrohanternih preloma je nerasrtanje preloma usled nedostatka dodatne aksijalne dinamizacije

implantata. Cilj rada bio je da se utvrdi efikasnost koncepta dvostruke dinamizacije (korišćenjem samodinamizirajućeg unutrašnjeg fiksatora) u lečenju stabilnih i nestabilnih intertrohanternih preloma. **Metode.** U periodu od 2000 do 2009. godine analizirali smo primenu samodinamizirajućeg unutrašnjeg fiksatora u lečenju 247 bolesnika sa stabilnim i nestabilnim intertrohanternim prelomima femura. Prelomi su klasifikovani na osnovu sistema klasifikacije AO/OTA. Sistemi bodovanja (ocenjivanja) Salvati-Vilson korišćeni su za funkcionalnu procenu, uzimajući u obzir bol, sposobnost samostalnog hoda i pokretljivost kuka operisanih bolesnika.

Rezultati. Od ukupnog broja lečenih bolesnika, bilo je 134 muškaraca i 113 žena, starosti od 19 do 90 (prosečno 49,6) godina. Više od polovine ispitanih bolesnika bilo je starije od 50 godina. Praćenje bolesnika nakon operacije sprovedeno je klinički i radiološki za period od tri do šest meseci kod svih ispitanika, dok je dvogodišnje praćenje sprovedeno kod ukupno 176 (71,2%) bolesnika. Prosečno vreme trajanja operacije iznosilo je 47 min, uz prosečan gubitak krvi od 145 mL, dok je prosečno vreme fluoroskopije iznosilo 16 (8–97) sec. Prosečno vreme zarastanja preloma iznosilo je 3,7 (3–6,5) meseci. Dupla dinamizacija (dinamizacija duž ose vrata i dijafize butne kosti) zabeležena je kod 85 (34,4%) bolesnika, i iznosila je u proseku 4,3 (1,5–8) mm. Svi prelomi kod kojih je došlo do dinamizacije implantata u potpunosti su sanirani najkasnije za šest meseci od operacije. Kod 17 bolesnika primećen je *cut-out* fenomen implantata (izvlačenje klinova iz glavenovratnog de-

la femura, sa dezintegracijom preloma), dok je kod sedam bolesnika došlo do mehaničkog loma implantata. Komplikacije su uočene u roku od 3 do 6 nedelja nakon operacije, a bolesnici su lečeni metodom intramedularne fiksacije *Gamma* klinom. Tokom studije nisu otkrivene infekcije i tromboembolijske komplikacije. **Zaključak.** Korišćenjem samodinamizirajućeg unutrašnjeg fiksatora koncept dvostruke dinamizacije značajno unapređuje lečenje stabilnih i nestabilnih intertrokanternih preloma. Ovaj biološki metod fiksacije pruža zarastanje intertrohanternih preloma u optimalnom vremenskom periodu, značajno smanjujući rizik od mogućih komplikacija lečenja.

Ključne reči:

kuk, prelomi; ortopedске procedure; fiksatori, unutrašnji; prelom, zarastanje; lečenje, ishod.

Introduction

The extension of life expectancy caused a growing number of patients with fractures of the proximal femur due to poor bone quality. For surgical treatment of these fractures different implants are still applied, which can be roughly divided into extramedullary and intramedullary implants. Complication rates arising during these fractures treatment using different surgical techniques and principles range in the literature from 10% to 20%^{1–6}. Complications in the form of delayed healing, nonunion and subsequent breakage of implants can have serious consequences for the patients⁷.

The first implants used for surgical treatment of intertrochanteric fractures were fixed-angle blade plates^{8,9}. After using this device more than a decade, many authors recommended them as the treatment of choices for intertrochanteric femur fractures, but the main complaint was that these implants did not allow controlled collapse and impaction at the fracture site without penetration of the femoral head¹⁰.

In the early seventies of the last century dynamic hip screw (DHS) has begun to be used more and more for the treatment of intertrochanteric fractures. One of the main reasons for the growing popularity of the application of this method of fixation was the ability of the implant to resist penetration and screw threads to increase fixation in the proximal fragment providing controlled spontaneous dynamisation of proximal fragment to achieve fracture healing. But, lack of axial dynamisation of this extramedullary implant has led to complications such as pulling off of the side plate from the femoral shaft and dissociation of the sliding compression hip screw from the barrel¹¹.

In the mid-1980's developed the first intramedullary nails for fixation of intertrochanteric fractures, and the first clinical application of the so-called Gamma Nail first generation took place in 1988, evolving from the concepts of Gerhard Küntscher to treat trochanteric fractures¹². The intramedullary position of Gamma Nail and other new intramedullary implants proximal femoral nail (PFN), proximal femoral nail anti-rotation (PFNA) considered to provide better biomechanical stability and still allowing controlled impaction of fracture¹³. Although considered to be mechani-

cally stronger than extramedullary implants, because they are closer to the mechanical axis of the femur and hence has less bending moments on the implant, there is no consensus among surgeons which implant, extramedullary or intramedullary has a lower complication rate¹⁴. To avoid these complications, it is necessary to provide good fractures reduction, proper position of the lag screws, in order to achieve the most important biomechanical factors of the stability of fixation.

A very important biomechanical characteristic of each implant is the presence of dynamic components of the implant to provide secondary impaction of fracture to achieve union. If this biomechanical characteristics of the implant is not present, in situations with the delayed union of fracture there may occur implants breakage as the implant becomes the weakest part of the rigid fixation construct. The role of dynamization is well-known in the orthopedic profession as an essential component of healing fractures, especially of the lower extremities, as well as to promote fracture healing in an optimal timeframe. Fractures of the proximal femur, intertrochanteric fractures, require special attention during the treatment, not only because of its prevalence in the pathology of trauma, but also because of a high incidence of morbidity and mortality in injured patients. Therefore, there is still ongoing debate in the professional literature on the selection of the appropriate implant for the treatment of intertrochanteric fractures of femur.

The aim of this study was to examine the efficacy of application of selfdynamisable internal fixator (SIF) in the treatment of stable and unstable intertrochanteric fractures.

Methods

Between January 2000 and December 2009 in the Department of Orthopedics and Traumatology, University Hospital Niš, Niš, Serbia, a total of 247 patients underwent treatment of intertrochanteric fracture of the femur using the SIF method of fixation. More than a half of the patients were older than 50 years. All fractures were classified according to the AO/OTA system of fracture classification. Those with pathological intertrochanteric fractures were excluded from

the study. Our criterion for distinguishing stable from unstable intertrochanteric fractures was the absence of medial support that was considered the main criterion for fracture instability¹⁵. According to this criterion, 97 consecutive patients in our study sustained unstable intertrochanteric fracture of the hip (fracture types 31–A3.1-3,A2.2,A2.3) according to the AO classification.

All the patients had their operation within 72 h of admission, carried out in the operating room using an orthopaedic traction table and image intensifier. After closed reduction, the proximal femur was exposed through a lateral approach using 5–6-cm-long skin incision, beginning just distally from the trochanteric ridge, and a guide wire was passed into the femoral neck aiming at the centre of the femoral head using a 130 degree guide. The operation was

in the laboratories the Faculty of Mechanical Engineering and in terms of testing the maximum load to destruction of the implant and cyclic tests the effect of repetitive loading was also investigated experimentally in 60 animals during the preparation of PhD thesis¹⁸.

The SIF is made of stainless steel (ASTM F 138-2). There are three different lengths of SIF for intertrochanteric fracture fixation, 100 mm, 150 mm, 200 mm, 250 mm. This variant consists of a trochanteric unit (for DHS), which extends distally as a bar. One or two clamps can be fixed to the bar. On the distal end, it has an anti-rotation dynamic unit, length 18 mm. On the trochanteric unit, there are three holes, but it is enough to introduce two screws (7 mm diameter) only into the neck and head of the femur, at 130 degrees (Figure 1).

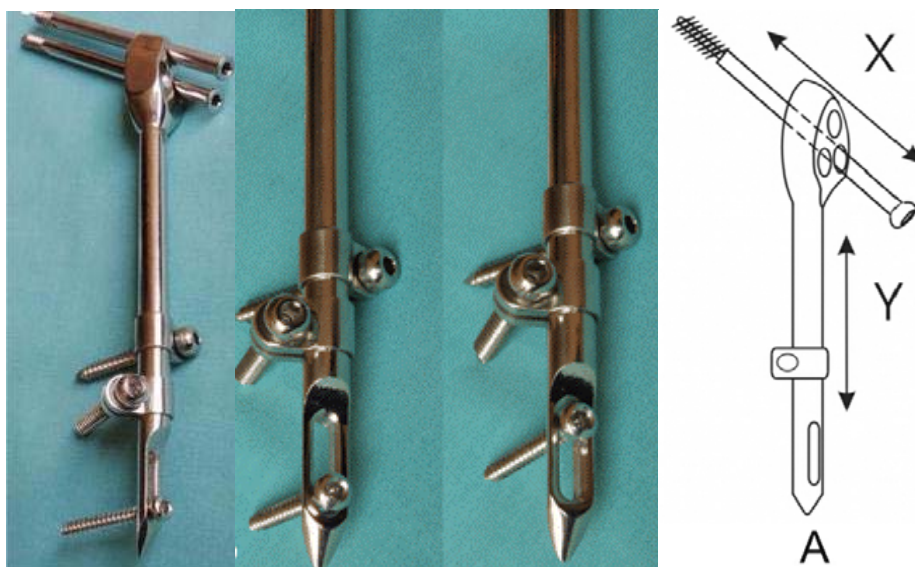


Fig. 1 – Concept of double dynamisation with selfdynamisable internal fixator implant.

carried out in a similar manner to a conventional DHS technique using a biological reduction concept without the attempt of open reduction or exposing fracture. Radiographs were taken postoperatively and at 6 to 8-week intervals during follow-up until clinical and radiological healing was achieved. During the first 6 weeks postoperatively, the patients were mobilised on partial to full weight bearing as far as were tolerated. Initial mobilisation was supervised by the physiotherapist. The mean hospital stay was 11.9 (range 7–25) days, depending on patient mobility and social circumstances.

During the follow-up visits, the patients were assessed with respect to walking ability, hip movements and pain. Radiographs were taken to assess healing and the neck-shaft angle.

Implant characteristics

The main three characteristics of SIF developed by Mitković et al.^{16,17}, are: possibility of spontaneous axial dynamisation, preservation of both periosteal and medullary bone blood circulation, and less invasive technique of application. This implant was approved by the National Drug and Medical Devices Agency. SIF has been investigated widely

Results

Of a total number of the treated patients, 134 were males and 113 females, aged 19 to 90 (average 49.6) years. More than a half of the patients were older than 50 years. The average duration of surgery was 47 min, the average blood loss 145 mL, and the average fluoroscopy time was 16 (8–97) sec. Of a total number of treated fractures ($n = 247$), 150 (60.7%) patients with intertrochanteric fractures were classified with stable fractures, while in 97 (39.3%) patients fractures were classified as unstable. Monitoring of the patients after the operation was carried out clinically and radiographically for a period of three to six months in all the patients, whereas in a two-year follow-up was conducted in a total of 176 (71.2%) patients. The average time for union was 3.7 (3–6.5) months. Double dynamisation (dynamisation along the neck and shaft of the femur) was observed in 85 (34.4%) patients, was on average 4.3 (1.5–10.5) mm. All fractures treated with dynamisation implants healed completely within no later than six months after the surgery.

Figure 2 shows radiographic findings during the effective treatment of the patient with stable intertrochanteric fracture.

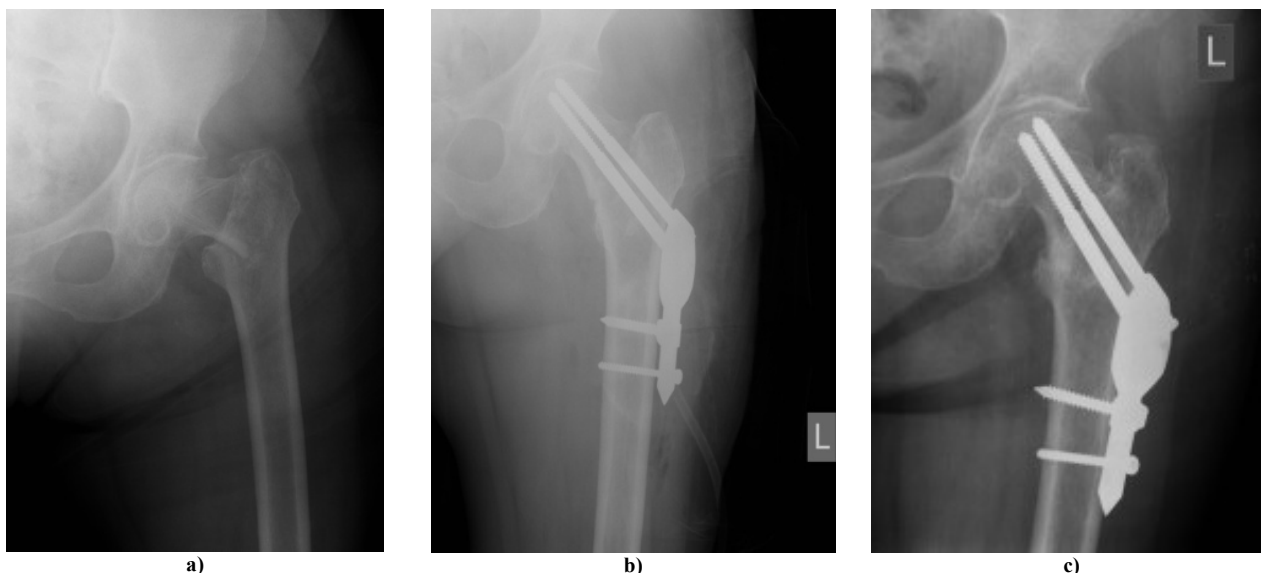


Fig. 2 – Radiographs of a 81-year-old female patient with stable osteoporotic intertrochanteric fractures (AO type 31-A1.2).

a) initial radiographic finding; b) postoperative radiography after osteosynthesis with a selfdynamisable internal fixator; c) radiography after 9 weeks-sufficient callus formation with double dynamisation of implant.

Cut-out phenomenon occurred in 17 (6.9%) cases, while in seven (2.8%) cases mechanical failure of implant was detected. These complications were detected within 3 to 6 weeks after the surgery. They were ultimately treated by removing the implants and intramedullary fixation with a long Gamma nail of third generation without bone grafting. All revised intertrochanteric fractures healed safely. During the study, there was no any case of thromboembolic complications, nor a single case of infection.

Figure 3 shows radiographs of the patient with unstable intertrochanteric fracture.

For functional assessment we used the Salvati and Wilson score, which showed excellent results in 175 (70.1%) fractures, good results in 54 (21.9%) fractures and fair results in 18 (7.3%). Hardware removal was done in 157 patients, typically not before 12 months after fracture union.

A failure of DHS fixation due to the lack of axial dynamisation is shown in Figure 4.

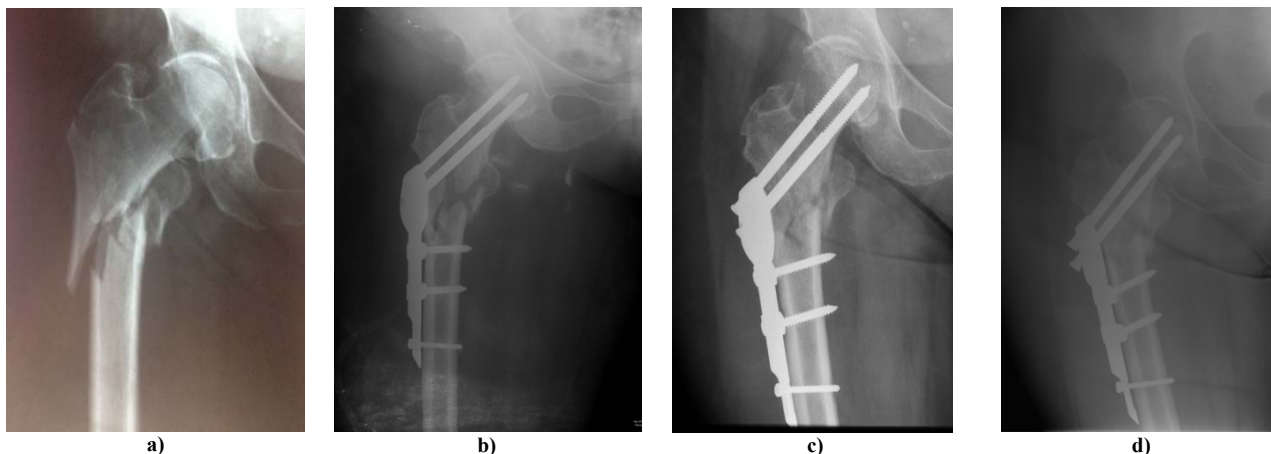


Fig. 3 – Radiographs of a 63-year-old-female patient with unstable, reverse obliquity, intertrochanteric fracture (AO type 31-A3.3).

a) preoperatively; b) postoperatively, after osteosynthesis with selfdynamisable internal fixator; c) 6 weeks postoperatively, double dynamisation of implant has been achieved; d) after 12 weeks radiographic image showing fracture healing.

In cases of unstable intertrochanteric fractures, the average dynamisation was 6.3 (3.7–10.5) mm. Fracture consolidation had been achieved in the mean duration of 10.3 (7–19) weeks. The patients started weight bearing as soon as possible after the operation, with the recommendation to weight bearing in the first three weeks as tolerated as well, and after that all patients started to walk full weight bearing with crutches.

Figure 5 demonstrates a correct position of a lag-screws SIF implant in anterior-posterior and profile radiographic imaging to avoid cut-out complication.

Discussion

The use of dynamic implants with a sliding screw in the axis of the femoral neck is now the standard in internal fixation

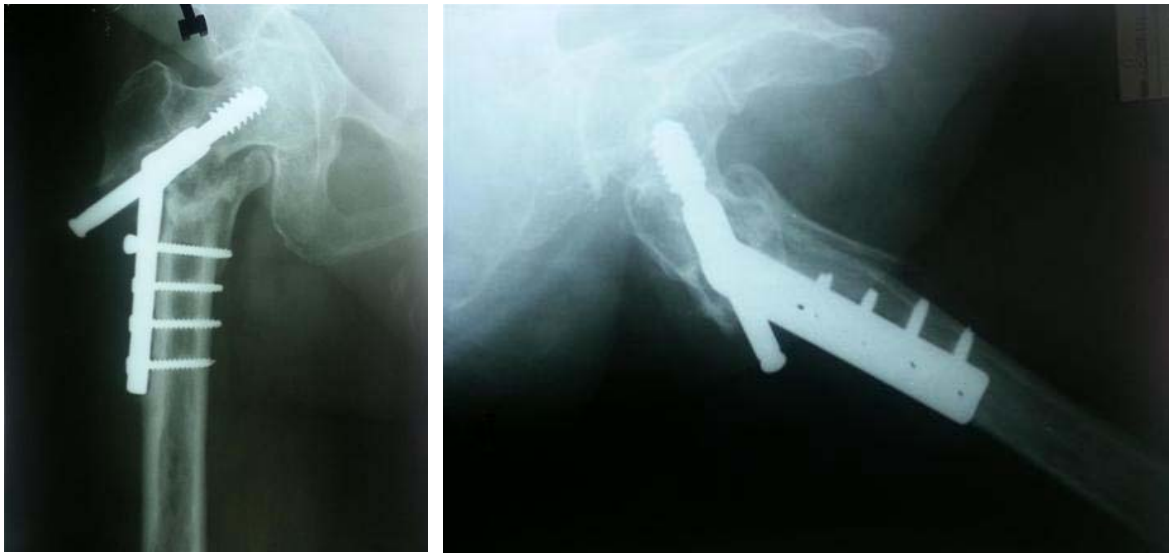

Fig. 4 – Failure of dynamic hip screw fixation due to the lack of axial dynamisation.

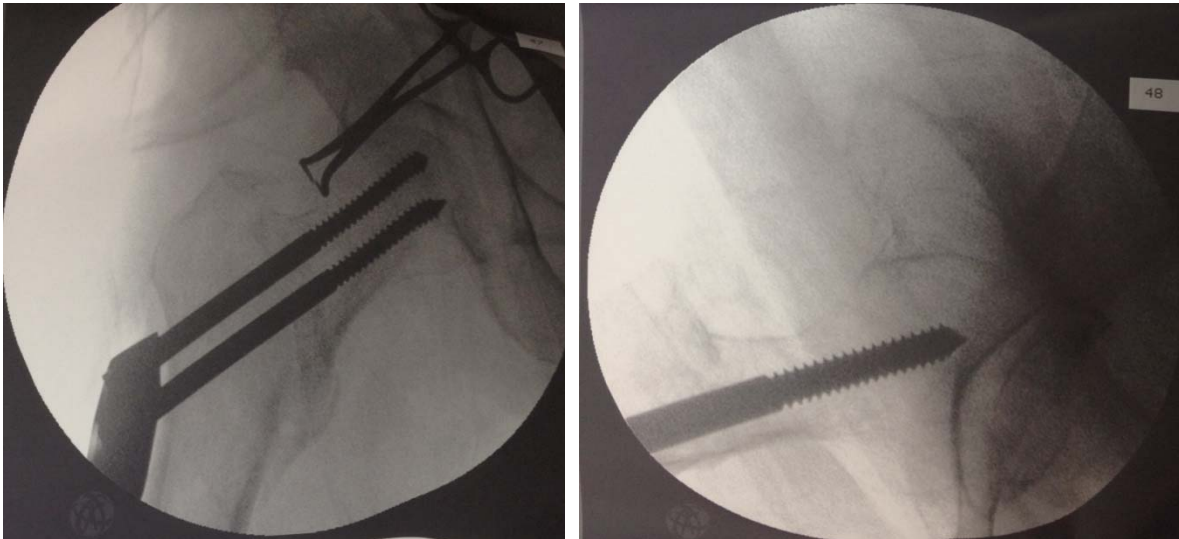


Fig. 5 – Correct position of lag-screws selfdynamisable internal fixator implant in anterior-posterior and profile radiographic imaging to avoid cut-out complications.

of intertrochanteric fractures. A sliding screw allows controlled collapse (dynamisation) and physiological compression of bone fragments at the fracture site, while preserving the neck-shaft femur axis. Weight bearing on the injured leg leading to the telescopic movement head-neck part of the femur together with the sliding screw, so that the possibility of fracture dynamisation directly depends on the ability of dynamisation of the sliding screw. While standing on the injured leg, the head of the femur is exposed to the force resulting from the effects of body weight and muscle contraction of the hip abductors^{19–22}. This force acts downward and outward, and it tends to dynamization of head-neck part of the femur with sliding screw and simultaneously performs cross slide screw load, leading to the appearance of sliding friction between the screw and the main part of the implant. This friction occurs at the two points of the support sliding screws of the implants: the lower part of the medial and upper lateral foramen through which the sliding screw passes.

Dynamisation occurs only when it overcomes this friction²³. Failure of DHS fixation is especially present during fixation of unstable intertrochanteric fractures, with the failure rate from 11% to 56%^{24, 25}. Despite this, a sliding hip screw remains the method of choice in surgical treatment of stable intertrochanteric femur fractures worldwide. In the largest published study to date on 1,024 patients with intertrochanteric fractures treated with DHS fixation, the authors obtained a low rate of fixation failure (3.2%), with the most common complications were cut-out of the lag screw from the femoral head with the incidence of 1.9%²⁶.

The analysis of our results after application of the SIF method of fixation in 247 patients, retrospectively monitored, treatment complications were found in a total of 24 (9.72%) patients.

The major complication was cut-out phenomenon detected in 17 (6.9%) cases. Analysis of these cases showed incorrect lag-screws positioning into the femoral head leading to this

complication. The importance of lag screw placement was explained in detail in the study of Baumgaertner et al.²⁷. They developed a simple method of measurement to describe the position of the screw. This measurement, the tip-apex distance, is the sum of the distance from the tip of the lag screw to the apex of the femoral head on anteroposterior radiograph and this distance on lateral radiograph, after controlling for magnification. To determine the value of this measurement in the prediction of so-called cut-out of the lag screw, 198 peritrochanteric fractures (193 patients) were studied by Baumgaertner et al.²⁷. Also, cut-out complications were detected in our study in the patients with surgery at the beginning of the study, so the learning curve plays an important role in the avoidance of technical errors of the SIF method.

As an alternative to this extramedullary sliding device we developed the SIF method of fixation for intertrochanteric femur fractures, in our institution (Clinic of Orthopaedic and Traumatology, University Hospital, Niš, Serbia), which has the possibility of dynamisation in two axes: axis of the femoral neck and the longitudinal femoral axis. After a period of biomechanical testing²³ of implants and experimental use of laboratory animals¹⁸, clinical application of this method started in early 2000^{16,17,28}.

The increased risk of intraoperative and late fracture of the femur and reoperation rate still remain a problematic aspect of proximal femoral nailing²⁹. The most recent randomised comparative study whose objective was to compare the clinical outcome and the rate of complications in the application of new design proximal intramedullary implants, Gamma Nail and PFNA, showed that the risk for experiencing a postoperative complication after Gamma 3 nailing was 40% versus 45% after PFNA fixation, concluding that there is no significant difference in the overall clinical outcome and risk of complications between the PFNA and the Gamma 3 treated patients during the first postoperative year. These complications were principally the impaction of the fracture area, cut-out, and fracture of the femoral shaft at the tip of the implant³⁰. All proximal femoral intramedullary nails of the new generation were designed to provide additional glid-

ing mechanism of lag screw in the axis of the femoral neck, and dynamisation along the femoral shaft axis through oval holes in the distal part of the nail for dynamic locking in both stable and unstable intertrochanteric fractures. In some cases, dynamisation of intramedullary proximal nail can be blocked so that the implant becomes the weakest point of fixation, leading to nail breakage. Complications in the form of delayed union, nonunion, and (subsequent) implant breakage are less frequent, but may also have devastating consequences for the patient.

In this situation, Biber et al.⁷ recommended the so-called lateral notching using a chisel they remove cortical bone right below the sleeve of the lag screw on the lateral side in order to achieve effective fracture impaction along the femoral shaft axis. Specifically, they noted in their series of 2,369 patients with intertrochanteric fractures surgically treated with proximal femoral Targon nail, some cases (14 patients, 0.6%) who were readmitted because of delayed union or nonunion. Normally distal dynamisation can be achieved either by removing the interlocking screws or by placing one screw into a long (dynamic) interlocking hole of the nail, but in these cases gliding of the nail was blocked by cortical support underneath the sleeve of the lag screw on the lateral side. In all of these cases healing was achieved 6 weeks later, after the additional new operation which included interlocking screw removal and lateral notching⁷. In our series of operated patients with the SIF method, dynamisation was observed in 85 (34.4%) patients, with no need for the new subsequent surgery to achieve further impaction of the fracture fragments.

Conclusion

According to our clinical data we can recommend self-dynamisable internal fixator as a safe extramedullary implant for fixation of both stable and unstable intertrochanteric fractures. It provides stable biological fixation of proximal femoral fractures, further adding impaction of the fragments along each axis (the axis of the femoral neck and the axis of the femoral shaft) whenever it is necessary to achieve the union.

R E F E R E N C E S

1. Baumgaertner MR, Curtin SL, Lindskog DM. Intramedullary versus extramedullary fixation for the treatment of intertrochanteric hip fractures. *Clin Orthop Relat Res* 1998; 348: 87–94.
2. Boyd HB, Anderson LD. Management of unstable trochanteric fractures. *Surg Gynecol Obstet* 1961; 112: 633–8.
3. Fielding JW, Magliato HJ. Subtrochanteric fractures. *Surg Gynecol Obstet* 1966; 122(3): 555–60.
4. Simmermacher RK, Bosch AM, van der Werken C. The AO/ASIF-proximal femoral nail (PFN): a new device for the treatment of unstable proximal femoral fractures. *Injury* 1999; 30(5): 327–32.
5. Watson HK, Campbell RD Jr, Wade PA. Classification, treatment and complications of the adult subtrochanteric fracture. *J Trauma* 1964; 4: 457–80.
6. Werner-Tutschku W, Lajtai G, Schmiedhuber G, Lang T, Pirkl C, Ortner E. Intra- and perioperative complications in the stabilization of per- and subtrochanteric femoral fractures by means of PFN. *Unfallchirurg* 2002; 105(10): 881–5. (German)
7. Biber R, Bail HJ, Stedtfeld HW. Lateral cortical notching in specific cases of delayed unions or nonunions after intertrochanteric and reversed fractures. *Arch Orthop Trauma Surg* 2013; 133(4): 495–501.
8. Holt EP. Hip fractures in the trochanteric region: treatment with a strong nail and early weight-bearing. *J Bone Joint Surg* 1963; 45A: 687–705.
9. Jewett EL. One-piece angle nail for trochanteric fractures. *J Bone Joint Surg* 1941; 23: 803–10.
10. Jacobs RR, Armstrong HJ, Whitaker JH, Pazell J. Treatment of intertrochanteric hip fractures with a compression hip screw and a nail plate. *J Trauma* 1976; 16(08): 599–603.
11. Kulkarni SS, Moran CG. Results of dynamic condylar screw for subtrochanteric fractures. *Injury* 2003; 34(2): 117–22.
12. Kuentscher G. Recent advances in the field of medullary nailing. *Ann Chir Gynaecol Fenn* 1948; 37(2): 115–36.

13. Curtis MJ, Jinnab RH, Wilson V, Cunningham BW. Proximal femoral fractures: a biomechanical study to compare intramedullary and extramedullary fixation. *Injury* 1994; 25(2): 99–104.
14. Matre K, Havelin LI, Gjertsen J, Espehang B, Ferang JM. Intramedullary nails result in more reoperations than sliding hip screws in two-part intertrochanteric fractures. *Clin Orthop Relat Res* 2013; 471(4): 1379–86.
15. Knobe M, Gradl G, Ladenburger A, Tarkin IS, Pape H. Unstable intertrochanteric femur fractures: is there a consensus on definition and treatment in Germany. *Clin Orthop Relat Res* 2013; 471(9): 2831–40.
16. Mitković M, Milenković S, Micic I, Mladenović D, Mitković M. Results of the femur fractures treated with the new selfdynamisable internal fixator (SIF). *Eur J Trauma Emerg Surg* 2012; 38(2): 191–200.
17. Mitković MB, Bumbasirević M, Milenković S, Micić ID, Mitković MM, Mitković MM, et al. Fractures of the upper part of the femur treated with Mitkovic selfdynamisable internal fixator (SIF). *Acta Chir Jugosl* 2010; 57(4): 103–5. (Serbian)
18. Gajdobranski DJ. Influence of different methods of Internal Fixation on bone callus characteristics in experimental animals [dissertation]. Niš: Faculty of Medicine, University of Niš; 2004. (Serbian)
19. Loch DA, Kyle RF, Bechtold JE, Kane M, Anderson K, Sherman RE. Forces required to initiate sliding in second-generation intramedullary nails. *J Bone Joint Surg Am* 1998; 80(11): 1626–31.
20. Lengsfeld M, Stammberger U, Mokwa A, Reeb S, Richter B. Predicting load bearing of the hip joint. Computerized analysis with a 3-D multibody model of the human. *Biomed Tech (Berl)* 1994; 39(12): 307–12.
21. Krebs DE, Robbins CE, Lavine L, Mann RW. Hip biomechanics during gait. *J Orthop Sports Phys Ther* 1998; 28(1): 51–9.
22. Ruszkowski I. Orthopedy. Zagreb: Jugoslovenska medicinska naklada; 1979.
23. Mitković MM, Manić MT, Petković DL, Milenković SS, Mitković MB. The force that causes dynamization of the selfdynamisable internal fixator (SIF). *Acta Chir Jugosl* 2013; 60(2): 87–91.
24. Haidukenyich GJ, Israel TA, Berry DJ. Reverse obliquity fractures of the intertrochanteric region of the femur. *J Bone Joint Surg Am* 2001; 83-A(5): 643–50.
25. Willoughby R. Dynamic hip screw in the management of reverse obliquity intertrochanteric neck of femur fractures. *Injury* 2005; 36(1): 105–9.
26. Chirodian N, Arch B, Parker MJ. Sliding hip screw fixation of trochanteric hipfractures: Outcome of 1024 procedures. *Injury* 2005; 36(6): 793–800.
27. Baumgaertner MR, Curtin SL, Lindskog DM, Keggi JM. The value of the tip-apex distance in predicting failure of fixation of peritrochanteric fractures of the hip. *J Bone Joint Surg Am* 1995; 77(7): 1058–64.
28. Micić ID, Mitković MB, Park I, Mladenović DB, Stojiljković PM, Golubović ZB, et al. Treatment of subtrochanteric femoral fractures using Selfdynamisable internal fixator. *Clin Orthop Surg* 2010; 2(4): 227–31.
29. Parker MJ, Handoll HH. Gamma and other cephalocondylic intramedullary nails versus extramedullary implants for extracapsular hip fractures in adults. *Cochrane Database Syst Rev* 2010; (9): CD000093.
30. Vaquero J, Muñoz J, Prat S, Ramirez C, Aguado HJ, Moreno E, et al. Proximal Femoral Nail Antirotation versus Gamma3 nail for intramedullary nailing of unstable trochanteric fractures. A randomised comparative study. *Injury* 2012; 43(Suppl 2): S47–54.

Received on October 25, 2013.

Revised on February 2, 2014.

Accepted on June 26, 2014.

Online First October, 2014.