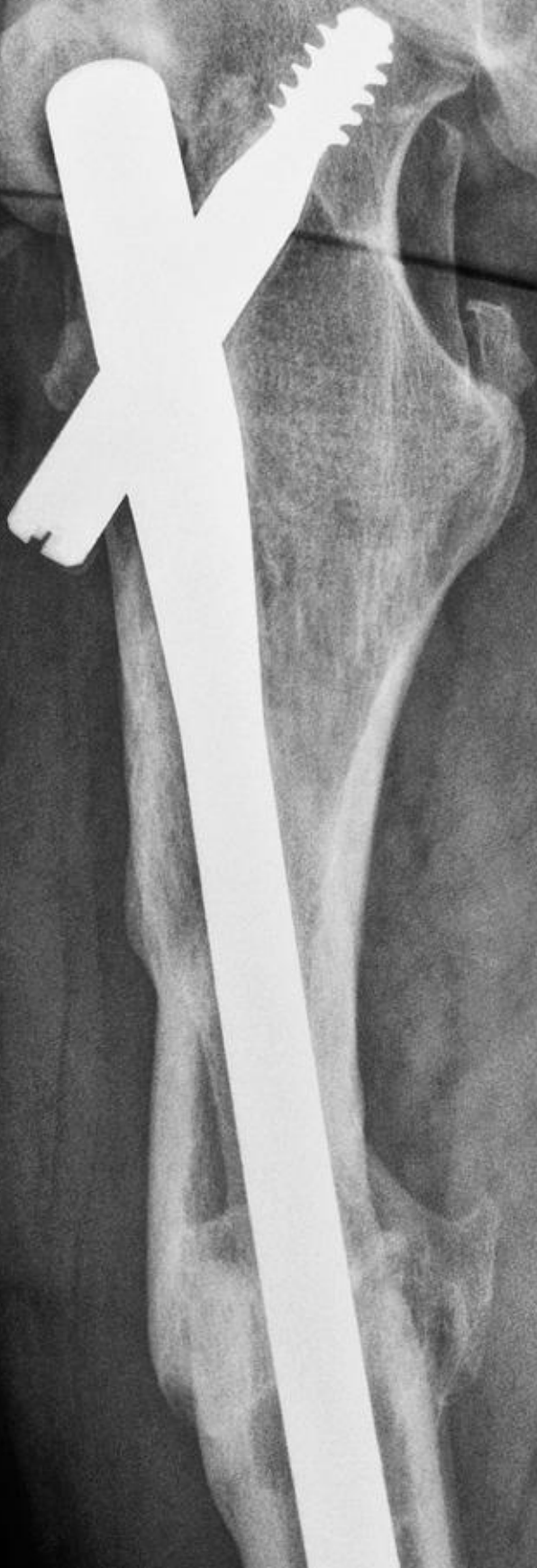

R



Trochanteric Fixation Nail

JESSE C PLUMMER, CST

Every year, more and more hip fractures are seen through the nation's hospital emergency departments. Although costs associated with hip fractures are constantly on the rise, mortality rates have been substantially reduced thanks in part to new techniques and surgical intervention. The Trochanteric Fixation Nail is only one system used to help reduce a patient's mortality and costs, all while returning the patient to mobility as soon as possible.

A BRIEF HISTORY OF ORTHOPEADIC SURGERY

Nicolas Andry coined the phrase, "orthopédie" in French, from the Greek words *orthos* ("correct," "straight") and *paidion* ("child"). In 1741, he published *Orthopédie: or the Art of Correcting and Preventing Deformities in Children*. Initially, the publication focused on children, but later it grew to mean the correction of spinal and bony deformities in all stages of life and eventually would become the cornerstone of the modern orthopedic practice.

Many developments in orthopedic surgery resulted from experiences during wartime. In the Middle Ages, the injured were treated with bandages soaked in horse blood, that would later dry to form a stiff splint. The unsanitary splint was discontinued as orthopedic and aseptic practices were developed to more modern standards.

The first orthopedic institute was established in 1780 by Jean-Andre Venel. The institute became the first hospital dedicated to the treatment of children's skeletal deformities. Venel went on to develop a shoe for children with club feet as well as developing various methods to treat scoliosis of the spine.

LEARNING OBJECTIVES

- ▲ Learn about how orthopedic surgery evolved
- ▲ Identify the typical demographics for hip fracture patients
- ▲ Recall the various instrumentation used for a trochanteric fixation nail procedure
- ▲ Examine the role of the surgical technologist throughout the operation
- ▲ Read tips and reminders on X-ray safety

Advances made in the 18th century, such as John Hunter's research on tendon healing and Percival Pott's work on spinal deformity steadily increased the range of new methods available for treatment. Antonius Mathysen, a Dutch military surgeon, invented the plaster of Paris cast in 1851, and in some cases, this method is still in use today.

Hugh Owen Thomas, a Welsh surgeon, became interested in orthopedics and bone setting at a young age and, after establishing his own practice, went on to expand the field into general treatment of fractures and other musculoskeletal problems. Dr Thomas pioneered many techniques and instruments used to detect defects and heal bone breaks and deformities. He invented the device known as an osteoclast, used to break and reset bones.

Many developments in orthopedic surgery resulted from experiences during wartime. In the Middle Ages, the injured were treated with bandages soaked in horse blood, that would later dry to form a stiff splint. The unsanitary splint was discontinued as orthopedic and aseptic practices developed to more modern standards.

Gerhard Küntscher from Germany pioneered the use of intramedullary rods to treat femur and tibia fractures. This made a noticeable difference in the speed of recovery of injured German soldiers during World War II. It also led to a widespread adoption of intramedullary fixation of fractures throughout the rest of the world. In the 1970s, Harborview Medical Center in Seattle popularized intramedullary fixation without opening up the fracture.¹

ANATOMY OF THE HIP

The hip anatomy consists of the acetabulum, femoral head, femoral neck, greater and lesser trochanter, the proximal femoral shaft and the medial femoral shaft. For the purposes of this article, the focus will be on the trochanteric part of the hip anatomy, the femoral head and the proximal femur. The intertrochanteric regions are made up of the proximal femur distal to the neck extending to the lesser trochanter. The majority of the bone in this region

is cancellous, extracapsular and highly vascularized leading to a robust healing environment.²

PATIENT DEMOGRAPHICS

The typical hip fracture patient is female, in her 60s to 70s, usually showing signs of osteoporosis, has a history of falls, may use a cane or other walking aid, presents pain in the hip and has an inability to put weight on the affected leg. Often, patients describe the incident as a "pop and then fall." Patients often will describe minor hip pain prior to the fall or a sudden onset of major hip pain. This is characteristic of a pathological fracture due to the development of osteoporosis. Although the trochanteric region is not often affected by trauma, emergency departments do see patients outside of this typical demographic with trochanteric hip fractures due to trauma. The neck of the femur is usually affected by trauma and the trochanter is affected by pathological disease such as cancer or osteoporosis. Drawing blood for lab work and checking the metabolic bone panel including calcium, phosphorus, Vitamin D3 and albumin is recommended. Any values found to be insufficient should be corrected in order to maximize a patient's outcome.

Atypical demographics also can occur. Intertrochanteric fractures are rare in younger patients and need further investigation. In this demographic, intertrochanteric fractures can be the result of a high-energy impact trauma or pathological conditions such as cancer. Patients that have had a previous humerus fracture are at a five times greater risk of a femoral fracture within a year and are at a three times greater risk of a subsequent hip fracture. A third of elderly males that suffer hip fractures die within the first year. Hip fracture patients with liver disease, renal failure and/or metastatic cancer have a particularly high mortality rate. Patients should consider a hip dual-energy X-ray absorptiometry (DEXA) to assess osteoporosis and fall risks. Patients who realize their risks for falls are more likely to reduce the risks and hazards and, ultimately, the costs associated with falls and hip fractures.^{3,4}

SURGICAL OPTIONS

While non-surgical options are rare, some patients may present with too many comorbidities for immediate surgery. Most patients with hip fractures present to the emergency department as the result of a fall or accident. Occasionally, elderly patients living alone may fall and not be found for hours or even days. This also could lead to dehydration causing their blood glucose and electrolytes to become off

balance. If this occurs, this condition will need to be treated prior to surgery. These patients will likely remain hospitalized and in traction while being treated.

When a patient has been stabilized and is cleared to undergo surgery, the surgeon has several options. The compression hip screw, plates and screws and intramedullary nails are modern options. This article will focus on trochanteric fixation nail. It is in the class of cephalomedullary nail, an intramedullary nail implanted from the head of the femoral bone and it uses a helical blade and a proximal locking screw and a distal locking screw. The distal locking screw may or may not be used based on the surgeon's preference.

SURGICAL TECHNIQUE

The patient should be positioned in the lateral decubitus position or supine position, depending on a surgeon's preference. In most cases, the supine position on a fracture table is the best position for a trochanteric fracture. The fracture is reduced by a combination of flexion, rotation and traction. The C-arm needs to be placed so that it will visualize the proximal femur in both the anterior-posterior and lateral positions. The patient's affected hip should have 10-15° of adduction.

The surgeon will use the radiographic ruler preoperatively to measure the femoral neck angle using the three oblique slots and the 3.2-mm diameter, 400-mm length guidewire. The nail comes in three angles, 125°, 130°, 135°. The surgeon will position the ruler over the proximal femur and take an AP image. He or she will select the angle that most closely matches the femoral neck angle.

The same ruler will be used to determine the proper nail length. The short nail comes in two lengths, 170 mm and 235 mm. The long nail comes in lengths between 300 mm - 460 mm. The surgeon will determine the diameter of the femoral shaft by placing the diameter tabs of the ruler perpendicular to the femur and reading the measurements through the image.

The patient's affected hip will be prepped with an iodine-based prep depending on the surgeon's preference. After the prep is dry, an isolation drape will be used to drape the patient and the surgical technologist will throw off the cautery cord. After the timeout, the surgeon will make an incision using a #10 blade on a #3 knife handle, superior to the greater trochanter. The nail's entry point will need to be inline with the medullary canal of the femur. The surgeon will dissect the gluteus maximus fascia longitudinally, separate the underlying muscle fibers and palpate the tip of

A Word About X-Ray Safety

Through out the surgery, the C-Arm will be used to verify nail length, width and angles. It will also be used to verify placement of the nail, the locking screws, the helical blade and the guidewires. Modern C-Arms use the minimal amount of radiation to get the image needed. However, there are still safety considerations you should follow.

- **Know the risks:** If the C-arm is improperly used, the patient, the surgeon, the surgical technologist and the circulator could be put at an undue risk. Do not be afraid to ask the X-ray technician if the C-Arm has passed the latest safety tests.
- **Dose Reduction:** The technician should use as little fluoroscopy as possible. He still needs to get a good image for the surgeon, but overexposure by keeping the fluoro live when not needed increases exposure. Keep it to required amounts to get the image but no more.
- **Lead Aprons and Other Personal Protective Equipment:** Wear lead. Lead aprons, lead-lined gloves and even lead glasses should be provided by your facility. Wear your radiation badge to measure your exposure doses. Thyroid cancer and other cancers are caused by excessive radiation exposure. If you or someone on your team is pregnant or suspect pregnancy, avoid being in the OR where the C-Arm is being used if at all possible. Birth defects can result from any exposure.⁸

the greater trochanter. Once that area is exposed, the surgical technologist will hand the surgeon the protection sleeve with the 3.2-mm guidewire with the 3.2-mm trochar installed. The 3.2-mm guidewire must be inserted at a 6° angle lateral to the femoral shaft. The surgeon will remove the trocar and insert the 3.2-mm guidewire. He or she will either insert the guidewire on power or use the universal T-handle for manual insertion. Using the C-arm, the surgeon will verify the guidewire placement on both AP and lateral planes, and continue the insertion of the guidewire to approximately 15 cm. The 3.2-mm guidewire will then be removed. The surgical technologist will hand the surgeon a drill with the 17-mm cannulated drill. The surgeon will place the cannulated drill over the guidewire and drill to the stop. The 17-mm cannulated drill and the protective sleeve then will be removed. Alternatively,

the surgeon may opt to use the cannulated awl to open the canal. Once the canal is open, the 3.2-mm guidewire will be removed and the guidewire will be disposed.

Reaming the medullary is optional. Many surgeons opt to ream when a long nail is used. If the surgeon determines reaming the canal is necessary, the surgical technologist will need to load the 2.5-mm ball-tipped reaming rod on the coupler in the power system. The reaming inserts come in 0.5-mm increments. The surgeon will need to ream to a diameter 1-mm greater than the measured diameter. The reaming rod may be used as a guide for the nail; the reaming insert will need to be removed and the guide re-inserted.

This next step will require the cannulated connection screw, the 5-mm flexible hexagonal screwdriver, the insertion handle and the 8-mm ball hexagonal screwdriver. The surgical technologist will load the nail on the insertion handle by orienting the handle laterally and matching the geometry of the handle to the nail. For the long nail, the bow of the nail will need to be aligned with the anterior bow of the femur

and ensured that the left or right nail is being used for the correct affected limb. The insertion handle is notched to match a notch on the nail. The surgeon will use the 5-mm cannulated screw to secure the nail to the insertion handle and tighten with the ball hexagonal screwdriver. The connecting screw will need to be tight enough to prevent misalignment when inserting the helical blade later in the procedure. The surgical technologist will hand the insertion handle to the surgeon, who will then insert the nail into the canal of the femur. The reaming rod can be used as a guide for the nail. This is especially useful if the proximal femoral shaft is also fractured, preventing the nail from exiting the shaft of the femur laterally. Although short nails do not usually require malleting or hammering, the surgical technologist will need to have the mallet ready just in case. Long nails almost always require malleting or hammering. If needed, there is a driving cap attachment available in the set for malleting. When using the mallet, the surgeon will need to carefully monitor the distal tip of the nail as the nail progresses to ensure it

➤ We're Committed To Advancing Your Education.

The ARC STSA 2015 Scholarship Program Multiple Scholarships—Up to \$1,000 each

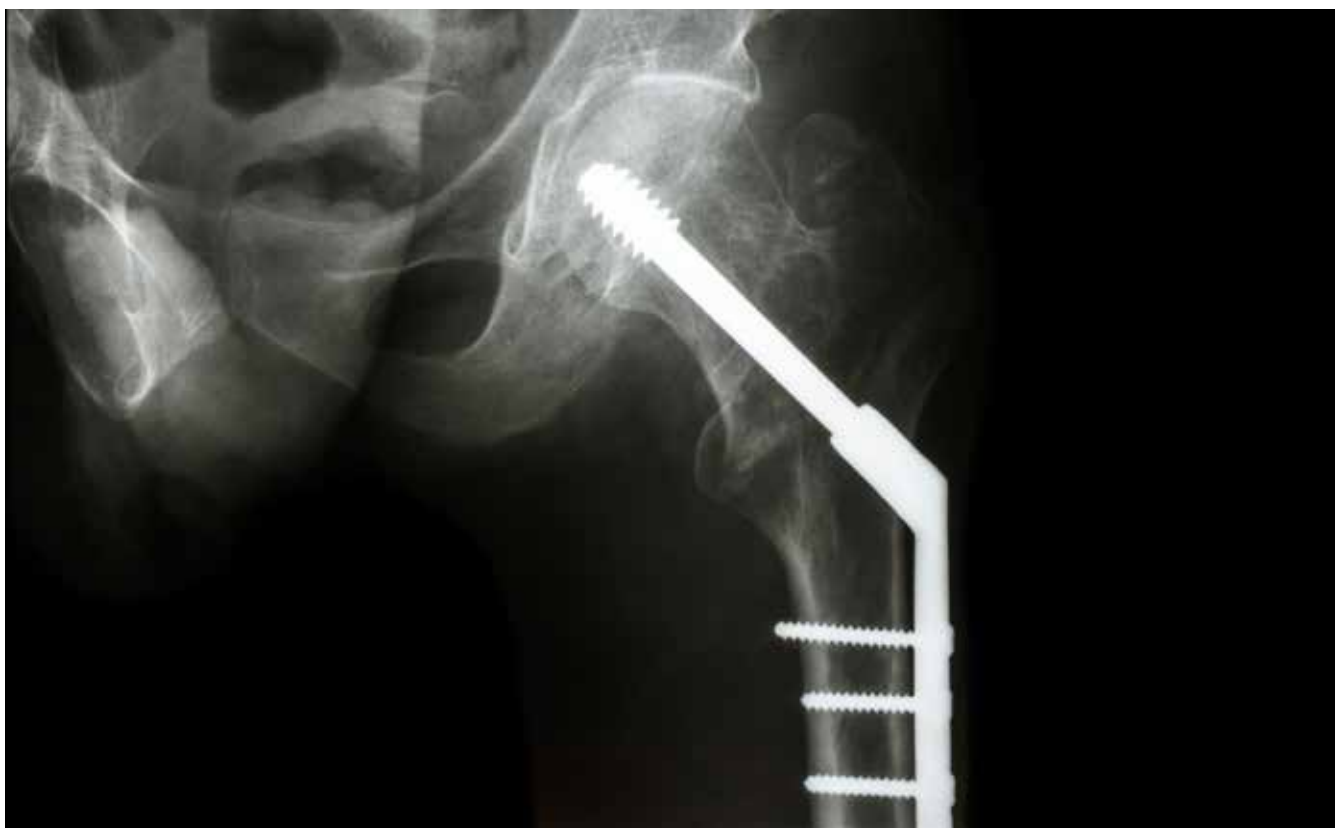The Accreditation Review Council on Education in Surgical Technology and Surgical Assisting (**ARC STSA**) is pleased to announce the launch of our **2015 Scholarship Program** in service to the Surgical Technology and Surgical Assisting student and educator communities.

Annually, since 2005, the **ARC STSA** Board of Directors has awarded multiple scholarships of up to **\$1,000** in at least two separate categories, Student Scholarship and Educator Scholarship. In 2015, the **ARC STSA** will award a total of up to **\$5,000** in combined scholarships.

➤ All eligible applicants are strongly encouraged to apply before the **February 27th deadline**. For eligibility requirements and to apply visit **arcstsa.org** today!

Scholarship recipients will be announced at the 2015 AST National Conference in San Antonio, TX and will be posted on our website, arcstsa.org, by July 3, 2015.





stays within the canal and there is no distal impingement. Once the nail passes the fracture site, the guidewire (if used) should be removed. The surgical technologist will give the surgeon the appropriate aiming arm, decided upon prior to the procedure. This will be attached to the insertion handle. The blade guide sleeve, the buttress/compression nut, the 3.2-mm guidewire and the 11-mm/3.2-mm guidewire will be used at this point. The buttress/compression nut will be placed about midway onto the blade guide sleeve. The blade guide sleeve and the 3.2-mm trocar will be placed onto the aiming arm with the 3.2-mm guidewire loaded onto a wire driver. The surgeon will make a small incision at the point of insertion using either a #10 blade or a #15 blade on a #3 knife handle and dissect the fascia.

The sleeve assembly will be inserted through the soft tissue to the bone. The buttress/compression nut will snap into the aiming arm. The buttress/compression nut will need to be turned counterclockwise to advance the blade guide sleeve to the bone. The surgeon will use the C-arm imaging to confirm the blade guide is on the lateral cortex. Fracture reduction will need to be confirmed by image intensification. The surgeon will remove the 3.2-mm trocar, and the surgical technologist will pass the 3.2-mm guidewire loaded

The intertrochanteric regions are made up of the proximal femur distal to the neck extending to the lesser trochanter. The majority of the bone in this region is cancellous, extracapsular and highly vascularized leading to a robust healing environment.²

onto a power guidewire driver. The guidewire will need to be advanced into the femoral head stopping 5 mm from the subchondral bone. The tip of the guidewire will be placed where the tip of the helical blade will be. The wire placement should be confirmed in both the AP and lateral views using the image intensifier. The 3.2-mm guidewire will then be removed.

Once the placement of the guidewire is confirmed, the surgeon will measure the length for the helical blade using the helical blade measuring device. With the guidewire still

in place, the measuring device will be placed over the guidewire, down to the blade guide sleeve. The blade length will be read directly from the measuring device to the tip of the guidewire.

The blade guide sleeve will then be removed. The surgical technologist will chuck up the 11-mm tapered cannulated drill bit and hand it to the surgeon. The surgeon will pass the drill bit over the guidewire and drill to the stop, opening the lateral cortex. While the surgeon is doing that, the surgical technologist will need to load the 6-mm/10-mm stepped cannulated drill bit. The stepped drill bit requires the drill stop. The drill stop will be slide onto the drill bit, and the surgical technologist will press the button to place the stop to the measured helical blade length.

The helical blade coupling screw will be placed down the inserter. The helical blade will be aligned with the inserter and the coupler screw will be used to secure the blade to the inserter. The coupler screw will need to be tightened by hand, and there needs to be emphasis to not overtighten. The surgical technologist will then hand over the helical

The surgeon will insert and tighten the screw by hand only using the hexagonal screwdrivers – no power will be used on this screw. The surgeon will then remove the aiming arm and nail insertion handle by using the 8-mm ball hexagonal screwdriver.

blade assembly with a mallet. Once the helical blade is fully inserted, the surgeon will need the 5.0-mm flexible hexagonal screwdriver to engage the locking mechanism. Once the helical blade is locked, interfragmentary compression will be obtained by turning the buttress/compression nut clockwise by hand. If additional leverage is needed, the 4.5-mm pin wrench will be used. The coupling screw and the inserter will be removed, and the surgeon will use the 5-mm flexible hexagonal screwdriver to loosen the connection and remove the blade guide sleeve from the aiming arm.

A 4-mm fluted drill bit loaded on a quick release adapt-

er will be needed. The surgeon will insert the assembled trocar and sleeves into the aiming arm marked for the locking screw. He or she will make a small incision using a #15 blade on a #3 knife handle. The surgeon's preference will dictate whether to use a hemostat to dissect to the bone. After the trocar touches the bone, it will be removed. The surgeon will then drill for the locking screw. The drill bit will be calibrated and once it goes through the medial cortex, the surgeon will advise on the screw length. Otherwise, a measuring device is available to measure the screw. After the drilling and measuring is complete, the surgeon will advise of the size and will remove the drill guide, leaving the protective sleeve in place. The surgeon will insert and tighten the screw by hand only using the hexagonal screwdrivers – no power will be used on this screw. The surgeon will then remove the aiming arm and nail insertion handle by using the 8 mm ball hexagonal screwdriver.

The end cap is optional. For reverse oblique intertrochanteric and high subtrochanteric fractures, the nail will need to sit slightly proud of the greater trochanter to provide an added point of fixation. If the nail is over-inserted, the end cap will be used to add length to the nail to accomplish the length requirements. The end cap also will be used if the surgeon is concerned about bony overgrowth into the proximal end of the nail. The end cap will be cannulated and inserted over the 3.2-mm guidewire with the guidewire inserted into the nail. An 11-mm ratchet, 5-mm flexible hexagonal screwdriver, 5-mm hexagonal shaft and the 11-mm hexagonal cannulated socket will be required to insert the end cap. The surgeon will place the end cap down over the guidewire and use the ratchet to tighten the end cap.

The surgeon will irrigate the wound with a saline irrigation. He or she will use an 0 polyglactin 910 on a CT-1 needle for the fascia layer and a 2-0 polyglactin 910 or a 3-0 polyglactin 910 for the subcutaneous layer, followed by either skin staples or a 4-0 polyglactin 910 on a PS-2 or a 4-0 poliglecaprone 25 on a PS-2 needle for the skin layer. Dressings usually include 4x4 paddings and tape. An adduction pillow may be used to keep the leg immobilized temporarily. Patients will be admitted for post-operative evaluation and pain management.

After the surgery, the patient will be evaluated for physical therapy. The goal is to get the patient as mobile as possible as quickly as possible.^{6,7} Most patients remain hospitalized for a week post-op.

POST RECOVERY

There are several factors involved in patient healing.

- Age - The older the patient, the longer the healing time. The typical demographic for hip fracture patients is 65 years of age and older.⁹
- General health - A patient without diabetes and hypertension will most likely have a faster recovery than a patient that presents with these conditions. Osteoporosis, the leading cause of intertrochanteric and peritrochanteric fractures, also can be an inhibitor of the healing process.^{10,11}
- Tobacco usage - Studies show patients who smoke can take as long as six weeks longer for bone union. Typically, patients with the most complications following surgical interventions for bone fractures are smokers because nicotine retards the osteogenesis process. Studies show that patients who quit smoking six months or more prior to elective orthopedic surgeries or who have never smoked, have fewer complications and better results than patients that either still smoke or quit within the last six months. Additional studies show smoking increases the severity of osteoporosis and in turn, increases the risks and severity of fractures. Studies also cite nicotine as the culprit, in turn revealing another example that the e-cigarette may not be a safe alternative. In addition, smoking dilates the vascular system, which restricts blood flow, and, therefore, inhibits healing factors.¹²



AUTHOR BIOGRAPHY

Jesse C Plummer, CST, has been a surgical technologist since 2004. He has 10 years of experience. He is currently working as a traveling surgical technologist. He enjoys traveling with his wife, Jessica, and seeing the country. He loves to play golf, photography and read books about the history of each area where he works.

Jesse completed the surgical technologist program at the College of Health Care Professions in Houston, Texas. Since then, he has lived in Arkansas, Tennessee and Oklahoma. He has traveled to Colorado, Michigan, South Dakota, Oklahoma, Montana, Iowa, Texas and Virginia.

Jesse credits Dr David M Sparks of Ponca City Medical Center; Scott Sjulín, Orthopedic Sales Rep; and Greg Rodenmeyer, CST, formerly of Ponca City Medical Center;

for taking him under their guidance and teaching him about orthopedic surgery. There have been many other influences in his professional life, in which he says “to list them all would take a book.”

REFERENCES

1. *A Brief History of Orthopedic Surgery* “[Http://en.wikipedia.org/wiki/orthopedic_surgery](http://en.wikipedia.org/wiki/orthopedic_surgery).” Web Accessed 24 May 2014
2. Thompson, Jon C. “*Netter’s Concise Orthopaedic Anatomy 2nd Edition*”, Philadelphia: Saunders 2009 E-Book
3. Kellie, Shirlie and Jacob Brody. “Sex-specific and Race-specific Hip Fracture Rates.” *American Journal of Public Health* June 2014: 326-328. PDF
4. Alexander, Bruce, Frederic Rivara and Marsha Wolf. “The Cost and Frequency of Hospitalization For Fall-Related Injuries in Older Adults.” *American Journal of Public Health* June 1992 1020-1023 PDF
5. Gardner, M et al, “Treatment of the Intertrochanteric Hip Fracture with the AO Trochanteric Fixation Nail” *Orthopedics* April 2005:117-122 PDF
6. Gardner, M et al, “Treatment of the Intertrochanteric Hip Fracture with the AO Trochanteric Fixation Nail” *Orthopedics* April 2005:117-122 PDF
7. “Titanium Trochanteric Fixation Nail System” Technique Guide, 2002, PDF
8. Giodarna, Brian “5 C-Arm Safety Tips” *Outpatient Surgery Magazine* August 2010:79-81 PDF
9. Kellie, Shirlie and Jacob Brody. “Sex-specific and Race-specific Hip Fracture Rates.” *American Journal of Public Health* June 2014: 326-328. PDF
10. Kellie, Shirlie and Jacob Brody. “Sex-specific and Race-specific Hip Fracture Rates.” *American Journal of Public Health* June 2014: 326-328. PDF
11. Alexander, Bruce, Frederic Rivara and Marsha Wolf. “The Cost and Frequency of Hospitalization For Fall-Related Injuries in Older Adults.” *American Journal of Public Health* June 1992 1020-1023 PDF
12. Sclaro, John A., et al. “Cigarette Smoking Increases Complications Following Fracture: A Systematic Review.” *The Journal of Bone & Joint Surgery* 96.8 (2014): 674-681. PDF

Trochanteric Fixation Nail

373 JANUARY 2015 1.5 CE credits \$9

1. Which demographic isn't the most common for hip fracture patients?
 - a. Male
 - b. Aged 60-70
 - c. Walks with a walking aid
 - d. Shows signs of osteoporosis

2. _____, a Dutch military surgeon, invented the plaster of Paris cast in 1851.
 - a. Hugh Owen Thomas
 - b. John Hunter
 - c. Antonius Mathysen
 - d. Gerhard Kuntscher

3. What is the best patient positioning for this procedure?
 - a. Lateral decubitus
 - b. Supine
 - c. Lateral
 - d. Anterior

4. The surgeon will start the incision with a _____ on #3 knife handle, superior to the greater trochanter.
 - a. #3
 - b. #6
 - c. #10
 - d. #12

5. Many surgeons opt to ream when a _____ is used.
 - a. Short nail
 - b. Long nail
 - c. Multiple nails
 - d. No nails

6. If the surgeon determines reaming the canal is necessary, the surgical technologist will need to load the ___ ball-tipped reaming rod on the coupler in the power system.
 - a. 1-mm
 - b. 1.5-mm
 - c. 2-mm
 - d. 2.5-mm

7. The first orthopedic institute was established in _____ by Jean-Andre Venel.
 - a. 1780
 - b. 1880
 - c. 1770
 - d. 1870

8. For the long nail, the bow of the nail will need to be aligned with the _____ of the femur and ensured that the left or right nail is being used for the correct affected limb.
 - a. Anterior
 - b. Lateral
 - c. Posterior
 - d. Supine

9. The blade guide sleeve and the 3.2-mm trocar will be placed onto the _____.
 - a. #15 blade
 - b. Guidewire
 - c. Aiming arm
 - d. Femur

10. In the _____, a Seattle medical center popularized intramedullary fixation without opening up the fracture.
 - a. 1870s
 - b. 1980s
 - c. 1970s
 - d. 1990s

TROCHANTERIC FIXATION NAIL 373 JANUARY 2015 1.5 CE CREDITS \$9

NBSTSA Certification No. _____

AST Member No. _____

My address has changed. The address below is the new address.

Name _____

Address _____

City _____ State _____ Zip _____

Telephone _____

Check enclosed Check Number _____

Visa MasterCard American Express

Credit Card Number _____

Expiration Date _____

	a	b	c	d		a	b	c	d
1	<input type="checkbox"/>	<input type="checkbox"/>	<input type="checkbox"/>	<input type="checkbox"/>	11	<input type="checkbox"/>	<input type="checkbox"/>	<input type="checkbox"/>	<input type="checkbox"/>
2	<input type="checkbox"/>	<input type="checkbox"/>	<input type="checkbox"/>	<input type="checkbox"/>	12	<input type="checkbox"/>	<input type="checkbox"/>	<input type="checkbox"/>	<input type="checkbox"/>
3	<input type="checkbox"/>	<input type="checkbox"/>	<input type="checkbox"/>	<input type="checkbox"/>	13	<input type="checkbox"/>	<input type="checkbox"/>	<input type="checkbox"/>	<input type="checkbox"/>
4	<input type="checkbox"/>	<input type="checkbox"/>	<input type="checkbox"/>	<input type="checkbox"/>	14	<input type="checkbox"/>	<input type="checkbox"/>	<input type="checkbox"/>	<input type="checkbox"/>
5	<input type="checkbox"/>	<input type="checkbox"/>	<input type="checkbox"/>	<input type="checkbox"/>	15	<input type="checkbox"/>	<input type="checkbox"/>	<input type="checkbox"/>	<input type="checkbox"/>
6	<input type="checkbox"/>	<input type="checkbox"/>	<input type="checkbox"/>	<input type="checkbox"/>					
7	<input type="checkbox"/>	<input type="checkbox"/>	<input type="checkbox"/>	<input type="checkbox"/>					
8	<input type="checkbox"/>	<input type="checkbox"/>	<input type="checkbox"/>	<input type="checkbox"/>					
9	<input type="checkbox"/>	<input type="checkbox"/>	<input type="checkbox"/>	<input type="checkbox"/>					
10	<input type="checkbox"/>	<input type="checkbox"/>	<input type="checkbox"/>	<input type="checkbox"/>					

11. The end cap also can be used if the surgeon is concerned about the bone _____ into the proximal end of the nail.

- a. Fracturing
- b. Splintering
- c. Breaking
- d. Overgrowth

12. Studies have shown that patients who smoke can take as long as _____ weeks or longer for bone union.

- a. Four
- b. Six
- c. Eight
- d. Ten

13. In the Middle Ages, the injured were treated with bandages soaked in _____.


- a. Iodine
- b. Saline
- c. Horse blood
- d. Human blood

14. The long nail comes in lengths between 300mm - 460mm. The short nail comes in two lengths _____.

- a. 170 mm and 230 mm
- b. 177 mm and 232 mm
- c. 170 mm and 231 mm
- d. 170 mm and 235 mm

15. Patients recovering from a trochanteric fixation nail procedure usually remain in the hospital for _____.

- a. 10 days
- b. 1 week
- c. 12 days
- d. 2 weeks



Earn CE Credits at Home

You will be awarded continuing education (CE) credits toward your recertification after reading the designated article and completing the test with a score of 70% or better. If you do not pass the test, it will be returned along with your payment.

Send the original answer sheet from the journal and make a copy for your records. If possible use a credit card (debit or credit) for payment. It is a faster option for processing of credits and offers more flexibility for correct payment. When submitting multiple tests, you do not need to submit a separate check for each journal test. You may submit multiple journal tests with one check or money order.

Members this test is also available online at www.ast.org. No stamps or checks and it posts to your record automatically!

Members: \$6 per credit

(per credit not per test)

Nonmembers: \$10 per credit

(per credit not per test plus the \$400 nonmember fee per submission)

After your credits are processed, AST will send you a letter acknowledging the number of credits that were accepted. Members can also check your CE credit status online with your login information at www.ast.org.

3 WAYS TO SUBMIT YOUR CE CREDITS

Mail to: AST, Member Services, 6 West Dry Creek Circle Ste 200, Littleton, CO 80120-8031

Fax CE credits to: 303-694-9169

E-mail scanned CE credits in PDF format to:
memserv@ast.org

For questions please contact Member Services - memserv@ast.org or 800-637-7433, option 3. Business hours: Mon-Fri, 8:00a.m. - 4:30 p.m., MT

Make It Easy - Take CE Exams Online

You must have a credit card to purchase test online. We accept Visa, MasterCard and American Express. Your credit card will only be charged once you pass the test and then your credits will be automatically recorded to your account.

Log on to your account on the AST homepage to take advantage of this benefit.

Studying for the CST Exam? There's an App for That

The only AST-authored study guide with more than 1,400 questions has gone mobile! AST recently published its first app – AST Study Guide – and it's available in the iTunes Store and Google Play.

The app includes six tests to review and utilize while preparing for the CST examination sponsored by the National Board of Surgical Technology and Surgical Assisting. Now, all the study tips are conveniently in the palm of your hand.

Study with confidence whenever and wherever you are!

