

Rapid forced eruption: A case report and review of forced eruption techniques

Timothy M. Durham, DDS | Thomas Goddard, DDS | Scott Morrison, DDS, MS

This article reviews the infrequently utilized treatment method of forced eruption and how it can serve as an alternative to the sacrifice of the natural root system.

Forced eruption can preserve the natural root system and related periodontal architecture, resulting in years of additional service for the patient. It also can maintain adjacent tooth structure while retaining the option for future implant reconstruction. Given the reported success of forced eruption, the technique requires greater attention and increased application among dentists. A case of forced eruption in the anterior maxilla utilizing a removable device is described. An overview of forced eruption technique also is provided.

Received: June 1, 2003

Accepted: July 3, 2003

Dentistry continues to make great strides in meeting the dental needs and evolving esthetic demands of patients.^{1,2} Bleaching, implants, and porcelain restorations are at the forefront of this approach to cosmetic care. Some of dentistry's more traditional treatment approaches and long-held values, such as saving the natural tooth and its root system for as long as clinically possible, have been challenged as a result. Levine noted in 1997 that while esthetics, function, and cost are at the core of patients' motivation, these goals may conflict with the goal of self-preservation.¹ There is growing opinion that recent advances in implantology have all but replaced the fixed partial denture (FPD) as the treatment of choice for restoring a missing tooth.³ Esthetic advances in implants allow for the successful and predictable replacement of missing anterior teeth.¹ Such success may contribute to a "rush to implant" mentality and diminish the value of self-preservation for both our patients and the profession.

In the case of a fractured anterior tooth, especially one with previous endodontic therapy, it is not uncommon for a dentist to recommend sacrificing the tooth and placing an implant.^{2,4,5} Unfortunately, traumatic injuries to the alveolus or extractions can cause a loss of buccal alveolar bone. In many cases, dentistry still lacks the ability to recreate normal periodontal architecture, despite improved technologies and biomaterials, soft- and hard-tissue grafting, and implantology.

These shortcomings can result in a compromised esthetic, such as lost interdental papillae or marginal gingival heights that are not aligned esthetically with adjacent teeth.¹ In a summary of current literature, Salinas commented that ancillary procedures often are necessary for more predictable outcomes from single-tooth implants. Frequently, there is a need to augment both hard and soft tissues in conjunction with such implant reconstructions. Even after a restoration is completed, changes of bone and soft tissues occur to affect the site's appearance.³ Furthermore, there still is a patient population that may not have the financial means for receiving implant care, even when it appears to be one of the best options.

This article reviews the infrequently utilized treatment method of forced eruption (orthodontic extrusion) as an alternative to the sacrifice of the natural root system.² When used in the correct situation, forced eruption can preserve the natural root system and its associated periodontal architecture, resulting in years of additional service for the patient; it also maintains adjacent supporting tooth structure while retaining the option for implant reconstruction.^{6,7} This article presents a forced eruption case in the anterior maxilla in which a removable device is utilized instead of the more frequently used fixed device design. An overview of forced eruption also is provided that describes the clinical indications and contraindications for use of the technique.

Case report

A 39-year-old woman came to the dental clinic after suffering a traumatic injury to tooth No. 7, which had been restored previously with a porcelain-fused-to-metal (PFM) crown. The injury fractured the clinical crown from the root at the level of the marginal gingiva, leaving two thin dentin spicules located centrally (Fig. 1). Teeth No. 3–5 also had an FPD, while teeth No. 6–11 also had porcelain-fused-to-metal crowns; the majority of those had been placed within the previous 18 months. A periapical radiograph indicated that the patient had not suffered root or alveolar fractures and that damage was limited to the clinical crown fracture. With circumferential probing depths of 1.0 mm, the biologic width had not been directly violated by the fracture; at the same time, there was inadequate tooth structure (1.5–2.0 mm) to achieve a ferrule effect following reconstruction with a post and core and crown. Under these conditions, the resulting restoration margin would extend to the depth of the gingival sulcus, encroach upon the biologic width, lack resistance strength and retention form, and lead to potential chronic gingival inflammation.

A number of treatment options were offered, including extracting tooth No. 7 and placing an implant; extracting tooth No. 7 and placing an FPD; and endodontic therapy, forced eruption, and reconstruction with a post and core and PFM crowns. Esthetically, there was concern that the extraction of tooth No. 7 and any subsequent implant procedures could result in the loss of interdental papillae, recession, and exposure of adjacent crown margins. Placing an FPD would be fairly straightforward, given the fact that teeth No. 6 and No. 8 had received crowns recently; however, the patient did not wish to have these crowns removed and replaced. After reviewing the risks and potential outcomes, the patient opted for forced eruption and reconstruction with a post and core and crown.

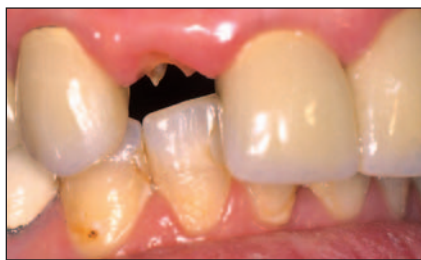

Fig. 1. Tooth No. 7 after endodontic therapy.

Selecting an appropriate method of root eruption was discussed. Although brackets could be affixed to the adjacent PFM crowns, there was concern that removing the brackets could chip the porcelain or damage the surface glaze in this esthetic zone. After assessing the degree of overjet and overbite, maxillary and mandibular alginate impressions were taken for the eventual design of a Hawley removable device.

Endodontic therapy was started immediately and taken to completion. The gutta-percha was removed from the coronal 3.0–4.0 mm of the canal space and the thin dentin was reduced. Using a drill, the coronal root area was prepared for a prefabricated post 1.0 mm in diameter. A plastic impression post was inserted into the canal and an impression was taken using a polyether material. The tooth was temporized with a self-curing acrylic corrected polycarbonate crown and a shortened steel vented post that engaged the upper 4.0 mm of the root canal space. A portion of the plastic impression post on the dental cast was reinserted into the stone and a hook was attached using sprue wax; this impression was sent to the laboratory so that it could be cast in a base metal. The maxillary cast also was sent to the laboratory with instructions on design and fabrication of a Hawley device incorporating a loop and hook (Fig. 2 and 3).

For this design, it was critical to center the Hawley's hook over the long axis of the root and maintain sufficient distance between the Hawley device hook and the hook that would be cemented into the root of tooth No. 7. The distance between the hooks would have to account for the desired eruption distance and provide adequate distance for the activation of an orthodontic elastic. In its inactivated state, a single orthodontic power chain loop or bracket elastic were measured clinically to be approximately



Fig. 2. A cast metal hook that was embedded into the canal space.

2.0 mm and 3.0 mm in diameter respectively; as a result, it was determined that a 5.0 mm distance between the two hooks would be necessary to achieve 2.0 mm of forced eruption. This distance was given to the laboratory as a guide, knowing that the distance could be modified clinically by changing the hook's vertical position while it was being cemented into the root surface.

The patient returned to the clinic for a try-in and hook separation distances were measured. Using zinc phosphate cement, the hook was cemented into the root when the Hawley device was in place. An effort was made to maintain the appropriate distance between the two opposing hooks and their alignment along the tooth's long axis. Once the cement was set, a single power chain loop was placed, creating immediate tension and discomfort for the patient; as a result, two loops were used initially (Fig. 4). The patient reported mild tension on the root when the device was activated in this manner. The curvature of the root hook was opened slightly with a diamond bur to allow for easier engagement of the elastic. The patient was instructed to use a hemostat to replace the elastics daily and was provided with enough elastic loops for one week. The patient was instructed to return to the clinic with any problems and to use over-the-counter analgesics for any discomfort associated with the extrusion.

After one week, the root showed both movement and mobility. The power chain loop was replaced with an orthodontic bracket elastic; at that time, the patient noted tolerable tension. The patient was examined weekly for another four weeks. At the end of this time, the distance between the two hooks was 3.0 mm, more than the 2.0 mm of desired extrusion (Fig. 5). A maxillary impression was taken for a stabilization device.

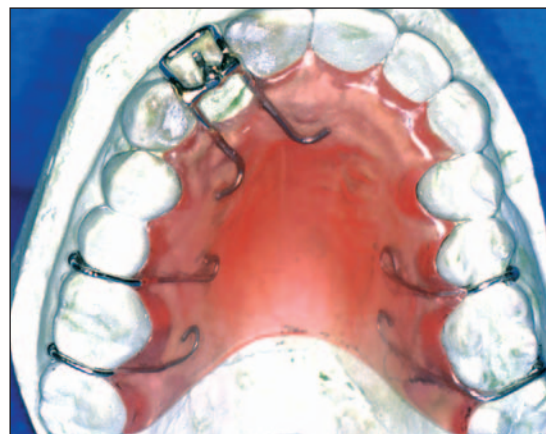


Fig. 3. A removable device designed for forced eruption.

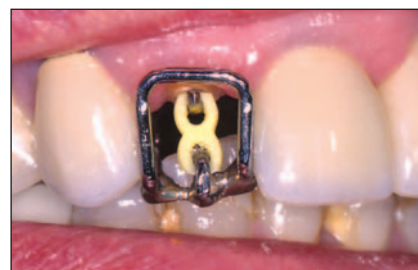

Fig. 4. The removable device is in place and activated with orthodontic powerchain.

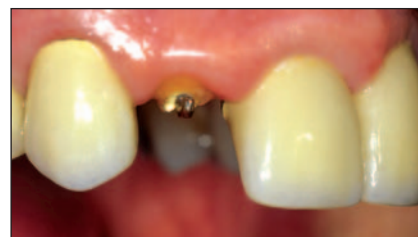

Fig. 5. Final position of tooth No. 7 following five weeks of forced eruption.

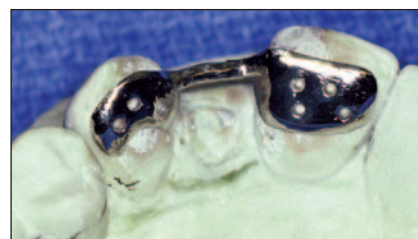

Fig. 6. A stabilization frame.

To stabilize the root system, the laboratory was asked to fabricate a thin Maryland bridge frame (Fig. 6). Maryland bridge wings were designed to overlay the lingual surfaces of teeth No. 6 and No. 8;

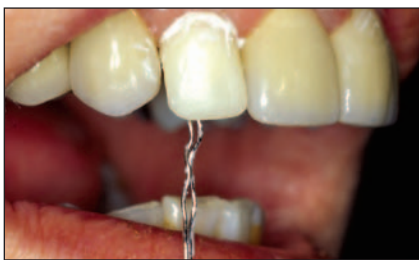

Fig. 7. A temporary crown is placed with ligature wire through the lingual access.

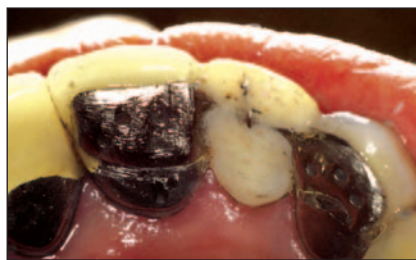

Fig. 8. The temporary crown in final position.

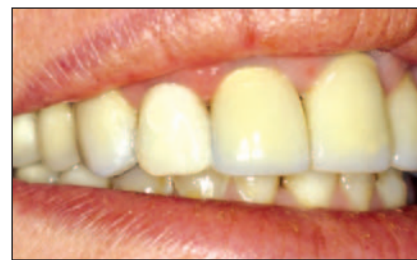

Fig. 9. The lingual surface of the stabilization device.

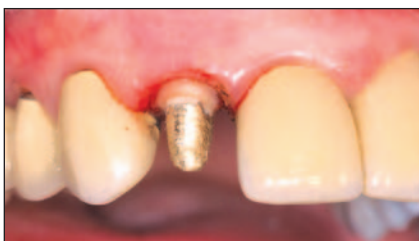

Fig. 10. The post and core following removal of excess gingival tissue.

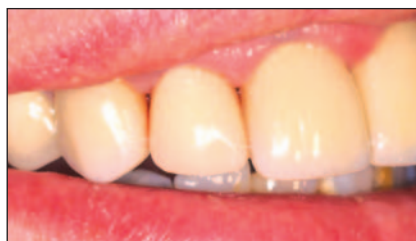

Fig. 11. A PFM crown after cementation.

the teeth were connected with a thin bar that allowed for the opposing occlusion. A polycarboxylate crown was fitted intra-orally over tooth No. 7. The lingual surface of the crown was removed, allowing for visualization of the hook through the back of the crown and clearance of the Maryland bridge connecting bar upon its seating. The crown was adapted to tooth No. 7 with self-curing acrylic. Once the Maryland bridge was seated, excess acrylic immediately was removed from around the hook and cleared from the lingual access area while the margins of the polycarboxylate crown were smoothed and polished with pumice. A ligature wire was secured around the cemented hook in tooth No. 7, then passed through the undersurface of the temporary crown and out via the lingual access opening.

The crown's undersurface was coated with a fresh mix of glass ionomer cement and the crown was manipulated into place. The Maryland bridge frame was inserted onto the lingual surfaces of teeth No. 6–8. The ligature wire was wrapped around the connecting bar and twisted to secure the frame against the lingual surfaces of teeth No. 6 and No. 8, resulting in stabilization for tooth No. 7 (Fig. 7–9). After excess cement was removed from the opening, the ligature wire was cut to an appropriate length so that it could be folded easily into the lingual surface access; the

area was closed with self-curing acrylic.

The dentist prescribed a two-month period of stabilization but the patient was unable to return to the clinic for final reconstruction until 12 months had elapsed. At that time, the stabilization device was removed and the root hook was detached using an ultrasonic scaler and a hemostat. The biologic width of the tooth was assessed to evaluate the need to remove excess hard and soft tissue. Sounding determined that the bone height was unchanged and that gingival height had increased approximately 1.5 mm during stabilization. The root system was prepared for the placement of a cast gold post and core, which was cemented into place after fabrication. Prior to final preparation, excess gingival tissue was removed using electrocautery (Fig. 10). After a 10-day healing period, the patient returned to receive final preparation and an impression was made from a polyether material. A PFM crown was fabricated and cemented into place (Fig. 11).

Discussion

Since their introduction in 1973, both fixed and removable devices have been used to extrude teeth; the use of fixed applications has been described more frequently.^{5,8} Forced eruption is advocated for treating coronal and root fractures, root caries, iatrogenically induced pin

trauma, and endodontic perforations that are at or slightly above the crestal bone height; in addition, forced eruption is a potential alternative therapy for infrabony pockets.^{1,2,4,6,7,10–16}

Unlike traditional orthodontic care, the objective of forced eruption is not to change the tooth's spatial position in the arch but to maintain and preserve the root system and its healthy biologic width.¹⁷ The forced eruption technique can occur slowly (that is, over the course of months), or very rapidly (over the course of weeks).^{1,14–17} The technique has advantages over crown lengthening, which is what dentists may consider first as a treatment option when faced with such clinical circumstances.¹⁷

While slow or rapid forced eruption will achieve the desired root movement, each technique has different periodontal implications. If the root is extruded slowly, there will be compensatory growth of bone and soft tissue not unlike what is seen in supereruption of an unopposed tooth.¹ Before the final restoration is completed, the bone and soft tissue must be recontoured to establish biologic width and alveolar architecture that is consistent with the adjacent teeth. Slow eruption can be advantageous for areas where bone growth is desired, such as interproximal areas where the bone can provide substructure for interdental papillae or to correct a bony defect. Movement from rapid eruption occurs so quickly that eruption outpaces bone growth.¹⁹

Soft tissue growth may be visible during the stabilization period as supra-alveolar (specifically, dentogingival) fibers retain their attachment to the erupting root. The longer the stabilization period, the more likely such growth will occur and minor periodontal gingival surgery may be necessary to remove gingival or even bony excess. Soft tissue overgrowth

was observed in this case when the patient failed to return in the specified time period. Some authors have discussed utilizing supracrestal fiberotomy before and during forced eruption to minimize this process and to limit intrusive forces once the root has been erupted into place.^{5,8,17} It is unclear as to whether fiberotomy would decrease the time required for stabilization.

The literature draws a clear distinction between the objectives and potential outcomes of forced eruption and associated periodontal surgical care and those of more traditional crown lengthening procedures.¹⁴⁻¹⁷ In the absence of root eruption, a crown lengthening procedure will have a negative architectural impact on the adjacent teeth that can impact crown-to-root ratio adversely, elongate clinical crowns, or open embrasure spaces by disrupting the interproximal bone.¹⁷ The bony housing is reduced to expose more root and requires a dentist to contour the adjacent bone, which could change the soft tissue contours of neighboring teeth as well. Such conditions can be avoided with forced eruption.¹⁷

During slow eruption, the alveolar bony housing moves along with the erupting root; during rapid eruption, bone movement may not be present at all and changes in soft tissue may involve a localized gingivectomy around the erupted root only.¹² Periodontal procedures that follow forced eruption (referred to as *biologic width realignment procedures*) do not have the same impact on the adjacent architecture.^{13,14,17} If necessary, realignment is performed to establish biologic width on the extruded root, repositioning soft tissue and/or bony profile apically into alignment with the architecture of the adjacent teeth.

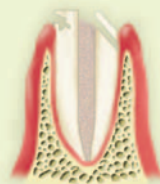
There are four identified phases of successful forced eruption therapy: case selection and root preparation, application of appropriate eruptive force, stabilization of the extrusion, and the final prosthetic reconstruction of the root.^{12,16,18} Endodontic, periodontic, prosthodontic, esthetic, and orthodontic principles are utilized in forced eruption therapy.^{9,18}

Case selection and technique

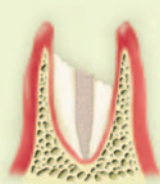Case selection requires analyzing a number of key areas, including root trauma, internal pulp canal form, root length, root form, root health, adjacent teeth, occlusion, tooth value, age, restorative

Table 1. Case selection criteria.

Root trauma



Unfavorable

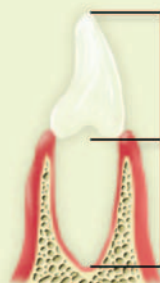

The level and extent of the fracture, caries, or perforation dictates the success of the eruption process and is critical for determining the necessary amount of eruption. The objective is to re-establish a biologic width of 2.04 mm; a minimum gingival sulcus of 0.69 mm; and a prosthetic ferrule effect (a 1.5–2.0 mm circumference of natural

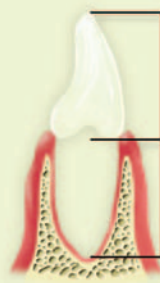tooth structure coronal to the final restorative margin). Sound to bone and review the radiograph for the trauma position and condition of the bone. If the bone is fractured at the alveolar crest, at least 4.0–5.0 mm of sound tooth structure is needed above the fracture to account for periodontal and prosthetic needs.

Root length

Favorable



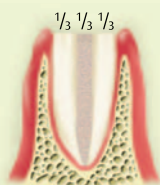
Unfavorable



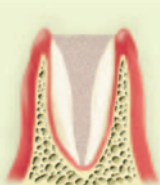A crown-to-root ratio of 1:1 is required. Measure the root length radiographically and estimate the final restoration length by measuring the distance from the free gingival margin to the incisal edge, using the adjacent teeth as a guide. The final restoration length should be equal to or less than the amount of root that will remain in the bone.

Internal pulp form

Favorable



Unfavorable

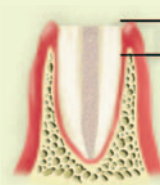


A large pulp canal form at the coronal aspect of the root is a contraindication for forced eruption. The width of the chamber leaves weakened tooth structure on the periphery that will fail when it is restored with a post and core. Assess whether the weakened area can be removed and the remaining root can be erupted into position. When assessing the

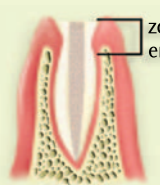
pulp form, use the “rule of thirds” (one-third for the canal space itself and one-third root thickness on both sides of the canal space).

Root form

Favorable



Unfavorable



A wide neck on the coronal root surface is most favorable esthetically. The potential impact on final esthetics increases as the root form becomes more narrow or tapered (especially in the zone of eruption). The tapered root will result in a final restoration with a narrow emergence profile.

Patient motivation

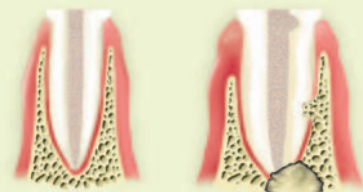
The patient must be motivated to save the tooth and appreciate the value of the natural root system. Manual dexterity for changing elastics and an understanding of the time devoted to care are vitally important.

Table 1. Case selection criteria. (continued)

Root health

Favorable

Unfavorable



The periapical area must be free of acute or chronic pathology. Endodontic care, in the form of initial therapy, retreatment, or canal preparation, may be required. A well-condensed canal with a quality apical seal is important for long-term success. Contraindications to forced eruption include calcified canals or other endodontic conditions that

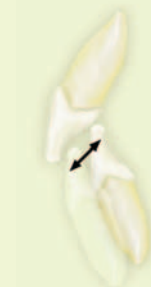may make treatment more difficult or reduce longevity (resorption processes).

Adjacent teeth



Determine the health of the adjacent teeth and if they are restored with crowns, composites, or other restorations. Natural tooth surfaces on adjacent teeth provide areas for bonding orthodontic brackets. Existing restorations may be partially removed for anchoring metal rods; the presence of crowns may dictate using a removable device. Generally, fixed techniques require two teeth on either side of the root for placement of orthodontic hardware.

Occlusion



Opposing occlusion must be evaluated for overjet, overbite, and lateral excursions, allowing dentists to assess that clearance is sufficient for either fixed or removable devices. Deep bites are more challenging in anterior cases and may eliminate removable devices from consideration.

Tooth value

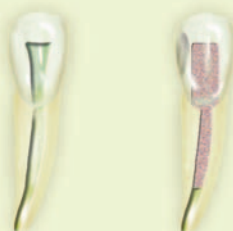

The value of the tooth must be assessed with respect to the remaining dentition. In the arch, gross periodontal changes, general neglect, or other nonsalvageable teeth in the arch may dictate a more comprehensive approach to patient care, leading to removal of the fractured tooth.

Age, history of care, esthetic zone

Favorable

Unfavorable



Salvaging the root system through forced eruption is an option that depends on the patient's age as well as the extent of trauma from previous dental interventions. High lip lines may expose more gingiva and teeth; in such situations, it is critical to maintain interproximal bone height and preserve the papillae. Lip position may make forced eruption a more attractive option than implant restoration or fixed prostheses.

history, lip position, and patient motivation (see Table 1).^{1,7,9,16,17} The most favorable clinical conditions for forced eruption involve cases where trauma has occurred at the cemento-enamel junction (CEJ) or at the level of the crestal bone height. When damage occurs apical to these points, the dentist must determine if any violation has occurred to the tooth's biologic width and establish an estimate of the future restorative margin; these two numbers will provide preliminary estimates of the eruption distance necessary. Biologic width includes 1.07 mm for connective tissue attachment above crestal bone, 0.97 mm for epithelial attachment, and an additional 0.69 mm for the gingival sulcus, resulting in a distance of 2.73 mm for the dentogingival complex.^{1,9,12}

Prosthetically, at least 1.5–2.0 mm of natural coronal tooth structure superior to the epithelial attachment level is desired.^{1,9,12,19,20} This amount of coronal tooth structure is one of the most important predictors of restorative success and is especially critical for reducing stress concentrations at the gingival margins of the future crown.²⁰ Fractures at the level of the crestal bone require the dentist to recapture and preserve the dentogingival complex and adequate tooth structure for prosthetic success through the eruption process. While the literature suggests that this distance should be 3.0–4.0 mm, the minimal distance may be closer to 4.0–5.0 mm; this variance depends on sulcular depth, the establishment of a ferrule effect, and whether the final restorative margin will be at or below the gingival margin height. As a result, when determining the necessary eruption distance, the dentist should account for connective tissue attachment, epithelial attachment, and a restorative margin that will preserve a minimum gingival sulcus while keeping 1.5–2.0 mm of sound tooth structure coronal to the future restorative margin.

As a clinical aid, tooth fragments can be examined for evidence of the CEJ. If the dentist can identify the CEJ on the fragment, the amount of tooth structure that extends apically beyond the CEJ can be measured by a periodontal probe. The CEJ lies approximately 2.0 mm beyond the crestal bone height; as a result, knowing the fracture position in relation to the CEJ can provide a very rapid and gross

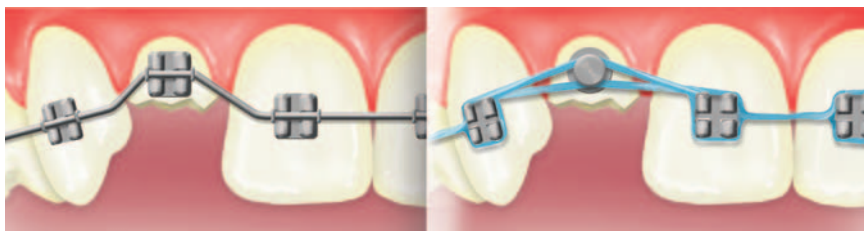


Fig. 12. Left: A fixed device utilizing orthodontic brackets and wire.^{1,17} Right: A fixed device utilizing orthodontic brackets, button, and elastics.^{4,7}

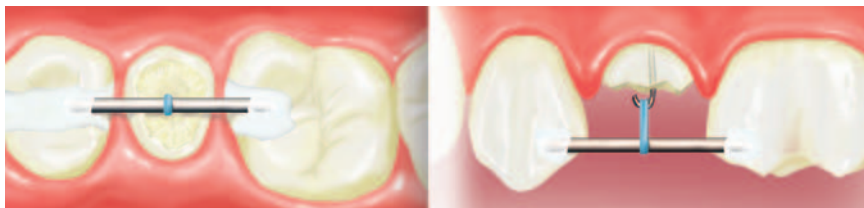

Fig. 13. Occlusal and buccal views of a fixed device with an embedded rod, root hook, and elastic.^{4,10}

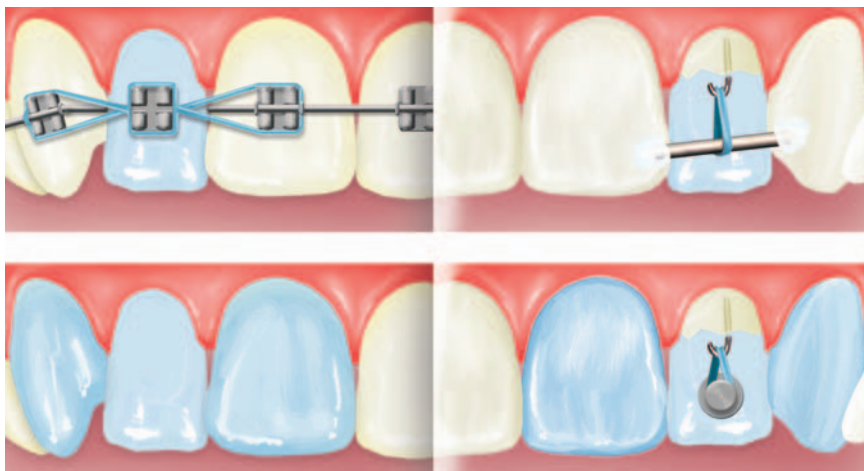


Fig. 14. Top: Buccal and lingual views of an esthetic fixed device consisting of orthodontic brackets, pontic, root hook, and elastic.¹⁸ Bottom: Buccal and lingual views of an esthetic fixed device consisting of a temporary bridge, root hook, and elastic.⁹

determination of the extent of biologic width encroachment and resulting necessary eruption distance. Radiographs and sounding also provide valuable clinical information for determining the extent of the encroachment and the distance required for forced eruption.

With the eruption distance established, the anticipated clinical crown height must be compared to the retained root length. If the displaced crown is not available, the missing crown height can be measured clinically by marking the distance between the gingival margin and the incisal edges of the adjacent teeth;

this distance must be compared to the radiographic length of the root (minus the desired eruption distance). After eruption, a crown-to-root ratio of 1:1 is preferred.^{9,13} This prosthetic principle will be violated if the crown length is greater than the projected root length after eruption; as a result, long-term success will be in doubt. Options other than forced eruption should be considered if the traumatic injury begins to extend into the middle third of the remaining root.

After the eruption distance and crown-to-root ratio are determined, the root system conditions should be as-

sessed to evaluate the the root system's overall health, the root's structural integrity, and any root morphology that could cause esthetic concerns for the final restoration. With respect to root health, the periapical area and root system should be free of acute or chronic disease; healthy conditions would include the area being free of resorptive processes and having an existing well-condensed, apically sealed root canal (or the ability to achieve such a result).⁹ Bone quality and periodontal health must not be compromised; orthodontic movement in the presence of inflammation may exacerbate both periodontal conditions and osseous defects.⁹ The tooth is not a candidate for forced eruption if clinical conditions exist that compromise the root health as described.

The root system's structural integrity and its ability to receive a post and core also must be considered. The canal space or internal pulp form at the level of the fracture must be evaluated. Thin and weakened tooth structure on the periphery of the root is possible if the pulp canal form is wide; post placement may cause these areas to collapse and fracture or lead to future splitting of the root. When evaluating the root system, the "rule of thirds" historically has been applied; based on this rule, the canal preparation should be no greater than one-third of the total mesial-to-distal root width.²¹ Since the thickness of remaining dentin is a determining factor of resistance to fracture, dentists must use professional judgment regarding the remaining root structure's soundness as a foundation for post and core placement.²⁰

The root form at the point of fracture also requires consideration, as it can have a significant impact on both the emergence profile and the final esthetics.^{9,12,16,18} Because root forms can be quite varied, the root area that is to be extruded (referred to as the *zone of eruption*) must be examined. In this zone, broad mesial-distal root form affords the most esthetic results for forced eruption cases, compared to tapered or narrow root forms. A tapered root in the zone of eruption will produce a narrow neck on the final crown as it emerges from the tissue, adversely affecting esthetics and periodontal health.^{9,16,18} Although crowns with an increased thickness of porcelain can be fabricated to improve the emergence

profile, there is a long-term risk of chronic gingival irritation or interproximal bone height loss.^{12,18}

If the root system is a candidate for successful forced eruption, the adjacent teeth and dentition should be evaluated to determine if a fixed or removable technique can be utilized; at that time, the prosthetic value of the root system with respect to the remaining dentition also should be assessed. Fixed forced eruption techniques center on readily recognizable orthodontic designs (Fig. 12–15). The adjacent teeth (usually two on each side of the root) are used as orthodontic anchors, except in posterior areas where a molar is equal to two anchor teeth.⁹ Ideally, teeth with virgin surfaces are used for bonding the brackets or buttons. It is possible to bond with resin or porcelain surfaces but removing the bracket could damage the underlying restoration. To produce the desired extrusion, a flexible multi-stranded stainless steel wire typically is secured into place while elastics are attached to the root.⁹ Wire and hook designs also have been utilized in the anterior segment and in premolar areas.¹⁰

Selecting this type of fixed device for premolar areas is enhanced by the presence of interproximal alloy or resin restorations in the adjacent teeth; a thick wire or bar can be embedded either into the restorations that lie on each side of the root to be extruded or on the facial surfaces of anterior teeth. The bar transverses the space over the exposed root at a level that is not impeded by and does not interfere with the patient's occlusion. A hook is placed into the root and the root hook is engaged with an elastic that is passed up and over the bar and back once again to the hook. Molars rarely undergo forced eruption and are more likely to undergo crown lengthening procedures.¹⁷ For premolar areas, the typical advantages of forced eruption may be outweighed by anchorage difficulties, decreased esthetic demand, and root form issues such as furcations. Cases can be treated using a removable device if overall oral conditions make a fixed device unsuitable.

The literature reports the use of Hawley-type devices, bruxism splints, and modified removable partial dentures as removable platforms for forced eruption.²⁵ For removable applications, a device must be stable when force is applied

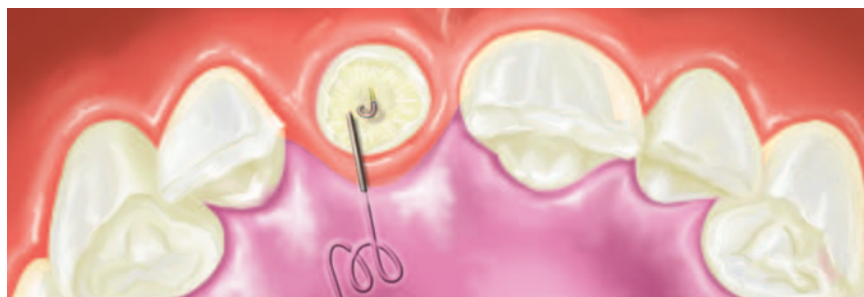
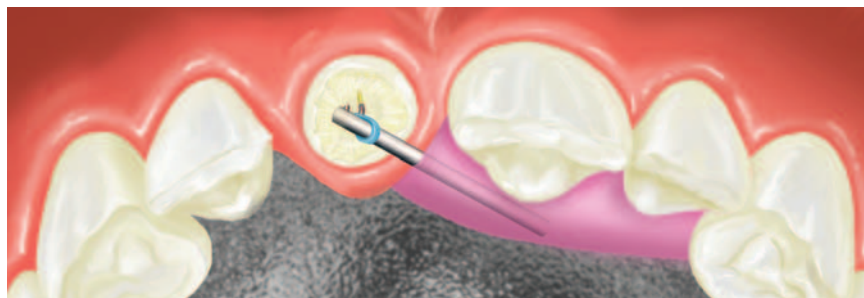
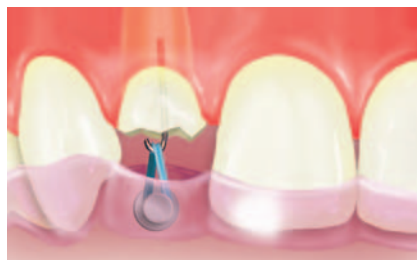

Fig. 15. Top: A removable device consisting of a bite splint with an embedded button, a root hook, and elastic.⁹ Center: A removable device consisting of an existing partial, an embedded rod in acrylic, a root hook, and elastic.⁵ Bottom: A removable device consisting of a Hawley device, an embedded spring in acrylic, and a root hook.²

and easy for the patient to place and remove when the dentist is absent. Murchison and Schwartz stated that removable devices are easier to clean and allow for better oral hygiene maintenance during eruption procedures.⁵

If hooks are used, they must be aligned over the long axis of the tooth, as both fixed and removable techniques seek to apply 25–30 g of eruptive force in line with this long axis.^{4,6,9} If the eruptive force is off center, a lateral shift or deviation away from the tooth's long axis may occur in a buccolingual or mesiodistal direction.^{6,9} Such lateral movement may improve the alignment and esthetics for a tooth originally out of arch alignment.⁶ An area of forced eruption must have sufficient clearance during maxillary intercuspation or lateral excursive movements for the placement of fixed or removable hardware. Patients are examined on a

weekly basis to assure compliance and movement; if undesired movement is noted, the device can be removed and the root will intrude to its original position.

Ultimately, the design of the eruption device (fixed or removable) depends on a dentist's imagination and the limitations resulting from the existing conditions.⁴ It was the authors' experience that using a removable device increased the amount of time required to produce the necessary eruption. This increase was attributed to the use of elastics capable of generating the required level of force, cautious execution of technique by both the dentist and the patient, and the challenges of 24-hour compliance with the device. Both techniques and their applications are summarized in Table 2.

Forced eruption therapy will not benefit the patient if the total value of the root system does not contribute to the

Table 2. Comparison of fixed and removable devices.

Fixed devices	Removable devices
Can lead to precise and well-defined movements	Less exacting and precise yet capable of producing the desired movement
Application may be limited in the presence of crowns and veneers	Application is useful when crowns, veneers, or movable devices are present or when adjacent tooth anchorage is missing
Stabilization is readily achieved by virtue of the design with options for placement of esthetic temporary veneers/crown pontic on the orthodontic wire to fill missing tooth space	Stabilization will require ingenuity and the utilization of adjacent teeth. Stabilization plan also must include consideration of temporary crown pontic placement
Arch space is not as critical, as the wire can be bent to avoid interferences	Adequate interarch space is required for both the device and stabilization materials
Generally requires less patient dexterity; some designs may require the patient to change elastics, thereby increasing the need for manual dexterity	The patient must disengage the device for removal and activate it upon insertion into the mouth
May require posteruption periodontal surgery	May require posteruption periodontal surgery

Table 3. Stages of treatment and duration for a forced extrusion of 4.0 mm.

Stage	Treatment	Duration
One (case selection and root preparation)	Examination, endodontic care as needed, fabrication of eruption device	Two weeks
Two (application of eruption force)	25–30 g of force with a general goal of 1.0 mm of extrusion per week under rapid forced eruption conditions	Four weeks
Three (stabilization)	One month of stabilization for every millimeter of extrusion. Consider fiberotomy prior to, during, or after stabilization	Four months
Four (prosthetic restoration)	If osseous surgery is needed, allow four to six weeks of healing prior to restoring with a crown. With minor gingival recontouring, two to four weeks of healing generally is needed before prosthetic care can start	Two to six weeks

overall health of the dentition or if the patient does not exercise self-preservation. Clinical states that would detract from the application of forced eruption include a fractured tooth within a periodontally ravaged mouth, a lone standing tooth that could not be used for anchorage of a prosthodontic device, or the presence of gross neglect and active decay.

Factors that must be considered include the patient's age, lip position, and motivation and the root system's dental history. Younger patients tend to be more ideal for this technique because their root systems generally have not endured accu-

mulative restorative trauma or root manipulations that are more common with aging. Dental caries, multiple endodontic procedures, loss of tooth structure, and previous restorations utilizing the canal space for restorative anchorage all compromise the root system, making it more fragile structurally for undergoing complex dental interventions.²² A younger patient also may have the advantages of more ideal internal canal form and better root health, which could allow the patient to retain the root, thereby providing a greater benefit over the course of a lifetime.

High lip lines expose more gingival surface and require the dentist to give greater care and attention to the periodontal architecture. Under such circumstances, forced eruption may provide a more esthetic result than an implant system in which buccal or interproximal bone loss and a need for ancillary procedures are risks.

Individuals who undergo forced eruption participate actively in the therapy (they have been described as “co-therapists”) and will need enough manual dexterity to change elastics.^{1,5} The esthetics of the device during the eruptive process should be a great concern for the patient; in addition, the patient must make a concomitant dedication to salvage the root and must understand the time involved in care (see Table 3).⁵

Stabilization

Once the desired amount of extrusion has been achieved, the tooth must be stabilized to allow for remodeling of the periodontal apparatus and to prevent relapse intrusion. Generally, the root system must be stabilized four weeks for every millimeter of movement.^{4,9,14} Stabilization techniques have varied as much as the design of the eruption devices but the goal of using a temporary crown or veneer to fill the space remains the same. It appears that esthetic stabilization is easier to achieve when fixed techniques are utilized, as a crown or veneer can be incorporated readily onto the orthodontic wire. The patient typically remains bracketed during the stabilization processes.

Removable devices require somewhat greater ingenuity. In the reported case, a Maryland bridge frame was used to maintain stabilizing force against root intrusion. This stabilization process was easy, applicable, and highly esthetic, providing adequate clearance on the lingual surface for the stabilization frame during both maximum intercuspation and lateral excursive movements. Fabricating the frame will not increase the laboratory cost of care dramatically.

Reconstruction

The last stage in forced eruption therapy is the placement of the final restoration. As noted previously, slow eruption causes bone and soft tissue growth, resulting in the need for realigning the biologic width.^{12,18,19} Such growth was experienced

in the present case and is attributed to the extended period of stabilization. With rapid eruption, it is more common to see only gingival growth, although some authors have mentioned bone growth as well.^{12,18,19} Regardless of technique, the biologic width should be checked and the marginal gingival height should be compared with that of the adjacent teeth after stabilization.⁹ These findings may require some form of periodontal recontouring prior to final placement of the restoration.^{4,9,10,12,18,19} Forced eruption techniques are selected for maintaining a healthy periodontium and esthetically favorable conditions. Failure to respect the biologic width at this point voids the intended objectives.

Prosthetic completion may be delayed depending on the type of periodontal intervention needed. If osseous recontouring is necessary, an additional four to six weeks of healing will be required before final reconstruction can begin. Esthetic areas may require up to 8–10 weeks of healing. If a gingivectomy is needed, tissue removal can occur along with fabrication and/or seating of the post and core; this will not delay the final restoration unduly. Completing the case involves following traditional prosthodontic techniques for post and core fabrication and crown placement.

Conclusion

Forced eruption provides both the dentist and the patient with another opportunity to use the natural root system and prevent the premature sacrifice of a tooth. It is a conservative approach that saves the root system, maintains periodontal architecture and esthetics, and preserves adjacent tooth structure by eliminating the restorative trauma of FPD preparation. Forced eruption also serves to maintain periodontal architecture in a manner that is more conducive to future implant placement.

Comparatively, the overall cost to the patient is typically less than that of an implant restoration or FPD care but more than that of a single crown. The procedure does require time (usually six to eight months to complete), although the amount of time depends directly on the amount of root eruption; this distance generally is comparable to the length of time devoted to most two-stage implant reconstructions.

When the rapid eruption technique is utilized, there is a period of time (typically four to five weeks) when esthetics are not favorable. Improved esthetics are possible during stabilization, although they are transitional in nature.

Forced eruption involves specific case selection criteria and requires a fairly motivated patient to complete. Fixed and removable techniques have produced the desired results adequately, providing dentists with a number of design and device options. While fixed techniques are applied most commonly, removable devices can be equally successful, both in similar clinical situations and in those where the fixed technique is not favorable. Given the reported success of forced eruption, the technique requires greater attention from and increased application by dentists.

Acknowledgement

The authors would like to thank Kim Theesen for artistic design work in this article.

Author information

Dr. Durham is an associate professor, Department of Dental Practice Management, College of Dentistry, University of Nebraska Medical Center in Omaha, where Dr. Morrison is a clinic instructor in Periodontics. Dr. Goddard is a postgraduate student in endodontics at the University of Iowa School of Dentistry in Iowa City.

References

1. Levine RA. Forced eruption in the esthetic zone. *Compend Contin Educ Dent* 1997;18:795-803.
2. Mandel RC, Binzer WC, Withers JA. Forced eruption in restoring severely fractured teeth using removable orthodontic appliances. *J Prosthet Dent* 1982;47:269-274.
3. Salinas TJ. A three unit FPD vs. single tooth implant restoration: What is the standard of care? Presented at: Annual meeting of the Academy of Prosthodontics; May 5, 2003; Boston, MA.
4. Benenati FW, Simon JH. Orthodontic root extrusion: Its rationale and uses. *Gen Dent* 1986;34:285-289.
5. Murchison DF, Schwartz RS. The use of removable appliances for forced eruption of teeth. *Quintessence Int* 1986;17:497-501.
6. Ziskind D, Sharon E, Hirschfeld Z, Becker A. Analysis of lateral tooth movement during forced orthodontic eruption. *J Prosthet Dent* 2000;84:462-466.
7. Simon JH, Kelly WH, Gordon DG, Ericksen GW. Extrusion of endodontically treated teeth. *J Am Dent Assoc* 1978;97:17-23.
8. Heithersay GS. Combined endodontic-orthodontic treatment of transverse root fractures in the region of the alveolar crest. *Oral Surg Oral Med Oral Pathol* 1973;36:404-415.
9. Stroster TG. Forced eruption: Clinical considerations. *Gen Dent* 1990;38:376-380.
10. Ziskind D, Schmidt A, Hirschfeld Z. Forced eruption technique: Rationale and clinical report. *J Prosthet Dent* 1998;79:246-248.
11. Berglundh T, Marinello CP, Lindhe J, Thilander B, Liljenberg B. Periodontal tissue reactions to orthodontic extrusion. An experimental study in the dog. *J Clin Periodontol* 1991;18:330-336.
12. Potashnick SR, Rosenberg ES. Forced eruption: Principles in periodontics and restorative dentistry. *J Prosthet Dent* 1982;48:141-148.
13. Biggerstaff RH, Sinks JH, Carazola JL. Orthodontic extrusion and biologic width realignment procedures: Methods for reclaiming nonrestorable teeth. *J Am Dent Assoc* 1986;112:345-348.
14. Wang WG, Wang WN. Forced eruption: An alternative to extraction or periodontal surgery. *J Clin Orthod* 1992;26:146-149.
15. Ivey DW, Calhoun RL, Kemp WB, Dorfman HS, Wheeler JE. Orthodontic extrusion: Its use in restorative dentistry. *J Prosthet Dent* 1980;43:401-407.
16. Johnson GK, Sivers JE. Forced eruption in crown-lengthening procedures. *J Prosthet Dent* 1986;56:424-427.
17. Stevens BH, Levine RA. Forced eruption: A multidisciplinary approach for form, function, and biologic predictability. *Compend Contin Educ Dent* 1988;19:994-1000.
18. Zyskind K, Zyskind D, Soskolne WA, Harary D. Orthodontic forced eruption: Case report of an alternative treatment for subgingivally fractured young permanent incisors. *Quintessence Int* 1992;23:393-399.
19. Schulz-Bongert J. Accelerated forced eruption as a preparatory measure for the restoration of severely damaged maxillary incisors: A case report. *Quintessence Int* 1991;22:425-430.
20. Rosenstiel SF, Land MF, Fujimoto J. Contemporary fixed prosthodontics, ed. 2. St. Louis: Mosby Year-Book;1995:241.
21. Messer HH, Wilson PR. Preparation for restoration and temporization. In: Walton RE, Torabinejad M, eds. Principles and practice of endodontics, ed. 2. Philadelphia: W.B. Saunders;1996:267.
22. Rosenstiel SF, Land MF, Fujimoto J. Contemporary fixed prosthodontics, ed. 2. St. Louis: Mosby-Year Book, Inc.;1995:238.

To order reprints of this article, contact Donna Bushore at 866.879.9144, ext. 156 or dbushore@fostereprints.com.

DART

Dental Article Review and Testing

Exercise No. 138 Subject Code: 250 Operative Dentistry

The 15 questions for this exercise are based on the article, "Rapid forced eruption: A case report and review of forced eruption techniques," on pages 167–175. This exercise was developed by Leslie A. Hayes, DDS, FAGD, in association with the *General Dentistry* DART Committee.

Reading the article and successfully completing this exercise will enable you to:

- evaluate root form and determine if remaining structure is adequate to perform forced eruption;
- determine whether fixed or removable devices are best for performing forced eruption;
- present the risks and potential outcomes of fixed partial denture placement, implant placement, and forced eruption with post and core placement and crown; and
- review other procedures needed after forced eruption to achieve desired esthetics.

Answer form and instructions are on pages 177-178.

- Compared to the loss of the natural root system, forced eruption offers which of the following advantages?
 - Adjacent tooth structure is maintained
 - Associated periodontal architecture is preserved
 - The option for future implant placement is retained
 - Preservation of buccal alveolar bone which otherwise may be traumatized or lost
 - 1, 2, and 3 only
 - 2, 3, and 4 only
 - 1, 2, and 4 only
 - 1, 2, 3, and 4
- What ancillary procedure often is necessary for improving esthetics after single tooth anterior implant placement?
 - Supercrestal fiberotomy
 - Orthodontic extrusion
 - Hard and soft tissue augmentation
 - Crown lengthening
- As with orthodontics, the main objective of forced eruption is to change the spatial position of the tooth in the arch while maintaining and preserving the root system and its healthy biologic width. Forced eruption can be done over months or within a few weeks.
 - Both statements are true.
 - The first is true; the second is false.
 - The first is false; the second is true.
 - Both statements are false.
- Which of the following statements regarding extrusion is false?
 - Compensatory growth of the bone and soft tissue will result if the root is extruded slowly.
 - Slow extrusion may require recontouring bone and soft tissue.
 - Eruption outpaces bone growth with rapid extrusion.
 - Rapid eruption provides substructure for interdental papillae.
- Which of the following items is not one of the four phases of forced eruption?
 - Case selection and root amputation
 - Application of appropriate eruptive force
 - Stabilization of extruded root system
 - Prosthetic restoration of the root
- Which of the following measurements is not included in biologic width?
 - 1.07 mm for connective tissue attachment above crestal bone
 - 0.97 mm for epithelial attachment
 - 0.69 mm for gingival sulcus
 - 2.73 mm for coronal tooth structure
- Which of the following conditions need not be considered when evaluating root health?
 - The presence of Class II bone
 - A periapical area free of disease
 - A root system free from resorptive processes
 - A well-condensed, apically sealed root canal
- Fixed and removable extrusion devices both seek to apply how many grams of eruptive force?
 - 5–10
 - 15–20
 - 25–30
 - 35–40
- A tooth that has been extruded 3.0 mm must be stabilized for how many weeks?
 - 4
 - 8
 - 12
 - 16
- Which of the following statements regarding root form is false?
 - A broad mesial-distal root form at the point of fracture affords the most esthetic results.
 - A tapered root in the zone of eruption will produce a narrow neck on the final crown, improving emergence profile and esthetics.
 - A wide pulp canal form has the potential to collapse and/or split the root upon post placement.
 - The canal preparation should be no greater than one-third of the total mesial-distal root width.
- Which of the following statements is not true when reconstructing following forced extrusion?
 - Biologic width must be established.
 - The final restoration may be placed immediately following stabilization.
 - Tissue removal can occur along with post and core fabrication.
 - The marginal gingival height must be compared with that of adjacent teeth and hard and soft tissues recontoured as needed.
- Forced eruption usually takes six to eight months to complete. This time is related directly to the length of the root.
 - Both statements are true.
 - The first is true; the second is false.
 - The first is false; the second is true.
 - Both statements are false.
- Which of the following effects would not be observed if biologic width were violated?
 - Chronic gingival inflammation
 - Lack of retention form
 - Lack of resistance strength
 - A restorative margin ending well above the depth of the gingival sulcus
- Forced eruption requires attention to and application of which of the following principles?
 - Endodontic
 - Periodontic
 - Prosthodontic
 - Esthetic
 - 1, 2, and 3 only
 - 2, 3, and 4 only
 - 1, 2, and 4 only
 - 1, 2, 3, and 4
- Which of the following statements is false?
 - Younger patients tend to have root systems that have suffered fewer cumulative traumas.
 - Following forced eruption, high lip lines that expose more gingival surface require less care and attention to the periodontal architecture.
 - The patient's age, motivation, and dental history of the root system all must be considered.
 - A patient must be of such a psychological demeanor that the esthetics of the device during the eruptive process presents them with no great concern.