

# BIOL 2210L

## Unit 11: Cranial Nerves, Spinal Cord, and Reflexes

Authors: Terri Koontz and Anna Gilletly, CNM Biology Department

[Creative Commons Attribution-NonCommercial 4.0 International License](#)

### Terms to Know for Unit 11

#### Cranial Nerves

Olfactory nerve

    Olfactory bulb

    Olfactory tract

Optic nerve

    Optic chiasma

    Optic tract

Oculomotor nerve

Trochlear nerve

Trigeminal nerve

Facial nerve

Vestibulocochlear nerve

Glossopharyngeal nerve

Vagus nerve

Accessory nerve

Hypoglossal nerve

#### Spinal Cord

Conus medullaris

Cauda equina

Gray matter

    Posterior horn

    Anterior horn

Central canal

Dorsal root

    Dorsal root ganglion

Ventral root

Spinal nerves

White matter

Filum terminale

Anterior median fissure

Posterior median fissure

#### Meninges

Epidural space

Dura mater

Arachnoid mater

Subarachnoid space

Pia mater

#### Reflex arc

Receptor

Sensory neuron

Afferent pathway

Integration Center

Interneuron

Motor neuron

Effector

#### Patellar reflex

Patellar ligament

Femoral nerve

Quadriceps femoris

Hamstrings

#### Additional Instructor Terms

### Learning Objectives (modified from [HAPS learning outcomes](#))

1. Structure & function of cranial nerves

- a. List and identify the cranial nerves by name and number.
  - b. Describe the specific functions of each of the cranial nerves and classify each as sensory, motor or mixed.
  - c. Identify the foramina that the cranial nerves pass through within the skull.
2. Anatomy of the spinal cord
    - a. Describe the gross anatomy of the spinal cord.
    - b. Identify the anatomical features seen in a cross sectional view of the spinal cord
    - c. Identify the dorsal root ganglia, dorsal and ventral roots, and spinal nerves.
3. Reflexes & their roles in nervous system function
    - a. Define the term reflex.
    - b. Describe reflex responses in terms of the major structural and functional components of a reflex arc.
    - c. Demonstrate a stretch reflex (e.g., patellar)
    - d. Propose how specific reflexes would be used in clinical assessment of nervous system function.

## Explanation of Anatomy

In this lab we begin with learning the twelve paired cranial nerves, where they are located and their functions. While learning the cranial nerves we'll revisit the skull and identify where each of the cranial nerves pass through the skull. Next, we'll explore the major components of the spinal cord and describe what happens during a reflex arc. We'll finish with applying knowledge of a reflex arc to what happens during the patellar reflex.

Think about how nerve and spinal cord damage can cause dysfunction. One paired cranial nerve, the trigeminal nerve, causes severe pain when constant pressure is applied to it, but if removed on one side will cause that side of the face to feel numb. Damage to the spinal cord can cause paralysis of limbs. Think about how clinical application of our understanding of cranial nerves, the spinal cord, and reflexes, help determine the severity and location of damaged areas within our nervous system. With this information, and as we continue to learn more about how our bodies function, practitioners can provide better treatment.

## Cranial Nerves

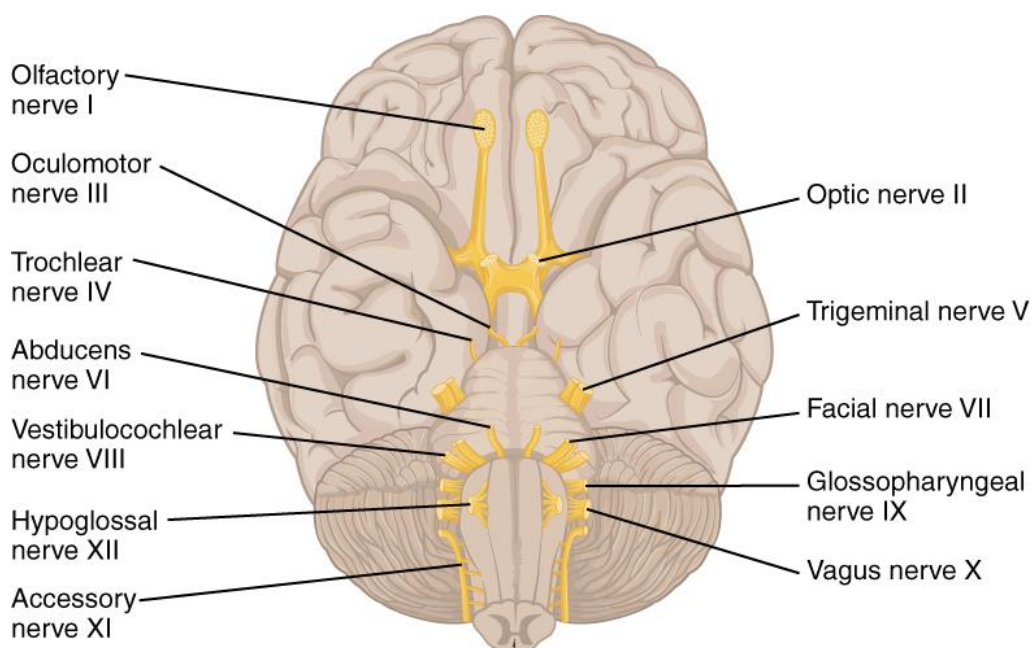
There are twelve paired **cranial nerves** (see Image 1). Nine of the paired cranial nerves branch from the brainstem, two paired cranial nerves branch from the forebrain (optic and olfactory), and one cranial nerve (accessory) emerges from the spinal cord but travels up to the brainstem and passes through the skull with the other cranial nerves. Unlike spinal nerves, not all cranial nerves have both sensory and motor neurons within their structure. Some cranial nerves only have a sensory function like the **optic nerves** that are involved with vision whereas other cranial nerves only have a motor function like the **oculomotor nerves** that are involved with eye movements. Two paired cranial nerves, **accessory nerves** and **hypoglossal nerves**, have some sensory function but are mainly motor. The accessory nerves control motor function for the sternocleidomastoid and trapezius muscles and the hypoglossal nerves control tongue movement.

There are four paired cranial nerves that are mixed nerves with a complex mix of sensory and motor functions: trigeminal, facial, glossopharyngeal and vagus nerves. The **trigeminal nerves'** sensory function involves detecting skin sensations and its motor function involves activating muscles for mastication

(chewing). The **facial nerves'** sensory function allows us to taste food and their motor function allows us to make facial expressions. **Glossopharyngeal nerves'** sensory function monitors carbon dioxide and oxygen blood levels to help regulate breathing and the motor function helps with swallowing. The last of the mixed nerves is the **vagus nerve** that monitors and controls viscera within the ventral body cavity using both sensory and motor neurons. Heart rate, breathing, and digestive system processes are regulated by the vagus nerves.

The olfactory and optic nerves have additional structures that you'll learn in this lab. The **olfactory bulb** is where the olfactory nerve neurons synapse with olfactory tract neurons. The olfactory bulb, along with the olfactory tract, are brain structures. The axons of the olfactory nerve are structures of the PNS. The **olfactory tract** is a bundle of axons that originate within the olfactory bulb.

Like the olfactory nerve and its "bulb", the optic nerve travels from outside the cranial cavity and will create a notable structure, the optic chiasma. Axons of the optic nerve cross over forming an "X" like structure, which is the **optic chiasma**. After the optic chiasma, the name of the bundled axons will change to **optic tracts** as those fibers move toward the thalamus of the brain. Since the optic nerve and its structures are brain outgrowths, they are visible PNS structures within the cranial cavity.



*Image 1: Cranial nerves*

[Creative Commons Attribution 4.0 International](#) Openstax URL: [Cranial nerves](#)

Listed in the following table are the twelve paired cranial nerves in the order that they branch from the forebrain, brain stem, and spinal cord. The paired cranial nerves are listed using Roman numerals and by name. For example, the optic nerve is also called the second cranial nerve and can also be called "cranial nerve II." In addition, next to each paired cranial nerve are their functions followed by where they pass through the skull.

<b>Nerve #</b>	<b>Name</b>	<b>Neuron type</b>	<b>Function</b>	<b>Skull feature</b>
I	Olfactory	Sensory	Sense of smell	cribriform plate
II	Optic	Sensory	Sense of sight	optic canal
III	Oculomotor	Motor	Movement of most voluntary eye muscles and involuntary muscles of the iris that control the size of the pupil	superior orbital fissure
IV	Trochlear	Motor	Controls a single extrinsic muscle of the eye that allows for eyeball movement	superior orbital fissure
V	Trigeminal	Sensory and Motor	Touch perception for skin of the face and movement for muscles involved with mastication	superior orbital fissure, foramen rotundum, and foramen ovale
VI	Abducens	Motor	Controls a single extrinsic muscle of the eye that allows for eyeball movement	superior orbital fissure
VII	Facial	Sensory and Motor	Senses taste from taste buds, movement of muscles involved in facial expressions, and controls secretions of lacrimal and salivary glands	internal acoustic meatus
VIII	Vestibulocochlear	Sensory	Sense of balance, equilibrium, and hearing	internal acoustic meatus
IX	Glossopharyngeal	Sensory and Motor	Involved with chemoreceptors and pressure receptors of carotid artery and movement for pharyngeal muscles used in swallowing	jugular foramen
X	Vagus	Sensory and Motor	both sensing and movement for visceral organs within thoracic and abdominopelvic body cavities	jugular foramen
XI	Accessory	Mainly motor	Movement of sternocleidomastoid and trapezius muscles	jugular foramen
XII	Hypoglossal	Mainly motor	Movement of tongue muscle	hypoglossal canal

Table 1: Cranial nerves, their functions, and skull features that they pass through

---

*Mini Activity: Functions of some cranial nerves*

---

Match the cranial nerve with its function.

- |                             |  |
|-----------------------------|--|
| 1. Trigeminal (V)           | A. Facial expressions and taste        |
| 2. Facial (VII)             | B. Tongue movement                     |
| 3. Hypoglossal (XII)        | C. Blood gas regulation and swallowing |
| 4. Glossopharyngeal (IX)    | D. Skin sensation and mastication      |
| 5. Vagus (X)                | E. Sternocleidomastoid movement        |
| 6. Olfactory (I)            | F. Vision                              |
| 7. Optic (II)               | G. Moves the eyeball                   |
| 8. Vestibulocochlear (VIII) | H. Smelling                            |
| 9. Oculomotor (III)         | I. Hearing                             |
| 10. Accessory (XI)          | J. Controls visceral organs            |

There are two cranial nerves that are not listed above, but are involved with “moving the eyeball”.

What are the names of those two cranial nerves?

- a.
- b.

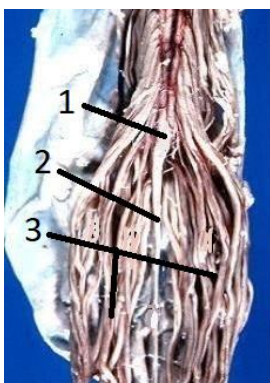
You can come up with your own mnemonic to learn the order of the cranial nerves or you can use the one below:

“O, O, O, To, Touch, And, Feel, Very, Good, Velvet, A, H”

**O**lfactory, **O**ptic, **O**culomotor, **T**rochlear, **T**rigeminal, **A**bducens, **F**acial, **V**estibulocochlear, **G**lossopharyngeal, **V**agus, **A**ccessory, **H**ypoglossal

### Spinal Cord

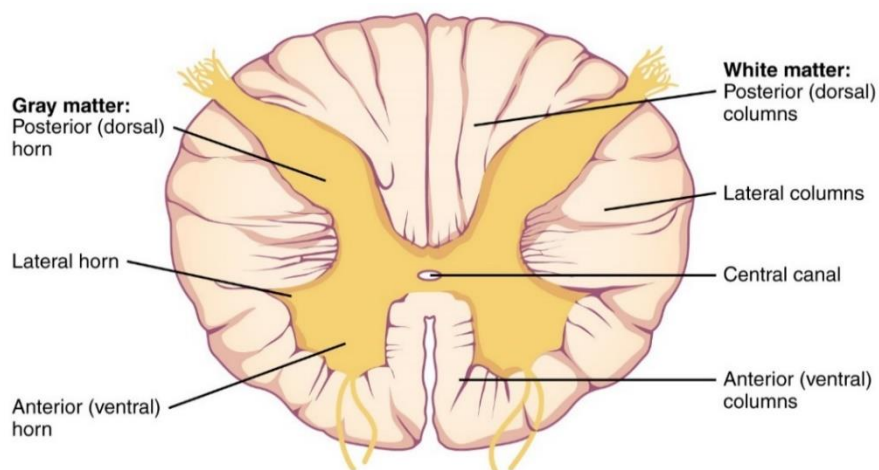
The spinal cord travels through the vertebral foramina that make up the vertebral body cavity. The inferior portion of the spinal cord tapers forming a structure called the **conus medullaris**. An anchoring structure called the **filum terminale** (extension of the pia mater) connects the conus medullaris to the coccyx, allowing the spinal cord to maintain its position during body movements. Also, the inferior end of the spinal cord has many spinal roots emerging that look like a horse’s tail and as a group are named the **cauda equina**. *Cauda* means tail and *equina* means horse. The reason for these long roots at the end of the spinal cord is because the vertebral column develops faster than the spinal cord, making it so that spinal nerves chase from where they exit the dorsal body cavity as the body grows from a fetus to a young child. Because of this “chasing” and stretching, the cauda equina is the one place where spinal nerves are found within the vertebral body cavity; on the more superior portions of the spinal cord, the name doesn’t change to spinal nerve until the sensory and motor roots bundle together their axons as they emerge from the intervertebral foramen. Image 2 depicts inferior structures of the spinal cord.



*Image 2: Spinal cord- 1. Conus medullaris, 2. Filum terminale, 3. Cauda equina*

Modified [CC BY 2.5](#) by John A Beal, PhD URL: [Spinal cord](#)

A cross section of the spinal cord shows its functional areas (see Image 3). The center of the cross section is the **central canal** that contains cerebrospinal fluid. Surrounding the central canal is **gray matter** in the shape of a butterfly. Gray matter in the CNS is made up of neuronal cell bodies and nonmyelinated neurons. The “wings” of the gray matter are called horns and it is within those horns that neurons communicate to one another. The **posterior horns** of the spinal cord allow for sensory neurons to send information to interneurons. The **anterior horns** of the spinal cord’s gray matter allow for information to travel to motor neurons. Pay attention to those locations. Interneurons are commonly found in the space between the two horns. The **white matter** surrounding the gray matter are myelinated fiber tracts (see definition of tract above); the whiter color is due to the myelin sheath.



*Image 3: Cross section of spinal cord*

Cropped [Creative Commons Attribution 4.0 International](#) Openstax URL: [Cross section of spinal cord](#)

Folds of the white matter are named based on their location and their depth. A deep fold is called a fissure and a shallow fold is called a sulcus. The deep anterior fold in the middle is called the **anterior median fissure** whereas the shallow posterior fold in the middle is called the **posterior median sulcus**.

As information is being sent to and away from the spinal cord, axons of neurons transition from being located within the PNS to the CNS or within the CNS to the PNS. When the axons are within the PNS, they are called roots or nerves. Incoming information along the axons of sensory neurons travels

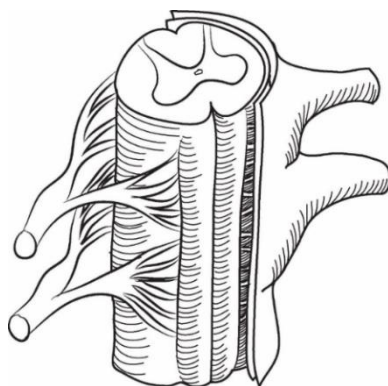
through the **dorsal root** where sensory neuronal axon terminals communicate with dendrites and cell bodies of interneurons within the posterior horn. The cell bodies of sensory neurons are in the **dorsal root ganglion**. The dorsal root ganglion is a noticeable bulge of PNS nervous tissue that can help orient what are posterior versus anterior spinal cord structures. As information is being sent to motor neurons that originate in the anterior horn of the spinal cord, the axons of these motor neurons enter the PNS via a **ventral root**. The dorsal and ventral roots merge at the intervertebral foramen to form a spinal nerve that contains both sensory and motor neuronal axons. The ventral and dorsal roots are located inside the vertebral foramen and once they pass through the intervertebral foramina (mixing sensory and motor axons), the name of the roots changes to spinal nerves. To be clear, except for the cauda equina, no “nerves” are found inside the vertebral cavity.

---

*Mini Activity: Label roots and spinal nerves*

---

1. In the drawing below, label the following: A. ventral root, B. dorsal root, C. spinal nerve



*Image 4: Drawing of spinal cord*

[CC BY 2.0 by Prof Alice Roberts](#) URL: [Drawing of spinal cord](#)

2. Now, look at a skeleton in the classroom and if available a vertebra. Find the following openings.

Intervertebral foramen

Vertebral foramen

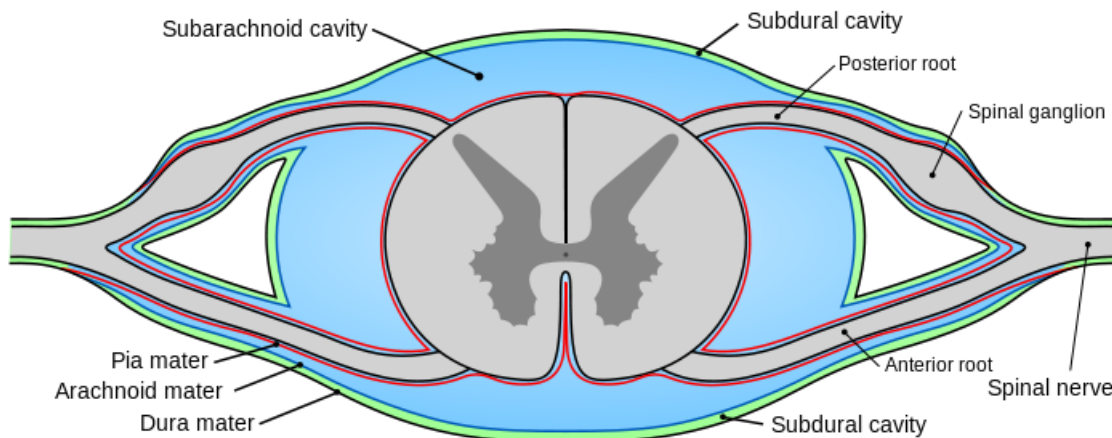
3. What is the significance of those two structures, the intervertebral foramen and the vertebral foramen, regarding the spinal cord and its nerves?

### Meninges

Meninges protect the CNS, both the brain and the spinal cord. There are three layers of meninges. Going from superficial to deep, the meninges are the dura mater, arachnoid mater, and pia mater (see Image 5). *Dura-* means tough and *mater* means mother, making the **dura mater** the toughest of all the meningeal layers. *Arachnoid* means spiderlike and the **arachnoid mater** is named because it contains



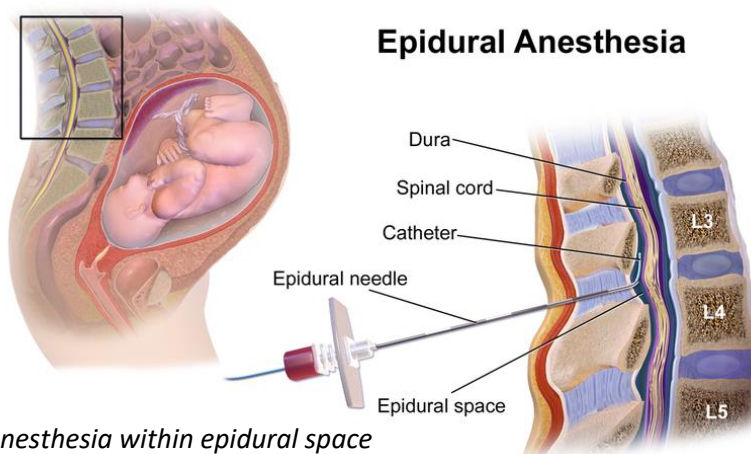
connective tissue fibers that look like a spider web. These web-like fibers connect the arachnoid mater to the pia mater. The **pia mater** directly attaches to and cradles the nervous tissue of the CNS. The word pia means delicate or gentle; pia mater is the gentle mother. Both the brain and spinal cord are surrounded by all three meninges. We will revisit the meninges again when we study brain anatomy.



*Image 5: Meninges of spinal cord*

[public domain by Mysid who modified a Henry Vandyke Carter drawing URL: Meninges of spinal cord](#)

There are two spaces among the meninges that you need to know. The **subarachnoid space** is the space between the pia and arachnoid maters where cerebrospinal fluid circulates around the outside of the brain and spinal cord (see Image 5). The **epidural space** is superficial to the dura mater between the bone and dura mater membrane (see Image 6). Adipose tissue is packed within the epidural space to absorb shock from blunt trauma to the head and torso. The epidural space also contains blood vessels, nerves, and lymphatic vessels. As a result, it is a common location for bleeding and swelling, especially in the head. It is also a convenient location to deliver anesthetic for some types of surgical procedures. This is commonly referred to as an “epidural.” Anesthetic is injected into that space because the medication can gently diffuse and numb sensory and/or motor nerve fibers without circulating through the cerebrospinal fluid. Epidural steroid injections are another type of treatment used to treat back pain.



*Image 6: Epidural anesthesia within epidural space*

[Creative Commons Attribution-Share Alike 4.0 International by BruceBlaus URL: Epidural anesthesia within epidural space](#)



## Reflex Arc

You already know the basic components of a reflex arc. It is the same components that make up the control system used in maintaining homeostasis. There are five components to a reflex arc.

1. **Receptor**– Detects a stimulus
2. Afferent pathway– **Sensory neurons** send information to the control center via a nerve
3. Control center– The **integration center** is the area in the CNS where **interneurons** receive information and send information to motor neurons.
4. Efferent pathway– **Motor neurons** send information from the control center to an effector via a nerve
5. **Effector**– Muscles or glands that receive information to provide a response (contraction or secretion)

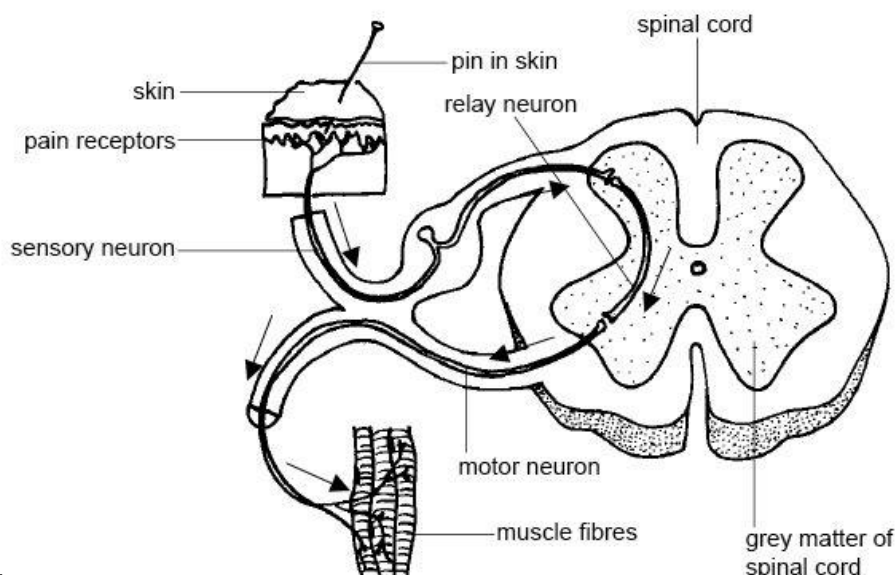


Image 7: Reflex arc

CC BY 3.0 by Ruth Lawson Otago Polytechnic URL: [Reflex arc](#)

---

### Mini Activity: "Label" components of a reflex arc

---

In Image 7, some components of the reflex arc aren't identified. Circle or highlight the anatomic structure that correctly corresponds to the missing components. It is recommended that you use different colored pencils or pens to highlight the missing components:

- **Blue**-Afferent Pathway,
- **Green**-Control Center,
- **Pink**-Efferent Pathway, and
- **Red**-Effector.

For example, highlight or circle the **sensory neuron in blue** to indicate that it is part of the **Afferent Pathway**.

## Patellar Reflex

The patellar reflex is an example of a reflex arc that has its integration center within the spinal cord (see Image 8). To initiate the patellar reflex the **patellar ligament** (patellar tendon) is tapped when a person is sitting dangling their legs from a table or chair. When the ligament is tapped it stretches, causing the **quadriceps femoris** muscles to lengthen or be stretched as well. This stretch of the quadriceps femoris muscles are detected by special sensory receptors called muscle spindles. Muscle spindles are proprioceptors (a type of mechanoreceptor) within whole muscles that detect when a muscle is stretched, lengthened. These muscle spindles are associated with dendrites of sensory neurons that will send the message to the spinal cord. Motor neurons directly receive the message within the anterior horn of the spinal cord at the lumbar region. These motor neurons continue the reflex arc by sending information along their efferent axons within the **femoral nerve** to excite quadriceps femoral muscles to contract, causing knee extension. In addition, sensory neurons are also communicating to interneurons in the posterior horn. The posterior horn interneurons inhibit different motor neurons that cause relaxation of three muscles commonly known as the **hamstring** muscles. This prevents the antagonizing movement of knee flexion during the patellar reflex.

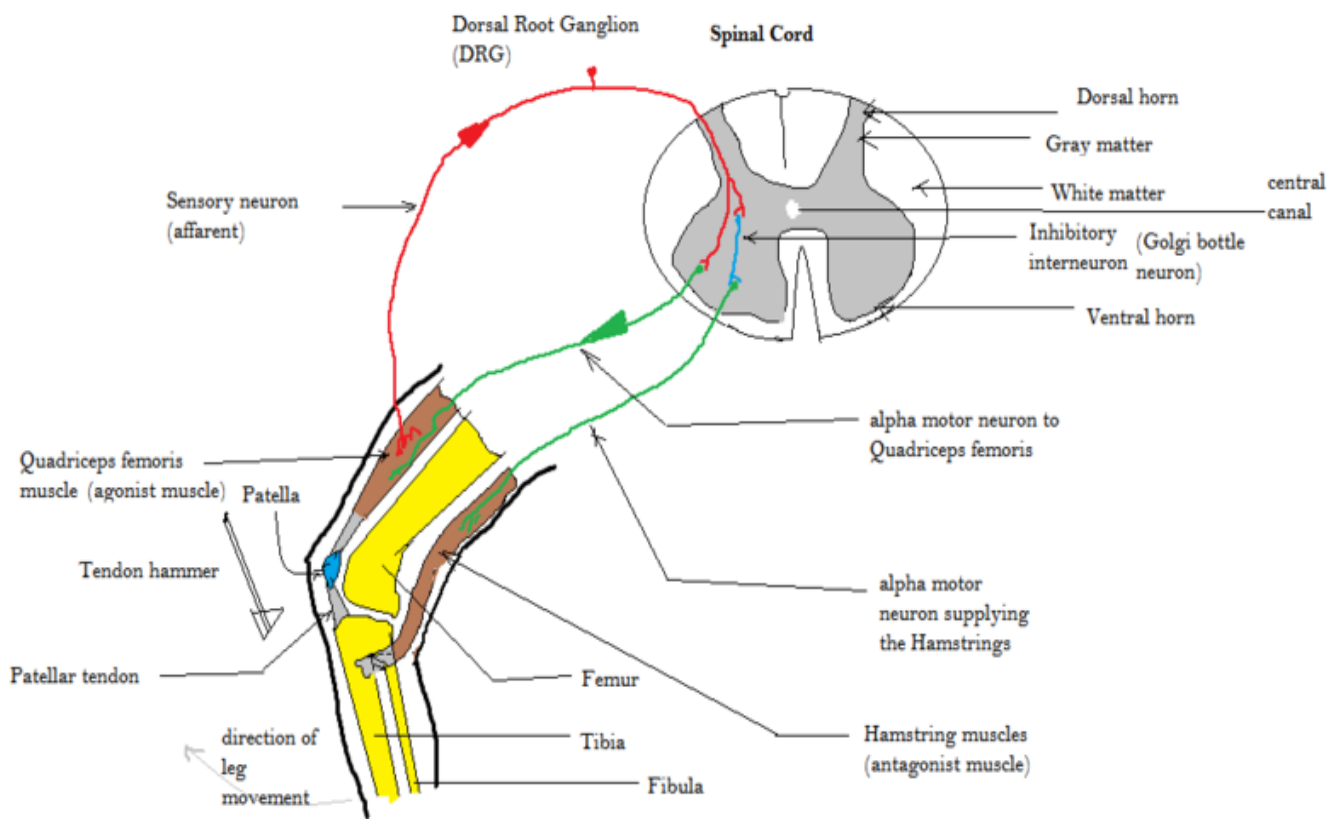


Image 8: Patellar Reflex

[Creative Commons Attribution-Share Alike 4.0 International](#) by [Amiya Sarkar](#) URL: [Patellar Reflex](#)

[Click Here](#) to watch a short demonstration of the patellar reflex.

---

*Mini Activity: Quadriceps femoris and hamstring muscles*

---

1. Below list the four muscles that make up the Quadriceps Femoris.

- a.
- b.
- c.
- d.

2. Now list the three muscles that make up the Hamstrings.

- a.
- b.
- c.

## Activity 1: Identifying and Labeling Cranial Nerves

**Part 1** -Using the models set up in the lab, identify the following cranial nerves and structures:

- a. optic nerve b. oculomotor c. trochlear d. trigeminal e. abducens f. facial g. vestibulocochlear
- h. glossopharyngeal i. vagus j. accessory k. hypoglossal l. olfactory bulb m. olfactory tract
- n. optic chiasma o. optic tract

It is recommended that you use painter's tape provided in the lab to label the above nerves and structures on the model. If you use the provided letters, you'll have a key to test your knowledge after labeling.

Use the space below to sketch out the cranial nerves and their structures.

## Part 2 - Test your knowledge on cranial nerve function.

1. What cranial nerves are strictly sensory and what is the sensory function of each of those nerves?
  
2. What cranial nerves are mixed nerves and what is the sensory and motor functions of each of those nerves?
  
3. List cranial nerves that move the skeletal muscle of the eyeball.
  
4. List the cranial nerve that controls the smooth muscle of the eye's iris?

## Activity 2: Labeling Skull Features Where Cranial Nerves Pass

Using the provided pipe cleaners in the classroom, label the following skull bone features.

- a. optic canal b. superior orbital fissure c. foramen rotundum d. foramen ovale  
 e. jugular foramen f. hypoglossal canal

Match the foramen with the cranial nerves that travel through them. Next to the lettered bone feature, write the number given to the cranial nerves listed to the right.

- |                                  |                          |
|----------------------------------|--------------------------|
| a. optic canal_____              | 1. Optic (II)            |
| b. superior orbital fissure_____ | 2. Oculomotor (I)        |
| c. foramen rotundum_____         | 3. Trochlear (IV)        |
| d. foramen ovale_____            | 4. Trigeminal (V)        |
| e. jugular foramen_____          | 5. Abducens (VI)         |
| f. hypoglossal canal_____        | 6. Facial (VII)          |
|                                  | 7. Glossopharyngeal (IX) |
|                                  | 8. Vagus (X)             |
|                                  | 9. Accessory (XI)        |
|                                  | 10. Hypoglossal (XII)    |

Two cranial nerves and their associated skull structures are missing from the lists above. What are those cranial nerves and their associated skull structures?

- a. Name of cranial nerves:                      b. The structures associated with those two cranial nerves:

## Activity 3: Identifying Spinal Cord Structures

**Part 1** - Using the models set up in the lab, identify the following spinal cord structures.

Use painter's tape provided in the lab and label the listed structures below on the models.

- a. conus medullaris b. cauda equina c. posterior horn d. anterior horn e. dorsal root ganglion  
f. epidural space g. subarachnoid space

**Part 2**- Test your knowledge on spinal cord structures by matching a description to its corresponding structure.

- |                              |   |
|------------------------------|---|
| a. conus medullaris ____     | 1. Gray matter that contains cell bodies of motor neurons     |
| b. cauda equina ____         | 2. Gray matter that contains cell bodies of interneurons      |
| c. posterior horn ____       | 3. PNS structure that contains cell bodies of sensory neurons |
| d. anterior horn ____        | 4. Area where cerebrospinal fluid is located                  |
| e. dorsal root ganglion ____ | 5. Area where fatty tissue is located                         |
| f. epidural space ____       | 6. End of the spinal cord                                     |
| g. subarachnoid space ____   | 7. Spinal nerves that are within the vertebral cavity         |

**Part 3** – Pick at least three structures above and describe their location and how they function within the nervous system.

For example, if the filum terminale was listed above you could describe its function as stabilizing the spinal cord during movement, but you would describe its location as attaching the spinal cord to the coccyx bone.

## Activity 4: Testing Reflexes

Use the medical hammer that is available in the lab and test a lab partner's patellar reflex.

1. One partner sits with their feet dangling.
  2. Once your partner is relaxed, gently tap on their leg where the patellar ligament is located.
  3. Write below what you observe.
- 
4. Why do doctor's test the patellar reflex?
- 
5. The patellar reflex is a stretch reflex. Now pick either a flexor (withdrawal) reflex or a cross-extensor reflex and complete a web search to learn more about it. From your web search explore the following:
    - a. Outline, draw, or describe the components of the reflex.
- 
- b. Why would a doctor test that reflex?