



University of New Mexico  
Orthopaedics Research  
Journal





**University of New Mexico  
Orthopaedics Research Journal**

Volume 2  
June 2013

**Co-Chief Editors**

Elizabeth Szalay, MD  
Robert Schenck, Jr. MD

**Managing Editor**

Kimberly Fields

**Editorial Assistant**

Joni Roberts

**Layout Editor**

Alexa Voshell

**Copy Editor**

Aditi Majumdar

**With thanks to:**

Rachel Baeza  
Jaqueline Bickel  
James Burbank  
Katharine Carillo  
Zachary Child, MD  
Mary Jacintha  
Rebecca Maher  
Angela McBride  
Sarah Melendez  
EL Pallai  
Scott Waters  
Ryan Wood

Sandia Orthopaedics Alumni Society (SOAS) provides services that enhance and enrich the educational experience of current residents and fellows in orthopaedics training at UNM. With more than 40 years of alumni to call on, SOAS is a vital and dynamic contributor to the program. We thank them for their generous support of the *University of New Mexico Orthopaedics Research Journal*.

Published by the Regents of the University of New Mexico  
All rights revert to author(s) upon publication  
ISSN 2167-4760

Department of Orthopaedics and Rehabilitation  
University of New Mexico  
MSC10 5600  
1 University of New Mexico  
Albuquerque, NM 87131  
505.272.4107

Printed by Starline Printing  
7111 Pan American West Freeway N.E.  
Albuquerque, NM 87109  
505.345.8900  
[www.starlineprinting.com](http://www.starlineprinting.com)

# Table of Contents

I.	Report from the Chair.....	7
II.	Letter from the Co-Editors.....	8
III.	Department of Orthopaedic Surgery Faculty.....	10
IV.	Department of Orthopaedic Surgery Fellows, Chiefs, and Residents.....	13
V.	Physical Therapy Faculty.....	16
VI.	Research Awards and Research Assistants.....	17
VII.	Report from the Residency Director.....	18
VIII.	Chief Resident Education	
	Hand Dominance Versus Stick Dominance in Youth Hockey .....	19
	<i>Owen Ala MD, Lee Swiderek BS, Eric Benson MD</i>	
	Long Head of Biceps Tendon.....	21
	<i>Lex Allen MD</i>	
	The Evolution of the Femoral Stem Design in Total Hip Arthroplasty .....	24
	<i>Dustin Briggs MD</i>	
	Management of Pediatric Femur Shaft Fractures .....	26
	<i>Aaron Dickens MD</i>	
	Chronic Injuries Due to Running and a Possible Cure with the Barefoot Style.....	31
	<i>Daniel M. Hoopes MD</i>	
IX.	Report from the Division of Physical Therapy.....	37
X.	sDPT Abstracts	
	Pressure Garment Therapy and Hypertrophic Burn Scars: A Case Study and Evidence-Based Analysis	
	<i>Hayley Davis sDPT</i> .....	38
	Will Lower Extremity Strengthening Be Beneficial for Ambulation in Patients with Guillain-Barré Syndrome?	
	A Case Study	
	<i>Bernadette Frigerio sDPT</i> .....	39
	Rehabilitation of a Patient with West Nile Virus and Associated Sequelae	
	<i>Vanessa Garcia sDPT</i> .....	40
	Does Hippotherapy Improve Gross Motor Function in Children with Cerebral Palsy?	
	<i>Rachel Y. Maestas sDPT</i> .....	41
	The Effects of Platelet-Rich Plasma Injections on Patellar Tendinopathy	
	<i>Shyla Mesch sDPT</i> .....	42
	The Efficacy of Orthoses Wear in a Patient with Sacral Level Myelomeningocele: A Case Report and Evidence-Based Analysis	
	<i>Krista Riebli sDPT</i> .....	43
	Multiple Sclerosis and Urinary Incontinence: A Case Study of Pelvic Floor Training and Postural Interventions	
	<i>Tara McCarthy Sanford sDPT</i> .....	44
XI.	Research Article	
	Medium- and Long-Term Radiographic Evaluation of Survivorship of Pegged Versus Keeled Glenoid Components.....	45
	<i>Matthew Ferguson MD, Daniel L. Aaron MD, Penelope Lang MD, Alexis Colvin MD</i>	

XII.	Case Report	
	Dorsal Intercarpal Ligament Instability Deformity Following Resection Arthroplasty of the Scaphotrapezotrapezoidal Joint .....	50
	<i>Moheb Moneim MD, Deana Mercer MD</i>	
XIII.	Original Articles	
	Glomus Tumor of the Upper Extremity: An Under-Recognized Cause of Pain .....	52
	<i>Dean W. Smith MD</i>	
	Narrative Medicine: A Pilot Program Integrating Creative Writing Pedagogy into Orthopaedic Medical Education .....	55
	<i>EL Pallai MFA, Caitlin Armijo BS</i>	
	The Orthopaedic Trauma Association Fracture Classification for Publications and Routine Daily Use .....	59
	<i>Thomas DeCoster MD</i>	
	What Are the Benefits to Orthopaedic Residents of Understanding Research Methodology .....	65
	<i>Deana Mercer MD</i>	
	Posterolateral Corner Injuries of the Knee .....	67
	<i>Benjamin C. Olson DO, Robert C. Schenck, Jr. MD, Daniel C. Wascher MD</i>	
	PCL Reconstruction: A Comparison of Techniques .....	74
	<i>Dustin L. Richter MD, Daniel C. Wascher MD, Robert C. Schenck, Jr. MD</i>	
	Damage Control Orthopaedics 2013.....	79
	<i>Urvij Modhia MD</i>	
	The Perry Initiative .....	83
	<i>Christina Salas MS, Deana Mercer MD</i>	
XIV.	University of New Mexico Department of Orthopaedic Surgery Alumni.....	84
XV.	Journal Submissions.....	86

# Report from the Chair

I'm pleased to present the second edition of the University of New Mexico Orthopaedics Research Journal. As the only academic orthopaedics training program in the state, we provide service and information that benefit the people of New Mexico and the community of orthopaedic practitioners who care for them, something we've done with distinction for 44 years now. One of the ways we accomplish this goal is through sharing orthopaedic information with our many partners in New Mexico and the Southwest. I'm proud to give you this report of some of what we've done in the past year.

Our faculty continued to grow. We welcomed Dr. Brad Blankenhorn, Dr. David Chafey, and Dr. John Austin this year. Brad is a foot and ankle specialist who came to us after med school at the University of Pittsburgh and fellowships at Brown University and the University of Utah. David is dually appointed to orthopaedics (trauma service) and the Cancer Center. He did fellowships at Sonoran Orthopaedic Trauma Surgeons in Arizona and at MD Anderson Cancer Center in Texas. John is practicing sports medicine and general orthopaedic surgery exclusively at Sandoval Regional Medical Center. He trained at the University of Michigan and did a fellowship at Cincinnati SportsMedicine and Orthopaedic Center. We're glad to have such fine new partners.



Robert C. Schenck, Jr. MD

We wish our senior residents well as they end this phase of their careers and begin new ones. Owen Ala is leaving for a hand fellowship at the University of Pennsylvania in Philadelphia. Aaron Dickens is going to the University of California San Diego for a trauma fellowship. Lex Allen will do a hand and upper extremity fellowship in Australia at the Brisbane Hand and Upper Extremity Research Institute. Dan Hoopes is going to the University of Washington in Seattle for a foot and ankle fellowship. Dustin Briggs will start a lower extremity reconstruction fellowship at Scripps Clinic in San Diego. They all have contributions in this issue of the journal, something of which I am most proud.

I want to thank Dean Smith (Class of 2000) and all of our loyal alumni for their great efforts and support through the Sandia Orthopaedic Alumni Society. SOAS brings UNM's orthopaedic surgeon training program full circle for former and current residents, fellows, and faculty. We have two annual events each year to honor former residents hosted by SOAS. The Eric Thomas Memorial Golf Tournament is held each September in honor of Eric Thomas (Class of 2004). We see alumni from all over the country back in Albuquerque, on the UNM Championship Golf Course links enjoying the great fall weather. The first Joel Lubin Visiting Lectureship was held this spring to honor Joel Lubin (Class of 2001). Larry Marsh from the University of Iowa delivered the lecture. Mike Willis (Class of 2000) also gave a talk that was much appreciated by the residents.

The assistance of alumni becomes more important to the department every year. SOAS, created exclusively for graduates of our program, has a new lifetime membership available for a pledge of \$25,000, \$5,000 each year for 5 years. I'm a proud donor and lifetime member of SOAS, and invite you to join me in becoming one, too. This is an exciting time to participate in the growth and success of UNM Orthopaedics.

# Letter from the Co-Editors

Greetings!

We welcome you to the second edition of the *University of New Mexico Orthopaedic Research Journal*, featuring research and educational efforts of UNM Department of Orthopaedics faculty, alumni, fellows, residents, and students.

Please explore further this selection of recent departmental publications:

Lecker SH, Zavin A, Cao P, **Arena R**, et al. Expression of the irisin precursor FNDC5 in skeletal muscle correlates with aerobic exercise performance in patients with heart failure clinical perspective. *CircHeartFailure*. 2012;5(6):812-818.

Martin BJ, Hauer T, **Arena R**, et al. Cardiac rehabilitation attendance and outcomes in coronary artery disease patients clinical perspective. *CirculationAHA*. 2012;126(6):677-687.

**Benson EC**, Athwal GS, King GJ. Clinical assessment of the elbow. In: Stanley D, Trail IA, eds. *Operative Elbow Surgery*. Edinburgh: Elsevier; 2012: 45-65.

Potter MQ, **Blankenhorn BD**, Avilucea FR, Beals TC. Osseous talofibular impingement after supination-external rotation stage II ankle fracture: case report. *Foot Ankle Int*. 2012;33(11):1006-1010.

**Chafey DH**, Deavers M, Moon BS. Chondroblastoma. *Orthopaedic Knowledge Online Journal*. 2012;10(9). Available at [http://orthoportal.aaos.org/oko/article.aspx?article=OKO\\_ONC025](http://orthoportal.aaos.org/oko/article.aspx?article=OKO_ONC025).

**DeCoster TA**. Low morbidity reported after iliac bone-graft harvesting [Commentary]. *J Bone Joint Surg*. 2012;94(18):e139 1-2.

Modhia UM, Dickens AJ, Glezos CD, **Gehlert RJ**, **DeCoster T**. Under-utilization of the OTA Fracture Classification in orthopaedic trauma literature. *Iowa Orthop J*. 2013;33. Available at <http://www.uiortho.com/images/stories/IOJ/IOJ2013.pdf>

Godfrey J. The ethics of a medical mission trip: a resident's reflections on a trip to Ecuador. *AAOS Now*. 2012;6(8). Available at <http://www.aaos.org/news/aaosnow/aug12/youraaos6.asp>.

Godfrey JM, Gines JL, McCarty EC. Comparison of computerized and paper versions of the Western Ontario Rotator Cuff (WORC) Index. *J Shoulder Elb Surg*. 2013;22(4):500-504.

Snyder, Warriner, **Hettrick H**. Is there a place for checklists in the current wound care model? *Wound Care and Hyperbaric Medicine*. 2012;3(2):30-35.

Bowen RE, Abel MF, Arlet V, ..., **Hoekstra DV**, et al. Outcome assessment in neuromuscular spinal deformity. *J Pediatr Orthop*. 2012;32(8):792-798.

McCord S. Development of an electronic handoff application tool to improve resident handoffs. *Journal of Quality Improvement in Healthcare*. 2013;2:38.

Hobby B, Moore K, Tripuraneni K, Richter D, **Schenck RC**. Knee dislocations, fracture-dislocations, and traumatic ligamentous injuries of the knee. In: Brinker MR, ed. *Review of Orthopaedic Trauma*. 2nd ed. Baltimore, MD: Lippincott Williams and Wilkins, 2013: 98-115.

**Schenck R**. The auction house. *Medical Muse*. 2012;17(2):45-46.

**Schenck R**. Billy Graham and the ice cream man. *Medical Muse*. 2013;18(1):10-13.

**Silva S**, Nowicki P, Caird, MS, Hurvitz EA, et al. A comparison of hip dislocation rates and hip containment procedures after selective dorsal rhizotomy versus intrathecal baclofen pump insertion in nonambulatory cerebral palsy patients. *J Pediatr Orthop*. 2012;32(8):853-856.

**Szalay EA**. Sexual dimorphism in musculoskeletal medicine. *Eur Musculoskel Rev*. 2012;7(3):162-164.

Johnson PL, **Szalay EA**. Relative osteopenia after femoral implant removal in children and adolescents. *Orthopedics*. 2013;36(4):e468-e472.

**Treme G**, **Schenck RC**. Medial ligamentous injuries of the knee: acute and chronic. In: Scott WN, ed. *Insall & Scott Surgery of the Knee*. 5th ed. Philadelphia PA: Elsevier, 2012: 348-355.


Rust DA, Gilmore CJ, **Treme G**. Injury patterns at a large western United States ski resort with and without snowboarders: the Taos experience. *Am J Sports Med*. 2013; 41(3):652-656.

Hobby BD, **Wascher DC**, **Schenck RC**. Classification of knee dislocations and the surgical implications. In: Fanelli GC, ed. *The Multiple Ligament Injured Knee: A Practical Guide to Management*. New York: Springer; 2013: 63-69.

Natividad, TT, **Wascher DC**. Complications associated with the treatment of the multiple ligament injured knee. In: Fanelli GC, ed. *The Multiple Ligament Injured Knee: A Practical Guide to Management*. New York: Springer; 2013: 443-450.

We invite you to peruse these offerings, and hope that they inspire thought and discussion, as well as future research ideas and contributions.

Sincerely,



Elizabeth Szalay MD  
Co-Editor



Robert C. Schenck, Jr. MD  
Co-Editor



# Department of Orthopaedic Surgery Faculty



**John Austin MD**-Assistant Professor  
Medical Degree: University of Michigan Medical School  
Residency: University of Michigan  
Fellowship: Cincinnati Sports Medicine and Orthopaedic Center  
Clinical Expertise: Shoulder/Knee Arthroscopy, Sports Medicine, Knee/Shoulder/Hip Arthroplasty



**David Chafey MD**-Assistant Professor  
Medical Degree: Ponce School of Medicine, Puerto Rico  
Residency: Baylor College of Medicine  
Fellowship: Trauma, Sonoran Orthopaedic Trauma Surgeons, Scottsdale, AZ;  
Musculoskeletal Oncology, University of Texas MD Anderson Cancer Center  
Clinical Expertise: Limb Salvage, Pelvic Reconstruction, Metastatic Disease to Bone



**Jeremy Becker MD**-Assistant Professor  
Medical Degree: Albany Medical College  
Residency: University of New Mexico  
Fellowship: University of New Mexico  
Clinical Expertise: Hip Arthroscopy, Total Joint Arthroplasty



**Tahseen Cheema MD**-Professor  
Medical Degree: Nishtar Medical College, Multan, Pakistan  
Residency: College of Medicines and Dentistry, New Jersey  
Fellowship: Hand and Microsurgery, Rush Presbyterian-St. Lukes Medical Center,  
Clinical Expertise: Hand and Microsurgery



**Attlee Benally DPM**-Assistant Professor  
Medical Degree: California College of Podiatric Medicine  
Post Medical School: Jerry Pettis Memorial VA Hospital, Saint Joseph's Hospital  
Clinical Expertise: Podiatry



**Thomas DeCoster MD**-Professor; Chief, Division of Orthopaedic Trauma, Assistant Team Physician, UNM Lobos; Orthopaedic Trauma Fellowship Program Director  
Medical Degree: University of Missouri, Columbia  
Residency: University of Vermont  
Fellowship: Trauma/Sports Medicine, University of Iowa  
Clinical Expertise: Musculoskeletal Trauma, Sports Medicine, Fractures



**Eric Benson MD**-Assistant Professor  
Medical Degree: Georgetown University  
Residency: University of New Mexico  
Fellowship: Shoulder, Elbow and Hand Fellowship, Hand and Upper Limb Centre, University of Western Ontario  
Clinical Expertise: Shoulder and Elbow Arthroscopy, Reconstruction and Trauma



**Paul Echols MD**-Professor; Chief, Division of General Orthopaedic Surgery  
Medical Degree: University of Texas, Galveston  
Residency: University of New Mexico  
Clinical Expertise: General Orthopaedic Surgery



**Brad Blankenhorn MD**-Assistant Professor  
Medical Degree: University of Pittsburgh  
Residency: Brown University  
Fellowship: Trauma, Brown University; Foot & Ankle, University of Utah  
Clinical Expertise: Common and complex disorders of the foot and ankle



**Rick Gehlert MD**-Associate Professor  
Medical Degree: University of Maryland School of Medicine  
Residency: Ohio State University  
Fellowship: Orthopaedic Trauma, University of Pittsburgh Medical Center  
Clinical Expertise: Orthopaedic Trauma

# Department of Orthopaedic Surgery Faculty



**Christopher Hanosh MD**-Assistant Professor  
Medical Degree: Johns Hopkins University  
School of Medicine  
Residency: University of New Mexico  
Fellowship: Reconstruction, Arizona  
Institute for Bone and Joint Disorders  
Clinical Expertise: Upper Extremities and  
Joints



**Elizabeth Mikola MD**-Associate Professor;  
Acting Chief, Division of Hand Surgery  
Medical Degree: University of Missouri,  
Kansas City School of Medicine  
Residency: University of Texas Health Science  
Center, Houston  
Fellowship: Hand Surgery, University of  
New Mexico  
Clinical Expertise: Hand Surgery



**Dale Hoekstra MD**-Assistant Professor  
Medical Degree: Wayne State University  
Residency: William Beaumont Hospital  
Fellowship: Pediatric Orthopaedic, Hospital for  
Sick Children  
Clinical Expertise: Pediatric Orthopaedics



**Richard A. Miller MD**-Professor; Chief,  
Division of Foot and Ankle Surgery  
Medical Degree: University of California,  
Los Angeles  
Residency: University of New Mexico  
Fellowship: Foot/Ankle with Dr. Roger Mann  
of San Leandro, California  
Clinical Expertise: Injuries and Reconstructive  
Surgery of the Foot and Ankle



**Antony Kallur MD**-Assistant Professor  
Medical Degree: University of Calicut  
Residency: Mahatma Gandhi University  
Fellowship: Spine, Hospital for Specialty  
Surgery; Orthopaedic Pediatric Surgery,  
Dupont Hospital for Children  
Clinical Expertise: Spine and Pediatric Trauma,  
Adult and Pediatric Spine Deformity



**Moheb S. Moneim MD**-Professor  
and Chairman Emeritus; Chief,  
Division of Hand Surgery; Hand Surgery  
Fellowship Program Director  
Medical Degree: Cairo University  
Residency: Duke University  
Fellowship: Hand Surgery, Hospital for Special  
Surgery, Cornell University  
Clinical Expertise: Hand Surgery



**Deana Mercer MD**-Assistant Professor  
Medical Degree: University of New Mexico  
Residency: University of New Mexico  
Fellowship: Should/Elbow Fellowship,  
University of Washington; Hand Surgery  
Fellowship, University of New Mexico  
Clinical Expertise: Hand and Upper Extremity



**Andrew Paterson MD**-Assistant Professor  
Medical Degree: University of Louisville  
Residency: University of New Mexico  
Fellowship: Orthopaedic Spine Surgery,  
Panorama Orthopaedics  
Clinical Expertise: Spine

# Department of Orthopaedic Surgery Faculty



**Robert Schenck, Jr. MD**-Professor and Chairman  
Medical Degree: Johns Hopkins University  
Residency: Johns Hopkins Hospital  
Fellowship: Foot and Ankle Surgery, Boise, ID; Sports Medicine, Cincinnati Sports Medicine and Orthopaedic Center  
Clinical Expertise: Sports Medicine



**Gehron Treme MD**-Assistant Professor, Division of Sports Medicine; Program Director, Orthopaedic Surgery Residency Program  
Medical Degree: Louisiana State University School of Medicine  
Residency: University of New Mexico  
Fellowship: University of Virginia, Orthopaedic Sports Medicine



**Frederick Sherman MD**-Professor Emeritus  
Medical Degree: Yale University School of Medicine  
Residency: San Francisco Orthopaedics Residency Training Program  
Fellowship: Pediatric Orthopaedics, Shriners Hospital, Los Angeles, CA; Pediatric Orthopaedics, Children's Hospital Medical Center, Boston, MA  
Clinical Expertise: Pediatric Orthopaedics



**Andrew Veitch MD**-Assistant Professor, Chief of Sports Medicine Division; Team Physician, UNM Lobos  
Medical Degree: University of New Mexico School of Medicine  
Residency: University of New Mexico  
Fellowship: Sports Medicine, University of California Los Angeles  
Clinical Expertise: Sports Medicine



**Selina Silva MD**-Assistant Professor  
Medical Degree: University of Colorado School of Medicine  
Residency: University of New Mexico  
Fellowships: Pediatric Orthopaedic Surgery, University of Michigan  
Clinical Expertise: Hip Dysplasia, Scoliosis, Limb Deformities



**Daniel Wascher MD**-Professor, Chief, Division of Sports Medicine; Assistant Team Physician, UNM Lobos; Orthopaedic Sports Medicine Fellowship Program Director  
Medical Degree: St. Louis University  
Residency: University of Rochester  
Fellowship: Sports Medicine, University of California, Los Angeles  
Clinical Expertise: Sports Medicine, Arthroscopy, Knee and Shoulder Reconstruction



**Elizabeth Szalay MD**-Professor  
Medical Degree: University of New Mexico  
Residency: University of Texas Health Science Center at San Antonio  
Fellowship: Pediatric Orthopaedics and Scoliosis, Texas Scottish Rite Hospital  
Clinical Expertise: Pediatric Orthopaedic Surgery and Pediatric Bone Densitometry

# Department of Orthopaedic Surgery Fellows



**James Clark MD-Hand Surgery**  
Medical Degree: Texas Tech University Health Sciences Center School of Medicine, Lubbock, TX  
Residency: Texas Tech University Health Sciences Center School of Medicine, Lubbock, TX  
Practice: University of New Mexico School of Medicine, Albuquerque, NM



**Benjamin Olson DO-Sports Medicine**  
Medical Degree: Kirksville College of Osteopathic Medicine, Kirksville, MO  
Residency: Ohio University- Affinity Hospital, Massillon, OH  
Practice: Grande Ronde Hospital, La Grande, OR



**Aaron Hoblet MD-Hand Surgery**  
Medical Degree: Ohio State University, Columbus, OH  
Residency: Madigan Army Medical Center, Tacoma, WA  
Practice: Desert Orthopaedics, Bend, Oregon



**Urvij Modhia MD-Trauma**  
Medical Degree: Gujarat University, Ahmedabad, India  
Residency: SMT. NHL Municipal Medical College, Ahmedabad, India  
Fellowship: Shriners Hospitals for Children, Philadelphia, PA



**Matthew Ferguson MD-Sports Medicine**  
Medical Degree: University of Texas Medical School, Houston, TX  
Residency: Mount Sinai School of Medicine, New York, NY  
Practice: Texas Tech University Health Sciences Center School of Medicine, Lubbock, TX

# Department of Orthopaedic Surgery Chiefs



**Owen Ala MD**  
Medical Degree: Cornell University Medical College  
Fellowship: Hand (University of Pennsylvania; Philadelphia, PA)



**Aaron Dickens MD**  
Medical Degree: University of Nevada School of Medicine  
Fellowship: Trauma (University of California San Diego; San Diego, CA)



**Lex Allen MD**  
Medical Degree: University of Utah School of Medicine  
Fellowship: Hand and Upper Extremity (Brisbane Hand and Upper Extremity Research Institute; Brisbane, Australia)



**Daniel Hoopes MD**  
Medical Degree: University of California, Irvine College of Medicine  
Fellowship: Foot and Ankle (University of Washington and Harborview Medical Center; Seattle, WA)



**Dustin Briggs MD**  
Medical Degree: University of Iowa College of Medicine  
Fellowship: Lower Extremity Reconstruction (Scripps Clinic; La Jolla, CA)

# Department of Orthopaedic Surgery Residents

## PGY 1



**Michael Decker MD**  
University of Illinois College of Medicine



**Katherine Gavin MD**  
Medical College of Wisconsin



**Keith Gill MD**  
Texas Tech University Health Sciences Center  
School of Medicine



**Drew Newhoff MD**  
University of Iowa College of Medicine



**Ian Power MD**  
University of New Mexico School of Medicine

## PGY 2



**Luke Bulthuis MD**  
Duke University School of Medicine



**Judd Fitzgerald MD**  
Medical College of Wisconsin



**Mischa Hopson MD**  
University of New Mexico School of Medicine



**Reilly Kuehn MD**  
University of Wisconsin Medical School



**Heather Menzer MD**  
University of New Mexico School of Medicine

# Department of Orthopaedic Surgery Residents

## PGY 3



**Scott Evans MD**  
Medical College of Wisconsin



**Sean Kuehn MD**  
University of Wisconsin Medical School



**Dustin Richter MD**  
University of New Mexico School of Medicine



**Greg Strohmeier MD**  
Northwestern University Medical School



**Heather Woodin MD**  
University of Arizona College of Medicine  
Health Sciences Center

## PGY 4



**Jenna Godfrey MD**  
University of Colorado School of Medicine



**J. Taylor Jobe MD**  
Texas Tech University Health Sciences Center  
School of Medicine



**Seth McCord MD**  
Boston University School of Medicine



**Nathan Morrell MD**  
Stanford University School of Medicine



**Charlotte Orr MD**  
University of Kentucky College of Medicine

# Physical Therapy Faculty



**Ron Andrews** PT, PhD-Associate Professor  
Degree: Masters, University of Wisconsin  
Madison; PhD, University of New Mexico  
Teaching Expertise: Kinesiology, orthopaedic  
evaluation and treatment



**Burke Gurney** PT, PhD-Associate Professor  
Degree: Masters, St. Johns College; PhD,  
University of New Mexico  
Teaching Expertise: Physical agents, exercise  
physiology, orthopaedic evaluation and  
treatment



**Ross Arena** PT, PhD, FAHA-Professor and  
Director, Physical Therapy Program  
Degree: Masters, Medical College of Virginia/  
Virginia Commonwealth University-  
Richmond; PhD, Medical College of  
Virginia/Virginia Commonwealth University-  
Richmond  
Teaching Expertise: Cardiopulmonary physical  
therapy, exercise science



**Beth Moody Jones** PT, DPT, MS, OCS-  
Assistant Professor  
Degree: DPT, AT Still University, Masters, Old  
Dominion University; PhD AT Still  
University  
Teaching Expertise: Gross anatomy, evidence  
based physical therapy, advanced spinal  
manipulation



**Fred Carey** PT, PhD-Assistant Professor  
Degree: PhD, University of Michigan  
Teaching Expertise: Neuroanatomy, acute care  
and cardiopulmonary, gross anatomy



**Beth Provost** PT, PhD, CHT-Associate  
Professor  
Degree: Masters, University of North Carolina  
at Chapel Hill; PhD, University of New  
Mexico  
Teaching Expertise: Pediatric evaluation and  
treatment; health, wellness, and fitness; mind  
body



**James "Bone" Dexter** PT, MA-Lecturer II  
Degree: Masters, University of New Mexico  
Teaching Expertise: Orthopaedics, geriatrics,  
prosthetics/orthotics



**Sue Queen** PT, PhD-Associate Professor  
Degree: PhD, University of New Mexico  
Teaching Expertise: Neurology, pharmacology,  
pathology



**Kathy Dieruf** PT, PhD, NCS-Assistant  
Professor  
Degree: Masters, University of New Mexico;  
PhD, University of New Mexico  
Teaching Expertise: Adult neuro evaluation  
and treatment, psychosocial issues, women's  
health, ethics, ethical decision making; quality  
of life



**Peg Wanta** PT, DPT-Academic Coordinator  
of Clinical Education  
Degree: DPT, AT Still University  
Teaching Expertise: Orthopaedics, health  
promotion and wellness, women's health



**Heather Hettrick** PT, PhD, CWS,  
FACCWS, MLT, DAPWCA, Assitant  
Professor and Director, Clinical Education  
Degree: PhD, Nova Southeastern University,  
PT, Chapman University  
Teaching Experience: Wound, burn, and  
lymphedema management

# Research Awards

## CTH Winter Conference Research Award



Aaron Dickens MD  
Comparison of Tibial Tubercle-Trochlear Groove  
Distance in Skeletally Immature Individuals With  
and Without Patellar Instability



Owen Ala MD  
Hand Dominance versus Stick Dominance in Youth  
Hockey

## Resident Research Award



Dustin Richter MD

## Research Assistants



Christina Salas  
University of New Mexico Center for Biomedical  
Engineering



Justin Brantley  
University of New Mexico Center for Biomedical  
Engineering



# Report from the Residency Director

Saying goodbye to another resident class brings the opportunity for reflection inherent to all transitions. I look forward to a life-long relationship with our graduating chiefs and hope that they remain involved with our program, as many have done over the years. We also welcome our incoming class of interns and believe that they will continue the tradition of excellence that has been established at UNM and exemplified by our 5 graduates this year. This is also a time to reflect on the quality of the program and to pursue opportunities for improvement so that we may provide the high quality clinical training that we have become known for while reacting to the changes in the health care environment.

Every year we react to change on a program, institution, and national level. These changes are usually slow and gradual, mirroring the needs of trainees and patients. The pace of change currently, however, is a bit more rapid and reflects the current position of health care in our nation's consciousness. It's no secret that medical care and physician training face challenges from many sides. Social, professional, regulatory, and financial pressures are shaping how we deliver care and how we train the orthopaedic surgeons of the future. Our reaction to this pressure must be measured and thoughtful to insure that our results remain excellent while we show sensitivity to these forces. Recently, the Accreditation Council for Graduate Medical Education has instituted a new process for evaluating all training programs, regardless of specialty, in the hope that some of these issues may be addressed formally. The New Accreditation System (NAS) goes into effect this year and Orthopaedic Surgery is among the specialties that will begin Phase One of the program this July. While NAS will give us some hurdles to overcome, it will also provide us with the welcome opportunity to innovate with respect to resident training.

In the modern health care environment, we must continue to produce talented physicians with world-class clinical and surgical skills as we have done in the past. In addition, however, we are tasked with teaching our graduates to appreciate health care quality in a broader sense and to make patient safety a priority. These points, along with a better understanding of health care delivery system dynamics, the importance of ethics and professionalism, and the delivery of cost efficient care, are more important than ever in our educational curriculum. These topics have always been taught here, but now the focus is stronger and all of our physicians must be aware of their importance. The irony, of course, is that the system that we work in has never been more fluid and the education of residents and faculty regarding these changes will have to occur in parallel. Fortunately, this dynamic is more common than not in medical education and I believe that we will integrate these concepts well.

The trick will be to incorporate these new focal points into the UNM Orthopaedic Surgery Residency (and all programs for that matter) without compromising the quality of the clinician that we graduate. That duty falls squarely on the shoulders of our leaders at all levels and is shared by the members of the residency group. We are more than up to the task and I look forward to these challenges. I am proud of our graduates and I look forward to working with all of them for the rest of our careers. Examples of their scholarship follow this report. Please join me in congratulating Owen, Lex, Dustin, Aaron, and Dan as they complete the biggest step thus far in their training. Nice work gentlemen.



Gehron Treme MD

# Hand Dominance Versus Stick Dominance in Youth Hockey

Owen Ala MD,<sup>1</sup> Lee Swiderek BS,<sup>2</sup> Eric Benson MD<sup>1</sup>

1. UNM Department of Orthopaedics & Rehabilitation 2. UNM School of Medicine

## Hypothesis

Most American hockey players use a right hockey stick in contrast to other countries where most hockey players use a left stick.<sup>1-3</sup> We hypothesize that most Americans use the wrong hockey stick and that a right hand dominant hockey player should use a left hockey stick and vice versa to gain an inherent performance advantage by having the dominant hand controlling the stick.<sup>4-7</sup>

## Methods

A novel test was created that simulates the back and forth motion of the hockey stick when handling a puck by moving the wrist into extreme supination and pronation (Image 1). The study tested a pediatric population ages 5-10 who had never participated in a stick sport (baseball, golf, hockey, etc.) to prevent stick

dominance bias. Participants were tested with the stick in the left and right stick positions, and asked to hit targets placed on two platforms. The number of repetitions in 20 seconds and accuracy were recorded. Researchers were blinded to the participant's hand dominance. Consents to participate were obtained from the parents of each participant.

Repeated measures analysis of covariance (ANCOVA) was used to compare the number of hits with right stick vs. left stick, controlling for hand dominance, age, and gender as covariates.

## Results

Forty participants were recruited ages 5 to 10 years old (average age being 7.2 years). There were 13 male and 27 female participants, of which 6 were left handed versus 34 right handed participants.

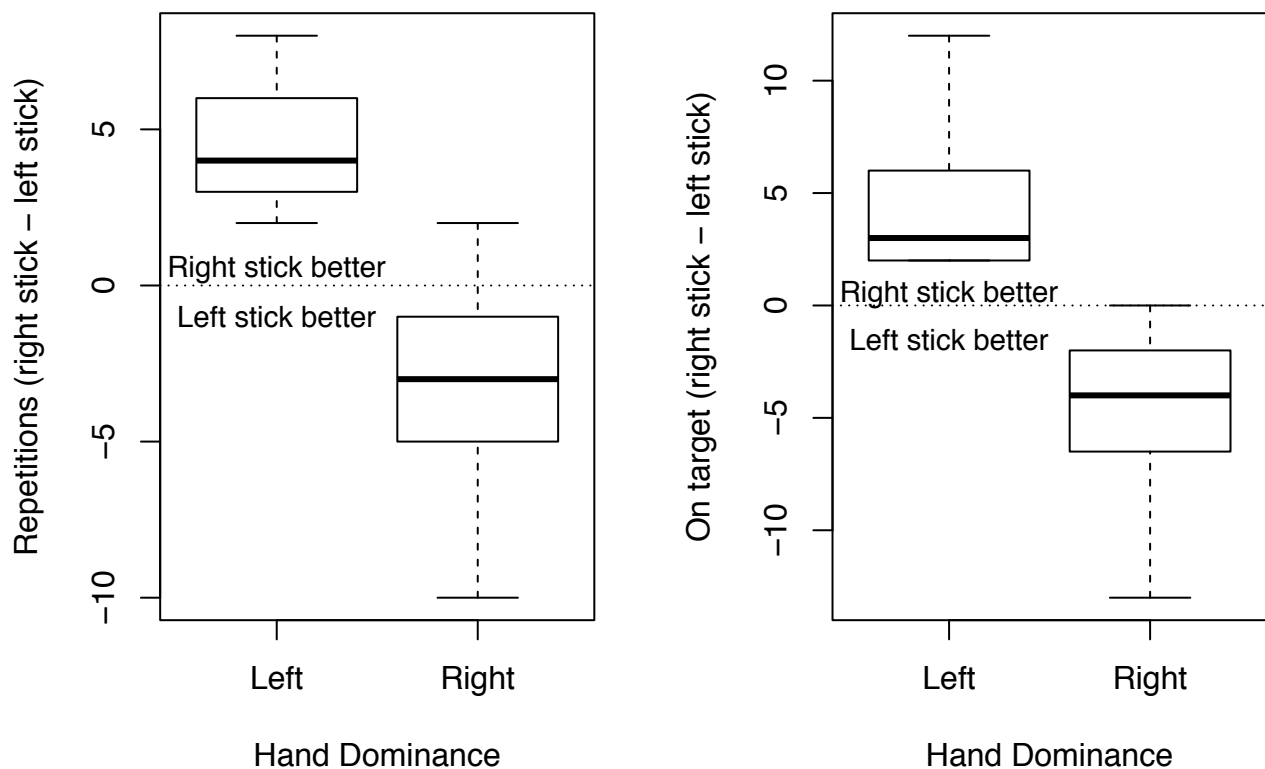


Figure 1: Results of all participants separated by hand dominance. Both repetitions in 20 seconds and on target hits in 20 seconds were performed better by left hand dominant participants using a right stick or right hand dominant participants using a left stick.



Image 1: Study participant performing test with a left hockey stick (stick held to the left of his body). He alternates back and forth between hitting the white target on the box to his right and the red target on the box to his left. Notice the extreme supination and pronation of his top hand (right hand). The test is designed to mimic the supination and pronation and back and forth motions used while playing hockey.

Of the 34 right handed participants, all but 3 performed better with the hockey stick in the left position, with a 95% confidence interval of 2.3 to 4.2 ( $p < 0.0001$ ). All 6 left handed participants performed better with the hockey stick in the right position with a 95% confidence interval of 2.2 to 6.7 ( $p < 0.0001$ ). ANCOVA was used to simultaneously fit gender, age, and hand dominance to difference in repetitions and strikes on target between right and left sticks. Gender ( $p = 0.61$ ) and age ( $p = 0.73$ ) were not significant predictors of difference; hand dominance ( $p < 0.0001$ ) was the only significant predictor (Figure 1).

### Summary Points

Right handed hockey players should use a left hockey stick and left handed players should use a right hockey stick. The hand situated at the top of the hockey stick exerts a greater degree of control and accuracy, making the dominant hand the logical choice; therefore, most Americans are using the wrong handed stick.

### Acknowledgement

This project was supported in part by the National Center for Research Resources and the National Center for Advancing Translational Sciences of the National Institutes of Health through Grant Number 8UL1TR000041, The University of New Mexico Clinical and Translational Science Center.

### References

1. Abrams DM, Pannaggio MJ. A model balancing cooperation and competition can explain our right-handed world and the dominance of left-handed athletes. *J R Soc Interface*. 2012;9(75):2718-2722.
2. Puterman J, Schorer J, Baker J. Laterality differences in elite ice hockey: an investigation of shooting and catching orientations. *J Sports Sci*. 2010;28(14):1581-1593.

3. Klein JZ. It's not political, but more Canadians are lefties. *The New York Times*. February 15, 2010.
4. Peters KS, McCallum S, Briggs L, Murrell GA. A comparison of outcomes after arthroscopic repair of partial versus small or medium-sized full-thickness rotator cuff tears. *J Bone Joint Surg Am*. 2012;94(12):1078-1085.
5. Goldstein SR, Young CA. "Evolutionary" stable strategy of handedness in major league baseball. *J Comp Psychol*. 1996;110(2):164-169.
6. Grondin S, Trottier M, Houle C. Préférences manuelle et latérale et style de jeu au hockey sur glace (Handedness and laterality and style of play in ice hockey). *STAPS*. 1994;35:65-75.
7. Michaud-Paquette Y, Magee P, Pearsall D, Turcotte R. Whole-body predictors of wrist shot accuracy in ice hockey: a kinematic analysis. *Sports Biomech*. 2011;10(1):12-21.

# Long Head of Biceps Tendon Anatomy, Biomechanics, Pathology, Diagnosis, and Management

Lex Allen MD<sup>1</sup>

1. UNM Department of Orthopaedics & Rehabilitation

## Introduction

Evaluation and treatment of the long head of the biceps tendon (LHBT) continues to be a source of debate. This review is aimed at discussing the anatomy, biomechanics, pathology, diagnosis and management of the LHBT. An extensive literature review was performed to help guide in management of disorders of the LHBT.

## Background

The LHBT has been a topic of discussion for many decades, and while it is becoming better understood it remains controversial with regards to function, diagnosis and treatment. The first known depictions of the biceps tendon date back to the early 1400s when it was noted in dissections performed by Vesalius. William Cowper reported one of the first pathologic etiologies of the LHBT in 1694 as a dislocation of the LHBT. It wasn't until 1841 when this diagnosis was finally "proven" during an autopsy. Meyer subsequently discussed LHBT ruptures and dislocations in the 1920s where it was attributed to attrition.<sup>1</sup> During the 1930s through 1950s the diagnosis of LHB tendinitis began appearing in the literature.<sup>2</sup> Since these early discussions of the LHBT, a significant amount of energy has been focused on its significance with regards to anatomy, function, role in shoulder pain/pathology and management of various disorders. Although it was originally described with such phrases as "Proverbial stepchild of the shoulder," "Appendix of the shoulder," and "Somewhat of a maverick, easy to inculcate but difficult to condemn," recent focus has turned to recognizing it as a source of pain and dysfunction in the shoulder that should be evaluated and treated appropriately.<sup>3-5</sup> Evaluation and appropriate treatment remain controversial but trends in treatment are continuing to develop.<sup>6</sup>

## Anatomy

The LHBT originates at the supraglenoid tubercle and superior glenoid labrum.<sup>7</sup> It then obliquely courses through the glenohumeral joint in an intra-articular but extra-synovial fashion before exiting the shoulder joint at a 30° to 40° angle via the biceps reflection pulley and the bicipital groove.<sup>8</sup> The tendinous portion of the LHBT measures 9 to 10cm in length and joins with the short head inserting on the radial tuberosity.<sup>9</sup> The long head of the biceps tendon is stabilized within the joint by the biceps reflection pulley and as it exits the joint by the osseous anatomy of the bicipital groove with the subscapularis forming its roof.<sup>10</sup> The LHBT receives the majority of its vascularity from the anterior circumflex humeral artery,

with a small portion coming from the suprascapular artery.<sup>11</sup> There is a watershed area described residing between the biceps reflection pulley and the bicipital groove.<sup>11</sup> Alpantaki performed immunohistochemical testing and found a high concentration of sensory nerve fibers in the proximal portion of the tendon.<sup>12</sup>

## Biomechanics

LHBT function remains controversial. Opinions vary widely, from no function in the shoulder to providing glenohumeral stability in all directions.<sup>13</sup> There are also thoughts in between, including humeral head depressor and providing glenohumeral stability especially when rotator cuff or labral pathology is present.<sup>14-16</sup> Pagnani in 1996 applied 55 N to LHBT in cadaveric specimens and demonstrated effect of humeral head depression.<sup>17</sup> Kuhn demonstrated (2005) resistance to external rotation by LHBT in a cadaveric study with 44.5 N of force applied.<sup>18</sup> Some authors have called into question these findings as it is felt LHBT cannot generate these amounts of force in vivo. EMG studies performed by Bassett and others call into question the amount of in vivo force the LHBT can generate, with their most recent findings suggesting the LHBT load is more reasonably estimated at 11 N.<sup>19</sup> In 2 separate in vivo radiographic studies Warner and Kido demonstrated humeral head depressor function of the LHBT in shoulders with intact or disrupted rotator cuff tendons.<sup>20,21</sup> Some authors have called these findings into question.

## Pathology

Disorders of LHBT are associated with rotator cuff tears (RCT) in up to 90% of cases and also associated with glenohumeral arthritis.<sup>4,7,15,22</sup> Isolated lesions on the LHBT are very rare and occur mostly in young overhead athletes.<sup>15</sup> The main lesions found in the LHBT can be grouped into 3 broad categories: inflammation, instability, and ruptures.<sup>15,23</sup> The first category, inflammation, is comprised of lesions varying in a spectrum of mild irritation to extensive fibrosis.<sup>24</sup> Common etiologies leading to the spectrum of LHBT inflammation are related to anatomy of the bicipital groove and possibly overuse injuries with hypovascularity occasionally being implicated.<sup>11,24</sup> The next category, instability, can lead to the disruption of the tendon's mechanical properties and thereby decrease its function and/or cause pain. Lesions that may lead to instability include subscapularis tendon tear, RCT, impingement, pathology of biceps reflection pulley, and superior labral anterior to posterior tears.<sup>25</sup> In

the final category, ruptures, these conditions are closely linked to the first 2 categories in that chronic inflammation or chronic instability can result in weakened mechanical properties of the tendon and eventual rupture. The other main cause of rupture of LHBT comes from trauma resulting in partial or complete tears. Partial ruptures may remain painful for extended periods of time whereas complete ruptures may be painful in the short term with pain subsiding in the long term.

## Diagnosis

Patients typically present with anterior shoulder pain that may occur at rest, with lifting, with overhead activities or they may feel popping or catching.<sup>5</sup> Patients may recall a specific injury or may state that symptoms began without a known inciting event. Standard shoulder radiographs should be obtained and often are normal in appearance.

Many physical exam tests have been described for evaluating the LHBT. The sensitivity and specificity of each test varies greatly. The commonly performed Speed's test has a specificity of 81% but only has a sensitivity of 54%.<sup>26</sup> The bear-hug test has a sensitivity of 79% but only 60% specificity, making it difficult to diagnosis LHBT pathology solely from physical exam.<sup>27</sup>

Magnetic resonance imaging (MRI) can be helpful in identifying inflammation, thickening, instability, and partial or full thickness ruptures. MRI has been shown to have 52% sensitivity and 27% specificity with a low interobserver reliability.<sup>27</sup> However, MRI arthrogram may increase sensitivity to 90% and specificity to 95% and many feel that the 3 Tesla MRI magnet approaches these values, as well.

Ultrasound can also be used in diagnosis but it is highly operator dependent and therefore is not utilized on a regular basis by most clinicians.<sup>28</sup> Diagnostic injections have also been utilized to help in diagnosis but a recent study by Hashiuchi suggests that ultrasound be used to insure the solution is injected around the biceps tendon, as he found a 27% injection accuracy without use of ultrasound and a much improved 87% with the ultrasound.<sup>29</sup> Arthroscopy remains the gold standard for diagnosing pathology within the LHBT.<sup>26,30</sup>

## Treatment

Treatment generally starts with non-operative modalities, including activity modification, physical therapy, non-steroidal anti-inflammatory drugs (NSAID), and steroid injections.<sup>27</sup> In general, non-operative treatments provide good results and patient satisfaction. When pain and disability continue despite non-operative management, surgical intervention can be discussed. There are a variety of surgical treatments to address LHBT pathological conditions but the mainstay of surgical treatment is tenodesis or tenotomy of the LHBT,

with surgical repair of concomitant shoulder pathology, as isolated lesions of LHBT are rare. Current trends demonstrate tenotomy being recommended more in elderly patients while tenodesis is being recommended in young, active patients and especially patients involved in heavy labor.<sup>3,31-33</sup> There is no clear evidence demonstrating that either tenotomy or tenodesis is superior, but patients should be informed of key aspects and outcomes of these 2 different procedures.<sup>31,33</sup> In complete ruptures, patients should be counseled that non-surgical management may result in 21% loss of supination strength and 8% loss of elbow flexion strength.<sup>34</sup> It is generally accepted that less strength will be compromised in patients undergoing tenodesis for complete ruptures.<sup>34</sup> Patients should be counseled regarding the possible cosmetic outcome of rupture of the LHBT resulting in a Popeye deformity of the biceps muscle belly.<sup>3,32</sup> Although complete rupture of the LHBT does not guarantee a biceps muscle deformity, the risk of experiencing a Popeye deformity is 33% higher in the non-operative group when compared with the tenodesis group.<sup>35</sup> However, recent literature has shown that patients may be less worried about this deformity than their surgeons are.<sup>35</sup> Various surgical techniques have been described for LHBT tenodesis, including soft tissue fixation, osseous fixation, and the level at which the tenodesis is performed.<sup>36</sup> No variation has been shown to be superior and most current literature recommends using the technique with which the surgeon is most comfortable and efficient.

## Conclusions

LHBT function remains not well understood. LHBT pathology is usually accompanied by other shoulder pathology and is rarely found in isolation. Diagnosing LHBT pathology can be challenging and surgeons are encouraged to use a variety of diagnostic avenues including history and physical exam, x-rays, MRI, ultrasound, and diagnostic injections. Arthroscopy remains the gold standard for assessing LHBT pathology and so surgeons should be prepared to address pathology intra-operatively even when lesions may not be suspected pre-operatively. Treatment with tenotomy or tenodesis is patient dependent. If using tenodesis, the technique the surgeon is most comfortable with should be used, as there are no obvious advantages of one over another. Patients should be counseled pre-operatively regarding possible loss of strength and possible deformity of the biceps muscle belly, which may occur with either tenotomy or tenodesis.

## References

1. Meyer AW. Spontaneous dislocation and destruction of tendon of long head of biceps brachii: 59 instances. *Arch Surg-Chicago*. 1928;17(3):493-506.
2. Hitchcock HH, Bechtol CO. Painful shoulder: observations on the role of the tendon of the long head of the biceps brachii in its causation. *J Bone Joint Surg Am*. 1948;30(2):263-273.

3. Boileau P, Ahrens PM, Hatzidakis AM. Entrapment of the long head of the biceps tendon: the hourglass biceps—a cause of pain and locking of the shoulder. *J Shoulder Elbow Surg.* 2004;13(3):249-257.
4. Beall DP, Williamson EE, Ly JQ, et al. Association of biceps tendon tears with rotator cuff abnormalities: degree of correlation with tears of the anterior and superior portions of the rotator cuff. *Am J Roentgenol.* 2003;180(3):633-639.
5. Crenshaw AH, Kilgore WE. Surgical treatment of bicipital tenosynovitis. *J Bone Joint Surg Am.* 1966;48(8):1496-1502.
6. Armstrong A, Teefey SA, Wu T, et al. The efficacy of ultrasound in the diagnosis of long head of the biceps tendon pathology. *J Shoulder Elbow Surg.* 2006;15(1):7-11.
7. Walch G, Edwards TB, Boulahia A, Nové-Josserand L, Neyton L, Szabo I. Arthroscopic tenotomy of the long head of the biceps in the treatment of rotator cuff tears: clinical and radiographic results of 307 cases. *J Shoulder Elbow Surg.* 2005;14(3):238-246.
8. Habermeyer P, Magosch P, Pritsch M, Scheibel MT, Lichtenberg S. Anterosuperior impingement of the shoulder as a result of pulley lesions: a prospective arthroscopic study. *J Shoulder Elbow Surg.* 2004;13(1):5-12.
9. Ahrens PM, Boileau P. The long head of biceps and associated tendinopathy. *J Bone Joint Surg Br.* 2007;89-B(8):1001-1009.
10. Cone RO, Danzig L, Resnick D, Goldman AB. The bicipital groove: radiographic, anatomic, and pathologic study. *Am J Roentgenol.* 1983;141(4):781-788.
11. Cheng NM, Pan WR, Vally F, Le Roux CM, Richardson MD. The arterial supply of the long head of biceps tendon: anatomical study with implications for tendon rupture. *Clin Anat.* 2010;23(6):683-692.
12. Alpantaki K, McLaughlin D, Karageorgos D, Hadjipavlou A, Kontakis G. Sympathetic and sensory neural elements in the tendon of the long head of the biceps. *J Bone Joint Surg Am.* 2005;87(7):1580-1583.
13. Krupp RJ, Kevern MA, Gaines MD, Kotara S, Singleton SB. Long head of the biceps tendon pain: differential diagnosis and treatment. *J Orthop Sports Phys Ther.* 2009;39(2):55-70.
14. Kumar VP, Satku K, Balasubramaniam P. The role of the long head of biceps brachii in the stabilization of the head of the humerus. *Clin Orthop Relat Res.* 1989(244):172-175.
15. Eakin CL, Faber KJ, Hawkins RJ, Hovis WD. Biceps tendon disorders in athletes. *J Am Acad Orthop Surg.* 1999;7(5):300-310.
16. Kim SH, Ha KI, Kim HS, Kim SW. Electromyographic activity of the biceps brachii muscle in shoulders with anterior instability. *Arthroscopy.* 2001;17(8):864-868.
17. Pagnani MJ, Deng X, Warren R, Torzilli PA, O'Brien SJ. Role of the long head of the biceps brachii in glenohumeral stability: a biomechanical study in cadavera. *J Shoulder Elbow Surg.* 1996;5(4):255-262.
18. Kuhn JE, Huston LJ, Soslowky LJ, Shyr Y, Blasier RB. External rotation of the glenohumeral joint: ligament restraints and muscle effects in the neutral and abducted positions. *J Shoulder Elbow Surg.* 2005;14(1 Suppl S):39S-48S.
19. Bassett RW, Browne AO, Morrey BF, An KN. Glenohumeral muscle force and moment mechanics in a position of shoulder instability. *J Biomech.* 1990;23:405-415.
20. Warner JJ, McMahon PJ. The role of the long head of the biceps brachii in superior stability of the glenohumeral joint. *J Bone Joint Surg Am.* 1995;77:366-372.
21. Kido T, Itoi E, Konno N, Sano A, Urayama M, Sato K. The depressor function of biceps on the head of the humerus in shoulders with tears of the rotator cuff. *J Bone Joint Surg Br.* 2000;82-B(3):416-419.
22. Checchia SL, Doneux PS, Miyazaki AN, et al. Biceps tenodesis associated with arthroscopic repair of rotator cuff tears. *J Shoulder Elbow Surg.* 2005;14(2):138-144.
23. Lam F, Mok D. Treatment of the painful biceps tendon—tenotomy or tenodesis? *Curr Orthopaed.* 2006;20:370-375.
24. Murthi AM, Vosburgh CL, Neviasser TJ. The incidence of pathologic changes of the long head of the biceps tendon. *J Shoulder Elbow Surg.* 2000;9(5):382-385.
25. Lafosse L, Reiland Y, Baier GP, Toussaint B, Jost B. Anterior and posterior instability of the long head of the biceps tendon in rotator cuff tears: a new classification based on arthroscopic observations. *Arthroscopy.* 2007;23(1):73-80.
26. Holtby R, Razmjou H. Accuracy of the Speed's and Yergason's tests in detecting biceps pathology and SLAP lesions: comparison with arthroscopic findings. *Arthroscopy.* 2004;20(3):231-236.
27. Nho SJ, Strauss EJ, Lenart BA, et al. Long head of the biceps tendinopathy: diagnosis and management. *J Am Acad Orthop Surg.* 2010;18(11):645-656.
28. Papatheodorou A, Ellinas P, Takis F, Tsanis A, Maris I, Batakis N. US of the shoulder: rotator cuff and non-rotator cuff disorders. *Radiographics.* 2006;26(1):e23.
29. Hashiuchi T, Sakurai G, Morimoto M, Komei T, Takakura Y, Tanaka Y. Accuracy of the biceps tendon sheath injection: ultrasound-guided or unguided injection? A randomized controlled trial. *J Shoulder Elbow Surg.* 2011;20(7):1069-1073.
30. Gill HS, El Rassi G, Bahk MS, Castillo RC, McFarland EG. Physical examination for partial tears of the biceps tendon. *Am J Sports Med.* 2007;35(8):1334-1340.
31. Frost A, Zafar MS, Maffulli N. Tenotomy versus tenodesis in the management of pathologic lesions of the tendon of the long head of the biceps brachii. *Am J Sports Med.* 2009;37(4):828-833.
32. Gill TJ, McIrvin E, Mair SD, Hawkins RJ. Results of biceps tenotomy for treatment of pathology of the long head of the biceps brachii. *J Shoulder Elbow Surg.* 2001;10(3):247-249.
33. Hsu AR, Ghodadra NS, Provencher MT, Lewis PB, Bach BR. Biceps tenotomy versus tenodesis: a review of clinical outcomes and biomechanical results. *J Shoulder Elbow Surg.* 2011;20(2):326-332.
34. Mariani EM, Cofield RH, Askew LJ, Li GP, Chao EY. Rupture of the tendon of the long head of the biceps brachii. Surgical versus nonsurgical treatment. *Clin Orthop Relat Res.* 1988(228):233-239.
35. Bradbury T, Dunn WR, Kuhn JE. Preventing the popeye deformity after release of the long head of the biceps tendon: an alternative technique and biomechanical evaluation. *Arthroscopy.* 2008;24(10):1099-1102.
36. Lutton DM, Gruson KI, Harrison AK, Gladstone JN, Flatow EL. Where to tenodesis the biceps: proximal or distal? *Clin Orthop Relat Res.* 2011;469(4):1050-1055.

# The Evolution of the Femoral Stem Design in Total Hip Arthroplasty

Dustin Briggs MD<sup>1</sup>

1. UNM Department of Orthopaedics & Rehabilitation

Since the introduction of Dr. John Charnley's "low-friction arthroplasty" in 1962,<sup>1</sup> the general concepts of total hip arthroplasty have remained greatly unchanged. He laid the foundation for a predictably successful surgical intervention for an ailment previously difficult to treat. The low-friction arthroplasty featured a monoblock stainless steel femoral stem, high density polyethylene, self-curing polymethyl-methacrylate (PMMA), and aseptic technique. Although the general principles of arthroplasty have remained remarkably similar, implant design has evolved over the past 50 years. The following is a review of the evolution of the femoral stem.

Long-term results of Charnley's total hip arthroplasty, including 35-year follow-up, reflect a 78% femoral stem implant survival.<sup>2</sup> Patients surviving 20 years after primary total hip arthroplasty had a femoral stem revision rate of 15%. Fifteen patients of the original 330 survived 35 years after the index procedure and had a femoral stem revision rate of 47%. Over the years, numerous changes have evolved, including improvements in cement technique, changes in implant design, and a trend toward biological fixation with press-fit implants.<sup>2</sup>

Cementing technique has evolved numerous generations and now includes vacuum centrifugation, pulsatile lavage, pressurized cement, and distal and proximal centralizers. These interventions have led to a more uniform, symmetric cement mantle.<sup>3</sup> Cemented femoral stems have evolved into 2 main types of design. The "loaded taper" stems rely on the principle that cement (PMMA) functions well under compression, generating radial compressive forces and resultant hoop strength.<sup>4</sup> These stems characteristically "creep" up to 1 mm over the first year and subsequently stabilize. The design rationale includes a polished, round, collarless, straight, tapered stem that facilitates creep while generating minimal particle debris.<sup>4</sup>

Conversely, the "composite beam" cemented stem has design features that allow minimal micromotion and employ an interference fit with the bone and cement mantle. These stems typically have a rough surface, are often rectangular, can be straight or anatomic, and occasionally have a collar. Both types of cemented stems have been shown to be successful, however the design rationale must comply with the planned mode of fixation and stay true to those principles. The disadvantage of the interference fit of the "composite beam" cemented stem is that even minimal micromotion can generate particle debris and potentially result in osteolysis. This may have led to the evolution of cementless, press-fit femoral stem design.<sup>4</sup>

As early as 1979, Lord reported early results of an "experimental" study of an uncemented total hip replacement.<sup>5</sup> He stated that "living bone that undergoes remodeling provides for long-term anchor of the prosthesis."<sup>5</sup> The anatomic medullary locking (AML) stem was the first cementless femoral implant approved for use in the United States (US). The design featured a straight, cobalt-chrome, extensively porous coated stem that employs distal, diaphyseal fixation. The stem has an exceptional track-record, including up to 98% survivorship at 20 years.<sup>6</sup> Disadvantages include proximal stress shielding and occasional thigh pain.<sup>6</sup>

Around the same time, the porous coated anatomic (PCA) stem was introduced in the US. This cobalt-chrome stem featured an anatomic sagittal curve and proximal porous coating. Long-term results were also favorable for survivorship, including nearly 90% rate of ingrowth and a 7% femoral stem revision rate at 15 years.<sup>7</sup> The major disadvantage of this stem design was a high prevalence of thigh pain, up to 30%.<sup>8,9</sup> The concepts of the AML and PCA are still in use to this day, with slight modifications that substantially reduce thigh pain.<sup>7</sup>

As total hip arthroplasty is now made available for younger, healthier, and more active patients, bone preservation is essential.<sup>10</sup> Proximal fixation with less subsequent stress shielding has become a focus. These implant designs include double taper metaphyseal filling stems and single, "M-L" (medial-lateral) taper stems. Each of these implants relies on metaphyseal fixation and ingrowth proximal to the diaphyseal and subtrochanteric regions. A double taper design allows for "fit and fill" of the metaphysis in both dimensions, theoretically allowing more rotational support.<sup>11</sup> However, anatomy is variable and occasionally there is a mismatch in the sagittal and coronal dimensions of the metaphysis. The M-L taper stems increase in size, largely only in the coronal dimension, eliminating this mismatch but theoretically providing less rotational stability. Both of these stem designs have an exceptional track-record of survivorship greater than 95% at 20 years and minimal thigh pain.<sup>12,13</sup>

Finally, short metaphyseal stems without distal extension are also available. These address the problem of metaphyseal-diaphyseal diameter mismatch. This mismatch is often encountered in young, active patients with a "champagne-flute" femur or very elderly patients with a "stove-pipe" femur. Although no long-term outcome studies exist, there are certainly advantages and disadvantages. Advantages include the elimination of metaphyseal-diaphyseal mismatch, substantial bone preservation with no reaming and minimal broaching,

ability to insert with any surgical approach, and ease of implant removal and bone conservation during revision. However, disadvantages include a concern for early stability and possible fibrous ingrowth, malposition due to lack of distal extension to guide position within the canal, and subsidence. Early studies have shown minimal blood loss, lack of thigh pain, successful ingrowth, and minimal stress shielding.<sup>12</sup>

In conclusion, total hip arthroplasty has become a successful operation with predictably excellent results. The general concepts remain true today just as they did 50 years ago when Charnley introduced the modern design rationale. Today surgeons have a choice of multiple femoral stem implants, each with a unique set of advantages and disadvantages. Understanding the design principles and the historical evolution is important in selecting an implant that meets the goals and expectations shared by the surgeon and patient.

## References

1. Charnley J. The long-term results of low-friction arthroplasty of the hip performed as a primary intervention. *J Bone Joint Surg Br.* 1972;54-B(1):61-76.
2. Callaghan JJ, Bracha P, Liu SS, Piyaworakhun S, Goetz DD, Johnston RC. Survivorship of a Charnley total hip arthroplasty: a concise follow-up, at a minimum of thirty-five years, of previous reports. *J Bone Joint Surg Am.* 2009;91(11):2617-2621.
3. Dennis DA, Lynch CB. Optimizing the femoral component cement mantle in total hip arthroplasty. *Orthopedics.* 2005;28(8 Suppl):s867-871.
4. Scheerlinck T, Casteleyn PP. The design features of cemented femoral hip implants. *J Bone Joint Surg Br.* 2006;88-B(11):1409-1418.
5. Lord GA, Hardy JR, Kummer FJ. An uncemented total hip replacement: experimental study and review of 300 madreporique arthroplasties. *Clin Orthop Relat Res.* 1979;141:2-16.
6. Belmont PJ, Powers CC, Beykirch SE, Hopper RH, Engh CA. Results of the anatomic medullary locking total hip arthroplasty at a minimum of twenty years: a concise follow-up of previous reports. *J Bone Joint Surg Am.* 2008;90(7):1524-1530.
7. Bojeskul JA, Xenos JS, Callaghan JJ, Savory CG. Results of porous-coated anatomic total hip arthroplasty without cement at fifteen years: a concise follow-up of a previous report. *J Bone Joint Surg Am.* 2003;85-A(6):1079-1083.
8. Kawamura H, Dunbar MJ, Murray P, Bourne RB, Rorabeck CH. The porous coated anatomic total hip replacement. A ten to fourteen-year follow-up study of a cementless total hip arthroplasty. *J Bone Joint Surg Am.* 2001;83(9):1333-1338.
9. Knight JL, Atwater RD, Guo J. Clinical results of the midstem porous-coated anatomic uncemented femoral stem in primary total hip arthroplasty: a five- to nine-year prospective study. *J Arthroplasty.* 1998;13(5):535-545.
10. Mai KT, Verioti CA, Casey K, Slesarenko Y, Romeo L, Colwell CW. Cementless femoral fixation in total hip arthroplasty. *Am J Orthop.* 2010;39(3):126-130.
11. Howie DW, Wimbhurst JA, McGee MA, Carbone TA, Badaruddin BS. Revision total hip replacement using cemented collarless double-taper femoral components. *J Bone Joint Surg Br.* 2007;89-B(7):879-886.
12. Khanuja HS, Vakil JJ, Goddard MS, Mont MA. Cementless femoral fixation in total hip arthroplasty. *J Bone Joint Surg Am.* 2011;93(5):500-509.
13. Lombardi AV, Berend KR, Mallory TH, Skeels MD, Adams JB. Survivorship of 2000 tapered titanium porous plasma-sprayed femoral components. *Clin Orthop Relat Res.* 2009;467(1):146-154.



# Management of Pediatric Femur Shaft Fractures

Aaron Dickens MD<sup>1</sup>

1. UNM Department of Orthopaedics & Rehabilitation

## Background

The incidence of pediatric femur fractures is 19 in 100,000 patients and is more common in boys than girls.<sup>1-4</sup> Femur fractures account for 1.4% to 1.7 % of all pediatric fractures.<sup>1-4</sup> In the 1990s it was reported as the leading cause for hospital stay (days/yr) longer than 5 days for pediatric patients.<sup>5</sup> Etiology of injury includes falls, motor vehicle related, sports injuries and abuse. Abuse has been reported as the leading cause of femur fractures in children less than 1 year old and of significant concern in those up to 5 years old.<sup>1,2,6</sup> Low socioeconomic status has been shown to be a risk factor for abuse related femur fractures, as well.<sup>2</sup>

Management of pediatric diaphyseal femur fractures has evolved significantly over the last 50 years. Nonoperative treatment with traction and immobilization was previously the mainstay of treatment. Due to the morbidity associated with prolonged immobilization and the development of fixation devices geared toward treatment of pediatric fractures, operative treatment is now more prevalent but is still age-dependent. Skeletal maturity and the potential for bony remodeling is a significant factor in guiding treatment.

Post-fracture growth acceleration is a special consideration. There is potential for 1 to 2 cm of overgrowth during fracture healing and remodeling.<sup>7</sup> Accelerated growth can continue for up to 5 years but most occurs within the first 2 years after fracture.<sup>8</sup> Fractures opposite to the dominant hand show more growth acceleration.<sup>9</sup> Overgrowth is decreased by shortening and accelerated by distraction. Neither patient age nor fracture type/location significantly affects overgrowth.<sup>10</sup>

## Fracture Classification

Historically, pediatric femur fractures were classified using descriptions of anatomic location and fracture characteristics. In 1963, Salter and Harris further described fractures involving the epiphyseal plate.<sup>10</sup> In 2007 the AO Foundation published Fracture and Dislocation Classification Compendium for Children.<sup>11</sup> This was the first comprehensive and anatomically descriptive classification system for pediatric fractures and includes both physeal and extra-physeal injuries. According to this system a pediatric diaphyseal fracture is classified as 32-D with further classification dependent upon fracture pattern and comminution.

## AAOS Clinical Practice Guidelines

In 2009, the American Academy of Orthopaedic Surgeons (AAOS) released clinical guidelines for the management of pediatric femur shaft fractures.<sup>12,13</sup>

A summary of the 14 recommendations based on available evidence as of 2009 is listed below. Grade A recommendations are based on level I evidence. Grade B suggestions are based on level II or III evidence. Grade C options are based on level IV or V evidence. Grade I (incomplete) has no or conflicting evidence and therefore recommendations cannot be made for or against a given intervention.

### Grade A Intervention:

- Recommend that children younger than 36 months with a diaphyseal femur fracture be evaluated for child abuse.

### Grade B intervention:

- Suggest early spica casting or traction with delayed spica casting for children age 6 months to 5 years with a diaphyseal femur fracture with less than 2 cm of shortening.

### Grade C interventions:

- Treatment with a Pavlik harness or a spica cast are options for infants 6 months and younger with a diaphyseal femur fracture.
- When using the spica cast in children 6 months to 5 years of age, altering the treatment plan is an option if the fracture shortens greater than 2 cm.
- It is an option for physicians to use flexible intramedullary nailing to treat children age 5 to 11 years diagnosed with diaphyseal femur fractures.
- Rigid trochanteric entry nailing, submuscular plating, and flexible intramedullary nailing are treatment options for children age 11 years to skeletal maturity diagnosed with diaphyseal femur fractures, but piriformis or near piriformis entry rigid nailing are not treatment options.
- Regional pain management is an option for patient comfort perioperatively.
- Waterproof cast liners for spica casts are an option for use in children diagnosed with pediatric diaphyseal femur fractures.

The committee was unable to recommend for or against the following Grade I (incomplete) interventions:

- Early spica casting for children age 6 months to 5 years with a diaphyseal femur fracture with greater than 2 cm of shortening.
- Using weight as a criterion for the use of spica casting in children age 6 months to 5 years with a diaphyseal femur fracture.
- Using any specific degree of angulation or rotation as a criterion for altering the treatment plan when using the spica cast in children 6 months to 5 years of age.
- Removal of surgical implants from asymptomatic patients after treatment of diaphyseal femur fractures.
- Outpatient physical therapy to improve function after treatment pediatric diaphyseal femur fractures.
- Use of locked versus non-locked plates for fixation of pediatric femur fractures.

### **Nonoperative Management**

Indications for nonoperative management are classically described in *Fractures in Children* by Rockwood, Wilkins, and Beaty.<sup>14</sup> Acceptable values for angulation and shortening decrease with advanced skeletal maturity, as there is less potential for remodeling of deformity. Patients from birth to 2 years can accept up to 30° of angulation in all planes and 15 mm of shortening. Patients aged 11 years to skeletal maturity can accept only 5° of varus/valgus, 10° of anterior/posterior degrees of angulation and up to 10 mm of shortening. Nonoperative stabilization options include Pavlik harness, early traction (skin and/or skeletal) with delayed spica casting, and early fracture manipulation with spica casting.

#### Pavlik Harness

Optimal positioning for affected limb is approximately 80° to 90° of hip flexion and 50° of hip abduction. A lateral pillow or blanket can also be used for comfort. Stannard et al. studied a series of 16 patients between 0 and 18 months treated with Pavlik harness and found that all femur shaft fractures united within 5 weeks without malunion or apparent complications.<sup>15</sup> They recommend it as a good option for patients less than 4 months and for small patients up to 6 months when there is less than 2 cm of shortening. Podeszwa et al. compared Pavlik harness with immediate spica casting for femur fractures in infants less than 6 months and found that they all united within 5 weeks and the spica group had more skin complications.<sup>16</sup>

#### Early Spica Casting

Optimal positioning for spica casting is approximately 40° to 60° of flexion and 90° of knee flexion. Wolff and James showed that the use of a waterproof liner significantly reduces loss of skin integrity and unexpected cast changes.<sup>17</sup>

#### Early Traction with Delayed Hip Spica Casting

Various methods of skin traction include Bryant's traction, Buck's traction and Russell's traction. Balanced skeletal traction with the hip and knee flexed at 90° is another option. Distal femoral transfixion pins have typically been utilized for balanced skeletal traction in these fractures. Once early bone healing has occurred patients can be transitioned into a hip spica cast. Rasool et al. compared immediate spica casting with skin traction and delayed casting and found more skin complications and hospital acquired infections in the traction group. There was also a significant difference in hospital expense favoring the immediate spica group.<sup>18</sup>

### **Operative Management**

Operative indications include unacceptable deformity, polytrauma, open fracture, neurovascular injury, pathologic fracture and body habitus not amenable to casting. Operative stabilization and fixation options include flexible/elastic intramedullary nailing, rigid intramedullary nailing, internal plate fixation and external fixation.

#### Flexible/Elastic Intramedullary Nailing

Implants include stainless steel flexible nails (Enders rods) and titanium elastic nails. The recommended diameter of each nail is 4/10 the diameter of the intramedullary canal at the isthmus.<sup>19</sup> They should diverge at the fracture site and should avoid leaving cut ends resting on the physis. They offer minimal control over fracture rotation. Buechsenschuetz et al. compared traction with delayed casting to stabilization with elastic nailing and found no difference in complications. There was higher parent satisfaction for the elastic nailing group. A cost analysis showed that the average cost of care was less for the elastic nailing group as well.<sup>20</sup> Flynn et al. performed a similar comparison and showed fewer malunions and complications in the elastic nailing group. Patients in the elastic nailing group also had shorter hospital stay, walked sooner and returned to school sooner.<sup>21</sup>

Moroz et al. looked at predictors of complications and poor outcomes with the use of titanium elastic nailing of femur fractures in children. They found limb-length discrepancy, malunion and loss of fixation to be 5 times higher when patient weighed over 49 kg (108 lbs). These complications were also higher for patients older than 11 years and for fractures in the distal third of the femoral diaphysis.<sup>22</sup>

Flexible interlocking intramedullary nails (FIIN) require a minimum 9 mm canal diameter and utilize a far lateral trochanteric entry to avoid disruption of the trochanteric apophysis and femoral head blood supply. It is not necessary to fill the canal and the nail should end approximately 1 to 3 cm proximal to the distal femoral physis. This device offers theoretically improved rotational and long axis stability compared to traditional flexible/elastic nails. The AAOS guidelines did not include studies reporting outcomes with this device. Jencikova-Celerin et al. compared FIIN with other types of fixation including elastic nails and found that the FIIN group has less blood loss and faster weight-bearing. Heterotopic ossification was the most common complication (13.8%) for the FIIN group. There were more complications with FIIN for patients weighing less than 45.5 kg (100 lbs) and for fractures in the distal fourth of the diaphysis.<sup>23</sup> Keeler et al. performed a case-series of 80 patients and showed 100% union without malunion or avascular necrosis (AVN).<sup>24</sup> These nails may be useful in patients too skeletally immature for use of a rigid nailing but too heavy for use of elastic intramedullary nailing.

#### Rigid Intramedullary Nailing

Trochanteric entry nails are the rigid nail of choice in appropriately developed pediatric patients. The recommended nail length should end 1 to 3 cm proximal to the distal femoral physis in order to prevent physeal injury. Piriformis nails are contraindicated in skeletally immature patients due to unacceptable risk of developing avascular necrosis (AVN). The reported rate of AVN with piriformis entry nailing was 4% according to Buford et al.<sup>25</sup> In this study the authors performed intramedullary nailing with an entry just posterior to the piriformis fossa in an effort to avoid the retinacular vessels from the lateral ascending branch of the medial femoral circumflex artery, which is the primary blood supply to the femoral head. Kanellopoulos et al. reported no major complications and 100% fracture union after use of locked trochanteric rigid nailing in this population.<sup>26</sup> Beaty et al. reported AVN as a complication after use of trochanteric entry nails but only in 1% of patients and is felt to possibly be related to the injury itself rather than the surgery.<sup>27</sup> Greater trochanteric growth disturbance is a concern and, in general, rigid nailing is not recommended in patients younger than 11 years of age for this reason.

#### Internal Plate Fixation

Indirect reduction with submuscular bridge plating can be utilized to preserve fracture site biology in comminuted fracture patterns not amenable to intramedullary stabilization. This technique achieves relative fracture stability and relies on secondary bone healing. The ability for pediatric patients to remodel

makes this an appealing option through minimal surgical exposure. Agus et al. reported a low rate (7%) of malunion and uncomplicated removal of submuscular plates after union.<sup>28</sup>

Open reduction internal fixation with a direct reduction and compression plating is another option but requires more surgical exposure to obtain an anatomic reduction at the fracture site. This requires some amount of soft tissue devitalization around the fracture site, which may be less of a concern in the pediatric population as the reported rate of nonunion is rare for diaphyseal femur fractures.<sup>29</sup>

#### External Fixation

External fixation is typically reserved for damage control situations where there is significant soft tissue and/or neurovascular injury. It can also be utilized for gradual correction of deformity. Pins are typically placed laterally and percutaneously. Barlas and Beg compared elastic nailing to external fixation for pediatric femur fracture stabilization. There was a higher reported rate of malunion and refracture in the external fixation group.<sup>30</sup> Pin tract infections and pin loosening can also be problematic with external fixation.

#### Complications

Complications of operative stabilization and fixation include femoral head avascular necrosis, which has been reported uncommonly after rigid intramedullary nailing but can have devastating outcomes. Malunion is a risk of all forms of operative stabilization but is more prevalent with external fixation and flexible/elastic intramedullary nailing in heavier children. Nonunion is uncommon in children. Implant migration has been reported most with flexible/elastic intramedullary nailing. Infection, neurovascular injury, implant prominence and refracture are also risks of various operative stabilization techniques. Venous thromboembolism and fat-emboli syndrome are rare in children with isolated femur shaft fractures.

#### **Other Considerations**

Age and skeletal maturity are perhaps the most important factors to consider when determining appropriate management of femur shaft fractures. Fracture stability and the potential for accelerated growth can also affect the decision for operative versus nonoperative treatment. The potential for remodeling makes nonoperative treatment appealing in younger patients but soft tissue integrity, body habitus, medical comorbidities, confounding injuries and the ability of family to appropriately care for the patient are important considerations in guiding appropriate treatment.

## Patient Transportation

Herman et al. evaluated the utilization of hip spica car seats for transportation of patients after casting. They reported that only 9% of caretakers used hip spica seats even after formal recommendation.<sup>31</sup> There are also proponents for hip spica casting without incorporation of the well limb (unilateral spica casting), which may improve the ability to transport patients safely after cast treatment as specialized car seats may then not be necessary. Transport for patients treated with surgical stabilization is less of an issue.

## Timing of Treatment

The current trend is toward definitive stabilization within 24 hours whenever possible. Patient comfort and parent satisfaction are important considerations here. Buckley concluded that prompt stabilization and reduction can help to decrease pain, hospital stay and overall complications.<sup>32</sup> Hedequist et al. concluded that the timing of stabilization of femur fractures had no apparent effect on pulmonary complications.<sup>33</sup> Other factors that can influence the timing of definitive stabilization include soft tissue integrity, neurovascular status and poly-trauma. Early stabilization results in earlier mobilization and can decrease hospital length of stay. This may also reduce the risk of developing venous thromboembolism and fat-emboli syndrome.

## Venous Thromboembolism (VTE)

Vavilala et al. performed a large retrospective study looking at prevalence and risk factors for VTE in trauma patients less than 16 years of age. They found that 0.08% (45/58,716) of patients developed VTE. Those that did were older and had higher injury severity scores (ISS). Patients who were more likely to have VTE included those who had central lines, severe vascular injuries, spinal cord injury, and pelvic injuries. They concluded that VTE chemoprophylaxis is not routinely recommended in pediatric population. An exception may be for those with ISS greater than 25. This ISS for an isolated femur shaft fracture is 3.<sup>34</sup>

## **Summary**

Nonoperative treatment options include Pavlik harness use for patients less than 6 months of age. Early closed manipulation and hip spica casting is the primary treatment for patients 6 months to 5 years old with less than 2 cm of fracture shortening. Traction is, in general, out of favor but is still an option for management.

Operative management options include the use of flexible/elastic nails for patients between 5 and 11 years old weighing less than 49 kg (108 lbs). Flexible interlocking nail (FIIN) is an option for patients between 5 and 11 years old weighing more than 45.5 kg (100 lbs) and too

skeletally immature for rigid nailing. Rigid trochanteric nailing is an option for patients older than 11 years. Indirect reduction with submuscular bridge plating is an option for operative comminuted fractures for patients older than 5 years. Direct open reduction with compressive plating is an option for fractures not amenable to closed or indirect reduction. External fixation is useful when skin integrity is compromised and for damage control but has a higher rate of malunion and pin tract infection.

Other critical steps to appropriately manage pediatric femur shaft fractures are to rule out child abuse and strive for definitive stabilization within 24 hours. VTE chemoprophylaxis is not routinely recommended for pediatric patients with isolated femur fractures but may be considered in specific situations. It is important to evaluate the ability of caretakers to safely and appropriately transport and manage patients treated in hip spica casts. Future studies are needed to fill gaps in current AAOS treatment guidelines. There is no substitute for sound clinical judgment and individual patient factors must ultimately dictate the most appropriate management for these patients.

## **References**

1. Hinton RY, Lincoln A, Crockett MM, Sponseller P, Smith G. Fractures of the femoral shaft in children: incidence, mechanisms, and sociodemographic risk factors. *J Bone Joint Surg Am.* 1999;81:500-509.
2. Rewers A, Hedegaard H, Lezotte D, et al. Childhood femur fractures, associated injuries, and sociodemographic risk factors: a population-based study. *Pediatrics.* 2005;115:e543-e552.
3. Sahlin Y. Occurrence of fractures in a defined population: a 1-year study. *Injury.* 1990;21:158-160.
4. McCartney D, Hinton A, Heinrich SD. Operative stabilization of pediatric femur fractures. *Orthop Clin North Am.* 1994;25:635-650.
5. Henderson J, Goldacre M, Yeates D. Use of hospital inpatient care in adolescence. *Arch Dis Child.* 1993;69:559-563.
6. Femoral Shaft Fractures Guideline Team. Evidence-based care guideline for medical management of femoral shaft fractures. Guideline 22, 1-19. 2006. Cincinnati Children's Hospital Medical Center. [http://asr.regione.emilia-romagna.it/trauma/letteratura/linea\\_guida/altre\\_istituzioni/cincinnati\\_childrens\\_hospital\\_medical\\_center/2006/cchmc\\_01.pdf](http://asr.regione.emilia-romagna.it/trauma/letteratura/linea_guida/altre_istituzioni/cincinnati_childrens_hospital_medical_center/2006/cchmc_01.pdf).
7. Hougaard K. Femoral shaft fractures in children: a prospective study of the overgrowth phenomenon. *Injury.* 1989;20:170-172.
8. Martin-Ferrero MA, Sanchez-Martin MM. Prediction of overgrowth in femoral shaft fractures in children. *Int Orthop.* 1986;10:89-93.
9. Meals RA. Overgrowth of the femur following fractures in children: influence of handedness. *J Bone Joint Surg Am.* 1979;61:381-384.
10. Salter RB, Harris WR. Injuries Involving the epiphyseal plate. *J Bone Joint Surg Am.* 1963;45:587-622.

11. Slong TF, Audige L; AO Pediatric Classification Group. Fracture and dislocation classification compendium for children: the AO pediatric comprehensive classification of long bone fractures (PCCF). *J Orthop Trauma*. 2007;21(10 Suppl):S135-160.
12. Kocher MS, Sink EL, Blasler RD. Treatment of pediatric diaphyseal femur fractures. *J Am Acad Orthop Surg*. 2009;17:718-725.
13. AAOS Clinical Practice Guidelines. Treatment of Pediatric Diaphyseal Femur Fractures: Guideline and Evidence Report. June 19, 2009; 1-121. [www.aaos.org/Research/guidelines/PDFFguideline.pdf](http://www.aaos.org/Research/guidelines/PDFFguideline.pdf).
14. Rockwood CA, Wilkins KE, Beaty JH. *Fractures in Children*. 4th ed. Philadelphia, PA: Lippincott Williams and Wilkins; 1996.
15. Stannard JP, Christensen KP, Wilkins KE. Femur fractures in infants: a new therapeutic approach. *J Pediatr Orthop*. 1995;15:461-466.
16. Podeszwa DA, Mooney JF III, Cramer KE, Mendelow MJ. Comparison of Pavlik harness application and immediate spica casting for femur fractures in infants. *J Pediatr Orthop*. 2004;24:460-462.
17. Wolff CR, James P. The prevention of skin excoriation under children's hip spica casts using the goretex pantaloons. *J Pediatr Orthop*. 1995;15:386-388.
18. Rasool MN, Govender S, Naidoo KS. Treatment of femoral shaft fractures in children by early spica casting. *S Afr Med J*. 1989;76:96-99.
19. Flynn JM, Schwend RM. Management of pediatric femoral shaft fractures. *J Am Acad Orthop Surg*. 2004;12:347-359.
20. Buechsenschuetz KE, Mehlman CT, Shaw KJ, Crawford AH, Immerman EB. Femoral shaft fractures in children: traction and casting versus elastic stable intramedullary nailing. *J Trauma*. 2002;53:914-921.
21. Flynn JM, Luedtke LM, Ganley TJ, et al. Comparison of titanium elastic nails with traction and a spica cast to treat femoral fractures in children. *J Bone Joint Surg Am*. 2004;86:770-777.
22. Moroz LA, Launay F, Kocher MS, et al. Titanium elastic nailing of fractures of the femur in children: predictors of complications and poor outcome. *J Bone Joint Surg Br*. 2006;88-B:1361-1366.
23. Jencikova-Celerin L, Phillips JH, Werk LN, et al. Flexible interlocked nailing of pediatric femoral fractures: experience with a new flexible interlocking intramedullary nail compared with other fixation procedures. *J Pediatr Orthop*. 2008;28:864-873.
24. Keeler KA, Dart B, Luhmann SJ, et al. Antegrade intramedullary nailing of pediatric femoral fractures using an interlocking pediatric femoral nail and a lateral trochanteric entry point. *J Pediatr Orthop*. 2009;29:345-351.
25. Buford D Jr., Christensen K, Weatherall P. Intramedullary nailing of femoral fractures in adolescents. *Clin Orthop Relat Res*. 1998;350:85-89.
26. Kanellopoulos AD, Yiannakopoulos CK, Soucacos PN. Closed, locked intramedullary nailing of pediatric femoral shaft fractures through the tip of the greater trochanter. *J Trauma*. 2006;60(1):217-222.
27. Beaty JH, Austin SM, Warner WC, et al. Interlocking intramedullary nailing of femoral-shaft fractures in adolescents: preliminary results and complications. *J Pediatr Orthop*. 1994;14:178-183.
28. Agus H, Kalenderer O, Eryanilmaz G, Omeroglu H. Biological internal fixation of comminuted femur shaft fractures by bridge plating in children. *J Pediatr Orthop*. 2003;23:184-189.
29. Lewallen RP, Peterson HA. Nonunion of long bone fractures in children: a review of 30 cases. *J Pediatr Orthop*. 1985;5:135-142.
30. Barlas K, Beg H. Flexible intramedullary nailing versus external fixation of paediatric femoral fractures. *Acta Orthop Belg*. 2006;72:159-163.
31. Herman MJ, Abzug JM, Krynetskiy EE, et al. Motor vehicle transportation in hip spica casts: are our patients safely restrained? *J Pediatr Orthop*. 2011;31:465-468.
32. Buckley SL. Current trends in the treatment of femoral shaft fractures in children and adolescents. *Clin Orthop Relat Res*. 1997;338:60-73.
33. Hedequist D, Starr AJ, Wilson P, et al. Early versus delayed stabilization of pediatric femur fractures: analysis of 387 patients. *J Orthop Trauma*. 1999;13:490-493.
34. Vavilala MS, Nathens AB, Jurkovich GJ, et al. Risk factors for venous thromboembolism in pediatric trauma. *J Trauma*. 2002;52:922-927.

# Chronic Injuries Due to Running and a Possible Cure with the Barefoot Style

Daniel M. Hoopes MD<sup>1</sup>

1. UNM Department of Orthopaedics & Rehabilitation

## Principles of Gait

The normal human walking gait cycle can be thought of as an inverted pendulum where the body swings over the lower extremity during stance phase.<sup>1</sup> The other part of the cycle is swing phase where the lower extremity is brought forward to repeat the stance phase once more. A portion of the gait cycle of either lower extremity overlaps with the other and this is called the double-stance phase.<sup>2,3</sup> Other gait cycles include running and sprinting.<sup>1</sup> These both involve something called a double-float phase where neither extremity is in contact with the ground.<sup>3</sup> These gait cycles also do not have a double-stance phase. Progression from walking to running to sprinting also involves a relative shortening of the stance phase, relative lengthening of the swing phase, and a shortening of the time it takes to complete a full gait cycle.<sup>1,3</sup>

## Chronic Injury Theory

Chronic injury to the human body is related to classical mechanics principles.<sup>4,5</sup> Tensile forces (stress) cause tissue to elongate (strain). Energy is stored as elastic potential energy and if this deformation is within the physiologic range, the tissue will recoil and return most of the energy that had been absorbed during tissue stretching. Ninety five percent of this energy is returned to the system in the form of kinetic energy and the rest is dissipated as heat from friction in normal physiologic conditions.

Repetitive stress injuries, which are common amongst runners result from an accumulation of microdamage from repeated application of stress.<sup>3,6</sup> This leads to strain, or deformation. At first, this falls within the physiologic range of elastic deformation. With excessive running, bones can be subjected to supraphysiologic plastic deformation and soft tissues can be subjected to supraphysiologic viscous deformation. High strain and high rates of application of that strain can lead to fatigue damage.<sup>6,7</sup> In bone, this manifests as microcracks, and as failures of collagen cross-links in soft tissue. These small-scale failures allow elastic hysteresis, which is the difference between the energy required (stress) to generate a given strain (deformation) and the elastic energy stored for a given cycle of loading. In other words, the accumulation of microdamage makes bones and soft tissues weaker and then less force is required to further the damage.

Repeated applications of this supraphysiologic load generates repeated cycles of hysteresis and leads to unrecoverable energy loss during unloading.<sup>6</sup> That energy is now being converted to tissue damage, or injury. Elastic hysteresis is more pronounced with higher rates of loading. Imagine the difference between being hit on the head with

a 5 pound metal hammer versus a 5 pound padded, soft mallet. The total energy absorbed can be the same while the resulting damage is very different.

In bone, if fatigue damage accumulates more rapidly than remodeling can remove it, then fatigue failure may occur. Fatigue failure is also known as a stress fracture.<sup>8</sup> In soft tissues such as tendons and ligaments, stresses that cause supraphysiologic strains can initiate microscopic failure as collagen cross-links begin to fail. Repeated strain levels or a single strain above a given magnitude and/or rate can cause tensile failure of the fibers and shear failure.<sup>6</sup> This catastrophic failure is manifested as tendon or ligament rupture.

## Chronic Running Injuries

Chronic running injuries include a wide variety of ailments, but the most common are muscle strains, patellofemoral pain syndrome, IT band syndrome, Achilles tendinopathies, plantar fasciitis, stress fractures, and medial tibial stress syndrome.<sup>6,8</sup> This last injury had previously been included under the term "Shin Splints." "Shin splints" are now either categorized as medial tibial stress syndrome (MTSS) and tibial periostitis.<sup>9</sup> MTSS specifically excludes exertional compartment syndrome and tibial stress fractures, which are also common chronic running injuries.<sup>9</sup> Acute traumatic injuries are different class of injury completely and will not be discussed here.

Risk factors for running injuries have been studied extensively. The number one risk factor is just being a runner.<sup>3,4,10</sup> Observational studies conclude that between 20% and 80% of runners have some kind of injury per year.<sup>5</sup> Therefore, after running for many years, essentially all runners will have some kind of injury at some point.<sup>3,10</sup> These injuries are predominantly about the knee. Extensive review papers attempting to identify risk factors for running injuries are only able to find strong evidence that a history of injury and greater distance training per week are predictive of future injury.<sup>3</sup> All other factors, those that most people might say could be related to running injury (such as physiological anomalies, level of experience, days trained per week, age of shoes, etc) have only limited or evidence. Essentially all of the commonly listed risk factors for injury are highly questionable.

New studies have taken a different approach in attempting to identify the cause of chronic running injuries: examine the stride and impact characteristics of runners.<sup>6,7</sup> A cross sectional study examining the running mechanics and anatomy of runners who had experienced tibial stress fractures versus matched runners who had not showed that the only significant differences were in

vertical loading rates and tibial shock at foot strike.<sup>11</sup> The peak impact did not change, but the slope of the line was steeper. Recall the 5 pound steel hammer versus the mallet.

### **The Barefoot Style**

Much of the research done on running mechanics recently has come to light due to a best-selling popular press book by Christopher McDougall called *Born to Run*.<sup>12</sup> Many runners and non-runners now discuss the merits and demerits of barefoot running, and controversy abounds. Many arguments on both sides of the issue begin (and sometimes end) with anecdotal evidence. However, recent, and some older less well-known studies can inform the anecdotal discussions.

Vin Lananna of Oregon is one of the most successful college track coaches ever. He has said, "When my runners train barefoot, they run faster and suffer fewer injuries."<sup>12</sup> A study by Richards et al. in 2009 in the *British Journal of Sports Medicine* systematically reviewed the evidence for prescription of distance running shoes.<sup>13</sup> Specifically, evidence was sought to support the use and recommendation of running shoes featuring elevated heels and pronation control systems tailored to the individual's foot type. No studies meeting criterion were found. Moreover, evidence about the modern running shoe, which typically features pronation control and elevated/cushioned heels (PCECH shoes), showed either inconclusive/conflicting evidence, or evidence to the contrary.<sup>13</sup> Evidence for prescribing PCECH shoes can be found in 2 papers from 2005, yet these are only expert opinions.<sup>14</sup> Recommendations from multiple international and national sports agencies almost always include references to specific models of Asics shoes, 1 of which has openly acknowledged a sponsorship arrangement with the company. In conclusion, PCECH shoes have never been tested in randomized controlled trials and their effects on injury rates, enjoyment, performance, osteoarthritis risk, physical activity levels and overall athlete health and well-being are unknown. The oft-repeated recommendation by physicians (and other professionals) to runners to use modern running shoes is not evidence-based.

However, if there is a controversy about running shoes and support for the modern running shoe is questioned, what of the evidence for barefoot style running? These studies do exist, and they mostly focus on foot strike characteristics.<sup>15-17</sup> The 2 main types of running foot strikes are the heel strike and the forefoot strike.<sup>4</sup> In the heel strike, a dorsiflexed ankle leads to a relatively stiff and noncompliant limb contacting the ground in front of the center of gravity of the runner. Approaching midstance, the relatively weak dorsiflexion muscles in the leg (tibialis anterior and toe extensors) are loaded eccentrically as they resist plantarflexion forces. In forefoot strikes, a plantarflexed ankle and inverted foot lead to a relatively

supple and compliant limb contacting the ground under the center of gravity of the runner. Approaching midstance, the relatively large and powerful plantarflexion muscles in the leg (gastroc-soleus complex, tibialis posterior and toe flexors) are loaded eccentrically as they resist dorsiflexion forces and allow for a physiologic pronation movement. In addition, the heel strike does not really load the arch of the foot at all and the forefoot strike depends on and encourages both the transverse and longitudinal arches of the foot.<sup>4</sup>

Another anecdote comes from Arthur Lydiard, who taught Nike cofounder Bill Bowerman about jogging and was a much more successful running coach himself. "We ran in canvas shoes. We didn't get plantar fasciitis, we didn't pronate or supinate, we might have lost a bit of skin from the rough canvas when we were running marathons, but generally speaking, we didn't have foot problems. Paying several hundred dollars for the latest in high-tech running shoes is no guarantee you'll avoid any of these injuries and can even guarantee that you will suffer from them in one form or another."<sup>18</sup>

A study by Daoud et al. in *Medicine & Science in Sports & Exercise* in 2012 retrospectively analyzed foot strikes and injury rates in endurance runners.<sup>4</sup> Analysis of these collegiate middle and long-distance runners showed that those who exhibited a rearfoot strike had double the rate of repetitive stress injuries per year.<sup>4</sup> This relative risk substantially dwarfs any other finding by any other study to date looking at risk factors for chronic injury. As this study was retrospective, the authors agreed that a prospective study would help to identify cause and effect of foot strike with chronic running injury.

A prospective study by Milner et al. attempted to answer this question.<sup>11</sup> Impact loads of rearfoot strike runners who go on to develop a running injury was compared to those who have never been injured. After 2 years, it was found that impact loading rate and tibial shock amplified the risk of developing a running-related injury.<sup>11</sup>

### **The Null Hypothesis**

Many who hear about barefoot-style running dismiss it as a fad that will blow over soon. These people, who include highly trained orthopaedists in sports and other disciplines fail to grasp that the true fad is shoes, not the lack of them. The principle of the null hypothesis is informative.<sup>17</sup> The null hypothesis is the general, or default position. The null hypothesis can never be proven and a set of data can either reject the null hypothesis or fail to reject it. In this light, which is the null hypothesis, barefoot and barefoot style running or shod running in the modern PCECH shoes?

A paper called "The Evolution of Marathon Running Capabilities in Humans" posits that today's

humans are descendents of an elite distance running population.<sup>19</sup> Cursors (animals with specializations for running) are either predators or prey. Humans are outprinted by cursors because we cannot gallop. Our running gait is most similar to quadruped trotting, which does not permit fast speeds in quadrupeds.<sup>19</sup> Our endurance running speed of 4 to 6 meters per second (m/s) exceeds the trot/gallop transition speed of any other mammal. This is significant because trotting is the quadruped endurance gait. Unless conditions are very cool, quadrupeds will quickly overheat and fatigue while galloping. For example, dogs and horses can maintain gallop speeds of 3.8 and 9 m/s respectively for only about 15 minutes. In long distance runs, horses are constrained to a canter, or slow gallop of 5.8 m/s and can maintain this for only about 20 km per day. Thus, at marathon-length distances, humans can outrun almost any other mammal.<sup>19</sup> A number of races across the world pit humans against horses. One such race in Wales had humans win 2 of the 9 races between 2003 and 2011. However, in the races humans lost, it is usually by less than 15 minutes, and sometimes by only seconds.

The authors theorize that humans evolved these capabilities about 2 million years ago with *Homo Erectus*.<sup>19</sup> This might explain the previously enigmatic reproductive supremacy of genus *Homo* over *Australopithecus* who was thought to be smarter, stronger, and bigger. Persistence hunting involves a hunter in hot/arid conditions who kills an animal by following it and keeping it above its trot/gallop transition for several hours. The animal is eventually driven to hyperthermia and essentially lays down before the hunter, unable to continue fleeing. This hunting method is still practiced by some Kalahari bushmen and a few other aboriginal tribes in remote parts of the world.<sup>19</sup>

### Primitive Versus Modern

Many might say that stories and theories about cavemen are interesting, but they should not guide decisions about health and fitness today because their life expectancy was rarely past the second decade. However, we cannot necessarily claim that our feet are healthier than more primitive peoples. Dr. Udaya Rao, in India once said: "In our clinic we have never seen a child from the farming community or from the family of a manual laborer who complained of flat foot. The few who do...are from affluent urban families and they all wear shoes."<sup>19</sup>

In fact, multiple studies dating back to 1958 support this statement.<sup>20-22</sup> The use of footwear has been linked to increasing the risk of hallux valgus (Sim-Fook in 1958 and Shine in 1965)<sup>20,21</sup> and decreasing hallux varus (Joseph 1987).<sup>22</sup> Two observational studies looked at the rates of flat feet in India. They found that earlier shoe wear (more than 8 hours per day before the age of 6) correlated

with significantly higher rates (about double) of flexible flat feet.<sup>19,22,23</sup>

Even modern shoe "experts" have begun to realize that their solution to runners' problems might not be the right one. Jeff Pisciotta, a senior researcher at Nike Sports Research Lab observed: "When you put a shoe on, it starts to take over some of the control... We found pockets of people all over the globe who are still running barefoot, and what you find is that during propulsion and landing, they have far more range of motion in the foot and engage more of the toe. Their feet flex, spread, splay, and grip the surface, meaning you have less pronation and more distribution of pressure."<sup>12</sup>

D'AoÚt et al., in a 2009 study, noted that habitual footwear use leads to higher concentrations of peak foot pressures in small areas of the fore and hind foot. In addition, habitually barefoot people have a flatter initial foot placement, correlating with the difference between forefoot strike runners compared to rearfoot strike runners.<sup>16</sup>

### Evolutionary Medicine

As noted, some argue that humans have been running for millions of years, and this running was done barefoot on hard, rough surfaces. The lack of any decrease in running-related injuries over the last 30 years has led some to question the modern approach to a problem that essentially all runners will encounter at some point. Lieberman hypothesized in 2012 that the human body adapted to running with a barefoot style whose kinematic characteristics generate less forceful impact peaks, use more proprioception, and that this may strengthen the feet to help avoid injury.<sup>17</sup> A key component of evolutionary medicine is the Evolutionary Mismatch Hypothesis, which states that rapid changes in culture can outpace natural selection, often to the detriment of our health.<sup>17</sup> For example, agricultural living changed lifestyle and diet rapidly and allowed us too great a supply of historically rare fats and sugars that have contributed to our epidemic of obesity. The Evolutionary Mismatch Hypothesis may apply to shoes and running.

Lieberman shows how modern shoes encourage an overstride and heel strike whose rate of loading of ground reaction forces as they relate to the moment arm involved are 3 to 4 times those of a forefoot strike with a short stride contacting the ground below the center of gravity of the runner.<sup>17</sup> The differences between the 2 strides and the difficulty of running in a more natural manner with a modern shoe can be understood by imagining someone trying to jump using their heels instead of their toes. Running is similar to jumping repeatedly. Lieberman also discusses the anatomical adaptations we are losing by using shoes. Eccentric loading of muscles is known to cause more muscle hypertrophy and strengthening. Shoes insulate



the foot's intrinsic and extrinsic muscles from eccentric loading. In addition, heel strike places the metatarsals on cantilever bend while the "arch support" of modern shoes counteracts the foot's natural 3-point bending mechanics and resulting arch lengthening which would have engaged the intrinsics in eccentric loading.<sup>17</sup> Bruggeman in 2005 showed that training for 5 months in minimalist shoes led to significantly larger and stronger extrinsic musculature in the leg which supports the structure of the foot.<sup>25</sup>

Another question, aside from the question of barefoot style running relating to injury, is whether it affects performance. Jenkins in 2010 showed that barefoot running has no appreciable negative effects on performance.<sup>15</sup> Indeed, Abebe Bikila and Zola Budd have set world records in the marathon and shorter distances running barefoot. Calculations show that barefoot running has a 1% to 4% lower energy cost of transport and that minimalist running (taking into account stride rate, shoe mass, and strike type) has a 2.5-3.3% lower energy cost of transport.<sup>15</sup>

### **The Transition Back to the "Evolutionary Default"**

Since this topic has burst onto the scene in the last few years, many runners have become "converted" and transitioned, only to trade one injury set for another. These injuries are almost always associated with a too-rapid transition. A forefoot strike places higher loads on the plantarflexion muscles and Achilles tendon which can lead to calf strains and Achilles tendinopathies. In addition, the increased bending forces on the midfoot and forefoot require strong metatarsals and extensor/dorsiflexor musculature to counteract the stronger flexor/plantarflexor muscles. In addition, poor form, including overstride, can bring impact peaks load rates of forefoot strike runners close to the high magnitude of rearfoot strike runners.

Defined strategies for transitioning to barefoot style running are outlined by both Vibram (the company whose FiveFinger<sup>®</sup> boating shoes have found a second life as a popular barefoot style running shoe) and Harvard's Lieberman (who published many of the studies mentioned in this article). Vibram's plan uses a percentage of the runner's normal distance and Lieberman's plan outlines specific distances to be run.<sup>26,27</sup> Both have a range for slow and fast transitions, but neither plan transitions the runner sooner than 2 months and both have provisions to slow or pause the transition if any soreness or pain is experienced. Indeed, the median transition times for each plan are closer to 3 months or much longer than this with the Lieberman plan. This is supported by a 2012 case series on injuries observed in 10 minimalist runners by a few foot and ankle-trained orthopaedic surgeons.<sup>28</sup> The injuries they saw correlate with the biomechanical reasoning discussed in the preceding paragraph. All of the runners transitioned too quickly and half had no transition time at all and

merely switched all at once. The admission that most of them sought softer surfaces to run on is actually evidence of poor form, since good form should allow for lower peak loading rates to the lower extremity with barefoot running on concrete.

### **How Did We Get to Where We Are?**

Some podiatrists see the human foot as "nature's mistake" and that it is their job to fix it. Before orthopaedists scoff, remember that many spine surgeons see the lumbar spine as "nature's mistake." Dr. Murray Weisenfeld, a leading sports podiatrist wrote the book *The Runner's Repair Manual*, one of the top-selling foot-care books of all time.<sup>29</sup> In the introduction, he states: "Man's foot was not originally designed for walking, much less running long distances...Man's foot is not yet completely adapted to the ground. Only a portion of the population has been endowed with well ground-adapted feet."<sup>29</sup>

Bill Bowerman, the University of Oregon track coach, was one of the winningest coaches in college track history. He did not even start running until age 50, which was 14 years after having already been first a football, then a track coach at Oregon. He discovered jogging after being introduced by Arthur Lydiard in Australia. He then wrote the best-selling book *Jogging* that ignited a jogging/running craze in the US.<sup>30</sup> After experimenting with shoe design, he founded Nike, whose shoes were initially minimalist shoes. These shoes soon morphed into shoes with highly padded heels and large forefoot/heel height difference. Soon after this, the shoes incorporated early attempts at "motion control" in order to counteract the pronation forces induced by the tall, wide heel. Other shoe companies followed suit.

Running form has changed since the invention of the modern running shoe, pioneered by Bowerman's Nike shoes. These shoes could have attracted converts from the previous, classical running style since they might give the benefit of instantaneous speed at the cost of chronic injury by allowing a longer stride than biology does alone. In Fred Wilt's 1959 book, he detailed the running techniques of 80 of the world's fastest runners.<sup>31</sup> "The forward foot moves toward the track in a downward, backward, 'stroking' motion (not punching or pounding) and the outer edge of the ball of the foot makes first contact with the track. Running progression results from these forces pushing behind the center of gravity of the body."<sup>31</sup>

In Bowerman's 1977 *Jogging*, he predicts that the "heel-to-toe [stride would be] the least tiring over long distances."<sup>30</sup> The longer stride might allow for temporary speed benefits, even if it is less or more tiring over distances. However, if these shoes are used over the course of a lifetime and throughout all training for running, then they could fundamentally change feet from their evolutionarily customized role as the robust contact points of a running species.

## What Can I Tell My Patients?

The American Academy of Orthopaedic Surgeons Clinical Guideline on the Treatment of Osteoarthritis (OA) of the Knee gives specific guidance for how orthopaedic surgeons should counsel patients.<sup>31</sup> Under “Patient Education and Lifestyle Modification,” recommendation #1 outlines some limitations and activity modification options: We suggest patients with symptomatic OA of the knee be encouraged to participate in self-management educational programs such as those conducted by the Arthritis Foundation, and incorporate activity modifications (e.g. walking instead of running; alternative activities) into their lifestyle.<sup>31</sup>

Recommendation #4 goes on to elaborate positive options for fitness: We recommend patients with symptomatic OA of the knee be encouraged to participate in low-impact aerobic fitness exercises.<sup>31</sup>

Thus, in light of the conclusions from the above studies, one activity with quantitatively lower impact than running with a heel strike would be barefoot-style running. A possible modification of these official guidelines might look like this: Patients with osteoarthritis about the knee may be encouraged to run using a barefoot style, either beginning or transitioning slowly and while paying attention to possible transition injuries.

## Summary and Implications

Recent interest in minimalist or barefoot-style running was largely sparked by a best-selling book on the subject, *Born to Run*. This has led to a rediscovery of existing research, and also an interest in new research on the topic of barefoot-style running. Chronic running injuries are likely due to high loading rates combined with loading characteristics that are mismatched to human physiology that may have been customized for long-distance running by eons of natural selection. Even though the human species may be the best long-distance running mammal on the planet, a running form that is evolutionarily mismatched to the optimized biomechanics of humans may be what is being used. This mismatch might give the short-term benefit of speed at the long-term cost of chronic injury. Whether or not barefoot-style running is slower or faster than running with modern shoes is still unresolved.

Critics of the barefoot-style point out that even the Africans setting world records in the marathon are using modern shoes and taking longer strides, while often exhibiting a heel strike stride. This does not change the fact that they likely grew up running barefoot. Runners who have run barefoot their entire lives will have a significantly different physiology, including specific bone modeling, intrinsic and extrinsic foot supporting musculature, and running style. These runners, whose feet and lower extremities are much more robust than those of

a Westerner who has used shoes which encouraged a non-physiologic stride, will be able to withstand the abnormal stresses placed on their anatomy much better. They will also likely be able to take advantage of any speed benefits which a longer stride could afford, even if it is at the expense of a higher risk of chronic injury in runners without the robust physiology they have.

One key point critics have the most difficult time confronting is that the null hypothesis, or default, is barefoot-style running and that evidence must either reject it or fail to reject it. Westerners grow up wearing shoes from infancy and think that walking and running with modern shoes is more natural than not using them at all. Just like a fish does not notice the water it has always known, Westerners are blinded by the reality in which they have been immersed all their lives. Barefoot running is the null hypothesis, yet more research is still needed to disabuse physicians and laypeople alike that it may be superior to shoes respecting both chronic injury, and performance.

## References

1. Novacheck TF. The biomechanics of running. *Gait Posture*. 1998;7(1):77-95.
2. Chambers HG, Sutherland DH. A practical guide to gait analysis. *J Am Acad Orthop Surg*. 2002;10(3):222-231.
3. Novacheck TF. Running injuries: a biomechanical approach. *Instr Course Lect*. 1998;47:397-406.
4. Daoud AI, Geissler GJ, Wang F, Saretsky J, Daoud YA, Lieberman DE. Foot strike and injury rates in endurance runners: a retrospective study. *Med Sci Sports Exerc*. 2012;44(7):1325-1334.
5. Lun V, Meeuwisse WH, Stergiou P, Stefanyshyn D. Relation between running injury and static lower limb alignment in recreational runners. *Br J Sports Med*. 2004;38(5):576-580.
6. Davis IS, Bradley BB, Mullineaux D. Do impacts cause running injuries? A prospective investigation. *Am Soc Biomech Annual Meeting*. 2010.
7. Chavet P, Lafortune MA, Gray JR. Asymmetry of lower extremity responses to external impact loading. *Hum Movement Sci*. 1997;16(4):391-406.
8. Shindle MK, Endo Y, Warren RF, et al. Stress fractures about the tibia, foot, and ankle. *J Am Acad Orthop Surg*. 2012;20(3):167-176.
9. Galbraith RM, Lavalley ME. Medial tibial stress syndrome: conservative treatment options. *Curr Rev Musculoskelet Med*. 2009;2(3):127-133.
10. van Gent RN, Siem D, van Middelkoop M, van Os AG, Bierma-Zeinstra SM, Koes BW. Incidence and determinants of lower extremity running injuries in long distance runners: a systematic review. *Br J Sports Med*. 2007;41(8):469-480; discussion 480.

11. Milner CE, Ferber R, Pollard CD, Hamill J, Davis IS. Biomechanical factors associated with tibial stress fracture in female runners. *Med Sci Sports Exerc.* 2006;38(2):323-328.
12. McDougall C. *Born To Run: A Hidden Tribe, Superathletes, and the Greatest Race the World Has Never Seen.* 1st ed. New York: Alfred A. Knopf; 2009.
13. Richards CE, Magin PJ, Callister R. Is your prescription of distance running shoes evidence-based? *Br J Sports Med.* 2009;43(3):159-162.
14. Nigg BM. *Biomechanics of Sports Shoes.* Calgary (Canada): Topline Printing; 2010.
15. Jenkins DW, Cauthon DJ. Barefoot running claims and controversies: a review of the literature. *J Am Podiatr Med Assoc.* 2011;101(3):231-246.
16. D'Août K, Pataky TC, De Clercq D, Aerts P. The effects of habitual footwear use: foot shape and function in native barefoot walkers. *Footwear Sci.* 2009;1(2):81-94.
17. Lieberman DE. What we can learn about running from barefoot running: an evolutionary medical perspective. *Exerc Sport Sci Rev.* 2012;40(2):63-72.
18. Lydiard A. *Running to the Top.* 3rd ed. United Kingdom: Meyer & Meyer Sport; 2011.
19. Lieberman DE, Bramble DM. The evolution of marathon running : capabilities in humans. *Sports Med.* 2007;37(4-5):288-290.
20. Rao UB, Joseph B. The influence of footwear on the prevalence of flat foot. A survey of 2300 children. *J Bone Joint Surg Br.* 1992;74(4):525-527.
21. Sim-Fook L, Hodgson AR. A comparison of foot forms among the non-shoe and shoe-wearing Chinese population. *J Bone Joint Surg Am.* 1958;40-A(5):1058-1062.
22. Shine LB. Incidence of hallux valgus in a partially shoe-wearing community. *Br Med J.* 1965;1(5451):1648-1650.
23. Joseph B, Chacko V, Abraham T, Jacob M. Pathomechanics of congenital and acquired hallux varus: a clinical and anatomical study. *Foot Ankle.* 1987;8(3):137-143.
24. Sachithanandam V, Joseph B. The influence of footwear on the prevalence of flat foot. A survey of 1846 skeletally mature persons. *J Bone Joint Surg Br.* 1995;77-B(2):254-257.
25. Bruggeman GP, Potthast W, Braunstein B, Niehoff A. Effect of increased mechanical stimuli on foot muscles functional capacity. Paper presented at: ISB Congress, American Society of Biomechanics 2005; Cleveland.
26. Vibram FiveFingers. Barefoot running [Web page]. [http://www.vibramfivefingers.com/education/barefoot\\_running.htm](http://www.vibramfivefingers.com/education/barefoot_running.htm). Accessed May 20, 2013.
27. Biomechanics of foot strikes and applications to running barefoot or in minimal footwear [homepage]. Tips on transitioning to forefoot or midfoot striking. <http://www.barefootrunning.fas.harvard.edu/5BarefootRunning&TrainingTips.html>. Accessed May 20, 2013.
28. Ridge ST, Johnson AW, Mitchell UH, et al. Foot bone marrow edema after 10-week transition to minimalist running shoes. *Med Sci Sports Exerc.* Accepted for publication January 7, 2013.
29. Weisenfeld MF, Burr B. *The Runners' Repair Manual : A Complete Program for Diagnosing and Treating Your Foot, Leg, and Back Problems.* New York: St. Martin's Press; 1980.
30. Bowerman WJ, Harris WE. *Jogging: A Physical Fitness Program for All Ages.* Grosset and Dunlap; 1967.
31. Wilt F. *How They Train: Long Distances.* Tafnews Press; 1959.
32. Richmond J, Hunter D, Irrgang J, et al. American Academy of Orthopaedic Surgeons clinical practice guideline on the treatment of osteoarthritis (OA) of the knee. *J Bone Joint Surg Am.* 2010;92(4):990-993.

# Report from the Division of Physical Therapy

The UNM Division of Physical Therapy (PT) is going strong as it approaches its 40th year anniversary in 2014. In the course of the 40 years more than 700 students have received entry level degrees in PT from the program and successfully passed the national PT licensure examination. Over 75% of our graduates practice in New Mexico. Since 1974 the program has transitioned from offering a 2-year Bachelor of Science in Physical Therapy degree, to a 2.5-year Master of Physical Therapy degree in 2000, to the 3-year Doctor of Physical Therapy (DPT) degree in 2009.

Many of the PT faculty have received UNM's School of Medicine Excellence in Teaching and Curricular Leadership awards in the category of Diagnostic and Therapeutic Sciences programs. As of 2013, 5 of the 8 faculty members with PhDs had been promoted with tenure to associate professor or professor, and 2 faculty on the clinical track were promoted to associate professor.

Faculty have grown more involved with important research studies ranging from basic science to clinical projects, including receipt of both intra- and extra-mural grant funding. Over the years several studies have been presented at national and international professional conferences and many articles have been published from this research.

An exciting development from 2010- 2012 was expansion of the program's motion analysis equipment to include an updated 8-camera system with force-plates as well as a Gait Rite mat system. This equipment was installed in a permanent location on the first floor of the Health Sciences and Services Building in 2012. The state of the art lab was named The Fred Rutan Center for Gait and Motion Analysis in honor of a previous Program Director. The new laboratory provides numerous opportunities for inter-professional clinical and research activities for the PT faculty. Collaborations have begun with the Departments of Orthopaedics and Neurology and Carrie Tingley Hospital, with others on the horizon.

The curricular emphasis is on the 4 primary treatment areas in physical therapy practice: musculoskeletal, neuromuscular, cardiovascular/pulmonary, and integumentary. With the inception of the DPT curriculum in 2009, content was expanded in the areas of Gender Health, Differential Diagnosis for Physical Therapists, Evidence Based Practice, Imaging, Pharmacology, and psychosocial/cultural aspects of patient care. Students now engage in 36 weeks of clinical experiences in acute care, orthopaedics, neurology/pediatrics, and 1 elective setting, at 4 of approximately 200 clinical sites. Concluding their didactic and clinical content, students develop and present a capstone project based on a clinical case study and appropriate evidence in the literature. Abstracts from some of the capstone projects of the Class of 2013 follow this report.

The Division of Physical Therapy has been an integral educational program within the School of Medicine for close to 40 years. We are proud the many accomplishments of our graduates, students, faculty and staff who continue to fulfill the mission of our Division and the UNM School of Medicine to meet the health care needs of New Mexicans.

# Pressure Garment Therapy and Hypertrophic Burn Scars: A Case Study and Evidence-Based Analysis

Hayley Davis sDPT<sup>1</sup>

1. UNM Department of Orthopaedics & Rehabilitation

## INTRODUCTION

This case study and evidence-based analysis aims to determine if pressure garment therapy (PGT) is more effective than no pressure or other modalities for the treatment of hypertrophic scars in burned patients. PGT has been a first-line conservative therapy for hypertrophic scarring since the early 1970s, however the research presents conflicting results and lacks consistency with study characteristics. With a myriad of possible side effects and limitations, research on PGT needs to be reanalyzed and its true potential determined.

## METHODS

In order to identify all relevant articles, the major computerized databases were searched: PubMed, the Physiotherapy Evidence Database (PEDro), Cumulative Index to Nursing and Allied Health Literature (CINAHL), and The Cochrane Library. Search terms included “compression garments,” “hypertrophic scar,” “pressure garment,” “scar,” “burn,” and “pressure therapy.” The main search of PubMed yielded 47 results. Twenty-five articles were excluded by title review, as the title suggested the subject did not pertain to the topic of this analysis, 13 did not meet the inclusion criteria of being published in the last 10 years, and 1 was excluded for not being in English. This left 8 articles for abstract review. Two were excluded after the abstracts were reviewed, as the subject did not pertain to the topic. This left 6 unique studies for review and analysis.

A search of PEDro produced 5 results, all of which were excluded: 3 by title review and 2 were duplicate publications. The search of CINAHL produced 3 duplicate publications, all of which were excluded. Searching Cochrane yielded 3 results and all excluded, as well: 2 were duplicate publications and 1 required a fee for access, therefore was excluded. A search of the unpublished literature produced 1 unique result included for review and analysis. A search for available foundational research yielded 1 available article that was cited by several textbooks and included articles. In total, 8 articles were included for this review: 6 were randomized controlled trials (RCTs), 1 was a series of case studies, and 1 was a meta-analysis. Each of the 8 articles were reviewed and analyzed.

## FINDINGS

A review of the current literature revealed that PGT can reduce the thickness or height of hypertrophic scars, with the greatest effects seen in the first month of treatment. PGT has no statistically significant effect on erythema, pruritus or rigidity. The mechanism of action and optimal pressure for garments remains hypothetical. Integrating the results from all the included studies became apparently unlikely, as each study varied considerably and many essential characteristics were commonly not reported.

## CONCLUSION

The overall quality of the current research is poor and consistently lacks good external validity. While PGT was shown to have no effect on all the characteristics of hypertrophic scars, additional benefits may exist. These possible benefits, the potential side effects, and cost should all be considered and discussed with the patient before prescribing PGT for hypertrophic scarring.

# Will Lower Extremity Strengthening Be Beneficial for Ambulation in Patients with Guillain-Barré Syndrome? A Case Study

Bernadette Frigerio sDPT<sup>1</sup>

1. UNM Department of Orthopaedics & Rehabilitation

## INTRODUCTION

Guillain-Barré is an immune-mediated response that triggers destruction of the myelin sheath covering the peripheral nerves. The demyelination occurs between the nodes of Ranvier, blocking the transmission of impulses from node to node. Typically, the axons are spared, but recovery occurs slowly as the remyelination takes place. It is more common in older persons, but can occur at a relatively young age, 30-50 years old. Recovery will typically begin after the acute/subacute and plateau phase with gradual resolution of the paralysis lasting 1-2 years. It has been noted that an increase in muscle strength will usually occur in the first 6 months of recovery, but continued, significant progress can be observed beyond 12 months. However, the ongoing impact of Guillain-Barré Syndrome on activities of daily living, work, social activities and health-related quality of life can be considerable. With minimal literature on the benefits of skilled physical therapy intervention concerning muscle strength in ambulation in patients with Guillain-Barré Syndrome, the aim of this case report was to determine if lower extremity strengthening would be beneficial for ambulation in patients with Guillain-Barré Syndrome.

## METHODS

The patient received skilled physical therapy intervention with a home health agency 2 times each week for 8 weeks. His therapy consisted of, but was not limited to, active range of motion, stretching, bilateral lower extremity strengthening, gait, balance, and transfer training.

## FINDINGS

This patient was not discharged from home health physical therapy because he still demonstrated a need for skilled care. However, at the time of his reassessment he had achieved all of his goals except for transferring with supervision utilizing an assistive device and increasing his Tinetti score to 19/28 or greater. He scored an 11/28 still classifying him as a high risk of falls, but a significant increase from his initial evaluation score of 0/28. His goals were adjusted to an advanced program. He will continue to receive skilled home health physical therapy for gait, transfer, and balance training.

## CONCLUSION

Guillain-Barré Syndrome is a multifaceted diagnosis and when this patient population is on the road to recovery there is little evidence that provides a formal exercise program to follow that would improve their functional capacities. However, implementing a lower extremity strengthening program in a home health setting is beneficial for ambulation in patients with Guillain-Barré Syndrome, but further research needs to be conducted in all aspects of rehabilitation as well as different stages of Guillain-Barré Syndrome in order to gain a firmer grasp on how to ideally treat these patients with physical therapy interventions.

# Rehabilitation of a Patient with West Nile Virus and Associated Sequelae

Vanessa Garcia sDPT<sup>1</sup>

1. UNM Department of Orthopaedics & Rehabilitation

## PURPOSE

The purpose of this study was to identify different treatment options available for a patient diagnosed with West Nile virus, as well as to learn about prognosis and long term sequelae. The research will allow for proper development of the treatment plan and patient/family education.

prognoses of patients with West Nile virus. This literature provided information that described the disease in-depth and included information about the awareness and knowledge needed to formulate treatment plans, as well as to provide education to family on expected outcomes and sequelae.

## CASE DESCRIPTION

The patient was a 64 year old male with a recent diagnosis of diffuse large B cell lymphoma, on R-CHOP therapy who apparently had gone camping a few weeks prior to presentation. The patient developed fever and headache on October 10, 2012. He presented to St. Vincent Hospital on October 13, 2012, where he was found to have a temperature of 103°, weakness in his lower extremities, and some neck stiffness. The patient was transferred to University of New Mexico Hospital on October 19, 2012, with progressive deterioration and ascending weakness; a diagnosis of West Nile virus was made. On November 5, 2012, he was transferred to Kindred Hospital, presenting with increased tone, impaired arousal, impaired active range of motion, and impaired motor control.

## FINDINGS

While at Kindred the patient had become medically stable and was making gradual progress towards goals. The patient continued to be dependent with all functional mobility skills but demonstrated an increase in arousal, increase in strength, and the ability to follow 1-step commands. The patient was discharged from Kindred and is now undergoing treatment at a rehabilitation facility. After leaving Kindred the patient's progress was not followed.

## CONCLUSION

There are currently 3 specific interventions within the literature that have been utilized for patients in this population. They are physical therapy interventions directed at increasing muscle performance, range of motion, mobility, and overall function; a post-polio approach; and rehabilitation protocols used for stroke patients. Due to the limited research on specific interventions, articles on prognoses and functional outcomes are also included in this case report. Articles related to prognosis offer a better understanding of functional outcomes that have been achieved and insight into how to individualize patient care in order to maximize potential and assist in discharge planning. The most beneficial articles were those discussing outcomes and

# Does Hippotherapy Improve Gross Motor Function in Children with Cerebral Palsy?

Rachel Y. Maestas sDPT<sup>1</sup>

1. UNM Department of Orthopaedics & Rehabilitation

## INTRODUCTION

Cerebral palsy (CP) refers to a group of non-progressive disorders of movement and posture caused by abnormal development of, or damage to, motor control centers of the brain. CP is caused by events before, during, or after birth. The abnormalities of muscle control that define CP are often accompanied by other neurological and physical abnormalities. Hippotherapy, a physical, occupational, and speech-language therapy treatment strategy that utilizes equine movement as part of an integrated intervention program to achieve functional outcomes, has become a popular intervention for children with CP. The purpose of this study was to determine if hippotherapy improves gross motor function in children with CP.

The subject in this case study was “Beth.” Beth was a 14 year old female with a diagnosis of CP that included spastic quadriplegia. She received early intervention services, including physical, occupational, and speech therapy in the past. Beth participated in hippotherapy between August 2011 and December 2012 and demonstrated steady but slow progress.

## METHODS

Beth participated in once a week sessions for 8 weeks. The sessions consisted of 20-30 minutes of work on functional positioning and attending to a task utilizing bilateral upper extremities followed by a session on a dynamic equine surface. While on the horse, Beth participated in reaching, positioning, attending to a task, and lower extremity stretching and strengthening.

The equine portion of the treatment session was based on the commonly used Silkwood-Sherer treatment protocol. Treatment consisted of 5 minutes of a warm-up session that consisted of the patient seated forward and working on relaxing the muscles and just “feeling” the movement of the horse followed by 10-15 minutes of strengthening, balance, proprioception, and motor planning through various tasks and position changes. The last 5 minutes of the session was the “cool down” portion, where the patient was encouraged to relax and feel the movement of the horse.

## FINDINGS

Beth made significant but limited progress during the 8 weeks of intervention for this study. At the conclusion of this case study, Beth demonstrated an increase in core

stability and in control of her upper and lower extremities. During the last 2 sessions of treatment, Beth required minimal cueing to grab the handle of the saddle and was able to hold the handle for more than 15 minutes. This demonstrated significant progress in body awareness, motor control, and the ability to quiet her body in order to control it.

## CONCLUSION

Based both on the preponderance of research that was found as well as the case study that was performed, hippotherapy improves gross motor function in children with cerebral palsy. Many positive changes were observed in Beth at the conclusion of this case study. In the future, hippotherapy may be recommended as a treatment approach to rehabilitate children with cerebral palsy.



# The Effects of Platelet-Rich Plasma Injections on Patellar Tendinopathy

Shyla Mesch sDPT<sup>1</sup>

1. UNM Department of Orthopaedics & Rehabilitation

## INTRODUCTION

Patellar tendinopathy is very common among elite and recreational athletes who participate in sports that involve jumping and quick directional changes. Several different therapies and modalities have been experimented with to increase the healing of the tendon. The purpose of this case study and review is to evaluate the effectiveness of platelet-rich plasma injection therapy on treating refractory long-term patellar tendinopathy.

The administration of platelet-rich plasma (PRP) is a new and clinically successful approach in the management of tendinosis and/or tendinopathy. PRP is an autologous blood derivative that contains a higher concentration of platelets with respect to baseline blood level. The biological rationale is that the platelets are a source of several growth factors amongst several other bioactive molecules that play an important role in tissue homeostasis and the healing cascade. The application of PRP into a damaged tendon could therefore encourage tissue regeneration. PRP has been applied in several clinical conditions, both as a conservative injective approach or to augment surgical procedures.

## METHODS

A full history was taken from the case study subject and a thorough evaluation was performed. The patient began physical therapy 3 weeks post-injection and continued through a progressive 5 week physical therapy program beginning with proprioception and stretching exercises and progressing into plyometrics and sport-specific training.

An extensive and comprehensive evidence-based literature search was conducted looking in 4 different databases, including PubMed, CINAHL Plus, Cochrane, and Web of Knowledge. A total of 20 articles were collected, and of those, 8 were selected for extensive analytical review.

## FINDINGS

Case study subject regained full functional strength and range of motion and a complete relief of knee pain at completion of physical therapy, 8 weeks post-injection. There was limited research on this topic, and even less published research that is considered high quality evidence. Much of the published research have high clinical and statistical relevance, but the sample sizes are smaller and lack randomization, blinding, and a control group. Platelet-rich plasma (PRP) injection looks to be a promising treatment for patellar tendinopathy from a standpoint of

clinical relevance. This type of modality looks to provide another treatment option for those with unrelenting, reoccurring, or recalcitrant tendinopathy.

## CONCLUSION

Physical therapy is often a very successful tool in the treatment of patellar tendinopathy and should be followed and implemented for at least 3 to 6 months as a first line of treatment. For those individuals suffering from recalcitrant patellar tendinopathy that have failed more conservative treatments, it may be worthwhile to include PRP injection therapy as a recommendation. Studies have shown decreases in tendon irregularities and results of pain reduction and/or increased function after PRP injection. Although current research is of lower quality and confers no clear benefit that can be stated with certainty, we can say PRP injection is a very safe and minimally invasive procedure that almost always provided patients with some sort of pain reduction and allowed many of the subjects to return to sport and play to full capacity. Further high quality research is needed in this area.

# The Efficacy of Orthoses Wear in a Patient with Sacral Level Myelomeningocele: A Case Report and Evidence-Based Analysis

Krista Riebli sDPT<sup>1</sup>

1. UNM Department of Orthopaedics & Rehabilitation

## INTRODUCTION

The purpose of this case report was to evaluate the effectiveness during gait of supra-malleolar orthoses (SMO) on a child with sacral level myelomeningocele who lacks normal strength in her lower extremities. A secondary purpose of this case report was to thoroughly review the current available literature regarding commonly used orthoses in children with sacral level myelomeningocele in order to adequately make further recommendations for a new pair of orthoses.

## METHODS

The subject was a 6 year old female with a diagnosis of S1 myelomeningocele which was present at birth. Evaluation and examination was performed by 1 examiner who was a physical therapy student. A clinical instructor observed all sessions with the patient and student. The patient's lower extremity range of motion, muscle strength, and sensation were all tested. The patient was also administered the Bruininks-Oseretsky Test of Motor Proficiency (BOT-II), while she was wearing her SMOs and tennis shoes and in just tennis shoes. A gait analysis was performed at the University of New Mexico Gait Lab using a Vicon Gait Analysis system. The patient was analyzed in the barefoot condition, as well as with her SMOs and tennis shoes. Sagittal parameters of the knee and ankle as well as spatial and temporal parameters were measured during the gait analysis. A literature search was conducted using the Academic Search Complete, PubMed, and Web of Knowledge databases. A total of 8 articles were reviewed, analyzed, and compared with the clinical question presented in the case.

## FINDINGS

The SMOs were not found to greatly increase the patients' scores on the BOT-II examination. During the gait analysis, the patient showed an increase in knee extension and dorsiflexion during the stance phase when the SMOs were worn. However, the values were still not enough to provide the patient with normal or near normal ranges. Benefits of the SMOs found during the gait analysis included more symmetrical values during double limb support, step length, and cadence; increased stride length; and increased walking speed. The literature search revealed that many children with sacral level myelomeningocele wear an ankle-foot orthosis (AFO) as opposed to any other type of orthotic. The literature also provided a sound argument that an AFO is much more beneficial to a

child of this population when compared to the barefoot condition. Various types of AFOs were compared in the literature, including carbon fiber spring AFO, hinged AFO, ground reaction AFO, and solid AFO. The literature lacked quality randomized controlled trials and systematic reviews.

## CONCLUSION

The SMOs were not providing the patient with the maximal amount of benefit she requires. A different orthotic, such as an AFO, would be of much more benefit to this patient and provide her with the support and alignment which she so desperately needs to prevent further impairments and complications. Further higher quality research is needed in the topic of bracing children with sacral level myelomeningocele.

# Multiple Sclerosis and Urinary Incontinence: A Case Study of Pelvic Floor Training and Postural Interventions

Tara McCarthy Sanford sDPT<sup>1</sup>

1. UNM Department of Orthopaedics & Rehabilitation

## INTRODUCTION

Multiple sclerosis (MS) is a progressive disease that is characterized by lesions causing loss of myelin in the central nervous system. Among the many symptoms that can occur, bowel, bladder, and sexual dysfunctions have been found in as many as 75% of the cases of men and women with the disease. Previous studies have shown statistically significant improvements for patients with urinary incontinence if pelvic floor muscle training is incorporated in treatment. Several studies have also found correlations between low back pain and pelvic floor dysfunction. This case study seeks to blend the 2 interventions - pelvic floor muscle training and low back treatment - to help a patient with multiple sclerosis and urinary incontinence. This case study prompted the following population, intervention, comparison, outcome (PICO) question: Can a patient with MS demonstrate improved urinary continence with postural interventions coupled with pelvic floor muscle training?

## METHODS

This case study looked at a 40 year old woman diagnosed with MS in 2007. She had been experiencing increased urinary incontinence and urgency in the last two years, as well as increased spasms in the low back. The patient was referred to physical therapy by her gynecologist for mixed urinary incontinence (ICD-9-CM 788.33) for treatment and bladder retraining. The patient was given several interventions, including pelvic floor muscle training, spinal alignment using muscle energy techniques, bladder retraining, biofeedback, postural interventions and functional, and pelvic floor specific exercises.

## FINDINGS

The following goals were set for the patient after her initial evaluation with the following outcomes:

1a. Increase strength of the pelvic floor by 1 pelvic floor muscle grade from 2/5 - 3/5, to reduce the leaking of urine, especially during walking to allow the patient to be more active.

1b. Goal met- demonstrated a 4/5 pelvic floor muscle grade at her 7th visit.

2a. Decrease resting tone of the pelvic floor to allow the patient to better empty her bladder and reduce the frequency of urination to allow the patient to be more active in her community.

2b. Goal met- reported urinating every 3 hours and reported less urine leakage, going from 4 pads daily to 1 pad daily.

3a. Decrease pelvic pain by 50% from 4/10 - 2/10 to allow the patient to more comfortably participate in sexual intercourse.

3b. Goal not met - continued pain at a 4/10 with intercourse.

4a. Improved core stabilization to promote pelvic and lumbar stability and improve overall pelvic floor function.

4b. Goal met - demonstrated good strength and form with lumbar stabilization and core exercises and maintained spinal alignment after adjustment of the sacroiliac joint.

## CONCLUSION

Overall, the research was compelling for this PICO question. The research was separately shown for pelvic floor training for MS patients and the treatment of low back pain for urinary incontinence with Oxford Levels of Evidence levels ranging from 1B to 4. This case study was important because it showed the significance of bringing those two separate treatment options together to make the best outcome for a patient.

# Medium- and Long-Term Radiographic Evaluation of Survivorship of Pegged Versus Keeled Glenoid Components

Matthew Ferguson MD<sup>1</sup>, Daniel L. Aaron MD<sup>2</sup>, Penelope Lang MD<sup>2</sup>, Alexis Colvin MD<sup>2</sup>

1. UNM Department of Orthopaedics & Rehabilitation 2. Icahn School of Medicine at Mount Sinai/Mount Sinai Hospital

Investigation performed at Icahn School of Medicine at Mount Sinai, Leni and Peter W. May Department of Orthopaedic Surgery, New York, New York

## Abstract

**Introduction:** This study evaluated the survivorship of pegged versus keeled cemented, all-polyethylene glenoid components using modern cementing and glenoid preparation techniques. Survival of glenoid design was determined according to severity of radiolucencies on follow-up radiographs.

**Methods:** Between April 22, 1999, and February 17, 2009, retrospective chart review was performed on 194 total shoulder arthroplasties performed by a single fellowship-trained shoulder surgeon. A minimum of 3-year follow-up was established. Scapular plane anteroposterior radiographs (Grashey view) were analyzed and graded for the degree of radiolucency surrounding the glenoid anchor using Franklin's method for keeled components and a modification of that method for pegged components. Radiographs were evaluated by 3 raters who independently graded radiographs for each patient in this study. Unpaired 2-tailed t-test was used to calculate significance,  $p < 0.05$ . Interobserver correlation was computed using the intraclass correlation coefficient (ICC) 2-way mixed model with measures of absolute agreement to analyze the measurement reliability. Values of ICC range from 0 to 1, with a higher value indicating better reliability. ICC less than 0.40 is considered poor; 0.40 to 0.59 as fair; 0.60 to 0.74 as good; and 0.75 to 1.00 as excellent. Active forward elevation (AFE) and active external rotation (AER) were recorded before and after surgery. The range of motion scores for pegged glenoids was compared to keeled glenoids, as well as grading lucency from 0-1 to >1 lucency.

**Results:** Fifty-two total shoulders in 45 patients met the inclusion criteria, with 36 pegged glenoid components and 16 keeled components. Average length of follow up was 67 months (range 36 to 128 months). Average radiolucency was 1.01 on a modified Franklin scale of 0

to 5 in the pegged glenoid component group, compared to 1.90 in the keeled group, ( $p < 0.01$ ). Interobserver correlation coefficient was 0.31. For the pegged group, AFE increased from 123° to 150°, and AER increased from 24° to 59°. For the keeled group, AFE increased from 105° to 148°, and AER increased from 14° to 59°. For grade 0-1 lucency, AFE increased from 120° to 151°, and AER increased from 20° to 56°. For grade >1 lucency, AFE increased from 114° to 148°, and AER increased from 21° to 61°.

**Conclusions:** Significantly greater component survival was found with pegged as opposed to keeled anchoring design. Poor interobserver reliability was noted with the Franklin grading system among orthopaedic physicians at various levels of training. There did not appear to be a difference in range of motion between pegged and keeled glenoids or with respect to degree of radiolucency.

## Introduction

Total shoulder replacement has been demonstrated to be an effective treatment for end-stage glenohumeral arthritis.<sup>1</sup> The presence of radiolucencies at the glenoid bone-cement interface has continued to be a concerning finding.<sup>2-21</sup> An association between glenoid radiolucencies and a worse functional outcome has been reported in the literature.<sup>22</sup> Torchia and colleagues reported that 39 (44%) of 89 glenoids had radiographic signs of loosening after a minimum duration of follow-up of 5 years and noted that these changes were associated with worsening function.<sup>18</sup> The reported prevalence of glenoid radiolucencies has varied from 0% to 96%, and this wide range has been postulated to be as a result of a lack of uniformity in grading and follow-up among studies.<sup>23,24</sup>

Biomechanical, animal, and retrospective studies have implicated glenoid design in the development of glenoid lucency.<sup>25-28</sup> In the literature, the effect of using pegged-back versus keeled-back glenoid components has

been controversial. Some studies have found no difference in glenoid lucency between the 2 designs,<sup>31-35</sup> whereas others have reported a lower radiolucent lines rate for pegged-back glenoids.<sup>19,26,27,36</sup> These studies indicate that cemented pegged glenoid components appear to have better fixation and a lower rate of radiographic lucency over time when compared with keeled components.<sup>25-28</sup> Gartsman and colleagues conducted a prospective, randomized study to compare the components, as used by a single surgeon, and found that glenoid lucency was seen in 9 (39%) of 23 keeled-back glenoids versus 1 (5%) of 20 pegged back glenoids ( $P = .026$ ).<sup>37,38</sup>

The current definition of a modern cementing technique relating to glenoid component fixation minimizes removal of subchondral sclerotic bone, compacts the cancellous bone during anchorage preparation, thoroughly cleans any blood and soft tissue debris, achieves meticulous drying of the glenoid by any method, inserts cement with a syringe, and pressurizes the cement after insertion by mechanical means.<sup>39</sup>

The hypothesis is that in the Bigliani-Flatow Total Shoulder Arthroplasty (TSA) System, the use of cemented pegged glenoid components will have lower grades of radiolucencies as compared to keeled cemented glenoid components in medium to long-term radiographic evaluation.

## Materials and Methods

Between April 22, 1999, and February 17, 2009, 194 total shoulder arthroplasties were performed by a single fellowship-trained shoulder surgeon. A retrospective chart review was performed. Inclusion criteria for this study were primary standard total shoulder arthroplasty performed without concurrent procedures, such as capsulorrhaphy. Revision procedures and concurrent capsulorrhaphies or other procedures were excluded. A minimum of 3-year follow-up was established. Scapular plane anteroposterior radiographs (Grashey view) were then analyzed and graded for the degree of radiolucency surrounding the glenoid anchor. Franklin's method was used to grade keeled components, and a modification of that method was used to grade pegged components. The radiographs were evaluated by 2 raters, including a fellowship-trained shoulder surgeon (DLA) and an orthopaedic resident in the second post-graduate year (PL). After familiarizing themselves with the described grading criteria by reviewing the previously published articles by Franklin et al.<sup>23</sup> and Lazarus et al.,<sup>26</sup> the raters independently graded the radiographs for each of the patients in this study. The orthopaedic

surgeon who had performed the arthroplasties was not a rater.

An unpaired 2-tailed t-test was used to calculate statistical significance, with significance being  $p < 0.05$ . Interobserver correlation was computed using the intraclass correlation coefficient (ICC) 2-way mixed model with measures of absolute agreement to analyze the measurement reliability. Values of ICC range from 0 to 1, with a higher value indicating better reliability. ICC less than 0.40 is considered poor; 0.40 to 0.59 as fair; 0.60 to 0.74 as good; and 0.75 to 1.00 as excellent.

Active forward elevation (AFE) and active external rotation (AER) were measured by the operating surgeon before and after surgery and the data was analyzed by retrospective chart review. Range of motion scores for pegged TSAs was compared to the keeled TSA glenoids. In addition, range of motion scores for those TSA glenoids with grade 0-1 lucency was compared to grade >1 lucency.

## Surgical Procedure

All patients underwent reconstructive surgery at a single institution using the Bigliani/Flatow<sup>®</sup> The Complete Shoulder Solution system (Zimmer, Warsaw, IN). All procedures were performed by a single experienced senior staff shoulder surgeon, who was a co-developer of the shoulder system used in this study. Cementing of the glenoid component was performed in a standard fashion with a modern cementing technique. The range of operative dates for the study group varied from April 22, 1999 to February 17, 2009.

## Radiographic Lucency

Radiographic lucency of the keeled glenoid components was graded according to criteria previously described by Franklin et al.<sup>23</sup> The pegged components were graded according to the modification described by Lazarus et al.<sup>26</sup>

The keeled components were graded between 0 and 5. A grade of 0 represented no lucency.

Grades 1 through 5 were as follows:

1. Radiolucency at inferior and/or superior flange
2. Incomplete radiolucency at keel
3. Complete radiolucency of less than 2 mm in width around keel
4. Complete radiolucency of 2 mm or greater in width around keel
5. Gross loosening

The pegged components were also graded between 0 and 5, with 0 representing no lucency.

The remaining grades were as follows:

1. Incomplete radiolucency around 1 or 2 pegs
2. Complete radiolucency of less than 2 mm in width around 1 peg only, with or without incomplete radiolucency around one other peg
3. Complete radiolucency of less than 2 mm in width around 2 or more pegs
4. Complete radiolucency of 2 mm or greater in width around 2 or more pegs
5. Gross loosening

## Results

### Subjects

Fifty-two total shoulder arthroplasties in 45 patients met our inclusion criteria, with 36 pegged glenoid components and 16 keeled components. One hundred and forty-two total shoulder arthroplasties were excluded due to the lack of follow-up radiographs performed at least 3-years from the date of the index procedure. The average length of follow-up radiographs was 67 months (range 36 to 128 months). The average degree of radiolucency was 1.01 (0 to 2.33) on a modified Franklin scale of 0 to 5 in the pegged glenoid component group, as compared to 1.90 (0.67 to 3.67) on a Franklin scale of 0 to 5 in the keeled group, ( $p < 0.01$ ). The interobserver correlation coefficient was 0.31.

Active forward elevation (AFE) and active external rotation (AER) were recorded before and after surgery for 49 total shoulder arthroplasties. The range of motion scores for 33 pegged glenoid total shoulder arthroplasties were compared to 16 keeled glenoid total shoulder arthroplasties. For 3 of the total shoulder arthroplasties there was insufficient documentation on the range of motion, either pre-operative or post-operative and these total shoulder arthroplasties were excluded from this portion of the study. For the pegged group, (33), AFE increased from an average of  $123^\circ$  ( $80^\circ$  to  $170^\circ$ ) to  $150^\circ$  ( $30^\circ$  to  $180^\circ$ ), and AER increased from an average of  $24^\circ$  ( $-20^\circ$  to  $70^\circ$ ) to  $59^\circ$  ( $30^\circ$  to  $80^\circ$ ). For the keeled group, (16), AFE increased from an average of  $105^\circ$  ( $35^\circ$  to  $165^\circ$ ) to  $148^\circ$  ( $100^\circ$  to  $180^\circ$ ), and AER increased from an average of  $14^\circ$  ( $-30^\circ$  to  $50^\circ$ ) to  $59^\circ$  ( $30^\circ$  to  $80^\circ$ ). In addition, the range of motion scores for 22 total shoulder arthroplasties with grade 0 - 1 glenoid lucency was compared to 27 patients with grade >1 glenoid lucency. Nineteen pegged glenoid total shoulder arthroplasties and 3 keeled glenoid total

shoulder arthroplasties comprised the group with grade 0 - 1 lucency. Fourteen pegged glenoid total shoulder arthroplasties and 13 keeled glenoid total shoulder arthroplasties comprised the group with grade >1 lucency. For grade 0 - 1 lucency, the 22 total shoulder arthroplasties' AFE increased from an average of  $120^\circ$  ( $60^\circ$  to  $165^\circ$ ) to  $151^\circ$  ( $90^\circ$  to  $180^\circ$ ), and AER increased from an average of  $20^\circ$  ( $-20^\circ$  to  $60^\circ$ ) to  $56^\circ$  ( $30^\circ$  to  $70^\circ$ ). For grade >1 lucency, the 27 total shoulder arthroplasties' AFE increased from an average of  $114^\circ$  ( $35^\circ$  to  $170^\circ$ ) to  $148^\circ$  ( $30^\circ$  to  $180^\circ$ ), and AER increased from an average of  $21^\circ$  ( $-30^\circ$  to  $70^\circ$ ) to  $61^\circ$  ( $30^\circ$  to  $80^\circ$ ). This study contained 1 keel (1/16, 6.25%) and 1 peg (1/36, 2.7%) component which required revision surgery.

## Discussion

The literature has previously suggested that round-backed, all-polyethylene components with peg fixation perform better than do flat-backed, metal-backed, or keeled components.<sup>40</sup> Lazarus et al. compared lucency rates between cemented pegged and cemented keeled components immediately after surgery.<sup>26</sup> They found that keeled components had a lucency rate (grade 2 lucency or higher) of 72% (11/39 components) whereas pegged components had a lucency rate of only 38% (180/289 components). They reported a mean lucency rating of 1.8 points for keeled components and 1.3 points for pegged components. Gartsman and colleagues,<sup>38</sup> in their series of randomized patients, reported that keeled glenoid components had a higher grade of radiographic lucency (39%) immediately after surgery than pegged glenoid components (5%). They reported a mean lucency ratings of 1.4 points for keeled components and 0.5 points for pegged components. This study found lucency grades of 1.90 for keeled glenoid components and 1.01 for pegged glenoid components. These findings support the conclusion regarding keel vs. peg glenoids that prior studies have reported.

An association between glenoid radiolucencies and a worse functional outcome which has been reported in the literature was not observed in this study.<sup>22</sup> This study showed no difference with respect to range of motion for keeled glenoids as compared to pegged glenoids. In addition, we found no difference with respect to range of motion as related to the severity of the radiolucencies. This finding is, to our knowledge the first reported lack of association regarding degree of radiolucency with respect to functional outcome. Controversy still exists as to the relationship between glenoid lucency and clinical failure of the glenoid

component. However, the long-term study by Torchia et al. suggests a positive correlation.<sup>18</sup> The present study contained 1 keel (1/16, 6.25%) and 1 peg (1/36, 2.7%) component which required revision surgery.

Study limitations were that this was a retrospective review of a small group of patients that primarily focused on radiographs and range of motion as recorded in the medical record. There may be inherent bias in that the operating surgeon was co-developer of the arthroplasty system used in the study. The use of radiographs for the assessment of radiolucent lines in the glenoid has been suggested to be inaccurate.<sup>28,29</sup> Differences between the modified Franklin scale and Franklin scale rating systems, such as assessing radiolucency around flanges as opposed to pegs, may be sources of inaccuracy in comparisons. There was poor interobserver correlation reflecting variation in grading experience of the raters who were used in this study. However, each grade was based on the average grade of the 3 raters, and assuming that each rater was consistent in his/her approach, an averaged value would incorporate these grading differences across the board and improve the reliability of the averaged measurements. Gartsman and colleagues reported a high level of intraobserver and interobserver consistency not seen in prior studies.<sup>37,38</sup> They attributed the consistency in their grading to a training process done on non-study radiographs to develop a consensus for grading, a process that could have been implemented in our study.

## Conclusion

Significantly greater component survival was found with pegged as opposed to keeled anchoring design. Poor interobserver reliability was noted with the Franklin grading system among orthopaedic physicians at various levels of training. In contrast to prior studies, this study did not demonstrate a difference in range of motion between pegged and keeled glenoids, nor a correlation between diminished range of motion and degree of radiolucency.

## References

1. Matsen FA III. Early effectiveness of shoulder arthroplasty for patients with primary glenohumeral degenerative joint disease. *J Bone Joint Surg Am.* 1996;78(2):260-264.
2. Amstutz HC, Thomas BJ, Kabo JM, Jinnah RH, Dorey FJ. The Dana total shoulder arthroplasty. *J Bone Joint Surg Am.* 1988;70-A(8):1174-1182.

3. Barrett WP, Franklin JL, Jackins SE, Wyss CR, Matsen FA III. Total shoulder arthroplasty. *J Bone Joint Surg Am.* 1987;69(6):865-872.
4. Barrett WP, Thornhill TS, Thomas WH, Gebhart EM, Sledge CB. Nonconstrained total shoulder arthroplasty in patients with polyarticular rheumatoid arthritis. *J Arthroplasty.* 1989;4(1):91-96.
5. Bell SN, Gschwend N. Clinical experience with total arthroplasty and hemiarthroplasty of the shoulder using the Neer prosthesis. *Int Orthop.* 1986;10:217-222.
6. Boyd AD Jr, Thornhill TS. Surgical treatment of osteoarthritis of the shoulder. *Rheum Dis Clin North Am.* 1988;14(3):591-611.
7. Cofield RH. Total shoulder arthroplasty with the Neer prosthesis. *J Bone Joint Surg Am.* 1984;66(6):899-906.
8. Fenlin JM Jr, Ramsey ML, Allardyce TJ, Frieman BG. Modular total shoulder replacement: design rationale, indications, and results. *Clin Orthop.* 1994;307:37-46.
9. Frich LH, Møller BN, Sneppen O. Shoulder arthroplasty with the Neer Mark-II prosthesis. *Arch Orthop Trauma Surg.* 1988;107:110-113.
10. Friedman RJ, Thornhill TS, Thomas WH, Sledge CB. Non-constrained total shoulder replacement in patients who have rheumatoid arthritis and class-IV function. *J Bone Joint Surg Am.* 1989;71(4):494-498.
11. Gristina AG, Romano RL, Kammire GC, Webb LX. Total shoulder replacement. *Orthop Clin North Am.* 1987;18(3):445-453.
12. Hawkins RJ, Bell RH, Jallay B. Total shoulder arthroplasty. *Clin Orthop Relat Res.* 1989;242:188-194.
13. Johnson RL. Total shoulder arthroplasty. *Orthop Nurs.* 1993;12(1):14-22.
14. Kelly IG, Foster RS, Fisher WD. Neer total shoulder replacement in rheumatoid arthritis. *J Bone Joint Surg Br.* 1987;69-B(5):723-726.
15. Neer CS II, Watson KC, Stanton FJ. Recent experience in total shoulder replacement. *J Bone Joint Surg Am.* 1982;64(3):319-337.
16. Sperling JW, Cofield RH, Rowland CM. Neer hemiarthroplasty and Neer total shoulder arthroplasty in patients fifty years old or less: long term results. *J Bone Joint Surg Am.* 1998;80-A(4): 464-473.

17. Stewart MP, Kelly IG. Total shoulder replacement in rheumatoid disease: 7- to 13-year follow-up of 37 joints. *J Bone Joint Surg Br.* 1997;79-B(1):68-72.
18. Torchia ME, Cofield RH, Settegren CR. Total shoulder arthroplasty with the Neer prosthesis: long-term results. *J Shoulder Elbow Surg.* 1997;6(6):495-505.
19. Wirth MA, Rockwood CA Jr. Complications of shoulder arthroplasty. *Clin Orthop.* 1994;307:47-69.
20. Brems J. The glenoid component in total shoulder arthroplasty. *J Shoulder Elbow Surg.* 1993;2(1):47-54.
21. Weiss AP, Adams MA, Moore JR, Weiland AJ. Unconstrained shoulder arthroplasty: a five-year average follow-up study. *Clin Orthop.* 1990;257:86-90.
22. Broström LA, Kronberg M, Wallensten R. Should the glenoid be replaced in shoulder arthroplasty with an unconstrained Dana or St. Georg prosthesis? *Ann Chir Gynaecol.* 1992;81(1):54-57.
23. Franklin JL, Barrett WP, Jackins SE, Matsen FA III. Glenoid loosening in total shoulder arthroplasty: association with rotator cuff deficiency. *J Arthroplasty.* 1988;3(1):39-46.
24. Collins D, Tencer A, Sidles J, Matsen F III. Edge displacement and deformation of glenoid components in response to eccentric loading: the effect of preparation of the glenoid bone. *J Bone Joint Surg Am.* 1992;74-A(4):501-507.
25. Lacroix D, Murphy LA, Prendergast PJ. Three-dimensional finite element analysis of glenoid replacement prostheses: a comparison of keeled and pegged anchorage systems. *J Biomech Eng.* 2000;122(4):430-436.
26. Lazarus MD, Jensen KL, Southworth C, Matsen FA III. The radiographic evaluation of keeled and pegged glenoid component insertion. *J Bone Joint Surg Am.* 2002;84(7):1174-1182.
27. Trail IA, Nuttall D. The results of shoulder arthroplasty in patients with rheumatoid arthritis. *J Bone Joint Surg Br.* 2002;84-B(8):1121-1125.
28. Wirth MA, Korvick DL, Basamania CJ, Toro F, Aufdemorte TB, Rockwood CA. Radiologic, mechanical, and histologic evaluation of 2 glenoid prosthesis designs in a canine model. *J Shoulder Elbow Surg.* 2001;10(2):140-148.
29. Molé D, Roche O, Riand N, Levigne C, Walch G. Cemented glenoid components: results in osteoarthritis and rheumatoid arthritis. In: Walch G, Boileau P, eds. *Shoulder Arthroplasty.* Berlin, Germany: Springer-Verlag; 1999:163-171.
30. Aliabadi P, Weissman BN, Thornhill T, Nikpoor N, Sosman JL. Evaluation of a nonconstrained total shoulder prosthesis. *Am J Roentgenol.* 1988;151(6):1169-1172.
31. Amstutz HC, Thomas BJ, Kabo JM, Jinnah RH, Dorey FJ. The Dana total shoulder arthroplasty. *J Bone Joint Surg Am.* 1988;70-A(8):1174-1182.
32. Carke IC, Sew Hoy AL, Gruen TA, Amstutz HC. Clinical and radiographic assessment of a non-constrained total shoulder. *Int Orthop.* 1981;5:1-8.
33. Wallace AL, Phillips RL, MacDougal GA, Walsh WR, Sonnabend DH. Resurfacing of the glenoid in total shoulder arthroplasty: a comparison, at a mean of five years, of prostheses inserted with and without cement. *J Bone Joint Surg Am.* 1999;81(4):510-518.
34. Lacroix D, Prendergast PJ. Stress analysis of glenoid component designs for shoulder arthroplasty. *Proc Inst Mech Eng H.* 1997;211(6):467-474.
35. Gartsman GM, Russell JA, Gaenslen E. Modular shoulder arthroplasty. *J Shoulder Elbow Surg.* 1997;6(4):333-339.
36. Gartsman GM, Elkousy HA, Warnock KM, Edwards TB, O'Connor DP. Radiographic comparison of pegged and keeled glenoid components. *J Shoulder Elbow Surg.* 2005;14(3): 252-257.
37. Young AA, Walch G. Fixation of the glenoid component in total shoulder arthroplasty: what is "modern cementing technique?" *J Shoulder Elbow Surg.* 2012; 19(8): 1129-1136.
38. Matsen FA III, Clinton J, Lynch J, Bertelsen A, Richardson ML. Glenoid component failure in total shoulder arthroplasty. *J Bone Joint Surg Am.* 2008;90:885-896.
39. Havig MT, Kumar A, Carpenter W, Seiler JG III. Assessment of radiolucent lines about the glenoid: an in vitro radiographic study. *J Bone Joint Surg Am.* 1997;79(3):428-432.
40. Kelleher IM, Cofield RH, Becker DA, Beabout JW. Fluoroscopically positioned radiographs of total shoulder arthroplasty. *J Shoulder Elbow Surg.* 1992;1(6):306-311.



# Dorsal Intercarpal Ligament Instability Deformity Following Resection Arthroplasty of the Scaphotrapezotrapezoidal Joint.

Moheb Moneim MD<sup>1</sup>, Deana Mercer MD<sup>1</sup>

1. UNM Department of Orthopaedics & Rehabilitation

Carpal collapse manifested as dorsal intercarpal ligament instability (DISI) deformity may follow partial excision of the distal scaphoid when treating arthritis of the scaphotrapezotrapezoidal (STT) joint or persistent scaphoid nonunion. It has also been reported following complete excision of the trapezium. The incidence is low and some patients may already have this deformity preoperatively. The etiology is unclear and there is no consensus in the literature of how to manage this problem as there is a paucity of long term follow up.

The authors are presenting a case of DISI deformity following partial excision of the distal scaphoid for STT arthritis. The case was treated by repair of the redundant scapholunate ligament and K wire fixation following correction of the DISI deformity. The purpose of this report is to discuss the significance and the management of this deformity.

## Case Report

A 50 year old woman was seen in the office complaining of pain in her right wrist for 6 months. She was unable to pick up objects or open jars because of the pain. On examination she was found to have localized tenderness at the base of the thumb and the distal scaphoid, with pain on radial and ulnar deviation of the wrist. She had no tenderness when the first metacarpal was manipulated against the trapezium. X-ray showed advanced degenerative changes at the STT joint with normal alignment at the midcarpal joint (Figure 1). Several weeks later she had no relief from splinting and non-steroidal medications. Resection of the distal scaphoid with tendon interposition through a volar incision was carried out.

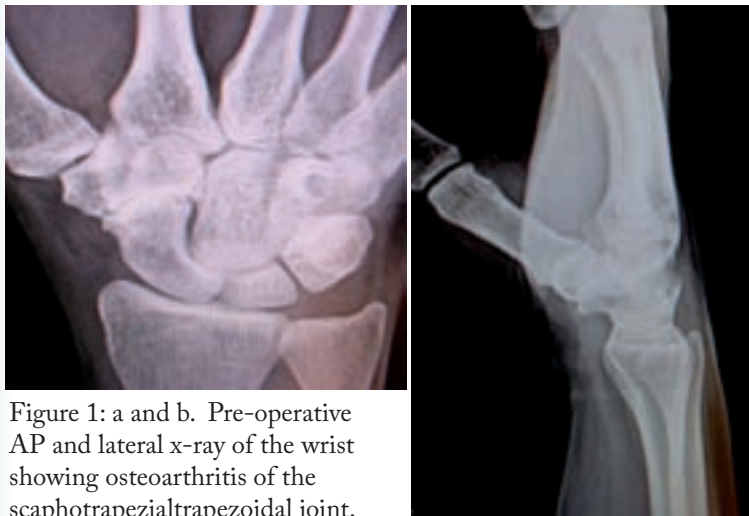

Figure 1: a and b. Pre-operative AP and lateral x-ray of the wrist showing osteoarthritis of the scaphotrapezotrapezoidal joint.

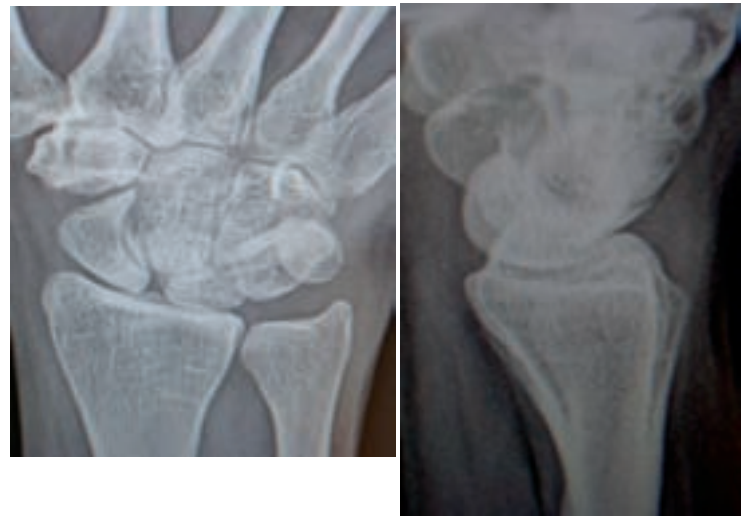

Figure 2: a and b. Post-operative x-ray showing a widened scapholunate interval and DISI deformity of the wrist.

The patient continued to have pain in her wrist. X-ray showed a midcarpal instability with clear evidence of DISI deformity (Figure 2). A magnetic resonance image (MRI) of the wrist showed a tear of the scapholunate ligament, increased T2 signal intensity between the remaining scaphoid and the capitate, and confirmed the DISI deformity (Figure 3).

Three months following the resection of the scaphoid the patient was taken back to surgery. The wrist joint was exposed through a dorsal incision. The scapholunate ligament was redundant with evidence of synovitis. The ligament was repaired after reduction of the DISI deformity and a pin was inserted from the radius into the scaphoid and capitate and another from the radius into the lunate and hamate (Figure 4). The patient was splinted and the pins were removed 6 weeks later. A year afterwards, she continued to have some pain in her wrist with good range of motion. A radiograph showed residual but improved DISI deformity. She was later treated for synovitis of the first extensor compartment.

## Discussion

Carpal collapse presenting as DISI can present following excision of the distal scaphoid for persistent nonunion of the scaphoid or for treating scaphotrapezotrapezoidal arthritis.<sup>1,2</sup> It has also been reported following trapezium excision

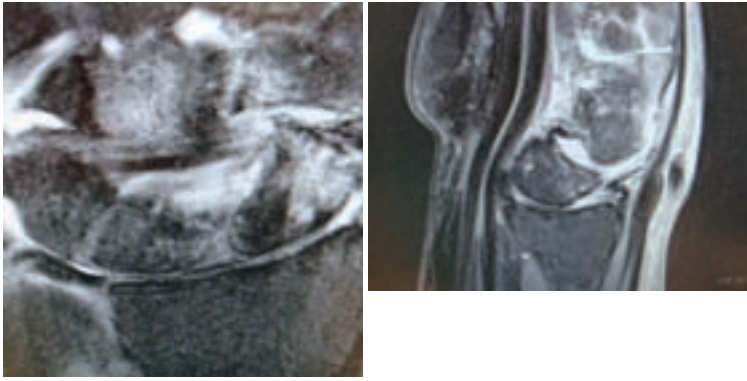


Figure 3: a and b. MRI of the wrist demonstrating tear of the scapholunate ligament, bone edema in the distal scaphoid and capitate, as well as DISI deformity.

for treating basal joint arthritis of the thumb. Few patients with arthritis of the STT or basal joint may have this finding at initial presentation.<sup>3</sup> There are some reports in the literature discussing this deformity, but there is no consensus on how to treat this problem if it occurs following surgery. The clinical relevance of this X-ray finding is also not clear, as some patients are symptomatic. The etiology is not clear. We suggest that there are strong ligaments between the distal scaphoid and the capitate that may be disrupted which will allow the scaphoid to flex and the scapholunate ligament to become deficient and the carpus to collapse. Additional work is needed in this area. Caution is required before recommending this procedure for patients with arthritis of the scaphotrapezial trapezoidal joint. This patient should exhaust all non-operative modalities of treatment.

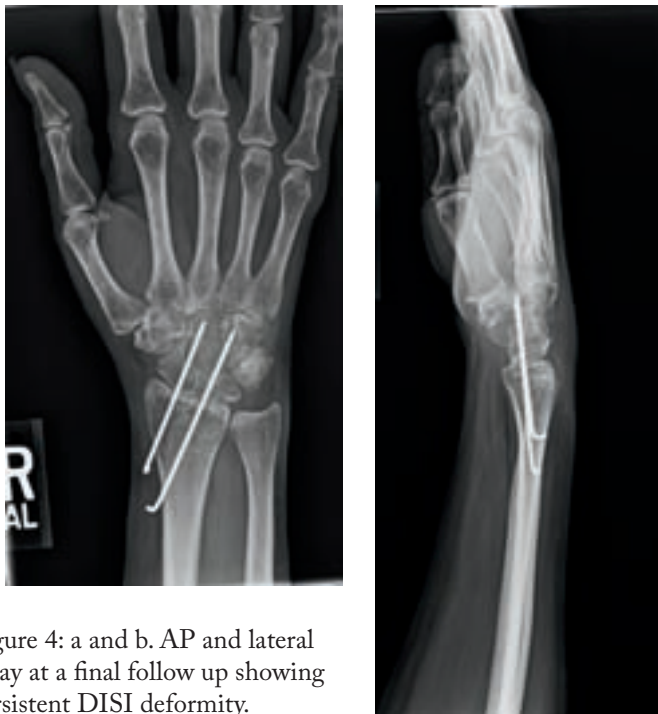

Figure 4: a and b. AP and lateral x-ray at a final follow up showing persistent DISI deformity.

## References

1. Kamal RN, Chehata A, Rainbow MJ, Llusá M, Garcia-Elias M. The effect of the dorsal intercarpal ligament on lunate extension after distal scaphoid excision. *J Surg Hand Am.* 2012;37(11):2240-2245.
2. Ruch DS, Papadonikolakis A. Resection of the scaphoid distal pole for symptomatic scaphoid nonunion after failed previous surgical treatment. *J Surg Hand Am.* 2006;31(4):588-593.
3. Tay SC, Moran SL, Shin AY, Linscheid RL. The clinical implications of scaphotrapezium-trapezoidal arthritis with associated carpal instability. *J Surg Hand Am.* 2007;32(1):47-54.

# Glomus Tumor of the Upper Extremity: An Under-Recognized Cause of Pain

Dean W. Smith MD<sup>1</sup>

1. University of Texas – Houston Department of Orthopaedic Surgery

## Introduction

Glomus tumors are benign tumors most frequently found in the hand but also reported elsewhere in the upper extremity and body. Symptoms include intense focal pain and cold sensitivity, and may also include neuropathy or complex regional pain. Patients may suffer for years before the diagnosis is made. As surgical excision commonly provides complete relief of symptoms, awareness of this tumor and its presentations can prevent unnecessary delays in treatment.

Glomus tumors account for up to 5% of all soft tissue tumors of the hand, and occur mostly within or adjacent to the nail bed. Rarely, these tumors occur in the lower extremity, pelvis, spine, head and neck, and abdominal-thoracic cavity. An accurate diagnosis may not be established for many years, especially with extra-digital tumor locations. Paroxysmal pain and

hypersensitivity to temperature change or pressure are common symptoms in cases involving the digit or nailbed. Extra-digital tumors can display unusual clinical features such as sensory neuropathy and chronic regional pain. These unusual presentations can result in misdiagnosis and delay in treatment. Pain and sensitivity from glomus tumors can be so intense that patients may display dysfunctional illness behavior, major depression, or even request amputation. Once the diagnosis is made, excision of the tumor is usually curative.

## Glomus Tumor

The normal glomus body is a specialized arteriovenous anastomosis located in the stratum reticulare layer of the dermis, more concentrated in the digital and subungual areas, that plays an important role in thermoregulation.<sup>1</sup> Glomus cell populations are characterized by Sucquet-Hoyer canals. Glomus tumors

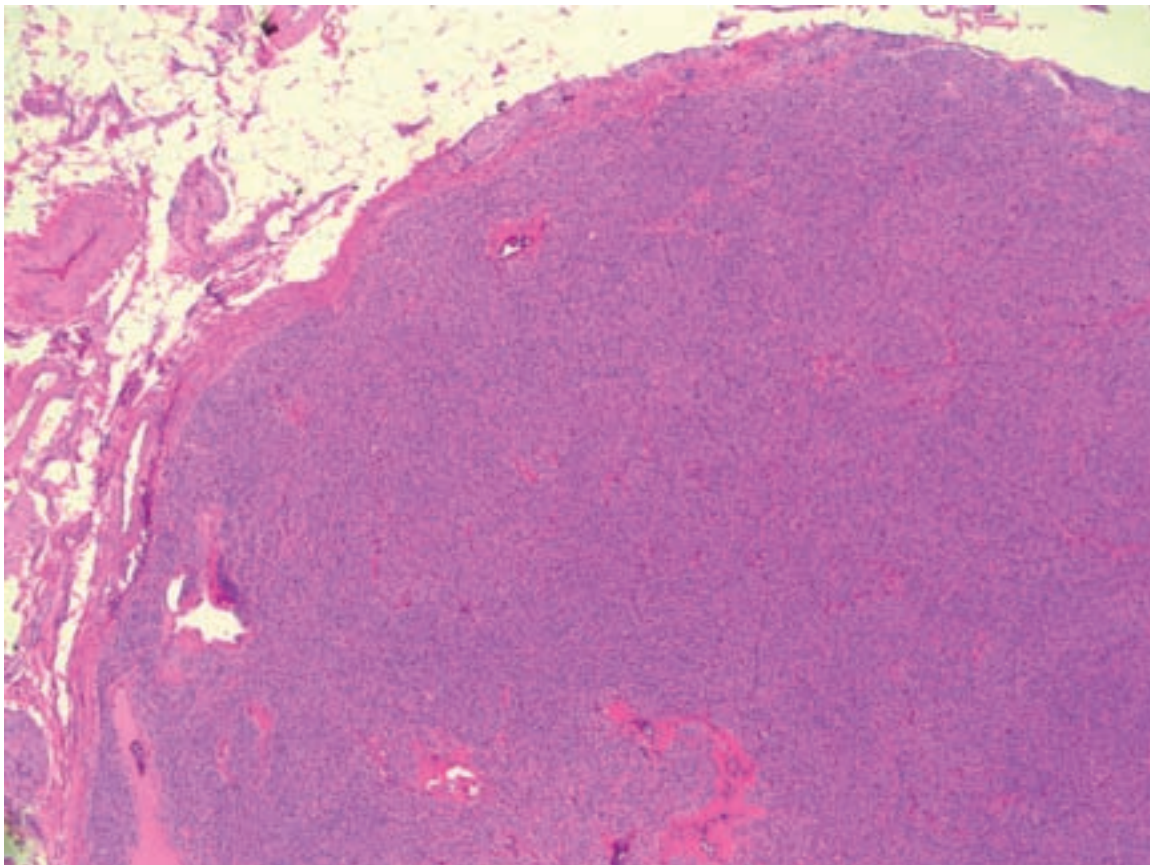


Figure. 1: Photomicrograph showing a well encapsulated nodule containing tightly packed uniform tumor cells.

are hamartomatous benign soft tissue proliferations of smooth muscle cells that typically present as small non-distinctive tumors of the distal extremities, most often within or adjacent to the nailbed. Rare instances of malignant transformation have been described, as has an association with neurofibromatosis type I.<sup>2</sup> The initiating event for glomus cell proliferation and tumor formation is unknown and can occur at any age.

An association of glomus tumor with complex regional pain syndrome has been reported in only a few cases.<sup>2,3,4,5</sup> In cases involving chronic pain, patients demonstrated one or more of the following: major psychological consequences, suicidal tendencies, and/or request for amputation. Delays in diagnosis (range 4-20 years) were reported, along with complete resolution of the chronic pain after surgical removal of the tumor.

Surgical excision of the tumor is an effective treatment.<sup>2,6</sup> Histopathology typically shows a well-encapsulated collection of densely packed benign uniform tumor cells surrounded by a fibrous rim that stains positive for smooth muscle actin and vimentin (Figure 1).

### Clinical Findings

The characteristic symptoms of a glomus tumor, a triad of sensitivity to cold, localized tenderness, and severe intermittent pain, may not always be present, especially with extra-digital tumor locations.<sup>7</sup> The pain can be excruciating, made worse with dependent posturing of the extremity. Tumors located within the nailbed or near the skin surface may demonstrate a bluish hue. Tumors located adjacent to nerves may present as sensory neuropathy.<sup>8</sup> Three clinical tests have been described (the Love pin test, Hildreth test, and cold sensitivity test<sup>6</sup>) to assess for glomus tumor in the upper extremity: none has excellent sensitivity or specificity.

To perform the Love pin test, the examiner presses the end of a paper clip against the area of the suspected tumor. A positive result is intensification of pain. An extension to the Love test, a positive Hildreth test occurs when exsanguination of the suspected digit or limb produces resolution of the pain associated with the pin test. The cold sensitivity test seeks increased pain and sensitivity when the area in question is exposed to a cold object or spray.

The author's personal clinical experience includes 3 patients who, on initial evaluation, had chronic paroxysmal pain of such intensity that each requested digital and/or hand amputation. Work-up identified

atypical glomus tumors in all 3 cases (2 in the digital pulp and 1 at the metacarpal base) that had been symptomatic for an average of 7 years (range 5 to 9).

Van Geertruyden et al., in 51 patients with digital tumor involvement, reported that an average of 2.5 physicians were consulted before correct diagnosis was made, and that symptom duration ranged from 1 to 40 years (average 10 years).<sup>9</sup> In 20 years experience with glomus tumors, Schiefer et al. found 56 extra-digital tumors, 26 of which were on the upper extremity. The average duration of symptoms was 7 years, with most patients having experienced one or more misdiagnoses.<sup>10</sup>

### Imaging

Plain radiography may reveal bony erosion or an osteolytic lesion with sclerotic border, most commonly seen in lesions involving the distal phalanx. Color-duplex ultrasonography can detect glomus tumors as small as 2 mm with high sensitivity and a high negative predictive value.<sup>11,12,13</sup>

Magnetic resonance imaging (MRI) may be beneficial in cases in which the diagnosis or specific location of the lesion is in question.<sup>14,15</sup> T1 MRI imaging of subungual lesions demonstrates a dark, well delineated mass, while on T2-weighted images, there is a high homogeneous signal over the tumor (Figure 2).<sup>15,16</sup> Post-gadolinium and fat saturation sequences may further delineate the lesion. While this magnetic resonance signal pattern can be seen with any vascular tumor, small subungual or digital lesions with this pattern are considered pathognomonic for glomus tumor.

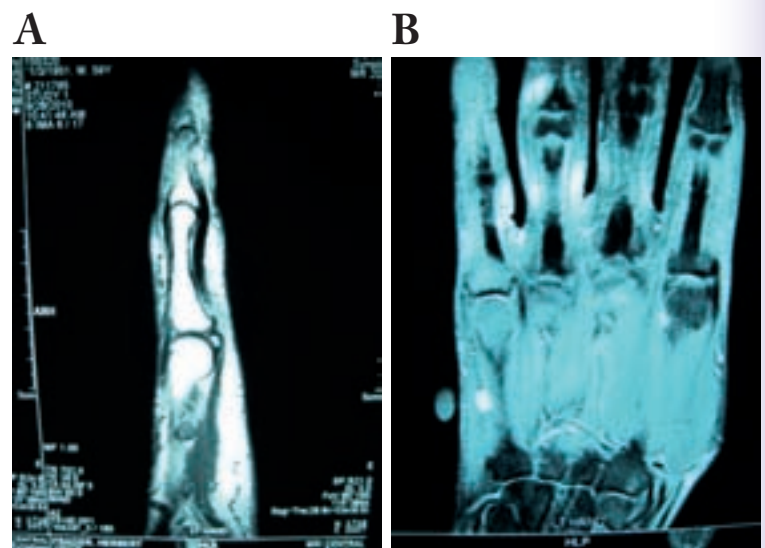


Figure 2: Magnetic resonance imaging demonstrating signal change and mass along the ulnar border of the small finger metacarpal. a. T-1 weighted image b. T-2 weighted image.

## Summary

While glomus tumors are most commonly located within the subungual area of a digit, extra-digital glomus tumors occur and may present with atypical symptoms. The pain and associated sensitivity with extra-digital glomus tumors can be so intense that patients may request amputation or display major psychological effects in cases that remain untreated. Imaging studies should begin with plain radiographs and proceed to color-duplex ultrasonography or MRI as indicated. Excision of the tumor usually provides immediate pain relief.

## References

1. Rettig AC, Strickland JW. Glomus tumor of the digits. *J Hand Surg.* 1977;2A(4):261-265.
2. Stewart DR, Sloan JL, Yao L, et al. Diagnosis, management, and complications of glomus tumors of the digits in neurofibromatosis type I. *J Med Genet.* 2010;47(8):525-532.
3. Longdon EJ, McCulloch TA, Perks AG, et al. Multiple glomus tumors: an unusual presentation of chronic regional pain. *Anesth Analg.* 2007;105(2):554-555.
4. Ghaly RF, Ring AM. Supraclavicular glomus tumor, a 20 year history of undiagnosed shoulder pain: a case report. *Pain.* 1999;83(2):379-382.
5. Smith DW. Periosteal glomus tumor of the metacarpal and associated type II CRPS: case report. *Hand.* 2013. in press.
6. McDermott EM, Weiss AP. Glomus tumors. *J Hand Surg.* 2006;31A(8):1397-1400.
7. Lee DW, Yang JH, Chang S, et al. Clinical and pathological characteristics of extra-digital and digital glomus tumours: a retrospective comparative study. *J Eur Acad Dermatol Venereol.* 2011;25(12):1392-1397.
8. Senol MG, Oguz M, Haholu A, et al. Glomus tumor of forearm: a rare cause of neuralgia. *Acta Neurol Belg.* 2007;107:58-59.
9. Van Geertruyden J, Lorea P, Goldschmidt D, et al. Glomus tumours of the hand. A retrospective study of 51 cases. *J Hand Surg (Br).* 1996;21(2):257-260.
10. Schiefer TK, Parker WL, Anakwenze OA, et al. Extra-digital glomus tumors: a 20 year experience. *Mayo Clin Proc.* 2006;81(10):1337-1344.
11. Matsunaga A, Ochiai T, Abe I, et al. Subungual glomus tumour: evaluation of ultrasound imaging in preoperative assessment. *Eur J Dermatol.* 2007;17(1):67-69.
12. Chen SH, Chen YL, Cheng MH, et al. The use of ultrasonography in preoperative localization of digital glomus tumors. *Plast Reconstr Surg.* 2003;112(1):115-119; discussion 120.
13. Fornage BD. Glomus tumors in the fingers: diagnosis with US. *Radiology.* 1988;167(1):183-185.
14. Theumann NH, Goettmann S, Le Viet D, et al. Recurrent glomus tumors of fingertips: MR imaging evaluation. *Radiology.* 2002;223(1):143-151.
15. Matloub HS, Muoneke VN, Prevel CD, et al. Glomus tumor imaging: use of MRI for localization of occult lesions. *J Hand Surg.* 1992;17A(3):472-475.
16. Lee S, Le H, Munk P, et al. Glomus tumour in the forearm: a case report and review of MRI findings. *JBR-BTR.* 2010;93(6):292-295.

# Narrative Medicine: A Pilot Program Integrating Creative Writing Pedagogy into Orthopaedic Medical Education.

EL Pallai MFA<sup>1</sup>, Caitlin Armijo BS<sup>2</sup>

1. UNM Department of Orthopaedics & Rehabilitation 2. UNM School of Medicine

## Abstract

The University of New Mexico Department of Orthopaedics and Rehabilitation has been piloting a narrative medicine program for its graduate medical students, faculty, and staff. The hypothesis was that with the use of a narrative medicine curriculum focused on creative writing pedagogy, residents and physicians would learn to gain a more detailed patient history, improve their relationships with their patients, and use creative writing as a new outlet to cope with stressful situations and burnout.

**Methods:** Workshops were held in the Orthopaedics conference room. Structured writing exercises were used along with literary analysis and dialogue.

**Results:** Fourteen people participated in the workshops. Participants included orthopaedic fellows (trauma, sports medicine, and hand), faculty, staff, one physical therapy Ph.D. candidate, and visiting residents. There have been 3 workshops (non-fiction, poetry, fiction) and each participant created 1 first draft of a work in each.

**Conclusion:** Creative writing is a useful tool to improve physician-patient relationships and observational skills. Creative writing is a tool useful to physicians, suggesting that narrative medicine should be further integrated into medical curriculum.

## Introduction

The practice of medicine requires vast knowledge in anatomy and physiology, with the integration of these into understanding the disease process. These are objective and testable. The art of medicine also requires communication skills to enable the physician to take a true and complete history, understand the patient's goals and concerns, and empathize with the patient. These skills are subjective, difficult to teach, and difficult to test.

Pedagogy is the science of teaching and teaching skills. The Department of Orthopaedics and Rehabilitation at the University of New Mexico is currently piloting a narrative medicine program focusing on the educational needs of fellows and residents. Narrative medicine is broadly defined as the incorporation of interpretive skills into clinical practice.<sup>1</sup> Narrative medicine and its role in enhancing traditional medical education was explored through a series of workshops utilizing creative writing pedagogy.

Rita Charon notes in her book *Narrative Medicine: Honoring the Stories of Illness* that physicians "must be prepared to offer the self as a therapeutic instrument."<sup>2</sup> By gaining narrative competence and interpretive skills, a physician improves empathy and effectiveness and strengthens relationships with patients. Learning to focus on patients' narratives, physicians improve their ability to listen.

The workshops offered in the Department of Orthopaedics and Rehabilitation focus not just on the benefits of literary analysis, but expand the process to include the benefits of creation, namely, language flexibility and acute observation of the sensory experience. Participants discuss a piece of literary work (poem, essay, story) and then are given structured prompts from which they write their own work.

## History/Theory

Narrative medicine has been explored since the late 1980s, as medical educators searched for methods to combat a growing disconnect between physicians and their work. Narrative medicine programs with a set curriculum began to solidify with the creation of the Narrative Medicine Master of Science program at Columbia University.<sup>3</sup>

In narrative medicine, reflective writing and creative writing must be defined. Reflective writing is the practice in which an individual reflects on a personal experience or event and describes the meaning of that experience. The goal of reflective writing is personal as well as professional development.<sup>4</sup>

Creative writing, while still encouraging self-expression, focuses on the development of literary analysis and writing in a more experimental manner.<sup>4</sup> Rather than simply requiring the writer to respond spontaneously to his or her reflections, creative writing requires the author to revise and edit the work multiple times. Creative writing involves being as interested in the way something is being said as by what is being said.

Many narrative medicine programs and research projects have suggested that poetry is an especially effective form of creative writing. Foster and Freeman conducted a study involving general practitioners who participated in 2 poetry sessions. During interviews conducted after the poetry sessions, the general practitioners revealed that they believed the poetry sessions helped them develop better listening skills, which could be utilized to better understand the patient's

agenda and story. Foster and Freeman concluded that by writing poetry, an individual gains interpretive skills that are useful during clinical encounters. An individual gains these skills through the practice of interpreting the many metaphors, meanings, and perspectives found in poems.<sup>5</sup>

Integrating narrative medicine into clinical practice offers many benefits. Medical students learn how to obtain a better patient story, as well as how to approach forming relationships with patients. The utilization of creative writing during residency gives residents the opportunity to focus on listening skills and emotional development, rather than just scientific knowledge. Horowitz, at NYU, asked his residents to read and interpret a poem of their choosing during daily rounds in the hospital. Poems chosen ranged from children's nursery rhymes to classical metered poetry. The team found the poem sessions useful and positive, improving the interpersonal relationships among the team members.<sup>6</sup>

Narrative medicine may also benefit midcareer physicians, because they are prone to burnout brought about by a perception of their work losing meaning from the repetitiveness of day-to-day schedules.<sup>7</sup> However, integrating the humanities into the clinical practice of midcareer physicians is difficult because these physicians often feel they do not have the time for it.

## Methods

The initial idea at the University of New Mexico was to utilize reflective techniques, such as writing about one's day, as a mode of connecting physicians to the patient and clinical work. However, as objectives were matched to those found in the Accreditation Council for Graduate Medical Education, the workshop objectives were expanded to include the benefits of creative writing.<sup>8</sup> Creative writing is a unique process in that it utilizes, or can be made to utilize, higher levels of thinking.<sup>9</sup> Thus, while the initial learning objectives focused on creating or exploring the participant's medical identity and patient interactions, they were refined into these 3:

1. Increase the participant's flexibility of language.
2. Increase the participant's observational skills and awareness.
3. Connect the participant to themselves, their work, and their patients.

Increasing empathy with patients through creative writing was a secondary focus of the workshops. A framework of creative writing pedagogy based on examination of the components of literature, such as plot, setting, characters, conflict, themes, and point of view,

and writing assignments employing those elements, was used.

Each workshop involved reading a work chosen to reflect on health care to provide a view that might not be the norm in medical education, followed by a short in-session writing assignment. For example, poetry works by disabled individuals who have been orthopaedic patients, published in the anthology *Beauty is a Verb*,<sup>10</sup> were paired with works published in the *Journal of the American Medical Association* written by residents and physicians about their interactions with patients with similar diagnoses (such as orthopaedic trauma). This juxtaposition was meant to create a dialogue between the works that could carry over into the workshop.

Discussing literature revealed differing interpretations of the work: people in different places in career and life interpreted literary works differently. Ideas were exchanged that challenged participants' initial interpretations. Discussing a poem or story is a process of positing a theory of interpretation, dialogue, and then modification of the theory. It is a space that allows participants the freedom to change their mind as more evidence is produced from the written work. Literature is a synthesis of the author's experiences and the reader's, just as a diagnosis comes from a synthesis of patient and doctor experience and dialogue. This discussion of literature allows for an open dialogue focused not just on comprehension and analysis, but synthesis – one of the highest cognitive domains.

After discussion, the participants wrote their own poem or story. The focus was on awareness and the sensory experience, thus the writing exercise asked the writer to "step into" the writing rather than just having a prompt or free-write session. This eased anxiety about the writing process while also showing it as a process. Participants were directed by the facilitator to first list examples, such as listing 10 patient interactions or times when they had been patients. Participants then were asked to "drill down" into the sensory experience or moment of interaction through guided exercises. These steps served to situate the participants in the moment of the action they would be writing about and provided a structured method by which to recall specific experiences and sensory data.

Once these "notes on the writing" were completed, the participants were asked to write a creative piece focusing on the act of writing, such as sentence structure, imagery, point of view, and conflict. This process helped participants become aware of the writing process and removed some of the anxiety that could accompany creative writing.

## Body

The smell of sterility + <sup>perspiration</sup> sweat began to mix.

The clang of the tools <sup>has</sup> ~~has~~ stopped

replaced by ~~the~~ hurried voices + rapid orders

Numbers sets in

Controlled panic replaces the confident faces of pros.

~~Waiting in silence~~ ; Waiting

~~Once A cry I hear~~ ~~Cries~~ ~~from deep the hulk breathe~~ ~~over heart~~ ~~but no sign yet~~

Feeling Returns, Exhale

~~Body is here is Born.~~

My Boy is here Born.

Figure. 1: This is a poem written by a participant in a narrative medicine workshop.



## Discussion

Many participants came to the writing workshops with little or no creative writing experience. Breaking down the writing process eased initial anxiety about taking part in an activity currently outside the norm of medical education. An example of a participant's workshop writing – a poem, “Brody” – is presented in Figure 1.

Through the “smell of sterility + perspiration”, the “sounds of the tongs now absent”, the “hurried voices and rapid orders” and the lack of sound with the “silence, waiting” the author conveyed scene and anticipation to the reader. The writer did not describe visual experiences in the poem, but sound or the anticipation of sound, as well as feeling, with numbness dissipating in the second to last line. This suggests the involvement of senses beyond sight.

The use of sensory recall and observational skills in “Brody,” a poem about the birth of the author's child, also relates to medical practice. Tools that aid the physician in recalling all details of the interactions with patients may increase the efficacy of visits and the patient/doctor bond, as the focus becomes not just the patient but also on the interaction between patient and physician.

This poem also exhibits language flexibility. Poetry is particularly beneficial to this objective, as there is no set way to write a line of poetry. This is most prominently displayed in the line, “Cries from down the hall.” The author tried several permutations, starting with “Cries a cry I hear.” The author eliminated the directness of “I hear,” as well as “are heard” and allows the reader to understand the sensation of the cries heard through directionality, “from down the hall.”

Flexibility of language is important to a physician, especially physicians who treat Limited English Proficient (LEP) patients and patients from culturally diverse backgrounds. It is important to understand the various ways a sentence can be spoken to convey meaning and be open to understanding a patient's speech patterns. Equally important is the ability to rephrase dialogue in a way that can convey meaning to patients with different cultural and linguistic backgrounds.

## Conclusion

In research and in practice, the integration of a narrative medicine curriculum focused on creative writing pedagogy, even using a series of short workshops, can have a beneficial impact on medical education, not just at the graduate level but across the realm of medical experience. The workshops provide the opportunity to explore the complex nature of modern medicine through

literature and the synthesis of ideas. Utilizing creative writing pedagogy in a medical setting allows exploration of the flexibility of language and increases awareness of sensory information provided in a patient/doctor relationship. This may increase the effectiveness of the clinical visit and provide the doctor more information with which to make an accurate diagnosis. Increased comfort with narrative writing may provide an outlet for expression while strengthening skills essential for growth as a physician or other health care worker.

## References

1. Charon R. Narrative medicine: a model for empathy, reflection, profession, and trust. *JAMA*. 2001;286(15):1897-1902.
2. Charon R. *Narrative Medicine: Honoring the Stories of Illness*. New York, NY: Oxford University Press; 2006.
3. Columbia University Medical Center Narrative Medicine Program [homepage]. New York, NY: The program in narrative medicine, 2013. <http://www.narrativemedicine.org/>. Accessed May 8, 2013.
4. Kerr L. More than words: applying the discipline of literary creative writing to the practice of reflective writing in health care education. *J Med Humanit*. 2010;31(4):295-301.
5. Foster W, Freeman E. Poetry in general practice education: perceptions of learners. *Fam Pract*. 2008;25(4):294-303.
6. Horowitz HW. Poetry on rounds: a model for the integration of humanities into residency training. *Lancet*. 1996;347(8999):447-449.
7. Myers KR, George DR. Humanities mini-course curricula for midcareer health professionals at the Penn State Milton S. Hershey Medical Center. *Acad Med*. 2012;87(8):1132-1137.
8. Accreditation Council for Graduate Medical Education [homepage]. Chicago, IL: ACGME, 2013. <http://acgme.org>. Accessed May 8, 2013.
9. Forehand M. Bloom's taxonomy. In: Orey M, ed. *Emerging Perspectives on Learning, Teaching, and Technology*. 2001. [http://projects.coe.uga.edu/epltt/index.php?title=Bloom's\\_Taxonomy](http://projects.coe.uga.edu/epltt/index.php?title=Bloom's_Taxonomy). Accessed March 10, 2013.
10. Bartlett J, Black SF, Northen M. *Beauty Is a Verb: The New Poetry of Disability*. El Paso, TX: Cinco Puntos Press; 2011.

# The Orthopaedic Trauma Association Fracture Classification for Publications and Routine Daily Use

Thomas DeCoster MD<sup>1</sup>

1. UNM Department of Orthopaedics & Rehabilitation

## Introduction

As orthopaedic surgery has evolved, numerous classification systems for various fracture patterns have been developed.<sup>1-6</sup> These various fracture classification systems as a whole have lacked uniformity, consistency, or validation of determinability or clinical significance. Each has had a specific way of describing a specific fracture pattern without offering applicability to fractures in other regions of the body. Also, multiple individual classifications exist for similar fracture patterns in the same body region. This lack of uniformity has resulted in an ineffective orthopaedic language and poor standardization, making it difficult to accumulate and interpret meaningful data.

Fracture classification is a useful way to facilitate communication regarding fracture care. It allows us to lump similar injuries and distinguish between dissimilar injuries at a variety of levels. Fracture classification is important for routine clinical use as well as musculoskeletal research. Historically, a wide variety of classifications have been utilized in orthopaedics and each classification has its strengths and deficiencies.<sup>6-9</sup> The Orthopaedic Trauma Association used the AO Mueller Fracture Classification to develop a comprehensive systematic illustrated classification

that was published in 1996.<sup>9-11</sup> I contributed to that work. The OTA Fracture Classification was revised and updated and republished in 2007 as the OTA Fracture and Dislocation Classification Compendium.<sup>12</sup> I served on the OTA Classification Committee and co-authored the published compendium. This classification has gained widespread, but not universal, use in the orthopaedic literature, and is gaining acceptance in routine fracture care communication. This article summarizes the basic elements of the OTA Fracture Classification, identifies the attractive features and appropriate applications of the classification, and mentions current problems and future directions.

The OTA Fracture Classification is available and provides a useful standard for reporting of skeletal trauma research.<sup>13</sup> The use of standard terminology and scheme of fracture classification allows for a more uniform reporting of data and facilitates understanding comparison and reproducibility of results. It gives the orthopaedic community a common language platform on which to base a scholarly discussion and development of our subspecialty. This standard should be routinely used for reporting of results in orthopaedic trauma journals. The Classification has been developed and adopted by the OTA and the Journal of Orthopaedic Trauma (JOT) and utilization of the Classification is required in the instructions to authors of the JOT.<sup>14</sup>

The OTA Fracture Classification should also be used for routine fracture communication outside of research and publications. The medical record and other written documents, like radiographic interpretations and operative notes, should utilize the classification.<sup>15</sup> The hierarchical organization of the classification allows the fractures to be identified at the appropriate level of specificity. The bone and bone segment, the classification's 2 most basic elements, should always be included when describing a fracture anywhere.

"Femur shaft fracture" is far better terminology than "broken leg" or any number of alternatives. "Femur shaft fracture" is directly specified by the language of the OTA Fracture Classification, which first names the bone and then distinguishes among 3 bone segments for each long bone (proximal, shaft, and distal). This same technique is utilized for the femur, leg (tibia and fibula), humerus, and forearm (radius and ulna). The other regions are the spine, pelvis, hand and wrist, foot, and shoulder girdle (scapula and clavicle) (Table 1)<sup>12</sup>.

Table 1  
Advantageous features of the OTA fracture classification system

Feature
Comprehensive
Radiographically and anatomically based
Hierarchical
Consistent
Referenced
Verified
Current
Alphanumeric shorthand available

### Advantages of the OTA Fracture Classification

The OTA Fracture Classification is *comprehensive* in that it applies to every bone in the human skeleton treated by orthopaedists, as well as every fracture of every bone. This classification includes everything from the clavicle to the distal phalanx of the big toe. Every possible fracture pattern and severity from a nondisplaced crack to segmental comminution is included. The Classification is all inclusive as there are no fractures that do not have a place within the classification. Furthermore, the classification is mutually exclusive in that the definitions allow for a unique identifier for each fracture pattern.<sup>12</sup>

The OTA Fracture Classification is *radiographically and anatomically based*. Fractures are classified by their radiographic appearance based on the bone involved, the bone segment involved, and the geometric pattern of the fractures and involvement of specific anatomic structures that can be identified radiographically. For example, the proximal and distal aspects of the long bones are subdivided into 3 types (extra-articular, partial articular, and total articular) based on degree of articular involvement. This consistent basis for classification is in distinction to other classifications or terminology like “mechanism of injury.”

The OTA Fracture Classification is *hierarchical* in that it starts with the most basic element and extends to as much detail as needed for the purpose of user. The levels of the classification are shown in Table 2. The most basic element is the broken bone (by name), which is then subclassified by the bone segment (e.g., femur shaft fracture). Each bone segment has 3 types, each type has 3 groups (total of 9 categories), each group has 3 subgroups (total of 27 categories), and some subgroups are further subclassified (51 categories). The person

Table 2  
Hierarchical levels of the OTA fracture classification system

Element
Bone
Bone segment
Type
Group
Subgroup
Other

utilizing the OTA Fracture Classification can match the level of specificity to the desired purpose. Chapter titles for publications would typically utilize the bone segment level (e.g., “femur shaft fractures”). Bone segment level would also be appropriate for diagnosis in medical records (e.g., “femur shaft fracture, left”). The “type” level of classification might be appropriate for a journal article (e.g., “proximal tibia, total articular fractures”) or clinically for an operative report (e.g., “ORIF of left proximal tibia, total articular fracture”). The group level might be appropriate for reporting a particularly high rate of complication in a journal article (e.g., “post-traumatic arthritis was highest in the total articular proximal tibia fractures with articular comminution”). Clinically, this might be useful within the body of an operative note to detail the articular injury pattern and fixation. The main point of the hierarchical component is that this classification can be utilized at the level of detail appropriate for the user. This feature is lacking in the vast majority of other classifications and makes the OTA Classification much more useful.

The OTA Classification is *consistent* in that the same techniques are utilized to classify patterns throughout the body. Each long bone is divided into proximal, shaft, and distal. The same technique is utilized to make this distinction (the rule of squares). The types are extra-articular, partial articular and total articular for each of the ends of the long bones. The shaft bone segments are classified into types based on fracture geometry (transverse, oblique, spiral), and groups based on pattern of comminution (none, butterfly, segmental). This consistency allows for easy recall of the classification and improves reliability and reproducibility. The pattern is occasionally modified when clinically indicated, such as using the anatomic landmark of the base of the lesser trochanter to designate the distal extent of the “proximal femur fractures” rather than the rule of squares.

The OTA Classification is *referenced*, as well as illustrated, in the *Journal of Orthopaedic Trauma OTA Fracture and Dislocation Classification Compendium*. This standardized reference allows everyone to utilize the same standard that is readily available worldwide. This helps to avoid problems with modification and mal-application that is rampant with the use of other classifications.<sup>16</sup> The illustrations and classification directions are particularly helpful to achieve consistent application of the classification. The illustrations can be compared to the radiographs of individual patients to enhance consistency of application of the classification, somewhat independent of language. This level of information is typically absent from other classifications which are generally included as a part of some bigger study of technique or clinical outcome.

The OTA Classification is *verified*. This reference and citation should be used routinely when the OTA Classification is utilized in publications. Another benefit of the referenced classification is that it has been verified. Numerous studies have reported the reliability and reproducibility of particular aspects of the classification.<sup>10,11</sup> This will save time and space within submitted manuscripts to focus on other important determinants of outcome and relieve the author of developing, reporting, and justifying a unique fracture classification for each article. It will also save time and facilitate understanding on the part of the reader interpreting the results of the study and comparing it to other existing similar studies that use a common language and classification scheme. This enables the reader to focus on the variable parameters (like individual treatment) while maintaining confidence that the treatments are being applied to similar fractures (by OTA classification).

The OTA Classification is *current*. It was originally published in 1996 and revised and re-published in 2007. This allowed inclusion of new knowledge and the incorporation of new and clinically important concepts with reconciliation with other existing classifications (like the AO Classification). The 2007 version also provides more detail for relatively “neglected” bone segments like the foot and hand and dislocations. It is planned for the 2017 revision of the classification to include the latest scapula fracture classification and other updates from the literature.

There is an *alphanumeric shorthand* available for the OTA Classification. Each bone is designated with a digit (1 to 9) and each bone segment with a second digit (1 to 3 usually; 1 to 9 in special circumstances). The types are designated with a capital letter (A, B, C usually; occasionally D). The groups are designated with another digit (1 to 3 usually; 1 to 5 in special circumstances), and subgroups by a digit following a period (1 to 3 usually). A total articular (bicondylar) proximal tibia fracture would be designated 41C. If both the medial and lateral plateau are comminuted the designation would be 41-C3.<sup>3</sup> This 5 digit alpha-numeric code then captures all of the verbiage in a concise manner. However, care should be taken to utilize the alphanumeric code as a shorthand version to optimize effective communication. There is a tendency to go straight to the code and this is not effective communication if the recipient or reader is not familiar with the code or if the code is inappropriately applied. A small typographical error or misunderstanding will result in a gross miscommunication. The alphanumeric designation is most appropriate for research data bases or internal record keeping or communication when conciseness is highly desirable.

### Problems with the OTA Fracture Classification

The Classification is not being used optimally as of 2011. The results of a study we completed and submitted for publication reveal that only 38% of fracture articles published in the JOT in 2011 utilized the OTA Classification. This shows that the classification is being used somewhat, but that there is room for improvement. The results also show that only 8% of fracture articles accurately cite the 2007 publication. There is a lot of room for improvement in the rate at which the classification is accurately cited. We believe that accurate citation will improve the accuracy with which the classification is used as authors and readers refer to the standardized publication and not some other version or potentially flawed understanding of the classification.<sup>17,18</sup>

### Utilizing the OTA Fracture Classification

There isn't much stopping its wider use other than inertia. There is no obvious major impediment to utilization of the OTA Fracture Classification other than the historical inertia of tradition in orthopaedic publishing. We found a low rate of need for another classification in reports from 2011 where some other classification contained clinically important distinctions that were not captured by the OTA Classification. In the uncommon situations where that does exist, the use of 2 different classifications within the same manuscript and a paragraph comparing the reported results are sufficient to capture and report all significant data. Furthermore, this will serve as a directive to future development of the OTA Classification to incorporate clinically significant category designations.

In the future, authors (and reviewers and editors) should make sure it is used and monitor the percentage usage on a yearly basis. We recommend routine utilization of the OTA Fracture Classification in trauma research publication in general, and specifically in study design and grant application and in selection of titles for articles, podium presentations, posters, book chapters, and other scientific communication. In reporting of results and complications, the 2007 reference should always be cited. The percentage of JOT articles utilizing and citing the OTA Classification should be reviewed annually.

Once it is standardized in orthopaedic trauma literature (JOT), a more convincing case for its use in other journals (Journal of Bone and Joint Surgery, Journal of Orthopaedic Research, etc), textbook, and educational literature can be made. When the percentage of articles in JOT that use and cite the OTA Classification is over 90%, then an effort should be made to extend this pattern to JBJS and other orthopaedic journals, textbooks, and educational literature.

There are many benefits to increased frequency of utilization of the OTA Fracture Classification (See Table 3). Utilizing it will improve the quality of our literature and knowledge and facilitate effective communication. Effective communication will be achieved by utilizing standardized terminology. This is important so that similar things are called the same thing and dissimilar things are called by different names. Standardization applies to all levels of the OTA Fracture Classification. This is crucial in the time of computer searches where consistency and standardization is required.<sup>17,18</sup> For example, if one wanted to perform a meta-analysis of the literature on treatment of distal radius fractures to determine standard of care it would be useful if a computer search of “distal radius fractures” in the title identified all pertinent articles. It would be less effective if “wrist fractures” or “Colles fracture” or any number of other eponyms or non-anatomic, non-OTA phrases were utilized in the article title. There are many other situations where non-OTA terminology is still commonly used in orthopaedic writing, even publications. “Hip fractures” is a phrase commonly used and seems to apply to proximal femur fractures. But the hip is a joint and not a bone. Acetabular fractures at least involve the hip joint but are not typically included in “hip fracture” series. Trochanteric proximal femur fractures are, by definition, not only extra-articular but outside of the hip capsule, yet they are commonly included in series titled “hip fractures.” This lack of consistency and anatomic accuracy plagues the past orthopaedic literature and is being improved by utilization of OTA Fracture Classification in the title of articles. “Ankle fractures” is another example of common terminology that is not anatomically consistent or correct. “Ankle fractures” does not typically include talar dome fractures, which clearly goes into the ankle joint; additionally, the talus is colloquially known as “the ankle bone.” “Ankle fracture” does typically include fracture of the fibula several centimeters proximal to the ankle joint. “Ankle fractures” do not typically include distal tibia plafond fractures, even though the latter involves even more injury to the ankle joint. All of this inconsistency, anatomic inaccuracy, and confusion can be avoided if the OTA terminology is utilized. Talus fractures are identified as just that. The distal tibia and fibula is divided into malleolar pattern (bone segment alphanumeric designation 44) and the plafond (bone segment alphanumeric designation 43).

Standard terminology is helpful for several reasons. The first is that it clearly and uniquely identifies the type of injury that is included in the report. It distinguishes the fracture from other, similar fractures. The terminology is uniquely defined by the OTA Fracture Classification. This contrasts with alternative

techniques, like eponyms or other classifications that have been reported but modified and adapted to clinical use, thereby confusing exactly what they mean and how they are applied. Is a Colles fracture any fracture of the distal radius or only the extra-articular dorsally angulated fracture? Is a Schatzker 5 any bicondylar tibial plateau fracture or only the one with an intact central column as originally described by Schatzker? Use of the OTA Fracture Classification terminology overcomes most of those problems, as each term is uniquely defined and every fracture falls in exactly 1 category. The OTA Classification is easily learned, as it uses consistent, anatomically accurate terms that are referenced in a readily available and readable compendium.

The OTA Fracture Classification utilizes clinically important criteria to separate categories. In general, the higher the type and group designation the more severe the injury and the worse the prognosis. A type level example is: extra-articular (A) versus partial articular (B) versus total articular (C). A group level example is comminution: non-comminuted (1), butterfly or “wedge” comminution (2), segmental comminution (3). Numerous publications have supported the prognostic value of specific aspects of the OTA Fracture Classification schemes at the type and group level, and a few at the subgroup level.<sup>19-21</sup>

The OTA Fracture Classification is also very useful to document less common injuries, like dislocations and fractures of the small bones. The classification of both of these areas were extensively revised and made more consistent and clinically applicable with the 2007 revision. Dislocations are identified by the joint involved (equivalent to bone segment) with the alphanumeric second digit as 0 to indicate dislocation. For example, knee dislocations are designated 40. The types are by direction of the distal part anatomically, thus anterior dislocations are A, posterior B, medial C, lateral D, and other E.

The small bone classification is consistent in the hand and foot with designation of the body part (hand 7 or foot 8), segment (tarsals, metatarsals, phalanges; carpus, metacarpals, phalanges). Tarsal and carpal bone is given a second digit numeric designation (1 - 9) and typed by absence (A) or presence (B) of comminution. Phalanges, metacarpals, and metatarsals are grouped similar to “long bones” into proximal, distal, and shaft. Subgrouping is by comminution.

## Conclusion

Utilizing the OTA Fracture Classification will improve the overall consistency and quality of orthopaedic trauma literature and be beneficial to authors, reviewers, editors, and readers. Authors benefit

Table 3  
Benefits of the OTA Fracture Classification system

Advantage
Effective communication
Standardized terminology
Efficient computer searches
Consistency
Comprehensive
Understood by all
Easily learned
Clinically applicable

by having established standardized terminology and classification schemes that they merely need to apply to their investigation. They will not have to develop or explain their individualized terminology or scheme. Furthermore, they will have easy access to existing literature by computer searches using standardized terms to direct the development of their own experimental methods and comparative discussion of results. The people who read the articles will also benefit from standardized and well-defined terminology and classification schemes. The standardized terms in the title and abstract will enable the reader to quickly understand which fractures are included. The alternative to the use of standardized language is the use of eponyms and jargon which may be an effective shortcut among a small group of club members who are familiar with the code, but this is not an effective technique for the wide dissemination of scientific knowledge.

The OTA Fracture Classification alphanumeric shorthand can be utilized when appropriate as a concise, elegant form of designation, especially in research settings and internal use situations. However, care should be taken to avoid overuse of the alphanumeric shorthand in more widely disseminated communication (like medical records), as lack of familiarity with the code by other individuals will render this confusing rather than clear communication.

Utilizing the OTA Fracture Classification by standardized referenced words and phrases in routine daily clinical communication will improve the overall consistency, quality, and effectiveness of communication in medical records. Other health care providers (e.g., ward nurses or anesthesiologists) will understand the fracture description by use of standard anatomic terms

and referenced phrases. Anyone who does not understand a term can find it in standard texts or dictionaries and can see the particular details of the published classification. The more frequently the classification is used, the easier it will be to remember and understand.

## References

1. Martin JS, Marsh JL. Current classification of fractures. Rationale and utility. *Radiol Clin North Am.* 1997;35(3):491-506.
2. Neer CS II. Displaced proximal humeral fractures. I. Classification and evaluation. *J Bone Joint Surg Am.* 1970;52(6):1077-1089.
3. Garbuz DS, Masri BA, Esdaile J, Duncan CP. Classification systems in orthopaedics. *J Am Acad Orthop Surg.* 2002;10(4):290-297.
4. Müller ME, Nazarian S, Koch P, Schatzker J. *The Comprehensive Classification of Fractures of Long Bones.* Berlin: Springer-Verlag; 1990.
5. Colton CL. Telling the bones (editorial). *J Bone Joint Surg Br.* 1991;73-B(3):362-364.
6. Marsh JL. OTA fracture classification. *J Orthop Trauma.* 2009;23(8):551.
7. Lichtenhahn P, Fernandez DL, Schatzker J. [Analysis of the "user friendliness" of the AO classification of fractures]. *Helv Chir Acta.* 1992;58(6):919-924.
8. Walton NP, Harish S, Roberts , Blundell C. AO or Schatzker? How reliable is classification of tibial plateau fractures? *Arch Orthop Trauma Surg.* 2003;123(8):396-398.
9. Bernstein J, Adler LM, Blank JE, Dalsey RM, Williams GR, Ionnotti JP. Evaluation of the Neer system of classification of proximal humeral fractures with computerized tomographic scans and plain radiographs. *J Bone Joint Surg Am.* 1996;78(9):1371-1375.
10. Fracture and dislocation compendium. Orthopaedic Trauma Association Committee for Coding and Classification. *J Orthop Trauma.* 1996;10(Suppl 1:v-ix):1-154.
11. Swiontowski MF, Agel J, McAndrew MP, Burgess AR, MacKenzie EJ. Outcome validation of the AO/OTA fracture classification system. *J Orthop Trauma.* 2000;14(8):534-541.
12. Marsh JL, Slongo TF, Agel J, et al. Fracture and dislocation classification compendium – 2007: Orthopaedic Trauma Association Classification, Database and Outcomes Committee. *J Orthop Trauma.* 2007;21(10 Suppl):S1-133.

13. Meling T, Harboe K, Enoksen CH, Aarflot M, Arthursson AJ, Søreide K. How reliable and accurate is the AO/OTA comprehensive classification for adult long-bone fractures? *J Trauma Acute Care Surg*. 2012;73(1):224-231.
14. Journal of orthopaedic trauma online submission and review system: instructions for authors [JOT Editorial Manager Website]. 2012. Available at <http://www.editorialmanager.com/jot>. Accessed October, 2012.
15. Meling T, Harboe K, Arthursson AJ, Søreide K. Steppingstones to the implementation of an inhospital fracture and dislocation registry using the AO/OTA classification: compliance, completeness and commitment. *Scand J Trauma Resusc Emerg Med*. 2010;18:54
16. Andersen DJ, Blair WF, Steyers CM, Adams BD, el-Khoury GY, Brandser EA. Classification of distal radius fractures: an analysis of interobserver reliability and intraobserver reproducibility. *J Hand Surg Am*. 1996;21(4):574-582.
17. Cheng TO. Reference citation is important. *J Lab Clin Med*. 2002;140(6):418.
18. Iino S. [Importance of the reference citation and the limitations in publication]. *Seikei Geka*. 1966;17(6):458.
19. Court-Brown CM, Garg A, McQueen MM. The epidemiology of proximal humeral fractures. *Acta Orthop Scand*. 2001;72(4):365-371.
20. Egol KA, Soojian MG, Walsh M, Katz J, Rosenberg AD, Paksima N. Regional anesthesia improves outcome after distal radius fracture fixation over general anesthesia. *J Orthop Trauma*. 2012;26(9):545-549.
21. McKenna P, Leonar M, Connolly P, Boran S, McCormack D. A Comparison of pediatric forearm fracture reduction between conscious sedation and general anesthesia. *J Orthop Trauma*. 2012;26(9):550-554.

# What Are the Benefits to Orthopaedic Residents of Understanding Research Methodology?

Deana Mercer MD<sup>1</sup>

1. UNM Department of Orthopaedics & Rehabilitation

Understanding research methodology offers the same benefits to residents as to all clinicians: it helps all of us take better care of our patients.

Every month, hundreds of clinical and basic science articles are published by myriad journals offered to guide clinical practice. The conclusions drawn by the authors (as well as readers) is of highly variable quality and often conclusions are not supported by the methodology. As clinicians reading these articles, we must be able to efficiently determine which have followed a reasonable methodology that supports the authors' conclusion. Before changing one's practice based on a scientific article, the clinician needs basic tools to ascertain that the article's conclusion is the result of rigor in a) generating a hypothesis and specific aims, b) sound methodology, accurate statistical analysis, and c) generating a conclusion which is supported by the study findings. The report also needs to be interpreted within the context of existing knowledge and one's own personal experience.

Medical school trained doctors do not typically have much specific training in research methodology.<sup>1</sup> The National Institutes of Health (NIH) and the Clinical Translational Science Centers (CTSC) recognize this. These institutions have created and funded specific programs to address this deficiency. One of the programs offered at the University of New Mexico, in which I had the opportunity to participate, is the "Master of Science in Clinical Research" (MSCR). The program is geared towards the clinician and the courses pertain to medical practice. The curriculum for the MSCR program was generated by clinicians, for clinicians. It is a 2-year curriculum taught by PhDs and MDs dedicated to improving research quality. The courses provide tools to become a better researcher and critical reader of the literature. This opportunity to further research understanding through the MSCR program is available to orthopaedic residents and fellows, although this rather arduous 3-year process is not readily incorporated into orthopaedic residency curriculum. Completing this program demonstrated to me how important enhanced understanding of research methodology is to orthopaedic residents.

Having completed this master's program in clinical research, I now have a much better understanding of research methodology and techniques. For the resident

surgeon who does not have the benefit of this specific training, I believe the old adage "it takes one to know one" can be applied. The orthopaedic resident can acquire a functional, practical working knowledge of research methodology (to "know one") by completing a research project (to "take one"). This is a much more efficient and appropriate way (with a steep learning curve, which is good) to acquire this important skill at the appropriate level than alternatives like a research year or a 3 year curriculum with a much longer learning curve to acquire the skill. The practical aspect of a specific research project and the tangibility of a publication contribute to this efficient steep learning curve. Completing a research project also brings the orthopaedic resident into a contributor role to the orthopaedic knowledge fund rather than merely being a consumer of other people's efforts. Everyone should contribute something to the common good at some point in life and this is a perfectly timed opportunity for the orthopaedic resident to contribute to the orthopaedic community fund of knowledge. How do we know that the A2 pulley should be released to treat trigger finger? Because someone in the past put in the time and effort to perform research and determine and report that this was an effective technique. We can pay homage to this and other past work by each making a contribution on our own, while becoming more skilled at the same time.

One of the best ways to become a better critical reader of the literature, an invaluable and necessary skill, is to actually perform research. Completing a research project provides a practical understanding of the many difficulties inevitably encountered, as well as the practical realization of executing an "ideal" methodology.

Also integral to completing a project is to understand the potential for errors to creep into the data. I was told by one of my mentors to be very critical when reading scientific journals for a variety of problems. Sometimes the methodology does not support the conclusions. Outcome assessment may be biased. Poor results may be excluded. I have been told to expect that "there is a lie in every paragraph," which does not render the information useless but does instill some skepticism and reservation before applying the conclusions of a report to a clinical situation. We cannot base our care of patients and change our clinical practice on poor quality work, so how do we sort the "wheat from the



chaff” and recognize the difference? A scientific paper published by a well-respected clinician with a flawed conclusion may become accepted treatment despite faulty methodology and lack of scientific rigor. We can prevent this by insisting upon rigor in research methodology and conclusion generation, both in our own work and in our acceptance of published works.

One need not profess a career in research to understand these principles. Struggling through the research process on 1 or 2 projects offers a basic understanding of the limitations of the process itself and is never wasted effort. It is an important part of resident education, as it lays the basis for a lifetime of adult learning, and we must support it wholeheartedly. Completing a research project and understanding research methodology is as important to an orthopaedic resident as is the acquisition of diagnostic acumen, knowledge base, inter-personal affect, and surgical skill.

## **References**

1. Schrier RW. Ensuring the survival of the clinician-scientist. *Acad Med.* 1997;72(7):589-94.

# Posterolateral Corner Injuries of the Knee

Benjamin C. Olson DO<sup>1</sup>, Robert C. Schenck, Jr. MD<sup>1</sup>, Daniel C. Wascher MD<sup>1</sup>

1. UNM Department of Orthopaedics & Rehabilitation

## Introduction

Posterolateral corner (PLC) injuries of the knee are a rare but often debilitating injury.<sup>1,2</sup> If left untreated, PLC injuries can lead to persistent instability, pain, articular degeneration, and failure of surgically treated cruciate ligament reconstructions.<sup>3-6</sup> Often resulting from a high energy hyperextension varus impact to the anteromedial knee<sup>7</sup>, cruciate ligament injuries, fractures, and neurovascular compromise are commonly associated with this injury.<sup>1-2,7-9</sup> Early recognition and appropriate treatment relies on an understanding of the anatomy, a thorough knee examination, careful surgical technique, and a protected rehabilitation protocol.

Due to the rarity of isolated PLC injuries, much of the literature on identification, treatment, and outcome is obtained from studies involving multiligament knee injuries. Acknowledging that the multi-ligament literature may not be directly applicable to the patient with an isolated PLC injury, the vast majority of patients with this condition will present in the setting of a knee dislocation.

## Anatomy

There are over 28 described structures that comprise the PLC of the knee.<sup>9</sup> Recent biomechanical studies have simplified the description to 3 main anatomic structures: the popliteus tendon, popliteofibular ligament (PFL), and fibular collateral ligament (FCL). These 3 have been identified as the most important structures for posterolateral knee stability.<sup>10</sup> The FCL is the primary restraint to varus stress, most notably during the first 30° of flexion.<sup>11</sup> The popliteus tendon and PFL are important structures for resisting external rotation torque.<sup>10,12-14</sup> Repair or reconstruction of the PLC typically attempts to recreate the stability provided by these 3 structures. The FCL originates in a slight depression slightly proximal and posterior to the lateral epicondyle of the femur.<sup>15</sup> Distally the FCL inserts on the anterolateral portion of the fibular head.<sup>16</sup> The popliteus tendon attaches on average 18.5 mm anterior and distal to the FCL within the popliteus sulcus of the lateral femur.<sup>15</sup> The sulcus can easily be seen and palpated during operative exploration. Distally the tendon gives rise to 3 popliteomeniscal fascicles which attach to the lateral meniscus.<sup>15</sup> The popliteofibular ligament originates at the musculotendinous junction of the popliteus providing anterior and posterior divisions which course laterally to insert on the posteromedial fibular styloid and FCL.<sup>12</sup>

There is an important correlation that exists between the integrity of the cruciates and PLC in providing stability to the knee. The posterior cruciate ligament (PCL) primarily resists posterior translation of the tibia on the femur. In addition, the posterior cruciate acts as a secondary restraint when varus and external rotation forces are applied to the knee. The PLC, on the other hand, provides a primary restraint to varus stress and external rotation forces to the knee. An important secondary role of the PLC is to provide restraint to posterior translation of the tibia on the femur.<sup>1,8,10,17</sup> Understanding this correlation between the PCL and PLC will improve the clinical diagnostic accuracy of complex ligament injuries to the knee.

## Diagnosis

### Gait and Alignment

Patients with chronic injuries to the PLC may demonstrate a varus thrust during foot strike of the gait cycle. While this can also be seen in medial compartment knee arthritis, recognition of this gait pattern in the setting of combined varus malalignment and anterior cruciate ligament (ACL) deficiency is important for identifying a PLC injury.

Recognition of preexisting limb malalignment on physical exam impacts treatment strategy regarding ligament injuries about the knee. Varus malalignment and varus thrust gait are specific indications for a valgus-producing proximal tibial osteotomy prior to ligament reconstruction surgery, especially when the ACL and/or PCL are involved.

### Varus Stress

The varus stress test is performed at both full extension and 30° of knee flexion. A positive test at full extension indicates a PLC injury with damage not only to the FCL and other varus stabilizing structures, but also indicates damage to the cruciate ligaments of the knee.<sup>18</sup> Varus stress at 30° of flexion relaxes the cruciates and other posterolateral structures, allowing isolated assessment of the FCL. This test is typically graded in relation to joint line opening, with Grade I demonstrating 0 to 5 mm of joint line opening, Grade II having 5 to 10 mm, and Grade III demonstrating over 1 cm of joint line opening as compared to the normal contralateral side.<sup>18,19</sup> Evaluation of the opposite, sound knee, illustrates the patient's normal cruciate and collateral laxity. If the contralateral knee is abnormal, evaluation is more difficult in the injured knee.

### Dial Test

The dial test is an important maneuver to assess the integrity of the PLC. The test is performed supine or prone, the thigh is stabilized by the examiner, and the foot is externally rotated. Attention is directed to the degree of external rotation of the foot as measured by the thigh-foot-angle of the injured knee compared to the unaffected knee. The exam is considered abnormal if side-to-side comparison demonstrates more than 10° to 15° of external rotation at either 30° or 90° of flexion.<sup>20</sup> An increase in external rotation at 30° of flexion indicates injury to the PLC, whereas increased external rotation at both 30° and 90° indicates injury to both the PLC and the PCL.<sup>11,20,21</sup>

### Posterior Drawer

The posterior drawer test is used to assess the integrity of the PCL. Performed by applying a posterior force to the proximal tibia with the knee in 90° of flexion, the translation is assessed by noting the difference between the anterior tibial plateau and femoral condyles before and after the applied load. A posterior drawer test with less than 10 mm of translation suggests an isolated posterior cruciate injury. Posterior tibial translation greater than 10 mm during the posterior drawer test, however, raises the suspicion of a combined posterior cruciate and PLC injury.<sup>11,21</sup>

### Posterolateral Drawer

The posterolateral drawer test is a functional exam that helps determine the integrity of the PLC. This is performed by flexing the knee to 90°, and with the foot in external rotation a posterior force is applied to the proximal tibia. The amount of translation is noted by assessing the degree of prominence of the anteromedial tibial plateau as compared to the femoral condyles. If the degree of translation that occurs with the posterolateral drawer is less than that which occurs with the posterior drawer test, the PLC is likely intact, and the posterior cruciate ligament is likely affected. If the degree of translation is equivalent in both posterolateral drawer and posterior drawer tests, the PLC and posterior cruciate both are likely disrupted.<sup>19,22</sup>

### External Rotation Recurvatum

The external rotation (ER) recurvatum test is performed by lifting the leg into full extension by the great toe. The degree of ER recurvatum which occurs is compared to the contralateral knee. A positive test suggests a multiligament knee injury involving both cruciate ligaments and posterolateral corner.<sup>3,22</sup> This exam will usually be negative if a PLC injured knee retains a functioning anterior cruciate.

### Reverse Pivot Shift

The reverse pivot shift test is performed by extending the knee from 45° to 60° of flexion while applying external rotation to the foot and a valgus stress to the knee. Damage to the PLC may result in a palpable shift or reduction of the subluxed knee as the knee is extended. This occurs as the effect of the iliotibial band (ITB) changes from a flexor to extensor force on the knee, which occurs between 25° to 30° of flexion. Although associated with a large number of false positives, this is a functional test that contributes to assessment of the integrity of the PLC.<sup>23,24</sup>

### Neurovascular Exam

A posterolateral corner injury may result in numbness or tingling in the peroneal nerve distribution with or without weakness with ankle dorsiflexion and great toe extension. These are signs suggestive of a common peroneal nerve injury. Identification and documentation of such findings is important as they are said to occur in as many as 15% of PLC injuries.<sup>18</sup> In cases in which the creation of a fibular head tunnel, reattachment of the biceps femoris tendon, or exploration of the PFL, FCL, or popliteus is needed, exploration and protection of the common peroneal nerve is warranted. Knowledge of peroneal nerve function preoperatively is critical in determining if surgical exploration affected nerve function postoperatively.

A dedicated vascular exam is also essential in the setting of a multi-ligament knee injury. The popliteal artery is at risk of injury, being tethered both proximally and distally as it courses through the popliteal fossa. Vascular injury has been documented in 7% to 40% of knee dislocations, with severity ranging from intimal wall injury to complete transection.<sup>25</sup> Clinical examination of distal pulses and perfusion, ankle brachial index (ABI), as well as computed tomography (CT) angiography are useful to assess vascular integrity of the injured limb.<sup>26</sup> An ABI less than 0.9 indicates injury to the vascular tree, and warrants additional vascular imaging, usually in the form of a CT angiogram.<sup>27</sup> If vascular compromise is suspected, an emergent vascular surgery consult is indicated. A patient with normal initial vascular exam following a multi-ligament knee injury should be followed closely with serial clinical examinations due to the limb-threatening consequences of a vascular injury.

### Imaging Examination

Standard imaging includes weight bearing radiographic evaluation and magnetic resonance imaging (MRI). The arcuate sign, which is an avulsion fracture of the fibular head by the PFL, can be identified with standard radiographs and is pathognomonic for a PLC

injury.<sup>28,29</sup> A Segond fracture, which is an avulsion fracture off the anterolateral proximal tibia from the middle third of the lateral capsule, can be identified with standard radiographic evaluation as well. Although nonspecific for a PLC injury, a Segond fracture may indicate a higher energy injury to the knee with concerns for cruciate disruption.<sup>18,30</sup> Varus malalignment can be evaluated in chronic PLC injuries with the aid of hip-to-ankle alignment films. Use of bilateral standing anteroposterior and flexed posteroanterior views of both knees on the same cassette are useful in ruling out any alignment or degenerative issues which may alter the treatment approach. Varus stress radiographs with the knee in 30° of flexion can help to determine the integrity of the stabilizing structures of the lateral knee.

While plain radiographs image bony structures, MRI scans are useful in assessing injuries to the soft tissues of the knee. Coronal oblique images through the fibular head improve visualization of the PLC. It is currently recommended that MRI scans for evaluation of this injury be obtained on a 1.5 T or higher magnet.<sup>19</sup> Given that magnetic resonance can overestimate injuries to the posterior cruciate and PLC, imaging should be interpreted in conjunction with a thorough clinical knee examination.

## **Treatment Options**

Treatment decisions for a PLC injury require an understanding of long term outcome studies, as well as the surgeon's personal experience. Nonoperative measures, such as bracing, strengthening, and activity modification are weighed. If surgery is elected, timing of surgery, tissue repair versus reconstruction, and postoperative rehabilitation are all important issues to address with the patient.

### Nonoperative Treatment

Nonoperative treatment, consisting of bracing, strengthening, and activity modification, may be appropriate for a select group of patients with isolated PLC injuries. A few studies have shown similar results in patients treated operatively or nonoperatively with Grade I and II injuries to the PLC.<sup>31,32</sup> Other studies have shown that Grade III PLC injuries, and combined PLC/cruciate ligament injuries respond unfavorably to conservative measures. Surgical intervention is encouraged in these situations for optimal outcome.<sup>31,33</sup>

Three specific studies have examined operative versus nonoperative management of multiligament knee injuries.<sup>34-36</sup> These studies have shown higher Lysholm and Tegner functional scores as well as a higher percentage of good/excellent results when evaluating International Knee Documentation Committee (IKDC)

scores in patients undergoing operative treatment, with poorer results seen with nonoperative management. Patients were more likely to return to work and sports activities following surgical intervention. However, mean range of motion (ROM) and ultimate flexion loss were not significantly different between the 2 groups.<sup>34,35</sup>

### Surgical Timing

The literature is controversial in regards to the definition of early versus late treatment of PLC injuries. Although concurrent injuries often preclude the ability to perform early surgery, most authors agree that early intervention is aimed at tissue repair, and as such should be carried out no later than 3 weeks post injury. Delay leads to tissue retraction and scar formation, issues which complicate identification and compromise quality of ligamentous structures. If tissue compromise is such that the involved structure is unable to hold suture, or mid-substance rupture of the stabilizing structure has occurred, reconstruction, as opposed to repair, is recommended. Likewise, tissue retraction and shortening will compromise primary repair, and in this setting reconstruction of the involved PLC structure is recommended.<sup>37-39</sup>

The differences between early and delayed surgery in multiligament knee injuries were studied in a recent systematic review by Levy et al.<sup>40</sup> The group that underwent early treatment received surgery on average 2 weeks post injury. The delayed surgery group underwent operative intervention on average 51 weeks post injury. Those who underwent early surgical treatment had higher Lysholm scores, as well as a higher percentage of good/excellent IKDC scores than those treated late. Collected knee outcome surveys available for review showed higher sports activity scores in the "early" group, however, failed to demonstrate a statistical difference in activities of daily living (ADL) scores. Tegner scores, mean postoperative ROM, and flexion loss were similar between those undergoing early versus delayed treatment.<sup>38,3,41-43</sup>

The development of arthrofibrosis in the postoperative patient with a multiligament knee injury is a concern, particularly for those undergoing early intervention. Multiple authors have cautioned against such early treatment due to a higher risk of this complication.<sup>44-49</sup> The senior authors of this paper caution against early bicruciate or multiligament reconstruction in the presence of a preoperative flexion contracture due to the higher risk of arthrofibrosis. To address this issue, preoperative rehabilitation is currently employed in our institution early after injury to decrease joint effusions and to establish ROM prior to reconstruction. Levy, however, failed to show any significant difference in final

mean ROM and flexion loss between the early and late surgically treated groups.<sup>40</sup>

### Reconstruction Techniques

Multiple techniques for addressing PLC reconstruction have been described. In 1996 Larson described passing a semitendinosus graft in a figure-of-8 manner through the proximal fibula and fixing the graft to the lateral femoral condyle between the attachment sites of the FCL and popliteus tendon.<sup>50</sup> Arciero, in 2005, introduced an anatomic reconstruction of the insertion sites of the popliteus tendon and FCL on the femur utilizing a dual-femoral socket technique.<sup>51</sup> LaParade outlines another anatomic technique for reconstruction in which the FCL, PFL, and popliteus tendon are reconstructed with allograft tissue through bone tunnels placed at their respective sites of origin and insertion.<sup>52</sup> Additionally, a 4 stranded hamstring autograft reconstruction has recently been described for reconstruction of the FCL and remaining PLC structures.<sup>53</sup> Although no consensus exists at present regarding recommended technique, the trend is towards anatomic PLC reconstruction. The anatomic reconstruction, as described by LaParade, is preferred by one of the senior authors (RCS).

### **Repair vs Reconstruction**

Several studies have examined outcome differences between reconstruction versus primary repair of the PLC in concert with a multiligament knee reconstruction. Stannard et al showed a failure rate of 37% with isolated PLC repair versus a failure rate of 9% with reconstruction.<sup>13</sup> Levy et al showed similar findings, with a failure rate of 40% for repair and 6% for reconstruction of the PLC in the setting of a multiligament knee injury.<sup>37</sup> There were, however, no significant difference between patients undergoing a reconstruction following failed repair compared to those knees which were initially reconstructed.<sup>37</sup>

Understanding the inter-relationship of cruciates and PLC prior to surgery is important. Reconstruction of a cruciate without addressing the PLC in a multiligament injured knee will eventually fail. Likewise, reconstruction of the PLC without addressing a cruciate injury will eventually fail. Due to concerns for excessive graft load on the reconstruction, most authors recommend reconstruction of all damaged ligaments in a single setting compared to staged surgery.<sup>3,5,28,29,54</sup>

### High Tibial Osteotomy

Limb malalignment, particularly varus, greatly impacts reconstructive surgery in a patient with a chronic PLC knee injury, so attention to limb

alignment is critical.<sup>55</sup> Chronic repetitive loads placed across a ligament reconstruction in the setting of limb malalignment will most likely produce an unsatisfactory result through graft attrition and eventual failure. High tibial osteotomy (HTO) is a procedure that redirects the mechanical weight-bearing axis and alters the loads distributed across the knee. Typically reserved for medial compartment osteoarthritis and painful varus malalignment, HTO can also be used to address coronal and sagittal malalignment associated with chronic ligament insufficiency to provide a more favorable mechanical environment for ligament reconstruction. Following HTO, ligament reconstruction is typically delayed 6 months to allow healing of the osteotomy. The stability afforded by the osteotomy is occasionally sufficient to provide the patient a functional knee without need for subsequent surgery. If instability persists following HTO, reconstruction of all injured ligaments may then be undertaken.<sup>55</sup>

### Treatment Summary

The literature suggests improved functional and clinical outcomes with early compared with delayed surgery, and favors reconstruction of the cruciates as well as the PLC for multiligament injuries of the knee. Management of all torn structures at one setting is considered the most reliable approach to successful surgery. HTO is recommended prior to ligament reconstruction in the unstable knee with malalignment.

### Operative Approach

For surgical exposure, a straight, curvilinear, or hockey-stick incision is carried out over the lateral aspect of the knee.<sup>56-58</sup> The best approach in our experience is a curvilinear incision from the lateral epicondyle proximally, and in line distally between Gerdy's tubercle and the fibular head. Palpation of the knee flexed to 90° helps in identification of the 3 windows used for this approach. "Window I," posterior to the biceps femoris tendon, is where one finds the peroneal nerve. Most authors recommend visualization of the nerve with neurolysis, followed by visualized protection throughout the procedure. "Window II," between the biceps femoris and ITB, is the internervous plane used historically for an inside out lateral meniscus repair. Identification and repair versus reconstruction of the fibular-based components of the PLC, as well as the popliteus tendon off the posterolateral tibia, can be done through "Windows I and II". Anterior, to this is "Window III", where the ITB is split from the lateral epicondyle of the femur to Gerdy's tubercle. This allows identification of the origin of the FCL and popliteus tendon from the lateral femur. LaParade<sup>19</sup> suggests placing a stay suture

in the FCL, if intact, in Window II. Pulling on this suture permits palpation of the FCL origin on the lateral epicondyle of the femur and identification of the starting point for exposure to “Window III”. Utilization of the “Windows” concept provides a safe and effective stepwise approach to the posterolateral knee.

### Rehabilitation

Multiple postoperative rehabilitation protocols have been proposed in the literature for both isolated and combined injuries to the PLC. Although no gold standard has been established, some general recommendations can be extrapolated from previous studies.<sup>13,39,59</sup> Non-weight-bearing on the operative extremity is typically recommended for the first 4-6 weeks postoperatively. During this time immediate ROM exercises can be initiated with avoidance of knee hyperextension. Goals of 90° of knee flexion by 2 weeks, and full ROM by 14 to 16 weeks postop, are set for the patient. Progressive strengthening is encouraged with the exception of active hamstring exercises. These are generally avoided for the first 4 months following surgery. Return to sporting activity is generally withheld until 9 to 12 months from surgery.

### **Conclusion**

Injuries to the PLC can be devastating, and often are associated with multiligament injuries to the knee. Prompt diagnosis and appropriate treatment are essential for restoration of stability. Simultaneous surgical treatment of all injured structures is typically recommended. Anatomic techniques are generally preferred, with attention placed on reconstruction of the FCL, PFL, and popliteus tendon. Postoperative rehabilitation focuses on return of strength and ROM. Further research is needed to provide optimal surgical and rehabilitation protocols for this high energy injury.

### **References**

1. Chen FS, Rokito AS, Pitman MI. Acute and chronic posterolateral rotatory instability of the knee. *J Am Acad Orthop Surg.* 2000;8(2):97-110.
2. DeLee JC, Riley MB, Rockwood CA Jr. Acute posterolateral rotatory instability of the knee. *Am J Sports Med.* 1983;11(4):199-207.
3. LaPrade RF, Resig S, Wentorf FA, Lewis JL. The effects of grade III posterolateral knee complex injuries on anterior cruciate ligament graft force: a biomechanical study. *Am J Sports Med.* 1999;27:469-475.
4. Harner CD, Vogrin TM, Hoher J, MA CB, Woo SL. Biomechanical analysis of a posterior cruciate ligament reconstruction: deficiency of the posterolateral structures as a cause of graft failure. *Am J Sports Med.* 2000;28:32-39.
5. Markolf KL, Wascher DC, Finerman GA. Direct in vitro measurement of forces in the cruciate ligaments. Part II: the effect of section of the posterolateral structures. *J Bone Joint Surg.* 1993;75:387-394.
6. Noyes FR, Barber-Westin SD, Roberts CS. Use of allografts after failed treatment of rupture of the anterior cruciate ligament. *J Bone Joint Surg.* 1994;76(7):1019-31.
7. Baker CL Jr, Norwood LA, Hughston JC. Acute posterolateral rotatory instability of the knee. *J Bone Joint Surg.* 1983;65:614-618.
8. Covey DC. Injuries of the posterolateral corner of the knee. *J Bone Joint Surg.* 2001;83-A(1):106-18.
9. Hughston JC, Jacobson KE. Chronic posterolateral instability of the knee. *J Bone Joint Surg.* 1985; 67(3):351-359.
10. Veltri DM, Deng XH, Torzilli PA, et al. The role of the popliteofibular ligament in stability of the human knee: a biomechanical study. *Am J Sports Med.* 1996;24(1):19-27.
11. Gollehon DL, Torzilli PA, Warren RF. The role of the posterolateral and cruciate ligaments in the stability of the human knee: a biomechanical study. *J Bone Joint Surg.* 1987;69:233-242.
12. Maynard MJ, Deng XH, Wickiewicz TL, Warren RF. The popliteofibular ligament: rediscovery of a key element in posterolateral stability. *Am J Sports Med.* 1996;24:311-316.
13. Stannard JP, Brown SL, Robinson JT, McGwin Jr G, Voldas DA. Reconstruction of the posterolateral corner of the knee. *Arthroscopy.* 2005;21:1051-1059.
14. Sanchez AR II, Sugalski MT, LaPrade RF. Anatomy and biomechanics of the lateral side of the knee. *Sports Med Arthrosc.* 2006;14:2-11.
15. Terry GC, LaPrade RF. The posterolateral aspect of the knee: anatomy and surgical approach. *Am J Sports Med.* 1996;24:732-739.
16. LaPrade RF, Hamilton CD. The fibular collateral ligament-biceps femoris bursa: an anatomic study. *Am J Sports Med.* 1997;25:439-443.
17. Veltri DM, Deng XH, Torzilli PA, Warren RF, Maynard MJ. The role of the cruciate and posterolateral ligaments in stability of the knee: a biomechanical study. *Am J Sports Med.* 1995;23:436-443.
18. LaPrade RF, Terry GC. Injuries to the posterolateral aspect of the knee: association of anatomic injury patterns with clinical instability. *Am J Sports Med.* 1997;25:433-438.

19. LaPrade RF, Wentorf F. Diagnosis and treatment of posterolateral knee injuries. *Clin Orthop Rel Res.* 2002;402:110-121.
20. Bleday RM, Fanelli GC, Giannotti BF, Edson CJ, Barrett TA. Instrumented measurement of the posterolateral corner. *Arthroscopy.* 1998;14:489-494.
21. Grood ES, Stowers SF, Noyes FR. Limits of movement in the human knee: effect of sectioning the posterior cruciate ligament and posterolateral structures. *J Bone Joint Surg.* 1988;70:88-97.
22. Hughston JC, Norwood LA. The posterolateral drawer test and external rotation recurvatum test for posterolateral rotational instability of the knee. *Clin Orthop Relat Res.* 1980;147:82-87.
23. Cooper DE. Tests for posterolateral instability of the knee in normal subjects. *J Bone Joint Surg.* 1991;73:30-36.
24. Jakob RP, Hassler H, Staubli HU. Observations on rotatory instability of the lateral compartment of the knee. Experimental studies of the functional anatomy and pathomechanism of the true and reverse pivot shift sign. *Acta Orthop Scand.* 1981;52(suppl 119):1-32.
25. Henrichs A. A review of knee dislocations. *J Athl Train.* 2004;39:365-369.
26. Stannard JP, Sheils TM, Lopez-Ben RR, et al. Vascular injuries in knee dislocations: the role of physical examination in determining the need for arteriography. *J Bone Joint Surg.* 2004;86-A:910-915.
27. Mills WJ, Barei DP, McNair P. The value of the ankle-brachial index for diagnosing arterial injury after knee dislocation: a prospective study. *J Trauma.* 2004;56:1261-1265.
28. Huang GS, Yu JS, Munshi M, Chan WP, Lee CH, Chen CY, Resnick D. Avulsion fracture of the head of the fibula (the "arcuate" sign): MR imaging findings predictive of injuries to the posterolateral ligaments and posterior cruciate ligament. *Am J Roentgenol.* 2003;180:381-387.
29. Strub WM. The arcuate sign. *Radiology.* 2007;244:620-621.
30. LaPrade RF, Bollom TS, Gilbert TJ, Wentorf F, Chaljub G. The MRI appearance of individual structures of the posterolateral knee: a prospective study of normal and surgically verified grade 3 injuries. *Am J Sports Med.* 2000;28:191-199.
31. Kannus P. Nonoperative treatment of grade II and III sprains of the lateral ligament compartment of the knee. *Am J Sports Med.* 1989;17:83-88.
32. Krukhaug Y, Molster A, Rodt A, Strand T. Lateral ligament injuries of the knee. *Knee Surg Sports Traumatol Arthrosc.* 1998;6:21-25.
33. Wascher DC, Grauer JD, Markoff KL. Biceps tendon tenodesis for posterolateral instability of the knee: an in vitro study. *Am J Sports Med.* 1993;21:400-406.
34. Rios A, Villa A, Fahandezh H, de Jose C, Vaquero J. Results after treatment of traumatic knee dislocations: a report of 26 cases. *J Trauma.* 2003;55:489-494.
35. Dedmond BT, Almekinders LC. Operative versus nonoperative treatment of knee dislocations: a meta-analysis. *Am J Knee Surg.* 2001;14:33-38.
36. Richter M, Bosch U, Wippermann B, Hofmann A, Krettek C. Comparison of surgical repair or reconstruction of the cruciate ligaments versus nonsurgical treatment in patients with traumatic knee dislocations. *Am J Sports Med.* 2002;30:718-727.
37. Levy BA, Dajani KA, Morgan JA, Shah JP, Dahm DL, Stuart MJ. Repair versus reconstruction of the fibular collateral ligament and posterolateral corner in the multiligament-injured knee. *Am J Sports Med.* 2010;38:804-809.
38. Liow RY, McNicholas MJ, Keating JF, Nutton RW. Ligament repair and reconstruction in traumatic dislocation of the knee. *J Bone Joint Surg Br.* 2003;85:845-851.
39. Fanelli GC, Giannotti BF, Edson CJ. Arthroscopically assisted combined posterior cruciate ligament/posterior lateral complex reconstruction. *Arthroscopy.* 1996;12:521-530.
40. Levy BA, Dajani KA, Whelan DB, et al. Decision making in the multiligament-injured knee: an evidence-based systematic review. *Arthroscopy.* 2009;25(4):430-438.
41. Wascher DC, Becker JR, Dexter JG, Blevins FT. Reconstruction of the anterior and posterior cruciate ligaments after knee dislocation: results using fresh-frozen nonirradiated allografts. *Am J Sports Med.* 1999;27:189-196.
42. Tzurbakis M, Diamantopoulos A, Xenakis T, Georgoulis A. Surgical treatment of multiple knee ligament injuries in 44 patients: 2-8 years follow-up results. *Knee Surg Sports Traumatol Arthrosc.* 2006;14:739-749.
43. Harner CD, Waltrip RL, Bennett CH, Francis KA, Cole B, Irrgang JJ. Surgical management of knee dislocations. *J Bone Joint Surg.* 2004;86:262-273.
44. Harner CD, Irrgang JJ, Paul J, Dearwater S, Fu FH. Loss of motion after anterior cruciate ligament reconstruction. *Am J Sports Med.* 1992;20:499-506.

45. Jari S, Shelbourne KD. Nonoperative or delayed surgical treatment of combined cruciate ligaments and medial side knee injuries. *Sports Med Arthrosc.* 2001;9:185-192.
46. Shelbourne K, Beale JR. Treatment of combined anterior cruciate ligament and medial collateral ligament injuries. *Am J Knee Surg.* 1988;1:56-58.
47. Shelbourne K, Wilckens JH, Mollabashy A, DeCarlo M. Arthrofibrosis in acute anterior cruciate ligament reconstruction: the effect of timing of reconstruction and rehabilitation. *Am J Sports Med.* 1991;19:332-336.
48. Shelbourne KD, Nitz P. Accelerated rehabilitation after anterior cruciate ligament reconstruction. *Am J Sports Med.* 1990;18:292-299.
49. Mohtadi NG, Webster-Bogaert S, Fowler PJ. Limitation of motion following anterior cruciate ligament reconstruction: a case-control study. *Am J Sports Med.* 1991;19:620-625.
50. Larson RV, Sidles JA, Beals TC. Isometry of the lateral collateral and popliteofibular ligaments and a technique for reconstruction University of Washington Orthopedic Research Report.1996;42-44.
51. Arciero RA. Anatomic posterolateral corner knee reconstruction. *Arthroscopy.* 2005;21(9):147.e1-1147.e5.
52. LaPrade RF, Tso A, Wentorf FA. Force measurements on the fibular collateral ligament, popliteofibular ligament, and popliteus tendon to applied loads. *Am J Sports Med.* 2004;32(7):1695-1701.
53. Jakobsen BW, Lund B, Christiansen SE, Lind MC. Anatomic reconstruction of the posterolateral corner of the knee: a case series with isolated reconstructions in 27 patients. *Arthroscopy.* 2010;26(7):918-925.
54. Harner CD, Vogrin TM, Höher J, Ma CB, Woo SL. Biomechanical analysis of a posterior cruciate ligament reconstruction: deficiency of the posterolateral structures as a cause of graft failure. *Am J Sports Med.* 2000;28(1):32-39.
55. Savarese E, Bisicchia S, Romero R, Amendola A. Role of high tibial osteotomy in chronic injuries of posterior cruciate ligament and posterolateral corner. *J Orthop Traumatol.* 2011;12(1):1-17.
56. Noyes FR, Barber-Westin SD. Surgical restoration to treat chronic deficiency of the posterolateral complex and cruciate ligaments of the knee joint. *Am J Sports Med.* 1996;24:415-426.
57. Veltri DM, Warren RF. Operative treatment of posterolateral instability of the knee. *Clin Sports Med.* 1994;13:615-627.
58. Noyes FR, Barber-Westin SD. Surgical reconstruction of severe chronic posterolateral complex injuries of the knee using allograft tissue. *Am J Sports Med.* 1995;23:2-12.
59. LaPrade RF, Johansen S, Agel J, Risberg MA, Moksnes H, Engebretsen L. Outcomes of an anatomic posterolateral knee reconstruction. *J Bone Joint Surg.* 2010;92:16-22.



# PCL Reconstruction: A Comparison of Techniques

Dustin L. Richter MD<sup>1</sup>, Daniel C. Wascher MD<sup>1</sup>, Robert C. Schenck, Jr. MD<sup>1</sup>

1. UNM Department of Orthopaedics & Rehabilitation

The posterior cruciate ligament (PCL) has been referred to as the cornerstone of ligamentous stability of the knee and in multiligamentous injuries has been our focus. The PCL is a primary stabilizer of the knee joint, the major restraint to posterior translation of the tibia on the femur, and the first ligament addressed in management of bicruciate knee injuries. Historically, injury to the PCL has been an uncommon and often unrecognized ligamentous injury. Complete ruptures of the PCL account for approximately 3% of all knee ligament injuries in the general population in one study.<sup>1</sup> As a result of the low frequency of injury and the significant rate of primary healing, the indications for surgery and surgical technique for reconstructing a torn PCL have taken years to define. Nonetheless, most authors will agree that isolated injuries to the PCL can oftentimes be treated nonoperatively with good results. However, reconstruction is indicated in the patient with a chronically symptomatic isolated grade III PCL injury or in the patient with a multiligamentous knee injury.<sup>2</sup> The most common scenario for surgery involves a complete PCL injury associated with an injury to the posteromedial or posterolateral corners, and in our extensive experience - in the bicruciate injured knee.<sup>3</sup>

Most PCL reconstruction techniques use both tibial and femoral bone tunnels for graft placement with arthroscopic assistance (transtibial technique). In this approach, intraoperative radiographs or fluoroscopy is used during drilling of the tibial tunnel to avoid plunging and potentially damaging limb-threatening popliteal neurovascular structures. Tibial tunnel reaming is then followed by preparation of the femoral tunnel. The graft is then passed through the tibial tunnel, into the joint, and retrieved out of the femoral tunnel. The turn around the tibial tunnel has been termed the “killer curve.” There has been some concern that as the graft exits out the posterior tibia and turns superiorly and anteriorly towards its position on the medial femoral condyle that there may be excess stress on the graft resulting in early failure due to the tibial tunnel-graft interface edge. These basic science controversies and studies have been minimized by long-term clinical studies. Fanelli et al. has published multiple studies where the outcomes for combined anterior cruciate ligament (ACL)/PCL and PCL/posterolateral complex reconstructions using the transtibial single-bundle technique provide long-term

functional stability with successful return to pre-injury level of activity observed in all patients. Moreover, the longevity of reconstruction stability with this technique was demonstrated at 3 to 8 year follow-up using stress radiography.<sup>4</sup> Regardless of the long-term effects of the “killer curve,” the acute turn from the posterior tibia to the femoral notch does often complicate graft passage during surgical reconstruction, but in many authors’ experiences does not play out clinically.

An alternative technique for PCL reconstruction that has been described involves placement of the graft’s bone block anatomically on the back of the tibia (inlay technique).<sup>5</sup> The tibial inlay technique avoids passing the graft around the “killer curve” found in the transtibial technique, thus preventing tibial edge stress on the graft as described earlier. The most often described technique for inlay involves initially starting with the patient in the supine position. While in the supine position, standard arthroscopy with graft harvest is performed and the femoral tunnel is prepared. The patient must then be repositioned in the prone position. The posterior tibia is then accessed using Burks’ posteromedial approach. The landmarks for this approach are the medial border of the medial head of the gastrocnemius, the posterolateral border of the semimembranosus, the popliteal crease, and the midline of the distal thigh. The medial head of the gastrocnemius is retracted laterally to protect the neurovascular structures and the interval is between the medial head of the gastrocnemius and semimembranosus. This allows visualization of the posterior capsule and ultimately direct visualization of the PCL origin on the posterior tibia.

The most common tibial inlay technique described above can be cumbersome to many surgeons as it involves flipping the patient from supine to prone and back again, adding additional time to the case with the entire leg needing to be repped and draped each time. Furthermore, any graft adjustments would require repositioning, adding to an already complicated and lengthy procedure. One of the senior authors (RCS) prefers the use of a novel operative technique for the tibial inlay method of PCL reconstruction using a modification of Lobenhoffer’s posteromedial approach, allowing the patient to remain in the supine position throughout the procedure.<sup>6</sup> This modification uses an interval between the posterior aspect of the medial

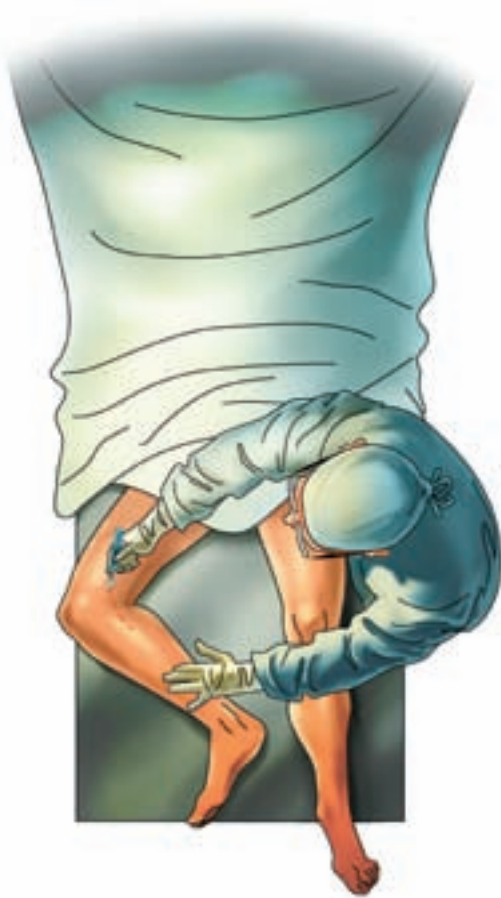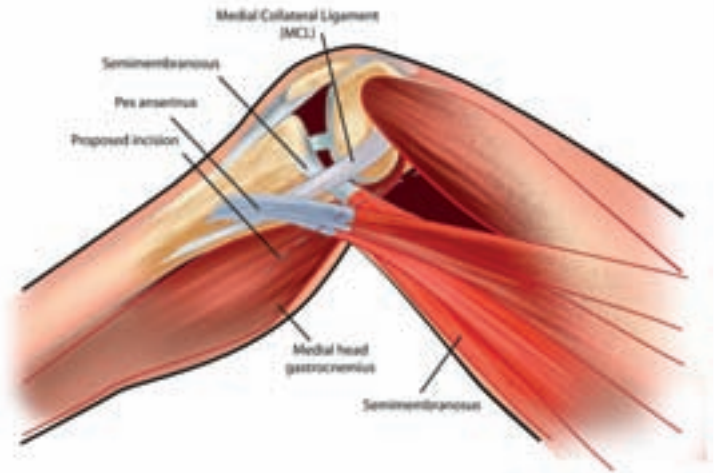
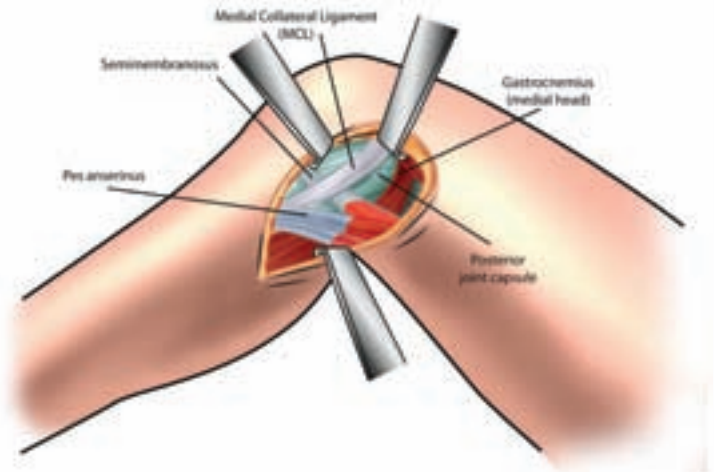
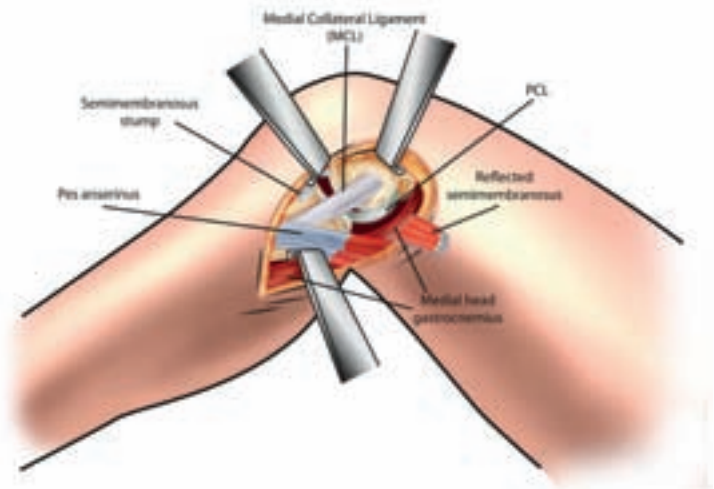
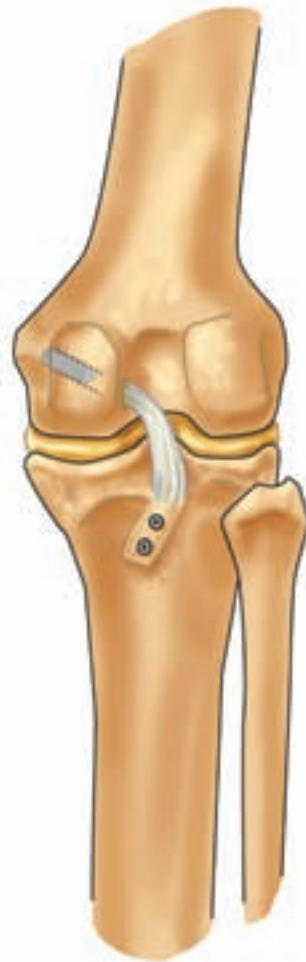**A****B****C****D**

Figure 1: Posteromedial approach to the tibial attachment of the PCL. **A.** The patient is placed in the supine position with the knee flexed 30° to 60° and the leg and hip externally rotated. **B.** A skin incision is placed at the back edge of the medial tibia, coursing proximally to the posterior edge of the medial epicondyle. Superficial dissection is made through the sartorius fascia along the line of the skin incision. **C.** Deep dissection is made between the posterior knee joint capsule and the gastrocnemius. Partial detachment of the semimembranosus is required to access this interval. **D.** Exposure of the proximal tibia and capsulotomy allow identification of the PCL.



Right Knee PCL inlay technique

Figure 2: A posterior cruciate ligament reconstruction utilizing a tibial inlay technique.

collateral ligament (MCL) and posterior tibia and the pes anserinus (gracilis and semitendinosus). This approach thus stays anterior to the gastrocnemius but requires taking down distal portions of the semimembranosus (with subsequent repair). By flexing the knee to 90° while externally rotating the hip (unilateral frog leg position), the surgeon is able to clearly and safely visualize the back of the tibia while standing on the opposite side of the table (Figure 1).<sup>7</sup> Additional technical modifications include rotating the tibial inlay trough/graft medially towards the medial tibial border (Figure 2). This allows for ease of placement of the 4.0mm cannulated screws such that they are positioned slightly lateral to midline, thus avoiding the ACL tunnel in the scenario of a bicruciate reconstruction.

The choice of surgical technique for PCL reconstruction is largely a matter of surgeon preference. Some techniques may be more cumbersome than others – requiring the patient to be flipped from supine to prone

and back again, or can potentially lead to mechanical degradation of the graft as it passes around the “killer curve” in the transtibial technique. The modification of the posteromedial approach where prone positioning is avoided is particularly useful for multiligamentous knee injuries involving the medial structures of the knee (KDIIM). In these cases, incisions are minimized, compared to use of inlay with a KDIIL or KDIV, allowing safe exposure for combined medial and posterior ligament reconstruction. In addition, the modified technique gives the orthopaedic surgeon another option for a revision case in which the failed index PCL reconstruction utilized a transtibial approach (Figure 3). Although more studies are needed, we hypothesize that there will be no difference in how one reconstructs the PCL, but will find improvement in outcomes depending on how well the PCL origin on the tibia is reestablished, including appropriate management of the corners.

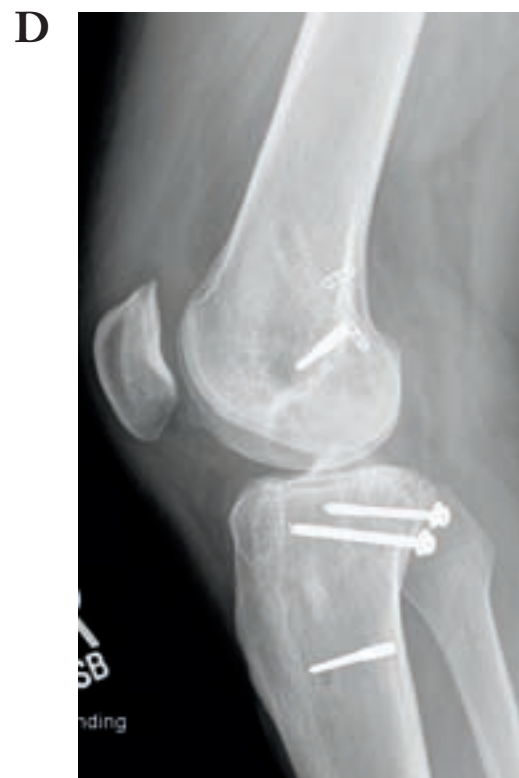
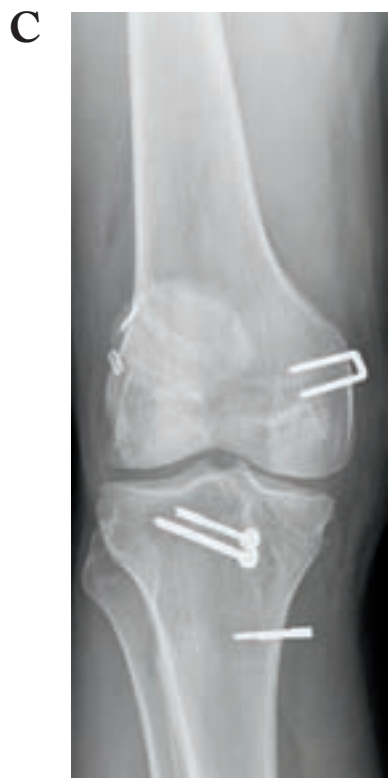
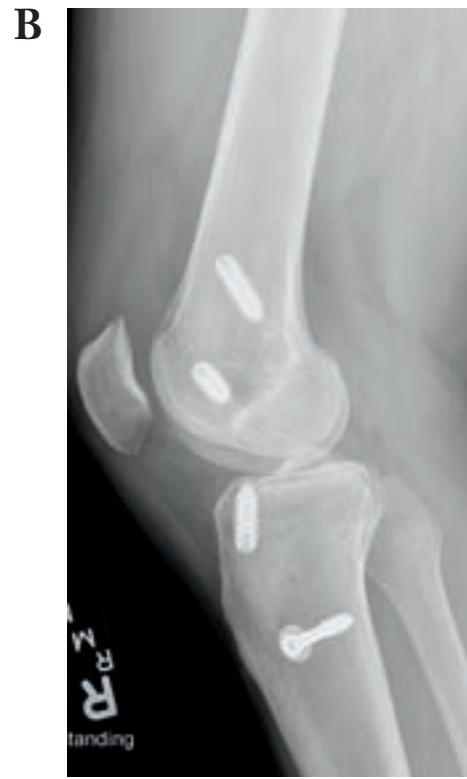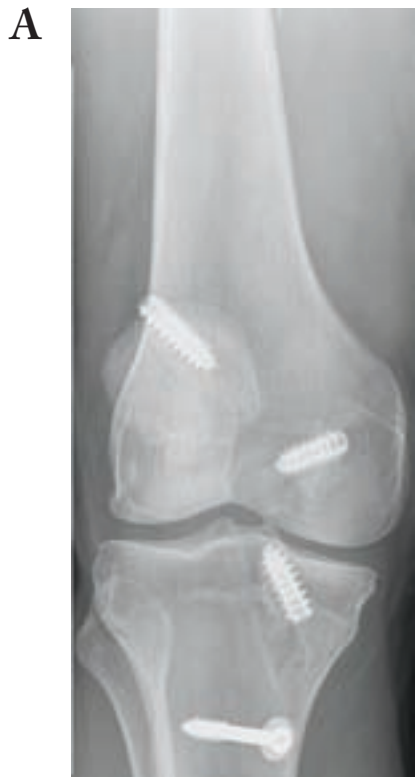Figure 3: **A, B.** KD3M injury treated with transitional PCL reconstruction. **C, D.** Conversion to inlay PCL reconstruction with double bundle ACL reconstruction after failure of both primary ACL and PCL grafts.

## References

1. Wind WM, Bergfeld JA, Parker RD. Evaluation and treatment of posterior cruciate ligament injuries: revisited. *Am J Sports Med.* 2004;32:1765-1775.
2. Noyes FR, Barber-Westin SD. Posterior cruciate ligament: diagnosis, operative techniques, and clinical outcomes. In: Noyes FR, ed. *Noyes' Knee Disorders: Surgery, Rehabilitation, Clinical Outcomes.* Philadelphia, PA: Elsevier Inc.; 2010: 503-506.
3. Wascher DC, Becker JR, Dexter JG, et al. Reconstruction of the anterior and posterior cruciate ligaments after knee dislocation: results using fresh-frozen nonirradiated allografts. *Am J Sports Med.* 1999;27(2):189-196.
4. Fanelli G, Orcutt D, Harris J, et al. Posterior cruciate ligament reconstruction. *Orthopaedic Knowledge Online Journal.* 2007; Vol 5.
5. Graham SC, Parker RD, McCallister DR, et al. Tibial inlay technique for posterior cruciate ligament reconstruction. *Techniques in Orthopaedics.* 2001;16(2):136-147.
6. Lobenhoffer P, Gerich T, Bertram T, et al. Particular posteromedial and posterolateral approaches for the treatment of tibial head fractures. *Unfallchirurg.* 1997;100(12):957-967.
7. Stannard JP, Schenck RC, Fanelli GC. Knee dislocations and fracture-dislocations. In: Bucholz RW, Heckman JD, Court-Brown CM, Tornetta P III, eds. *Rockwood and Green's Fractures in Adults.* 7th ed. Philadelphia, PA: Lippincott Williams & Wilkins; 2010: 1840-1847.

# Damage Control Orthopaedics 2013

Urvij Modhia MD<sup>1</sup>

1. UNM Department of Orthopaedics & Rehabilitation

## Introduction

Damage control orthopaedics is an approach to musculoskeletal injury treatment and timing that recognizes the potential of surgical intervention to interfere with recovery, as well as to enhance recovery. Damage control attempts to optimize trauma outcome by matching the patient's tolerance to surgical intervention with the extent and aggressiveness of the approach. The timing and treatment of orthopaedically injured patients with long bone fractures generally consists of early total care which means operative fixation within 24 hours. It improves their outcome and decreases the complication rate. However, this approach is not always the best and actually might be harmful for patients. After injury, patients develop a hyper-inflammatory reaction which is followed by hypo-inflammatory phase. Any additional surgical insult can create additional inflammatory response. This additional insult in single injured patient generally does not lead to any additional consequences. However, in the case of a multiply injured patient, extensive surgical insults can lead to severe inflammatory changes called systemic inflammatory reaction syndrome, which ultimately leads to multiple organ failure and increased risk of death. Damage control orthopaedics emphasizes stabilization and control of injuries, along with preventing the progression of injuries.<sup>1</sup>

## History

Before 1970, treatment for multiply injured patients consisted of observation with immobilization of fractures with splints, traction, etc., and if patients survived, then definitive fixation.<sup>1</sup> In the 1980s, Bone et al.<sup>2</sup> and Border<sup>3</sup> demonstrated that immediate or early fixation of fractures in multiply injured patients led to a decrease in pulmonary complications and improvement of skeletal outcomes. This brought the era of immediate total care (definitive long bone fixation within 4-6 hours) and later on, early total care (definitive fixation within 24 hours).<sup>2</sup> The term "damage control" came into use at first by general surgeons when they did immediate, abbreviated procedures, primarily in the abdomen, to control and prevent further progression of damage and then at a later date, definitive repair of the injuries and closure of the abdomen.<sup>4</sup> In the late 1990s, studies showed that in severely injured patients, an injury severity score greater than 25 was associated with higher inflammatory burden, acute lung injury, and increased mortality rate.<sup>5</sup> It was recognized that there are some patients who are so severely injured that they

cannot tolerate long operations, blood loss, and especially medullary canal manipulation, without a significant life threatening deterioration of pulmonary function and overall homeostasis. Temporary external fixation, which is the hallmark of damage control orthopaedics, was not associated with inflammatory changes. The studies also showed that it was easy to convert external fixation to definitive fixation later on when the patient's overall condition had stabilized to the point where definitive fixation procedures could be tolerated.<sup>5,6</sup>

## Physiology

Systemic inflammatory response, also called "first hit," after polytrauma is followed by counter inflammatory response (host defense response), which is a hypo-inflammatory reaction to counter severe inflammation.<sup>7</sup> Any further insult, such as extensive surgical insult, can lead to "second hit," ending with multiple organ failure and death.<sup>7</sup> Various parameters, such as body temperature, heart rate, white blood cell count, respiratory rate, serum lactate level at admission and lactate clearance, can help to identify whether a patient is in severe inflammatory reaction or not.<sup>7</sup> Damage control orthopaedics concentrates on prevention of this severe inflammatory reaction, or second hit, while simultaneously stabilizing fractures to prevent further damage.

## Patient selection

Inter-service communication is an integral part of damage control orthopaedics. The trauma team in the United States consists of an anesthesiologist, an intensivist, a trauma surgeon and an orthopaedic surgeon who, with the trauma surgeon, provides major input. For long bone fractures, the trauma surgery service, with the help of the orthopaedic service, makes the decision as to whether the patient is fit to undergo definitive orthopaedic intervention or requires damage control with staged skeletal stabilization.<sup>1</sup>

Patients with multiple injuries can be divided into stable, unstable, or borderline patients.<sup>8,9</sup> Early total care is suitable for stable patients, while unstable patients benefit from damage control orthopaedics.<sup>8,9</sup> Patients identified as borderline by the criteria given by Pape can undergo immediate interventions, such as hemorrhage control and decompression of body cavities. If they become stable after these interventions then early total care becomes beneficial for them; otherwise, damage control should be applied.<sup>8</sup>

## Strategies and methods for damage control orthopaedics

External fixation is a mainstay for damage control orthopaedics, as it rapidly stabilizes the fracture with minimal blood loss, minimal additional soft tissue damage, and minimal disruption of the medullary contents, leading to minimal pulmonary and systemic inflammatory reaction. It restores alignment and stability to the fractured skeleton, which allows soft tissue to rest and prevents soft tissue shortening, beneficial both immediately and subsequently at the time of definitive surgical repair. Generally, fixator pins are placed away from the zone of injury with a simple frame, providing temporary fixation which can be converted easily to definitive fixation. Procedures that reduce physiologic burdens on the trauma patient without causing increasing catabolic demands, such as debriding open wounds and treating compartment syndrome, if present, with fasciotomy, are priorities in damage control. Other methods used in damage control orthopaedics are long bone fixation with unreamed or unlocked intramedullary nails and retrograde femoral intramedullary nail fixation to achieve long bone stabilization while reducing the extensive physiological stress of standard nailing and the application of splints to more minor fractures, allowing soft tissue to rest (Tables 1 and 2).

Inflammatory markers, elevated after injury, generally stabilize in 3 to 5 days, after which definitive surgical fixation could be considered with significant decreased risk of second hit.<sup>10</sup> Temporarily placed external fixators are converted to definitive fixation within 5 to 14 days. The fracture fragments can still be manipulated 14 to 21 days after injury so as to provide optimal fracture reduction.<sup>11</sup>

The concepts of damage control are applicable locally as well as generally. The previous comments have dealt with the patient's general condition and risk of death and treatments which impact the overall patient. Focal damage control is the recognition that the immediate condition of the local tissue may not tolerate immediate definitive operative intervention. Focal damage control suggests a staged treatment approach with immediate treatment that minimizes additional local injury and more aggressive, more definitive treatment several weeks later when the local soft tissue condition allows. One great example is the treatment of distal tibial plafond fractures where very high rates of soft tissue slough and infection often occurs after immediate plating. These commonly require free flap coverage or other extensive soft tissue reconstructions and even then a relative high rate of amputation is reported. The complications of operative treatment (amputations) are far worse than the natural history of the injury (ankle arthritis).<sup>12</sup>

Focal damage control principles have gained acceptance with staged treatment. On the day of injury a spanning external fixator is placed which restores length and stability to the limb without causing much additional soft tissue injury. The local soft tissue is given time to stabilize and definitive reduction and fixation is performed when swelling has resolved and the soft tissue envelope is more tolerant of surgical dissection. The same principles have been applied to calcaneus fractures, which are typically treated initially with a closed reduction and splint and a delayed open reduction internal fixation. Severe proximal tibia fractures associated with compartment syndrome, arterial injury, extensive comminution, diaphyseal extension, open wounds, or soft tissue injury are typically treated with a spanning

Table 1

Basic strategies for damage control orthopaedics

Interventions
Immediate and rapid stabilization of long bone fractures, typically with external fixation
Release of tight soft tissue compartments (compartment syndrome)
Reductions of dislocations
Surgical debridement of open wounds
Amputation, in cases of unsalvageable extremities

Table 2

Injuries in which damage control orthopaedic principles are beneficial

Injury	Comments
Bilateral femoral fractures	Early total care is associated with a high rate of adult respiratory distress syndrome (ARDS). <sup>14</sup>
Femur fracture in the presence of chest injury	Early total care is associated with a high rate of ARDS. <sup>14</sup>
Polytrauma with chest injury	Early total care is associated with a high rate of ARDS. <sup>14</sup>
Polytrauma with head injury	Early total care leads to secondary brain injury by decreasing mean arterial pressure and increasing intracranial pressure. <sup>15,16</sup>
Pelvic ring disruptions associated with potentially lethal hemorrhage	Damage control orthopaedic principles include resuscitation, application of pelvic binder or pelvic external fixation, along with angiographic embolization. <sup>10</sup>
Mangled extremities	Mangled extremity severity score is useful. In patients with score above 7 amputation should be considered. <sup>13</sup>

external fixation and delayed plating when the soft tissue envelope has recovered. In patients with fractures that are associated with a high rate of soft tissue complication, application of damage control orthopaedic principles allows the soft tissues to rest while maintaining soft tissue and bony length.<sup>12,13</sup>

### Summary

Damage control orthopaedics is an accepted approach to musculoskeletal injury treatment and timing that recognizes the potential of surgical intervention to interfere with recovery as well as to enhance recovery. There are two types of damage control: general and local. General damage control orthopaedics avoids the early second hit phenomena and prevents worsening of systemic inflammation which can contribute to increased mortality rates in severely traumatized patients. It simultaneously stabilizes the fractures sufficiently to prevent further tissue damage without pushing patients beyond physiological tolerance limits. Focal damage control applies the same principle to local injury, typically using immediate temporary external fixation with delayed staged plating when the soft tissue envelope will tolerate an extensive surgical dissection.

### References

1. Roberts CS, Pape HC, Jones AL, Malkani AL, Rodriguez JL, Giannoudis PV. Damage control orthopaedics: evolving concepts in the treatment of patients who have sustained orthopaedic trauma. *Instr Course Lect.* 2005;54:447-462.
2. Bone LB, Johnson KD, Weigelt J, Scheinberg R. Early versus delayed stabilization of femoral fractures: a prospective randomized study. *J Bone Joint Surg Am.* 1989;71:336-340.
3. Border JR. Blunt Multiple Trauma: Comprehensive Pathophysiology and Care. New York: Marcel Dekker;1990.
4. Scalea TM, Boswell SA, Scott JD, Mitchell KA, Kramer ME, Pollak AN. External fixation as a bridge to intramedullary nailing for patients with multiple injuries and with femur fractures: damage control orthopedics. *J Trauma.* 2000;48:613-623.
5. Nowotarski PJ, Turen CH. Conversion of external fixation to intramedullary nailing for fractures of the shaft of the femur in multiply injured patients. *J Bone Joint Surg Am.* 2000;82:781-788.
6. Pape HC, Grimme K, van Griensven M, et al. Impact of intramedullary instrumentation versus damage control for femoral fractures on immunoinflammatory parameters: prospective randomized analysis by the EPOFF Study Group. *J Trauma.* 2003;55:7-13.
7. Pape HC, van Griensven M, Rice J, et al. Major secondary surgery in blunt trauma patients and perioperative cytokine liberation: determination of the clinical relevance of biochemical markers. *J Trauma.* 2001;50:989-1000.



8. Pape HC, Rixen D, Morley J, et al. Impact of the method of initial stabilization for femoral shaft fractures in patients with multiple injuries at risk for complications (borderline patients). *Ann Surg.* 2007;246:491-499.
9. Pape HC, Hildebrand F, Pertschy S, et al. Changes in the management of femoral shaft fractures in polytrauma patients: from early total care to damage control orthopedic surgery. *J Trauma.* 2002;53:452-462.
10. Pape H, Stalp M, van Griensven M, Weinberg A, Dahlweit M, Tscherne H. [Optimal timing for secondary surgery in polytrauma patients: an evaluation of 4,314 serious-injury cases]. *Chirurg.* 1999;70:12 87-93. German.
11. Pape HC, Giannoudis P, Krettek C. The timing of fracture treatment in polytrauma patients: relevance of damage control orthopedic surgery. *Am J Surg.* 2002;183:622-629.
12. Smith DG, Castillo RC, MacKenzie EJ, Bosse MJ; for the LEAP Study Group. Functional outcomes of patients who have late amputation after trauma is significantly worse than for those who have early amputation. Read at the Annual Meeting of the Orthopaedic Trauma Association; 2003 Oct 9-11; Salt Lake City, UT.
13. Helfet DL, Howey T, Sanders R, Johansen K. Limb salvage versus amputation: preliminary results of the Mangled Extremity Severity Score. *Clin Orthop.* 1990;256:80-86.
14. Copeland CE, Mitchell KA, Brumback RJ, Gens DR, Burgess AR. Mortality in patients with bilateral femoral fractures. *J Orthop Trauma.* 1998;12(5):315-319.
15. Jaicks RR, Cohn SM, Moller BA. Early fracture fixation may be deleterious after head injury. *Trauma.* 1997;42:1-6.
16. Martens F, Ectors P. Priorities in the management of polytraumatised patients with head injury: partially resolved problems. *Acta Neurochir (Wien).* 1988;94:70-73.

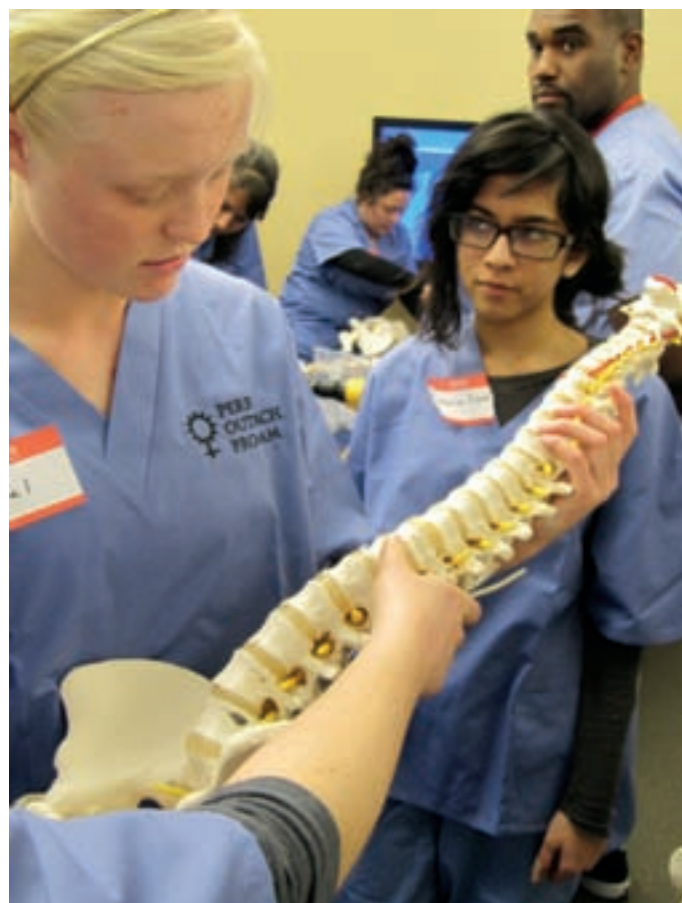## The Perry Initiative Christina Salas MS<sup>1</sup>, Deana Mercer MD<sup>2</sup>

1. UNM Center for Biomedical Engineering 2. UNM Department of Orthopaedics & Rehabilitation

Jacqueline Perry (May 31, 1918-March 11, 2013), known among her peers as the Grande Dame of Orthopaedics, was one of the first 10 board certified orthopaedic female surgeons. She earned wide attention for her work in analyzing human gait. Her 1992 text, *Gait Analysis: Normal and Pathological Function*, became a standard text for orthopaedists, physical therapists, and rehabilitation professionals. She is most known for treating polio victims in the 1950s by developing surgical techniques for spinal fusion and development of the “halo” device for treatment of cervical spine fracture. She died in her home in Downey, California, at age 94.

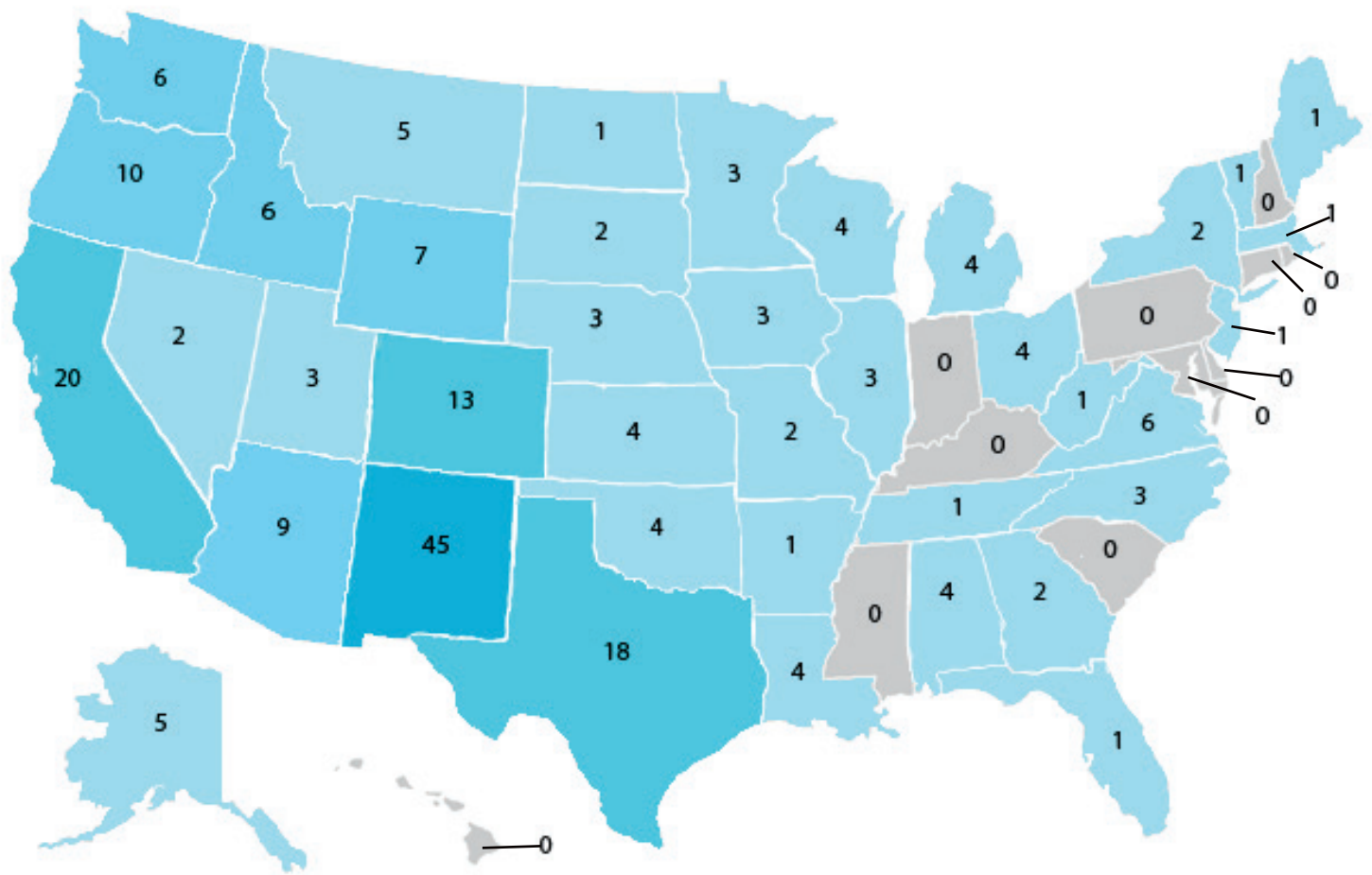
The Perry Initiative was established in her honor. It is a non-profit program supported by engineers and orthopaedic surgeons, aimed towards introducing young women to the fields of orthopaedics and engineering, with an emphasis on introduction to research in these fields. It is a 1 day program where the students participate in a biomechanical skills laboratory. The skills laboratory is comprised of 6 stations supervised by volunteer orthopaedic surgeons and engineers. This year, the University of New Mexico (UNM) had the opportunity to participate in the initiative. Thirty-nine young high school women, ages 15-18, traveled to the UNM campus from surrounding areas, including Arizona, Texas, and New Mexico. The program was held in the Leonard M. Napolitano, Ph.D. Anatomical Education Center.

The young women eagerly participated in Sawbones™ simulations of femur fracture fixation, distal radius fracture plating, reconstruction of knee ligaments, spine fixation, including pedicle screw placement, and suturing lacerations in pig feet. They also observed a live dissection of a human hand. Volunteers at the event included Kim Fields, Alicia Garcia, Karla Parra-Marrufo, Dr. Ann Mercer, and Drs. Elizabeth Mikola, Selina Silva, Deana Mercer, and Heather Menzer from the Department of Orthopaedics; Ashley Gilbert and Dukens LaBaze from the School of Medicine; and Professor Elizabeth Dirk and Christina Salas from the Center for Biomedical Engineering. Rachel Baeza, Julie Bowers, Jude McMullan, and Ryan Wood from the Department of Orthopaedics and Summer Little from the UNM Women’s Resource Center helped plan the event, which was underwritten by Acumed and the Carrie Tingley Hospital Education and Research



Fund. The all-day Saturday program ended with a panel question/answer session where the young women and their parents asked very insightful questions about what the lives of engineers and orthopaedic surgeons are like, the cost of education and available financial resources, quality of life issues, and the changing healthcare environment.

Despite the use of electric drills, saws, needles, and scalpels for the first time by many of the students, there were no casualties and the young women left with a new appreciation for the opportunities available to them in the fields of orthopaedics, engineering, and research. The feedback from the students and their families and teachers was overwhelmingly positive. Many of them followed up with letters of thanks and requests for mentoring. The orthopaedics department plans to support this program yearly to continue to raise awareness and improve the representation of women in orthopaedics and engineering.



## University of New Mexico Department of Orthopaedic Surgery Alumni

### Hand Surgery Fellows

Adamany, Damon (AZ) 2007  
 Affi, Ahmed (OH) 2008  
 Aldridge, Jeffrey (OR) 1987  
 Blair, William (TX) 1979  
 Bolger, John (WI) 1980  
 Buchman, Mark (NE) 1989  
 Capen, David (TX) 1975  
 Castaneda, Edwin (IA) 1988  
 Dalton, Anthony 1980  
 de Carvalho, Alex (KS) 2005  
 Doherty, William (MA) 1993  
 Duncan, Gregory (CA) 1992  
 Eiser, Thomas (OK) 1979  
 Espirtu, Edgardo (TX) 1985  
 Fahmy, Hani (EG) 1993  
 Ford, Ronald (MI) 1997  
 Freeh, Eric (NM) 1983  
 Fraser, Bonnie (NV) 2007  
 Garst, Jeffrey (IL) 1994  
 Gerstner, David (MI) 1988  
 Gobeille, Richard (NM) 1985  
 Gordon, Douglas (OH) 1987  
 Green, Matthew (UT) 2012  
 Gross, Dominic (ID) 1997  
 Hamilton, Conrad (NM) 2011

Hofammann, Karl (AL) 1983  
 Howey, Thomas (SD) 1992  
 Hudson, Patrick (NM) 1978  
 Hurley, Davis (CO) 2003  
 Hussain, Tariq (NY) 2002  
 Inhofe, Perry (OK) 1994  
 Irey, William (IA) 1982  
 Johnson, Glenn (MN) 1998  
 Johnson, Jann (CA) 1984  
 Johnston, David 1995  
 Joseph, Terrell (CO) 2006  
 Kelly, Jon (CA) 1993  
 Koester, Alan (WV) 1995  
 Lakshman, Shankar (CA) 2004  
 Langford, Scott (MO) 2000  
 Larsen, Kenna (NM) 2009  
 Lehman, Thomas (OK) 2002  
 Luce, Paul (MI) 1999  
 Mercer, Deana (NM) 2010  
 Mikola, Elizabeth (NM) 2001  
 Miller, Gary (MO) 1986  
 Miller, Steven (AZ) 2009  
 Morrow, Robert (LA) 1980  
 Mourikas, Anastasos (GR) 2004  
 Murdock, Louis (ID) 1996  
 Mustapha, Abdul (OH) 2000  
 Narsete, Thomas (TX) 1981

Niedermeier, William (WI) 1979  
 O'Mahony, Gavin (OK) 2012  
 Oschwald, Don (NC) 1985  
 Pennino, Ralph (NY) 1986  
 Pokorny, Jeffrey (NC) 2002  
 Prabhakar, Ram (CA) 1980  
 Pribyl, Charles (NM) 1989  
 Richards, Allison (NM) 2008  
 Rosquete, Hector (ME) 1990  
 Saide, Robert 1983  
 Saleh, Ehab (KY) 2005  
 Serota, Joseph 1983  
 Shirali, Swati (VA) 1999  
 Sleeper, Richard 1988  
 Swanson, Scott (CO) 2010  
 Taylor, Steven (WI) 2006  
 Tegtmeier, Ronald (KS) 1976  
 Teter, Kenneth (KS) 1993  
 Torkelson, Erik\* 1984  
 Voit, Gregory (NJ) 1996  
 Walsh, Catherine (CA) 2011  
 Weinberg, Howard 1978  
 Yi, InSok (CO) 1998  
 Yoo, Robert (MA) 1977  
 Young, Steven (IL) 2001  
 Yu, Elmer 1979

### Sports Medicine Fellows

Abraham, Roy (IA) 2006  
 Jasko, John (WV) 2010  
 Johnson, Adam (NM) 2012  
 Kiburz, A. John (NM) 2009  
 Mann, John (AL) 2010  
 Natividad, Toribio (TX) 2011  
 Passerelli, Ralph (PA) 2007  
 Sparks, Brad (AK) 2008  
 Veazey, Brad (TX) 2007  
 Wyatt, Jonathan (AR) 2012

### Trauma Fellows

Bozorgnia, Shahram (GA) 2008  
 de Carvalho, Max (MN) 2011  
 Figueiredo, Fabio (ME) 2007  
 Hamedan, Shehada (NY) 2006  
 Matt, Victoria (NM) 2005  
 Molk, Gary (WY) 2010  
 Rise, Leroy (NM) 2012  
 Xing, Zhiqing (AL) 2009

# University of New Mexico Department of Orthopaedic Surgery Alumni

## Residents

Aboka, Alexander (VA)	2011	Helpenstell, Thomas (WA)	1991	Renwick, Stephen (OR)	1994
Achterman, Christopher (OR)	1977	Hensal, Fredrick (AL)	1982	Reyna, Jose (NM)	1983
Adams, Brook (TN)	2011	Hobby, Bryon (CA)	2012	Richards, Allison (NM)	2002
Adler, Zachary (NM)	2007	Huberty, David (OR)	2005	Robinson, Brian (NM)	1998
Agarwala, Amit (CO)	2002	Ilic, Sergio (CA)	1977	Rork, Peter (WY)	1984
Alyea, Alan (WA)	1986	Izadi, Kayvon (NE)	2008	Roth, Kenneth (CA)	1967
Balduini, Frederick (NJ)	1981	Jabczynski, Felix (AZ)	1989	Rothman, Michael (NM)	1974
Barmada, Adam (OR)	2001	Johnson, Robert (ND)	1981	Rust, David (MN)	2012
Bear, Jan (NM)	1991	Kaltenbaugh, Orie (ID)	1978	Schaab, Peter (AK)	1990
Becker, Jeremy (NM)	1997	Kane, Daniel (IL)	1977	Schwarting, Ted (AK)	2003
Behzadi, Kambiz (CA)	1994	Khoury, David (WY)	2007	Shafer, Jonathan (WA)	2006
Benson, Robert (NM)	1973	Klein, Roger (CA)	1984	Shantharam, Sanagaram (CA)	1992
Benson, Eric (NM)	2007	Kloberdanz, Dennis (NM)	1988	Shonnard, Paul (NV)	1995
Bergeson, Ryan (TX)	2008	Korthauer, Ken (TX)	1985	Silva, Selina (NM)	2010
Bernasek, Thomas (FL)	1986	Kosty, John (TX)	1983	Simpson, Robert (NY)	1976
Blackwood, C. Brian (CO)	2011	Lansing, Letitia (NY)	2010	Slauterbeck, James (VT)	1993
Bloome, David (TX)	2001	Larson, Loren (WA)	2006	Smith, Christopher (WY)	1974
Burner, William (VA)	1980	Latimer, Earl (NM)	1993	Smith, Dean (TX)	2000
Burney, Dwight (NM)	1980	Lee, Robert (ID)	1995	Smith, Jason (LA)	2007
Burwell, Dudley (MS)	1987	Lieber, Corey (NM)	2006	Sotta, Robert (OR)	1987
Butler, Dale (CA)	1973	Looby, Peter (SD)	1995	Southwell, Richard (WY)	1980
Campbell, Everett (TX)	1973	Lubin, Joel*	2001	Stewart, Daniel (CO)	2012
Cashmore, Bourck (AZ)	1997	Manweiler, Julia (AK)	2009	Summa, Christopher (CA)	1995
Castillo, Richard (NM)	1988	Marcus, Norman (VA)	1983	Teter, Kenneth (KS)	1993
Child, Zachary (WA)	2011	Marshall, Charley (UT)	2005	Thomas, Eric*	2004
Cleary, Joel (MT)	1985	Martinez, Roberto (FL)	1984	Treme, Gehron (NM)	2006
Cohen, Mitchell (CA)	1992	Matt, Victoria (NM)	2002	Tripuraneni, Krishna (NM)	2009
Cole, Harry (WI)	1992	McAdams, Timothy (CA)	2000	Troop, Randall (TX)	1989
Conklin, Matthew (AZ)	1988	McClellan, Victoria (OR)	1984	VanBuskirk, Cathleen (CO)	1999
Conrad, Clayton (NM)	2009	McEnnerney, Thomas (NM)	1984	Vance, Tedman (GA)	1999
Cook, Geoffrey (AZ)	1988	McGee, Kevin (NM)	2008	Veitch, Andrew (NM)	2003
Cortese, David (WA)	2005	McGinty, Laurel*	1991	Veitch, John (NM)	1978
Crawford, Mark (NM)	1994	McGuire, Michael (NE)	1995	Verploeg, Eric (CO)	1987
Dona, Grant (LA)	1993	McKinley, Matthew (NM)	1998	Verska, Joseph (ID)	1994
Downey, Daniel (MT)	1992	Mercer, Deana (NM)	2008	Webb, David (TX)	1977
Durrani, Shakeel (NY)	2010	Miller, Richard (NM)	1990	White, Richard (NM)	1979
Dvirnak, Paul (CO)	1996	Milner, Brent (WY)	2003	Wiemann, John (OH)	2011
Echols, Paul (NM)	1978	Minor, Frank (CA)	1982	Willis, Michael (MT)	2000
Eglinton, Daniel (NC)	1983	Montgomery, Rosalyn (OR)	1991	Witmer, Bruce (CA)	1982
Fahey, James (NM)	1978	Moore, Kris (OR)	2008	Yaste, Jeffrey (NC)	2009
Ferries, James (WY)	1995	Motamedi, Ali (TX)	1998		
Ferro, Thomas (CA)	1990	Munger, David (AZ)	1969		
FitzPatrick, Jennifer (CO)	2010	Naraghi, Fred (CA)	1981		
Franco, John (NM)	2003	Newcomer, Joseph (IL)	1998		
Garza, Orlando (TX)	1977	Ochsner, Lockwood (LA)	1986		
Gilmore, Jan (VA)	2012	Paterson, Andrew (NM)	2004		
Goodman, Robert (CO)	1980	Patman, L. Johnsonn (UT)	2012		
Griffiths, Stan (ID)	1989	Paton, William (AK)	1977		
Grimes, Speight (TX)	2004	Paton, William (AK)	1977		
Hanosh, Christopher (NM)	2001	Patton, Matt (NM)	2002		
Hartman, Gregg (CA)	1997	Peer, Chris (MI)	2005		
Hayes, Robert (TX)	1975	Pflum, Eugene (CO)	1976		
Hayes, William (TX)	1996	Phelps, Dennis (CO)	1985		
Heetderks, David (MT)	1990	Pike, Gregg (MT)	2004		
		Porras, Mario (NV)	1977		
		Racca, Jeffrey (NM)	2000		
		Redmon, Shannah (AZ)	2009		

\*Deceased

# Journal Submissions

## Instructions to Authors

The mission of the University of New Mexico Orthopaedics Research Journal is to highlight the research work in orthopaedics done by the faculty, fellows, residents, students, staff, and alumni associated with the UNM Department of Orthopaedics and Rehabilitation. The journal invites submissions of original articles that have not been published, case reports, review articles, descriptions of novel procedures, and updates of research studies in progress.

Manuscripts saved as Microsoft Word documents should be sent to UNMORJ@salud.unm.edu for consideration. Please be sure the manuscript has a title page, short unstructured abstract (less than 300 words), and introduction, methods, data analysis, results, discussion, and reference sections. Tables and figures, if included, should be on separate pages at the end of the document. References should be listed using AMA style.

## Conditions of Submission

**WORK(S) COVERED UNDER THIS AGREEMENT:** This agreement includes all submitted written material as well as any supplementary digital material including, but not limited to, audio, video, and other data files whose formats may vary.

**RETAINED RIGHTS:** Copyright and other proprietary rights related to the Work shall be retained by the authors.

**ORIGINALITY:** Each author warrants that his or her submission to the Work is original and that he or she has full power to enter into this agreement.

**AUTHORSHIP RESPONSIBILITY:** Each author certifies that he or she has participated sufficiently in the conception and design of this work, intellectual content, the analysis of data, if applicable, and the writing of the work to take responsibility for the integrity and accuracy of the data. Each has reviewed the final version of the work, believes it represents valid work, and approves it for publication. Moreover, the authors shall produce the data upon which the work is based for examination should the editors request it.

**DISCLAIMER:** Each author warrants that this Work contains no libelous or unlawful statements and does not infringe on the rights of others. If excerpts (text, figures, tables, or illustrations) from copyrighted works are included, a written release will be secured by the authors prior to submission, and credit to the original publication will be properly acknowledged. Each author warrants that he or she has obtained, prior to submission, written releases from patients whose photographs are submitted as part of the Work. Each author further warrants that any patient photographs or histories have been de-identified pursuant to UNMHSC policy, and any releases have been completed on the prescribed UNMHSC form. Should UNMHSC request copies of such written releases, authors shall provide them to UNMHSC in a timely manner.

## Grant of Copyright License

**AUTHORS' OWN WORK:** In consideration of UNMHSC's considering publication of the Work, the authors hereby grant to UNMHSC the non-exclusive royalty free irrevocable, worldwide, right and license, but not obligation, to exercise all rights to the Work submitted by authors including but not limited to the right to reproduce and publish in all languages, and in all forms of media now or hereafter known, including electronic media such as CD-ROM, Internet, and Intranet, and to authorize another or others to do any of the foregoing. If UNMHSC should decide for any reason not to publish an author's submission to the Work, UNMHSC shall give prompt notice of its decision to the corresponding author, this agreement shall terminate, and neither the author nor UNMHSC shall be under any further liability or obligation. The authors grant UNMHSC the rights to use their names, images and biographical data (including professional affiliation) in the Work and in its or the Publication's promotion.

**WORK MADE FOR HIRE:** If this work has been commissioned by another person or organization, or if it has been written as part of the duties of an employee, an authorized representative of the commissioning organization or employer must also sign an authorship form stating his or her title in the organization.

**GOVERNMENT EMPLOYEES:** If this submission to the Work has been written in the course of the author's employment by the United States Government, check the "Government" box at the end of the authorship form. A work prepared by a government employee as part of his or her official duties is called a "work of the U.S. Government" and is not subject to copyright. If it is not prepared as part of the employee's official duties, it may be subject to copyright.

**INSTITUTIONAL REVIEW BOARD/ANIMAL CARE COMMITTEE APPROVAL:** Each author certifies that his or her institution has approved the protocol for any investigation involving humans or animals and that all experimentation was conducted in conformity with ethical and humane principles of research.





