




USMLE Step 1

Sample Test Questions

A Joint Program of the Federation of State Medical Boards of the United States, Inc.,
and the National Board of Medical Examiners®



This booklet updated April 2014.

Copyright © 2014 by the Federation of State Medical Boards of the United States, Inc. (FSMB), and the National Board of Medical Examiners® (NBME®). All rights reserved. Printed in the United States of America. The United States Medical Licensing Examination (USMLE®) is a joint program of the FSMB and the NBME.

CONTENTS

USMLE Step 1 Test Question Formats	3
Introduction to USMLE Step 1 Sample Test Questions	4
Normal Laboratory Values	5
USMLE Step 1 Sample Test Questions.....	7
Answer Form for USMLE Step 1 Sample Test Questions.....	42
Answer Key for USMLE Step 1 Sample Test Questions.....	43

USMLE Step 1 Test Question Formats

Strategies

The following are strategies for answering one-best-answer items:

- Read each question carefully. It is important to understand what is being asked.
- Try to generate an answer and then look for it in the option list.
- Alternatively, read each option carefully, eliminating those that are clearly incorrect.
- Of the remaining options, select the one that is most correct.
- If unsure about an answer, it is better to guess since unanswered questions are automatically counted as wrong answers.

Single-Item Questions

A single patient-centered vignette is associated with one question followed by four or more response options. The response options are lettered (ie, A, B, C, D, E). A portion of the questions involves interpretation of graphic or pictorial materials. You are required to select the best answer to the question. Other options may be partially correct, but there is only ONE BEST answer. This is the traditional, most frequently used multiple-choice question format on the examination.

Example Item

A 32-year-old woman with type 1 diabetes mellitus has had progressive renal failure over the past 2 years. She has not yet started dialysis. Examination shows no abnormalities. Her hemoglobin concentration is 9 g/dL, hematocrit is 28%, and mean corpuscular volume is $94 \mu\text{m}^3$. A blood smear shows normochromic, normocytic cells. Which of the following is the most likely cause?

- | | |
|-----------------------------------|--------------------------------|
| (A) Acute blood loss | (G) Polycythemia vera |
| (B) Chronic lymphocytic leukemia | (H) Sickle cell disease |
| (C) Erythrocyte enzyme deficiency | (I) Sideroblastic anemia |
| (D) Erythropoietin deficiency | (J) β -Thalassemia trait |
| (E) Immuno-hemolysis | |
| (F) Microangiopathic hemolysis | |

(Answer: D)

Sequential Item Sets

A single patient-centered vignette may be associated with two or three consecutive questions about the information presented. Each question is associated with the initial patient vignette but is testing a different point. You are required to select the ONE BEST answer to each question. Questions are designed to be answered in sequential order. You must click “Proceed to Next Item” to view the next item in the set; once you click on this button, you will not be able to add or change an answer to the displayed (previous) item.

NOTE: Some item types that appear on the Step 1 examination are NOT depicted in the sample items provided in this booklet: sequential item sets and items with multimedia features (such as audio). In addition, when additional item formats are added to the exam, notice will be provided at the USMLE Web site: www.usmle.org. You must monitor the Web site to stay informed about the types of items that occur in the exam, and must practice with the downloadable sample test items available on the USMLE Web site to be fully prepared for the examination.

Introduction to USMLE Step 1 Sample Test Questions

The following pages include 138 sample test questions. Most of these questions are the same as those you install on your computer from the USMLE Web site. Please note that reviewing the sample questions as they appear on pages 7-41 is not a substitute for practicing with the test software. You should download and run the Step 1 tutorial and practice test items that are provided on the USMLE website well before your test date. The sample materials available at the USMLE Web site include additional items and item formats that do not appear in this booklet, such as items with associated audio or video findings and sequential item sets. You should become familiar with all item formats that will be used in the actual examination.

Although the sample questions exemplify content on the examination, they may not reflect the content coverage on individual examinations. In the actual examination, questions will be presented in random order; they will not be grouped according to specific content. The questions will be presented one at a time in a format designed for easy on-screen reading, including use of exhibit buttons for the Normal Laboratory Values Table (included here on pages 5–6) and some pictorials. Photographs, charts, and x-rays in this booklet are not of the same quality as the pictorials used in the actual examination. In addition, you will be able to adjust the brightness and contrast of pictorials on the computer screen.

To take the following sample test questions as they would be timed in the actual examination, you should allow a maximum of one hour for each 46-item block, for a total of three hours. Please be aware that most examinees perceive the time pressure to be greater during an actual examination. An answer form for recording answers is provided on page 42. An answer key is provided on page 43. In the actual examination, answers will be selected on the screen; no answer form will be provided.

LABORATORY VALUES

* Included in the Biochemical Profile (SMA-12)

	<u>REFERENCE RANGE</u>	<u>SI REFERENCE INTERVALS</u>
BLOOD, PLASMA, SERUM		
* Alanine aminotransferase (ALT), serum.....	8-20 U/L	8-20 U/L
Amylase, serum.....	25-125 U/L.....	25-125 U/L
* Aspartate aminotransferase (AST), serum	8-20 U/L.....	8-20 U/L
Bilirubin, serum (adult) Total // Direct	0.1-1.0 mg/dL // 0.0-0.3 mg/dL	2-17 µmol/L // 0-5 µmol/L
* Calcium, serum (Ca ²⁺)	8.4-10.2 mg/dL.....	2.1-2.8 mmol/L
* Cholesterol, serum	Rec:<200 mg/dL	<5.2 mmol/L
Cortisol, serum.....	0800 h: 5-23 µg/dL // 1600 h: 3-15 µg/dL	138-635 nmol/L // 82-413 nmol/L
	2000 h: ≤ 50% of 0800 h.....	Fraction of 0800 h: ≤ 0.50
Creatine kinase, serum	Male: 25-90 U/L	25-90 U/L
	Female: 10-70 U/L	10-70 U/L
* Creatinine, serum	0.6-1.2 mg/dL	53-106 µmol/L
Electrolytes, serum		
Sodium (Na ⁺)	136-145 mEq/L	136-145 mmol/L
* Potassium (K ⁺)	3.5-5.0 mEq/L	3.5-5.0 mmol/L
Chloride (Cl ⁻).....	95-105 mEq/L	95-105 mmol/L
Bicarbonate (HCO ₃ ⁻).....	22-28 mEq/L	22-28 mmol/L
Magnesium (Mg ²⁺).....	1.5-2.0 mEq/L	0.75-1.0 mmol/L
Estriol, total, serum (in pregnancy)		
24-28 wks // 32-36 wks	30-170 ng/mL // 60-280 ng/mL	104-590 nmol/L // 208-970 nmol/L
28-32 wks // 36-40 wks	40-220 ng/mL // 80-350 ng/mL	140-760 nmol/L // 280-1210 nmol/L
Ferritin, serum.....	Male: 15-200 ng/mL	15-200 µg/L
	Female: 12-150 ng/mL	12-150 µg/L
Follicle-stimulating hormone, serum/plasma	Male: 4-25 mIU/mL	4-25 U/L
	Female: premenopause 4-30 mIU/mL	4-30 U/L
	midcycle peak 10-90 mIU/mL	10-90 U/L
	postmenopause 40-250 mIU/mL	40-250 U/L
Gases, arterial blood (room air)		
pH	7.35-7.45	[H ⁺] 36-44 nmol/L
PCO ₂	33-45 mm Hg	4.4-5.9 kPa
PO ₂	75-105 mm Hg	10.0-14.0 kPa
* Glucose, serum.....	Fasting: 70-110 mg/dL	3.8-6.1 mmol/L
	2-h postprandial: < 120 mg/dL	< 6.6 mmol/L
Growth hormone - arginine stimulation	Fasting: < 5 ng/mL	< 5 µg/L
	provocative stimuli: > 7 ng/mL	> 7 µg/L
Immunoglobulins, serum		
IgA	76-390 mg/dL.....	0.76-3.90 g/L
IgE	0-380 IU/mL	0-380 kIU/L
IgG	650-1500 mg/dL	6.5-15 g/L
IgM	40-345 mg/dL	0.4-3.45 g/L
Iron	50-170 µg/dL	9-30 µmol/L
Lactate dehydrogenase, serum	45-90 U/L.....	45-90 U/L
Luteinizing hormone, serum/plasma	Male: 6-23 mIU/mL	6-23 U/L
	Female: follicular phase 5-30 mIU/mL	5-30 U/L
	midcycle 75-150 mIU/mL	75-150 U/L
	postmenopause 30-200 mIU/mL	30-200 U/L
Osmolality, serum	275-295 mOsmol/kg H ₂ O	275-295 mOsmol/kg H ₂ O
Parathyroid hormone, serum, N-terminal	230-630 pg/mL	230-630 ng/L
* Phosphatase (alkaline), serum (p-NPP at 30°C)	20-70 U/L	20-70 U/L
* Phosphorus (inorganic), serum.....	3.0-4.5 mg/dL	1.0-1.5 mmol/L
Prolactin, serum (hPRL)	< 20 ng/mL	< 20 µg/L
* Proteins, serum		
Total (recumbent)	6.0-7.8 g/dL	60-78 g/L
Albumin	3.5-5.5 g/dL.....	35-55 g/L
Globulin	2.3-3.5 g/dL.....	23-35 g/L
Thyroid-stimulating hormone, serum or plasma	0.5-5.0 µU/mL	0.5-5.0 mU/L
Thyroidal iodine (¹²⁵ I) uptake.....	8%-30% of administered dose/24 h	0.08-0.30/24 h
Thyroxine (T ₄), serum.....	5-12 µg/dL	64-155 nmol/L
Triglycerides, serum.....	35-160 mg/dL.....	0.4-1.81 mmol/L
Triiodothyronine (T ₃), serum (RIA)	115-190 ng/dL	1.8-2.9 nmol/L
Triiodothyronine (T ₃) resin uptake.....	25%-35%	0.25-0.35
* Urea nitrogen, serum	7-18 mg/dL	1.2-3.0 mmol/L
* Uric acid, serum	3.0-8.2 mg/dL	0.18-0.48 mmol/L

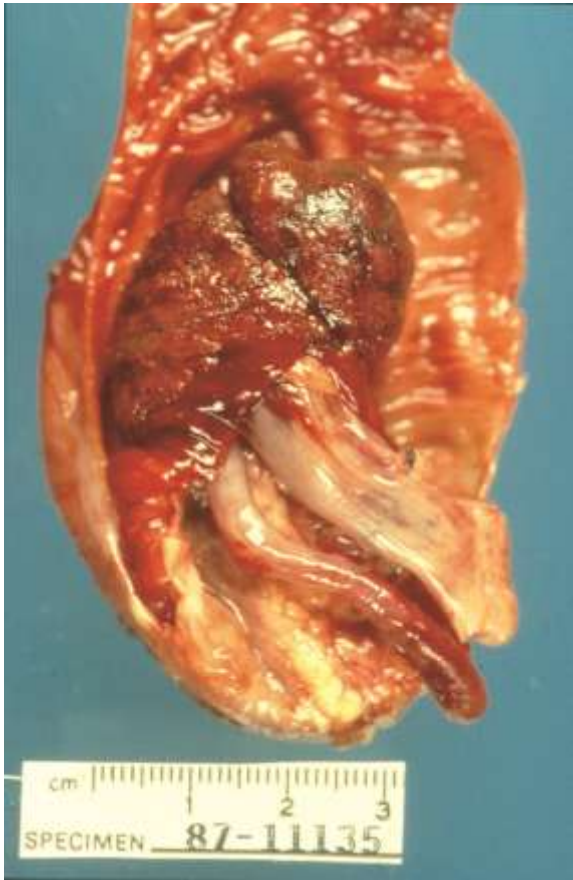LABORATORY VALUES (continued from previous page)

	<u>REFERENCE RANGE</u>	<u>SI REFERENCE INTERVALS</u>
BODY MASS INDEX (BMI)		
Body mass index	Adult: 19-25 kg/m ²	
CEREBROSPINAL FLUID		
Cell count	0-5/mm ³	0-5 x 10 ⁶ /L
Chloride	118-132 mEq/L	118-132 mmol/L
Gamma globulin.....	3%-12% total proteins	0.03-0.12
Glucose	40-70 mg/dL	2.2-3.9 mmol/L
Pressure	70-180 mm H ₂ O	70-180 mm H ₂ O
Proteins, total	<40 mg/dL	<0.40 g/L
HEMATOLOGIC		
Bleeding time (template)	2-7 minutes	2-7 minutes
Erythrocyte count	Male: 4.3-5.9 million/mm ³ Female: 3.5-5.5 million/mm ³	4.3-5.9 x 10 ¹² /L 3.5-5.5 x 10 ¹² /L
Erythrocyte sedimentation rate (Westergren).....	Male: 0-15 mm/h Female: 0-20 mm/h	0-15 mm/h 0-20 mm/h
Hematocrit	Male: 41%-53% Female: 36%-46%	0.41-0.53 0.36-0.46
Hemoglobin A _{1c}	≤ 6%	≤ 0.06
Hemoglobin, blood.....	Male: 13.5-17.5 g/dL Female: 12.0-16.0 g/dL	2.09-2.71 mmol/L 1.86-2.48 mmol/L
Hemoglobin, plasma	1-4 mg/dL	0.16-0.62 mmol/L
Leukocyte count and differential		
Leukocyte count	4500-11,000/mm ³	4.5-11.0 x 10 ⁹ /L
Segmented neutrophils	54%-62%	0.54-0.62
Bands.....	3%-5%	0.03-0.05
Eosinophils	1%-3%	0.01-0.03
Basophils.....	0%-0.75%	0-0.0075
Lymphocytes	25%-33%	0.25-0.33
Monocytes	3%-7%	0.03-0.07
Mean corpuscular hemoglobin	25.4-34.6 pg/cell	0.39-0.54 fmol/cell
Mean corpuscular hemoglobin concentration	31%-36% Hb/cell	4.81-5.58 mmol Hb/L
Mean corpuscular volume	80-100 μm ³	80-100 fL
Partial thromboplastin time (activated)	25-40 seconds	25-40 seconds
Platelet count.....	150,000-400,000/mm ³	150-400 x 10 ⁹ /L
Prothrombin time	11-15 seconds	11-15 seconds
Reticulocyte count.....	0.5%-1.5%	0.005-0.015
Thrombin time	<2 seconds deviation from control	<2 seconds deviation from control
Volume		
Plasma	Male: 25-43 mL/kg Female: 28-45 mL/kg	0.025-0.043 L/kg 0.028-0.045 L/kg
Red cell	Male: 20-36 mL/kg Female: 19-31 mL/kg	0.020-0.036 L/kg 0.019-0.031 L/kg
SWEAT		
Chloride.....	0-35 mmol/L	0-35 mmol/L
URINE		
Calcium	100-300 mg/24 h	2.5-7.5 mmol/24 h
Chloride.....	Varies with intake	Varies with intake
Creatinine clearance	Male: 97-137 mL/min Female: 88-128 mL/min	
Estriol, total (in pregnancy)		
30 wks	6-18 mg/24 h	21-62 μmol/24 h
35 wks	9-28 mg/24 h	31-97 μmol/24 h
40 wks	13-42 mg/24 h	45-146 μmol/24 h
17-Hydroxycorticosteroids	Male: 3.0-10.0 mg/24 h Female: 2.0-8.0 mg/24 h	8.2-27.6 μmol/24 h 5.5-22.0 μmol/24 h
17-Ketosteroids, total	Male: 8-20 mg/24 h Female: 6-15 mg/24 h	28-70 μmol/24 h 21-52 μmol/24 h
Osmolality	50-1400 mOsmol/kg H ₂ O	
Oxalate	8-40 μg/mL	90-445 μmol/L
Potassium	Varies with diet	Varies with diet
Proteins, total	<150 mg/24 h	<0.15 g/24 h
Sodium	Varies with diet	Varies with diet
Uric acid.....	Varies with diet	Varies with diet

USMLE STEP1 SAMPLE TEST QUESTIONS

BLOCK 1, ITEMS 1-46

1. A 25-year-old woman is brought to the emergency department 1 hour after she fainted. She has had mild intermittent vaginal bleeding, sometimes associated with lower abdominal pain, during the past 3 days. She has had severe cramping pain in the right lower abdomen for 12 hours. She has not had a menstrual period for 3 months; previously, menses occurred at regular 28-day intervals. Abdominal examination shows mild tenderness to palpation in the right lower quadrant. Bimanual pelvic examination shows a tender walnut-sized mass in the right parametrium. Which of the following is the most likely diagnosis?
- (A) Appendicitis
 - (B) Cancer of the ovary
 - (C) Ectopic pregnancy
 - (D) Endometriosis
 - (E) Ovarian cyst
 - (F) Placenta previa
2. A 12-year-old girl with a 1-year history of systemic lupus erythematosus is brought to the physician for a routine follow-up examination. During the past year she has done well with the exception of occasional mild frontal headaches, fatigue, and arthralgias; the results of regular laboratory evaluations have been stable. She has missed 20 days of school in the past 4 months. Her parents express concern that sending her to school might cause her to be exposed to children with contagious diseases that might exacerbate their daughter's condition. The girl tells the physician that she misses seeing her many friends at school. Passive motion of the elbows, wrists, and knees produces mild discomfort. Physical examination shows no other abnormalities. Which of the following is the most likely cause of this patient's excessive school absences?
- (A) Lupus arthritis
 - (B) Lupus cerebritis
 - (C) Malingering
 - (D) School phobia
 - (E) Vulnerable child syndrome
3. A 4-year-old boy has delayed motor development and choreoathetosis. He had normal development at birth. He chews his fingers and lips, which has resulted in tissue loss. He has arthritis. Serum and urine uric acid concentrations are increased. Which of the following abnormalities is the most likely cause of these findings?
- (A) Adenine phosphoribosyltransferase deficiency
 - (B) Hypoxanthine-guanine phosphoribosyltransferase deficiency
 - (C) Increased cellular turnover of nucleic acids
 - (D) Increased conversion of hypoxanthine to inosine monophosphate
 - (E) Phosphoribosylpyrophosphate synthetase deficiency
4. A 42-year-old woman comes to the physician for a routine examination. She says that she has felt well except for occasional episodes of constipation, abdominal discomfort, and mild fatigue. She was treated for a renal calculus 10 years ago and was told she had a "lazy gallbladder." Her pulse is 82/min, and blood pressure is 150/80 mm Hg. Physical examination shows no other abnormalities. Laboratory studies show:
- | | |
|----------------------|---------------------------|
| Erythrocyte count | 3 million/mm ³ |
| Serum | |
| K ⁺ | 4.5 mEq/L |
| Cl ⁻ | 107 mEq/L |
| Ca ²⁺ | 12 mg/dL |
| Phosphorus | 2.2 mg/dL |
| Alkaline phosphatase | 95 U/L |
- The most likely cause of this patient's condition is a small, well-defined nodule in which of the following locations?
- (A) Adrenal gland
 - (B) Anterior pituitary gland
 - (C) Gallbladder
 - (D) Kidney
 - (E) Parathyroid gland
 - (F) Thymus

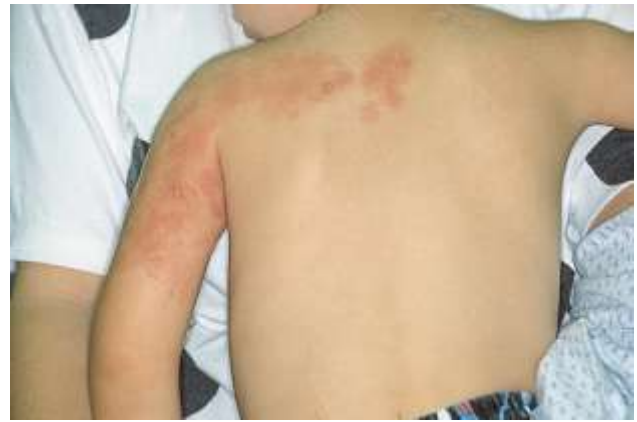

5. A 4-year-old girl has the sudden onset of abdominal pain and vomiting. She has a mass in the right lower quadrant and hyperactive bowel sounds. A segment of resected bowel is shown in the photograph. Which of the following is the most likely diagnosis?

- (A) Appendicitis
- (B) Intussusception
- (C) Meckel diverticulum
- (D) Necrotizing enterocolitis
- (E) Strangulated hernia

6. A 12-year-old girl with sickle cell disease has pain in her right arm. An x-ray of the right upper extremity shows bony lesions consistent with osteomyelitis. Which of the following is the most likely causal organism?

- (A) *Clostridium septicum*
- (B) *Enterococcus faecalis*
- (C) *Listeria monocytogenes*
- (D) *Proteus mirabilis*
- (E) *Pseudomonas aeruginosa*
- (F) *Salmonella enteritidis*
- (G) *Serratia marcescens*



7. A 3-year-old boy is brought to the physician because of fever, headache, and sores on his back and left shoulder for 1 day. His temperature is 37.8°C (100°F). Physical examination shows vesicles over the back and left shoulder as in the photograph shown. Treatment with aspirin is CONTRAINDICATED in this patient because of an epidemiologic association with a syndrome that includes which of the following adverse effects?

- (A) Bronchoconstriction
- (B) Disseminated intravascular coagulation
- (C) Gastric irritation
- (D) Hepatomegaly
- (E) Immunosuppression

8. A 62-year-old woman comes to the physician because of low back pain for 1 week. Menopause occurred 10 years ago. Physical examination shows localized tenderness over the lumbar spine after movement. X-rays of the spine show a compression fracture of L1-2. A DEXA scan shows decreased bone mineral density. Serum calcium and phosphorus concentrations and serum alkaline phosphatase activity are within the reference ranges. A bisphosphonate drug is prescribed. The expected beneficial effect of this drug is most likely due to which of the following actions?

- (A) Decreased insulin-like growth factor-1 concentration
- (B) Decreased osteoclast activity
- (C) Decreased osteoprotegerin production
- (D) Increased 1,25-dihydroxycholecalciferol concentration
- (E) Increased osteoblast activity
- (F) Increased receptor activator of NF-κB ligand (RANKL) production

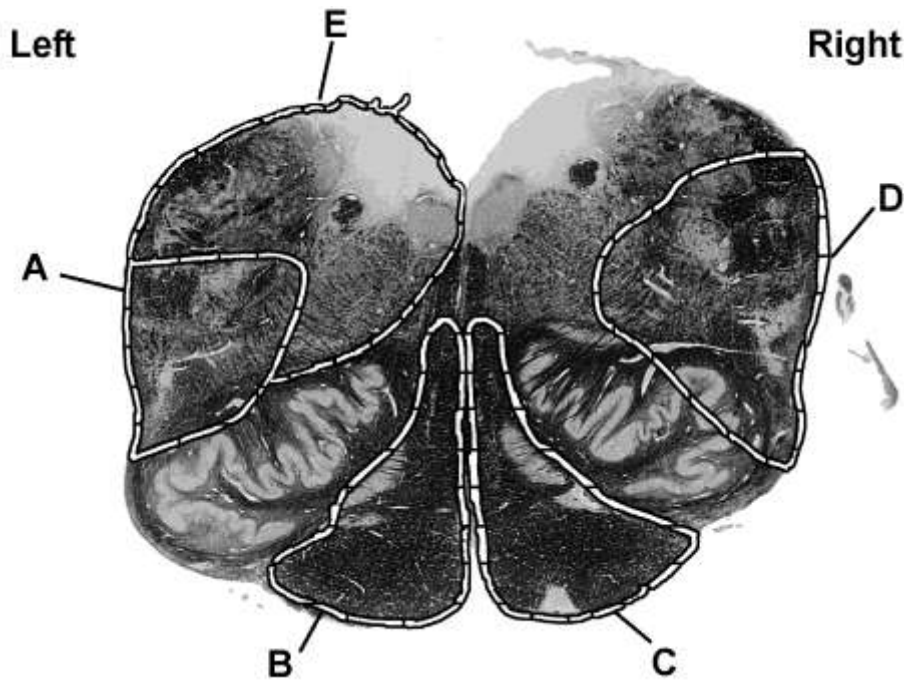
9. Hospital discharge of a 75-year-old man is delayed due to unavailability of a bed in a nursing home. He is bedridden and unable to attend to his personal needs. During a 3-day period, his pulse increases from 82/min to 125/min, and blood pressure decreases from 124/72 mm Hg to 100/55 mm Hg. Laboratory values include:

	Day 1	Day 3
Hemoglobin	16.4 g/dL	18.4 g/dL
Serum		
Urea nitrogen	18 mg/dL	56 mg/dL
Glucose	100 mg/dL	89 mg/dL
Na ⁺	135 mEq/L	151 mEq/L
Creatinine	1.1 mg/dL	1.2 mg/dL

Which of the following is the most likely diagnosis?


- (A) Acute renal failure
 (B) Dehydration
 (C) Diabetic ketoacidosis
 (D) Gastrointestinal hemorrhage
 (E) Syndrome of inappropriate ADH (vasopressin)
-
10. A 76-year-old man with a history of prostatic hypertrophy has the recent onset of increased difficulty urinating. Symptoms began shortly after he started taking a nasal decongestant orally for cold symptoms. Which of the following types of receptors is most likely to be involved in these adverse effects?
- (A) α_1 -Adrenergic
 (B) β_2 -Adrenergic
 (C) Ganglionic nicotinic
 (D) Nicotinic receptor at the neuromuscular junction
 (E) Serotonergic
11. A 15-year-old girl is brought to the physician because of a 3-week history of excessive thirst and voiding excessive amounts of urine. She shows no signs of kidney damage, and she is not taking any medications. Physical examination shows no abnormalities. She undergoes an 8-hour water deprivation test. She is also given 5 units of ADH (vasopressin), subcutaneously. Under both conditions, she continues to produce large volumes of dilute urine. Her symptoms are most likely due to a relative lack of which of the following proteins from the apical membranes of collecting duct epithelial cells?
- (A) Aquaporin
 (B) Epithelial Na⁺ channel
 (C) Na⁺-K⁺ ATPase
 (D) Na⁺-K⁺-2Cl⁻ cotransporter
 (E) Urea transporter
12. A placebo-controlled clinical trial is conducted to assess whether a new antihypertensive drug is more effective than standard therapy. A total of 5000 patients with essential hypertension are enrolled and randomly assigned to one of two groups: 2500 patients receive the new drug and 2500 patients receive placebo. If the alpha is set at 0.01 instead of 0.05, which of the following is the most likely result?
- (A) Significant findings can be reported with greater confidence
 (B) The study will have more power
 (C) There is a decreased likelihood of a Type II error
 (D) There is an increased likelihood of statistically significant findings
 (E) There is an increased likelihood of a Type I error
13. A sexually active 23-year-old man with multiple sex partners has dysuria and a yellow urethral exudate. Gram stain of the exudate shows numerous neutrophils, many that contain intracellular gram-negative diplococci. He has had three similar episodes of urethritis over the past 2 years. Which of the following properties of the infecting organism best explains the reinfection?
- (A) Antigenic variation
 (B) Catalase
 (C) Inhibition of B-lymphocyte function
 (D) Inhibition of T-lymphocyte function
 (E) Polysaccharide capsule

14. A 68-year-old woman has the sudden onset of weakness in her right arm and leg. She can speak, but her words are not enunciated clearly. Neurologic examination 6 weeks later shows an extensor plantar reflex on the right. When she is asked to protrude her tongue, it deviates to the left, and the muscle in the left side of the tongue shows considerable atrophy. Which of the following labeled areas in the transverse sections of the brain stem is most likely damaged?

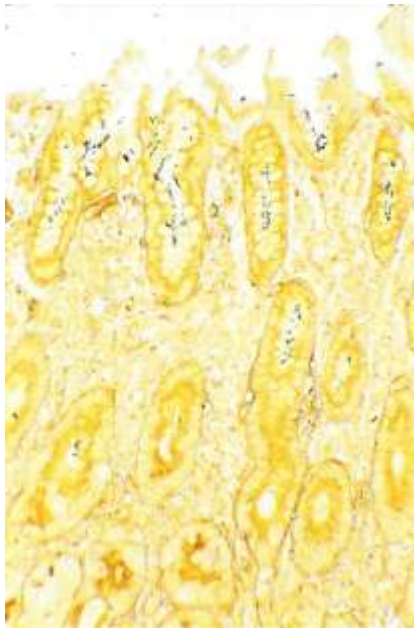


15. A 33-year-old woman comes to the physician because of a 2-day history of mild nausea, increased urinary urgency and frequency, and constipation. She also has had a 4.5-kg (10-lb) weight loss during the past 2 weeks and a 3-week history of vaginal bleeding. Pelvic examination shows a nodular cervix with an irregular, friable posterior lip, and a rock-hard, irregular, immobile pelvic mass that extends across the pelvis. Examination of biopsy specimens from the cervix and anterior wall of the vagina show well-differentiated keratinizing squamous cell carcinoma. Which of the following best describes the pathogenesis of this patient's disease?
- (A) Inactivation of cellular p53
 - (B) Insertion of viral promotors adjacent to cellular growth factor genes
 - (C) Specialized transduction
 - (D) Transactivation of cellular growth factor genes by *TAX*
 - (E) Translocation of *CMYC* to an Ig gene promoter
16. A 22-year-old man develops delusions, flattening of affect, catatonic behavior, hallucinations, and aphasia. Which of the following symptoms would be more likely to improve if this patient were treated with clozapine rather than with haloperidol?
- (A) Affective flattening and aphasia
 - (B) Affective flattening and hallucinations
 - (C) Aphasia and delusions
 - (D) Catatonia and delusions
 - (E) Hallucinations and catatonia
17. After infection with measles virus, a 6-year-old boy produces antibodies to all eight viral proteins. The next year he is again exposed to measles virus. Antibodies to which of the following viral proteins are most likely to be protective?
- (A) Hemagglutinin
 - (B) Matrix
 - (C) Nonstructural
 - (D) Nucleocapsid
 - (E) Polymerase

18. A 25-year-old woman comes to the physician because of a 10-year history of frequent occurrences of fever blisters. Physical examination shows perioral vesicles. Microscopic examination of culture of scrapings from three vesicles shows herpes simplex virus 1. Which of the following patterns in the figure shown was most likely observed when the viral DNA from the cultures was examined by restriction enzyme analysis on polyacrylamide gels?



19. A 52-year-old woman comes to the physician because of a 2-day history of fever and left flank pain. She has been treated for multiple episodes of pyelonephritis during the past 3 years. Her temperature is 37.8°C (100.1°F). Physical examination shows left flank tenderness. Urinalysis shows 12–18 WBC/hpf with occasional lymphocytes and mononuclear cells with features of macrophages. Cultures of urine grow 80,000 colonies/mL of *Proteus mirabilis*. An x-ray of the abdomen shows a 3-cm mass in the lower pole of the left kidney. Gross examination of the mass after it has been resected shows that it is yellow, 3.2-cm in diameter, and centrally but not marginally necrotic. Histologic examination of the mass shows a predominance of epithelioid cells with partially clear and granular-to-foamy cytoplasm. Nuclei are eccentric, normochromic, symmetric, and without significant pleomorphism. Scattered lymphocytes and plasma cells are intermixed. Which of the following is the most likely diagnosis?
- (A) Acute pyelonephritis
 - (B) Malacoplakia
 - (C) Renal cell carcinoma, clear cell type, intermediate grade
 - (D) Renal cell carcinoma, granular cell type
 - (E) Xanthogranulomatous pyelonephritis
20. A 35-year-old woman with a bicuspid aortic valve comes to the physician because of a 1-week history of a swollen, painful left knee. She has had occasional fever and progressive fatigue during the past 4 months. Her temperature is 38.2°C (100.8°F). Physical examination shows a tender left knee with an effusion. A grade 2/6 systolic murmur is heard. Echocardiography shows a vegetation on the aortic valve. Analysis of synovial fluid aspirated from the left knee shows many segmented neutrophils; a Gram stain shows no organisms, and culture is negative. Microscopic examination of the urine shows RBCs and RBC casts, but culture of the urine grows no organisms. Four blood cultures grow an α -hemolytic streptococcus. Which of the following is the most likely cause of the joint and renal disease?
- (A) Autoimmune response triggered by a bacterial antigen
 - (B) Deposition of antigen-antibody complexes
 - (C) IgA nephropathy
 - (D) Neutrophil response to replicating bacteria
 - (E) Type IV (delayed) hypersensitivity to a bacterial antigen



21. An otherwise healthy 45-year-old man comes to the physician because of a 3-week history of progressive epigastric heartburn and a 4.5-kg (10-lb) weight loss. The pain tends to be more severe at night and occurs 1 to 3 hours after meals during the day. He has had similar episodes with lesser intensity during the past year. Abdominal examination shows tenderness to deep palpation. Test of the stool for occult blood is positive. Endoscopy shows a bleeding 3-cm ulcer in the antrum of the stomach. A photomicrograph of Steiner silver-stained tissue (400x) from a biopsy of the gastric mucosa adjacent to the ulcer is shown. Which of the following processes is most likely to be involved?

- (A) Elaboration of proteases and urease with local tissue destruction
- (B) Hyperacidity and gastric ulcer development
- (C) Ingestion of preformed toxins in contaminated well water
- (D) Spirochete invasion of gastric cells

22. A 28-year-old man comes to the physician because of a 1-year history of pain with urination that has increased in severity during the past month. He also has had episodes of blood in his urine during the past 5 years. He lived in sub-Saharan Africa until he came to the USA 6 months ago for graduate school. His temperature is 38°C (100.4°F), pulse is 80/min, respirations are 16/min, and blood pressure is 110/84 mm Hg. Physical examination shows suprapubic tenderness. Laboratory studies show:

Hemoglobin	12.3 g/dL
Hematocrit	37%
Leukocyte count	13,400/mm ³
Segmented neutrophils	65%
Bands	5%
Eosinophils	5%
Lymphocytes	22%
Monocytes	3%
Serum	
Urea nitrogen	75 mg/dL
Creatinine	3.8 mg/dL
Urine	
Blood	3+
RBC	200/hpf
WBC	100/hpf
RBC casts	absent
WBC casts	absent

Imaging studies show bilateral hydronephrosis and hydroureter and foci of calcification in the region of the bladder. A biopsy specimen of the bladder shows marked chronic inflammation with fibrosis and scattered granulomas. Which of the following best explains the biopsy findings?

- (A) Exposure to a chemical toxin
- (B) Interstitial cystitis
- (C) Malacoplakia
- (D) Schistosomiasis
- (E) Vesicoureteral reflux

23. A 4-year-old boy is brought to the physician because of slow growth during the past year. He has had recurrent urinary tract infections since the age of 1 year. He is at the 10th percentile for height and 25th percentile for weight. Physical examination shows pallor. Laboratory studies show a normochromic, normocytic anemia and increased serum concentrations of urea nitrogen and creatinine. Urinalysis shows a low specific gravity. Which of the following sets of additional serum findings is most likely in this patient?

	Calcium	Inorganic Phosphorus	1,25-Dihydroxycholecalciferol	Erythropoietin
(A)	↑	↑	↑	↓
(B)	↑	↑	↓	↓
(C)	↑	↓	↓	↑
(D)	↓	↑	↑	↓
(E)	↓	↑	↓	↓
(F)	↓	↓	↑	↑

24. A 38-year-old man who recently immigrated to the USA comes to the physician because of a 1-month history of cough and a 4.5-kg (10-lb) weight loss. Physical examination shows no abnormalities. A chest x-ray shows a right upper lobe infiltrate. One of three sputum samples is positive for acid-fast bacilli. Treatment with isoniazid, rifampin, ethambutol, and pyrazinamide is started. Which of the following should be added to the medication regimen to prevent neurologic toxicity in this patient?

- (A) Folic acid
- (B) Nicotinic acid
- (C) Vitamin B₆ (pyridoxine)
- (D) Vitamin B₁₂ (cyanocobalamin)
- (E) Vitamin C

26. A technician wants to determine whether cytomegalovirus (CMV) DNA is present in the blood of a bone marrow transplant recipient. DNA purified from the leukocytes of the patient is reacted in a mixture containing oligonucleotides specific for CMV DNA, thermostable DNA polymerase, and nucleotides. Repetitive cycles of heating and cooling are performed, and the reaction product is detected by gel electrophoresis. The technician most likely used which of the following laboratory procedures on this patient's blood?

- (A) Northern blotting
- (B) Polymerase chain reaction
- (C) Reverse transcription
- (D) Southern blotting
- (E) Western blotting

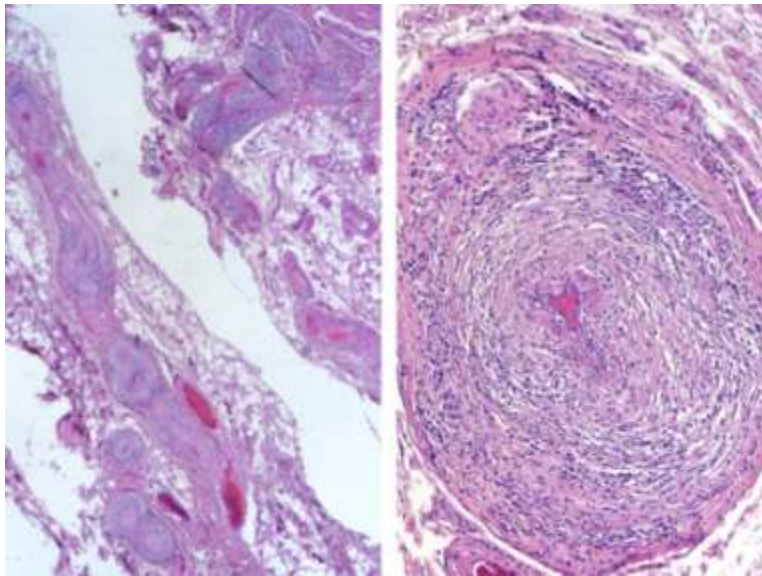
25. A 12-year-old girl is brought to the emergency department by her parents because of a 3-day history of fever and a 12-hour history of lethargy. Her parents say that she has been sleeping most of the day and has been unresponsive when awake. Her temperature is 39.2°C (102.6°F). Physical examination shows numerous petechial hemorrhages and nuchal rigidity. A lumbar puncture yields cloudy cerebrospinal fluid (CSF) that clots in the collection tube. Microscopic examination of the CSF shows numerous segmented neutrophils, and a Gram stain shows gram-negative diplococci. Which of the following is the most likely causal organism?

- (A) *Haemophilus influenzae*
- (B) *Mycoplasma pneumoniae*
- (C) *Neisseria meningitidis*
- (D) *Salmonella typhi*
- (E) *Streptococcus pneumoniae*

27. A 6-year-old boy from rural Mississippi is brought to the physician by his mother because of a 6-month history of lethargy; he also has had a 4-kg (9-lb) weight loss during this period. The mother says her son used to be active, often playing outside without wearing his shoes. The patient is at the 10th percentile for height and 12th percentile for weight. He appears pale. Physical examination shows pale oral mucosa. Laboratory studies show iron deficiency anemia. Microscopic examination of the stool shows thin-shelled ova. Which of the following is the most appropriate pharmacotherapy for this patient?

- (A) Doxycycline
- (B) Ivermectin
- (C) Mebendazole
- (D) Mefloquine
- (E) Trimethoprim-sulfamethoxazole

28. A 17-year-old girl has never had a menstrual period. Physical examination shows a normal female body habitus, normal breast development, and normal appearing external genitalia. She has no axillary or pubic hair. The patient refuses to have a pelvic or rectal examination. Which of the following is the most likely explanation for the clinical presentation?
- (A) Androgen insensitivity
 - (B) Congenital adrenal hyperplasia
 - (C) Ectodermal dysplasia
 - (D) A psychiatric disorder
 - (E) A sex chromosome mosaicism
29. Warfarin is administered to a 56-year-old man following placement of a prosthetic cardiac valve. The warfarin dosage is adjusted to maintain an INR of 2.5. Subsequently, trimethoprim-sulfamethoxazole therapy is begun for a recurring urinary tract infection. In addition to monitoring prothrombin time, which of the following actions should the physician take to maintain adequate anticoagulation?
- (A) Begin therapy with vitamin K
 - (B) Increase the dosage of warfarin
 - (C) Make no alterations in the dosage of warfarin
 - (D) Decrease the dosage of warfarin
 - (E) Stop the warfarin and change to low-dose aspirin
30. A 40-year-old woman comes to the physician because of a 6-month history of increased facial hair growth. Her last menstrual period was 4 months ago. She is 165 cm (5 ft 5 in) tall and weighs 70 kg (154 lb); BMI is 26 kg/m². Her pulse is 80/min, and blood pressure is 130/82 mm Hg. Physical examination shows temporal balding and coarse dark hair on the upper lip and chin. Pelvic examination shows clitoral enlargement. Her serum testosterone concentration is increased. Serum concentrations of androstenedione, dehydroepiandrosterone, and urinary 17-ketosteroids are within the reference ranges. Ultrasonography of the pelvis shows a 12-cm ovarian mass. Which of the following best describes this mass?
- (A) Granulosa tumor
 - (B) Ovarian carcinoid
 - (C) Sertoli-Leydig tumor
 - (D) Teratoma
 - (E) Thecoma
31. A 7-month-old infant is brought to the physician's office because of poor weight gain despite large food intake. He has had two episodes of pneumonia and has frequent bulky stools. He coughs frequently. X-rays of the lungs show increased markings and hyperinflation. Trypsin is absent in a fresh stool sample, and the fat content is increased. Which of the following is the most likely cause of this infant's disorder?
- (A) Autoimmune disorder
 - (B) Defective ion transport at epithelial surfaces
 - (C) Disaccharidase deficiency
 - (D) Inability to synthesize apolipoprotein B
 - (E) Villous atrophy of the jejunum
32. A 50-year-old man has headache, vertigo, and generalized pruritus. He has the recent onset of angina pectoris. His hematocrit is 65%, leukocyte count is 12,000/mm³, and erythrocyte mass is increased. Erythropoietin concentration is decreased. Which of the following is the most likely diagnosis?
- (A) Glucose-6-phosphate dehydrogenase deficiency
 - (B) Hemochromatosis
 - (C) Immune thrombocytopenic purpura
 - (D) Pernicious anemia
 - (E) Polycythemia vera
 - (F) Pyruvate kinase deficiency
 - (G) Secondary polycythemia
33. A new blood test to detect prostate cancer is evaluated in 300 male volunteers. A needle biopsy of the prostate gland is done on all men with serum prostate-specific antigen concentrations greater than 5 ng/mL (N<4). One hundred men undergo biopsy procedures; 90 are found to have prostate cancer, and five are found to have chronic prostatitis. Which of the following is necessary to calculate the sensitivity of this test?
- (A) Incidence of chronic prostatitis in the general population
 - (B) Number of men with test results greater than 5 ng/mL and a normal biopsy specimen
 - (C) Prevalence of chronic prostatitis in the general population
 - (D) Prostate biopsies of men with test results equal to or below 5 ng/mL



34. A 47-year-old man comes to the physician because of a 1-week history of temperatures to 38.3°C (101°F) and occasional vomiting. He also has a 1-year history of joint and muscle pain in his calves and a 1-month history of intermittent, diffuse abdominal pain. His temperature now is 37.2°C (99°F). Abdominal examination shows mild diffuse tenderness. There is no ascites. Test of the stool for occult blood is positive. Serum studies show mildly increased urea nitrogen and creatinine concentrations. Photomicrographs of a biopsy specimen of the mesentery are shown. Which of the following is the most likely diagnosis?

- (A) Angiodysplasia
- (B) Mucocutaneous lymph node syndrome (Kawasaki disease)
- (C) Polyarteritis nodosa
- (D) Takayasu arteritis
- (E) Thromboangiitis obliterans
- (F) Wegener granulomatosis

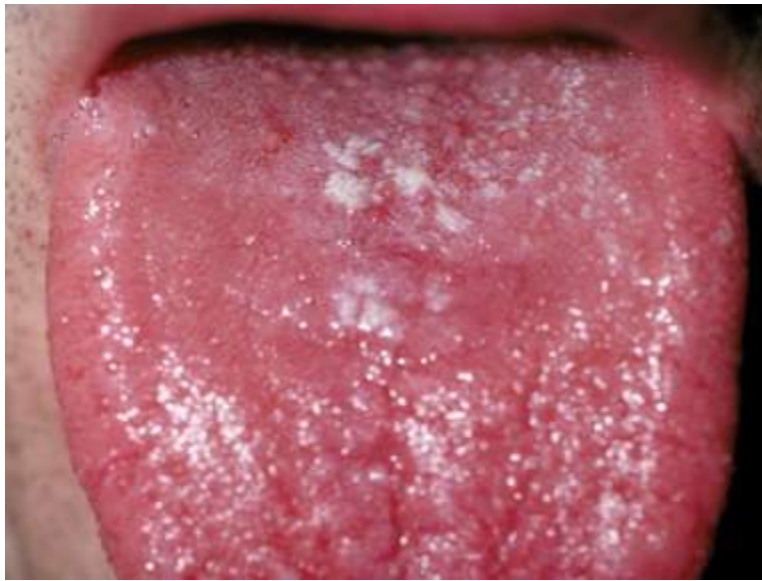35. A 15-year-old girl comes to the physician because of a 3-month history of acne. Breast and pubic hair development began at the age of 12 years. Menarche occurred at the age of 14 years. Physical examination shows scattered open and closed comedones over the cheeks and forehead. Breast and pubic hair development are Tanner stage 5. Which of the following is the most likely underlying cause of this patient's acne?

- (A) Decreased parasympathetic stimulation to the sebaceous glands
- (B) Increased estrogen stimulation of the sebaceous glands
- (C) Increased responsiveness of the sebaceous glands to follicle-stimulating hormone
- (D) Increased sympathetic stimulation to the sebaceous glands
- (E) Stimulation of the sebaceous glands by androgens

36. A 6-year-old boy with glioblastoma has a recurrence of the tumor despite aggressive treatment. The physician discusses the patient's prognosis with his parents and recommends palliative care. The parents ask how they should talk with their son about his prognosis and possible death. The physician advises that the parents should be honest and follow the patient's lead during the conversation. This patient most likely has which of the following concepts of death?

- (A) Being asleep
- (B) Being final
- (C) Being a long journey
- (D) Being a temporary separation from his parents
- (E) No understanding of death

37. A 42-year-old man comes to the physician for a follow-up examination 1 week after he passed a renal calculus. X-ray crystallographic analysis of the calculus showed calcium as the primary cation. Physical examination today shows no abnormalities. A 24-hour collection of urine shows increased calcium excretion. Which of the following is the most appropriate pharmacotherapy?
- (A) Carbonic anhydrase inhibitor
 - (B) Na^+-Cl^- symport inhibitor
 - (C) $\text{Na}^+-\text{K}^+-2\text{Cl}^-$ symport inhibitor
 - (D) Osmotic diuretic
 - (E) Renal epithelial sodium channel inhibitor
38. A 35-year-old man who works at a facility processing highly radioactive substances accidentally receives a high, whole-body dose of ionizing radiation estimated to be 1500 rads (15 gray). He dies 1 week later. At autopsy, histologic examination of the skin shows scattered, individual epidermal cells with shrunken, markedly eosinophilic cytoplasm and pyknotic, fragmented nuclei. These morphologic changes most likely indicate which of the following processes?
- (A) Apoptosis
 - (B) Coagulation necrosis
 - (C) Liquefaction necrosis
 - (D) Mutagenesis
 - (E) Tumor initiation
39. A 52-year-old man comes to the emergency department because he has had vomiting, nausea, and abdominal pain for the past 12 hours. He says he attempted suicide 3 days ago by "taking everything in the medicine cabinet." He was stuporous for approximately 12 hours after the overdose but felt better the following day. At this time, he has jaundice and pain in the right upper quadrant. Which of the following drugs is most likely to have caused the pain, vomiting, and jaundice?
- (A) Acetaminophen
 - (B) Aspirin
 - (C) Cimetidine
 - (D) Diphenhydramine
 - (E) Triazolam
40. A 45-year-old man comes to the physician because of right shoulder pain that began after he chopped wood 2 days ago. Examination of the right upper extremity shows no obvious bone deformities or point tenderness. The pain is reproduced when the patient is asked to externally rotate the shoulder against resistance; there is no weakness. In addition to the teres minor, inflammation of which of the following tendons is most likely in this patient?
- (A) Infraspinatus
 - (B) Pectoralis
 - (C) Subscapularis
 - (D) Supraspinatus
 - (E) Trapezius
41. A 2-year-old girl is brought to the emergency department because of pain in her right forearm after a fall 1 hour ago. She has a history of fractures of the left femur and right tibia. Physical examination shows blue sclerae. There is tenderness to palpation over the distal right radius. A mutation in which of the following genes is the most likely cause of the recurrent fractures in this patient?
- (A) Calcitonin
 - (B) Collagen, type I
 - (C) 1α -Hydroxylase
 - (D) Parathyroid hormone
 - (E) Vitamin D receptor
42. A 55-year-old woman with small cell carcinoma of the lung is admitted to the hospital to undergo chemotherapy. Six days after treatment is started, she develops a temperature of 38°C (100.4°F). Physical examination shows no other abnormalities. Laboratory studies show a leukocyte count of $100/\text{mm}^3$ (5% segmented neutrophils and 95% lymphocytes). Which of the following is the most appropriate pharmacotherapy to increase this patient's leukocyte count?
- (A) Darbepoetin
 - (B) Dexamethasone
 - (C) Filgrastim
 - (D) Interferon alfa
 - (E) Interleukin-2 (IL-2)
 - (F) Leucovorin



43. A 23-year-old man comes to the physician because of a 2-day history of sore throat. Current medications include an inhaled corticosteroid for asthma. His temperature is 37°C (98.6°F). A photograph of the tongue is shown. A KOH preparation of a scraping from one of the plaques shows budding yeast. Which of the following is the most appropriate pharmacotherapy for this patient?
- (A) Amphotericin B
 - (B) Caspofungin
 - (C) Fluconazole
 - (D) Flucytosine
 - (E) Itraconazole
 - (F) Nystatin
 - (G) Voriconazole
-
44. A full-term female newborn is examined shortly after birth. She appears to be small for gestational age, and she has excess skin on the nape of the neck and lymphedema of the hands and feet. Chromosomal analysis shows some cells with a normal 46,XY karyotype and some cells with a 45,X karyotype. Which of the following mechanisms best explains this cytogenetic abnormality?
- (A) Nondisjunction in mitosis
 - (B) Reciprocal translocation
 - (C) Robertsonian translocation
 - (D) Skewed X-inactivation
 - (E) Uniparental disomy
45. A 46-year-old woman receives a non-T-lymphocyte-depleted, allogeneic bone marrow transplant from a matched, unrelated donor. Immunosuppressive therapy with cyclosporine is started. One month later, she has fever. Cytolytic destruction of the skin, gastrointestinal tract, and liver is seen, with associated dermatitis, enteritis, and hepatitis. Which of the following best explains these findings?
- (A) C3b deposition
 - (B) Cytomegalovirus infection
 - (C) Graft-versus-host disease
 - (D) Tolerance induction
 - (E) Type I (immediate) hypersensitivity

46. A 26-year-old man is brought to the emergency department by ambulance 30 minutes after being shot in the leg. He is unconscious and appears markedly pale. His pulse is 120/min, respirations are 16/min, and blood pressure is 80/60 mm Hg. Compared with a healthy adult, which of the following findings is most likely in this patient?

	Arterial Baroreceptor Firing Rate	Systemic Vascular Resistance	Pulmonary Vascular Resistance	Systemic Capillary Fluid Transfer
(A)	↑	↑	↑	filtration
(B)	↑	↓	↑	absorption
(C)	↑	↓	↓	filtration
(D)	↓	↑	↑	absorption
(E)	↓	↑	↓	filtration
(F)	↓	↓	↓	absorption

USMLE STEP1 SAMPLE TEST QUESTIONS

BLOCK 2, ITEMS 47-92

47. A 37-year-old woman has blurred, double vision 8 hours after eating home-preserved peppers. Six hours later, she has dysphagia, dry mouth and eyes, progressive weakness of the arms and legs, and urinary retention. She is awake and alert. Which of the following is the most likely mechanism of these adverse effects?

- (A) Antagonism of muscarinic receptors
- (B) Antagonism of nicotinic receptors
- (C) Inhibition of acetylcholine release
- (D) Inhibition of cholinesterase activity
- (E) Inhibition of G proteins

48. Vascular control is studied in an intact hind extremity of an anesthetized experimental animal. After a normal control period, the blood flow to the extremity is completely occluded for 1 minute. When the occlusion is released, blood flow increases abruptly and exceeds the control value for several minutes (reactive hyperemia). After an appropriate recovery period, the procedure is repeated and the extremity is actively exercised during the occlusion period. Which of the following best describes the reactive hyperemia after the second occlusion compared with that after the first occlusion?

- (A) Abolished
- (B) Decreased but not abolished
- (C) Increased
- (D) Unchanged

49. A 70-year-old man is brought to the emergency department by his wife because of fever and shortness of breath for 2 days. He underwent an oral surgical procedure 6 weeks ago. His respirations are 22/min, and blood pressure is 140/60 mm Hg. A soft diastolic murmur is heard. The diagnosis of bacterial endocarditis is made. Gentamicin therapy is initiated. This patient is at increased risk for developing which of the following as a result of this therapy?

- (A) Cardiac ischemia
- (B) Hearing loss
- (C) Hyperglycemia
- (D) Lung infection
- (E) Torsades de pointes

50. A 26-year-old woman is brought to the emergency department 3 hours after ingesting approximately 50 tablets of aspirin in a suicide attempt. She is nauseated, confused, and sleepy. Her pulse is 130/min, respirations are 30/min, and blood pressure is 100/60 mm Hg. Which of the following sets of laboratory values is most likely on evaluation of blood obtained before treatment?

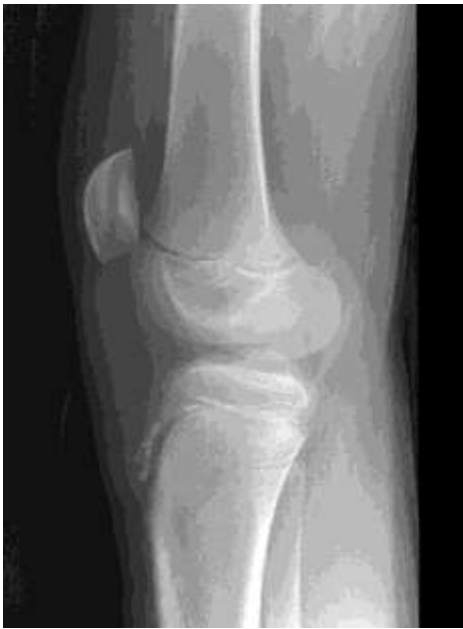	Serum HCO_3^-	Arterial Blood pH	Arterial Blood PCO_2
(A)	↑	↓	↑
(B)	↓	↓	↓
(C)	↑	↑	↓
(D)	↓	↓	↑
(E)	↑	↑	↑

51. A 31-year-old woman comes to the physician because of a 2-week history of malaise, nausea, vomiting, and decreased appetite. She is a known user of intravenous heroin. She appears chronically ill. She is 165 cm (5 ft 5 in) tall and weighs 47 kg (103 lb); BMI is 17 kg/m². Her temperature is 36.7°C (98.1°F), pulse is 90/min, respirations are 18/min, and blood pressure is 114/68 mm Hg. Physical examination shows scleral icterus and a liver span of 16 cm. The spleen is not palpable. Serum studies show:

Total bilirubin	3.2 mg/dL
AST	774 U/L
ALT	820 U/L
HIV antibody	negative
Hepatitis B surface antigen	negative
Hepatitis B surface antibody	positive
Anti-hepatitis B core antibody	positive
Hepatitis B DNA	negative
Anti-hepatitis C virus	positive
Hepatitis C RNA	positive

Which of the following is the most likely outcome of this patient's infection?

- (A) Complete resolution of infection
- (B) Latent infection with intermittent viremia
- (C) Lifelong persistent infection
- (D) Patient death from acute infection

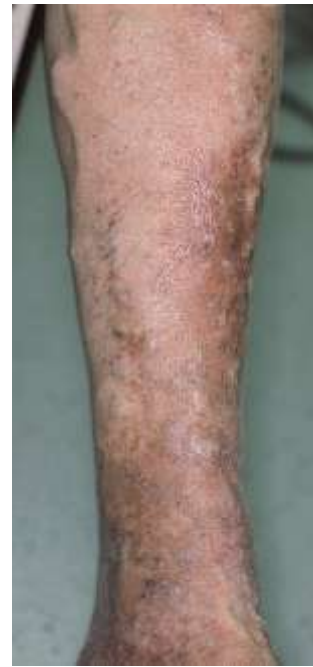

52. A 12-year-old boy is brought to the physician by his mother because of a 1-month history of pain below the left knee. His mother says, "He can usually walk around, but he hasn't been able to play in any of his soccer games since this all began." Examination of the left knee shows warmth, swelling, and tenderness. An x-ray of the knee is shown. Which of the following structures is attached to the abnormal anterior tibial area?

- (A) Anterior cruciate ligament
- (B) Gastrocnemius muscle
- (C) Patellar ligament
- (D) Popliteus muscle
- (E) Posterior cruciate ligament
- (F) Soleus muscle

53. A 31-year-old woman with type 2 diabetes mellitus comes to the physician because of an oozing, foul-smelling wound on her foot for 2 days. Physical examination shows a 4-cm, necrotizing wound with a purplish black discoloration over the heel. Crepitant bullae producing profuse amounts of serous drainage are seen. A Gram stain of a tissue biopsy specimen shows gram-positive rods. The causal organism most likely produces which of the following virulence factors?

- (A) Endotoxin
- (B) Fimbriae
- (C) Pneumolysin
- (D) Polysaccharide capsule
- (E) α -Toxin



54. A 64-year-old man comes to the physician because of swelling in his feet for the past 2 years. He says that his skin is dry and itchy and his feet "feel heavy." One of his legs is shown. Which of the following is the most likely cause of his condition?

- (A) Arteriolar constriction and arteriolar hypertension
- (B) Arteriolar dilation and venous hypertension
- (C) Venous constriction and arteriolar constriction
- (D) Venous hypertension and incompetent valves
- (E) Venous hypertension and venous constriction

55. A 55-year-old man is brought to the emergency department because of shortness of breath and confusion for 4 hours. He has hypertension and chronic kidney disease requiring hemodialysis. An ECG shows low voltage with electrical alternans. Physical examination is most likely to show which of the following findings?

	Blood Pressure (mm Hg)	Pulse (/min)	Jugular Venous Pressure	Pulsus Paradoxus
(A)	85/60	120	increased	increased
(B)	85/60	120	increased	normal
(C)	85/60	120	normal	normal
(D)	120/80	80	increased	increased
(E)	120/80	80	normal	increased
(F)	120/80	80	normal	normal

56. A patient being treated with clindamycin for aspiration pneumonia develops diarrhea. The stool contains a toxin that kills cultured epithelial cells. Stool culture grows an anaerobic gram-positive rod. The same organism is cultured from his bedpan. Which of the following is most likely to sterilize the bedpan?

- (A) Boiling for 45 minutes
- (B) Exposure to benzalkonium chloride for 1 hour
- (C) Exposure to ethyl alcohol for 1 hour
- (D) Exposure to saturated steam (121°C) for 15 minutes
- (E) Heating in an oven at 150°C for 30 minutes

57. A 15-year-old girl who is a ballet dancer has not had a menstrual period for the past 3 months. Menses were previously regular at 29-day intervals. She has lost weight over the past year; her weight is 70% of that expected for her height. She is afebrile and has purpuric lesions on her extremities and trunk. Platelet, absolute neutrophil, and lymphocyte counts are below the reference range. She has macrocytic anemia. The most likely cause of these symptoms is a deficiency of which of the following nutrients?

- (A) Folic acid
- (B) Iron
- (C) Linoleic acid
- (D) Magnesium
- (E) Niacin
- (F) Protein
- (G) Vitamin A
- (H) Vitamin B₆ (pyridoxine)
- (I) Vitamin C
- (J) Vitamin D
- (K) Vitamin E
- (L) Vitamin K
- (M) Zinc

58. An otherwise healthy 26-year-old woman has had petechiae on her legs during the last 24 hours. Laboratory studies show:

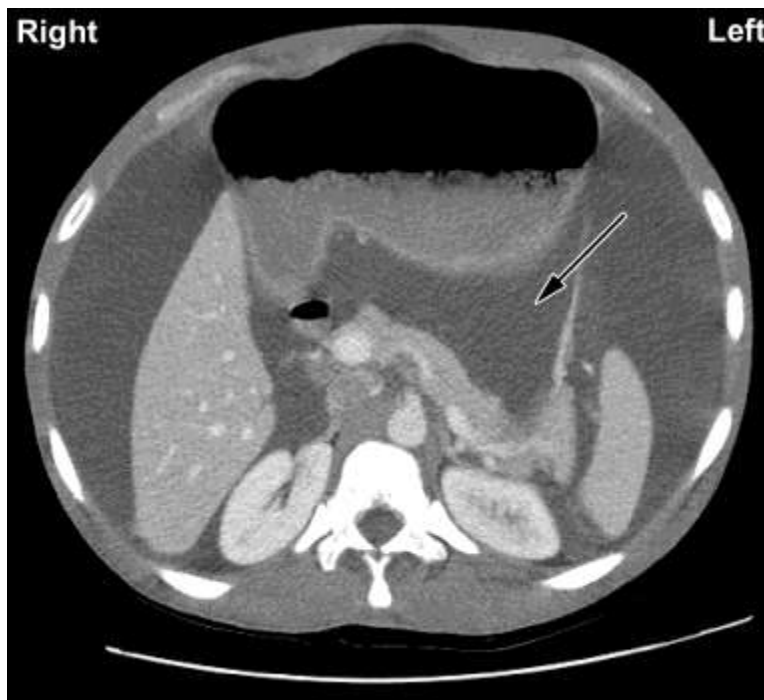
Hemoglobin	13.1 g/dL
Hematocrit	39.7%
Leukocyte count	8500/mm ³
Neutrophils	65%
Lymphocytes	30%
Monocytes	5%
Mean corpuscular volume	82.2 μm ³
Platelet count	20,000/mm ³

A peripheral blood smear shows normal red cell morphology; a bone marrow smear shows mature megakaryocytic hyperplasia. Which of the following is the most likely diagnosis?

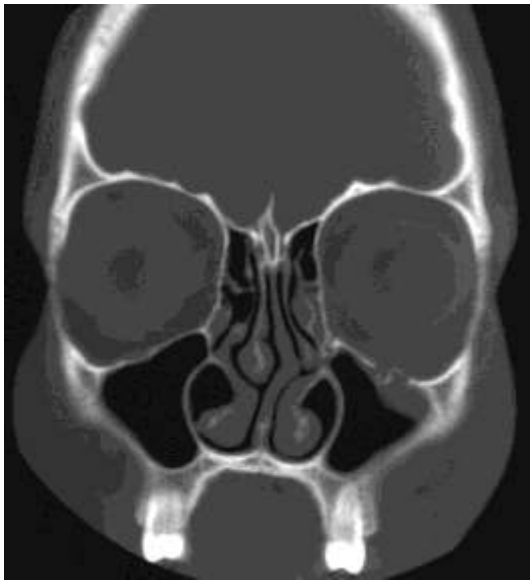- (A) Acute megakaryocytic leukemia
- (B) Acute myelogenous leukemia
- (C) Aplastic anemia
- (D) Immune thrombocytopenic purpura
- (E) Epstein-Barr viral infection
- (F) Papovavirus infection
- (G) Thrombotic thrombocytopenic purpura

59. A 64-year-old man with non-Hodgkin lymphoma comes to the physician because of a 3-week history of progressive numbness in his hands and feet and weakness in his legs when he stands. He received his third course of chemotherapy 4 weeks ago. Physical examination shows areflexia. Which of the following drugs is the most likely cause of these adverse effects?

- (A) Bleomycin
- (B) Cyclophosphamide
- (C) Cytarabine
- (D) Doxorubicin
- (E) Fluorouracil
- (F) Methotrexate
- (G) Vincristine



60. A 36-year-old man with profound intellectual disability is brought to the physician by staff at his facility because of increasing abdominal girth during the past 2 weeks. He is unable to speak, and no medical history is currently available. Physical examination shows a protuberant abdomen with a fluid wave and shifting dullness. There are no signs of trauma to the area. Laboratory studies show no abnormalities. A CT scan of the abdomen is shown. Fluid is present in which of the following areas as indicated by the arrow?
- (A) Epiploic foramen
 - (B) Gastrosplenic ligament
 - (C) Hepatorenal pouch (of Morison)
 - (D) Omental bursa (lesser sac)
 - (E) Sulcus pericolicus
-
61. A 66-year-old man is brought to the emergency department by neighbors 1 hour after the sudden onset of progressive confusion and sleepiness. He had just seen the physician 1 week before, and he appeared cheerful and his usual sharp self until he was found wandering in his neighbor's yard the day of admission. He appears sleepy, but he is arousable. He is oriented to person, but not to place or time. He recalls two of three objects after 5 minutes. He says, "There are so many little people here. What sort of place is this?" He then falls back asleep. Which of the following is the most likely cause of this patient's condition?
- (A) Acute paranoid schizophrenia
 - (B) Arsenic poisoning
 - (C) Dementia, Alzheimer type
 - (D) New medication regimen
 - (E) Tertiary syphilis
62. A 30-year-old man is brought to the emergency department 30 minutes after being stung by several wasps. He is confused and has difficulty breathing. His temperature is 38°C (100.4°F), pulse is 122/min, respirations are 34/min, and blood pressure is 80/40 mm Hg. Physical examination shows dry skin and decreased capillary refill. There are multiple erythematous, inflamed marks on the back and 1+ pitting edema of the ankles. In addition to the administration of 0.9% saline, the most appropriate next step in management is administration of which of the following?
- (A) Atropine
 - (B) Captopril
 - (C) Epinephrine
 - (D) Losartan
 - (E) Methacholine
 - (F) Whole blood



63. A 42-year-old woman is brought to the emergency department because of double vision that began 20 minutes after she fell from her horse and landed on the left side of her face. Examination of the face shows ecchymoses over the left zygomatic arch. A CT scan of the head is shown. Which of the following arteries is at greatest risk for injury in this patient?

- (A) Facial
- (B) Frontal
- (C) Infraorbital
- (D) Lacrimal
- (E) Ophthalmic

64. Over 1 year, a study is conducted to assess the antileukemic activity of a new tyrosine kinase inhibitor in patients with chronic myeloid leukemia in blast crisis. All patients enrolled in the study are informed that they would be treated with the tyrosine kinase inhibitor. They are assigned to successive dose cohorts of 300 to 1000 mg/day of the drug. Six to eight patients are assigned to each dose. Treatment efficacy is determined based on the results of complete blood counts and bone marrow assessments conducted regularly throughout the study. This study is best described as which of the following?

- (A) Case-control study
- (B) Crossover study
- (C) Open-labeled clinical trial
- (D) Randomized clinical trial
- (E) Single-blind, randomized, controlled trial

65. A previously healthy 19-year-old woman comes to the physician because of a 3-day history of fever, fatigue, and sore throat. She lives with a roommate who has a cat. Her temperature is 37.8°C (100°F). Physical examination shows mildly tender cervical and submental adenopathy and pharyngitis. There is mild splenomegaly. Laboratory studies show:

Hemoglobin	13.3 g/dL
Hematocrit	43%
Leukocyte count	12,500/mm ³
Platelet count	250,000/mm ³
Heterophile antibody titer	positive

The most likely cause of this patient's condition is infection with which of the following?

- (A) *Bartonella henselae*
- (B) Cytomegalovirus
- (C) Epstein-Barr virus
- (D) Rhinovirus
- (E) *Toxoplasma gondii*

66. A previously healthy 3-month-old boy is brought to the physician because of a runny nose and a dry cough for 2 days. Physical examination shows tachypnea, a nasal discharge, and wheezing. An x-ray of the chest shows hyperexpansion but no infiltrates. The causal virus was most likely transmitted by which of the following routes?

- (A) Blood transfusion
- (B) Ingestion of contaminated formula
- (C) Inoculation onto mucous membranes
- (D) Insect bite
- (E) Transplacental transfer

67. Six healthy subjects participate in a study of muscle metabolism during which hyperglycemia and hyperinsulinemia is induced. Muscle biopsy specimens obtained from the subjects during the resting state show significantly increased concentrations of malonyl-CoA. The increased malonyl-CoA concentration most likely directly inhibits which of the following processes in these subjects?

- (A) Fatty acid oxidation
- (B) Fatty acid synthesis
- (C) Gluconeogenesis
- (D) Glycogenolysis
- (E) Glycolysis
- (F) Oxidative phosphorylation

68. A 6-year-old boy is brought to the physician by his parents because of a 3-day history of fever, headache, and cough productive of a green, foul-smelling discharge that also exits from his nose. He has had repeated episodes of similar symptoms during the past 4 years. He appears pale and lethargic. His height and weight are both below the 10th percentile. Coarse rhonchi are heard bilaterally. An x-ray of the chest shows scattered peripheral opacities, dilated and thickened airways consistent with bronchiectasis, and a cardiac apex that is directed toward the right. The most likely cause of his recurrent infections is a dysfunction of which of the following cell types?
- (A) Alveolar capillary endothelial cell
 - (B) Alveolar macrophage
 - (C) Chondrocyte
 - (D) Ciliated columnar epithelial cell
 - (E) Clara cell
 - (F) Goblet cell
 - (G) Kulchitsky cell
 - (H) Squamous epithelial cell
 - (I) Type I pneumocyte
 - (J) Type II pneumocyte
69. A 23-year-old woman has a progressive increase in her serum β -human chorionic gonadotropin (β -hCG) concentrations during an 8-week period. A hydatidiform mole is removed, but the β -hCG concentration continues to increase. Which of the following is the most likely diagnosis?
- (A) Adrenal adenoma
 - (B) Choriocarcinoma
 - (C) Ectopic pregnancy
 - (D) Pituitary insufficiency
 - (E) A second noninvasive mole
70. A 45-year-old man has abnormal circadian variation in body temperature, disruption of the sleep-wake cycle, and an impaired nocturnal surge of secretion of melatonin. An MRI of the brain is most likely to show a lesion involving which of the following nuclei?
- (A) Accessory optic
 - (B) Lateral preoptic
 - (C) Pretectal
 - (D) Suprachiasmatic
 - (E) Supraoptic
71. A 75-year-old woman has increasing shortness of breath on exertion. Findings on physical examination are unremarkable. X-rays of the chest show no abnormalities of the heart or lungs. Pertinent laboratory findings include:
- | | |
|-------------------------|--------------------|
| Hematocrit | 28% |
| Hemoglobin | 9 g/dL |
| Mean corpuscular volume | 70 μm^3 |
- Which of the following is the most likely basis for these findings?
- (A) Acquired hemolytic anemia
 - (B) Chronic blood loss
 - (C) Folic acid deficiency
 - (D) β -Thalassemia minor
 - (E) Pernicious anemia
72. A 42-year-old woman is brought to the emergency department 4 hours after the onset of severe shortness of breath. She has no recent history of trauma, hospital admission, or operations. She had an episode of deep venous thrombosis 10 years ago that required treatment in the hospital. Her respirations are 34/min. Pulse oximetry on room air shows an oxygen saturation of 65%. A helical CT scan shows a large filling defect in the right pulmonary artery. Which of the following hypercoagulability disorders is the most likely underlying cause of these findings?
- (A) Antiplatelet antibody syndrome
 - (B) Antithrombin III deficiency
 - (C) Factor V Leiden mutation
 - (D) Protein C deficiency
 - (E) Protein S deficiency
73. A 12-year-old girl is admitted to the hospital because of marked shortness of breath, an erythematous rash, and painful, swollen hip and knee joints. She is agitated. A chest x-ray shows an enlarged heart and changes consistent with pulmonary edema. Intractable congestive heart failure develops, and she dies on the second hospital day. This child most likely had a recent history of which of the following?
- (A) Cyanosis with chest pain
 - (B) Jaundice
 - (C) Meningitis
 - (D) Pharyngitis
 - (E) Skin infection

74. A population-based, case-control study is conducted to assess whether there is an association between statin use and incidence of colorectal cancer. A total of 900 participants are enrolled: 400 patients who were diagnosed with colorectal cancer between 1998 and 2004, and 500 healthy participants matched for age, sex, and ethnicity. A structured interview is used to determine statin use in the two groups. Results are shown:

Statin Use		Colon Cancer		Total
		Present	Absent	
	Positive	100	200	300
	Negative	300	300	600
	Total	400	500	900

Which of the following is the estimated odds ratio of colon cancer in statin-treated patients compared with patients with no statin treatment?

- (A) -1.0
- (B) -0.5
- (C) 0
- (D) 0.5
- (E) 0.67
- (F) 0.75
- (G) 1.3
- (H) 2

75. A 5-year-old child with short stature is being evaluated for delayed dentition and excessive caries. Examination of the chest shows pectus carinatum and bead-like enlargement of the costochondral junctions. Which of the following findings is most likely on histologic examination of a section of bone?

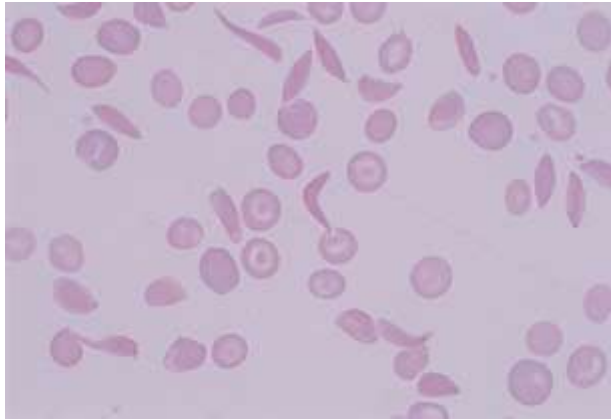
- (A) Absence of cartilage in the epiphyseal plates
- (B) Absence of osteoblasts
- (C) Enlarged osteoclasts with an increased number of nuclei
- (D) Increased proportions of osteoid

76. A 12-year-old boy is brought to the physician by his father because of redness and swelling of his left foot for 24 hours. Three days ago, the boy scraped his foot while wading in a drainage ditch. Examination of the left foot shows a purulent abrasion with edema, erythema, and tenderness on the lateral side. Infection is most likely to next spread from the lateral side of the foot to the regional lymph nodes in which of the following areas?

- (A) Lateral surface of the thigh
- (B) Medial malleolus, posteriorly
- (C) Popliteal fossa
- (D) Sole of the foot
- (E) Superficial inguinal area

77. A 52-year-old man with recently diagnosed type 2 diabetes mellitus comes to the physician for a follow-up examination. Physical examination shows no abnormalities. Laboratory studies show an increased hemoglobin A_{1c} despite patient compliance with diet and exercise recommendations. Treatment with a sulfonylurea is started. Which of the following is most likely to occur in this patient?

- (A) Decreased entry of glucose into the muscle cells
- (B) Decreased production of glucose from the liver
- (C) Decreased secretion of insulin from the pancreas
- (D) Decreased speed of carbohydrate absorption from the intestines
- (E) Increased entry of glucose into the muscle cells
- (F) Increased production of glucose from the liver
- (G) Increased secretion of insulin from the pancreas
- (H) Increased speed of carbohydrate absorption from the intestines



78. A 2-year-old boy is brought to the emergency department because of shortness of breath and left-sided abdominal pain for 3 hours. He appears pale. Physical examination shows hypotension and tachycardia. There is splenomegaly with the spleen tip palpated 8 cm below the left costal margin. Laboratory studies show:

Hemoglobin	5.1 g/dL (N=12.1–14.9)
Hematocrit	16% (N=37%–44.4%)
Leukocyte count	4500/mm ³ (N=4000–11,500)
Platelet count	87,000/mm ³ (N=150,000–400,000)

A photomicrograph of a Wright-stained peripheral blood smear is shown. Which of the following is the most likely cause of this patient's current condition?

- (A) Aplastic crisis
- (B) Autoimmune hemolysis
- (C) Congestive heart failure
- (D) Salmonella sepsis
- (E) Splenic sequestration

79. A 73-year-old woman comes to the physician because of a 2-month history of diffuse weakness and tingling of her arms and legs. Neurologic examination shows weakness of the extensor and flexor muscles of the lower extremities. Knee and ankle deep tendon reflexes are exaggerated. Sensation to vibration and position is decreased in all extremities, but the decrease is more prominent in the lower extremities than in the upper extremities. This patient most likely has a deficiency of which of the following vitamins?

- (A) Niacin
- (B) Vitamin B₁ (thiamine)
- (C) Vitamin B₂ (riboflavin)
- (D) Vitamin B₆ (pyridoxine)
- (E) Vitamin B₁₂ (cyanocobalamin)

80. In a cohort study of elderly women, the relative risk ratio for hip fractures among those who exercise regularly is 1.2 (95% confidence interval of 1.1 to 1.8). Which of the following is the most appropriate conclusion about the effect of regular exercise on the risk for hip fracture?

- (A) Statistically nonsignificant increase in risk
- (B) Statistically nonsignificant overall decrease in risk
- (C) Statistically significant overall decrease in risk
- (D) Statistically significant overall increase in risk

81. A 32-year-old man with non-Hodgkin lymphoma comes to the physician 6 days after finishing the initial chemotherapy regimen. His leukocyte count is $1600/\text{mm}^3$, indicating greater bone marrow suppression than expected. When questioned, the patient says that he has been taking Madagascar periwinkle as an herbal remedy for his condition. He obtains this substance from an herbalist. Which of the following is the most appropriate response by the physician?
- (A) Ask the patient to stop using the herbal supplement because supplements are generally ineffective
 - (B) Continue the patient's chemotherapy
 - (C) Explain the adverse effects this herbal supplement has on the patient's treatment
 - (D) Report the herbalist to the Food and Drug Administration
 - (E) Suggest that the patient take daily multivitamin and protein supplements in addition to the herbal supplement
82. A 16-year-old girl has hirsutism, deepening of the voice, and cessation of menses. She swims in competitions. Which of the following drugs is most likely to have caused these findings?
- (A) Ethinyl estradiol
 - (B) Leuprolide
 - (C) Medroxyprogesterone
 - (D) Nandrolone
 - (E) Tamoxifen
83. A 55-year-old man comes to the physician because of a 2-week history of recurrent, widespread blister formation. Physical examination shows lesions that are most numerous in the flexural areas including the axillae and groin. The blisters do not break easily, and there are no oral lesions. These blisters are most likely the result of adhesion failure involving which of the following?
- (A) Basement membrane
 - (B) Dermal papillae
 - (C) Langerhans cells
 - (D) Melanocytes
 - (E) Merkel cells
84. A study is designed to evaluate the feasibility of acupuncture in children with chronic headaches. Sixty children with chronic headaches are recruited for the study. In addition to their usual therapy, all children are treated with acupuncture three times a week for 2 months. Which of the following best describes this study design?
- (A) Case-control
 - (B) Case series
 - (C) Crossover
 - (D) Cross-sectional
 - (E) Historical cohort
 - (F) Randomized clinical trial
85. A 33-year-old woman comes to the physician 2 days after the result of a home pregnancy test was positive. The result of a serum pregnancy test in the office is positive. She tells the physician that she enjoys seafood, but she has heard that some types "can be bad for the baby." It is most appropriate for the physician to recommend that the patient avoid which of the following species of fish during her pregnancy?
- (A) Catfish
 - (B) Cod
 - (C) Salmon
 - (D) Swordfish
 - (E) Tilapia
86. A 16-year-old boy is admitted to the emergency department because of a knife wound to the left side of his chest. An x-ray of the chest shows an air-fluid level in the left side of the chest, partial collapse of the left lung, and elevation of the stomach bubble. The mediastinum is in the midline. Which of the following is the most likely diagnosis?
- (A) Hemopneumothorax, not under tension
 - (B) Hemothorax, not under tension
 - (C) Pneumothorax, not under tension
 - (D) Tension hemopneumothorax
 - (E) Tension hemothorax
 - (F) Tension pneumothorax

87. A 45-year-old woman has a 6-month history of progressive shortness of breath on exertion. She does not smoke. Pulmonary function findings are shown (values are given as % of predicted normal):

Vital capacity	60
Forced expiratory volume in 1 second (FEV ₁)	70
Diffusing capacity for carbon monoxide	50
Maximum voluntary ventilation	60

Which of the following most likely explains her limited ability to increase ventilation?

- (A) Airway obstruction
 - (B) Decreased activation of pulmonary juxtacapillary (J) receptors
 - (C) Decreased lung compliance
 - (D) Depression of central chemoreceptors
 - (E) Depression of peripheral chemoreceptors
-

88. A 74-year-old man with urinary frequency and urgency has benign prostatic hyperplasia. He refuses operative intervention but agrees to a trial of finasteride therapy. During the trial, synthesis of which of the following substances is most likely to be inhibited?

- (A) Androstenedione
- (B) Dihydrotestosterone
- (C) Estradiol
- (D) Estrone
- (E) Testosterone

89. A 30-year-old man with peptic ulcer disease suddenly develops pain, redness, and swelling of his right first metatarsophalangeal joint. There is no history of injury. Serum uric acid concentration is 8 mg/dL. Examination of joint aspirate shows birefringent crystals. Which of the following drugs is most appropriate to treat the acute symptoms in this patient?

- (A) Allopurinol
- (B) Colchicine
- (C) Morphine
- (D) Probenecid
- (E) Sulfinpyrazone

90. A 55-year-old man who is a business executive is admitted to the hospital for evaluation of abdominal pain. He is polite to the physician but berates the nurses and other staff. The patient's wife and two of his three adult children arrive for a visit. The patient says with disgust that the missing child is and always has been worthless. Which of the following is the most likely explanation for this patient's behavior?

- (A) Countertransference
- (B) Projection
- (C) Projective identification
- (D) Reaction formation
- (E) Splitting

91. A 14-year-old girl is brought to the physician by her mother because of a 2-month history of heavy vaginal bleeding during menstrual periods. She has had episodes of excessive periodontal bleeding while brushing her teeth and easy bruising for 6 years. She also had an episode of extended bleeding after a tooth extraction 4 years ago. Her mother and brother have had similar symptoms. Physical examination shows patchy ecchymoses over the upper and lower extremities. Laboratory studies show:

Platelet count	234,000/mm ³
Bleeding time	17 min
Prothrombin time	12 sec (INR=1)
Partial thromboplastin time	46 sec

Which of the following is the most likely diagnosis?

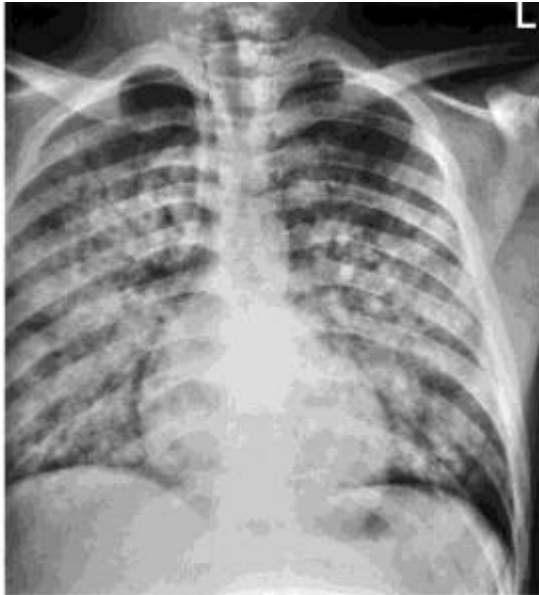- (A) Factor VII (proconvertin) deficiency
 - (B) Factor X (Stuart factor) deficiency
 - (C) Factor XII (Hageman factor) deficiency
 - (D) Hemophilia A
 - (E) Vitamin K deficiency
 - (F) von Willebrand disease
92. A previously healthy 40-year-old man is brought to the emergency department because of constant substernal chest pain for 12 hours that is exacerbated by coughing and inspiration. The pain is relieved with sitting up and leaning forward. There is no family history of heart disease. His temperature is 38°C (100.4°F), pulse is 120/min, and blood pressure is 110/60 mm Hg. The lungs are clear to auscultation. Cardiac examination shows distant heart sounds. An ECG shows diffuse ST-segment elevation in all leads. An x-ray of the chest shows normal findings. The most likely cause of his condition is injury to which of the following tissues?
- (A) Aortic intima
 - (B) Esophageal sphincter
 - (C) Myocardium
 - (D) Pericardium
 - (E) Pleura

USMLE STEP1 SAMPLE TEST QUESTIONS

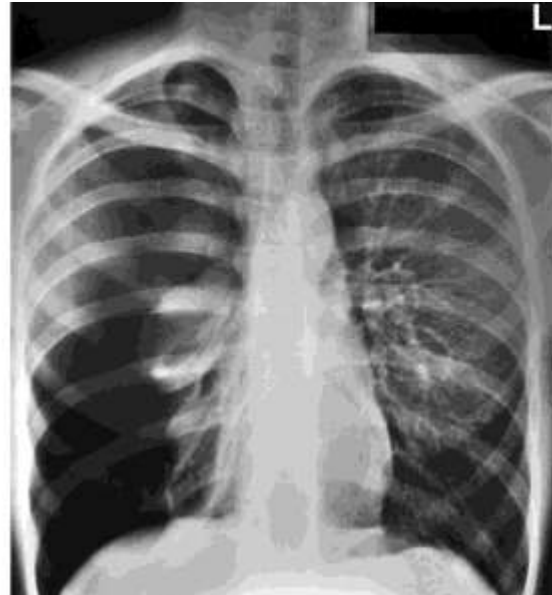BLOCK 3, ITEMS 93-138

93. A 17-year-old boy comes to the emergency department because of severe thirst and weakness and a 4-kg (8.8-lb) weight loss over the past 36 hours. He began having voluminous painless watery diarrhea on the airplane while returning from a trip to Thailand 36 hours ago. He has not vomited. While supine, pulse is 110/min and blood pressure is 110/60 mm Hg. While standing, pulse is 170/min and blood pressure is 70/40 mm Hg. His abdomen is nontender and bowel sounds are increased. Which of the following treatments is most appropriate at this time?
- (A) Ciprofloxacin
 - (B) Doxycycline
 - (C) Exploratory laparotomy
 - (D) Potassium chloride
 - (E) Rehydration
 - (F) Trimethoprim-sulfamethoxazole
94. A 22-year-old man comes to the emergency department because of the recent onset of torticollis and uncontrollable facial grimacing. He began therapy with a new drug 24 hours ago. Which of the following drugs is the most likely cause?
- (A) Amitriptyline
 - (B) Diazepam
 - (C) Fluoxetine
 - (D) Haloperidol
 - (E) Levodopa
95. A 66-year-old man has become increasingly short-tempered with his wife. He has diarrhea, weight loss, and weakness in the proximal muscles. He has atrial fibrillation and tachycardia. Which of the following is the most likely diagnosis?
- (A) Congestive heart failure
 - (B) Cushing syndrome
 - (C) Hyperthyroidism
 - (D) Mitral valve prolapse
 - (E) Pheochromocytoma
96. After being severely beaten and sustaining a gunshot wound to the abdomen, a 42-year-old woman undergoes resection of a perforated small bowel. During the operation, plastic reconstruction of facial fractures, and open reduction and internal fixation of the left femur are also done. Thirty-six hours postoperatively, she is awake but not completely alert. She is receiving intravenous morphine via a patient-controlled pump. She says that she needs the morphine to treat her pain, but she is worried that she is becoming addicted. She has no history of substance use disorder. She drinks one to two glasses of wine weekly. Which of the following initial actions by the physician is most appropriate?
- (A) Reassure the patient that her chance of becoming addicted to narcotics is minuscule
 - (B) Maintain the morphine, but periodically administer intravenous naloxone
 - (C) Switch the patient to oral acetaminophen as soon as she can take medication orally
 - (D) Switch the patient to intramuscular lorazepam
 - (E) Switch the patient to intravenous phenobarbital
97. A 49-year-old woman is found to have mild proteinuria and pyuria on routine screening. Urine specific gravity is 1.000. Culture of the urine grows no organisms. She has taken large doses of combination over-the-counter analgesic preparations for 10 years due to a low back injury. Which of the following renal abnormalities is most likely in this patient?
- (A) Acquired cystic disease
 - (B) Acute glomerulonephritis
 - (C) Hyperplastic arteriolitis
 - (D) Nephrolithiasis
 - (E) Papillary necrosis

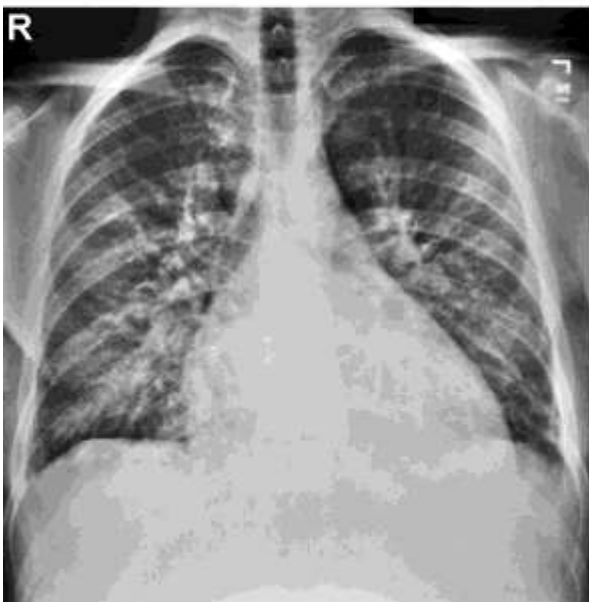98. A previously healthy 26-year-old patient develops shortness of breath over several hours during a mountain climb at 5000 m (16,404 ft). There is no history of trauma. On examination, the point of cardiac apical impulse is not displaced and there are widespread crackles throughout both lung fields. Which of the following x-rays of the chest shown best represents this patient?



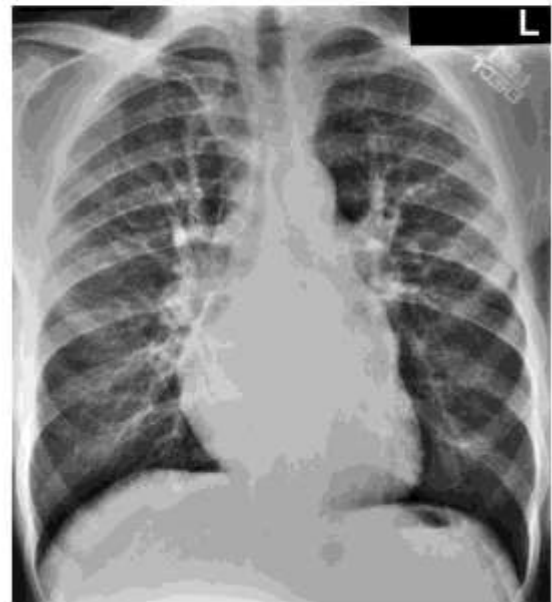A



B



C



D

The genetic code

First position (5' end)	Second position				Third position (3' end)
	U	C	A	G	
U	Phe	Ser	Tyr	Cys	U C A G
	Phe	Ser	Tyr	Cys	
	Leu	Ser	Stop	Stop	
	Leu	Ser	Stop	Trp	
C	Leu	Pro	His	Arg	U C A G
	Leu	Pro	His	Arg	
	Leu	Pro	Gln	Arg	
	Leu	Pro	Gln	Arg	
A	Ile	Thr	Asn	Ser	U C A G
	Ile	Thr	Asn	Ser	
	Ile	Thr	Lys	Arg	
	Met	Thr	Lys	Arg	
G	Val	Ala	Asp	Gly	U C A G
	Val	Ala	Asp	Gly	
	Val	Ala	Glu	Gly	
	Val	Ala	Glu	Gly	

99. During an experiment, an investigator finds a point mutation (CGG→TGG) in the gene encoding the protein kinase regulatory subunit. The genetic code is shown in the figure. This mutation is most likely to alter the amino acid sequence with which of the following changes?

(A) Arg→Trp
 (B) Gly→Arg
 (C) Gly→Trp
 (D) Thr→Gly
 (E) Trp→Arg

100. A 6-day-old breast-fed boy is brought to the emergency department by his mother because of poor weight gain and irritability since delivery, and a 2-hour history of vomiting. Physical examination shows jaundice and hepatomegaly. A reducing substance test result of the urine is positive, and a glucose oxidase test result is negative. The concentration of which of the following metabolites in liver is most likely increased in this patient?

(A) Fructose 1,6-bisphosphate
 (B) Galactose 1-phosphate
 (C) Glucose 1-phosphate
 (D) Glucose 6-phosphate

101. A 35-year-old man comes to the physician because of pain and swelling of his right arm where he scraped it on a tree branch 2 days ago. His temperature is 38.3°C (101°F). Examination of the right forearm shows edema around a fluctuant erythematous lesion at the site of trauma. The area is extremely tender to palpation. Which of the following is most likely the primary mechanism of the development of edema in this patient?

(A) Degranulation of eosinophils
 (B) Disruption of vascular basement membranes
 (C) Increased hydrostatic pressure
 (D) Release of thromboxane
 (E) Separation of endothelial junctions

102. A 72-year-old man collapses while playing golf. He has a 5-year history of angina and type 2 diabetes mellitus. Paramedics arrive in 10 minutes. Examination shows no respirations or blood pressure; an ECG shows asystole. Cardiopulmonary resuscitation is attempted for 10 minutes without success. Which of the following is the most likely cause of death in this patient?

(A) Cardiac tamponade
 (B) Embolus to the right middle cerebral artery
 (C) Necrosis of the myocardium
 (D) Rupture of the papillary muscle
 (E) Ventricular fibrillation

103. A 60-year-old woman with reflux esophagitis comes to the physician for a follow-up examination. She has been undergoing proton-pump inhibitor therapy for the past month and shows clinical improvement. Upper endoscopy is done. A biopsy specimen of the stomach is most likely to show which of the following?

(A) Acute inflammation
 (B) Gastric atrophy
 (C) Intramucosal smooth muscle
 (D) Lymphoid nodules
 (E) Parietal cell hyperplasia

104. A 40-year-old woman receives an intravenous infusion of drug X that selectively constricts the efferent arterioles in her kidneys. Following the infusion, total cardiac output and renal afferent arteriolar tone are unchanged, but renal efferent arteriolar tone and total renal vascular resistance have both increased. Which of the following sets of changes most likely occurred following the infusion of drug X?

	Glomerular Filtration Rate	Filtration Fraction	Renal Blood Flow
(A)	↓	↓	↑
(B)	↓	↑	↓
(C)	↓	↑	↔
(D)	↑	↓	↔
(E)	↑	↑	↓

105. A 28-year-old woman comes to the physician because of a 6-month history of intermittent feelings of progressive overwhelming fear and apprehension, restlessness, and palpitations. She says that she often feels tense, and she has difficulty concentrating because she is unable to stop thinking about the things that worry her. Physical examination shows no abnormalities. A selective serotonin reuptake inhibitor (SSRI) is prescribed for long-term management. Which of the following is most appropriate to provide immediate relief for this patient until the effects of the SSRI treatment occur?

- (A) Alprazolam
- (B) Amitriptyline
- (C) Diphenhydramine
- (D) Haloperidol
- (E) Phenobarbital
- (F) Tramadol

106. A healthy 28-year-old woman comes to the physician for advice on losing weight. She is 150 cm (4 ft 11 in) tall and weighs 56 kg (124 lb); BMI is 25 kg/m². Physical examination shows no other abnormalities. The physician recommends a diet that will restrict her daily intake by 500 kilocalories. Which of the following processes is most likely to increase in this patient as a result of following this diet?

- (A) Adipocyte glucose uptake
- (B) Cerebral ketone utilization
- (C) Hepatic lipid oxidation
- (D) Muscle glucose uptake
- (E) Resting energy expenditure

107. A 25-year-old woman has a routine, pre-employment physical examination. Laboratory studies include:

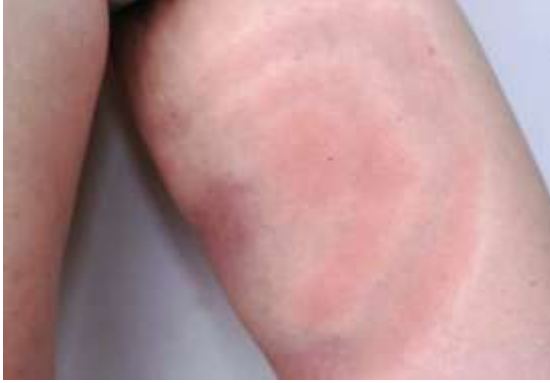Hemoglobin	11.3 g/dL
Hematocrit	34%
Erythrocyte count	5.2 million/mm ³
Mean corpuscular volume	65 μm ³

Follow-up laboratory studies show that the serum iron concentration and iron-binding capacity are within the reference ranges. Hemoglobin electrophoresis shows increased hemoglobin A₂ (5%). Which of the following is the most likely diagnosis?

- (A) Anemia of chronic disease
- (B) Iron deficiency anemia
- (C) Sideroblastic anemia
- (D) α-Thalassemia minor
- (E) β-Thalassemia minor

108. An 18-year-old woman comes to the physician for a health maintenance examination. She has not had major medical illnesses. She takes no medications. She does not smoke cigarettes, drink alcohol, or use illicit drugs. Physical examination shows diffuse brownish yellow discoloration of all teeth. Which of the following most likely occurred during childhood to cause this finding?

- (A) Amelogenesis imperfecta
- (B) Dentinogenesis imperfecta
- (C) Rh incompatibility
- (D) Syphilis
- (E) Tetracycline use
- (F) Vitamin D deficiency

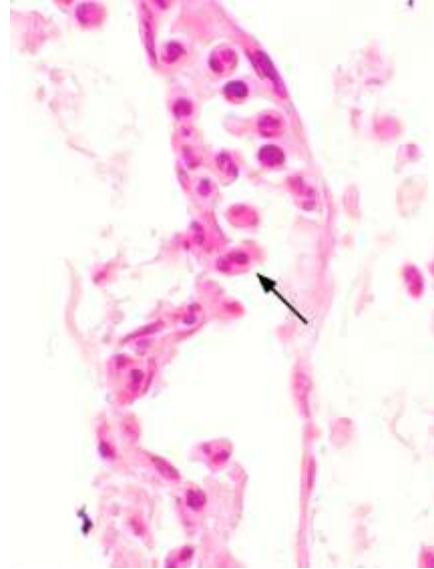


109. A 16-year-old boy comes to the physician because of a rash on his left inner thigh that first appeared 2 days after he returned from a hunting trip with friends in Minnesota. A photograph of the rash is shown. Without treatment, this patient is at increased risk for which of the following?

- (A) Carditis
- (B) Glomerulonephritis
- (C) Hepatitis
- (D) Pancreatitis
- (E) Thrombocytopenia

110. A 37-year-old woman comes to the physician because of a 2-month history of pain with movement of her hands and feet. Physical examination shows warmth and swelling of the metacarpophalangeal and metatarsophalangeal joints. Laboratory studies show increased titers of antibodies to Fc component of IgG and a negative antinuclear antibody test result. A drug is prescribed that binds to tumor necrosis factor- α (TNF- α) and blocks its interaction with cell-surface TNF receptors. Her symptoms improve within 1 month. She is most likely receiving treatment with which of the following drugs?

- (A) Adalimumab
- (B) Anakinra
- (C) Gold
- (D) Methotrexate
- (E) Prednisone



111. A 63-year-old homeless man is brought to the emergency department 1 hour after police found him unresponsive. His respirations are 30/min. Crackles are heard over the left upper and the entire right lung fields. Despite appropriate lifesaving measures, he dies. A photomicrograph of a section of the right lung obtained at autopsy is shown. Which of the following mediators is the most likely cause of the position of the cell indicated by the arrow?

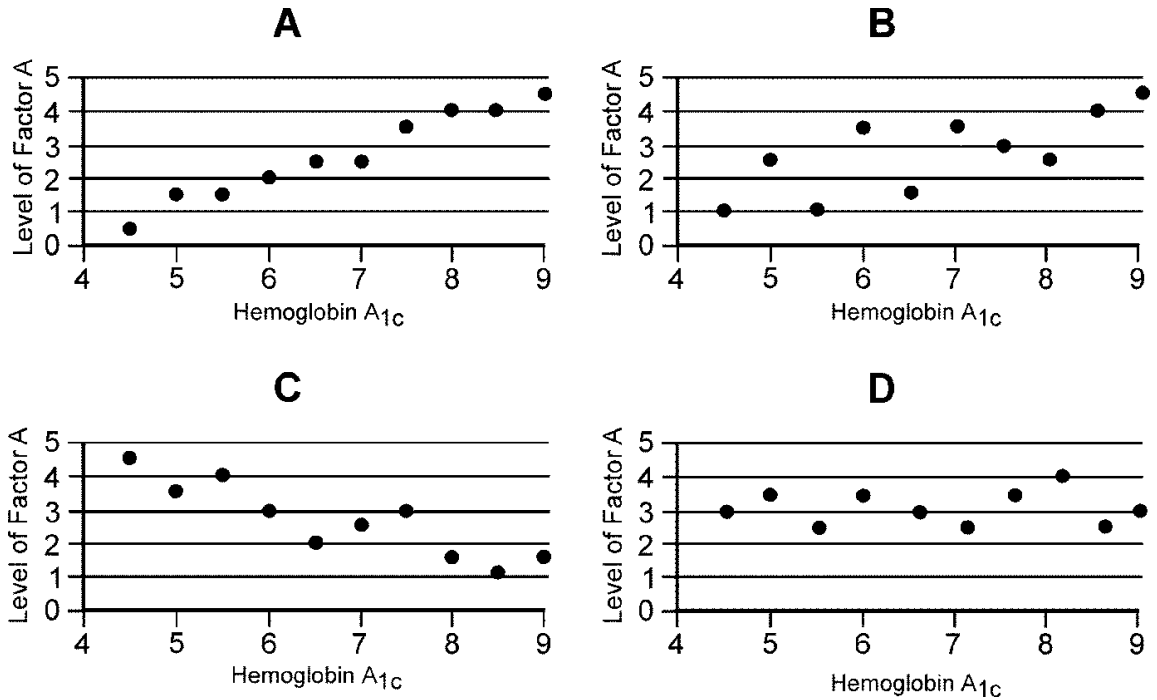
- (A) Bradykinin
- (B) C5a
- (C) Histamine
- (D) Nitrous oxide
- (E) Prostaglandins

112. A 48-year-old man with AIDS has chorioretinitis with flame-shaped hemorrhages and large white patches. Three weeks after starting therapy, his vision is improved, but he has granulocytopenia. Which of the following antiviral agents is most likely responsible for these findings?

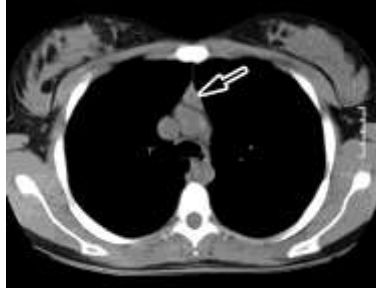- (A) Amantadine
- (B) Foscarnet
- (C) Ganciclovir
- (D) Lamivudine (3TC)
- (E) Ribavirin

113. A 30-year-old woman, gravida 3, para 3, comes to the physician because of a 2-month history of loss of urine when she sneezes or laughs. Her three children were all delivered vaginally at term. Physical examination shows no abnormalities. Which of the following nerve roots supplies the muscle group that is weakened in this patient?
- (A) C1-2
 - (B) L1-2
 - (C) L4-5
 - (D) S1-2
 - (E) S3-4
114. A 36-year-old woman has been trying to conceive for the past 2 years. Her menses occur every 19 to 45 days. She has a past history of some type of sexually transmitted disease, but says she was treated and cured. She is 163 cm (5 ft 4 in) tall and weighs 109 kg (240 lb); BMI is 41 kg/m². Physical examination including a pelvic examination is unremarkable. An endometrial biopsy is performed based on the menstrual history and a negative pregnancy test. The biopsy shows stromal breakdown associated with proliferative glands. Which of the following is the most likely cause of her infertility?
- (A) Anovulation
 - (B) Chronic endometritis
 - (C) Endometrial polyps
 - (D) Endometriosis
 - (E) Leiomyomata
115. A 1-day-old newborn is evaluated for possible sepsis. Blood cultures grow gram-positive cocci in pairs and chains that agglutinate with group B antiserum. The most likely epidemiologic risk factor for this infection involves bacterial colonization of which of the following?
- (A) Mother's vagina
 - (B) Newborn's gastrointestinal tract
 - (C) Newborn's nasopharynx
 - (D) Placenta
 - (E) Umbilical cord remnant
116. A 26-year-old woman is brought to the emergency department by her mother 1 hour after she had a generalized tonic-clonic seizure at home. The mother states that her daughter has been talking to herself at all hours of the day and night about being thirsty. The patient was found to have schizophrenia 6 years ago. Her only medication is haloperidol. She was admitted to the hospital twice in the past year for psychotic episodes. Physical examination shows no other abnormalities. She is oriented to person but not to place or time. Her serum sodium concentration is 114 mEq/L on arrival but returns to normal with appropriate treatment. Which of the following interventions is the most appropriate next step?
- (A) Refer the patient for behavior therapy
 - (B) Restrict the patient's fluid intake
 - (C) Add lithium carbonate to the medication regimen
 - (D) Administer furosemide therapy
 - (E) Begin mineralocorticoid therapy
117. A 29-year-old man is brought to the physician for removal of a cast from his left leg. He sustained a fracture of the left lower extremity 6 weeks ago and was immobilized in a cast that extended from just below the knee to the foot. At the time of injury, there was severe pain but normal strength in the extremity. When the cast is removed today, physical examination shows a pronounced left footdrop with paresthesia and sensory loss over the dorsum of the left foot and lateral leg. Injury to which of the following nerves is the most likely cause of this patient's condition?
- (A) Common fibular (peroneal)
 - (B) Femoral
 - (C) Obturator
 - (D) Sciatic
 - (E) Tibial

118. An investigator is studying the effect of the number of hours watching television (Factor A) on the percent of hemoglobin A_{1c} in people with type 2 diabetes mellitus. Two different variables, Factor A and hemoglobin A_{1c}, are compared. The results of the study indicate a correlation coefficient of +0.9. Which of the following graphs shown best corresponds to these results?



119. A 24-year-old woman comes to the physician for a follow-up examination. One week ago, she was treated in the emergency department after she accidentally spilled hot grease on her left leg while working at a fast-food restaurant. Examination of the left lower extremity shows a 7-cm, pink, soft, granular, edematous wound. The formation of this tissue was most likely caused by increased activity of which of the following?
- (A) Complement C3b
 - (B) Glycosylation-dependent cell adhesion molecule-1
 - (C) P-selectin
 - (D) Stromelysin
 - (E) Vascular endothelial growth factor
120. A 10-year-old boy is brought to a new physician by his parents for an initial examination. The patient was born with congenital glaucoma, hearing loss, and a patent ductus arteriosus that has since been surgically corrected. At the time of birth, he also had purpura, jaundice, and splenomegaly. He is in a special education class for students with mental retardation. He is at the 75th percentile for height and weight, and 5th percentile for head circumference. This patient's condition was most likely caused by in utero exposure to which of the following?
- (A) Cytomegalovirus infection
 - (B) HIV infection
 - (C) Rubella
 - (D) Syphilis
 - (E) Toxoplasmosis



121. A 45-year-old woman is brought to the physician because of a 4-month history of muscle fatigue. She says that she has difficulty initiating movements and focusing her eyes. Physical examination shows bilateral ptosis of the upper eyelids. Repetitive nerve stimulation testing of a motor nerve shows a 30% decrease in the compound muscle action potential amplitude. A CT scan of the chest is shown; the arrow indicates an abnormality. Which of the following is the most likely cause of the muscle weakness in this patient?
- (A) Mesothelioma of the pleura
 - (B) Myasthenia gravis
 - (C) Sarcoidosis
 - (D) Small cell carcinoma of the lung
 - (E) Squamous cell carcinoma of the esophagus

-
122. An investigator is conducting a study of hypertension in an experimental animal model. Results show that hypertension is induced when one renal artery is constricted with a clamp, but both kidneys remain intact. Which of the following best explains the contribution of the normal kidney to the hypertension in this experimental model?
- (A) Aldosterone-induced sodium and water retention
 - (B) Angiotensin I-induced vasoconstriction
 - (C) Angiotensin II-induced renal vein constriction
 - (D) Expression of angiotensin-converting enzyme
 - (E) Increased renin secretion

123. One day after a 10-km race, a previously healthy 42-year-old man has dark urine. Urinalysis shows:

Specific gravity	1.010
Dipstick	
Glucose	negative
Blood	positive
Nitrites	negative
Microscopic examination	
WBC	negative
RBC	negative

Which of the following is the most likely cause of these findings?

- (A) Acute glomerulonephritis
 - (B) Hypovolemia
 - (C) Renal infarct
 - (D) Renal vein thrombosis
 - (E) Rhabdomyolysis
124. A 68-year-old man comes to the physician because of worsening nonproductive cough and progressive shortness of breath during the past 2 months. Three months ago, he was able to walk an unlimited distance without difficulty; now, he becomes short of breath after walking one block. He has had no fever, chest pain, or leg swelling. He has atrial fibrillation and hypertension treated with medications. His temperature is 37.7°C (99.8°F), pulse is 90/min, and respirations are 22/min. Pulse oximetry on room air shows an oxygen saturation of 92%. Diffuse inspiratory crackles are heard bilaterally. The remainder of the examination shows no abnormalities. His plasma brain natriuretic peptide concentration is within the reference range. A chest x-ray shows bilateral interstitial infiltrates. Which of the following medications is the most likely cause of these findings?
- (A) Amiodarone
 - (B) Digoxin
 - (C) Lisinopril
 - (D) Metoprolol
 - (E) Procainamide

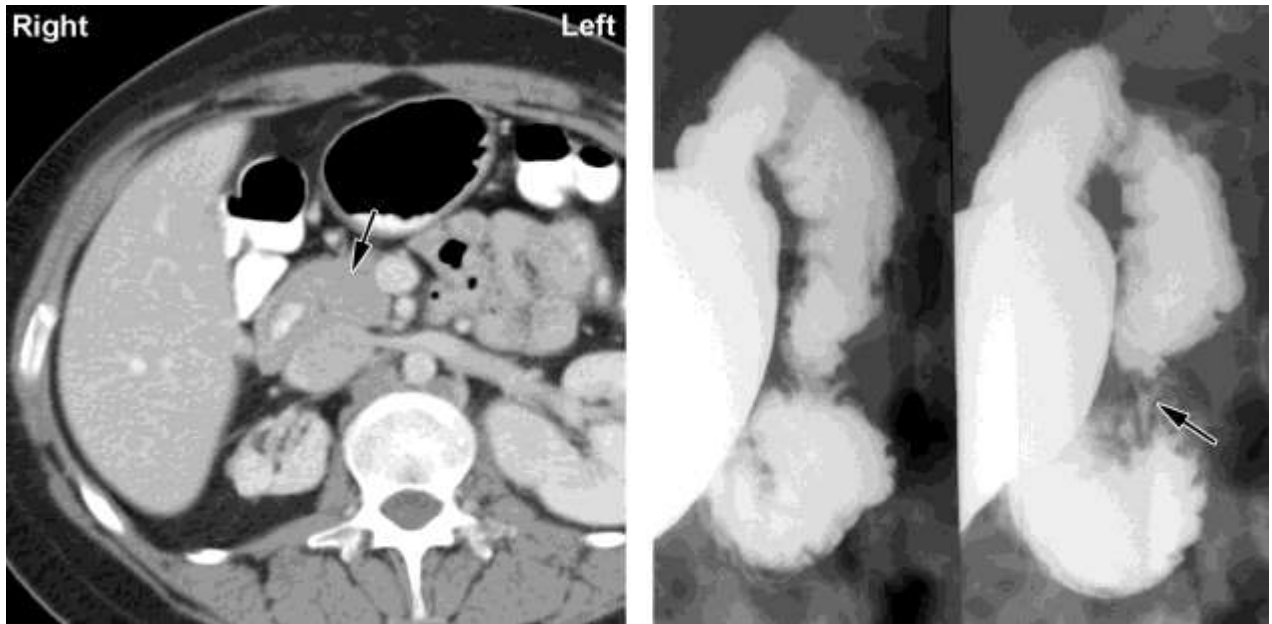
125. A 2-week-old female newborn delivered at term is brought to the physician by her mother because of an increasingly severe diaper rash since birth. No congenital anomalies were noted after delivery. Physical examination shows a red and swollen umbilical remnant that has not separated. There are ulcerations of the skin but no purulent exudate in the area of the diaper. A culture of one of the ulcers grows *Staphylococcus aureus*. Despite antibiotic therapy, 1 month later she develops a perirectal fissure, culture of which grows *Escherichia coli* but a smear of which shows scarce segmented neutrophils. Laboratory studies now show:

Hemoglobin	12.7 g/dL
Hematocrit	38%
Mean corpuscular volume	98 μm^3
Leukocyte count	89,790/mm ³
Segmented neutrophils	89%
Bands	6%
Lymphocytes	3%
Monocytes	2%
Platelet count	249,000/mm ³
Serum	
IgA	92 mg/dL
IgG	766 mg/dL
IgM	101 mg/dL

A peripheral blood smear shows normochromic, normocytic erythrocytes and leukocytes with normal morphology. This patient most likely has which of the following conditions?

- (A) Acute myelogenous leukemia
 (B) AIDS
 (C) Chédiak-Higashi syndrome
 (D) Common variable immunodeficiency
 (E) Leukocyte adhesion deficiency
-
126. A 52-year-old woman comes to the physician because of a 1-month history of headache, weakness, tingling of her extremities, muscle cramping, and fatigue. Her blood pressure is 170/110 mm Hg. Physical examination shows no other abnormalities. Laboratory studies show a decreased serum potassium concentration, metabolic alkalosis, and decreased plasma renin activity; serum sodium concentration is within the reference range. Urine catecholamine concentrations are within the reference range. Which of the following is the most likely diagnosis?
- (A) Adrenal adenoma
 (B) Focal segmental glomerulosclerosis
 (C) Hypothalamic tumor
 (D) Juxtaglomerular cell tumor
 (E) Renal artery stenosis
127. A 72-year-old man who is a retired construction worker comes to the physician because he has had a lesion on his face for 3 months. Physical examination shows a 6-mm, red, ulcerated lesion with heaped borders. A biopsy specimen of the lesion shows atypical, dysplastic keratinocytes within the epidermis and dermis. Which of the following is the most likely diagnosis?
- (A) Actinic keratosis
 (B) Discoid lupus erythematosus
 (C) Melanoma
 (D) Mycosis fungoides
 (E) Squamous cell carcinoma

128. An 84-year-old woman who resides in an assisted living facility is brought to the emergency department because of fever and cough for 1 week. The cough has been productive of foul-smelling, yellow-green sputum for 24 hours. She has a 2-year history of dementia, Alzheimer type. Her temperature is 38.5°C (101.3°F), pulse is 80/min, respirations are 20/min, and blood pressure is 116/66 mm Hg. Coarse inspiratory crackles are heard over the right lung field. Laboratory studies show a leukocyte count of 13,500/mm³ (72% segmented neutrophils, 8% bands, 1% eosinophils, 16% lymphocytes, and 3% monocytes). A CT scan shows a cavitary lesion in the superior segment of the right lower lobe. The lesion has a thick wall and an irregular peripheral margin; there is no displacement of the adjacent bronchovascular bundle. Which of the following is the most likely cause of the lung lesion in this patient?
- (A) Antecedent viral pneumonia
 - (B) Aspiration of gastric contents
 - (C) Bronchial obstruction by metastatic carcinoma
 - (D) Lung infarction secondary to arterial thrombosis
 - (E) Primary carcinoma of the lung
 - (F) Secondary infection of a congenital lung cyst
 - (G) Septic embolism from an extrapulmonary site
129. A 20-year-old man comes to the physician's office for a scheduled health maintenance examination. His father died of a myocardial infarction at age 55 years. Physical examination shows a tendon xanthoma on the elbow. His serum total cholesterol concentration is 360 mg/dL. A mutation is most likely to be found in which of the following genes?
- (A) apoA2
 - (B) apoC2
 - (C) apoE-ε4
 - (D) LDL receptor
 - (E) VLDL receptor
130. A full-term 2-week-old male newborn has cyanosis. Pregnancy and delivery were uncomplicated. His lungs are clear, and a midsystolic murmur is heard that is loudest in the left third intercostal space and associated with a thrill. Which of the following is the most likely diagnosis?
- (A) Atrial septal defect
 - (B) Bicuspid aortic valve
 - (C) Coarctation of the aorta
 - (D) Patent ductus arteriosus
 - (E) Tetralogy of Fallot
131. A study is conducted to assess the relationship between serum protein YY (PYY) concentrations and obesity. A total of 24 subjects with BMIs ranging from 17 to 40 kg/m² are enrolled in the study. A fasting serum PYY concentration is determined for each patient. The investigators report that the correlation coefficient between the two parameters is -0.84 ($p < 0.001$). Based on these results, which of the following is the most accurate conclusion?
- (A) A decreased serum PYY concentration is a cause of obesity
 - (B) The likelihood of a correlation between high BMIs and serum PYY concentrations is 0.16
 - (C) Obesity is not related to serum PYY concentrations
 - (D) The slope of the line showing the relationship between serum PYY concentrations and BMIs is -0.84
 - (E) Subjects with lower BMIs have higher serum PYY concentrations



132. A 47-year-old woman comes to the emergency department because of a 2-week history of intermittent abdominal pain, nausea, and vomiting. She has had similar episodes sporadically during the past 4 years. Physical examination shows dehydration, jaundice, and upper abdominal distention. Laboratory studies show hyperbilirubinemia. A CT scan and upper gastrointestinal series of the abdomen with oral contrast are shown; the arrows indicate the abnormality. Which of the following is the most likely cause of these findings?
- (A) Annular pancreas
 - (B) Cirrhosis of the liver
 - (C) Duodenal constriction by the portal vein
 - (D) Duodenal constriction by the superior mesenteric artery
 - (E) Pyloric stenosis

133. A 37-year-old woman with right lower extremity edema is evaluated because of the sudden onset of shortness of breath and pleuritic chest pain. A diagnosis of pulmonary embolism is made. Which of the following signs, if present on physical examination, would be the most specific indicator of pulmonary arterial hypertension in this patient?

- (A) Increased jugular venous pressure
- (B) P_2 louder than A_2
- (C) Peripheral edema
- (D) Presence of an S_3
- (E) Pulmonary crackles

134. A 56-year-old man comes to the emergency department because of a 4-day history of colicky right flank pain that radiates to the groin and hematuria. Ultrasound examination of the kidneys shows right-sided hydronephrosis and a dilated ureter. Which of the following is most likely to be found on urinalysis?

- (A) Erythrocyte casts
- (B) Glucose
- (C) Leukocyte casts
- (D) Oval fat bodies
- (E) Uric acid crystals

135. A 62-year-old man comes to the physician for a follow-up examination after he was diagnosed with chronic inflammatory interstitial pneumonitis. Following pulmonary function testing, a biopsy specimen of the affected area of the lungs is obtained. Compared with a healthy man, analysis of this patient's biopsy specimen is most likely to show which of the following patterns of changes in the cell populations of alveoli?

	Type I Pneumocytes	Type II Pneumocytes	Fibroblasts
(A)	↑	↑	↑
(B)	↑	↑	↓
(C)	↑	↓	↑
(D)	↑	↓	↓
(E)	↓	↑	↑
(F)	↓	↑	↓
(G)	↓	↓	↑
(H)	↓	↓	↓

136. A 63-year-old man with a 5-year history of congestive heart failure comes to the emergency department because of a 1-month history of fatigue and labored breathing. Evaluation shows pulmonary edema. Furosemide is administered. Which of the following sets of physiologic changes is most likely following administration of the drug?

	$\text{Na}^+ - \text{K}^+ - \text{Cl}^-$ Transport in the Thick Ascending Loop of Henle	Osmolarity of the Medullary Interstitium	Water Absorption in the Descending Loop of Henle
(A)	↑	↑	↑
(B)	↑	↑	↓
(C)	↑	↓	↑
(D)	↑	↓	↓
(E)	↓	↑	↑
(F)	↓	↑	↓
(G)	↓	↓	↑
(H)	↓	↓	↓

137. A 55-year-old man with a history of drug and alcohol abuse undergoes operative placement of a portosystemic shunt to relieve portal hypertension. During this procedure, it is most appropriate for the physician to anastomose a major tributary of the portal vein to which of the following vessels?

- (A) Left gastric vein
- (B) Left renal vein
- (C) Splenic vein
- (D) Superior mesenteric vein
- (E) Umbilical vein

138. A 52-year-old woman is admitted to the hospital because of breast cancer metastatic to the liver. Her prognosis is poor. She begs her husband to stay with her at the hospital because she is afraid to be left alone. Which of the following defense mechanisms best explains her behavior?

- (A) Denial
- (B) Displacement
- (C) Regression
- (D) Repression
- (E) Sublimation

Answer Form for USMLE Step 1 Sample Test Questions

Block 1 (Questions 1-46)

1. ___	11. ___	21. ___	31. ___	41. ___
2. ___	12. ___	22. ___	32. ___	42. ___
3. ___	13. ___	23. ___	33. ___	43. ___
4. ___	14. ___	24. ___	34. ___	44. ___
5. ___	15. ___	25. ___	35. ___	45. ___
6. ___	16. ___	26. ___	36. ___	46. ___
7. ___	17. ___	27. ___	37. ___	
8. ___	18. ___	28. ___	38. ___	
9. ___	19. ___	29. ___	39. ___	
10. ___	20. ___	30. ___	40. ___	

Block 2 (Questions 47-92)

47. ___	57. ___	67. ___	77. ___	87. ___
48. ___	58. ___	68. ___	78. ___	88. ___
49. ___	59. ___	69. ___	79. ___	89. ___
50. ___	60. ___	70. ___	80. ___	90. ___
51. ___	61. ___	71. ___	81. ___	91. ___
52. ___	62. ___	72. ___	82. ___	92. ___
53. ___	63. ___	73. ___	83. ___	
54. ___	64. ___	74. ___	84. ___	
55. ___	65. ___	75. ___	85. ___	
56. ___	66. ___	76. ___	86. ___	

Block 3 (Questions 93-138)

93. ___	103. ___	113. ___	123. ___	133. ___
94. ___	104. ___	114. ___	124. ___	134. ___
95. ___	105. ___	115. ___	125. ___	135. ___
96. ___	106. ___	116. ___	126. ___	136. ___
97. ___	107. ___	117. ___	127. ___	137. ___
98. ___	108. ___	118. ___	128. ___	138. ___
99. ___	109. ___	119. ___	129. ___	
100. ___	110. ___	120. ___	130. ___	
101. ___	111. ___	121. ___	131. ___	
102. ___	112. ___	122. ___	132. ___	

Answer Key for USMLE Step 1 Sample Test Questions

Block 1 (Questions 1-46)

1. C	13. A	25. C	37. B
2. E	14. B	26. B	38. A
3. B	15. A	27. C	39. A
4. E	16. A	28. A	40. A
5. B	17. A	29. D	41. B
6. F	18. A	30. C	42. C
7. D	19. E	31. B	43. F
8. B	20. B	32. E	44. A
9. B	21. A	33. D	45. C
10. A	22. D	34. C	46. D
11. A	23. E	35. E	
12. A	24. C	36. B	

Block 2 (Questions 47-92)

47. C	59. G	71. B	83. A
48. C	60. D	72. C	84. B
49. B	61. D	73. D	85. D
50. B	62. C	74. D	86. A
51. C	63. C	75. D	87. C
52. C	64. C	76. C	88. B
53. E	65. C	77. G	89. B
54. D	66. C	78. E	90. E
55. A	67. A	79. E	91. F
56. D	68. D	80. D	92. D
57. A	69. B	81. C	
58. D	70. D	82. D	

Block 3 (Questions 93-138)

93. E	105. A	117. A	129. D
94. D	106. C	118. A	130. E
95. C	107. E	119. E	131. E
96. A	108. E	120. C	132. A
97. E	109. A	121. B	133. B
98. A	110. A	122. A	134. E
99. A	111. B	123. E	135. E
100. B	112. C	124. A	136. H
101. E	113. E	125. E	137. B
102. E	114. A	126. A	138. C
103. E	115. A	127. E	
104. E	116. B	128. B	