

Johnson & Johnson INSTITUTE

FOUNDATIONAL LEARNING SYSTEM

## MODULE 1: ANATOMY & PHYSIOLOGY OF THE BRAIN

# Stroke Foundational Learning System



CERENOVUS

© Johnson & Johnson Services Inc. 2018 All rights reserved.

092892-181219

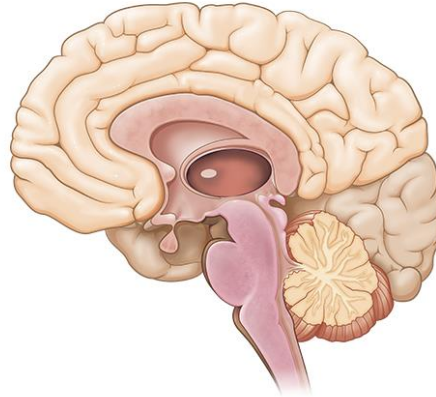
1

**SAY:** Welcome to Module 1: Anatomy & Physiology of the Brain. This module will strengthen your understanding of basic neuroanatomy, neurovasculature, and functional roles of specific brain regions.

## Lesson 1: Introduction to the Brain

The brain is a dense organ with various functional units. Understanding the anatomy of the brain can be aided by looking at it from different organizational layers.

In this lesson, we'll discuss the principle brain regions, layers of the brain, and lobes of the brain, as well as common terms used to orient neuroanatomical discussions.



*Johnson & Johnson* INSTITUTE

2

**SAY:** The brain is a dense organ with various functional units. Understanding the anatomy of the brain can be aided by looking at it from different organizational layers. (Purves 2012/p717/para1)

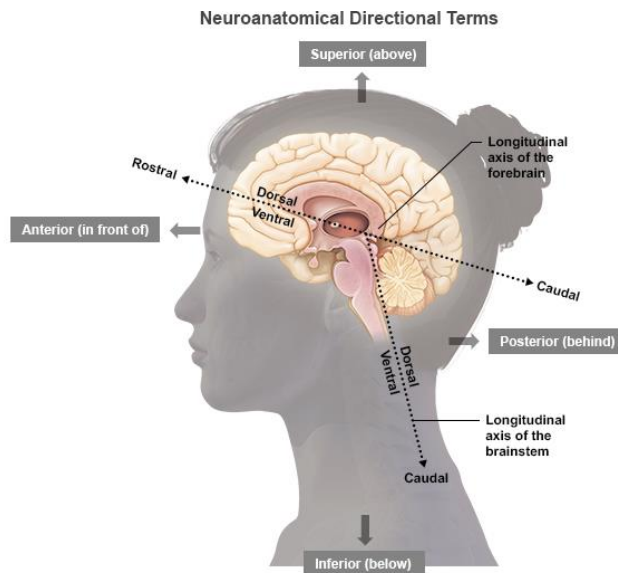
In this lesson, we'll explore these organizational layers by discussing the principle brain regions, layers of the brain, and lobes of the brain. We'll also discuss the terms used by scientists and healthcare providers to orient neuroanatomical discussions.

## Lesson 1: Learning Objectives

- Define terms used to specify neuroanatomical locations
- Recall the 4 principle regions of the brain
- Identify the 3 layers of the brain and their relative location
- Match each of the 4 lobes of the brain with their respective functions

**SAY:** Please take a moment to review the learning objectives for this lesson.

## Directional Terms Used in Anatomy



Johnson & Johnson INSTITUTE

4

**SAY:** Specific directional terms are used when specifying the location of a structure or area of the brain.

Note that the terms anterior, posterior, superior, and inferior refer to the long axis of the body (which is straight), and doesn't change. (Purves 2012/p718/Figure A1/caption)

However, the terms dorsal, ventral, rostral, and caudal are relative to the nervous system axis they are describing,

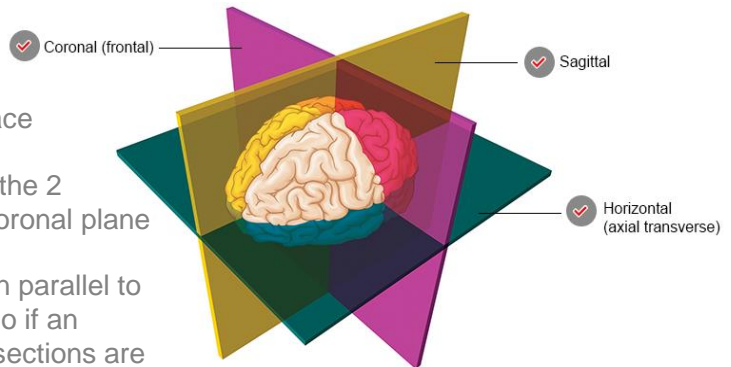
which bends at the brainstem. (Purves 2012/p718/Figure A1/caption)

Image Reference: ([Purves 2012/p718/Figure A1](#))

## Sectional Planes Used in Anatomy

- **Coronal:** taken in the plane of the face
- **Sagittal:** taken in the plane dividing the 2 hemispheres, perpendicular to the coronal plane
- **Horizontal (axial transverse):** taken parallel to the rostral-caudal axis of the brain; so if an individual is standing upright, these sections are parallel to the ground

*This is not the case for the brainstem; remember that in humans, the rostral-caudal axis of the forebrain is tilted. Therefore, a transverse section of the brainstem is perpendicular to its long axis and the posterior-anterior axis indicate the same directions*



Johnson & Johnson INSTITUTE

5

**SAY:** When studying the internal anatomy of the brain, you may notice different sectional planes. (Purves 2012/p718/c2/para1)

The terms used to describe these planes help provide a common frame of reference when discussing the locations of brain structures. (Purves 2012/p718/c2/para1)

Image Reference: (Purves 2012/p718/Figure A1B; Tortora 2009/pg 56/Figure14.4)

*There are 3 key planes to note, the coronal plane, the sagittal plane, and the horizontal, or axial transverse plane.*

- **Coronal (frontal):** taken in the plane of the face (Purves 2012/p718/c1/para2)
- **Sagittal:** taken in the plane dividing the 2 hemispheres, perpendicular to the coronal plane (Purves 2012/p718/c1/para2)
- **Horizontal** (also called axial sections): taken parallel to the rostral-caudal axis of the brain; so if an individual is standing upright, these sections are parallel to the ground (Purves 2012/p718/c1/para2)

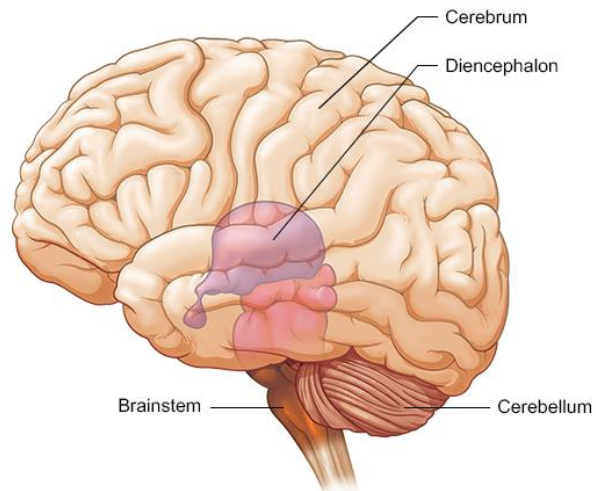
This is not the case for the brainstem; remember that in humans, the rostral-caudal axis of the forebrain is tilted (Purves 2012/p718/c1/para2).

Therefore, a transverse section of the brainstem is perpendicular to its long axis and the posterior-anterior axis indicate the same directions (Purves 2012/p718/c2/para1).

## Principal Regions of the Brain

There are 4 principal regions of the adult brain:

- Cerebrum
- Cerebellum
- Diencephalon
- Brainstem



Johnson & Johnson UNIVERSITY

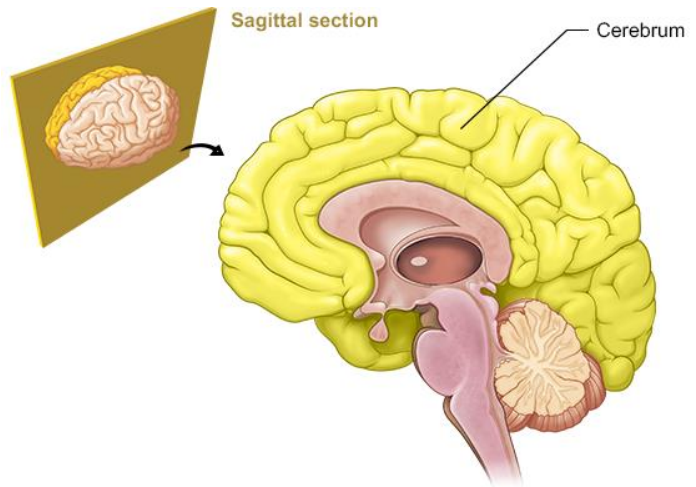
6

**SAY:** There are 4 principal regions of the adult brain, which are shown here. Let's begin reviewing these regions starting with the cerebrum.

Image Reference: (Marieb 2016/p432/Figure 12.2)

## Principal Regions of the Brain: Cerebrum

- Largest portion of the brain
  - 83% of brain mass
- Responsible for complex aspects of consciousness
  - Memory
  - Personality
  - Intelligence



Johnson & Johnson INSTITUTE

7

**SAY:** The cerebrum is the largest portion of our brain, accounting for 83% of the total brain mass. (Marieb 2016/p434/c2/para1)

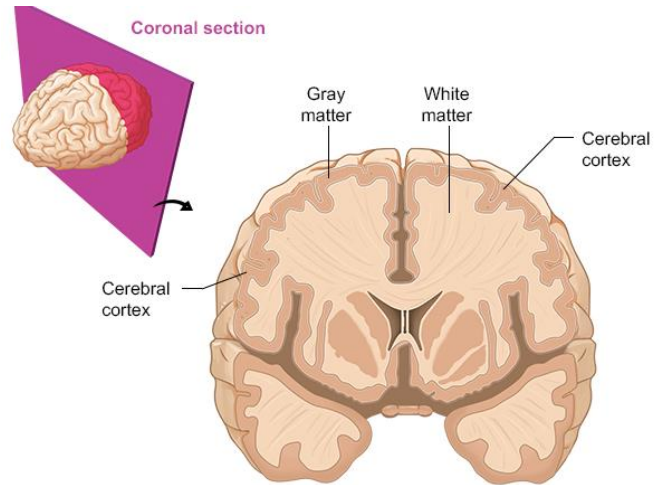
It is responsible for complex aspects of our consciousness, such as memory, personality, and intelligence. (Tortora 2009/p508/Table 14.2/c2/last para)

Image Reference: (Marieb 2016/p454/Table 12.1/row 1)

## Principal Regions of the Brain: Cerebrum

Divided into 2 **cerebral hemispheres**:

- Outer Cerebral Cortex
- Inner regions of **grey matter** and **white matter**



Johnson & Johnson INSTITUTE

8

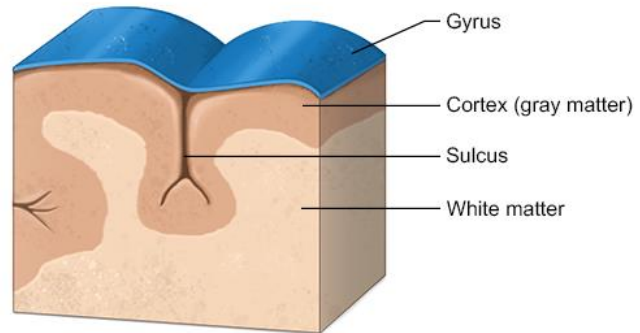
**SAY:** The cerebrum is divided into 2 **cerebral hemispheres** (Marieb 2016/cerebrum) each of which consists of an outer cerebral cortex, and inner regions of **grey matter** and **white matter**. (Tortora 2009/p514/c1/para1)

Image Reference: Marieb 2016/p44/Figure 12.10b)



## Cerebrum: Cerebral Cortex

- 2-4 mm thick
- Billions of neurons
- **Folds triple surface area**
  - Ridges (gyri)
  - Grooves (sulci)



Johnson & Johnson INSTITUTE

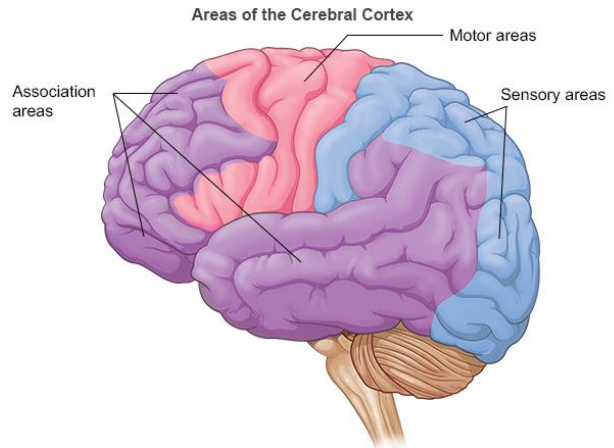
9

**SAY:** The cerebral cortex is 2 to 4 millimeters thick, contains billions of neurons, and has folds that nearly triple its surface area (Marieb 2016/p435/c2/para3). The folds on the surfaces of the cerebral hemispheres are comprised of ridges of tissue, called gyri, separated by shallow grooves, called sulci (Marieb 2016/p435/c1/para 3)

Image Reference: (Marieb 2016/p434/Figure 12.5)

## Cerebrum: Cerebral Cortex

- Areas:
  1. **Sensory** areas that deal with the perception of sensory information
  2. **Motor** areas that control voluntary movement execution
  3. **Association** areas that integrate complex functions
- Each hemisphere predominantly controls the opposite side of the body
- No functional area acts alone
- Conscious behavior requires entire cortex



Johnson & Johnson INSTITUTE

10

**SAY:** The cerebral cortex contains (Tortora 2009/p508/Table 14.2/c2/last para)

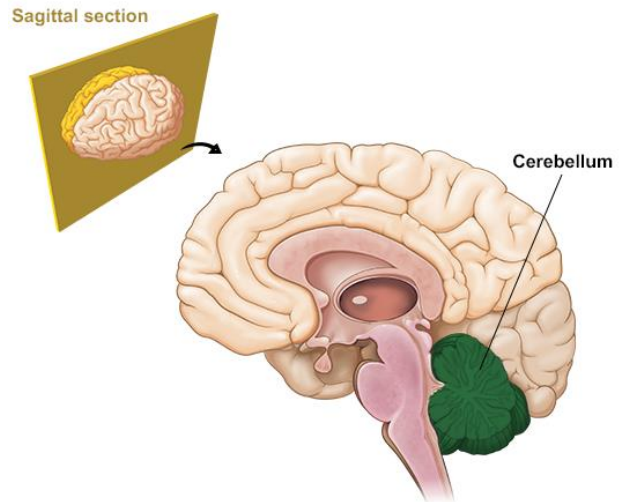
- Sensory areas that deal with the perception of sensory information,
- Motor areas that control voluntary movement execution, and
- Association areas that integrate complex functions.

Each hemisphere predominately controls the opposite side of the body; however, no one functional area of the cortex acts entirely alone—conscious behavior requires the entire cortex to play a role. (Marieb 2016/p437/c1/para 1)

Image Reference: (Marieb 2016/Figure 12.7a)

## Principle Regions of the Brain: Cerebellum

- “Little Brain”
- Second largest part of brain
- 11% of brain mass
- Folds increase surface area and allow for greater numbers of neurons
- Functions
  1. Coordinates skeletal muscle contractions
  2. Regulates balance and posture
  3. May have a role in language processing and recognition



Johnson & Johnson INSTITUTE

11

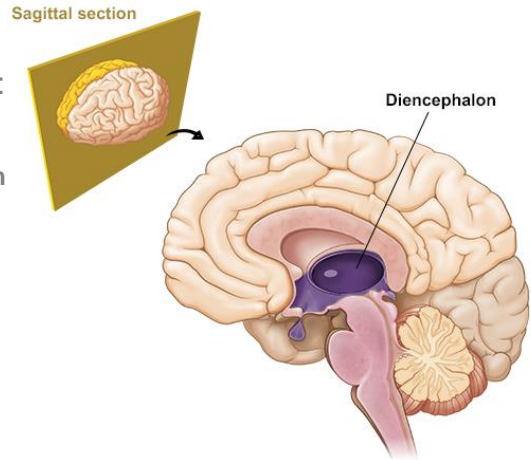
**SAY:** The cerebellum sits in the inferior and posterior part of the cranial cavity (Tortora 2009/p507/c2/para4). It is also known as the “little brain” and is the second largest part of the brain, accounting for 11% of total brain mass (Tortora 2009/p496/c2/para1) (Marieb 2016/p434/c2/para1’450/c1/para8).

Similar to the cerebrum, the cerebellum has folds that increase surface area and allow for a greater number of neurons. (Tortora 2009/p507/c2/para4). The cerebellum coordinates skeletal muscle contractions, regulates balance and posture, and may have a role in language processing and cognition. (Tortora 2009/p508/Table 14.2/c1/last para)

Image Reference: (Marieb 2016/p455/Table 12.1/last row)

## Principle Regions of the Brain: Diencephalon

- Partners with the cerebrum and cerebellum to:
  1. Coordinate motor functions
  2. Play a role in consciousness
  3. Control and integrate the **autonomic nervous system**
  4. Regulate eating and thirst
  5. control body temperature and circadian rhythm



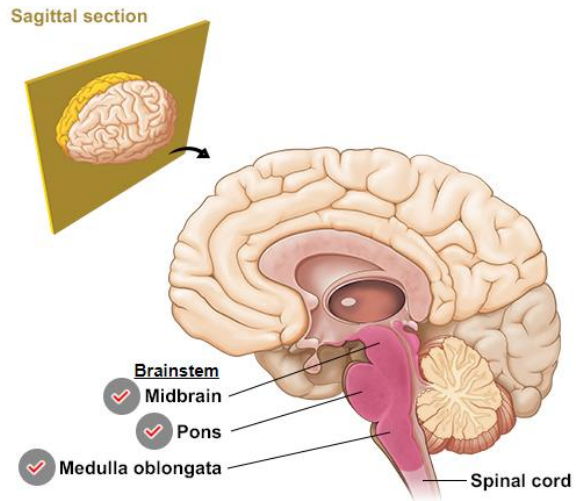
**SAY:** The diencephalon is surrounded by the cerebral hemispheres. (Marieb 2016/p443/c2/para2) It contains structures that partner with the cerebrum and the cerebellum to coordinate motor functions, play a role in consciousness, control and integrate the **autonomic nervous system**, regulate eating and thirst, and control body temperature and circadian rhythm. (Tortora 2009/p508/Table 14.2/c2/para1)

Image Reference: (Marieb 2016/p454/Table 12.1/row2)

## Principle Regions of the Brain: Brainstem

Located between the diencephalon and the spinal cord, it is **composed of 3 parts**:

1. Midbrain
2. Pons
3. Medulla Oblongata



Johnson & Johnson INSTITUTE

13

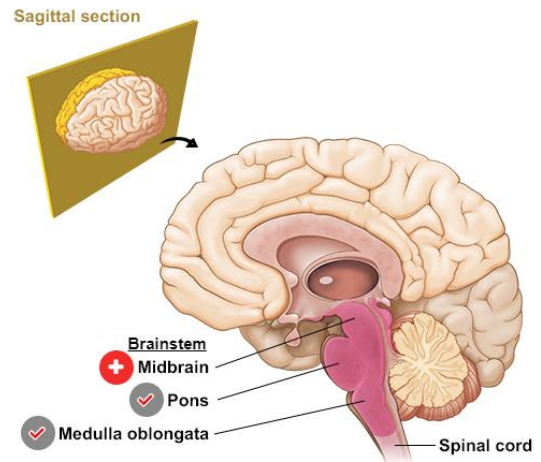
**SAY:** The brainstem is located between the diencephalon and the spinal cord. It is composed of 3 parts. (Tortora 2009/p504/c1/para1)

The MidBrain, the Pons, and the Medulla Oblongata

Image Reference: (Purves 2012/p730/FigureA12) (Marieb 2016/p446/Figure 12.13)

## Brainstem: Midbrain

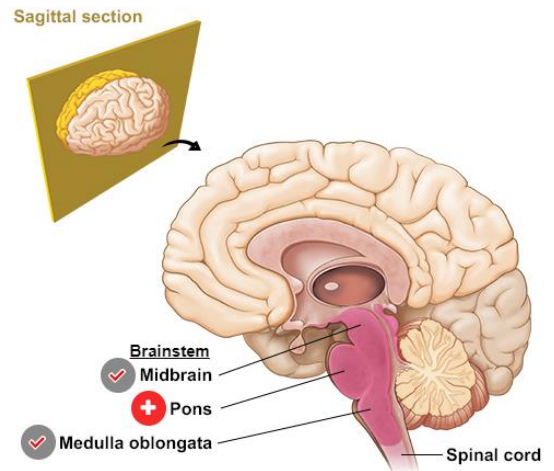
The **Midbrain** contains tracks for nerve impulses between motor areas of the cerebral cortex to the spinal cord. Some of the other functions that relay through the midbrain include reflexes for the head, eyes and trunk response to visual stimuli, and impulses for auditory stimuli (eg, the **startle reflex**)



**SAY:** The midbrain contains tracks for nerve impulses between motor areas of the cerebral cortex to the spinal cord. (Tortora 2009/p507/c1/para1) Some of the other functions that relay through the midbrain include reflexes for the head, eyes, and trunk in response to visual stimuli, and impulses for auditory stimuli (e.g., the **startle reflex**). (Tortora 2009/p503/c2/para2)

## Brainstem: Pons

The **pons** serves as a bridge to connect areas of the brain to one another. The pons contains areas that relay signals for voluntary movements, equilibrium information from the inner ear, and areas that (together with the medulla oblongata) help control breathing

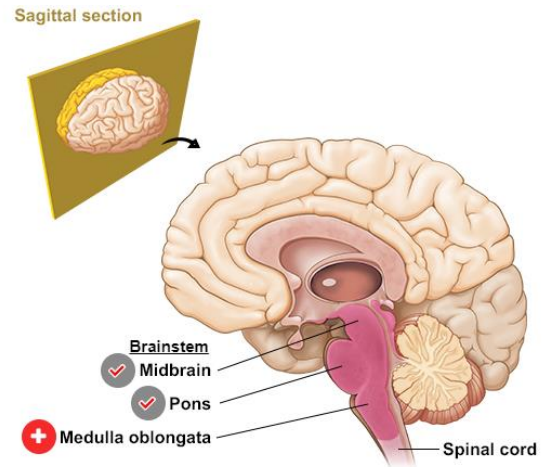


**SAY:** The pons serves as a bridge to connect areas of the brain to one another. The pons contains areas that relay signals for voluntary movements, equilibrium information from the inner ear, and areas that (together with the medulla oblongata) help control breathing. (Tortora 2009/p505/c2/para2)

## Brainstem: Medulla Oblongata

The **medulla oblongata** (also called medulla) contains areas that control key vital body functions:

- the cardiovascular center, which regulates the rate and force of the heartbeat and the diameter of blood vessels
- the respiratory center, which adjusts the basic rhythm of breathing.
- reflexes for swallowing, sneezing, vomiting, hiccupping, and coughing



Johnson & Johnson INSTITUTE

16

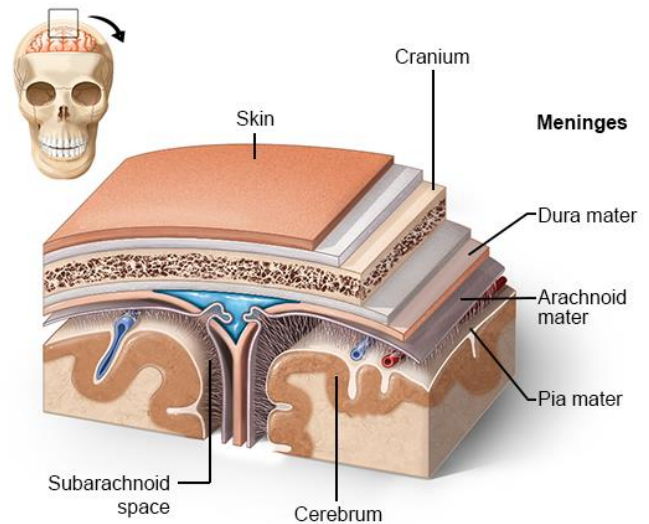
**SAY:** The medulla oblongata (also called medulla) contains areas that control key vital body functions. For example, the medulla contains the cardiovascular center, which regulates the rate and force of the heartbeat and the diameter of blood vessels. The medulla also contains the respiratory center, which adjusts the basic rhythm of breathing. (Tortora 2009/p503/c2/para2) Other sections of the medulla control reflexes for swallowing, sneezing, vomiting, hiccupping, and coughing. (Tortora 2009/p503/c2/para3)



## Layers of the Brain

### Meninges:

- Connective tissue
- **3 layers:**
  - Dura Mater
  - Arachnoid Mater
  - Pia Mater
- Cover and protect the brain and blood vessels, contain **cerebrospinal fluid**, and create partitions in the skull



Johnson & Johnson INSTITUTE

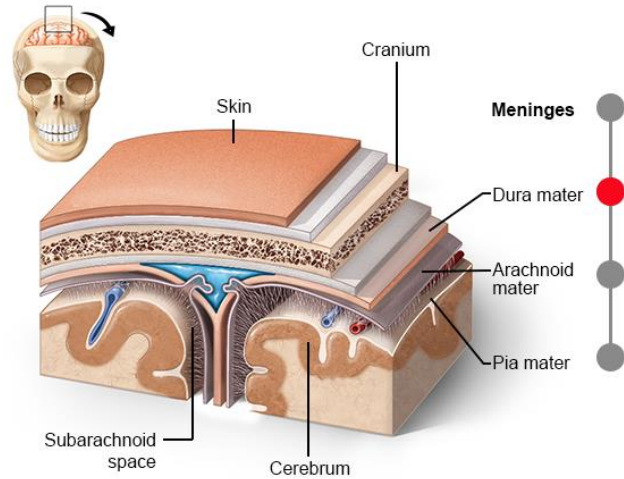
17

**SAY:** Now that we have discussed the principle parts of the brain, let's look at the layers of the brain from the outside moving in. The brain is surrounded by 3 layers of connective tissue membrane called **meninges**. These layers cover and protect the brain and blood vessels, contain cerebrospinal fluid, and create partitions in the skull. (Marieb 2016/p460/c2/para1)

# Layers of the Brain: Meninges

## Dura Mater<sup>1</sup>

- Outermost layer
- Strongest of the 3 meninges
- 2-layered sheet



1. Marieb 2016/p460/c2/para1

*Johnson & Johnson* INSTITUTE

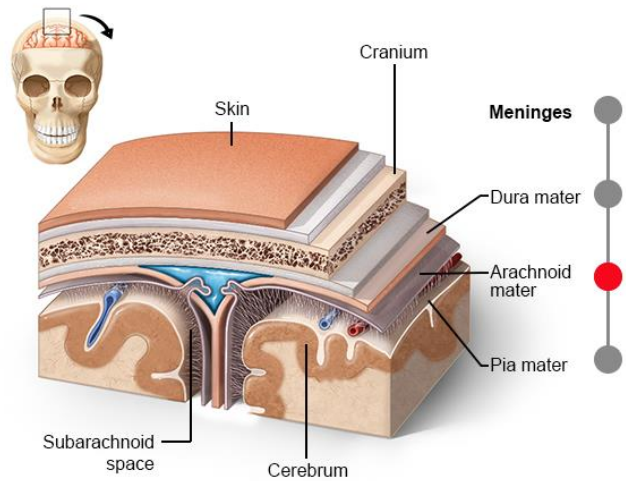
18

**SAY:** The outermost layer of the meninges, the dura mater, is the strongest of the 3 meninges. The dura mater is a 2-layered sheet, the most superficial of which is attached to the inner surface of the skull. (Marieb 2017/p460/c2/para3) In some places, the folds of the dura mater extend into the cerebral hemispheres to limit excessive movement of the brain within the cranium. (Marieb 2017/p460/c2/para3)

## Layers of the Brain: Meninges

### Arachnoid Mater

- Middle layer
- Forms a loose brain covering, separated from the dura mater by a narrow cavity
- Beneath the arachnoid membrane is the subarachnoid space, which contains web-like extensions that secure the arachnoid mater to the pia mater below it
- Term come from the word "*arachnida*", meaning spider



Johnson & Johnson INSTITUTE

19

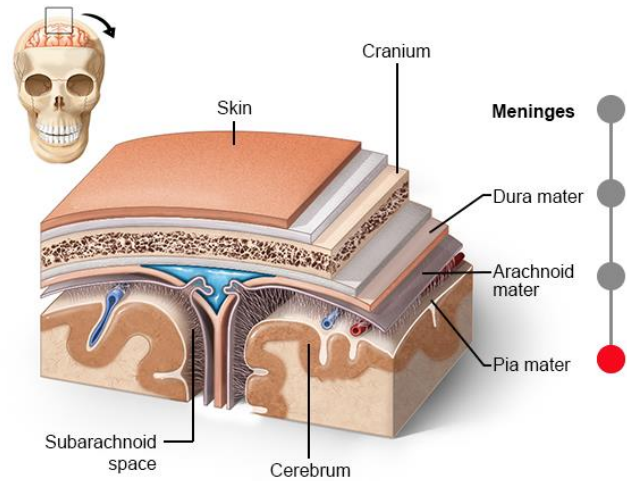
**SAY:** The middle layer of the meninges is the arachnoid mater. This layer forms a loose brain covering that is separated from the dura mater by a narrow cavity. Beneath the arachnoid membrane is the **subarachnoid space**, which contains web-like extensions that secure the arachnoid mater to the pia mater below it. (Marieb 2017/p461/c1/para4)

The term arachnoid comes from the word *arachnida*, meaning spider. The arachnoid mater is named for its web-like extensions. (Marieb 2017/p461/c1/para4)

# Layers of the Brain: Meninges

## Pia Mater

- Innermost layer
- Composed of delicate connective tissue and small blood vessels

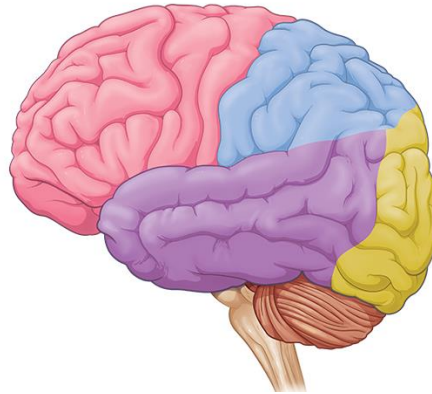


Johnson & Johnson INSTITUTE

20

**SAY:** The pia mater is the innermost layer of the meninges and closely adheres to the shape of the brain. (Marieb 2017/p461/c1/para5-c2/para1) The pia mater is composed of delicate connective tissue and many small blood vessels. (Marieb 2017/p461/c1/para4) As blood vessels pass along the surface of the brain and turn inward, they are covered by a loose-fitting sleeve of pia mater. (Tortora 2009/p496/c2/para2)

## Lobes of the Brain



Johnson-Johnson UNIVERSITY

21

**SAY:** Let's shift our attention to another form of anatomical subdivision, the lobes of the brain.

Image Reference: (Purves 2012/p720/Figure A3a)

## Lobes of the Brain

Fill in the blank: The Brain has \_\_\_\_\_ lobes.



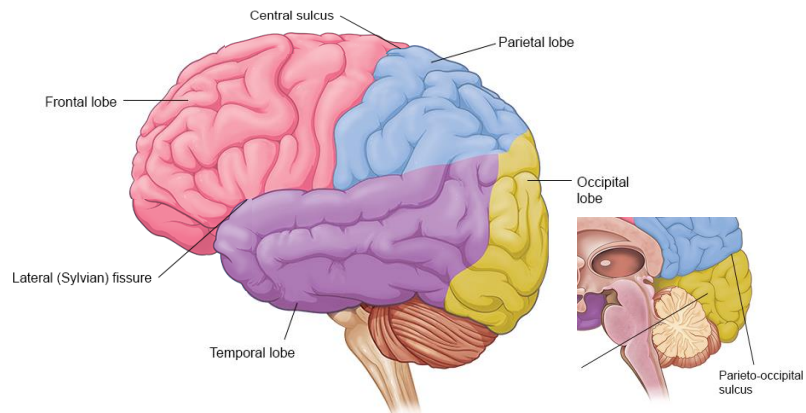
**SAY:** How many lobes does the brain have?

## Lobes of the Brain

Fill in the blank: The Brain has \_\_\_\_\_ lobes.

There are **4 Lobes**:

- Frontal
- Parietal
- Occipital
- Temporal



**SAY:** There are 4 lobes of the brain. Specific gyri and sulci on the surface of the cerebrum serve as anatomical landmarks to divide the brain into 4 lobes: frontal, parietal, occipital, and temporal. (Purves 2012/p720/c1/para3)

Landmarks that divide the brain into lobes include the central sulcus that divides the frontal lobe from the parietal lobe. Additionally note the lateral fissure, also known as the Sylvian fissure, dividing the temporal lobe from the frontal and parietal lobes. (Purves 2012/p720/c1/para1)

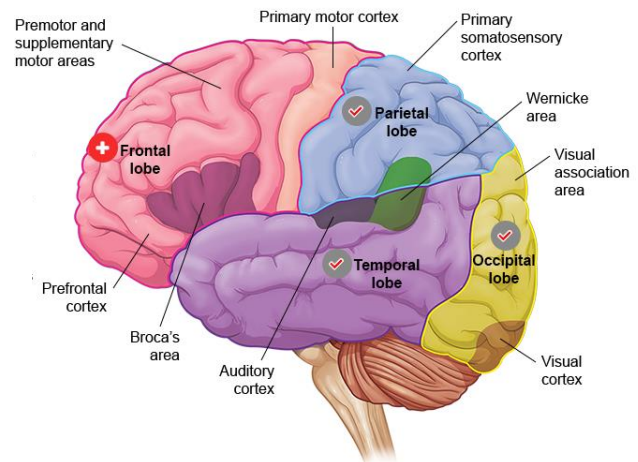
Looking at the brain from the hemisected view allows us to note the parieto-occipital sulcus separates the parietal and occipital lobes.

Image Reference: (Purves 2012/p720/Figure A3a)

## Functional Areas of the Brain: Frontal Lobe

Associated with executive functions, motor performance, and production of language

- **Prefrontal Cortex:**
  - Executive functions (e.g., personality & recognizing consequence)
- **Primary Motor Cortex:**
  - Motor Performance (e.g., initiation of voluntary movement as well as the premotor and supplementary motor areas, which coordinate the planning and initiation of voluntary movement)
- **Broca's area:**
  - Production of language
  - Damage causes Broca's aphasia, a condition in which the patient understands many written and spoken words, but has difficulty speaking them



Johnson & Johnson INSTITUTE

24

**SAY:** The frontal lobe is associated with executive functions, motor performance, and production of language. (Vanderah 2016/p61/c2/last para-p62/c2/para1)

The first of these functions occupies a large portion of the frontal lobe and is called the **prefrontal cortex**. This area is involved with executive functions, which include personality, and recognizing future consequences of current actions. (Vanderah 2016/p62/c1/para2)

Areas of the frontal lobe associated with motor performance include the **primary motor cortex**, which is involved in the initiation of voluntary movement, as well as the premotor and supplementary motor areas, which coordinate the planning and initiation of voluntary movement.

The motor aspects of language (ie, the production of language) are controlled by an area in 1 hemisphere (typically the left) of the frontal lobe called **Broca's area**. (Vanderah 2016/p62/c1/para3) Damage to this area causes Broca's aphasia, a condition in which the patient understands many written and spoken words but has difficulty speaking them. (Dorland's/broca's asphasi)

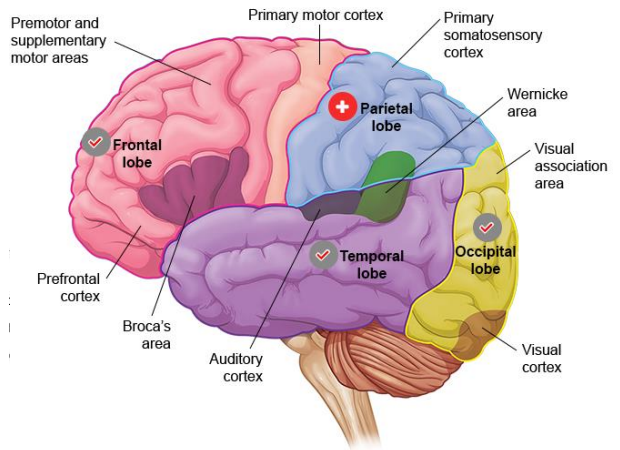
Image Reference: (Patton 2014/p255/Figure 10-13)



## Parietal Lobe

Associated with integrating sensory information, contains the spatial orientation system, and is involved in the comprehension of language

- **Primary somatosensory cortex:**
  - Concerned with processing of proprioceptive and tactile stimuli
- **Parietal Cortex:**
  - Controls aspects of spatial orientation and directing attention
- **Wernicke's area:**
  - Located partially in the parietal lobe
  - Involved in recalling, recognizing, and interpreting words and other sounds in the process of using language



Johnson & Johnson INSTITUTE

25

**SAY:** The parietal lobe is associated with integrating sensory information, contains the spatial orientation system, and is involved in the comprehension of language. (Vanderah 2016/p64/c1/para2-c2/para3)

An area of the parietal lobe, called the **primary somatosensory cortex**, is concerned with the processing of proprioceptive and tactile stimuli. (Vanderah 2016/p64/c1/last para-c2/para1)

The **parietal cortex** controls complex aspects of spatial orientation and directing attention. (Vanderah 2016/p64/c2/para3)

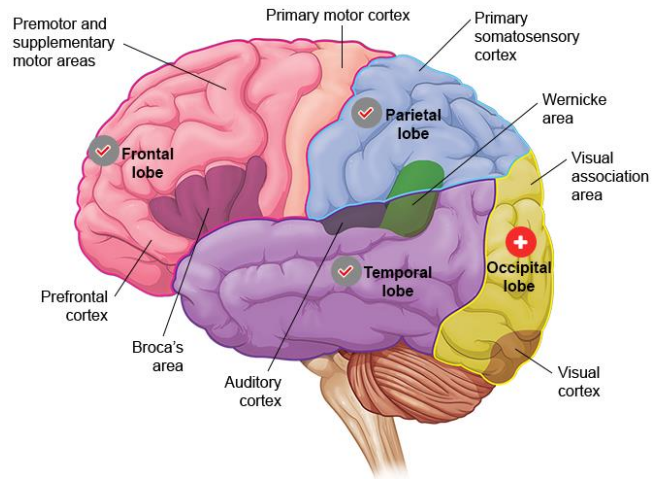
A large portion of the parietal lobe of one of the hemispheres (typically the left) works with portions of the temporal lobe to comprehend language.

**Wernicke's area** is located partially in the parietal lobe and is involved in recalling, recognizing, and interpreting words and other sounds in the process of using language. (Dorland's/Wernicke aphasia) (Taber's/Wernicke).

## Occipital Lobe

Chiefly responsible for visual functions

- Contains the primary visual cortex and the majority of the visual association area, involved in higher order processing of visual information



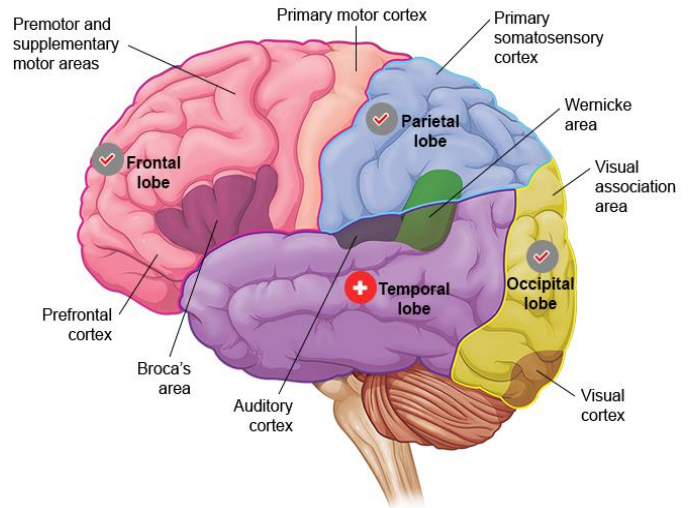
Johnson & Johnson INSTITUTE

26

**SAY:** The occipital lobe is chiefly responsible for visual functions. This lobe contains the primary visual cortex and the majority of the visual association area, involved in higher order processing of visual information. (Vanderah 2016/p65/c2/para2)

## Temporal Lobe

- Contains the primary auditory cortex and part of Wernicke's area
- Medial parts of the temporal lobe are involved in aspects of memory and learning



Johnson & Johnson INSTITUTE

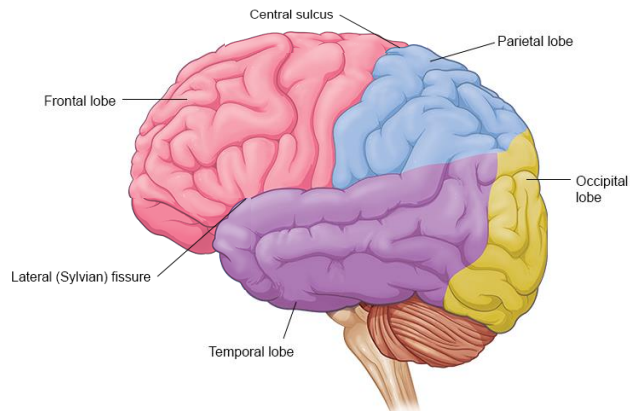
27

**SAY:** The temporal lobe contains the primary auditory cortex (involved with auditory perception (Taber's/auditory area) and part of Wernicke's area. (Vanderah 2016/p65/c1/para2) Recall that Wernicke's area is involved in the comprehension of language; a patient with damage to Wernicke's area (Wernicke aphasia) would be unable to understand written, spoken, or tactile speech symbols. (Dorland's/Wernicke aphasia) Medial parts of the temporal lobe are involved in aspects of memory and learning. (Vanderah 2016/p65/c1/para3)

## Lobes of the Brain

Which lobe's primary function is integrating sensory information?

- a) Occipital lobe
- b) Parietal lobe
- c) Frontal lobe
- d) Temporal lobe

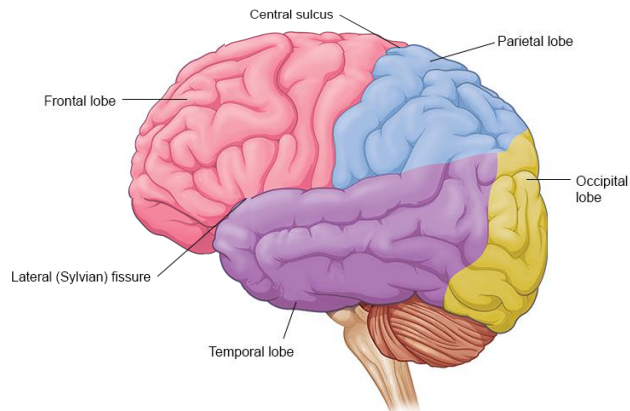


**SAY:** Let's briefly review. Which of the lobe's primary function is integrating sensory information?

## Lobes of the Brain

Which lobe's primary function is integrating sensory information?

- a) Occipital lobe
- b) Parietal lobe**
- c) Frontal lobe
- d) Temporal lobe



**SAY:** That's correct – the parietal lobe's primary function is integrating sensory information

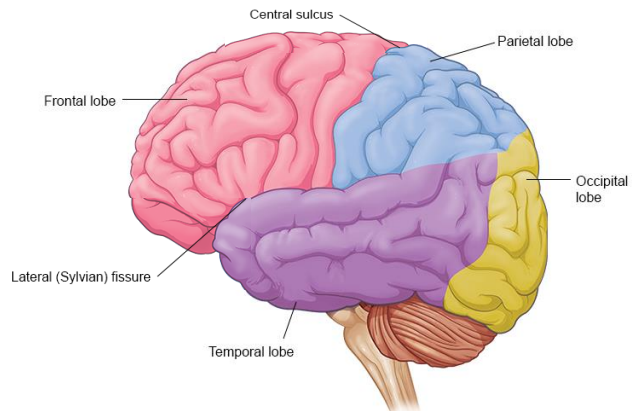
OR

**SAY:** That's incorrect – the parietal lobe's primary function is integrating sensory information

## Lobes of the Brain

Which lobe is associated with executive functions, motor performance, and production of language?

- a) Occipital lobe
- b) Parietal lobe
- c) Frontal lobe
- d) Temporal lobe

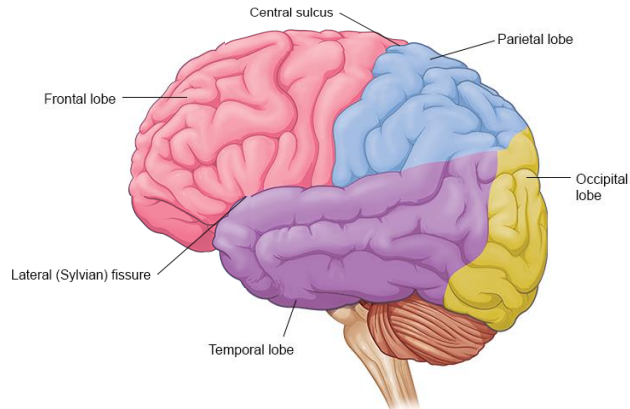


**SAY:** Let's do another review. Which lobe is associated with executive functions, motor performance, and production of language?

## Lobes of the Brain

Which lobe is associated with executive functions, motor performance, and production of language?

- a) Occipital lobe
- b) Parietal lobe
- c) **Frontal lobe**
- d) Temporal lobe



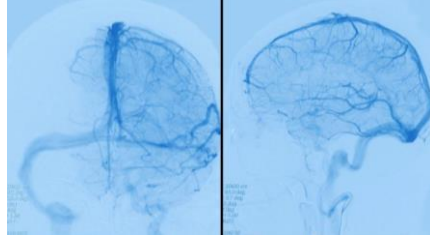
**SAY:** That's correct – the frontal lobe is associated with executive functions, motor performance, and production of language

OR

**SAY:** That's incorrect - the frontal lobe is associated with executive functions, motor performance, and production of language

## Lesson 2:

# Blood Supply to the Brain



In this lesson, we'll discuss the arterial system and the branches of the aorta that supply our brains with this critical substance.

**SAY:** Let's move on to the next topic: blood supply to the brain. In this lesson, we'll discuss the arterial system and the branches of the aorta that supply our brains with this critical substance.



## Lesson 2: Learning Objectives

- Define the types of arteries in the arterial system, and the flow of blood through these arteries
- List the 3 portions of the aorta
- Label the aortic arch, the brachiocephalic artery, and their respective branches
- Name common types and variations in the aortic arch
- Recall the 2 sources for the brain's arterial blood supply

**SAY:** Please take a moment to review the learning objectives for this lesson.

## Blood Supply to the Brain

How quickly do we lose consciousness after losing blood supply to the brain?



**SAY:** How quickly do we lose consciousness after losing blood supply to the brain?

## Blood Supply to the Brain

How quickly do we lose consciousness after losing blood supply to the brain?

After just **10 seconds**



**SAY:** To function correctly, our brains require a continuous supply of well-oxygenated blood. After just 10 seconds without it, we lose consciousness. After a few minutes, irreversible damage usually begins to manifest. To account for this dependency, neural tissues are supplied by a dense meshwork of blood vessels. (Vanderah 2016/p126/c1/para1).

# The Arterial System

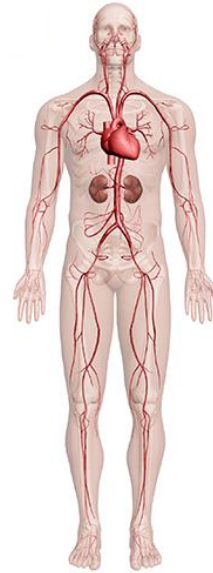The arterial system is divided into **2 major circulation systems**

## 1. Systemic arteries:

- Carry blood from the heart to the whole body
- Direct or indirect branches from the aorta, the main and largest artery of the body

## 2. Pulmonary arteries:

- Carry deoxygenated blood from the heart to the lungs.



Johnson & Johnson INSTITUTE

36

**SAY:** The arterial system is divided into 2 major circulation systems. (SEER 2018/p1/para1)

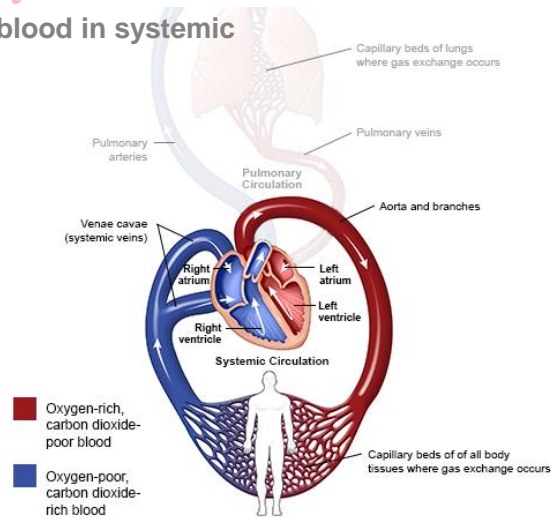
The first are the systemic arteries that carry blood from the heart to the whole body. (SEER 2018/p2/para1)

All systemic arteries are either direct or indirect branches from the aorta, (SEER 2018/p2/para3), the main and largest artery of the body. (Patton 2014/p705/aorta) The second are the pulmonary arteries that carry deoxygenated blood from the heart to the lungs. (Patton 2014/p399/c1/para2-c2/parra1) (Marieb 2016/p729/c1/para3)

## Systemic and Pulmonary Circulation

**Flow of oxygenated and nutrient rich blood in systemic circulation:**

- Left ventricle of the heart
- Systemic arteries
- Capillaries in body tissues
- Returns deoxygenated blood back to the heart through systemic veins



Johnson & Johnson INSTITUTE

37

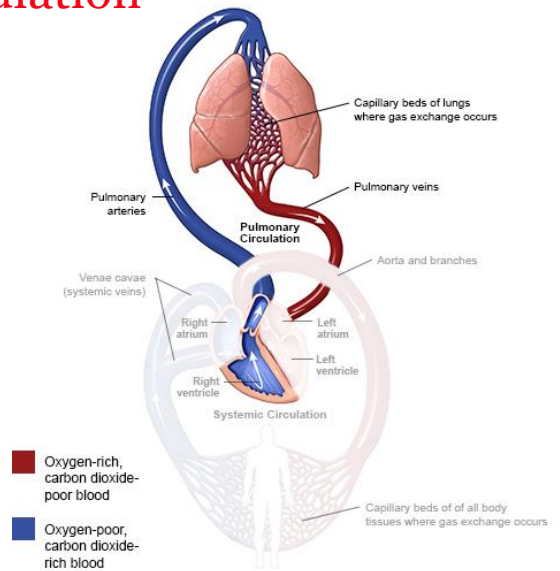
**SAY:** Systemic circulation carries oxygenated and nutrient-rich blood from the left ventricle of the heart, through systemic arteries to capillaries in the body's tissues, and then returns deoxygenated blood back to the heart through systemic veins. (Patton 2014/p399/c1/para2-c2/para1) (Marieb 2016/p729/c1/para3)

Image Reference: (Marieb 2016/p664/Figure 18.1)

# Systemic and Pulmonary Circulation

## Flow of blood in pulmonary circulation:

- Right ventricle of the heart
- Left and right pulmonary arteries
- Lungs for gas exchange



Johnson & Johnson INSTITUTE

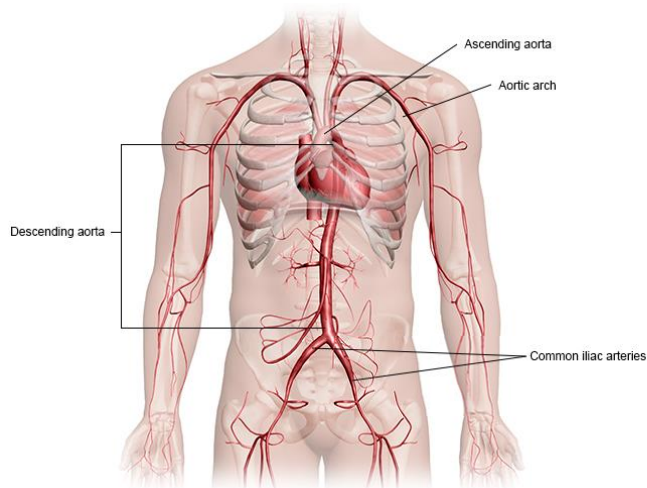
38

**SAY:** Pulmonary circulation brings blood from the right ventricle of the heart, through the left and right pulmonary arteries, to the lungs for gas exchange. (Marieb 2016/p728/c1/para1-2)

## The Aorta

The aorta can be divided into 3 main portions

1. Ascending aorta
2. Aortic arch
3. Descending aorta
  - Thoracic part
  - Abdominal part



Johnson & Johnson INSTITUTE

39

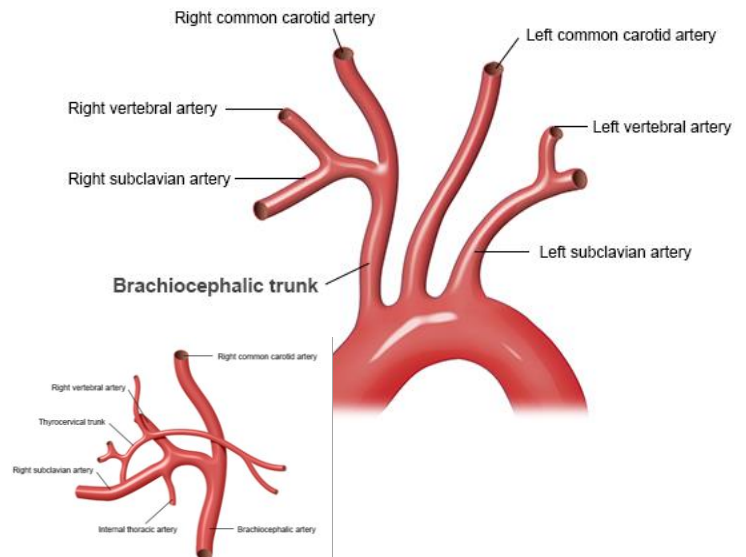
**SAY:** The aorta can be divided into 3 main portions. (SEER 2018/p2/para3):

The first portion is the ascending aorta, which begins where the aorta arises from the left ventricle of the heart. The second part begins as it then bends into the aortic arch. Finally, the third portion arises as it proceeds downward as the descending aorta through the upper thoracic part and the lower abdominal part. At that point, it divides into the 2 common iliac arteries, the internal and external. (Dorlands/aorta) (Taber's/artery/p7(external); p10(internal))

Image Reference: (Dorland's/aorta)

# Aortic Arch

- **Brachiocephalic trunk/artery**
  - Brachiocephalic artery or innominate artery
  - First and largest branch
  - Ascends beside the trachea
- **Common Carotid artery**
- **Subclavian artery**
  - Vertebral artery
  - Internal thoracic artery



Johnson & Johnson INSTITUTE

40

**SAY:** The brachiocephalic trunk, also called the brachiocephalic artery or the innominate artery, is the first and largest branch that arises from the aortic arch. (Osborn 1999/p12/c2/para2)

The brachiocephalic artery ascends beside the trachea, and branches into the right common carotid artery and the right subclavian artery (Osborn 1999/p12/c2/para2)

Arteries that further branch from the right subclavian artery are the right vertebral artery, the internal thoracic artery, and the thyrocervical artery. (Osborn 1999/p13/figure 1-7)

Image Reference: (Osborn 1999/p12/figure 1-6;p13/figure 1-7)



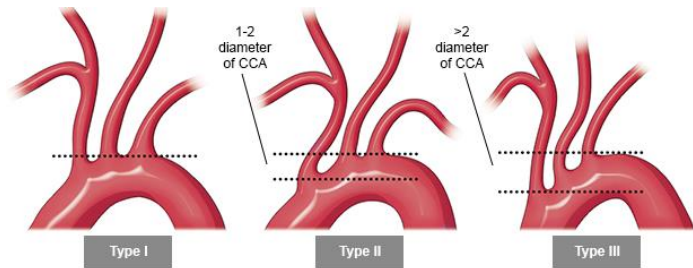
## Aortic Arch Types

- **Aortic arch differences**

- Important for designing and therapeutic interventions

- **Types**

- **Type I:** Distance from origin to top of the arch is  $<1$  diameter of the left common carotid artery
- **Type II:** Distance from origin to top of the arch is between 1 and 2 diameters of the left common carotid artery
- **Type III:** Distance from origin to top of the arch is  $>2$  diameters of the left common carotid art



**SAY:** Knowledge of the differences in each individual's aortic arch is important for surgeons and interventionalists (Demertzis 2010/p588/c1/para1) in designing and optimizing therapeutic intervention. (Demertzis 2010/p588/c2/para1).

One way the aortic arch can be described is by aortic arch type, which measures the vertical distance from the origin of the brachiocephalic trunk to the top of the arch. (Demertzis 2010/p589/c2/para1)

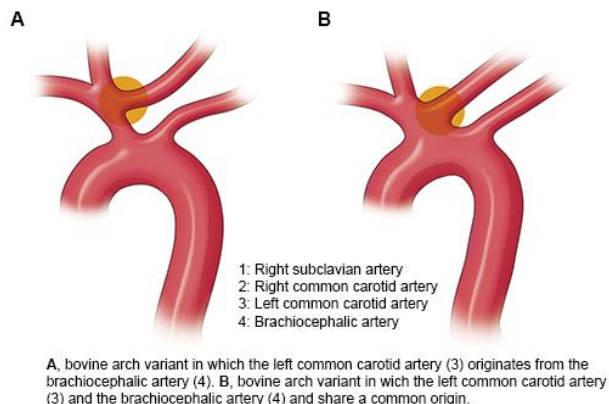
The 3 types are shown here

- First is the type I arch, where the distance from origin to top of the arch is  $<1$  diameter of the left common carotid artery.
- Next is the Type II arch, where the distance from origin to top of the arch is between 1 and 2 diameters of the left common carotid artery.
- Finally, there is the Type III arch, where the distance from origin to top of the arch is  $>2$  diameters of the left common carotid artery. (Demertzis 2010/p589/c2/para1)

Image Reference: (Demertzis 2010/p590/Figure3)

## Bovine Aortic Arch

- Bovine arch refers to anatomical variations in the configuration of the 3 vessels originating from the aortic arch
- Important for therapeutic interventions (e.g., stenting)
- Less usual variation (Figure A)
- More usual variation (Figure B)
- No resemblance to branching pattern found in cattle



Johnson & Johnson INSTITUTE

42

**SAY:** The bovine arch refers to anatomical variations in the configuration of the 3 vessels originating from the aortic arch. (Spacek 2012/p166/para1)

Knowledge of the aortic arch branching variations is important for therapeutic interventions, especially during stenting of the left internal carotid artery, which is performed by passage through the bovine arch. (Spacek 2012/p166/para3)

In the less usual variation, or about 7% of the population, the brachiocephalic artery trifurcates into the left common carotid artery, the right common carotid artery and the right subclavian artery, shown in Figure A here. (Spacek 2012/p166/para1)

In the more usual variation, or about 20% of the population, the brachiocephalic artery and the left common carotid artery share a common origin, shown in Figure B here. (Spacek 2012/p166/para1)

Note that the name of the bovine arch is a common misnomer in medical literature. The anatomical configuration it describes in humans does not have any resemblance with the aortic arch branching pattern found in cattle. (Layton 2006/p1541/c1/para1).

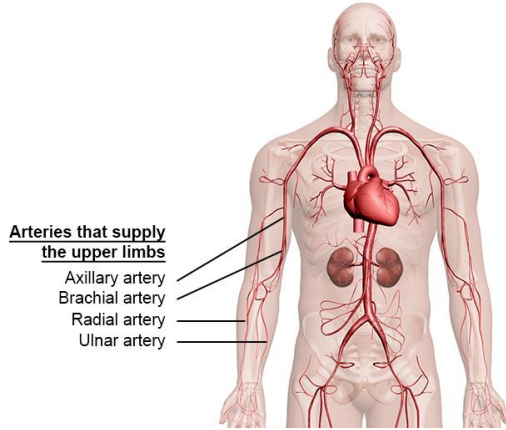
Instead, it is believed to have been named for the resemblance the pattern has to a bovine's head and horns. (Spacek 2012/p166/para2; p167/Figure2).

Image Reference: (Spacek 2012/p167/Figure 1)

# Blood Supply to the Limbs

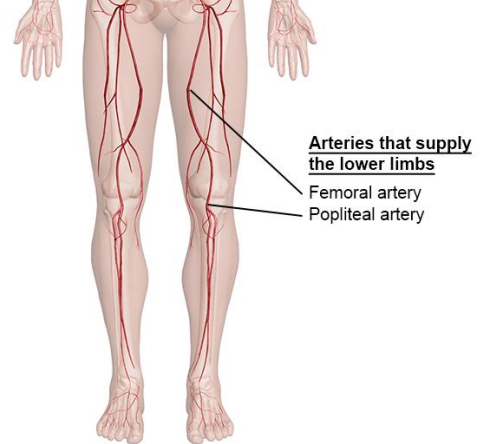
## Brachial Artery

– Major artery of upper arm



## Femoral Artery

– Major artery of thigh



Johnson & Johnson INSTITUTE

43

**SAY:** The brachial artery is the major arterial supply of the upper arm. (Patton 2014/p395/Table 15-1) It is the continuation of the axillary artery. At the point of the elbow joint, it divides into the ulnar and radial arteries. (Stedmans/brachial artery) (Marieb 2016/p731/Figure 19.4)

The femoral artery is the major arterial supply of the thigh. (Patton 2014/p395/Table 15-1)(Marieb 2016/p740/c2/para4) Near the knee, the femoral artery passes posteriorly and through a gap in the muscle, where its name changes to the popliteal artery. (Figure 2.1, Table 2.1). (Marieb 2016/p740/c2/para4)

Image Reference: (Marieb 2016/p731/Figure 19.4)

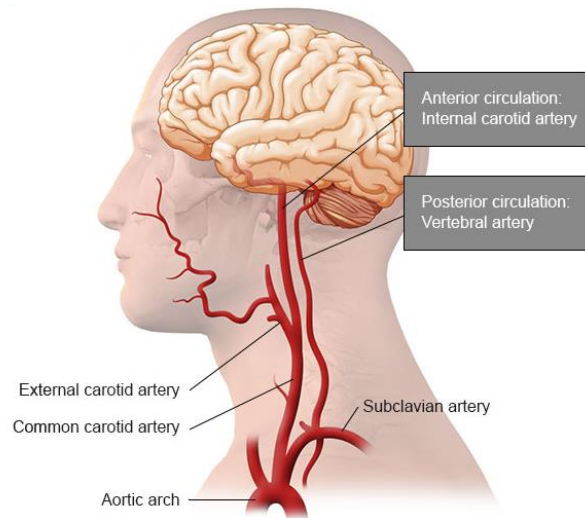
## Major Arterial Supply of Upper and Lower Extremities

Major Arterial Supply of Upper and Lower Extremities		
	Artery	Tissues Supplied
Upper Extremity	Axillary	Armpit
	Brachial	Arm
	Radial	Hand, lateral side
	Ulnar	Hand, medial side
Lower Extremity	Internal iliac	Pelvic viscera, genitalia, rectum
	External iliac	Lower trunk and lower extremities
	Deep femoral	Deep thigh muscles
	Femoral	Thigh
	Popliteal	Knee and leg
	Anterior tibial and posterior tibial	Leg

**SAY:** These are the major arteries that supply the upper and lower extremities.

Image Reference: (Patton 2015/p395/Table 15-1)

## Blood Supply to the Brain



Johnson & Johnson INSTITUTE

45

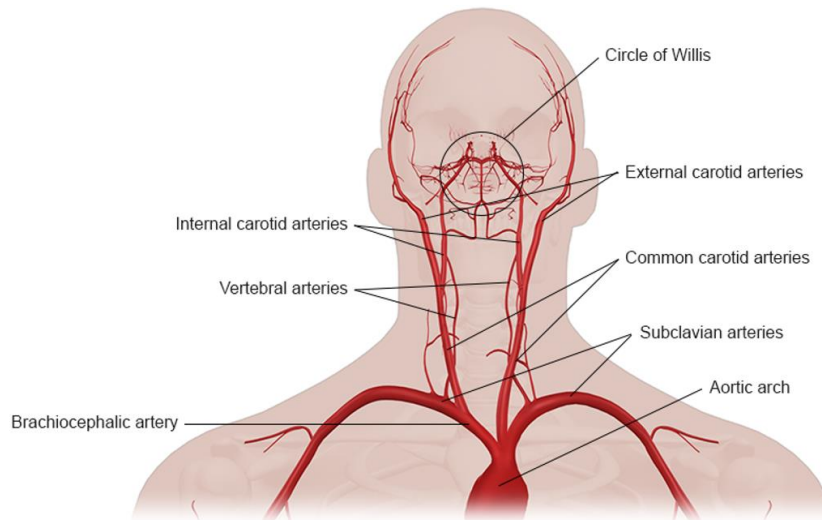
**SAY:** The brain receives its arterial blood supply from 2 sources:

- The internal carotid arteries, known as anterior circulation
- The vertebral arteries, known as posterior circulation (Brain in Morton 2011/p5/para3)

Anterior and posterior circulation will be covered in greater detail in Lesson 3 and Lesson 4. Here, we will begin with an overview of the arteries that make up these circuits.

Image Reference: (Purves 2012/p736/Figure A15A)

## Blood Supply to the Brain



Johnson & Johnson INSTITUTE

46

**SAY:** The left and right common carotid arteries branch to the internal and external carotid arteries.

The internal carotid arteries enter the base of the skull, whereas the external carotid arteries send branches to the neck and face. (Brain in Morton 2011/p5/para4)

The left subclavian artery arises from the aortic arch, and rises to the neck before descending toward the ribs. (Osborn 1999/p15/c1/para1)

The vertebral artery arises from the brachiocephalic artery on the right and the subclavian artery on the left.

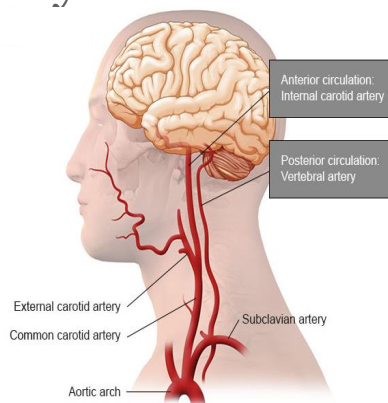
It has 4 segments, and only the fourth, called V4, gives rise to branches that supply the brainstem and cerebellum. (Smith in Harrison's 2014/p46/para5) A branch of the subclavian artery is the thyrocervical trunk. (Osborn 1999/p28/c2/para3)

Image Reference: (Purves 2012/p736/FigureA15A)

## Lesson 3: Anterior Circulation

### The Internal Carotid Artery

In this lesson, the anterior circulation of the brain will be reviewed



Johnson & Johnson INSTITUTE

47

**SAY:** Recall that the vascular networks that supply blood to the brain can be divided into 2 systems based on the anatomical regions of the brain that they supply: (Purves 2012/p736/c1/TableA4/para1-c2/para1)

- Anterior portions of the brain are supplied by the anterior circulation, formed from the major branches that arise from the internal carotid arteries
- Posterior portions of the brain are supplied by the posterior circulation, formed from the major branches of the vertebrobasilar system

The anterior and posterior circulation of the brain will be reviewed in the following 2 lessons. Let's start by discussing the anterior circulation.

Image Reference: (Purves 2012/p736/FigureA15A)

## Lesson 3: Learning Objectives

- List the segments and major branches of the internal carotid artery
- Name the artery that joins the anterior and posterior circulations
- Identify the segments and major branches of the anterior cerebral artery
- Name the artery that connects the 2 anterior cerebral arteries from each hemisphere
- Identify the segments and major divisions of the middle cerebral artery
- Name the group of small arteries that arises from the middle cerebral artery
- Identify the brain regions that are supplied by the anterior and middle cerebral arteries

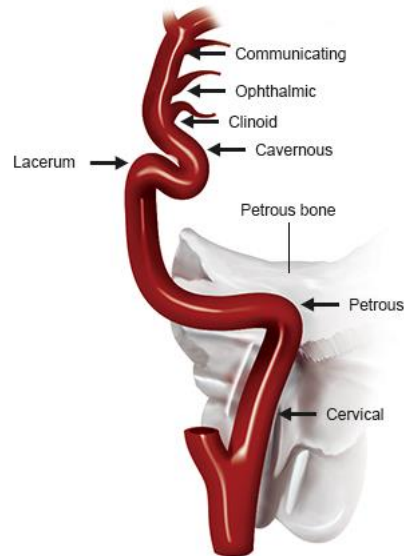
**SAY:** Please take a moment to review the learning objectives for this section.



## Internal Carotid Artery

- 1 of 2 pairs of arteries that supply blood to the brain
- 80% of the brain supplied
- 7 segments:
  - Cervical
  - Petrous
  - Lacerum
  - Cavernous
  - Clinoid
  - Ophthalmic
  - Communicating

Segments of the Internal Carotid Artery



Johnson & Johnson INSTITUTE

49

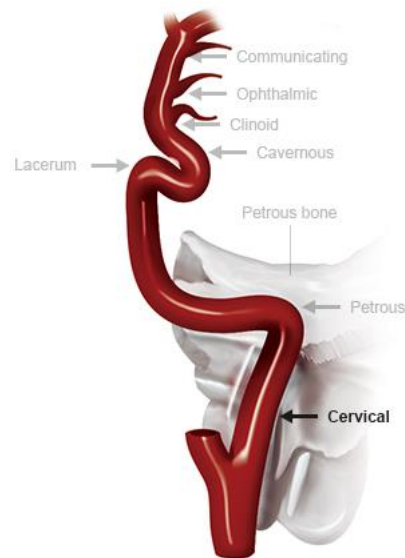
**SAY:** The internal carotid arteries are 1 of the 2 pairs of arteries that supply blood to the entire brain. The internal carotid arteries arise from the common carotid arteries to supply about 80% of the brain, including the cerebral hemispheres and diencephalon. (Vanderah 2016/p126/c2/para2) (Osborn 1999/p57/c1/para1; c2/para3)

The internal carotid artery can be divided into 7 anatomically distinct segments shown here. (Osborn 1999/p57/c1/para2)

Image Reference: (Osborn 1999/p58/c1/Figure 3-1; p72/Figure 3-19)

## Cervical Segment

- Only extracranial segment
- Prone atherosclerotic disease
- Common problems
  - Coiling or complete looping
  - Fibromuscular dysplasia



Johnson & Johnson INSTITUTE

50

**SAY:** The cervical segment of the internal carotid artery is the only extracranial segment. It ends at the base of the skull and is prone to atherosclerotic disease. (Osborn 1999/p58/c2/para2; p59/c1/para2; p361/c1/para5,6) (Cloud 2003/p27/c1/para1)

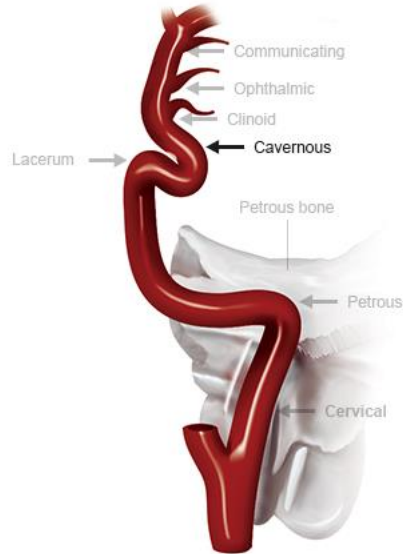
Some of the common problems that can occur in the cervical segment include:

- Coiling or complete looping of the cervical segment, and (Osborn 1999/p63/c1/para2)
- Fibromuscular dysplasia of the cervical segment (Bhuriya 2008/p41/c1/para1)

## Cavernous Segment

### Three subsegments:

1. Posterior ascending segment
2. Longer horizontal segment
3. Shorter anterior vertical segment



Johnson & Johnson INSTITUTE

51

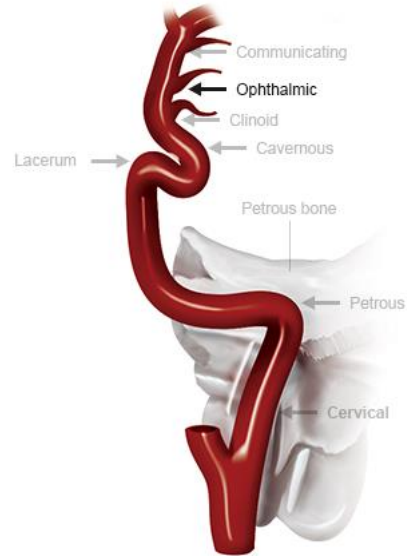
**SAY:** The cavernous segment of the internal carotid artery is made up of 3 subsegments: (Osborn 1999/p83/c1/para2)

- A posterior ascending segment,
- A longer horizontal segment, and
- A shorter anterior vertical segment

# Ophthalmic Segment

## Two Branches:

1. Ophthalmic artery
  - First major intracranial branch of the internal carotid artery
  - Travels through the optic canal
  - Supplies the retina, orbit, and part of the scalp
2. Superior hypophyseal artery



Johnson & Johnson INSTITUTE

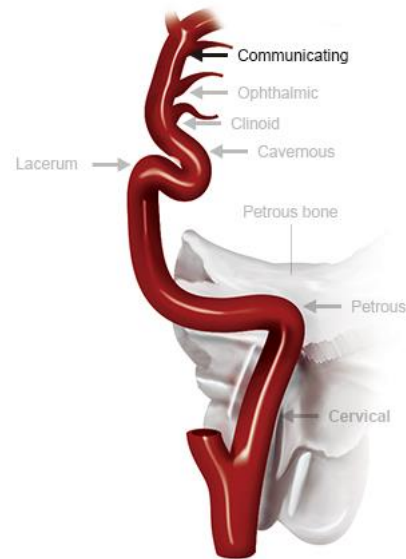
52

**SAY:** The ophthalmic segment of the internal carotid artery has 2 branches. (Osborn 1999/p96/c2/para2) The first is the ophthalmic artery. It is the first major intracranial branch of the internal carotid artery and travels through the optic canal to supply the retina, orbit, and part of the scalp. (Osborn 1999/p96/c2/para3) (Brain in Morton 2011/p5/para5) The second branch is the superior hypophyseal artery. (Osborn 1999/p96/c2/para2)

# Communicating

## 2 Branches:

1. Posterior communicating artery
  - Connects the anterior and posterior circulations
  
2. Anterior choroidal artery
  - Ends at division into
    - Anterior artery
    - Middle cerebral artery



Johnson & Johnson INSTITUTE

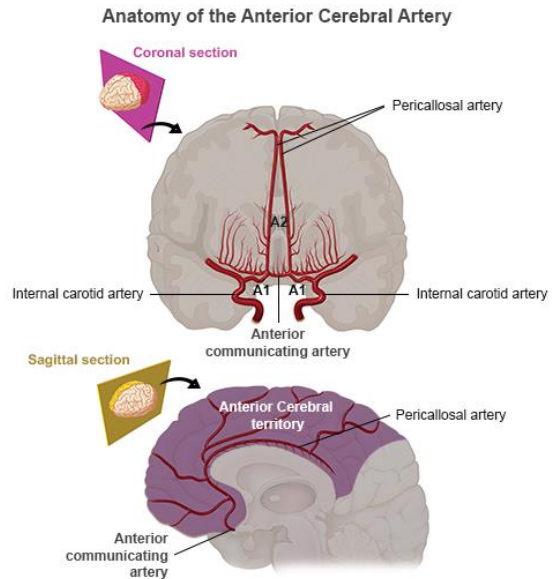
53

**SAY:** The communicating segment of the internal carotid artery has 2 branches. (Osborn 1999/p99/c2/para3) The first is the posterior communicating artery. By connecting to the posterior cerebral artery, a branch of the vertebrobasilar system, the posterior communicating artery connects the anterior and posterior circulations. (Osborn 1999/pp99/c2/para4) The second branch is the anterior choroidal artery. (Osborn 1999/p99/c2/para3)

This segment ends at the division of the internal carotid artery into its 2 terminal branches, the anterior and middle cerebral arteries. (Osborn 1999/p99/c1/last para)

## Anterior Cerebral Artery

- Smaller terminal branch of internal carotid artery
- Each artery supplies medial (middle) surface of the anterior 2/3 (frontal and parietal lobes) of its cerebral hemisphere
- Anterior cerebral arteries from each hemisphere connect via the anterior communicating artery at cerebrum base



Johnson & Johnson INSTITUTE

54

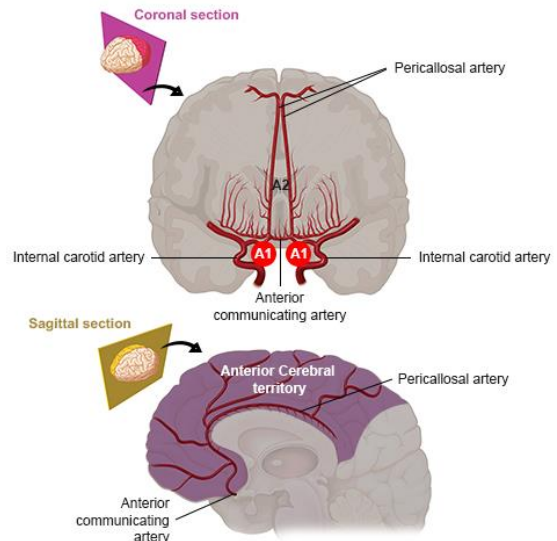
**SAY:** The anterior cerebral artery is the smaller of the 2 terminal branches of the internal carotid artery. (Osborn 1999/p117/c2/last para; p119/c1/para1) Each anterior cerebral artery supplies the medial, also called the middle, surface of the anterior two thirds, or the frontal and parietal lobes, of its cerebral hemisphere. (Marieb 2016/p732/c2/para4) (Osborn 1999/p131/c1/para2) The anterior cerebral arteries from each hemisphere are connected via the anterior communicating artery, a short artery at the base of the cerebrum. (Osborn 1999/p119/c2/para1; Figure 6-2/legend)

Image Reference: (Osborn 1999/p118/Figure 6-1; p119/Figure 6-2) (Vanderah 2016/p131/Figure 6-4 A)

# Anterior Cerebral Artery

## 3 Segments

- A1
  - Precommunicating segment
  - Extends horizontally from the beginning of the anterior cerebral artery to its junction with the anterior communicating artery.
- A2
  - Postcommunicating segment
  - Extends vertical from the anterior communicating artery
- A3
  - Divides into 2 main arteries
  - Pericallosal artery is the larger artery



Johnson & Johnson INSTITUTE

55

**SAY:** The anterior cerebral artery can be divided into 3 segments, A1-A3.

The A1 and A2 segments are also connected by the anterior communicating artery at the base of the cerebrum. (Osborn 1999/p117/c1/para3; p119/c1/para2,3; Figure 6-2/legend)

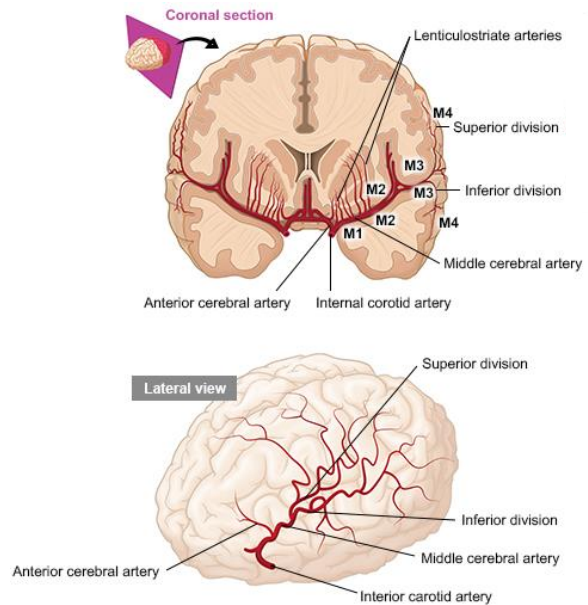
The A1 segment is called the pre-communicating segment and extends horizontally from the beginning of the anterior cerebral artery to its junction with the anterior communicating artery. (Osborn 1999/p117/c1/para3; p119/c1/para2,3)

The A2 segment is called the postcommunicating segment and extends vertical from the anterior communicating artery. (Osborn 1999/p119/c1/para3)

The A3 segment divides into 2 main arteries. The larger of the 2 is the pericallosal artery, which represents the continuation of the main anterior cerebral artery trunk. It travels posteriorly through the brain. (Osborn 1999/p130/c2/para5)

## Middle Cerebral Artery

- Larger branch of the internal carotid artery
- Twice the size of the anterior cerebral artery
- Supplies most of the lateral (side) surface of the cerebral hemispheres
- 4 segments:
  - M1: Horizontal segment
  - M2: Insular segment
  - M3: Opercular segment
  - M4: Cortical segment



Johnson & Johnson INSTITUTE

56

**SAY:** The middle cerebral artery is the larger of the 2 terminal branches of the internal carotid artery. It is approximately twice the size of the anterior cerebral artery. The middle cerebral arteries supply most of the lateral, or side, surface of the cerebral hemispheres. (Osborn 1999/p135/c1/para1; p137/c2/para1)

The middle cerebral artery can be divided into 4 segments: (Osborn 1999/p135/c1/para1,2)

- The M1: Horizontal segment,
- The M2: Insular segment,
- The M3: Opercular segment, and
- The M4: Cortical segment

Image Reference: (Osborn 1999/p136/Figure 7-1) (Vanderah 2016/p131/Figure 6-4 B) (Zivin 2008/p2703/c1/last para)



# M1 Segment

## Lenticulostriate Arteries

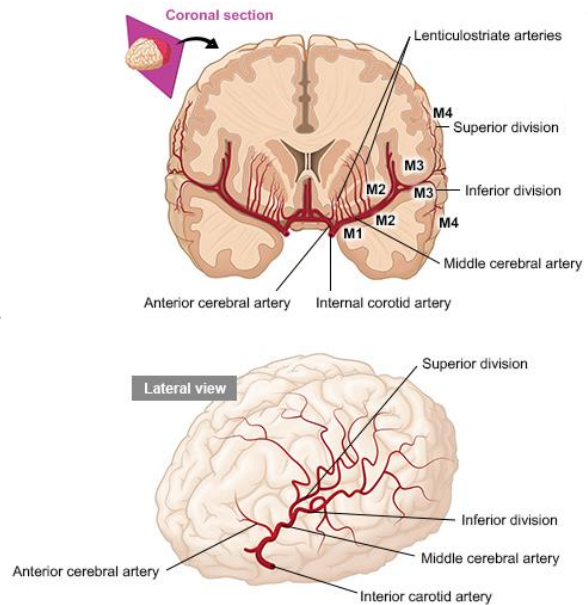
- Before the M1 segment of the middle cerebral artery divides, a number of small arteries arise, called the **lenticulostriate arteries**. These arteries supply the deep lying structures of the brain

## Superior Division

- The M1 segment of the middle cerebral artery typically divides into a superior and inferior division. The superior division supplies the frontal and superior parietal lobes

## Lenticulostriate Arteries

- The inferior division of the M1 segment supplies the temporal and inferior parietal lobes



Johnson & Johnson INSTITUTE

57

**SAY:** Before the M1 segment of the middle cerebral artery divides, a number of small arteries arise, called the **lenticulostriate arteries**. These arteries supply the deep lying structures of the brain

The M1 segment of the middle cerebral artery typically divides into a superior and inferior division. (Osborn 1999/p 138/c1/para1) (Zivin 2008/p2703/c1/last para)

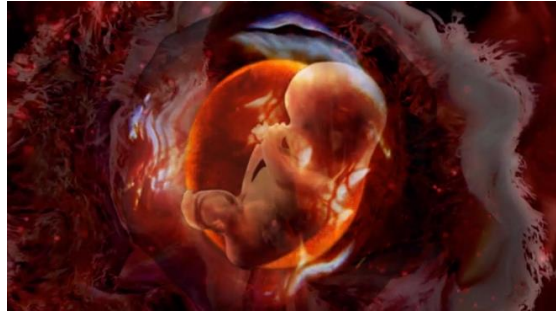The superior division supplies the frontal and superior parietal lobes. The inferior division of the M1 segment supplies the temporal and inferior parietal lobes. (Zevin 2008/p2703/c1/last para)

The inferior division supplies the temporal and inferior parietal lobes. (Zivin 2008/p2703/c1/last para)

## Lesson 4: Posterior Circulation

### The Vertebrobasilar System

In this lesson, the posterior circulation of the brain will be reviewed



Johnson & Johnson INSTITUTE

58

**SAY:** As the occipital lobe and brainstem grow during embryonic development, the formation of the posterior circulation is initiated. The basilar arteries are formed first when the embryo is just 4 to 5 millimeters, followed by the vertebral arteries, when the embryo is 7 to 12 millimeters. (Menshawi 2015/p145/c2/last para-p146/c1/para1)

The vertebrobasilar system primarily supplies blood to the posterior regions of the brain, including the brainstem, cerebellum, as well as parts of the diencephalon, and the occipital and temporal lobes. (Vanderah 2016/p126/c2/para2-p127/c1/para1)

Posterior circulation will be discussed in this lesson

## Lesson 4: Learning Objectives

- Name the 2 main arteries that supply the posterior regions of the brain
- Identify the location of the vertebral arteries and their branches
- Identify the location of the basilar arteries and their branches
- Recognize the function of the circle of Willis

**SAY:** Please take a moment to review the learning objectives for this lesson.

## Posterior Circulation

Which of the following primarily supplies the posterior regions of the brain?

- a) Anterior choroidal artery
- b) Anterior cerebral artery
- c) Middle cerebral artery
- d) Vertebral artery

1. Brain in Morton 2011/p5/para3

**SAY:** Which artery primarily supplies the posterior regions of the brain?

## Posterior Circulation

Which of the following primarily supplies the posterior regions of the brain? <sup>1</sup>

- a) Anterior choroidal artery
- b) Anterior cerebral artery
- c) Middle cerebral artery
- d) Vertebral artery**

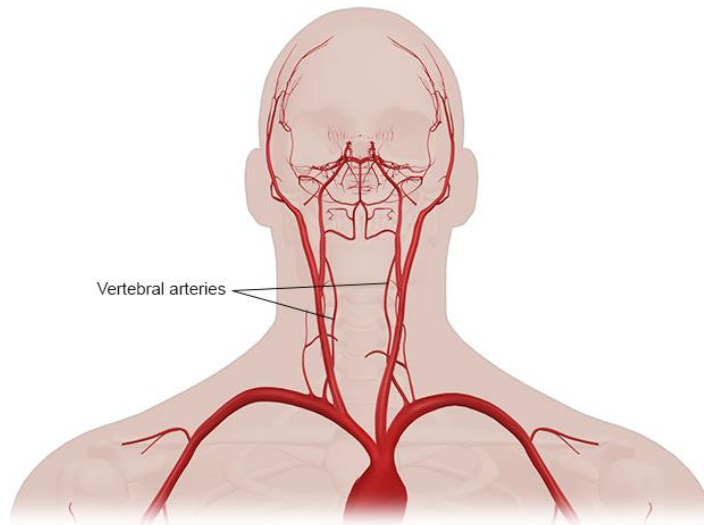
1. Brain in Morton 2011/p5/para3

**SAY:** That's correct. The vertebral artery primarily supplies the posterior regions of the brain

OR

That's incorrect. The vertebral artery primarily supplies the posterior regions of the brain

## Vertebral Arteries



Johnson & Johnson INSTITUTE

62

**SAY:** The Vertebral arteries are 1 of 2 pairs of arteries that supply blood to the entire brain (the other is the internal carotid arteries). (Vanderah 2016/p126/c2/para2)

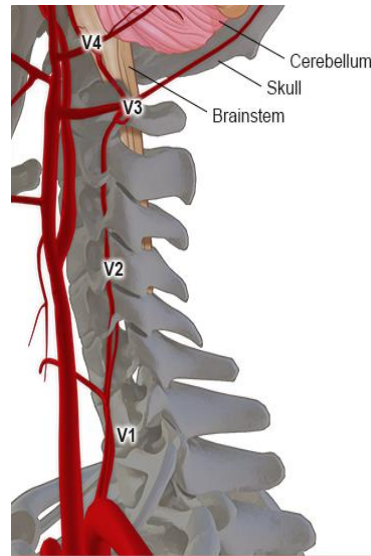
The Vertebral arteries arise from the subclavian arteries and run along the anterior surface of the brainstem. (Marieb 2016/p732/c2/last para) (Vanderah 2016/p130/c1/last para)

Image Reference: (Purves 2012/p736/Figure 15A)

## Vertebral Arteries

Divided into 4 **Segments**:

- Three extracranial segments (V1-V3)
- One intracranial segment (V4)



Johnson & Johnson INSTITUTE

63

**SAY:** Each vertebral artery is divided into 4 segments known as V1 through V4.

V1 through V3 are extracranial segments, while V4 is an intracranial segment. (Exaire 2004/p1/para5)

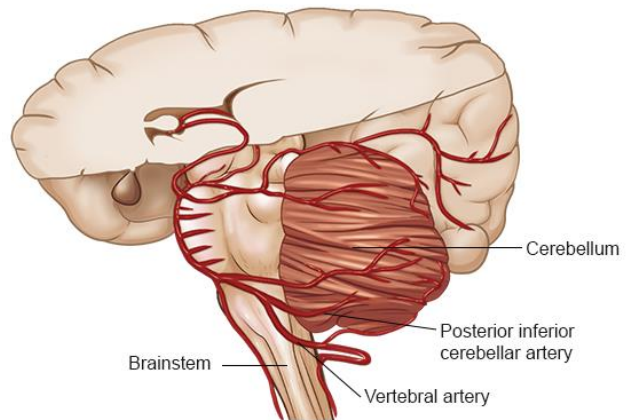
The V4 segment of the vertebral artery enters the cranium by piercing the dura and arachnoid mater at the base of the skull. (Exaire 2004/p1/para5)

Image Reference: (Osborn 1999/p175/Figure 9-1A)

## Vertebral Arteries

### Branches of the Vertebral Arteries:

- Posterior Inferior Cerebellar Arteries
  - Supply much of the inferior surface of the cerebellum



Johnson & Johnson INSTITUTE

64

**SAY:** Once inside the cranium, each vertebral artery branches to give rise to the posterior inferior cerebellar artery.

The posterior inferior cerebellar artery, as its name implies, supplies much of the inferior surface of the cerebellum. (Vanderah 2016/p130/c2/last para; p132/c2/para1)

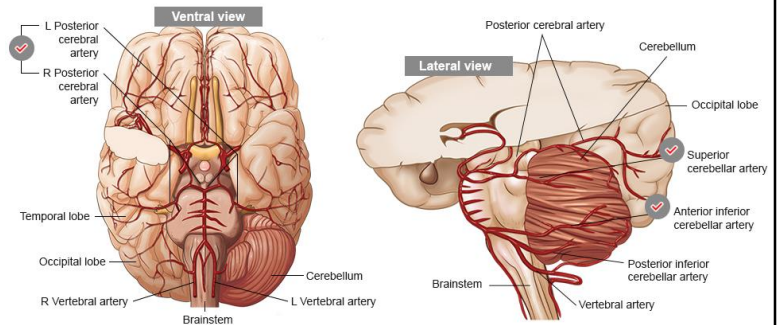
Image Reference: (Brain in Morton 2011/p6/Figure 16-3 C) (Marieb 2016/p733/Figure 19.22 D) (Osborn 1999/p177/Figure 9-3; p178/Figure 9-4)



## Basilar Artery

The right and left vertebral arteries fuse to form the midline basilar artery

- Anterior Inferior Cerebellar Arteries
  - supply the cerebellum, parts of the brainstem, and the inner ear
- Superior Cerebellar Arteries
  - travel along the superior surface of the cerebellum
  - supply the cerebellum, parts of the brainstem, and the inner ear
- Posterior Cerebral Arteries
  - supply the medial and inferior surfaces of the occipital and temporal lobes.



Johnson & Johnson INSTITUTE

65

**SAY:** The right and left vertebral arteries fuse to form the midline basilar artery. (Marieb 2016/p733/c1/para1) The basilar artery continues to ascend along the surface of the brainstem. (Vanderah 2016/p130/c1/last para-c2/para1)

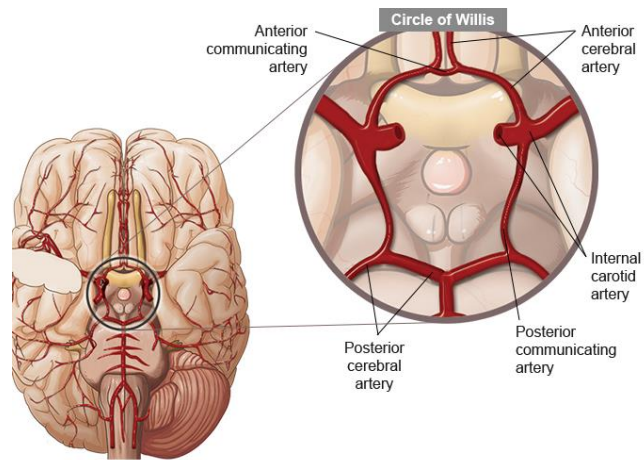
The **anterior inferior cerebellar arteries** travel along the inferior surface of the cerebellum. (Brain in Morton 2011/p6/last para) They supply the cerebellum, parts of the brainstem, and the inner ear. (Marieb 2016/p733/c1/para1-c2) (Vanderah 2016/p132/c2/para1)

The **superior cerebellar arteries** travel along the superior surface of the cerebellum. (Brain in Morton 2011/p7/para1) They supply the cerebellum, parts of the brainstem, and the inner ear. (Marieb 2016/p733/c1/para1-c2/para2) (Vanderah 2016/p132/c2/para1)

Near the top of the brainstem, the basilar artery divides into a pair of **posterior cerebral arteries** that supply the medial and inferior surfaces of the occipital and temporal lobes. (Vanderah 2016/p132/c2/para1; p133//c2/para1)

## Circle of Willis

- Arterial polygon at the base of the brain that consists of parts of:
  - Internal carotid artery
  - Anterior cerebral artery
  - Posterior cerebral artery
- Allows for blood to be rerouted in the event of a major artery blockage
- Ensures similar blood pressure throughout brain



Johnson & Johnson INSTITUTE

66

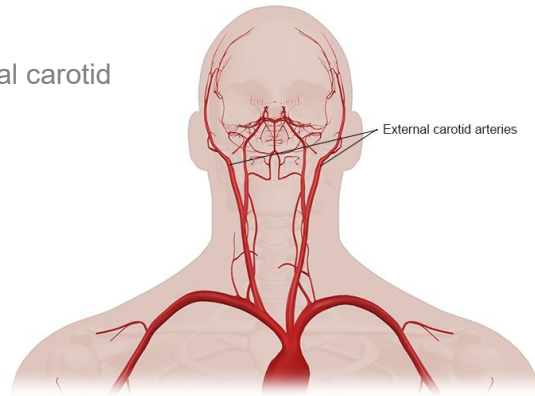
**SAY:** The Circle of Willis, or cerebral arterial circle, is the arterial polygon at the base of the brain that consists of parts of the internal carotid, anterior cerebral, and the posterior cerebral arteries, interconnected by the anterior and posterior communicating arteries. Therefore, through the Circle of Willis, the arteries that deliver blood to the entire brain are joined to create a single vascular network. (Vanderah 2016/p134/c1/para1)

The Circle of Willis also functions as a safety valve by providing a mechanism for blood to be rerouted in the event that one of the major arteries is blocked. In addition, these connections ensure that blood pressure will be similar throughout the brain. (Marieb 2016/p733/c2/para2) (Vanderah 2016/p134/c1/para1)

Image Reference: (Marieb 2016/p733/Figure 19.22 D) (Vanderah 2016/p134/Figure 6-11)

## Lesson 5: The External Carotid Artery and Its Major Branches

In this lesson, we'll discuss the external carotid artery and its major branches



Johnson & Johnson INSTITUTE

67

**SAY:** The external carotid artery is the smaller of the 2 terminal branches of the common carotid artery; the other is the internal carotid artery. The external carotid artery delivers blood to most of the tissues in the head and neck, except for the brain and eye. It also has many important connections with the internal carotid arteries and the vertebrobasilar system. (Osborn 1999/p31/c1/para1,2)

The external carotid artery will be discussed in detail in this lesson.

Image Reference: (Purves 2012/p736/FigureA15A)

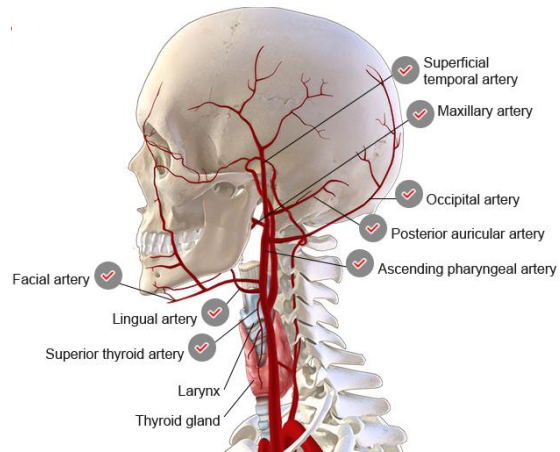
## Lesson 5: Learning Objectives

- List the branches of the external carotid artery
- Identify the regions of the head and neck that are supplied by the branches of the external carotid artery
- Define collateral circulation and its functional importance

**SAY:** Please take a moment to review the learning objectives for this lesson.

## External Carotid Artery

- 8 Major Branches:
  - Superior thyroid artery
  - Ascending pharyngeal artery
  - Lingual artery
  - Facial artery
  - Occipital artery
  - Posterior auricular artery
  - Maxillary artery
  - Superficial temporal artery
- Mnemonic:
  - **S**ome **A**natomists **L**ike **F**reaking **O**ut **P**oor **M**edical **S**tudents



Johnson & Johnson INSTITUTE

69

**SAY:** As shown here, the external carotid artery runs toward to the top of the skull. The main trunk rapidly decreases in size as it gives off branches to the tongue, face, and neck. It ends by dividing into 2 main branches. (Osborn 1999/p37/c1/last para-c2/para1)

There are 8 major branches of the external carotid artery. (Osborn 1999/p37/c1/last para;c2/Box/branches) There is a mnemonic phrase that exists to help you remember these branches. The first letter of each word in the phrase corresponds to 1 of the 8 branches of the external carotid artery. The mnemonic is: Some Anatomists Like Freaking Out Poor Medical Students.

Image Reference: (Osborn 1999/p37/Figure 2-8) (Marieb 2016/p733/Figure 19.22 B)

## External Carotid Artery

Which of the following are branches of the external carotid artery?

- a) Basilar artery
- b) Facial artery
- c) Posterior auricular artery
- d) Superior thyroid artery
- e) Vertebral artery

Mnemonic:

**Some Anatomists Like Freaking Ot Poor Medical Students.**

**SAY:** Let's try it out. Based only on the mnemonic, can you tell which of the following are branches of the external carotid artery?

## External Carotid Artery

Which of the following are branches of the external carotid artery?

- a) Basilar artery
- b) **F**acial artery
- c) **P**osterior auricular artery
- d) **S**uperior thyroid artery
- e) Vertebral artery

Mnemonic:

**S**ome **A**natomists **L**ike **F**reaking **O**ut **P**oor **M**edical **S**tudents.

**SAY:** That's correct. The Facial, Posterior auricular, and Superior thyroid arteries are branches of the external carotid artery.

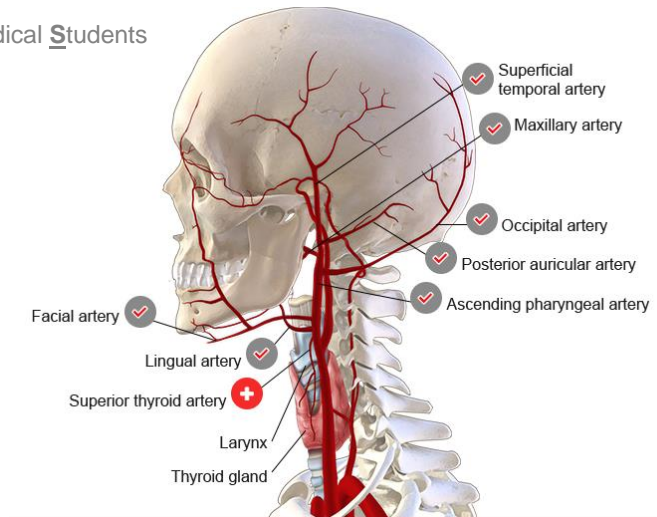
OR

**SAY:** That's incorrect. The Facial, Posterior auricular, and Superior thyroid arteries are branches of the external carotid artery.

## Superior Thyroid Artery

Some Anatomists Like Freaking Out Poor Medical Students

- The first branch to arise from the anterior wall of the external carotid artery
- Travels down toward the thyroid gland and supplies the larynx and the upper portion of the thyroid gland



Johnson & Johnson INSTITUTE

72

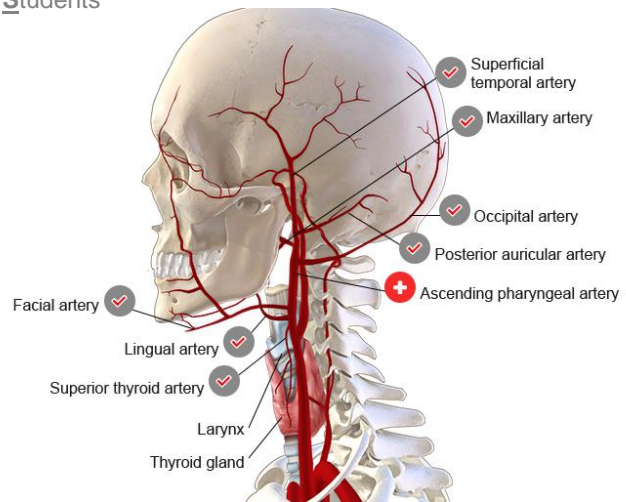
**SAY:** The superior thyroid artery is the first branch to arise from the anterior wall of the external carotid artery. It travels down toward the thyroid gland and supplies the **larynx** and the upper portion of the **thyroid gland**. (Osborn 1999/p37/c1/para2;p38/c1/para2)



## Ascending Pharyngeal Artery

Some Anatomists Like Freaking Out Poor Medical Students

- Smallest branch of the external carotid artery
- First to arise from it's posterior wall of the external carotid artery
- Ascends to supply the pharynx, middle ear, and the dura



Johnson & Johnson INSTITUTE

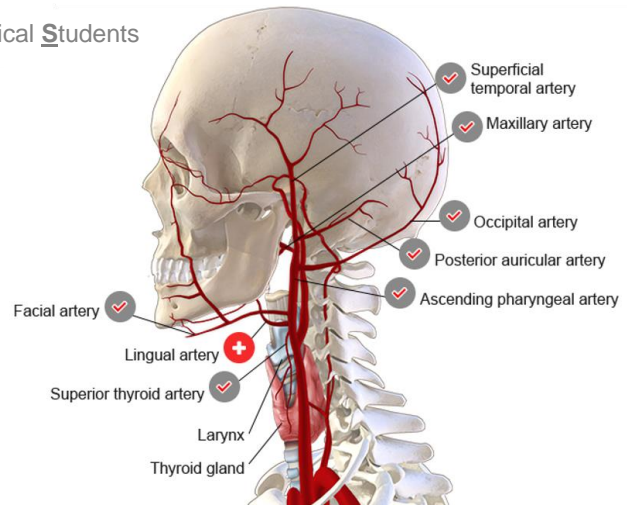
73

**SAY:** The ascending pharyngeal artery is the smallest branch of the external carotid artery. It is the first to arise from its posterior wall of the external carotid artery and ascends to supply the pharynx, middle ear, and the dura. (Osborn 1999/p38/c1/last para-c2/para1)

## Lingual Artery

Some Anatomists Like Freaking Out Poor Medical Students

- Second anterior branch of the external carotid artery
- Supplies the tongue and mouth



*Johnson & Johnson* INSTITUTE

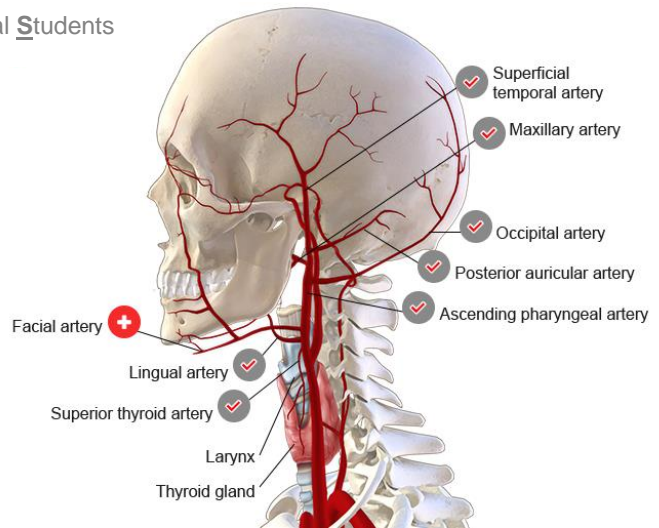
74

**SAY:** The lingual artery is the second anterior branch of the external carotid artery. It supplies the tongue and mouth. (Osborn 1999/p39/c1/para2)

## Facial Artery

Some Anatomists Like Freaking Out Poor Medical Students

- Third anterior branch of the external carotid artery
- Travels toward the lower jaw and also across the cheek to terminate near the eye
- Supplies most of the face, palate, lips, and cheeks



Johnson & Johnson INSTITUTE

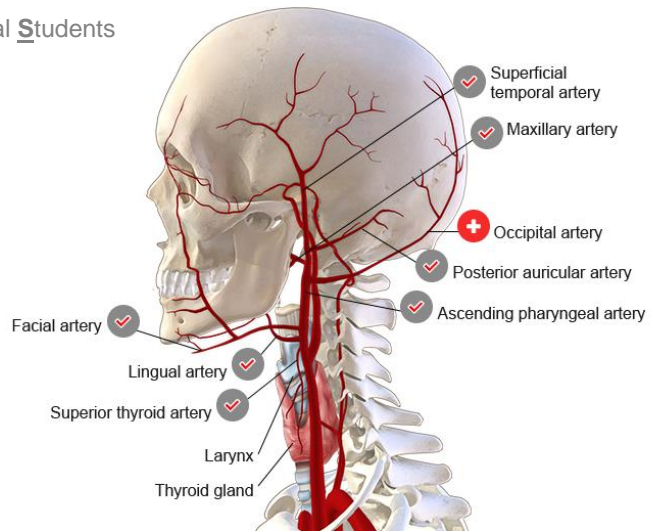
75

**SAY:** The facial artery is the third anterior branch of the external carotid artery. It travels toward the lower jaw and also across the cheek to terminate near the eye. It supplies most of the face, palate, lips, and cheeks. (Osborn 1999/p39/c1/para3-6)

## Occipital Artery

Some Anatomists Like Freaking Out Poor Medical Students

- Second and largest posterior branch of the carotid artery
- Travels toward the back of the head to supply the posterior neck and scalp as well as the dura



Johnson & Johnson INSTITUTE

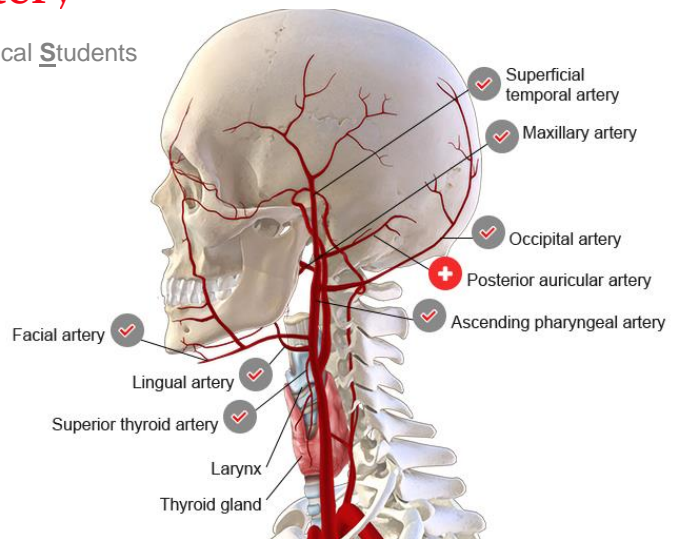
76

**SAY:** The occipital artery is the second and largest posterior branch of the external carotid artery. It travels toward the back of the head to supply the posterior neck and scalp as well as some of the dura. (Osborn 1999/p39/c1/para7,8; p45/c2/para2)

## Posterior Auricular Artery

Some Anatomists Like Freaking Out Poor Medical Students

- 3<sup>rd</sup> small posterior branch of the external carotid artery
- Travels toward the back of the head to supply the scalp and external parts of the ear



Johnson & Johnson INSTITUTE

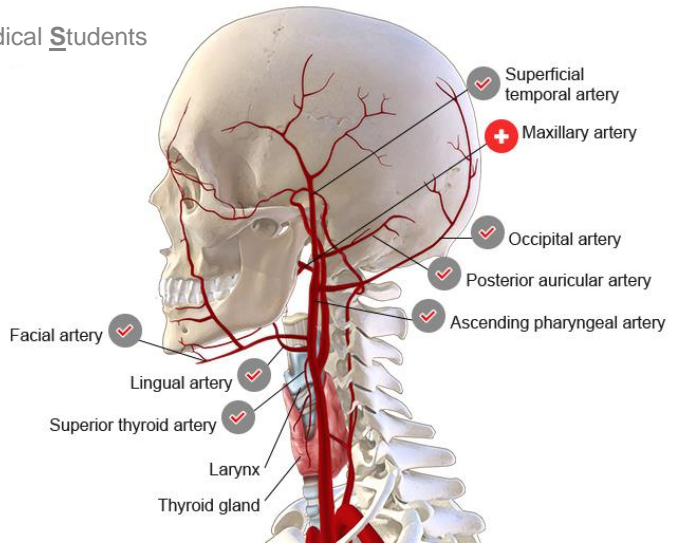
77

**SAY:** The posterior auricular artery is the third small posterior branch of the external carotid artery. It also travels toward the back of the head to supply the scalp and external parts of the ear. (Osborn 1999/p39/c2/para2)

## Maxillary Artery

Some Anatomists Like Freaking Out Poor Medical Students

- The larger terminal branch of the external carotid artery
- Arises behind the lower jaw and travels forward toward the middle of the head to supply the upper and lower jaw, deep facial areas, and the nasal cavity



Johnson & Johnson INSTITUTE

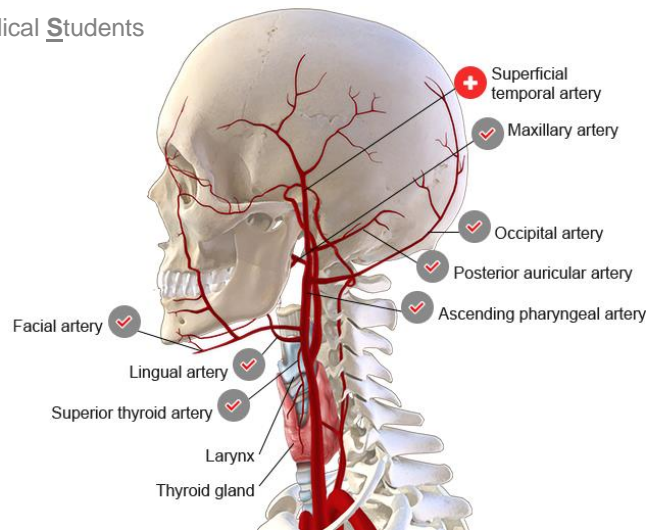
78

**SAY:** The maxillary artery (sometimes called the internal maxillary artery) is the larger terminal branch of the external carotid artery. It arises behind the lower jaw and travels forward toward the middle of the head to supply the upper and lower jaw, deep facial areas, and the nasal cavity. (Osborn 1999/p39/c2/para5) (Marieb 2016/p732/c2/para3)

## Superior Temporal Artery

Some Anatomists Like Freaking Out Poor Medical Students

- The other, smaller terminal branch of the external carotid artery
- It becomes more superficial to supply the anterior two thirds of the scalp, parts of the ear, and the parotid salivary gland



Johnson & Johnson INSTITUTE

79

**SAY:** The superior temporal artery is the other, smaller terminal branch of the external carotid artery. As the superior temporal artery ascends it becomes more superficial to supply the anterior two thirds of the scalp, parts of the ear, and the parotid salivary gland.

## The External Carotid Artery

Which branch of the external carotid artery supplies the upper and lower jaw, deep facial areas, and the nasal cavity?<sup>1,2</sup>

- a) Ascending pharyngeal artery
- b) Lingual artery
- c) Occipital artery
- d) Maxillary artery
- e) Superficial temporal artery

1. Osborn 1999/p39/c2/para5, 2. Marieb 2016/p732/c2/para3

**SAY:** Which branch supplies the upper and lower jaw, deep facial areas, and the nasal cavity?



## The External Carotid Artery

Which branch of the external carotid artery supplies the upper and lower jaw, deep facial areas, and the nasal cavity?<sup>1,2</sup>

- a) Ascending pharyngeal artery
- b) Lingual artery
- c) Occipital artery
- d) Maxillary artery**
- e) Superficial temporal artery

1. Osborn 1999/p39/c2/para5, 2. Marieb 2016/p732/c2/para3

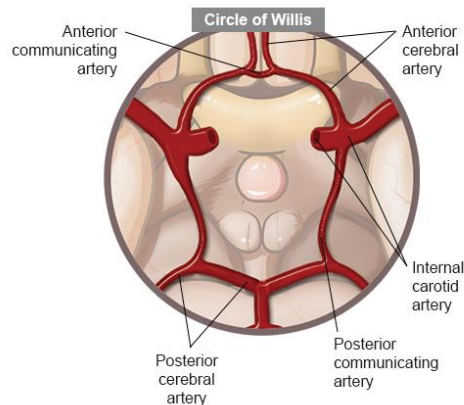
**SAY:** That's correct. The Maxillary artery supplies the upper and lower jaw, deep facial areas, and the nasal cavity

OR

**SAY:** That's incorrect. The Maxillary artery supplies the upper and lower jaw, deep facial areas, and the nasal cavity

## Collateral Circulation

- Network of vascular connections that stabilize central blood flow via secondary channels if primary artery is obstructed
- Established through connections between arteries that supply adjacent vascular territories



Johnson & Johnson INSTITUTE

82

**SAY:** Collateral circulation refers to the network of vascular connections that stabilize cerebral blood flow by providing secondary channels through which blood can flow to and from a tissue if the principal artery becomes obstructed. This type of compensatory circulation is established through connections between arteries that supply adjacent vascular territories. (Taber's 2017/p1/collateral circulation) (Liebeskind 2003/p2279/c1/para1)

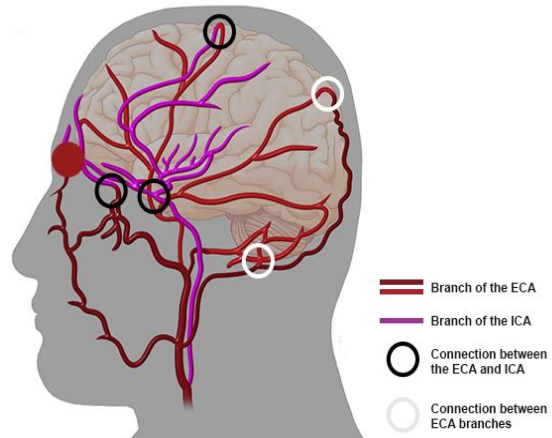
Recall from earlier, that the circle of Willis provides a collateral circulation pathway for cerebral blood flow between major arteries of the brain.

There are many connections between the branches of the external carotid artery and the internal carotid system that may serve as an important supply of collateral blood flow. (Brain in Morton 2011/p7/para2)

Image Reference: (Marieb 2016/p733/Figure 19.22 D) (Vanderah 2016/p134/Figure 6-11)

## Collateral Circulation

- There are many connections between the branches of the external carotid artery and the internal carotid system that may serve as an important supply of collateral blood flow

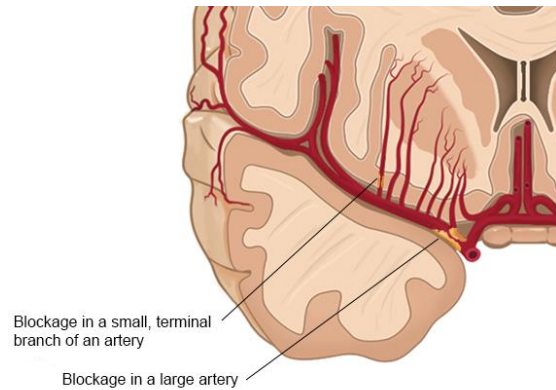


**SAY:** As shown here, there are many connections between the branches of the external carotid artery and the internal carotid system that may serve as an important supply of collateral blood flow. (Osborn/p31/c1/para2; p38/c2/para3/Table 2-1)

Image Reference: (Liebeskind 2003/p2280/c1/Figure 1)

## Blockage in the Arteries of the Brain

- Neurons require constant supply of nutrients via blood
- Interruptions of blood flow >few minutes causes irreversible damage<sup>1</sup>
- The amount of brain damage and the types of symptoms experienced by the patient depend on the area of the vascular tree that is affected.



**SAY:** Neurons in the brain require a constant supply of nutrients to remain viable. As a result, any interruption in blood flow to the brain that lasts more than a few minutes can cause irreversible damage. (Zivin 2008/p2705/c2/para1) The amount of brain damage and the types of symptoms experienced by the patient depend on the area of the vascular tree that is affected. (Vanderah 2016/p141/c2/para2)

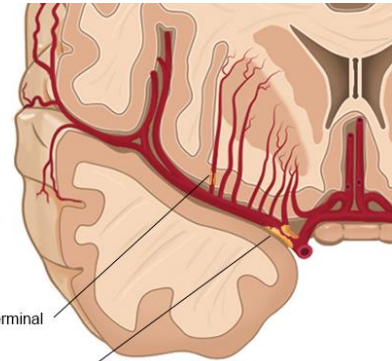
## Blockage in the Arteries of the Brain

### Blockage in a Small, Terminal Branch of Artery

- Affected brain tissues will be relatively small
- Functional deficits experienced by the patient will be relatively specific

### Blockage in a Large Artery

- Affected brain tissues will include all of the areas normally supplied by that artery and all of its branches
- Broader range of functional deficits experienced by the patient



**SAY:** If there is a blockage in a small, terminal branch of an artery:

- affected brain tissues will be relatively small and
- functional deficits experienced by the patient will be relatively specific (Vanderah 2016/p141/c2/para2)

If there is a blockage in a large artery:

- affected brain tissues will include all of the areas normally supplied by that artery and all of its branches and
- a broader range of functional deficits will be experienced by the patient (Vanderah 2016/p141/c2/para2)

## Glossary

- artery: A vessel through which the blood passes away from the heart to the various parts of the body.<sup>1</sup>
- atherosclerotic: A condition during which the arteries become narrowed or hardened due to a buildup of fats, cholesterol and other substances (plaques) along the artery walls, which can restrict blood flow.<sup>2</sup>
- autonomic nervous system: The parts of the nervous system that control unconscious, involuntary, and visceral body functions (e.g., smooth muscle tone, blood pressure, temperature, fluid composition, state of digestion, metabolic activity, and sexual activation).<sup>3</sup>
- brachiocephalic trunk: The first branch of the aortic arch, which divides into the right common carotid and right subclavian arteries, with distribution to the right side of the head and neck and to the right upper limb; also called brachiocephalic artery, and innominate artery.<sup>1</sup>
- cerebral hemisphere: Either of the 2 hollow convoluted lateral halves of the cerebrum.<sup>1</sup>
- cerebrospinal fluid: A clear, colorless liquid that continuously circulates through cavities in and around the brain, and protects the brain from chemical and physical injuries. It also carries oxygen, glucose, and other chemicals needed from the blood.<sup>4</sup>
- cranium: The large round superior part of the skull, enclosing the brain; made up of the cranial bones.<sup>1</sup>
- extracranial: Located or occurring outside of the portion of the skull that surrounds and protects the brain (cranium).<sup>3</sup>

1. [Dorland's]. 2. NIH MedlinePlus 2018/p1/para1, 3. [Taber's], 4. Tortora 2009 Ch14, p499, c2, para3

**Johnson & Johnson** INSTITUTE

## Glossary

- fibromuscular dysplasia: The abnormal growth of cells in the walls of arteries causing the vessels to narrow or bulge. The carotid arteries in the neck are commonly affected, which can lead to reduced blood flow to the brain.<sup>1</sup>
- grey matter: Neural tissue composed mostly of nerve cell bodies, unmyelinated nerve fibers, and supportive tissue.<sup>2</sup>
- intracranial: Located or occurring within the portion of the skull that protects the brain (cranium).<sup>3</sup>
- larynx: A tube composed of cartilage that forms the initial segment of the respiratory tree. It houses the vocal chords and is involved in producing sounds. It also protects the trachea from aspirated foods and liquids.<sup>3</sup>
- left ventricle: The lower chamber of the left side of the heart, which pumps oxygenated blood out through the aorta into the systemic arteries.<sup>2</sup>
- medial: Pertaining to the middle; closer to the median plane, middle layers, or the midline of a structure.<sup>2</sup>
- meninges: The 3 membranes that envelop the brain and spinal cord: the dura mater, the arachnoid mater, and the pia mater.<sup>2</sup>
- pharynx: A passageway for air from the nasal cavity to the larynx (voice box) and for food from the mouth to the esophagus.<sup>3</sup>

1. NINDS 2018/p1/para1, 2. [Dorland's]. 3. [Taber's]

## Glossary

- proprioception: The awareness of posture, movement, and changes in equilibrium and the knowledge of position, weight, and resistance of objects in relation to the body.<sup>1</sup>
- right ventricle: The lower chamber of the right side of the heart, which pumps venous blood through the pulmonary trunk and arteries to the capillaries of the lungs.<sup>2</sup>
- skull: The skeleton of the head, including the cranium and the mandible.<sup>2</sup>
- startle reflex: Sudden movements of the head, eyes, and trunk that occur when you are surprised by a loud noise (e.g., a gunshot).<sup>3</sup>
- subarachnoid space: The space between the arachnoid mater and the pia mater, containing cerebrospinal fluid.<sup>2</sup>
- thyroid gland: A large gland at the base of the neck from which thyroid hormones are produced. These hormones regulate a person's metabolic rate throughout the body.<sup>1</sup>
- trachea: The tube by which air passes to and from the lungs.<sup>4</sup>
- white matter: Neural tissue composed mostly of myelinated nerve fibers that conduct information.<sup>2</sup>

1. [Taber's], 2.[Dorland's]. 3.Tortora 2009/p507/c1/para2, 4. [Stedman's]



## References

- Bhuriya R, Arora R, Khosla S. Fibromuscular dysplasia of the internal carotid circulation: an unusual presentation. *Vasc Med*. 2008;13(1):41-43. [Bhuriya 2008]
- Cloud GC, Markus HS. Diagnosis and management of vertebral artery stenosis. *QJM*. 2003;96(1):27-34. [Cloud 2003]
- Demertzis S, Hurni S, Stalder M, Gahl B, Herrmann G, Van den Berg J. Aortic arch morphometry in living humans. *J Anat*. 2010;217(5):588-596. [Demertzis 2010]
- Dorland's Online Medical Dictionary. <https://www.dorlands.com>. Accessed February 19, 2018. [Dorland's]
- Exaire JE, Yadav JS. Basic Anatomy. In: Bhatt DL, ed. *Guide to Peripheral and Cerebrovascular Intervention*. London, England: Remedica; 2004. <https://www.ncbi.nlm.nih.gov/books/NBK27421/>. Accessed February 15, 2018. [Exaire 2004]
- Layton KF, Kallmes DF, Cloft HJ, Lindell EP, Cox VS. Bovine aortic arch variant in humans: clarification of a common misnomer. *AJNR Am J Neuroradiol*. 2006;27(7):1541-1542. [Layton 2006]
- Liebeskind DS. Collateral circulation. *Stroke*. 2003;34(9):2279-2284. [Liebeskind 2003]
- Marieb EN, Hoehn K. *Human Anatomy & Physiology*. 10th ed. Boston, MA: Pearson Education, Inc; 2016. [Marieb 2016]
- Menshawi K, Mohr JP, Gutierrez J. A functional perspective on the embryology and anatomy of the cerebral blood supply. *J Stroke*. 2015;17(2):144-158. [Menshawi 2015]
- Morton DA, Foreman K, Albertine KH, eds. *The Big Picture: Gross Anatomy*. New York, NY: McGraw-Hill; 2011. <http://accessmedicine.mhmedical.com/content.aspx?bookid=381&sectionid=40140024>. Accessed January 29, 2018. [Brain in Morton 2011]
- National Institute of Neurological Disorders and Stroke. Fibromuscular dysplasia information page. <https://www.ninds.nih.gov/Disorders/All-Disorders/Fibromuscular-Dysplasia-Information-Page>. Accessed February 22, 2018. [NINDS 2018]

## References

- National Institutes of Health. MedlinePlus. Atherosclerosis. <https://medlineplus.gov/atherosclerosis.html>. Accessed February 22, 2018. [NIH MedlinePlus 2018]
- Osborn AG. Diagnostic Cerebral Angiography. 2nd ed. Philadelphia, PA: Lippincott Williams & Wilkins; 1999. [Osborn 1999]
- Patton KT, Thibodeau GA. The Human Body In Health & Disease. 6th ed. Maryland Heights, MO: Mosby, an imprint of Elsevier Inc; 2014. [Patton 2014]
- Purves D, Augustine GJ, Fitzpatrick D, Hall WC, LaMantia AS, White LE, eds. Neuroscience. 5th ed. Sunderland, MA: Sinauer Associates, Inc; 2012. [Purves 2012]
- Smith WS, Johnson SC, Hemphill JC III. Cerebrovascular diseases. In: Longo DL, Fauci AS, Kasper DL, Hauser SL, Jameson J, Loscalzo J, eds. Harrison's Principles of Internal Medicine. 19th ed. New York, NY: McGraw-Hill; 2015. <http://accessmedicine.mhmedical.com/content.aspx?bookid=1130&sectionid=79755261>. Accessed February 25, 2018. [Smith in Harrison's 2014]
- Spacek M, Veselka J. Bovine arch. Arch Med Sci. 2012;8(1):166-167. [Spacek 2012]
- Stedman's Online Medical Dictionary. <http://stedmansonline.com/index>. Accessed February 24, 2018. [Stedman's]
- Taber's Online Medical Dictionary. <https://www.tabers.com/tabersonline/ub>. Accessed February 19, 2018. [Taber's]
- Tortora GJ, Derrickson B. Principles of Anatomy and Physiology. 12th ed. Hoboken, NJ: John Wiley & Sons, Inc; 2009. [Tortora 2009]
- US National Institutes of Health, National Cancer Institute. SEER Training Modules, Cancer Registration & Surveillance Modules: Circulatory Pathways. Accessed February 24, 2018. <https://training.seer.cancer.gov/anatomy/cardiovascular/blood/pathways.html>. [SEER 2018]

## References

- Vanderah TW, Gould DJ. Nolte's the Human Brain: An Introduction to its Functional Anatomy. 7th ed. Philadelphia, PA: Elsevier; 2016. [Vanderah 2016]
- Zivin JA. Approach to cerebrovascular disease. In: Goldman L, Ausiello D, eds. Cecil Medicine. 23rd ed. Philadelphia, PA: Saunders Elsevier; 2008: 2701-2707. [Zivin 2008]

# Congratulations!

Complete the final assessment at <https://courses.jnjinstitute.com>  
to receive CE credits applicable to your learning.

*Johnson & Johnson* INSTITUTE

92

## Knowledge Check

1. Which of the following terms can be used to describe structures in front of or behind, respectively?

- Anterior and posterior
- Dorsal and ventral
- Rostral and caudal
- Superior and inferior

# Knowledge Check

2. Which of the following are the 4 principle regions of the brain? Select all that apply.

- Brainstem
- Cerebellum
- Cerebrum
- Cortex
- Diencephalon
- Pons
- Thalamus

## Knowledge Check

3. Which of the following list the layers of the brain from external to internal?

- Arachnoid mater, Dura mater, and pia mater
- Dura mater, arachnoid mater, and pia mater
- Dura mater, pia mater, and arachnoid mater
- Pia mater, arachnoid mater, and dura mater

## Knowledge Check

4. Which of the following lobes of the brain is associated with executive functions, motor performance, and production of language?

- Frontal lobe
- Occipital lobe
- Parietal lobe
- Temporal lobe



## Knowledge Check

5. Which of the following lobes of the brain contains the auditory cortex as well as areas of the brain involved in aspects of memory and learning?

- Frontal lobe
- Occipital lobe
- Parietal lobe
- Temporal lobe

## Knowledge Check

6. Which of the following describe common bovine arch variations?

- A trifurcation from the left common carotid artery
- A trifurcation from the left subclavian artery
- The left common carotid artery and the brachiocephalic artery share a common origin
- The left subclavian artery and the brachiocephalic artery share a common origin

## Knowledge Check

7. The brain receives its arterial blood supply from which of the following arteries?

- Brachial and internal iliac arteries
- Common carotid and aortic arteries
- External carotid and subclavian arteries
- Internal carotid and vertebral arteries

## Knowledge Check

8. The internal carotid artery divides into which of the 2 terminal branches? Select all that apply

- Anterior cerebral artery
- Basilar artery
- External carotid artery
- Middle cerebral artery
- Posterior cerebral artery

## Knowledge Check

9. Which of the following branches of the internal carotid artery connects the anterior and posterior circulations?

- Anterior choroidal artery
- Ophthalmic artery
- Posterior communicating artery
- Superior hypophyseal arteries

## Knowledge Check

10. Which of the following arteries connects the 2 anterior cerebral arteries from each hemisphere?

- Anterior communicating artery
- Pericallosal artery
- Posterior communicating artery
- Lenticulostriate artery

## Knowledge Check

11. The anterior cerebral artery supplies the medial surface of which of the following lobes of the brain? Select all that apply.

- Frontal
- Parietal
- Temporal
- Occipital

## Knowledge Check

12. Which of the following arteries arises from the subclavian arteries and run along the anterior surface of the brainstem?

- Anterior cerebral artery
- Basilar artery
- Middle cerebral artery
- Vertebral artery



## Knowledge Check

13. Which of the following arteries is a branch of the vertebral artery?

- Posterior inferior cerebellar artery
- Anterior inferior cerebellar arteries
- Superior cerebellar arteries
- Posterior cerebral arteries

## Knowledge Check

14. Which of the following arteries make up the circle of Willis? Select all that apply.

- Anterior and posterior communicating arteries
- Anterior cerebral arteries
- External carotid artery
- Internal carotid arteries
- Middle cerebral artery
- Posterior cerebral arteries

## Knowledge Check

14. What is the name of the network of vascular connections that allows blood to continue to flow from one tissue to another if the principal artery becomes obstructed?

- Collateral circulation
- Compensatory circulation
- Secondary circulation
- Systemic circulation