

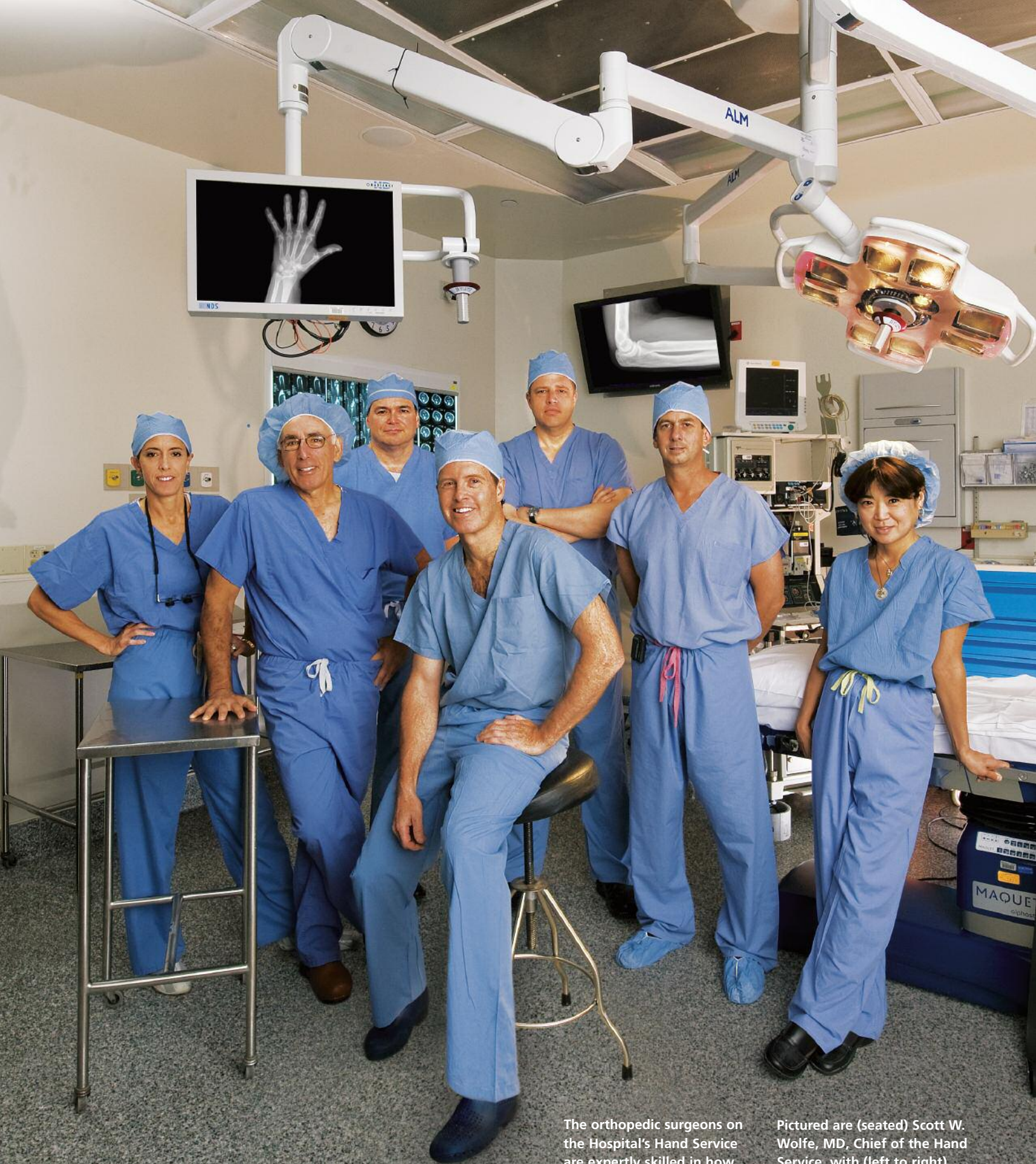HOSPITAL FOR  
SPECIAL SURGERY:  
SPECIALISTS IN  
MOBILITY  
WINTER 2009

# Horizon



**The Hand:** Incredible Form, Extraordinary Function





The orthopedic surgeons on the Hospital's Hand Service are expertly skilled in how best to repair the nerves, vessels, soft tissues, and bones of the hand, wrist, and elbow so that they work individually and together for optimal function.

Pictured are (seated) Scott W. Wolfe, MD, Chief of the Hand Service, with (left to right) Michelle G. Carlson, MD, Andrew J. Weiland, MD, Robert N. Hotchkiss, MD, Aaron Daluiski, MD, Edward A. Athanasian, MD, and Lana Kang, MD.



# The Hand: Incredible Form, Extraordinary Function

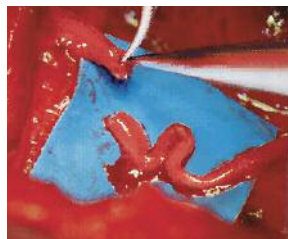
The human hand is nothing short of incredible. It allows us to work, to touch, to tie a tie, or to catch a ball. Our hands help us to communicate and to express our emotions. From morning 'til night, they are ever moving, and when something goes awry in their intricate anatomy, their importance to our lives is never more apparent.

**T**he Hand Service at Hospital for Special Surgery offers an unparalleled depth of expertise that encompasses a broad array of treatments for common and complex conditions. “When you consider the number of activities that require the use of our hands, any injury or disorder that compromises their function can be devastating to a career or quality of life,” says Thomas P. Sculco, MD, Surgeon-in-Chief. “Our hand specialists, through their skills in surgical interventions that include reconstruction of nerve injuries, arthroscopic repair of complex ligament tears and wrist and forearm fractures, microsurgical repair of blood vessels, and reconstruction of complex elbow injuries, are committed to giving patients every opportunity to recover optimal function so that they can resume the lifestyle they had previously.”

“While our seven physicians treat conditions affecting every facet of the upper extremity,” says Scott W. Wolfe, MD, Chief of the Hand Service, each has further developed a subspecialty expertise in such areas as traumatic injuries, degenerative diseases, congenital hand disorders, vascular diseases, nerve injuries, tumors of the upper limb, and reconstruction of the elbow.”

## Reconstructing Nerves in the Brachial Plexus

Stephen Cook was harvesting a tree on his farm in the Adirondacks when a dead branch fell 80 feet, hitting him, and fracturing his skull, arm, neck, and back. His brachial plexus, the web of large nerves that originate from the spinal cord in the neck and direct the movement and sensation of the entire upper limb, had been severely injured. “I rode snowmobiles, hunted, and then, ‘hey buddy, you’ve got only one good arm!’” recalls Mr. Cook. “The local doctors painted such a bleak picture that I was contemplating amputation. I dealt with that for a few months, and then I Googled brachial plexus. Dr. Wolfe’s name popped up. I called him and he told me time was of the essence since it was already five months past the date of the accident.”

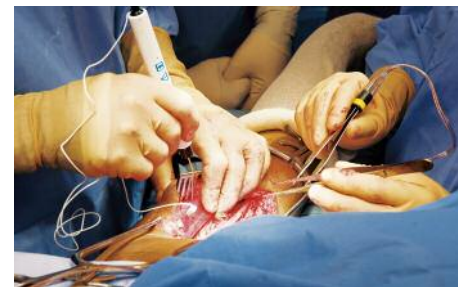
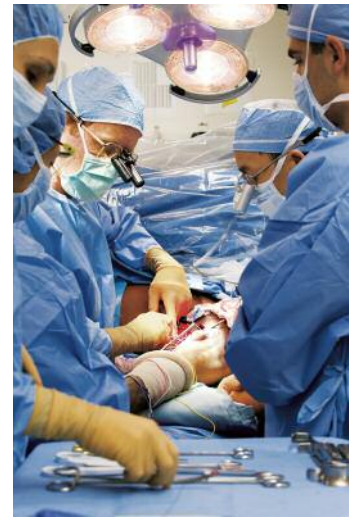
Extensive surgery by Dr. Scott Wolfe on the nerves of the brachial plexus saved Stephen Cook’s arm, enabling him to return to his work as a tree farmer and rustic furniture maker. At left, a microscopic view of brachial plexus nerves in the midst of being surgically repaired. (more online at [www.hss.edu/horizon](http://www.hss.edu/horizon))

“A brachial plexus injury can have a devastating impact on upper limb function, potentially affecting – as in Mr. Cook’s case – the muscle power of the entire arm,” says Dr. Wolfe. “There is a small window of time that if you don’t get a spark going in the muscle, it’s never coming back. To allow regenerating nerves to connect with paralyzed muscles and restore muscle function before dense scarring develops, nerve reconstructive surgery is ideally performed within the first three to five months after an injury. Recovery from brachial plexus surgery is measured in months and years rather than days or weeks. At four to eight months after surgery, patients will experience a flicker of muscle recovery, with a gradual return of strength and mobility.”

“When my bicep started twitching,” recalls Mr. Cook, “I noticed just a little twitter. I worked it hard. About a year from that I was able to raise my arm.” That was over four years ago and, today, Mr. Cook continues to make his living as a rustic furniture maker.

The Hand Service has established a brachial plexus registry, enabling the Hospital’s surgeons to pursue studies of innovative nerve transfer and repair procedures and research and evaluate patient outcomes to improve management of these complex injuries even further. Many of these procedures require a microsurgical approach in order to address the reconstruction of the body’s minute nerves and vessels.



### Applying Microsurgical Technology

Performed under the magnification of a microscope, microsurgery is typically used to transplant tissue from one part of the body to another, or to reconstruct arteries, veins, and nerves by placing sutures in the walls of the blood vessels and nerve coverings. Connections for blood vessels and nerves can then be made to reestablish blood flow and nerve transmission. The field of microsurgery has vastly improved since the 1970s, when Andrew J. Weiland, MD, performed some of the world’s first free tissue transfers and bone grafts.

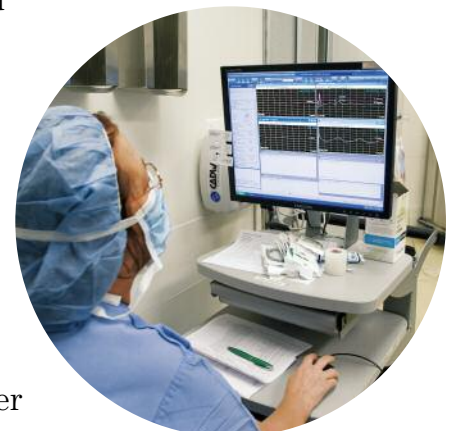According to Dr. Weiland, innovative techniques using microsurgical dissection, such as nerve transfers, have revolutionized how surgeons can reconstruct extremities and repair nerves and vessels. “Technology has also advanced nerve repairs and treatment of tendon injuries,” says Dr. Weiland. “Surgeons are starting to use nerve guidance tubes to make up gaps in nerves that may perhaps be equivalent to performing nerve grafts. In the future I think biologics will be the answer. We’ll have a better handle on growth factors and how to get those to help us heal tissues.”

### Emphasizing the Elbow Joint

At the age of eight, Adriana Ricottone fell and suffered a radial head fracture of her right elbow with resulting tendon and ligament contracture. This type of elbow fracture is very common, usually caused by falling on an outstretched hand. “The radial head, which is a small bone in the forearm near the elbow, is important for bending of the elbow joint, as well as rotation of the forearm,” says Robert N. Hotchkiss, MD. “If there is only a slight loss of motion, we let the child continue to grow and follow his or her

Dr. Scott Wolfe performs surgery to repair damaged nerves, tendons, and blood vessels associated with a brachial plexus injury.

The patient’s nerves are electrically stimulated in the surgical field and recordings are obtained from nerves and/or muscles to assess the degree of nerve injury. Says Brion D. Reichler, MD, who directs the Intraoperative Neurophysiological Monitoring Service, “This helps to differentiate functioning from non-functioning nerves.”





functional capabilities closely. But Adriana's elbow had become very stiff to the point where she actually couldn't move the joint at all. On September 8, 2008, Dr. Hotchkiss performed surgery to release contractures and remove the bone affected by the fracture. Six weeks after her surgery, Adriana's mother, Stephanie, reported she was doing very well. Difficult orthopedic conditions around the elbow – from fractures in children to arthritis in older adults – are a subspecialty focus of Dr. Hotchkiss. He and his team of researchers are addressing all aspects of elbow reconstruction. "We are one of the few institutions around the country that has the concentration of practice, the accumulated experience, and the multidisciplinary collaboration with engineers, biologists, and implant manufacturers who can come to the table to discuss challenges to elbow replacement and generate progress," says Dr. Hotchkiss.

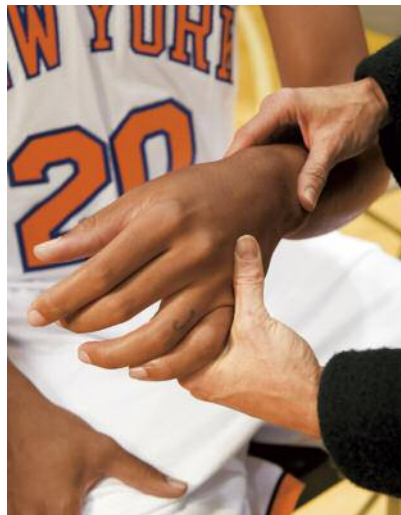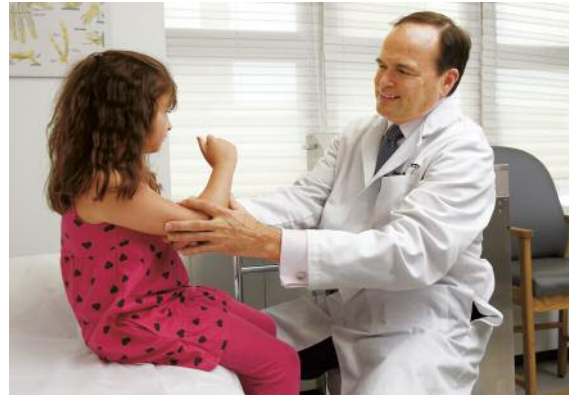### Addressing Athletic Ailments

Sports-related injuries to the hand and forearm can range from a jammed finger during a basketball game to a fracture or dislocation of the wrist. Professional and recreational athletes, or active teens and children, are all prone to these types of injuries, and regardless of the severity, prompt attention from a hand surgeon can make an important difference in long-term recovery and ability to continue in that sport. No one knows this better than an elite athlete such as the Knicks' forward Jared Jeffries. Injured in a game in which he fell on his wrist, Mr. Jeffries had fractured the scaphoid bone – a small bone that sits at the base of the thumb. "With athletes, particularly professional athletes, we need to determine whether to let them continue to play and repair the injury at the end of the season, or fix it now and get them back to playing as soon as possible," says Michelle G. Carlson, MD, who consults on hand injuries for the New York Knicks, working closely with Answorth Allen, MD, an orthopedic surgeon with Hospital for Special Surgery, who serves as the Knicks team physician, and Lisa R. Callahan, MD, medical director of the Knicks. Dr. Carlson put a screw into Mr. Jeffries' scaphoid to allow for the quickest healing of the bone. "We followed up with regular CT scans to evaluate when the bone was healed, and at six weeks he was able to return to play."

### Treating Tumors, Retaining Function

Edward A. Athanasian, MD, focuses on bone and soft tissue sarcomas of the hand, forearm, and elbow which, although uncommon, can be life-threatening. "My goal is to accomplish both the primary objective of getting the tumor out and preventing local recurrence and metastasis, and then put things back together so that the hand will retain as much function as possible,"

Adriana Ricottone gives a "thumbs up" to Dr. Robert Hotchkiss, Director of Research for the Hand Service and Director of Clinical Research for the Hospital, during a post-operative examination.



Dr. Michelle Carlson inspects the progress of New York Knicks player Jared Jeffries, who had fractured his wrist during a game.





# Total Care of the Hand, Wrist, and Elbow

Among the many conditions that bring patients to Hospital for Special Surgery's Hand Service are:

Distal radius fracture ❶ This fracture of the larger of the two forearm bones linking the hand to the elbow occurs when the radius breaks, usually when landing on outstretched hands

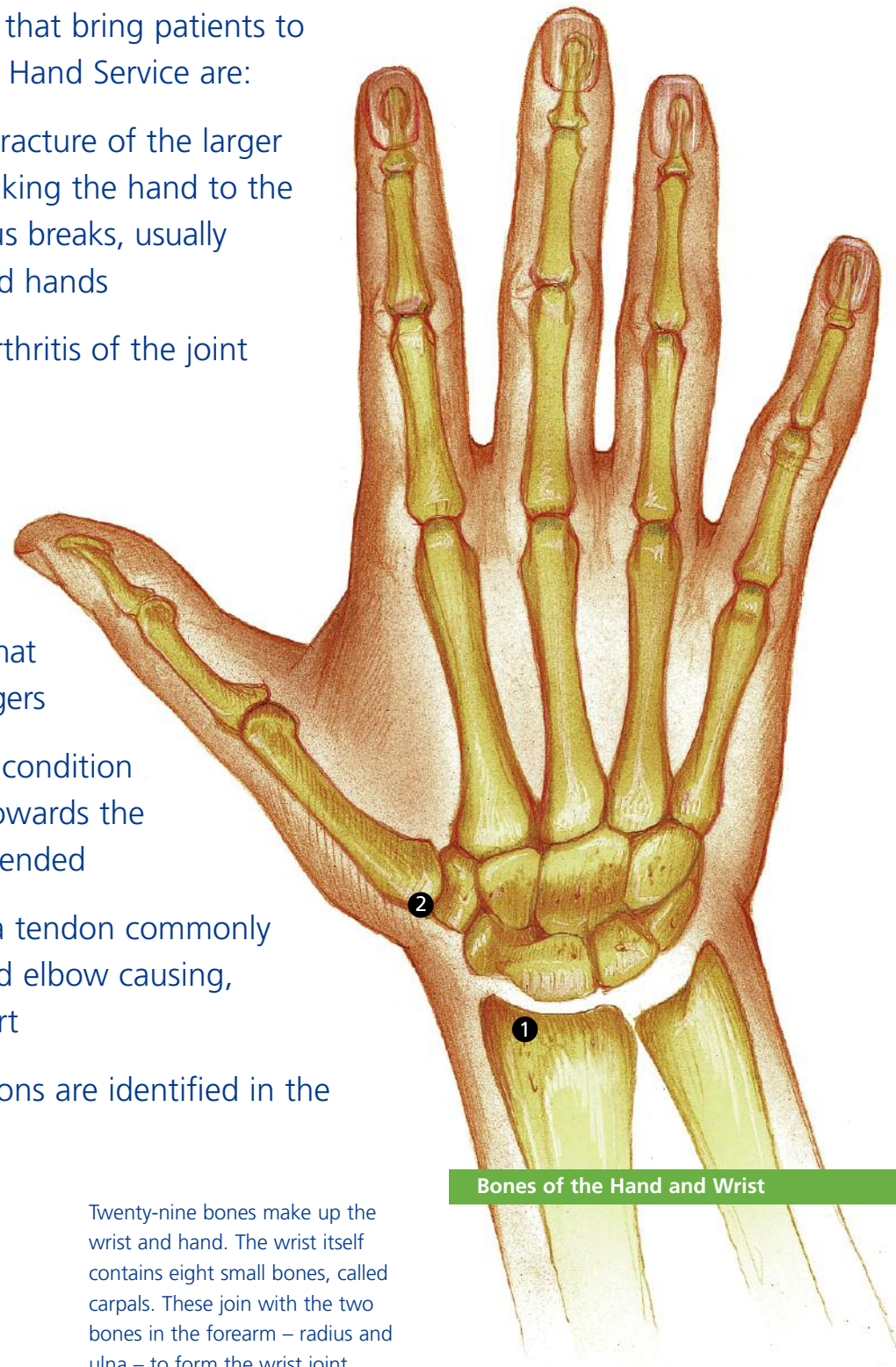
Basal joint arthritis ❷ Osteoarthritis of the joint at the base of the thumb

Carpal tunnel syndrome ❸ A gradual reduction in the carpal tunnel (the space in the wrist bound on three sides by bone) for the nerve that runs from the neck to the fingers

Dupuytren's contracture ❹ A condition where the fingers contract towards the palm and cannot be fully extended

Tendonitis ❺ Entrapment of a tendon commonly seen in the wrist, fingers, and elbow causing, swelling, pain, and discomfort

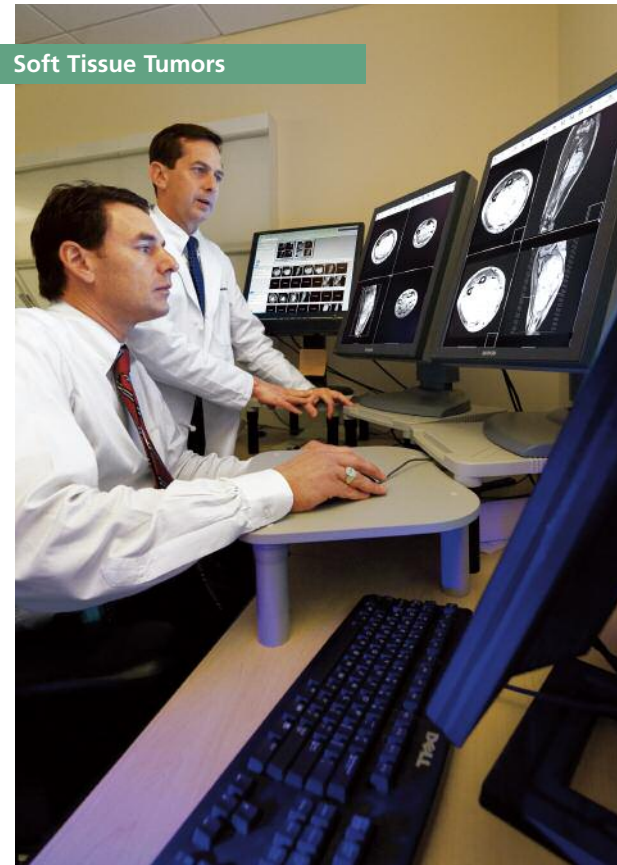The location of these conditions are identified in the accompanying illustrations.



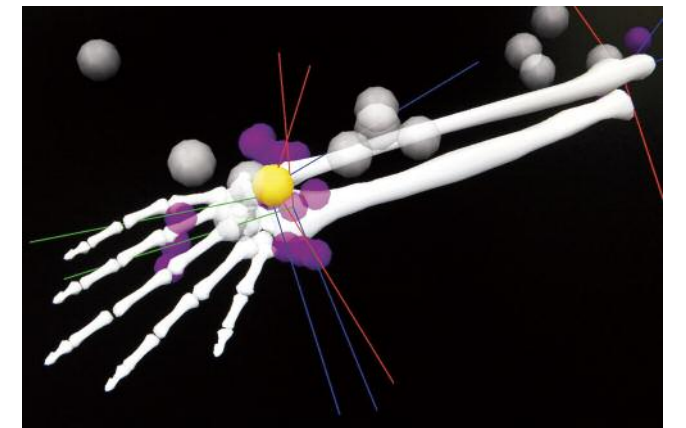
Bones of the Hand and Wrist

Twenty-nine bones make up the wrist and hand. The wrist itself contains eight small bones, called carpals. These join with the two bones in the forearm – radius and ulna – to form the wrist joint.


Soft Tissue Tumors



Orthopedic surgeon Edward A. Athanasian (standing) and radiologist Douglas Mintz, MD, combine their expertise in soft tissue tumors of the hand and upper extremity to maximize outcomes for patients. Using MRI and other imaging technologies for diagnosis and for monitoring treatment response, Dr. Mintz provides important information that Dr. Athanasian will need for surgery to remove the tumor and preserve healthy tissue.



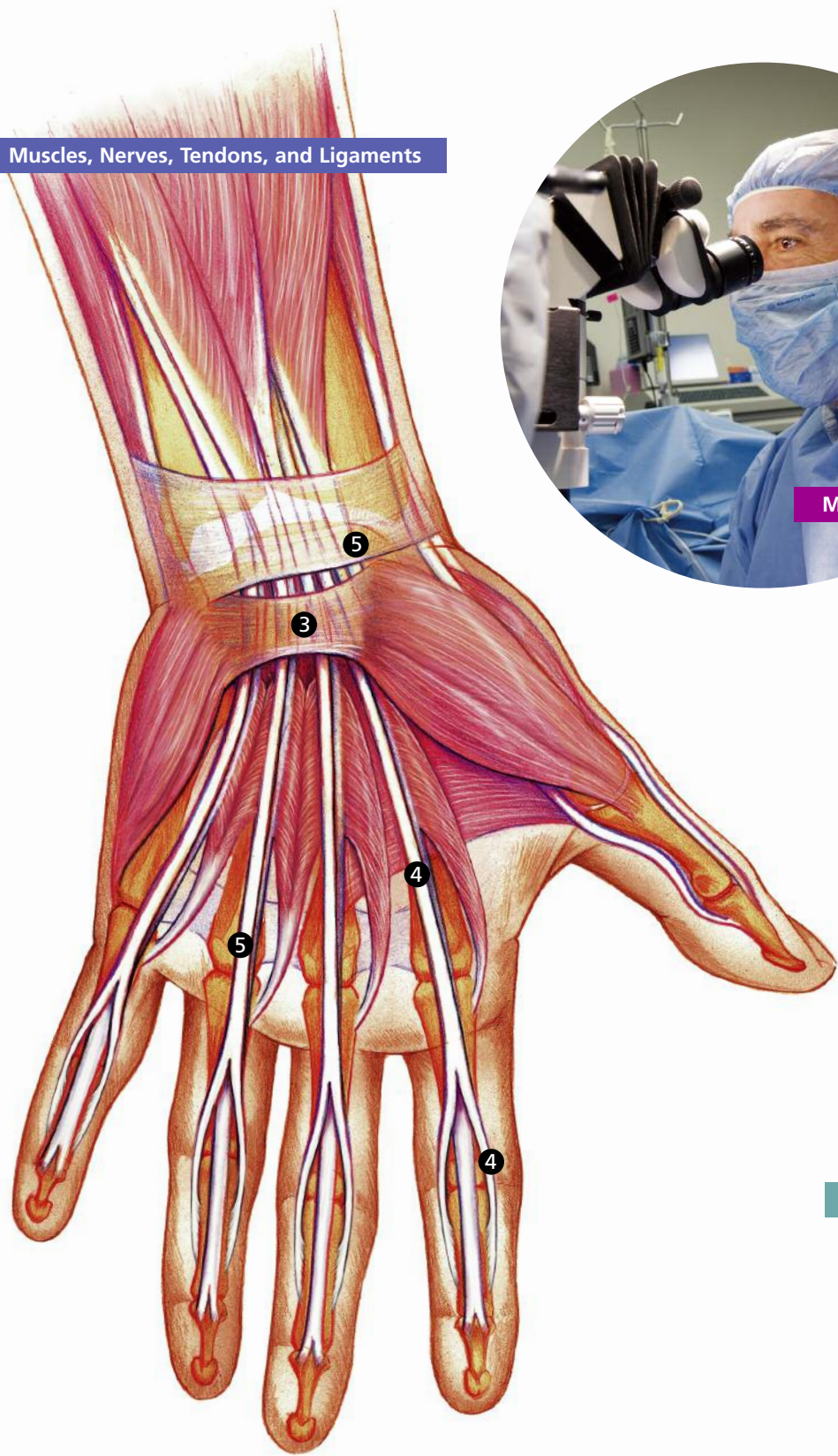
Understanding Wrist Motion



"Throwing a dart requires a specific wrist motion that enables us to perform a number of occupational and sports-related activities," says Scott Wolfe, MD, Chief of the Hand Service, who directs federally funded research in wrist kinematics. Dr. Wolfe and his research team in the Leon Root, MD Motion Analysis Lab are detailing the arc of a dart-thrower's motion using markers affixed to the hand and the forearm in order to calculate parameters that allow wrist motion. The data will provide important information for treatment, and will also be used to develop a breakthrough wrist replacement prosthesis.



## Muscles, Nerves, Tendons, and Ligaments



Many of the muscles that control the hand start at the elbow, travel down the forearm, and cross at the wrist and hand. Some control motions of the wrist, while others allow the fine motor actions involving the fingers and thumb.

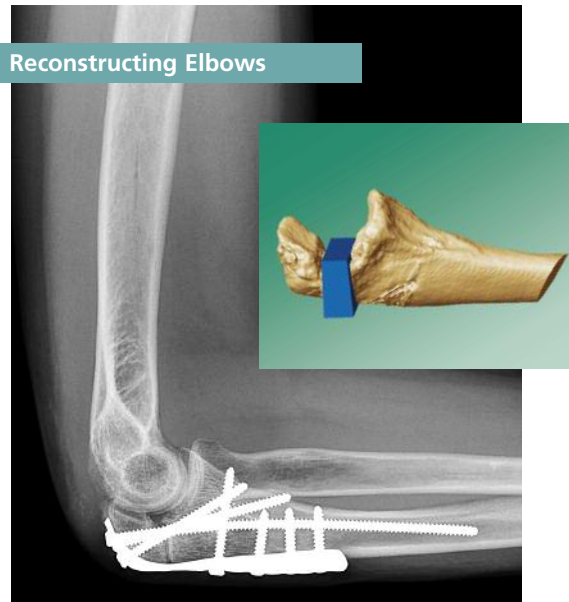

## Microsurgical Repair

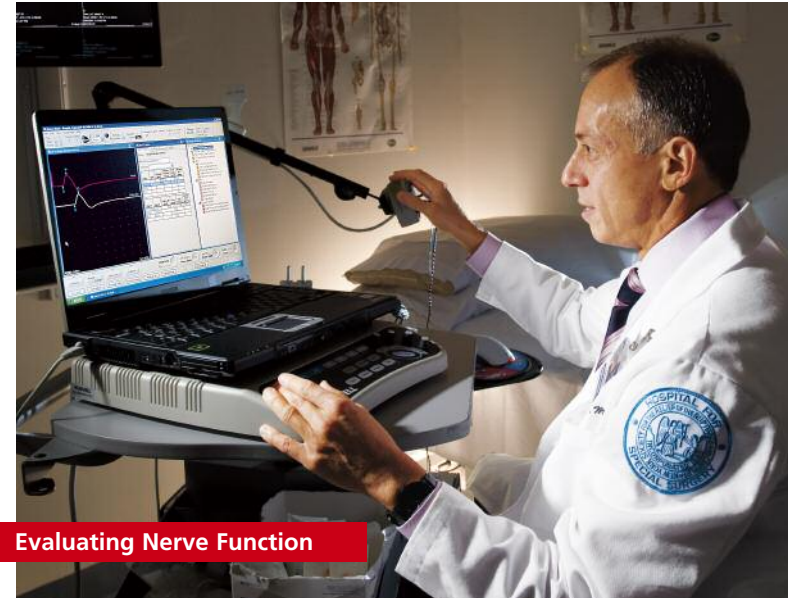
Dr. Andrew Weiland has several decades of experience with microsurgery, which is performed under the magnification of a microscope and used to repair or reconstruct small vessels and nerves in the hand in order to reestablish blood flow and nerve transmission.

The three-dimensional model of the ulna based on CT scans and the planned surgical procedure created by Joseph Lipman, MS, Director of Device Development in the Department of Applied Biomechanics and Orthopedic Surgery, served as the template for reconstruction surgery on a patient with a complex fracture at the tip of the ulna. The post-operative radiology image displays the pins, wires, and screws that were used to secure the ulna, radius, and humerus bones in the proper position.

## Reconstructing Elbows



Physiatrist Joseph H. Feinberg, MD, performs electrodiagnostic studies to localize the source of a patient's neurological symptoms – such as weakness, numbness, tingling, or loss of function in the hands – by determining if the site of the injury is from the neck, brachial plexus, the elbow, or the wrist. They can also help to quantify the extent of nerve injury and dysfunction.



## Evaluating Nerve Function

The Division of Rheumatology at Hospital for Special Surgery is among the top ranked in the nation. Rheumatologists such as Linda Russell, MD, participate in crucial collaborations with the Hand Service. They play a key role in the care of patients with arthritis of the thumb, finger, and wrist joints, providing medical management and non-surgical treatments to minimize pain and discomfort and maximize function.



## Medical Management

## Maximizing Function



Under the direction of Aviva Wolff, CHT, OTRL, (above) the Hospital's Hand Therapy Department plays a prominent role in the care of adults and children with acute hand and elbow injuries, chronic conditions, and those recovering from surgery.



says Dr. Athanasian. “Sometimes we’re in a situation where no textbook can describe what to do. For example, instead of amputating an arm because of a tumor inside the patient’s elbow joint, I may take out the entire elbow as one piece and then reconstruct it with bone transplants, an artificial elbow, and some form of soft tissue coverage.” Dr. Athanasian and his colleagues are now pioneering the concept of thumb salvage. “We recently completed a study showing that reconstruction following resection can result in acceptable functional outcomes with a low risk of complication. This is important since the thumb accounts for about 50 percent of the function of the hand.”

### **The Potential to Transform Treatment**

When Mrs. Rosalie Van Cleef shattered her right wrist as the result of a fall, she sought out Aaron Daluiski, MD, for care. “I knew that if I had to have surgery he would be the doctor for me,” recalls Mrs. Van Cleef. This past September, Dr. Daluiski performed a nearly hour and a half surgery during which he repaired a distal radius fracture and ulna fracture using a steel plate and cadaver bone. Today, Mrs. Van Cleef’s fractures have healed and she has complete use of her wrist.

Injuries such as Mrs. Van Cleef’s are of particular interest to Dr. Daluiski, a clinician-scientist who is conducting basic science research on the molecular events of fracture healing that will have broad-based applications for orthopedic surgeons. “There is a set pattern in fracture healing and a clear difference in how children heal versus adults that is remarkable,” says Dr. Daluiski. “Children’s fractures can potentially heal within three to four weeks, while it can take six to seven weeks for the same fracture to heal in adults.” Dr. Daluiski and his colleagues have already isolated several genes that may be implicated in this disparity. “If we understand these differences, then we will be able to develop targeted therapies to replicate how a child’s fracture heals.” (*more online at [www.hss.edu/horizon](http://www.hss.edu/horizon)*)

### **A Perspective on Hand Surgery**

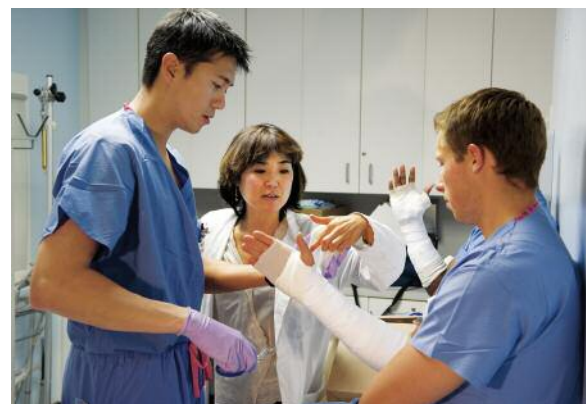
“The use of our hands is reflective of our talents and our intellect – our hands are precise and functional,” says Lana Kang, MD, who has a special interest in hand and upper extremity trauma, carpal tunnel syndrome, and overuse and work-related conditions.

Dr. Kang and her colleagues are continually engaged in outcomes research to help further knowledge in the treatment of the hand and upper extremity. She has recently been involved in the development of a patient database for compression syndrome of the ulna nerve – one of the three main nerves in the arm. “The condition can sometimes be associated with elbow trauma, but it also occurs spontaneously,” says Dr. Kang. “By evaluating information of patients enrolled in a database, we can better understand what affects these conditions and help determine which treatment method is best suited for a particular patient.” ■

**Opposite page: The Hospital’s hand surgeons have (clockwise) helped Peggy Ogden return to sculpting after surgery for carpal tunnel syndrome and basal joint arthritis; saved the hand of Christopher Manno with microvascular surgery to restore circulation; enabled world-renowned pianist Misha Dichter to again play his favorite concerto after surgery for Dupuytren’s contraction; and sent New York Knicks Power Forward Malik Rose quickly back to the court after he sprained his wrist. (*more online at [www.hss.edu/horizon](http://www.hss.edu/horizon)*)**



**Dr. Aaron Daluiski and his colleagues have discovered a gene that appears to inhibit a signaling pathway, which may be key in bone growth and fracture healing.**



**The newest Special Surgery orthopedic residents undergo a lesson in upper extremity casting by Dr. Lana Kang.**







# HOSPITAL FOR SPECIAL SURGERY



## Contacting Special Surgery

### Finding a Physician

Our Physician Referral Service can help find you the right doctor for your medical needs. Call 800.796.0783

### Visit Our Web Site

Need more information on musculoskeletal health and our medical services? Visit [www.hss.edu](http://www.hss.edu)

### Education Programs

For information on classes, lectures, workshops, and support groups, call 212.606.1057

### Giving to HSS

To support the Hospital's pioneering work in research, patient care, and education, call 212.606.1196 or visit [www.hss.edu/giving](http://www.hss.edu/giving)

*Editor-in-Chief*  
Sara Kosowsky

*Managing Editor*  
Linda Errante

*Design*  
Arnold Saks Associates

*Cover and Inside Photography*  
Robert Essel

*Hand Illustrations*  
Anatomical Chart Company

External Affairs Department  
Hospital for Special Surgery  
535 East 70th St., Suite 842W  
New York, NY 10021  
[horizon@hss.edu](mailto:horizon@hss.edu) [www.hss.edu](http://www.hss.edu)

Hospital for Special Surgery is an affiliate of NewYork-Presbyterian Healthcare System and Weill Cornell Medical College.

This publication was printed with 100% renewable, non-polluting, wind-generated power on 10% post-consumer recycled paper that is certified by the Forest Stewardship Council (FSC).

©2008 Hospital for Special Surgery.  
All rights reserved.

## Promoting Excellence in Health Care: Perspectives of Two Philanthropists

When a torn ligament in his hand nine years ago threatened to curb his active lifestyle, businessman and philanthropist Thomas L. Kempner sought treatment at Hospital for Special Surgery. "I've always known the reputation



**Thomas L. Kempner**

of the Hospital's physicians and the institution," says Mr. Kempner, whose daughter Jessica had been treated for a Colles' fracture by Michelle G. Carlson, MD. So when he injured his hand, Mr. Kempner came to Special Surgery to see Dr. Carlson. "People can live the rest of their lives without this ligament, but there is a high risk of developing arthritis," he says. "I ride a bicycle 7,000 miles a year and am active in sports. I was afraid that losing the ligament would have long-term consequences and would have lowered the quality and enjoyment of my life." Following surgery to repair the ligament, Mr. Kempner underwent six months of physical therapy. "My hand is 100 percent as good as it was," he says. "Who would complain about results like this?"

Impressed as he was with Dr. Carlson's surgical skills, he also admired her work as Director of the Hospital's Children and Adolescent Hand and Arm (CHArm) Center, prompting him to become a major contributor. The CHArm Center provides surgical and nonsurgical treatments for sports injuries, congenital disorders, cerebral palsy, juvenile arthritis, and fractures.

Supporting Hospital for Special Surgery, says Mr. Kempner, is a way to help change people's lives. "For most of us who have busy jobs and can't volunteer our time, the least we can do is volunteer some money," he says. "I'm happy to help empower people who I think are doing great things and helping to make the world a concretely better place for others."

### Supporting Science

Russell L. Carson would agree. Over the past 35 years, he has been a patient at Hospital for Special Surgery for various sports-related injuries. His personal perspective is complemented by a professional interest in health care. Mr. Carson's firm is the largest private investor in the health care industry in the country, and he has been a member of the Board of Trustees of The Rockefeller University since 1994, serving as Chairman since 2005. When Richard L. Menschel, Chairman Emeritus of the Hospital's Board of Trustees, invited him to learn about a new clinician-scientist incubator that was to be launched at Special Surgery, Mr. Carson was intrigued.

"The whole area of trying to coordinate the scientists and clinicians is very much of interest to me," says Mr. Carson. "How



**Russell L. Carson**

do you get them working together so that you are asking practical questions and discovering practical solutions to real world problems?" A major gift from Mr. Carson and his wife Judy helped to establish Special Surgery's clinician-scientist incubator, including the laboratory of Aaron Daluiski, MD, a clinician-scientist specializing in hand and upper extremity surgery. According to Dr. Daluiski, Special Surgery offered him a unique opportunity to both care for patients and pursue basic research.

Says Mr. Carson, "I'd argue that the research makes the clinician a better doctor and the clinical side makes the doctor a better researcher. When you have been a patient, you develop an appreciation for the people who work in health care, but you also recognize the necessity of continuing to find better ways of doing things." ■