

Wound Coverage Techniques for the Injured Extremity

Gil Ortega, MD, MPH

Sonoran Orthopaedic Trauma Surgeons

Site Director, Phoenix Orthopaedic Residency Program

Scottsdale Healthcare Trauma Center

Scottsdale, AZ

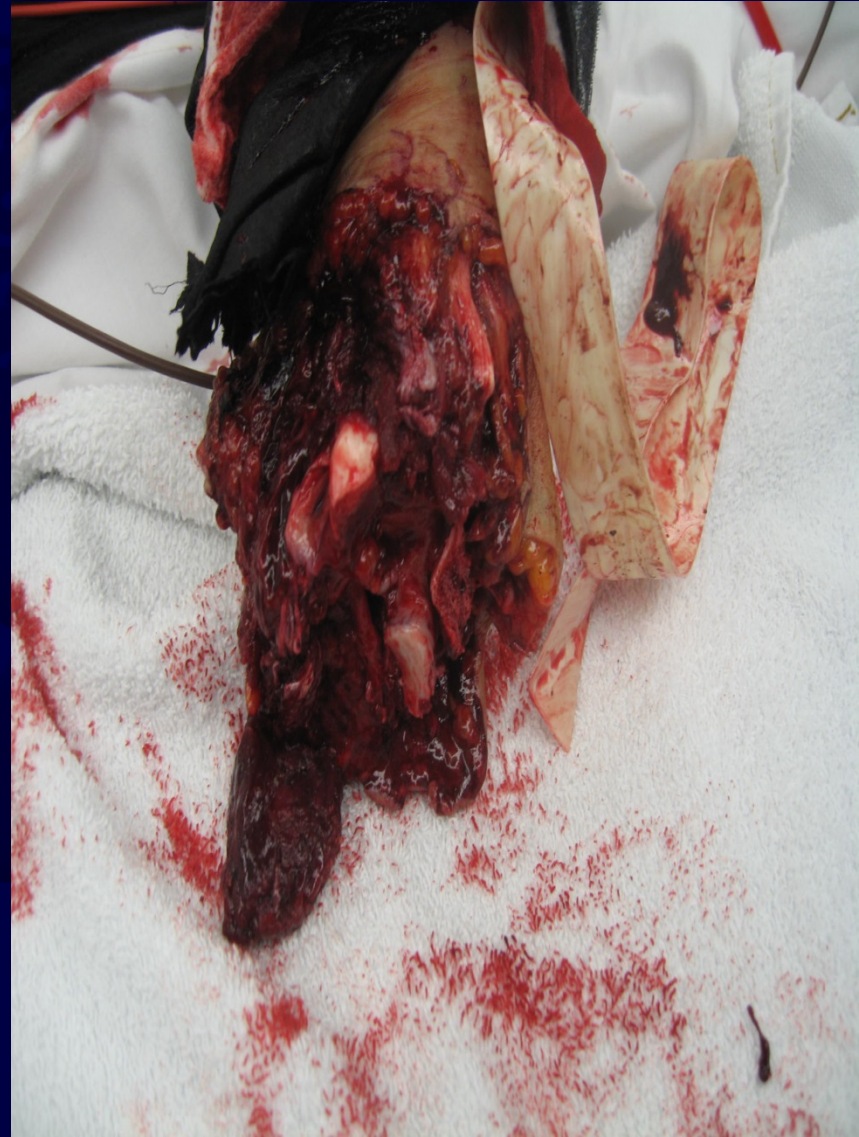
New Author: Gil Ortega, MD, MPH; Revised September 2009
Original Author: David Sanders, MD; Created January 2006

Objectives

- Review multi-disciplinary approach to evaluation and treatment of Soft Tissue injuries
- Review up to date methods of coverage
 - Open
 - Primary vs. Secondary
 - Skin grafting
 - Flap
- Review Non-surgical and Surgical Options for Soft-Tissue injuries
- Review current literature concerning Soft-Tissue injuries and Wound Coverage Techniques

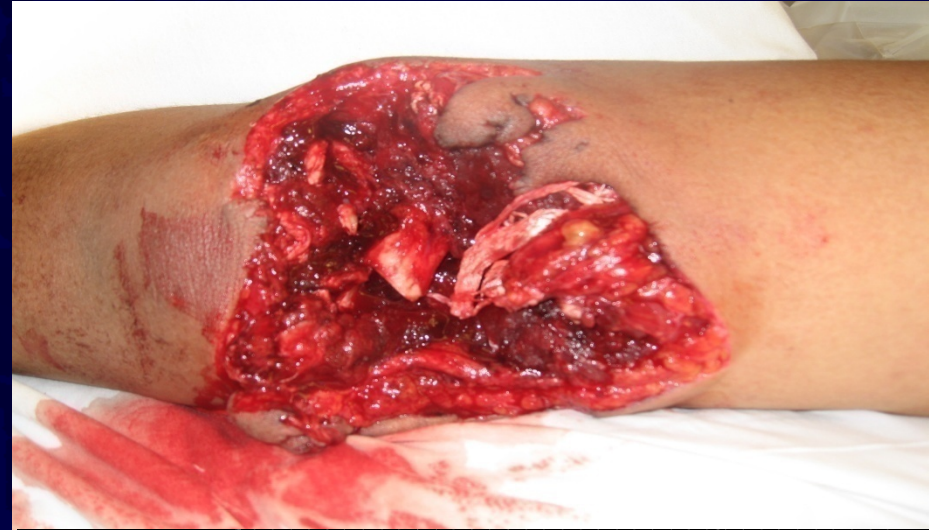Initial Assessment

- History
 - Time and mechanism of injury
 - Functional demands of the patient
 - Patient variables
 - Age
 - Diabetes
 - Malnutrition
 - Obesity
 - Infection
 - Smoker
 - Medications
 - Underlying physiology
 - Occupation

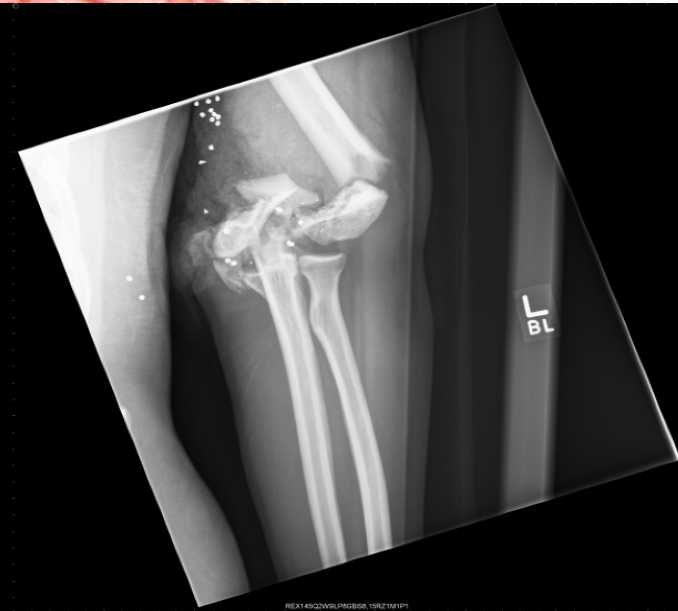

Initial Assessment

- Physical exam
 - Severity of Injury
 - Energy of Injury
 - Morphology of associated fracture
 - Bone loss
 - Blood supply
 - Location



Se:4
Im:1



REX145CZWSLPROGRS198ZTM1P1

Initial Treatment

- Management of soft tissue injury requires:
 - Early aggressive debridement in OR
 - Early intravenous antibiotics
 - Skeletal stabilization
 - Timely soft tissue coverage
 - Tetanus prophylaxis
- Prophylactic antibiotics:
 - 1st generation cephalosporin
 - Clindamycin if penicillin allergy
 - Penicillin for clostridia-prone wounds

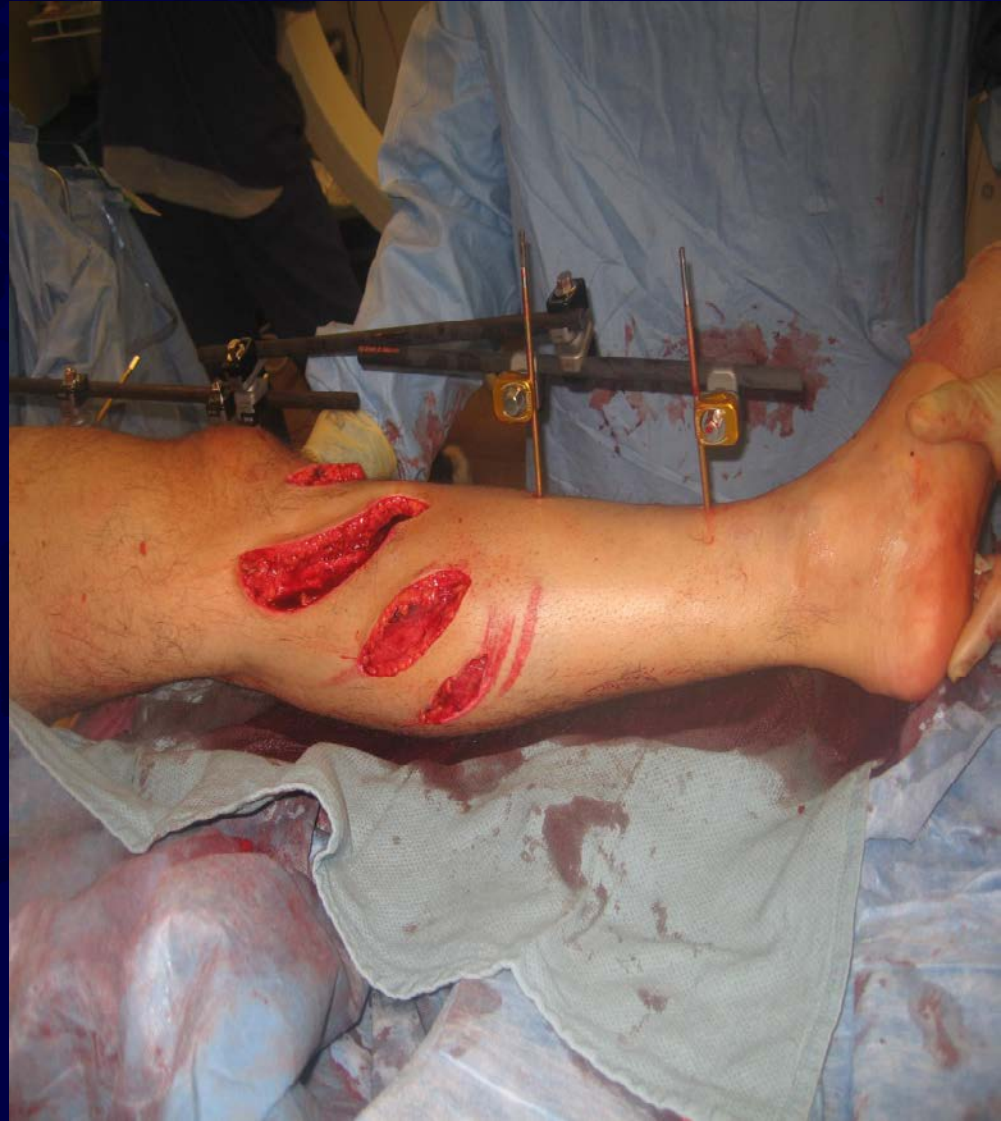Wide Variety of Soft Tissue Injuries; Similar Initial Treatment Options

- Injury:
 - Realignment/splint
 - Neurovascular exam
 - Cover wound with sterile dressing
 - Radiographs



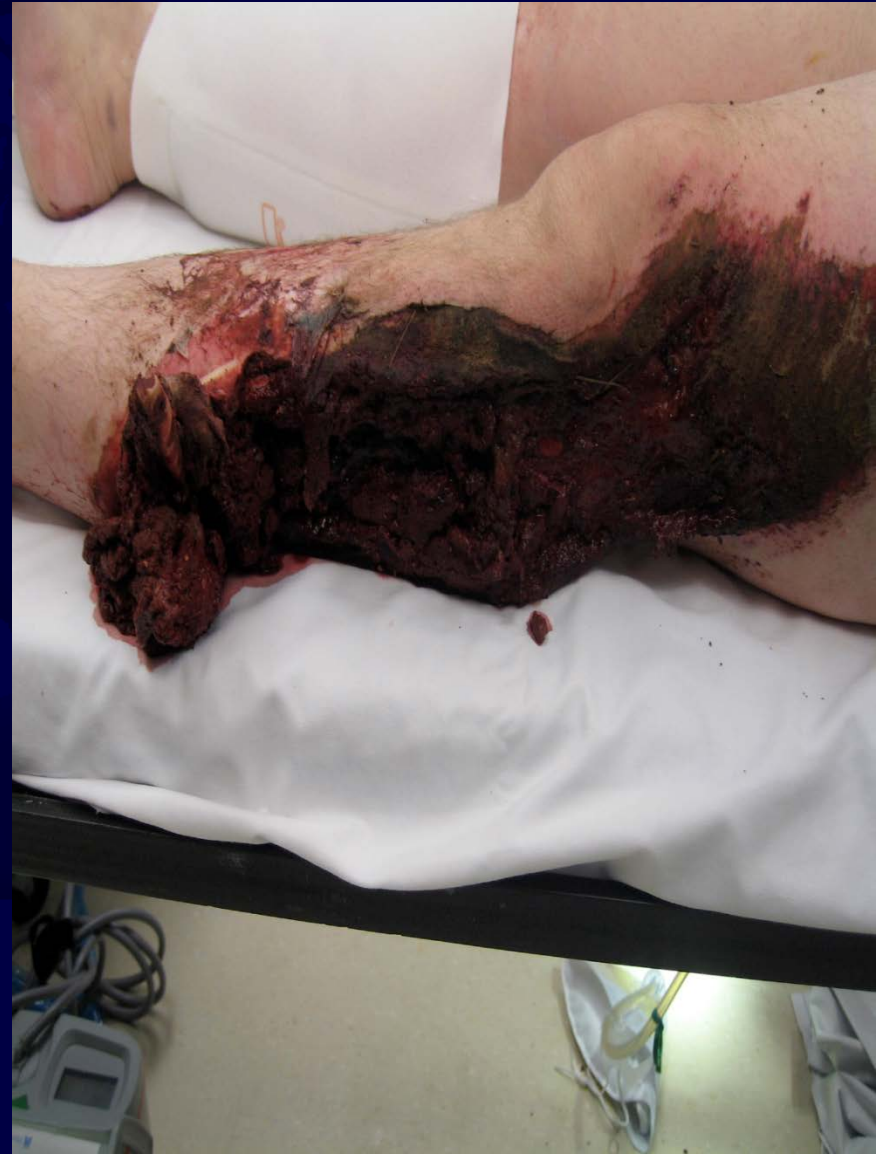Wound Colonization

- Initial colonization of traumatic wound
 - Increases with time
 - Need to debride necrotic muscle, dead space, and poorly vascularized tissue including bony injuries



Wound Excision- Debridement

- Conversion of traumatic wound to a “surgical” wound with debridement of all devitalized tissue – skin, fascia, and bone
- Unless gross contamination, evidence unclear as to best time for operative debridement as to whether 0-6 hours, 6-12 hours or > 12 hours to decrease risk of infection, however, patient must receive IV antibiotics promptly



Tripuraneni K et al. **The Effect of Time Delay to Surgical Debridement of Open Tibia Shaft Fractures on Infection Rate.** *ORTHOPEDICS* 2008; 31:1195.

Initial Management After Debridement

- Restore vascularity
- Stabilize skeletal injury
 - Splinting
 - External Fixation
 - Early Total Orthopaedic Care vs. Damage Control Orthopaedics
- Repair nerves
- Repair musculotendinous units
- PLAN reconstruction
 - When patient is best physiologically stable
 - When best team is available for reconstruction(s)

Reconstructive Ladder

Methods

Direct closure

Skin Grafts

Local and Regional Flaps

Distant Pedicle Flaps

Free Flaps

Types

Primary

Secondary

STSG

FTSG

Random

Axial

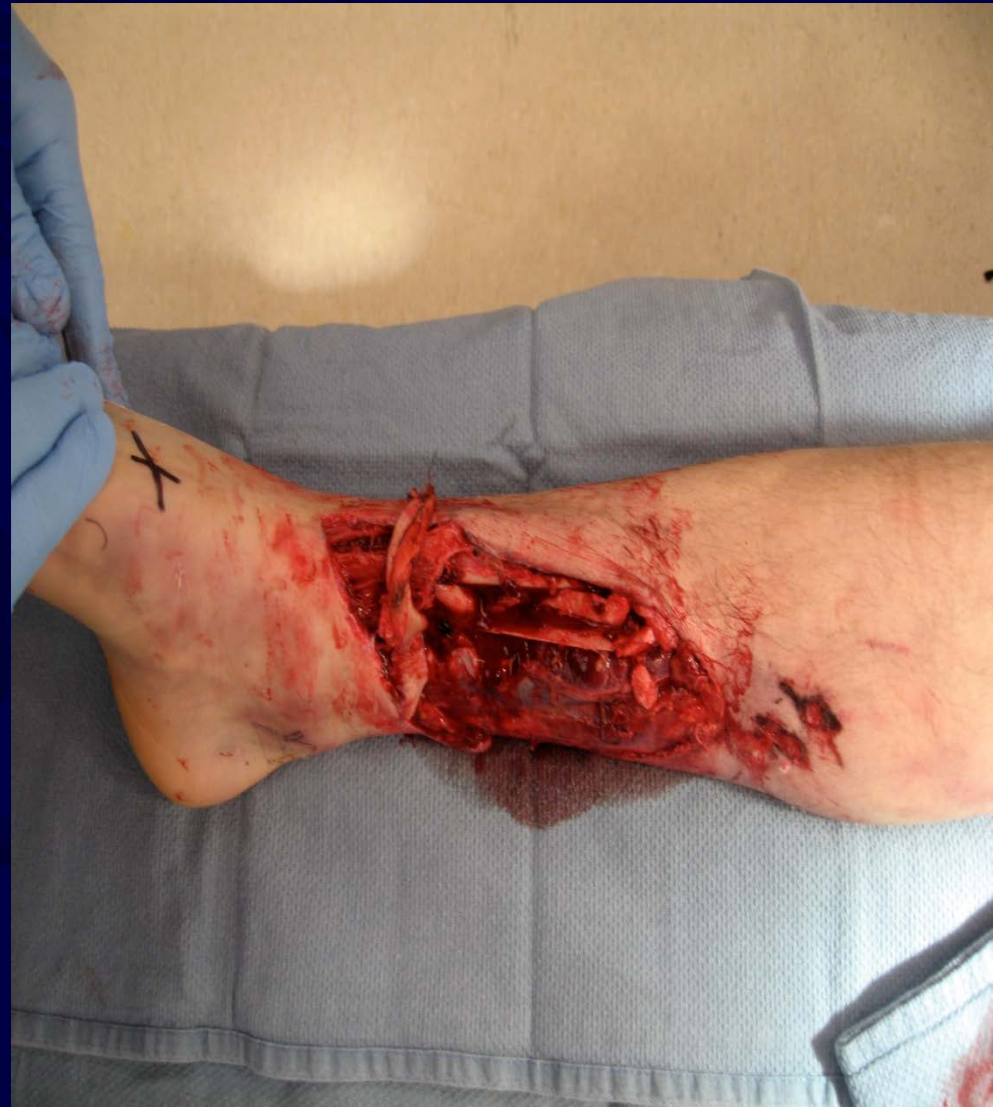Random

Axial

(See next slide)

Reconstructive Ladder

- Free flaps
 - Cutaneous
 - Fascial/
Fasciocutaneous
 - Muscle/
Musculocutaneous
 - Osteocutananeous



Direct Closure

- Direct closure is simplest and often most effective means of achieving viable coverage
- May need to “recruit” more skin to achieve a tension free closure

Direct closure

- Decreasing wound tension can be accomplished by:
 - Relaxing skin incisions
 - “Pie crusting” of the skin under tension (perpendicular to the direction of tension)
 - Application of negative pressure wound therapy

Negative pressure therapy

- Advantages:
 - Increased neovascularization
 - Increased granulation tissue formation,
 - Decreased bacterial count
 - Decreased seroma formation
 - Wound contracture
- Disadvantages:
 - Device Cost
 - Can't see wound when sponge is in place

Negative pressure therapy

Components:

- Apply a polyvinyl sponge to wound
- Impermeable membrane sealing wound from the external environment
- Low or intermittent negative pressure vacuum suction [i.e. KCI Vacuum Assisted Closure, or V.A.C.[®] Therapy System]

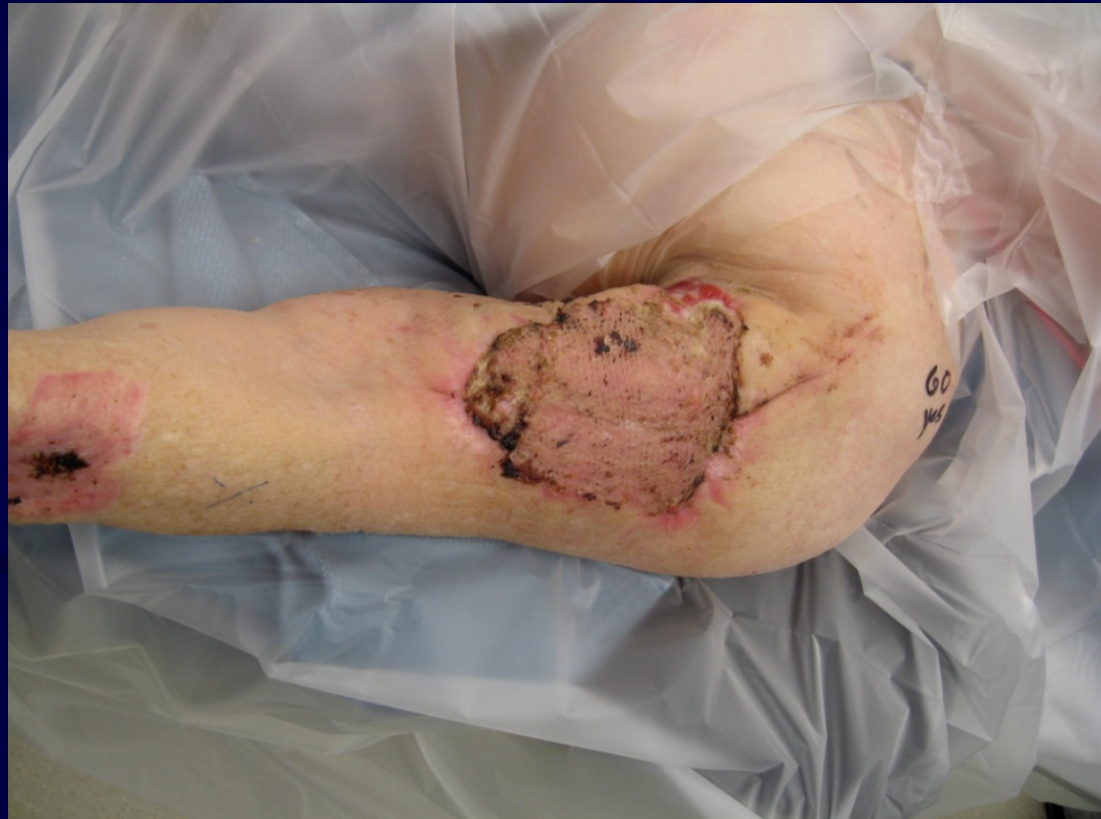Negative pressure therapy

- Routine use of VAC with open tibia fractures is safe
- According to Bhattacharyya et al, in Gustilo Type IIIB tibia fractures, vacuum-assisted closure therapy does not allow delay of soft-tissue coverage past 7 days without a concomitant elevation in infection rates

Bhattacharyya et al. **Routine use of wound vacuum-assisted closure does not allow coverage delay for open tibia fractures.** *Plast Reconstr Surg.* 2008 Apr;121(4):1263-6.

Skin Grafting

- Split thickness (STSG)
- Full thickness (FTSG)



STSG

- **Advantages**

- May be meshed
- Large area
- Require less revascularization
- Temporary coverage

- **Disadvantages**

- Poor cosmesis
- Limited durability
- Contracts over time
- Donor site problems
 - Pain
 - Infection

FTSG

- **Advantages**

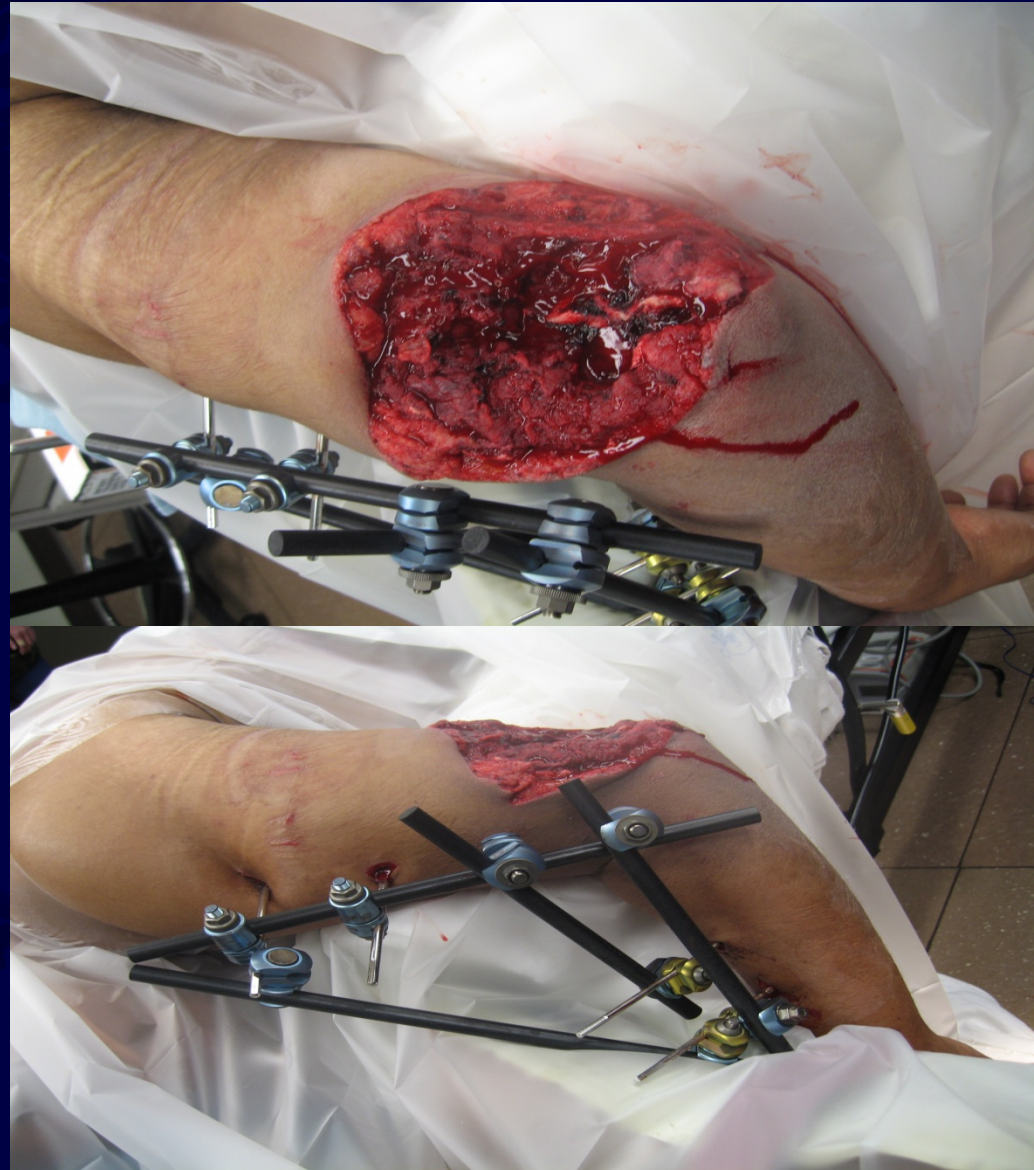- No wound contracture
- Increased sensibility
- Increased durability
- Better cosmesis
- Primary closure of donor site

- **Disadvantages**

- Longer to revascularize
- Cannot mesh
- Recipient site must have rich vasculature

Wound Preparation for Grafts

- Vascularity
- Hemostasis
- Debride all necrotic tissue
- Optimize co-morbid conditions



Donor Site Selection

- **STSG**

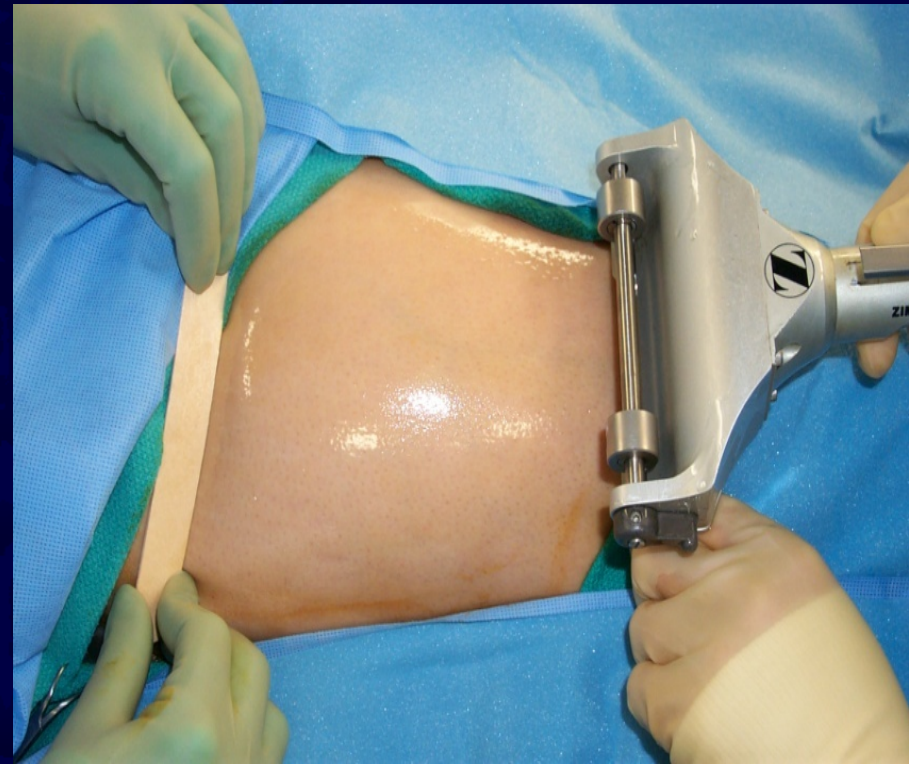- 0.015 inches thick (thickness #15 scalpel)
- Lateral buttock
- Ant. and Lat. Thigh
- Lower abdomen
- Avoid medial thigh and forearm

- **FTSG**

- Depends on area to be covered
- Large grafts-lower abdomen and groin
- Small- medial brachium and volar wrist crease
- Plantar skin from instep

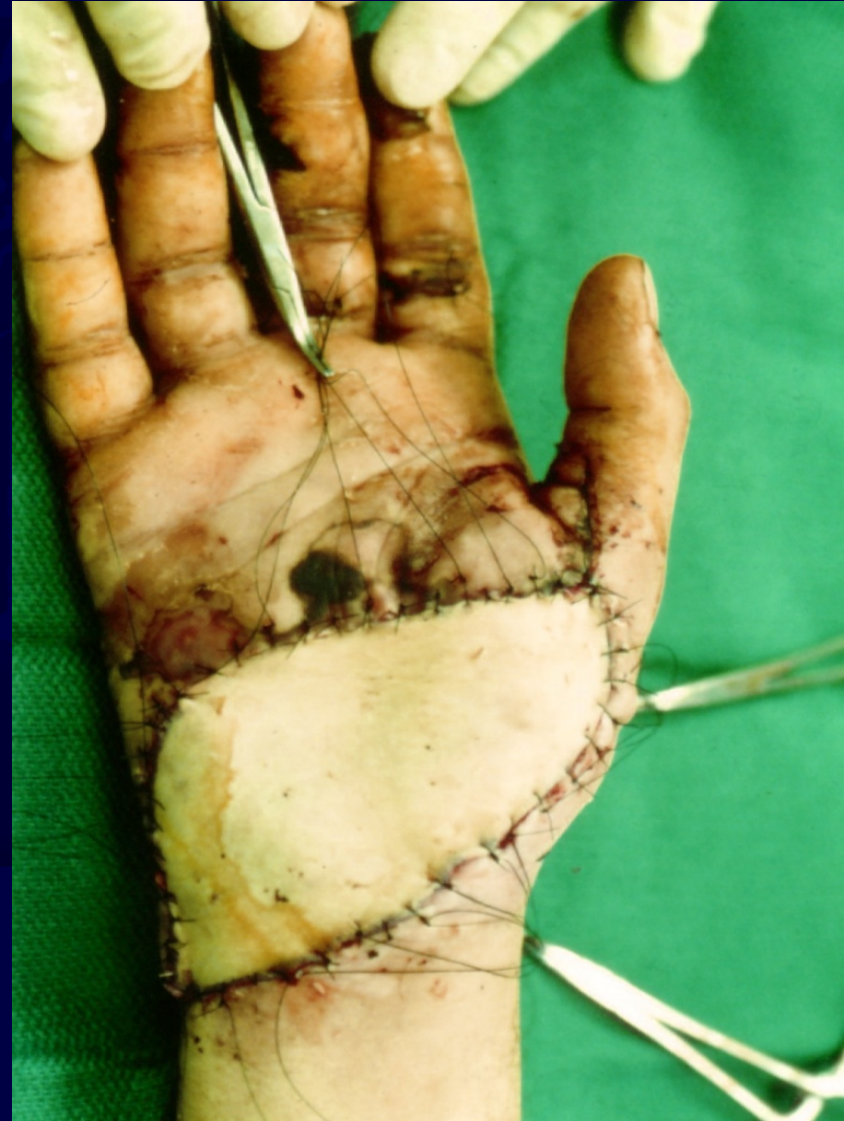Skin Harvest for STSG

- Sterile preparation
- Lubricate
- Set depth (0.012 inch most common)
- Traction with tongue blade
- May use mineral oil for skin



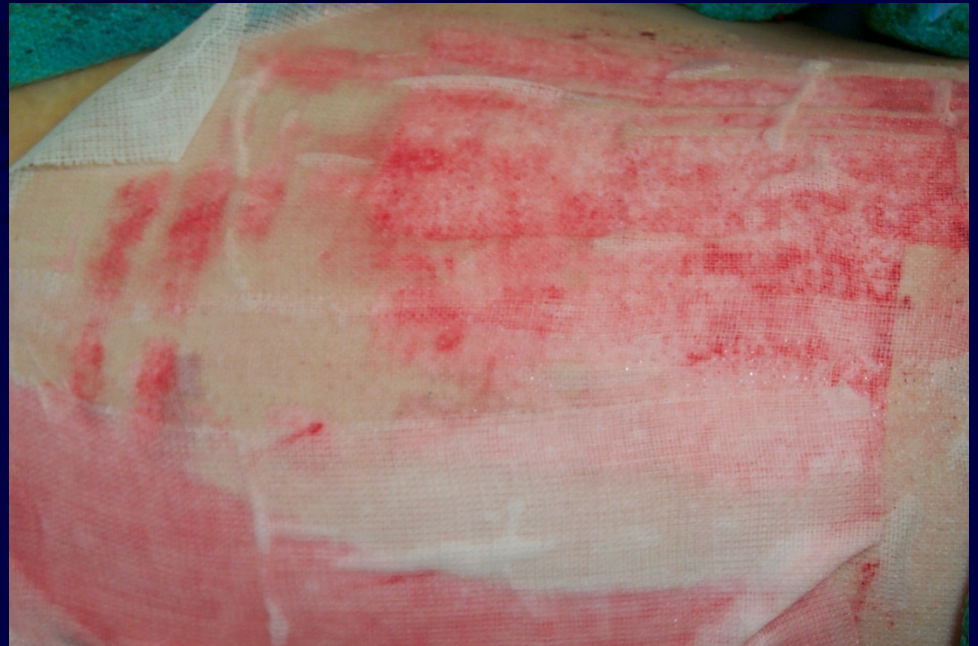
Skin Harvest for FTSG

- Use template
- Cut out ellipse
- Defat after harvest
- Apply and compress with moist bolster



Donor Site Care

- Open
- Semi-open
- Semi-occlusive
- Occlusive
- Biologic



Indications for Flap Coverage

- Skin graft cannot be used
 - Exposed cartilage, tendon (without paratenon), bone, open joints, metal implants
- Flap coverage is preferable
 - Secondary reconstruction anticipated, flexor joint surfaces, exposed nerves and vessels, durability required, multiple tissues required, dead space present

Classification of Soft Tissue Flaps

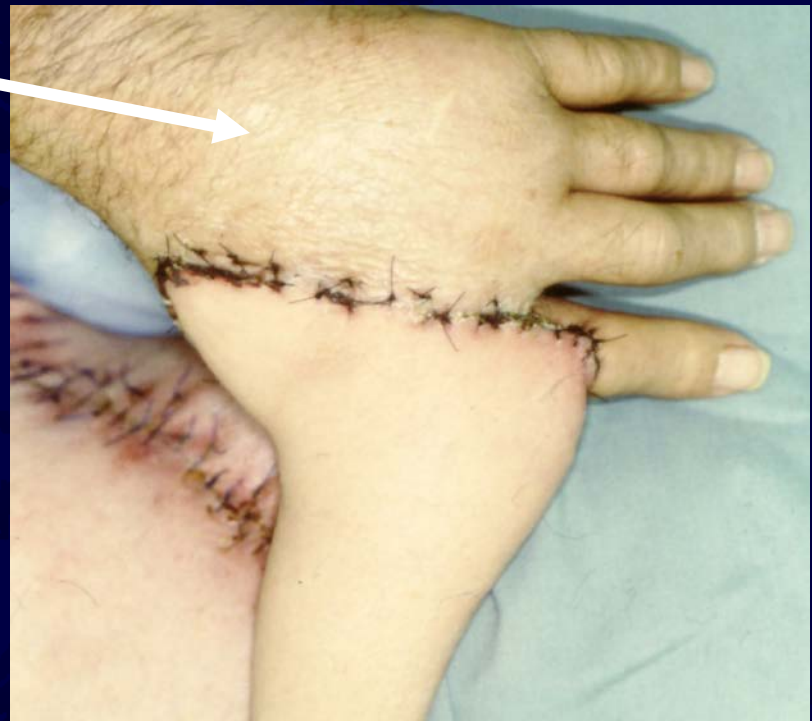- Random
- Axial
- Local
 - Advancement
 - Rotation
- Distant
 - Direct
 - Tubed
 - Free

Classification of Soft Tissue Flaps

- Direct cutaneous
- Musculocutaneous
- Septocutaneous

Direct Cutaneous Flaps

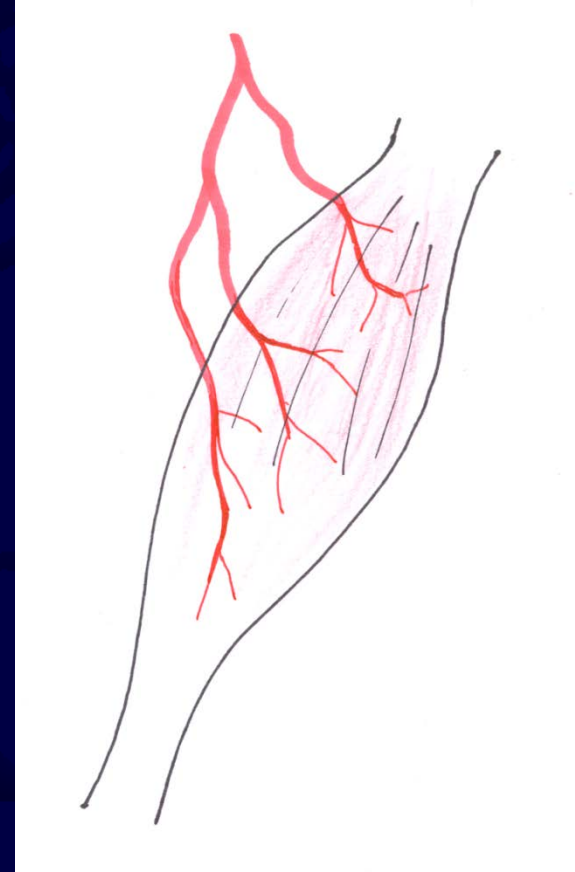
- Groin flap-
superficial
circumflex iliac
artery
- Deltopectoral flap-
2nd and 3rd
perforating br. Of
int thoracic artery



Musculocutaneous Flaps

Mathes Classification

- Type I- one vascular pedicle
 - Gastrocnemius
 - Tensor fascia Lata

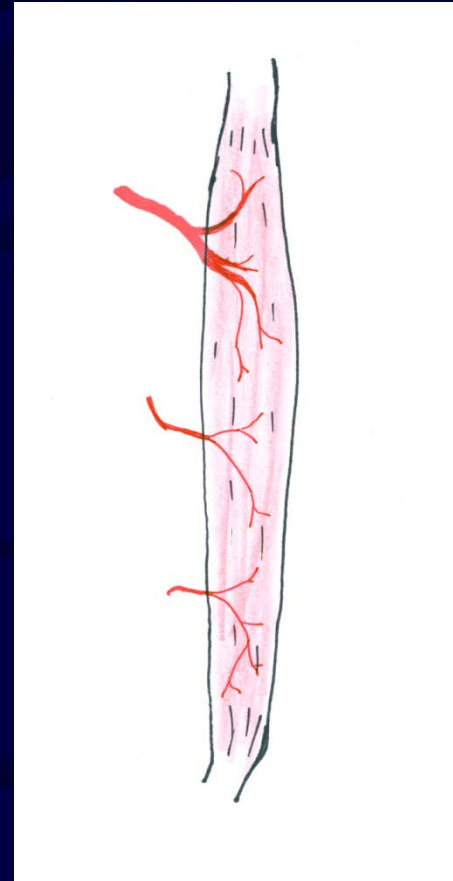


Type I: Tensor Fascia Lata

Musculocutaneous Flaps

Mathes Classification

- Type II- one dominant vascular pedicle close to insertion with additional smaller pedicles entering along the course of the muscle
 - Brachioradialis
 - Gracilis
 - Soleus

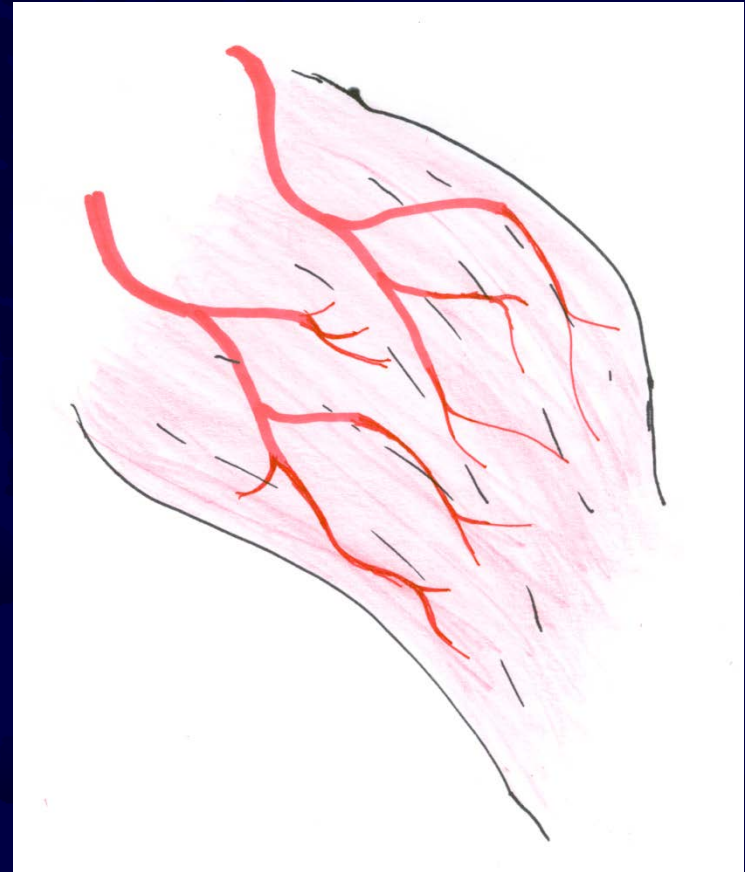


Type II: gracilis

Musculocutaneous Flaps

Mathes Classification

- Type III - two dominant vascular pedicles
 - Rectus abdominis
 - Gluteus maximus

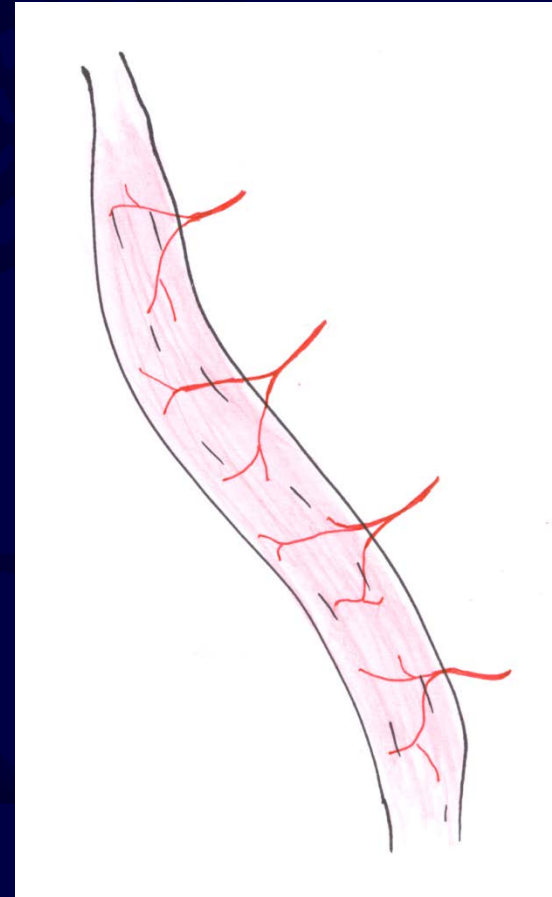


Type III: Gluteus Maximus

Musculocutaneous Flaps

Mathes Classification

- Type IV- multiple pedicles of similar size
 - Generally of less use in reconstruction than single or double pedicled muscles

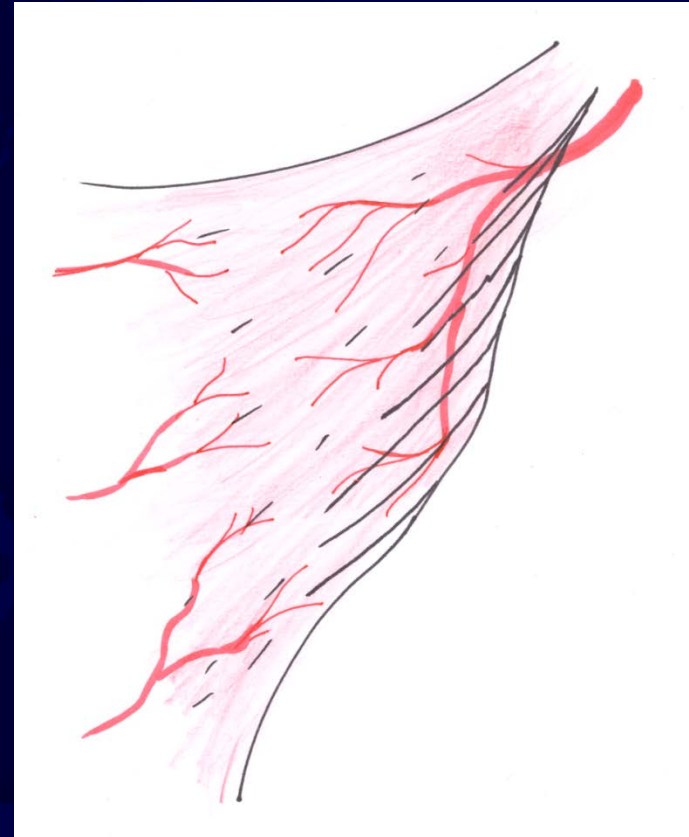


Type IV: Sartorius

Musculocutaneous Flaps

Mathes Classification

- Type V- one dominant pedicle and several smaller segmental vascular pedicles
 - Latissimus Dorsi
 - Pectoralis major



Type V: Latissimus Dorsi

Septocutaneous Flaps

Cormack, et. al

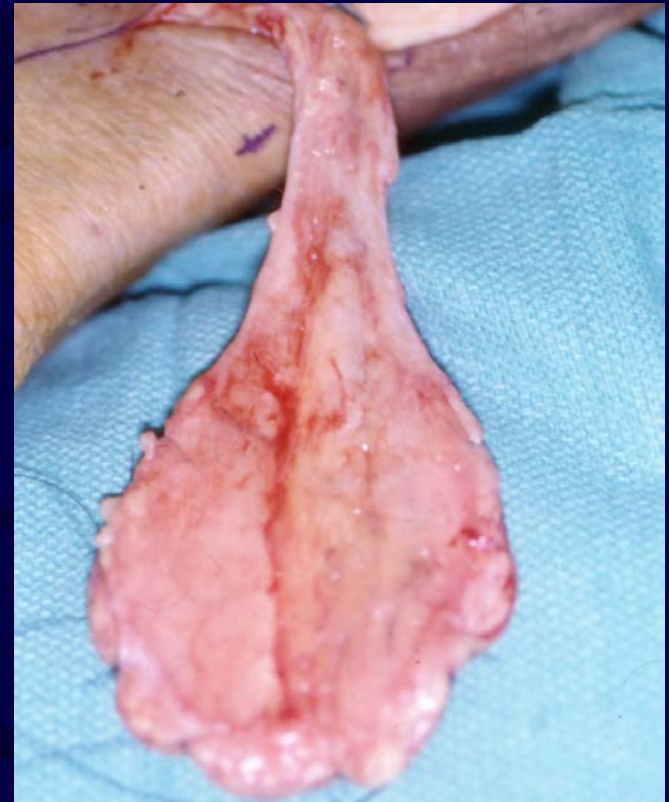
- Type A- flap dependent on multiple fasciocutaneous perforators



Septocutaneous Flaps

Cormack, et. al

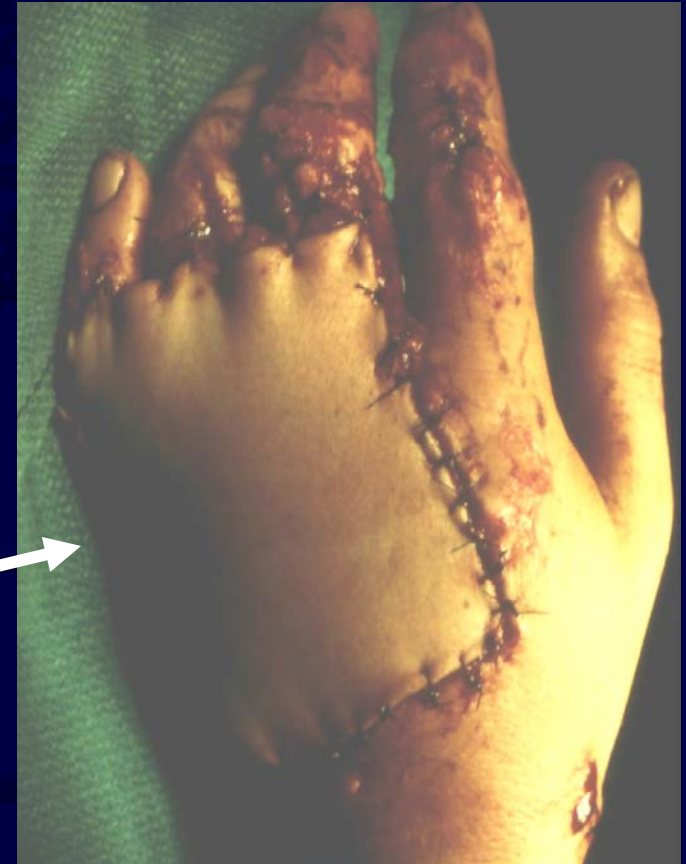- Type B-based on single fasciocutaneous perforator of moderate size consistent in presence and location
- Parascapular flap- circumflex scapular artery
- Saphenous artery flap
- Lateral thigh flap- 3rd profunda perforator



Septocutaneous Flaps

Cormack, et. al

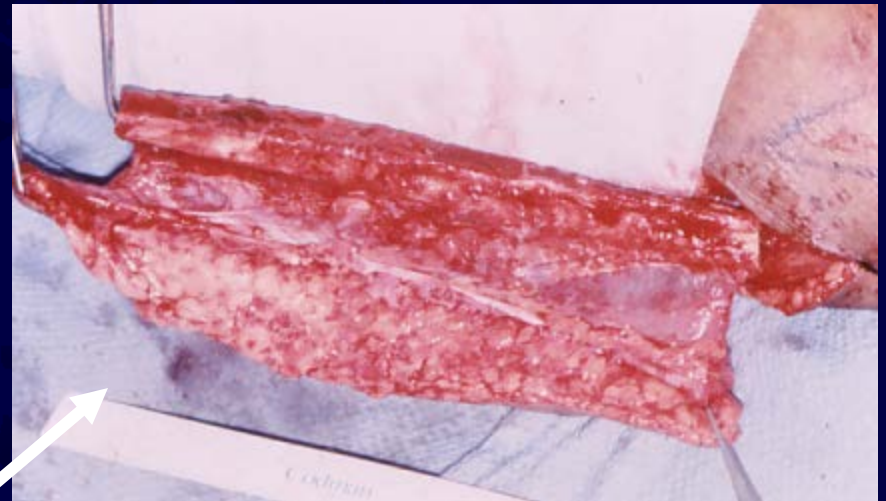- Type C- supported by multiple perforators which pass from a deep artery thru a fascial septum
- Radial forearm flap
- Posterior Interosseous flap



Septocutaneous Flaps

Cormack, et. al

- Type D -type C septocutaneous flap removed in continuity with adjacent muscle and bone to create a osteo- myo- fasciocutaneous flap
- Free fibula osteocutaneous flap



Principles of Free Tissue Transfer

- Pre-operative Assessment
 - Physical Examination
 - Vascular Status
 - Arteriogram
 - Alternative methods
 - Choice of donor site
 - Length and width necessary to fill defect
 - Vascular pedicle length
 - Innervated or composite with bone

Principles of Free Tissue Transfer

- Surgical Considerations
 - Team approach
 - Comfortable setting
 - Anesthesia- regional block/ epidural
 - Temperature
 - Volume replacement
 - Careful surgical technique
 - PREVENT SPASM

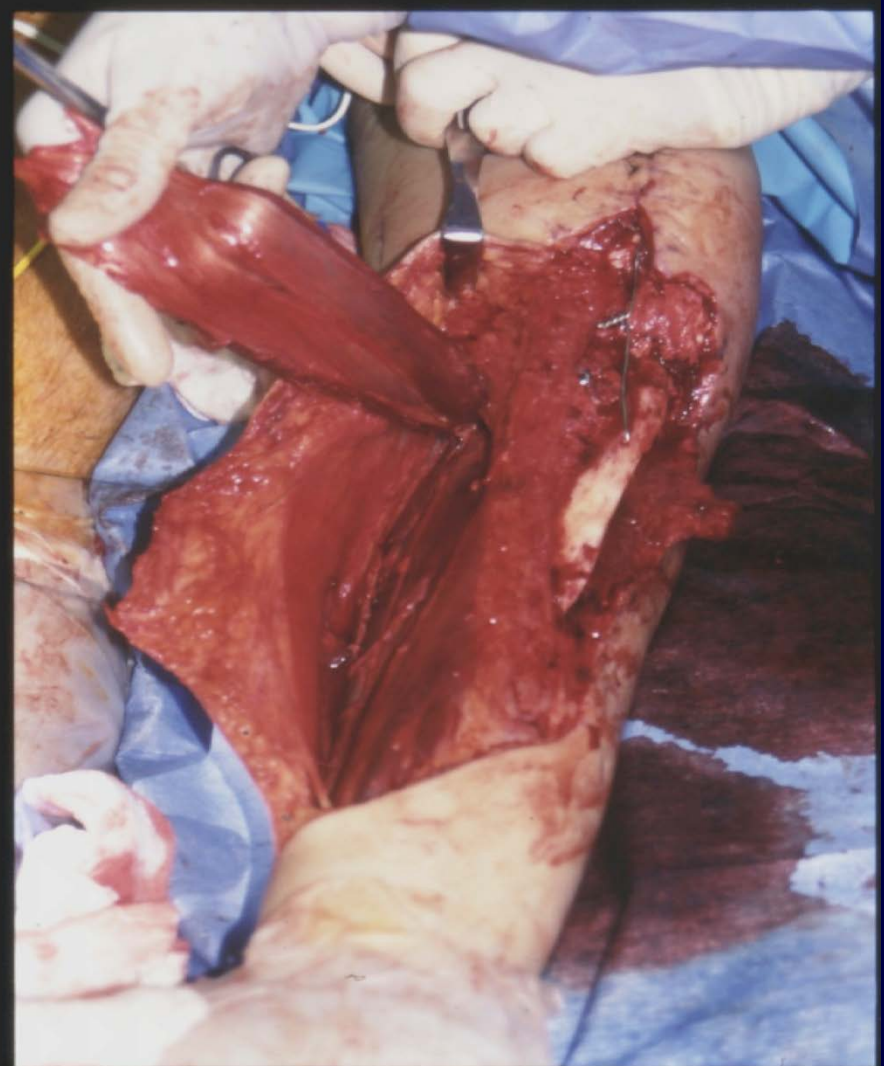
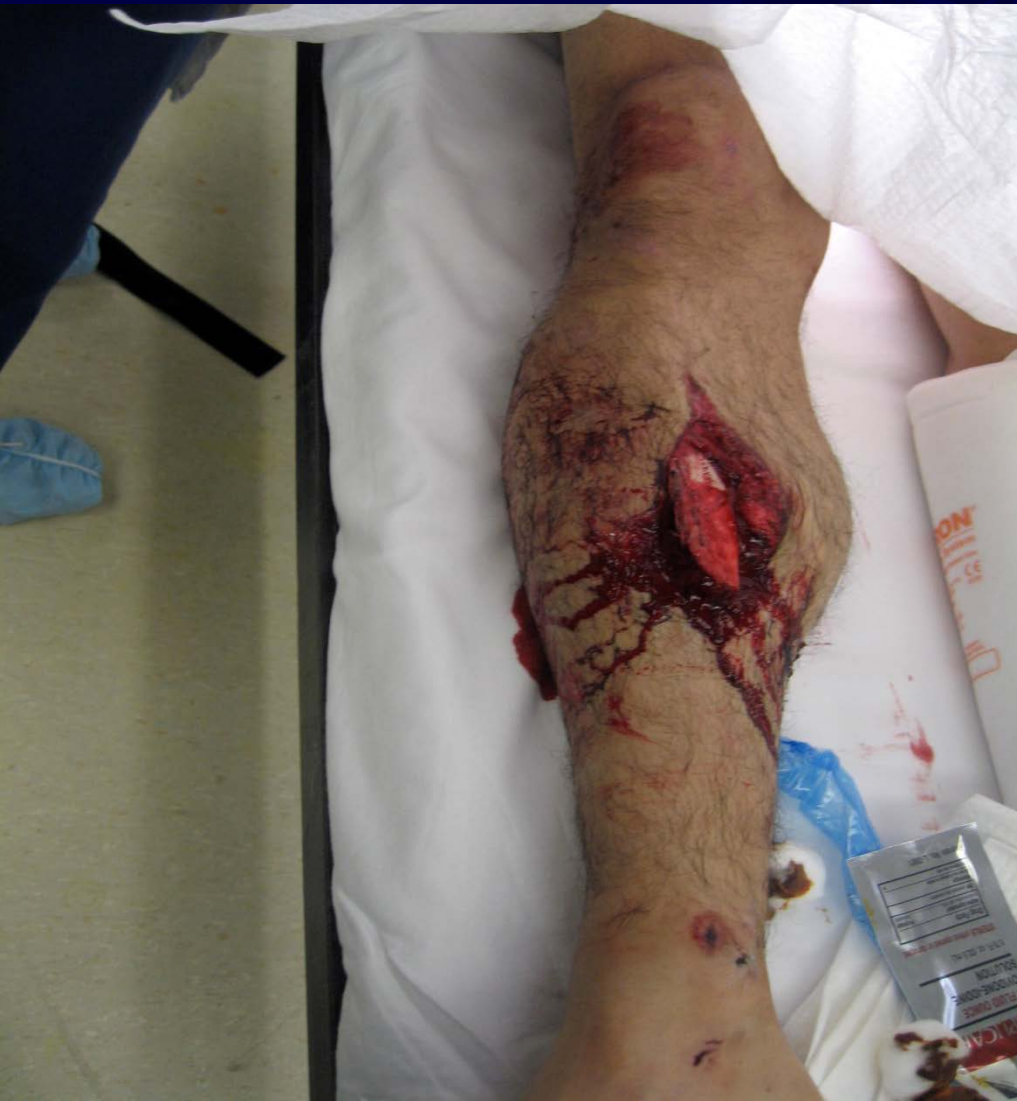Principles of Free Tissue Transfer

- Post-operative Management
 - ICU for monitoring
 - Maintain body temperature
 - Fluid balance
 - Good pain relief
 - Monitoring flap- temperature, doppler, photoplethysmography

Soft Tissue Coverage for the Tibia

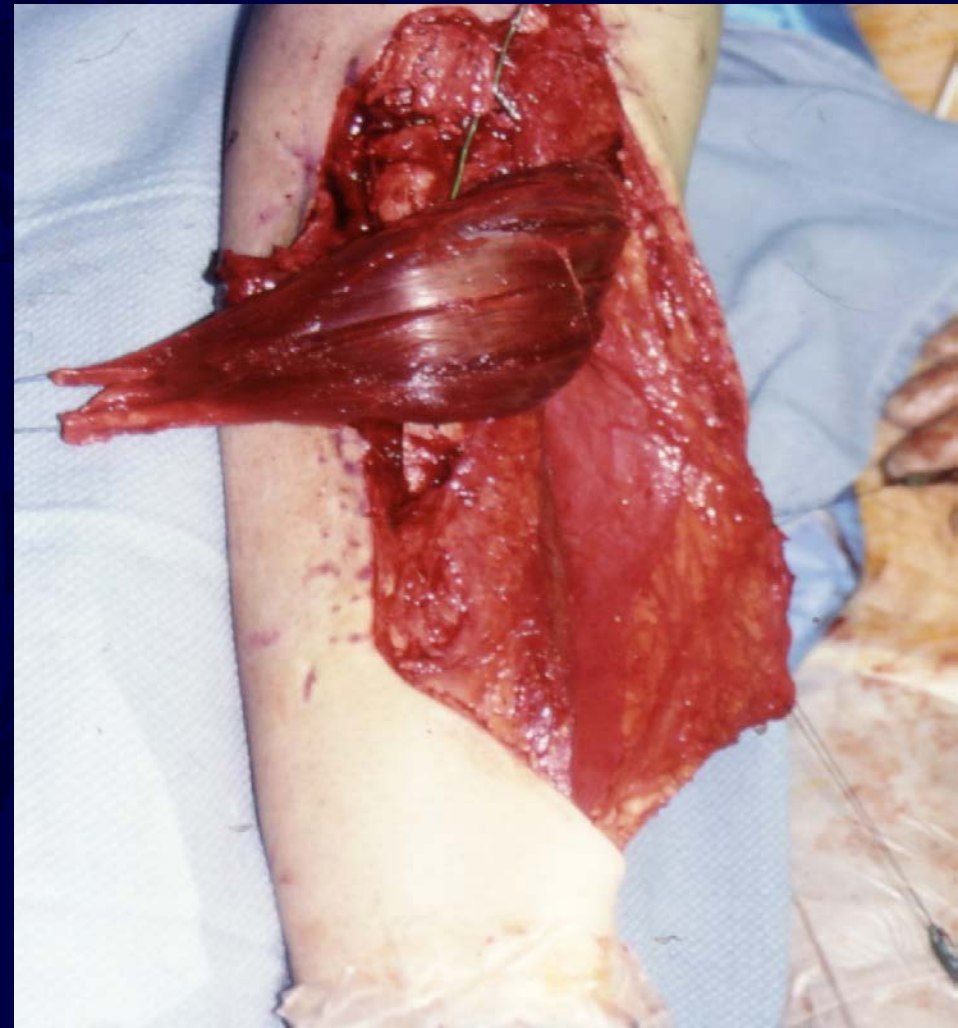
- Conventional teaching
 - Proximal 1/3 Tibial defect- Gastrocnemius rotational flap
 - Middle 1/3 Tibial defect - Soleus rotational flap
 - Distal 1/3 Tibial defect - free flap
 - Large defect- Latissimus Dorsi
 - Smaller defect- radial forearm, Sural artery Fasciocutaneous flap

Medial Gastrocnemius for Proximal 1/3 Tibia

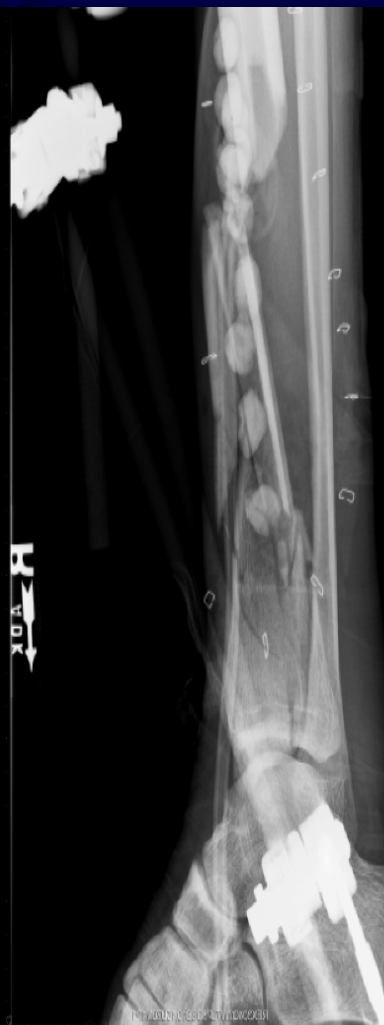
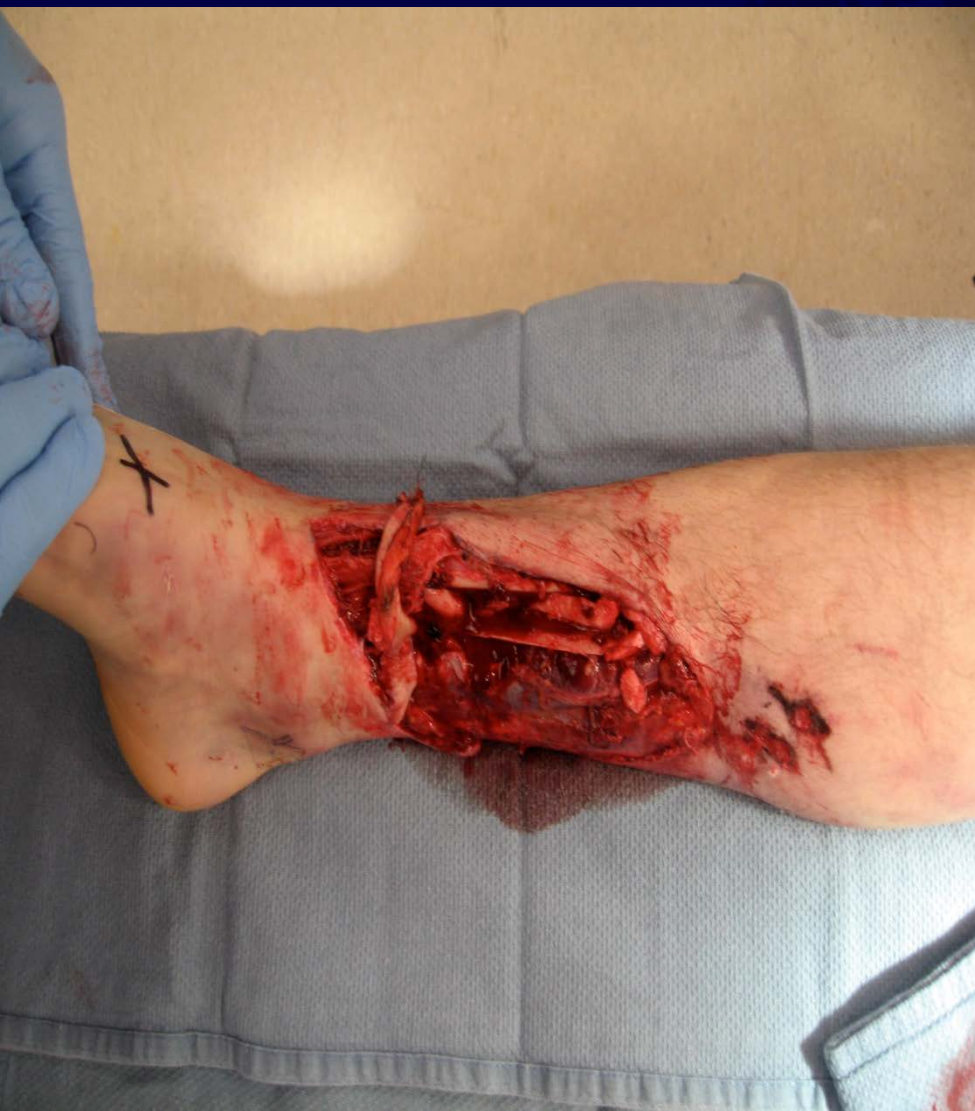
Soft Tissue Coverage for the Middle 1/3 Tibia

- Soleus flap
- Narrower muscle belly compared to gastrocs and a somewhat less robust vascular supply
- Less tolerant of tension compared to gastrocs flap so harvesting and mobilization of muscle belly can be technically demanding



Soft Tissue Coverage for the Distal 1/3 Tibia



Soft Tissue Coverage for the Tibia

- When treating limbs with severe underlying bone injury (ASIF/ OTA type C), use of a free flap for soft tissue coverage was less likely to have a wound complication than use of a rotational flap, regardless of location.
 - Zone of injury may be larger than anticipated and may include rotated muscle
 - More muscle tissue available in free flaps

Soft Tissue Coverage for the Tibia

- Timing: best results obtained with early soft tissue coverage (< 72 hours) for Type III-B open tibial fractures
- Definitive bony and soft tissue surgery may not always be possible within 72 hours because of concomitant injuries or delayed referral
- Therefore, according to Steiert AE and Karanas et al., both groups have showed high success rates with delayed (> 72 hours) with meticulous microsurgical treatment planning and vessel anastomoses outside of zone of injury
- Steiert et al. have shown that the use of Damage Control Orthopaedics may enable surgeon to treat injury definitely beyond 72 hour window with similar results to that of definitive surgeries within 72 hours

Steiert AE et al. *J Plast Reconstr Aesthet Surg*. 2009 May;62(5):675-83.

Karanas et al. *Microsurgery*. 2008;28(8):632-4

Cierny G. et al. *Clin Orthop* 178: 54-63, 1983

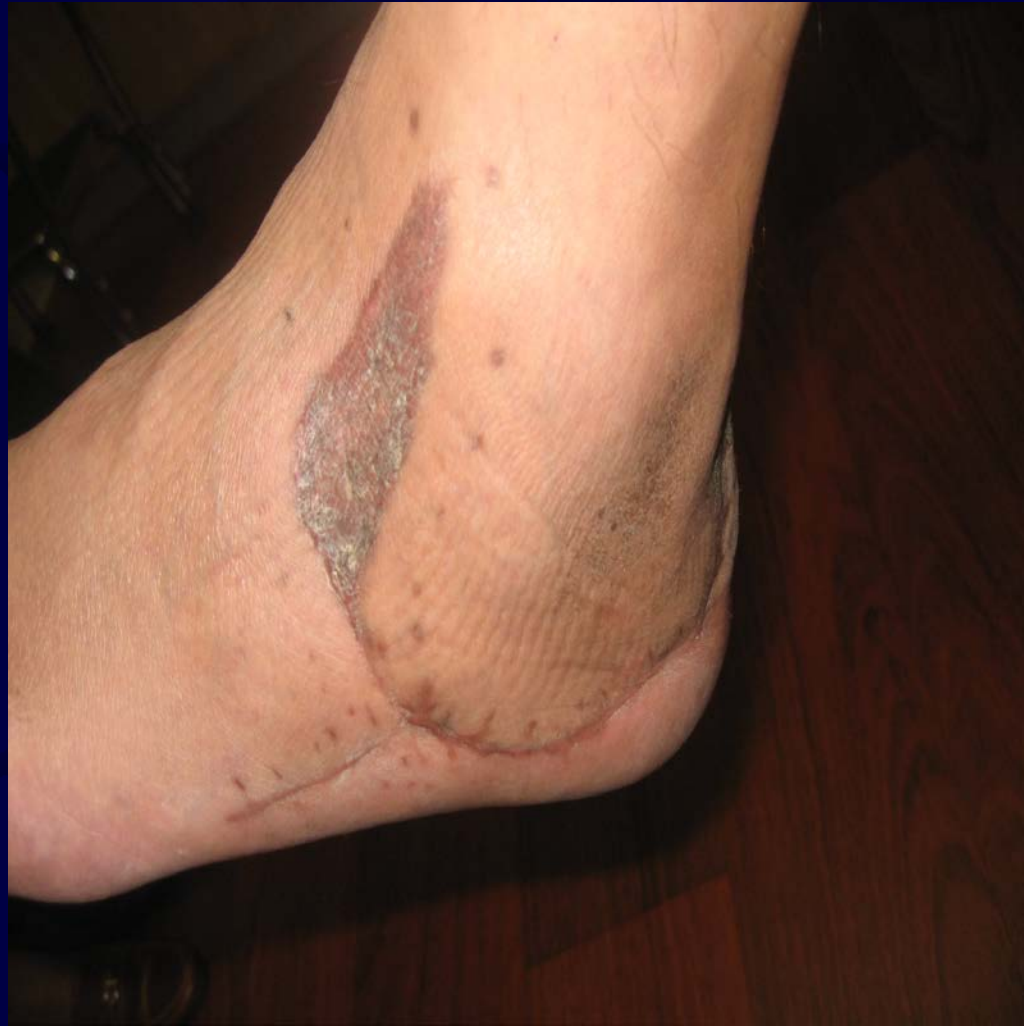Fischer et al. *JBJS* 73-A: 1316-1322, 1991

Godina M. *Plat Reconstr Surg* 78: 285-293, 1986

Soft Tissue Coverage of the Ankle/ Foot

- Open wounds in this area remain a challenge
- Donor site options
- Medial plantar flap for reconstruction of the heel
- Abductor hallucis flap
- Flexor digitorum brevis

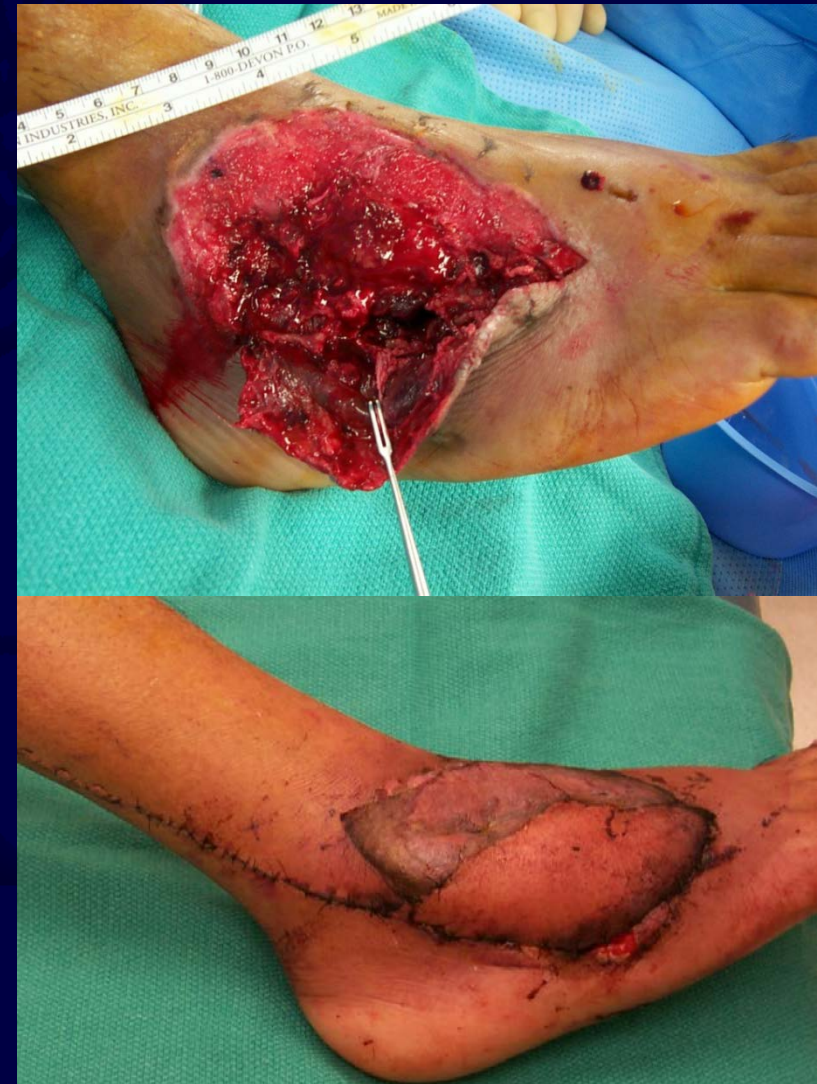Soft Tissue Coverage of the Ankle/ Foot



Soft Tissue Coverage of the Ankle/ Foot

- Increasingly popular method among reconstructive surgeons is use of a distally based sural artery flap
- Supplied by most distal perforating artery of peroneal artery which is located approximately 5-7 cm above tip of lateral malleolus
- According to Ríos-Luna et al, the sural fasciocutaneous offers technical advantages such as easy dissection with preservation of more important vascular structures in limb, complete coverage of soft tissue defect without need of microsurgical anastomosis

Ríos-Luna et al. Versatility of the sural fasciocutaneous flap in coverage defects of the lower limb. *Injury*. 2007 Jul;38(7):824-31.



Soft Tissue Coverage of the Elbow

- Skin graft for wounds that are well-vascularized without injury to neurovascular or osseous structures.

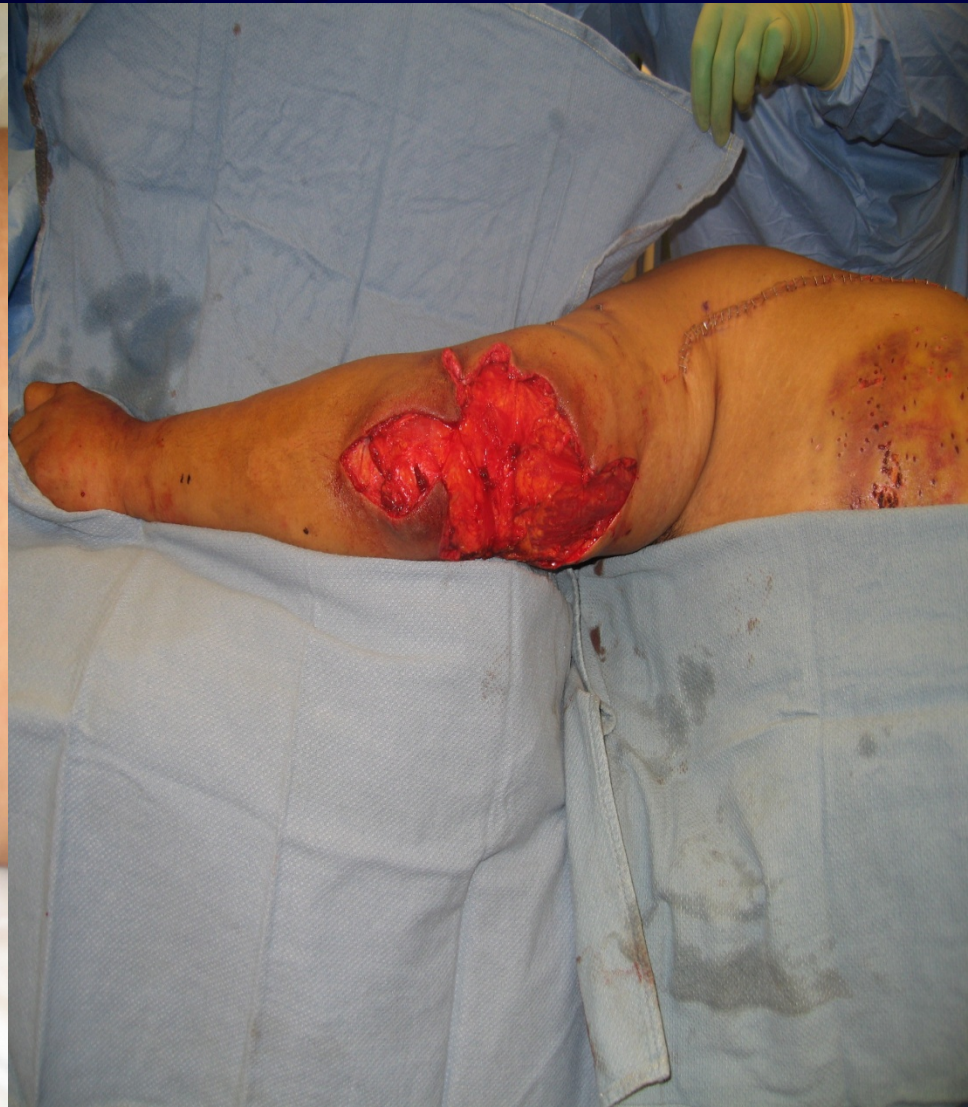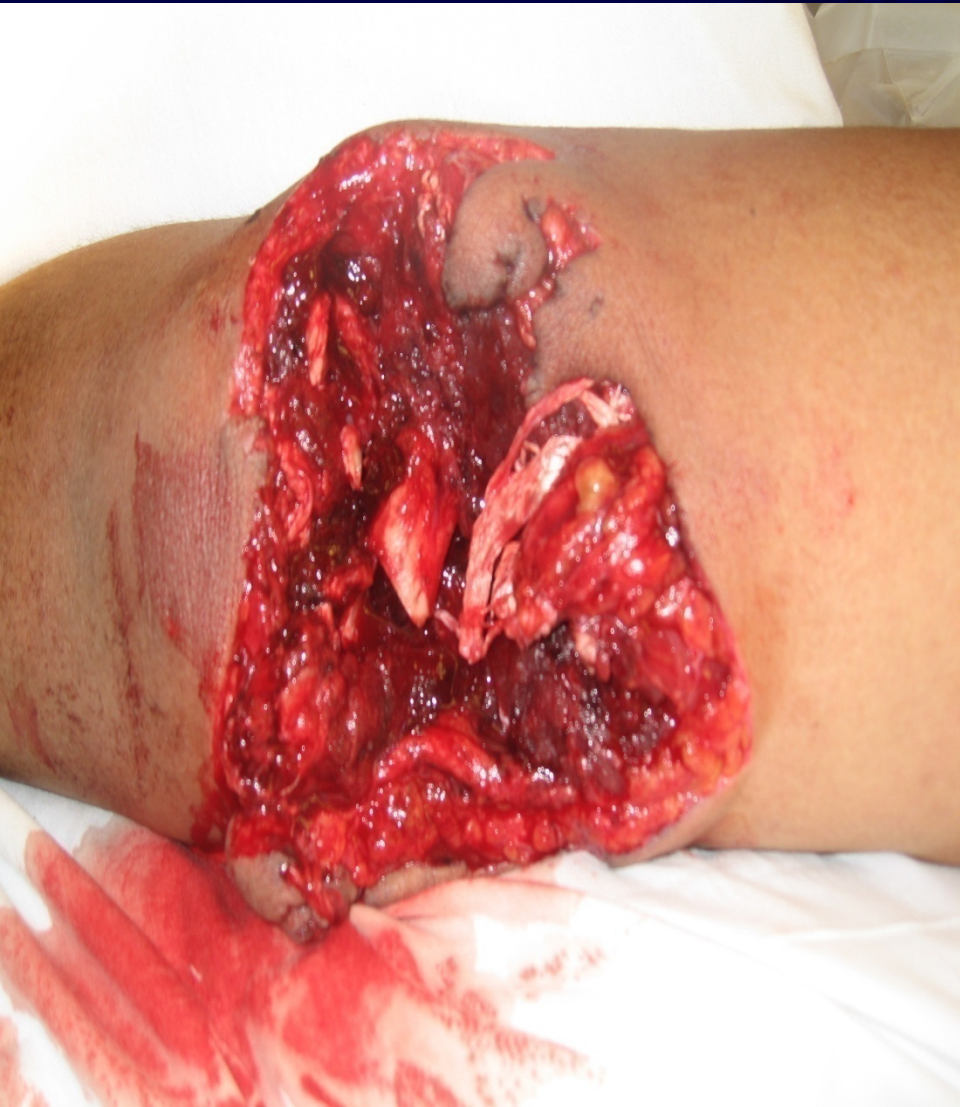Soft Tissue Coverage of the Elbow

- Flaps
 - Infection or dead space-use muscle flap
 - Extensive soft tissue avulsion- parascapular flap
 - Functional restoration of elbow flexion - latissimus dorsi

Considerations for Flap Coverage of the Elbow

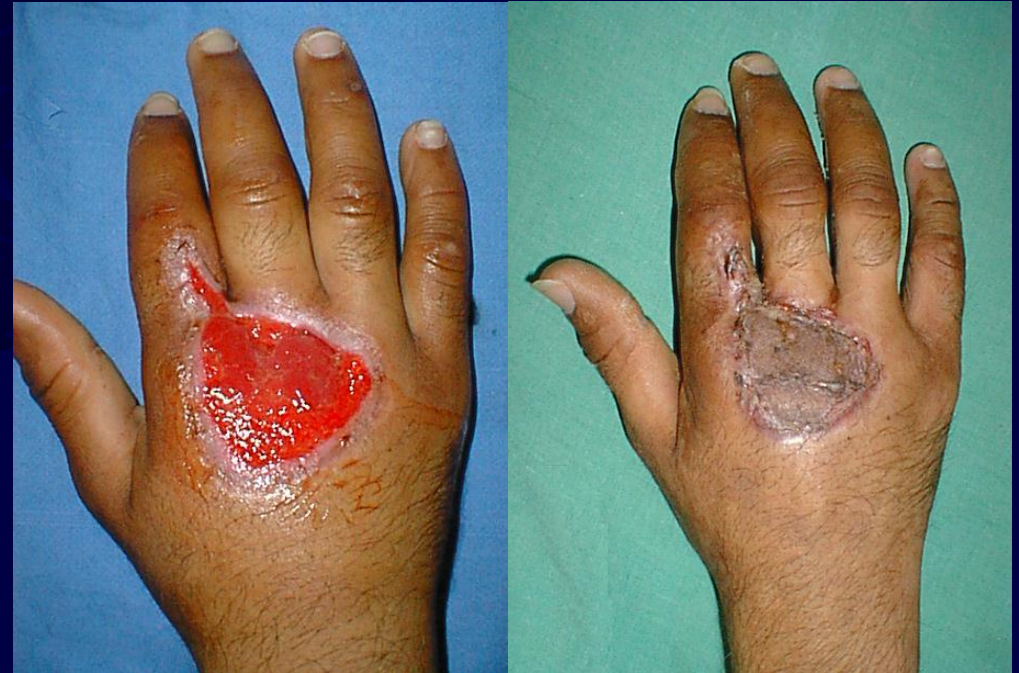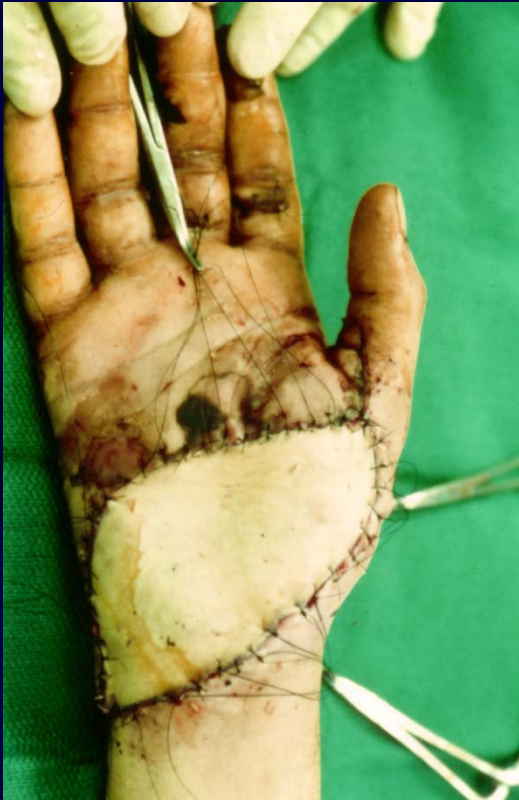- Regional
 - FCU- Ulnar recurrent artery
 - Brachioradialis- radial recurrent artery
- Intermediate
 - Radial artery fascio-cutaneous flap
 - Posterior Interosseous flap
- Distant pedicle
 - Latissimus dorsi - Thoracodorsal artery
 - Serratus anterior- Thoracodorsal artery
- Free tissue transfer
 - Latissimus dorsi
 - Rectus Abdominis - deep inferior epigastric
 - Parascapular - circumflex scapular artery

Flap Coverage of the Elbow: Example of Latissimus Dorsi Local Transfer Flap



Soft tissue coverage of the Hand

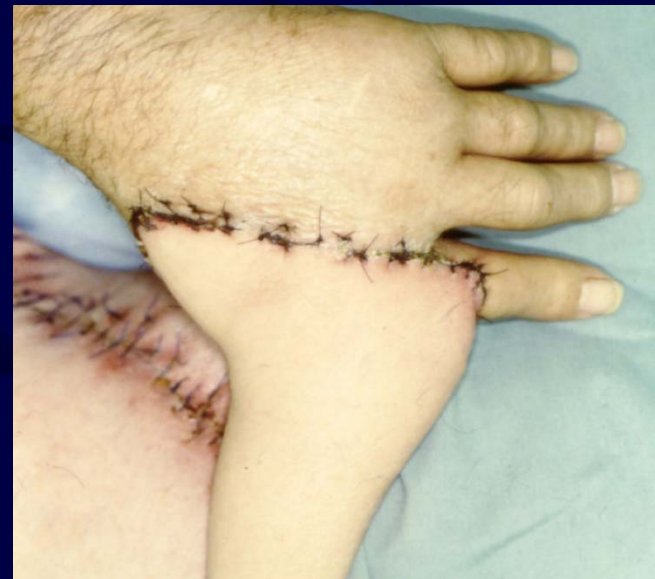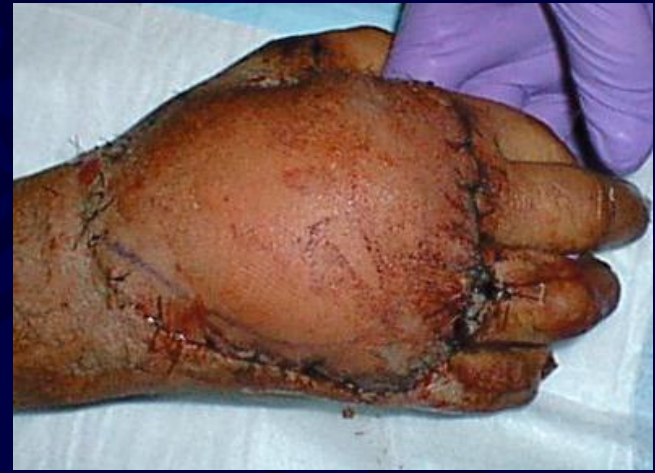- Sheet STSG for dorsum of hand



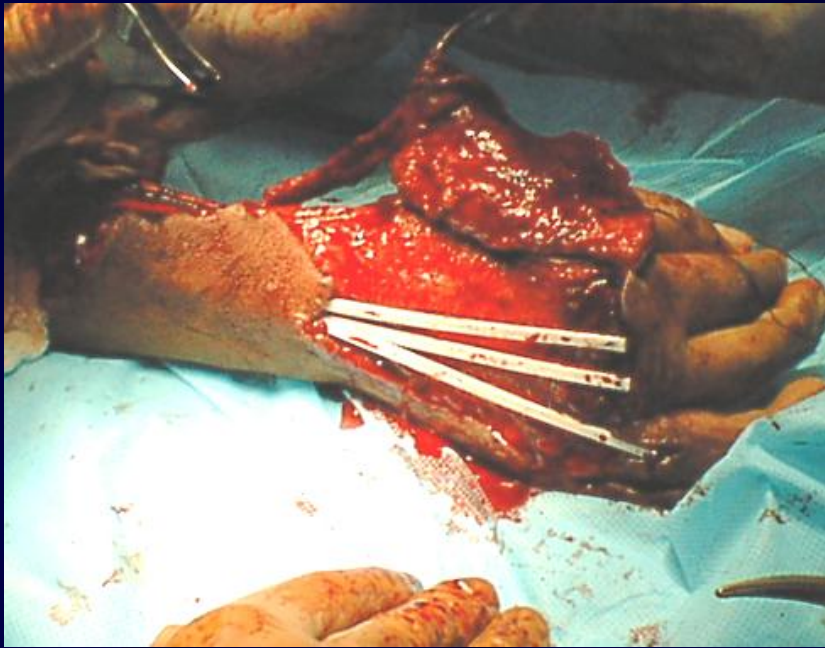
- FTSG for volar aspect of hand

Soft Tissue Coverage of the Hand

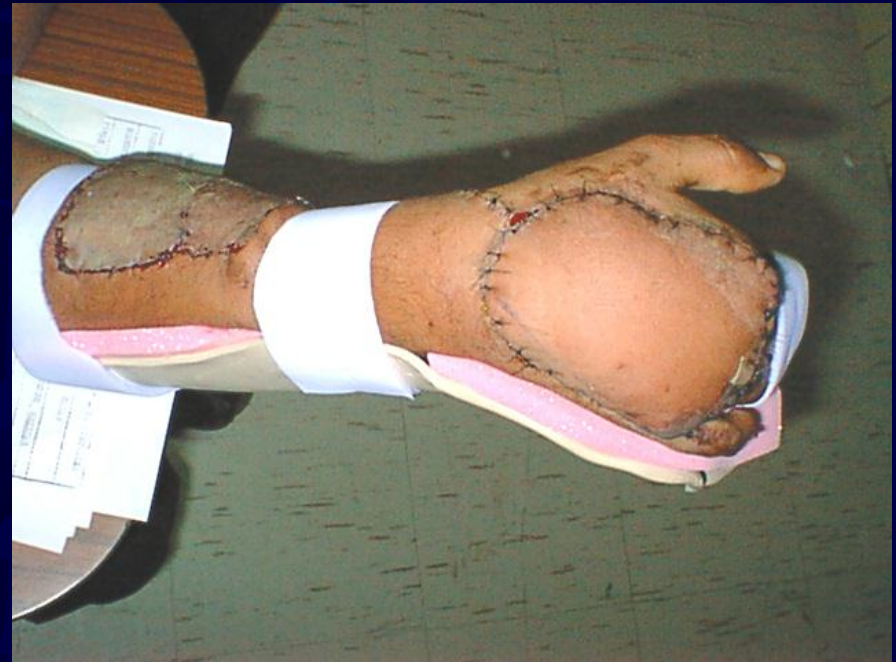
- Common flaps
 - Cross finger flap
 - Thenar flap
 - Radial forearm flap
 - Posterior interosseous flap
 - Groin flap



Flaps for Hand Reconstruction



**Dorsal Soft tissue
avulsion injury**



**Coverage with
radial forearm flap**

Limb Salvage Vs. Amputation

- Lower Extremity Assessment Project (LEAP) study provides evidence for outcomes of limb salvage
- Largest study with followup up to 7 years
- Compares functional outcome of patients with limb salvage vs. amputation

Bosse et al. A prospective evaluation of the clinical utility of the lower extremity injury severity scores. *JBJS Am.* 83: 3-14, 2001.

LEAP Study Major Conclusions

- Limb threatening injuries severely impair patient outcome
- When comparing limb salvage vs. amputation, the patient outcome is generally the same at 1-5 years
- Lack of plantar sensation does not predict poor outcome after limb salvage

LEAP Study Patients with Poor Outcomes

- Rehospitalization of major complication
- Lower level of education
- Non white
- Poverty
- Smokers
- Poor social support
- Involved in social legal compensation

Summary

- Appropriate debridement with first debridement being most important
- Appropriate antibiotic regime
- Appropriate bony stability
- Early coverage to prevent dessication of critical structures and decrease risks of wound infection
- Choose appropriate coverage method
 - Defect requirements
 - Patient needs
 - Surgeon factors
- Protect limb to appropriate healing

References

- **Classical**

- Cierny G. et al. Primary versus delayed soft tissue coverage for severe open tibial fractures. A comparison of results. Clin Orthop 178: 54-63, 1983.
- Fischer et al. The timing of flap coverage, bone-grafting, and intramedullary nailing in patients who have a fracture of the tibial shaft with extensive soft-tissue injury. JBJS 73-A: 1316-1322, 1991.
- Godina M. Early microsurgical reconstruction of complex trauma of the extremities. Plat Reconstr Surg 78: 285-293, 1986.
- Serafin, Donald M.D.: Atlas of Microsurgical Composite Tissue Transplantation. W.B. Saunders Company, 1996.
- Webster, Martyn H. C. MBChB, FRCS (Glasg.), Soutar, David S. MBChB, FRCS (ED.): Practical Guide to Free Tissue Transfer. Butterworth & Co, 1986.

References

- **Classical**

- McCraw, John B. M.D., F.A.C.S., Arnold, Phillip G. M.D., F.A.C.S., et al: McCraw and Arnold's Atlas of Muscle and Musculocutaneous Flaps, Hampton Press Publishing Co.,1986.
- Cormack, George C. MA, MB, ChB, FRCS(ED), Lamberty, B. George H. MA, MB, BChir, FRCS: The Arterial Anatomy of Skin Flaps. Churchill Livingstone, 1986.
- Moy, Owen J. M.D., et al: Soft Tissue Management of Complex Upper Extremity Wounds. W.B. Saunders Company, 13-2: 163-318, May 1997.

References

- **Technique/Outcomes/Recent articles**

- Tripuraneni K et al. The Effect of Time Delay to Surgical Debridement of Open Tibia Shaft Fractures on Infection Rate. *ORTHOPEDICS* 2008; 31:1195.
- Bhattacharyya et al. Routine use of wound vacuum-assisted closure does not allow coverage delay for open tibia fractures. *Plast Reconstr Surg.* 2008 Apr;121(4):1263-6.
- Pollak, et.al. Short-Term Wound Complications After Application of Flaps for Coverage of Traumatic Soft-Tissue Defects About the Tibia. *JBJS* 82-A: 1681-1691, 2000.
- Steiert AE et al. Delayed flap coverage of open extremity fractures after previous vacuum-assisted closure (VAC) therapy - worse or worth? *J Plast Reconstr Aesthet Surg.* 2009 May;62(5):675-83.
- Karanas et al. The timing of microsurgical reconstruction in lower extremity trauma. *Microsurgery.* 2008;28(8):632-4
- Bosse et al. A prospective evaluation of the clinical utility of the lower extremity injury severity scores. *JBJS Am.* 83: 3-14, 2001.

References

- **Technique/Outcomes/Recent articles**

- Reuss BL et al. Effect of delayed treatment on open tibial shaft fractures. *Am J Orthop.* 2007 Apr;36(4):215-20.
- Gopal S et al. Fix and flap: the radical orthopaedic and plastic treatment of severe open fractures of the tibia. *J Bone Joint Surg Br.* 2000 Sep;82(7):959-66.
- Yazar S et al. One-stage reconstruction of composite bone and soft-tissue defects in traumatic lower extremities. *Plast Reconstr Surg.* 2004 Nov;114(6):1457-66.
- Yazar S et al. Outcome comparison between free muscle and free fasciocutaneous flaps for reconstruction of distal third and ankle traumatic open tibial fractures. *Plast Reconstr Surg.* 2006 Jun;117(7):2468-75; discussion 2476-7.

Thank You

Gil Ortega, MD, MPH
Sonoran Orthopaedic Trauma Surgeons
Site Director, Phoenix Orthopaedic
Residency Program
Scottsdale Healthcare Trauma Center
Scottsdale, AZ

If you would like to volunteer as an author for the Resident Slide Project or recommend updates to any of the following slides, please send an e-mail to ota@ota.org

[Return to
General/Principles
Index](#)

